Morphology of the Southern Ground-Hornbill (*Bucorvus leadbeateri*) gastro-intestinal tract

by

Anel Delene Naude

BSc

Submitted in partial fulfilment in accordance with the requirements

for the degree of

MSc Veterinary Science

in the subject

Veterinary Anatomy and Physiology

at the

DEPARTMENT OF ANATOMY AND PHYSIOLOGY

FACULTY OF VETERINARY SCIENCE

PRETORIA

2020

Supervisor:

Associate Professor Martina Rachel Crole Department of Anatomy and Physiology Faculty of Veterinary Science University of Pretoria Pretoria

Co-supervisor:

Senior Lecturer Katja Natalie Koeppel Department of Production Animals Faculty of Veterinary Science University of Pretoria Pretoria

DECLARATION:

I declare that the dissertation which I hereby submit for the degree MSc (Veterinary Sciences) at the University of Pretoria is my own work and has not been submitted by me for a degree at another university.

Dedication

To my parents, Juan and Karen Naudé, thank you for your support. Without you I would not have been able to follow my dreams.

My partner, Bennie Smit, thank you for always being there for me and motivating me to be the best I can be. You play a fundamental role in my pursuit of excellence.

My work colleagues and providers, Dr Hill and Dr Le Grange, thank you for allowing me to pursue my studies and giving me the time away from work to complete my degree.

"He will cover you with His feathers and under His wings
And under His wings you will find refuge"

- Psalms 91:4

CONTENTS

ACKNOWLEDGEMENTS

My supervisor, Prof Martina Crole, thank you for shaping me into a researcher. Your guidance can not be quantified.

My cosupervisor, Dr. Katja Koeppel, thank you for al the last minute feedbacks and continuous encouragement.

Dr. Joseph Chamunorwa, The Head of the Department of Anatomy and Physiology, Faculty of Veterinary Science. Your support and guidance assisted greatly in my research project.

The personnel and technical staff of the Department of Anatomy and Physiology. Your willingness to help made the research process effortless.

Mayville Animal Clinic, Dr E Hill and V Le Grange for allowing me to complete my degree with support and understanding.

AgriSETA for financing this research project.

SUMMARY

Morphology of the Southern Ground-Hornbill (*Bucorvus leadbeateri*) gastro-intestinal tract

by

ANEL DELENE NAUDE

SUPERVISOR: Professor Doctor Martina Rachel Crole
CO-SUPERVISOR: Doctor Katja Natalie Koeppel

DEPARTMENT: Department of Anatomy and Physiology, Faculty of Veterinary Science, University of Pretoria, Private Bag X04, Onderstepoort, 0110, Republic of South Africa.

DEGREE: Magister Scientiae (MSc)

The Southern Ground-Hornbill (SGH) is the largest bird species that breeds cooperatively and the only entirely carnivorous hornbill. Currently, there are only an estimated 417 breeding groups in South Africa. As the bird is an obligatory carnivore the gastro-intestinal tract (GIT) may display specific adaptations which could be of significance in the husbandry of this endangered species. Factors that contribute to unnatural mortality in SGH's in South Africa are poisoning, both primary and secondary; electrocution on transformer boxes; shooting; and illegal capture for trade. An undescribed threat is lead contamination of hunting offal from the use of lead-based ammunition as well as object ingestion as the SGH is a non-discriminate eater in the wild as well as in captivity. Carnivorous bird species have important gastrointestinal

differences in anatomy, physiology, nutrition, and disease etiologies that greatly affect the success of medical and surgical intervention during gastrointestinal diseases.

Nine adult SGH’s, of either sex, which succumbed due to natural causes, unknown causes, attack from other birds, euthanasia for humane reasons or untreatable conditions and management reasons (usually reproductive failure) were used in this study. Deceased birds were from Mabula Ground Hornbill project (Bela-Bela, Limpopo, South-Africa) and were transported to the Faculty of Veterinary Science for post-mortem examination. After the latter, the GIT with the liver, pancreas and spleen, were removed and immersion-fixed in 10% neutral-buffered formalin. In some instances, not all parts of the digestive tract were included in the study due to obvious pathology. The hollow organs were cut longitudinally to reveal and describe the inner surfaces. The topography of the organs was described and captured during post-mortem examinations with a Go-pro HERO 7 action camera (American technology) and a Samsung A51 smartphone (Samsung electronics, South Africa). The terminology used in this study is that of Nomina Anatomica Avium (Baumel, 1993). After the gross description, samples for histology from the various sections of the GIT were taken, dehydrated and there after processed through 50:50 ethanol: xylol, 2X xylol and 2X paraffin wax using a Shandon model 2LE Automatic Tissue Processor. Tissue samples were then manually imbedded in paraffin wax in plastic moulds. Sections were cut at 3-5 µm and stained with Haematoxylin and Eosin (H&E), Peroidic Periodic acid–Schiff (PAS) and Masson’s Trichrome.

The most notable organ from ventral view was the ventriculus situated between the two liver lobes. The coelom cavity is divided into cavities, cranial to caudal consist of a pericardial cavity (*Cavum pericardii*), four hepatic peritoneal cavities (*Cavitas peritonealis hepatica*), and an intestinal peritoneal cavity (*Cavitas peritonealis* *intestinalis*). The proventriculus is situated in the left *Cavitas peritonealis hepatica dorsalis*, the ventriculus is situated in the left *Cavitas peritonealis hepatica ventralis*, the intestine in the *Cavitas peritonealis intestinalis* and the liver in the left and right *Cavitas peritonealis hepatica ventralis* and *Cavitas peritonealis hepatica dorsalis.* The four *Cavitas peritonealis hepatica* are bounded caudally by the transversely oriented *Septum posthepaticum* and separates the *Cavitas peritonealis hepatica* from the *Cavum intestinale peritonei*. The proventriculus was small and the ventriculus large. Low longitudinal folds were present on the luminal surface allowing for distention, for large prey to move through. *Gll. proventriculares profundae* were visible macroscopically in the wall of the proventriculus and formed the main feature on the cut surface. Some of the glands emptied into the cranial aspect of the ventriculus and were more concentrated on the dorsal aspect, the *Zona intermedia gastris*. The proventriculus was seperated from the ventriculus by the *Isthmus gastris*. The large ventriculus displayed prominent longitudinal folds on the dorsal surface that ran perpendicular to the ventriculo-duodenal opening on the luminal surface and circumferentially around the *Centrum tendineum*. The pylorus was on the right lateral aspect of the ventriculus and was represented by the slit-like ventriculo-duodenal opening. The intestine consist of the duodnenum, jejunum, ileum and the large intestine, or the rectum. There is a total of 5 loops comprising the small intestine. The *Flexura duodenojejunalis* marked the transition from the duodenum to the jejunum. The point where the last branch of the cranial mesenteric artery supplied the small intestine marked the transition from the jejunum to the ileum, no Meckel's diverticulum was present in order to identify this transition. The rectum was short and straight and slightly larger in diameter than the ileum. Ceacae were not observed. The pancreas was situated in the *Ligamentum pancreaticoduodenale*, between the descending and ascending duodenum, or the *Ansa duodenalis*. It was composed of three lobes, the dorsal lobe (*Lobus pancreaticus dorsalis*), the ventral lobe (*Lobus pancreaticus* *ventralis*) and the splenic lobe (*Lobus pancreaticus splenalis*). The *Ductus pancreaticus ventralis*, *Ductus pancreaticus dorsalis* and *Ductus pancreaticus accessorius*, were identified and drained into the ascending duodenum at the duodenal papilla, at the point where the bile ducts entered the ascending duodenum. The liver was large, with a smaller left lobe (*Lobus hepaticus sinister*) and a larger right lobe (*Lobus hepaticus dexter*). The two lobes were separated caudally by a complete deep, median, caudal interlobular incisure (*Incisura interlobaris caudalis*) and connected by the *Pars interlobaris*. Various organs made impressions on the liver. Two bile ducts were present, the *Ductus hepatoentericus communis* and the *Ductus cysticoentericus*.

The proventriculus was composed of the six layers; *Lamina epithelialis*, *Lamina propria*, *Lamina muscularis mucosae*, submucosa, *Tunica muscularis* and Serosa. The *Lamina epithelialis,* presenting rugae / plicae (*Rugae proventriculares*) lined by simple columnar epithelium. It was supported by the *Lamina propria* that in places was obliterated by internodular lymphoid tissue. The *Lamina propria* and *Lamina epithelialis* formed finger-like projections in transverse section. *Gll. proventricularis superficialis* was composed of columnar cells that stained PAS positive, secreting mucus into the lumen of the proventriculus. The tips of the *Rugae proventriculares* were more strongly PAS positive. The *Lamina propria* contained infiltrations of internodular lymphoid tissue. *Lamina muscularis mucosae* housed the massive, deep compound tubular proventricular glands (*Gll. proventricularis profundae*). The glands weere lined by two distinct epithelia; a simple cuboidal and a columnar epithelium. The columnar epithelium staind more strongly PAS positive in the tertiary duct, secreting mucous into the tertiary, secondary and primary duct of the proventriculus. The cuboidal epithelium represented the oxynticopeptic cells, staning dark red with TRI, bright pink with H&E and PAS negative, and secreting pepsin and hydrochloric acid

(HCL). The *Tunica muscularis* was composed of the inner S*tratum longitudinale* and a much thicker outer *Stratum circulare*. Connective tissue divided the two layers into various bundles. The ventriculus lacked the *Lamina muscularis mucosae*. The luminal and crypt columnar, chief cells secreted a substance that was less intensely eospinophilic (H&E), weakly PAS positive (light pink) and stained pale red with TRI. The apical part of the glands stained intensely pink with H&E, dark red with TRI and were PAS positive. The koilin layer was formed as part of two different secretory phases that hardened in the lumen due to the pH difference. The alternating layers of dark and light-staining secretions formed layers that merged on the surface, the light layer has the vertical rods and the dark layer the *Matrix horizontalis*, together they formed the *Cuticula gastrica*. The intestine contained no *Plicae circulares*. The *Villi intestinales* become shorter and broader, the *Tunica muscularis intestinae* was less well-developed and the goblet cells more numerous when moving from the duodenum aborally towards the rectum. The goblet cells stained PAS positive and secreted mucus into the lumen of the intestine. An inner longitudinal and outer circular layer of the *Lamina muscularis mucosae* was present in the small intestine.

The size and position of digestive organs are important when evaluating topography and pathology on diagnostic imaging. Abdominal masses can cause changes in the location of the GIT. Ventral midline approach to laparotomy is used and sutures applied to the ventriculus rather than the proventriculus, most foreign bodies are situated in the ventriculus. The structural differences of the size in the proventriculus and ventriculus is largely determined by the dietary preferences. The ventriculus is highly distensible and function mainly as a storage organ. The presence of an *Isthmus gastris* makes foreign body removal by endoscopic removal less feasible. The ventriculus of the SGH is relatively featureless as seen in other carnivorous species and contained non-food items, supporting the statement that they are indiscriminate eaters. The SGH uncommonly produces a casting and likely function similar to the Falconiformes that digest bones of their prey and often eat more than one meal before casting. The Osprey (*Pandion haliaetus*) produces pellets that are small and rarely seen, which indicates that most of their dietary items pass through the entire GIT and is similarly noted in the SGH. The relatively thinner wall and absence of rocks in the ventriculus of the SGH's in the present study, support the notion that the main digestive mechanism occurs by enzymes and not grinding by a thick muscular ventriculus. The intestine displays the least variability between species, with the length being the most common variable. Changes in gastrointestinal morphology, like intestine length and the presence of cecae is induced as a consequence of captivity could be a factor influencing the survival of released captive-reared birds and can be a factor to consider in the SGH. Many birds of prey do not require water beyond that provided in their prey, specifically in the wild and possibly supports the notion that the SGH have the ability to reabsorb water in the rectum and cloaca. Pancreas size is reported to be smaller in carnivorous bird, as seen in the SGH, and is related to the high digestibility of their diet. There are considerable differences in the number, course and opening of the pancreatic ducts noted in literature. The large liver of the SGH supports a high metabolic rate, protein, acid and bile salt synthesis, and excretion and detoxification processes. Carnivorous species have particularly well developed gall bladders as seen in the relatively well developed gall bladder of the SGH.

The primary function of the proventriculus is to secrete mucous, hydrochloric acid and pepsinogen into the digestive compartments. The viscoelastic mucus gel cover, lubricate and protect the stomach surface from corrosive actions, providing a physical barrier with low permeability to pepsin and other macromolecules. Distribution of the deep proventricular glands is not consistent among avian species. The gland free regions in flowe-seeking parrots and possibly in the SGH makes the organ more distensible. The ventricular koilin layer forms part of two secretory phases and is continuesly worn down and replaced. Strands of smooth muscle run perpendicular to the glands that may assist in pulling the glands closer to the muscle layer, having the effect of emptying the gland contents. The thin musculature of the ventriculus would conceivably allow more distensibility, making it easy to house large prey. The small intestine mainly functions to digest and reabsorb nutrients. The zigzag formation was seen in the rectum and together with the presence of more goblet cells in the SGH, supports the notion of the absorptive function of the large intestine. The villi become shorter and broader, goblet cells become more numerous and the Lamina muscularis become less well developed when moving aborally towards the rectum.

The massive deep proventricular glands, thin-walled ventriculus, thick koilin layer and uncommon casting support enzymatic digestion over the grinding of ingesta. The layered koilin secretion may assist in the flexibility of the ventriculus to house large pray such as hares. Heavy reliance on enzymatic digestion is important in husbandry and stress related ulceration. Stress slows gastric emptying and ion exchange, causes colonic mucin depletion and increased intestinal permeability leading to the passage of antigens to the *Lamina propria* and bacterial translocation. The well-developed *Lamina muscularis mucosae*, numerous goblet cells, fast gut transit time, short GIT, presence of microvilli and villi all indicate fine control and increased absorption of water and nutrients and emphasizes the importance of maintaining intestinal motility, making GIT stasis a life threatening condition.

Chapter 1

General Introduction

1.1 A general introduction to the Southern Ground-Hornbill

It has been estimated that one bird species has gone extinct every year in the past 500 years, making research on avian species to improve conservation important (Pimm *et al.*, 2006). Of the 856 bird species in South Africa, 132 have been declared threatened with extinction by the IUCN (International Union for Conservation of Nature) Red List in 2019 (IUCN, 2019). The Southern Ground-Hornbill (*Burcorvus leadbeteri*) (SGH) has been classified as Vulnerable across its range by the IUCN since 2016 (BirdLife International, 2016). Factors that contribute to unnatural mortality in SGH's in South Africa are poisoning, both primary and secondary; electrocution on transformer boxes; shooting; and illegal capture for trade (both for aviculture and traditional medicine) (Trail, 2007; Botha *et al.*, 2011). An undescribed threat is lead contamination of hunting offal from the use of lead-based ammunition. The SGH scavenge on carcasses which makes them susceptible to poisoning when scavenging on poisoned baits (Kemp and Woodcock, 1995; Butler and du Toit, 2002; Koeppel and Kemp, 2015). Poisoning can also occur by direct poisoned baits put out for predatory or rabid pests such as jackals, or indirectly by incorrect use of agricultural pesticides that poison insects but then, in turn, poisons hornbills. Some cultures also believe that the SGH possess benefits to one's health and use them in traditional medicine

(Bruyns, Williams and Cunningham, 2013). They also face persecution for breaking windows when their highly territorial nature has them fighting the ‘enemy’ seen in their reflections (Coetzee, Nell and van Rensburg, 2014).

SGH’s can be found across northern Namibia and Angola to northern South Africa and southern Zimbabwe to Burundi and Kenya (Combrink *et al.*, 2017). Although SGH’s are considered as ‘Vulnerable’ throughout their range (Botha *et al.*, 2011), within South Africa they have been classified as ‘Endangered’ and have lost an estimated 70% of their range and 50% of the historic population (Theron *et al.*, 2017). It is estimated that they are only about 1500 SGH’s left in South Africa, of which half are found within protected areas of the greater Kruger National Park (Pimm *et al.*, 2006). As with most large birds, SGH’s are unevenly distributed at low densities, defend large territories (about 100km^2) and have widely spaced breeding sites (Kemp and Kemp, 1980; Wyness, 2011). Furthermore, this species is the largest bird species that breeds cooperatively and the only hornbill that is entirely carnivorous (Kemp and Kemp, 1980). Currently, there are only an estimated 417 breeding groups in the whole of South Africa, while data from the Kruger National Park shows that, on average, only one chick is raised to adulthood every nine years (Kemp and Woodcock, 1995; Combrink *et al.*, 2017). Maturity is only reached at an estimated age of around 5-6 years for both males and females with breeding attempts occurring only much later on in the lifecycle of individuals (Pimm *et al.*, 2006).

1.2 Diet and behaviour of the Southern Ground-Hornbill

SGH live in groups of 2 to 10 individuals including adults and juveniles, although most groups are of 3-5 members (Botha *et al.*, 2011). The status of the members in the group os usually not obvious while the dominant male and female is usually obvious, bill-beating indicating uncertainty of its status and food offering a sign of dominance (Kemp and Kemp, 1980). The females in the group usually disperse at one year of age (Carstens, 2017). The adult helpers assist with territorial defence, predator vigilance, feeding the nest-bound female during incubation and early brooding, and later with the nestling and post-fledging care - essentially alloparenting (Kemp *et al.*, 2020). They require a savanna habitat with large trees for nesting and dense but short grass for foraging (Pimm *et al.*, 2006; Theron *et al.*, 2013), where they feed on reptiles, frogs, snails, insects and mammals up to the size of hares (Combrink *et al.*, 2017). Ground-Hornbills are faunivorous and opportunistic in their diet preferences, including scavenging if the opportunity presents itself (Kemp *et al.*, 2020). They favour areas of short open grass- and herb-land, within which it can find sufficient animal prey, escape predators and find trees of sufficient size to roost in and provide nest cavities (Botha *et al.*, 2011). The nest location depends more on the availability of trees, earth banks or rock faces than specific selection between territories (Botha *et al.*, 2011). General requirements of the nest include an internal diameter of ≥40 cm, an elevation of 1-50m and larger trees along watercourses that form branches/trunks or cavities are favoured (Kemp and Kemp, 1980).

SGH groups are very vocal and contact is made by calls in chorus which can usually be heard at distances of up to 5 kilometers (Pimm *et al.*, 2006). The calls can be characterized as territorial, contact, alarm, flight, acceptance or begging (Kemp and Kemp, 1980). The calls allow each group to maintain their territories. Nesting sites are the primary resource associated with SGH territories, whilst food resources are secondary (Theron *et al.*, 2013). Each group appeared to possess and spend much time on well grazed areas associated with watering points for mammals (Kemp and Kemp, 1980). Often, neighboring groups are engaged in aerial pursuits to actively defend their home ranges and territories (Zoghby, 2015). Territory defense is undertaken by adult group members and consists of regular pre-dawn vocalizations while still at the roost site and high aerial pursuits if groups hear or encounter rival neighbors (Kemp, Joubert, & Kemp, 1989). Their deep booming call, which is audible to humans at distances of up to 5 km, is most often a duet initiated by the alpha breeding pair, with the male calling at a lower pitch than the female (Kemp and Kemp, 1980; Botha *et al.*, 2011).

SGH's spend most of the day on the ground foraging as the main activity, flying occurs in the first few hours of the day, moving from roosts, moving along territorial boundaries, moving to feeding areas, or chasing (Kemp and Kemp, 1980). Activities such as territorial defense, moving to check on nest sites or to reach special feeding areas were not distinguished since they take little time and are rarely independent of foraging.

The SGH is susceptible to overheating and shows several heat loss postures and behaviors, starting at environmental temperatures of 26°C (Kemp and Kemp, 1980).

Heat-loss behaviors such as opening of the bill, holding the wings away from the body and forming an umbrella over the body with the wings have been noted (Kemp and Kemp, 1980). Opening of the bill exposes the damp mouth lining to evaporative cooling. The wings are long and broad and lack underwing coverts. Raising the wings would form an umbrella over the body and facing into the wind with wrists apart would expose the naked underwing to radiative and convective cooling. Thereafter if the behaviors and postures did not succeed, they move to the shade (Kemp and Kemp, 1980).

1.3 Reproductive behaviour

The SGH has a unique reproductive pattern rendering it subject to vulnerability. The SGH's live in a group of 2-10 individuals and are monogamous with only one mating pair per group. They are known for cooperative breeding, taking care for the offspring as a group (Wilson, Hockey and Marsden, 2013). Sexual maturity is reached at approximately 3 years of age. This stage is marked by characteristics distinctive to the sex where the facial skin of the males becomes completely red and the skin below the beak violet blue in the female (Kemp and Kemp, 1980). Mating occurs seasonally in early summer. The male SGH's produce a mating call when courting females and are not known to fight over females. The copulation and nesting period lasts for about 3 months (September to December) and laying may start earlier if the rains start earlier (Kemp and Kemp, 1980). The alpha male and female are the only two that will mate and they choose one another based on size. The alpha female is courted mainly by the alpha male while she starts to nest, thereafter copulating near the nest, where the male heavily preens the female’s head and neck at first and forces her to crouch before he mounts her (Kemp and Kemp, 1980). After copulation the eggs hatch approximately 37 to 43 days later (Msimanga, 2004). The female lays her eggs 3-7 days apart, resulting in.the first chick being 3-7 days older than the second, and the second chick normally dies off within a week due to starvation (Botha *et al.*, 2011). After hatching the chick has 86 days until the fledging stage (Msimanga, 2004). After the offspring is produced by the alpha pair the rest of the flock serve as helpers to feed the chick (Msimanga, 2004; Wilson, Hockey and Marsden, 2013)Approximately every nine years only one of the chicks will make it to the fledging state.

1.4 Husbandry

The husbandry and cage space requirements survey by Sweeney (2016), produced a large amount of useful information that is now used for the development of husbandry guidelines. Animal care manuals are also produced and shared in several publications that describe different aspects on the management of SGH’s in zoos (Sweeney, 2016). The SGH in captivity spend less time foraging, possibly due to foraging pressure relief in captivity because food is provided in compact spatio-temporal instances and hence foraging occupies less of the time-activity budget (Cooper and Jordan, 2013).

1.5 Hypothesis

The anatomy and histology of the SGH gastrointestinal tract will be similar to that of other carnivorous avian species.

1.6 Aims and objectives

The aim of this project is to provide a comprehensive description of the morphology of the gastro-intestinal tract of the SGH.

The benefits of this project include:

- An in depth description of the anatomy and histology of this species could benefit the conservation of this species in the wild and captivity by aiding the anatomical and physiological understanding and surgical procedures.
- Several SGH's die due to digestive pathology and/or abnormal behavioural patterns seen in husbandry. Husbandry guidelines may be substantiated or even slightly altered with more information regarding the digestive system structure.
- Enhanced treatment and care of captive birds as well as more success in hand-rearing birds.
- Possible surgical refinement or alternative approaches to surgical techniques.
- Improved hospitalization environment and physiological stress control.
- Future perspectives, refinement and/or improvement of published research.

CHAPTER 2

TOPOGRAPHY AND GROSS ANATOMY OF THE GASTRO-INTESTINAL TRACT OF THE SOUTHERN GROUND-HORNBILL

2.1 Introduction

Despite recent studies on the habitat and behaviour of the Southern Ground-Hornbill (*Bucorvus leadbeateri*) (SGH) (Kemp and Kemp, 1980), reproduction (Msimanga, 2004), gastrointestinal surgery (Rosskopf and Walter, 1991; Hayati *et al.*, 2011) and pathology (Jones, 1999; Davies, 2000; Schmidt, Reavill and Phalen, 2003) in wild and domestic avian, there is a persistent gap in available knowledge of the anatomy and histology of the gastro-intestinal tract (GIT) of most wild bird species (North, Movassaghi and Smits, 2016). The typical avian GIT is composed of the stomach (proventriculus and ventriculus (gizzard)), duodenum, jejunum, ileum, cecae and rectum (Nickel, Schummer and Seiferle, 1977). Associated with the GIT and of interest in this study is the liver, pancreas and spleen. The SGH is the only entirely carnivorous hornbill, consuming animals up to the size of hares although feeding mainly on reptiles, amphibians, snails and insects (Kemp and Kemp, 1980). They are similar to raptors, which are carnivorous members of the orders falconiformes and strigiformes, represented by hawks, falcons, caracaras, eagles, ospreys, kites, condors, vultures, secretary birds and owls (Klaphake and Clancy, 2005; Murray, 2014). Carnivorous bird species have important gastrointestinal differences in anatomy, physiology, nutrition, and disease aetiologies that greatly affect the success of medical and surgical intervention during gastrointestinal diseases (Klaphake and Clancy, 2005).

The proventriculus of the griffon vulture (*Aegypius Monachus*) displays many folds in the proventricular wall allowing for distension (Langlois, 2003), whereas that of most granivorous birds (seed-eaters) possess small proventriculi with no folds (Langlois, 2003). Carnivorous species tend to have low, longitudinal folds in the proventricular lumen (Abumandour, 2014). The proventriculus differs remarkably in size when comparing it to that of the most commonly larger ventriculus and may vary from species to species (Langlois, 2003). The herbivorous avian tends to have longer, more complex digestive systems, while carnivorous avian have smaller, less elaborate digestive systems (Degolier, Mahoney and Duke, 1999).

Granivorous birds tend to have larger ventriculus than their frugivorous (fruit-eaters) and carnivorous (meat-eaters) counterparts in order to grind the harder seeds (Gionfriddo and Best, 1996; Krautwald-Junghanns *et al.*, 2002). The ventriculus of the chicken is a masticatory stomach that has strong musculature and aids in grinding its content (Nickel, Schummer and Seiferle, 1977). In contrast, the ventriculus of most raptors is poorly developed, lacks the distinct thick and thin muscle characteristic of the granivorous ventriculus and aids primarily in chemical digestion (Duke, 1997; Langlois, 2003; Scanes, 2015). Mechanical digestion of food does not occur at any stage in the raptor gastrointestinal tract; instead food is broken down entirely by chemical digestion (King and McLelland, 1984). A koilin layer that protects the surface of the ventriculus is absent in the white-backed vulture (*Gyps africanus*) (Houston and Cooper, 1975). Overall, the herbivorous species have a consistently heavier ventriculus than their carnivorous or omnivorous counterparts (Degolier, Mahoney and Duke, 1999).

The liver, pancreas and spleen, although not part of the GIT, are closely associated with the GIT due to their attachments to the stomach and intestine. Additionally, these organs are important diagnostic indicators of various disease conditions. Clostridial diseases, pseudotuberculosis, aspergillosis, candidiasis and various viruses affect the liver and spleen of raptors (Shivaprasad, 2002).The liver of raptors is often affected by *Pasteurella multocida* infection and the spleen congested (Morishita *et al.*, 1997). Avian mycobacteriosis in free living raptors presents with white–yellowish nodules mainly in the liver, spleen and intestine (Millán *et al.*, 2010). Diabetes mellitus has been reported in the carnivorous red-tailed hawk (*Buteo jamaicensis*) (Wallner-Pendleton, Rogers and Epple, 1993). Metal concentration has been tested in raptor species and found that chronic exposure to low levels of pollutants results in liver damage (Zaccaroni *et al.*, 2008). Lead poisoning by direct and secondary ingestion is common among raptors as well as the SGH (Kendall *et al.*, 1996; Koeppel and Kemp, 2015). As the SGH is a threatened species, post mortem examinations are conducted on all deceased birds. It is noted that the liver often demonstrates pathology (Klaphake and Clancy, 2005). This study therefore will include the liver and pancreas.

The liver in birds is one of the largest, most important organs in the body. It has numerous functions, as in other vertebrates, including digestive functions, metabolism of proteins, fats, and carbohydrates, synthesizing and secreting bile, which contains two bile pigments bilirubin and biliverdin, into the small intestine

(Al-Aaraji, 2015). The avian liver shows many variations in size, shape and amount of lobes between the different species (Al-Hamadawi *et al.*, 2017). The pancreas, in the right lateral aspect of the abdomen is situated between the ascending and descending duodenum in all avian species (Hodges, 1974; Stornelli *et al.*, 2006; Hussein and Rezk, 2016). The pancreas plays a major role in the secretion of enzymes for digestion (Bailey *et al.*, 1997; Al-Samarae, Thayer and Swad, 1999). The spleen is not directly related to but in contact with the gastro-intestinal tract, functioning to clear microorganisms and particulate antigens from the blood stream and synthesis of immunoglobulins (IgG) (Farner, 1960). The spleen is affected by related pathology and is thus worth mentioning but will not be described in depth.

Southern Ground-Hornbill's are housed and bred in captivity in an attempt to increase their population (Botha *et al.*, 2011). However, in captivity these birds face certain challenges, including those with regards to digestive pathologies, foreign object ingestion and poisoning (K.N. Koeppel, personal communication). As the above mentioned problems manifest themselves within the GIT, and there is little information documented in this species, this study will describe the gross morphology of the GIT and associated organs. This will aid veterinarians in treatment and diagnostics and provide a better understanding of the digestive system to inform husbandry and conservation practices.

2.2 Materials and Methods

Nine adult Southern Ground-Hornbills (SGH's), of either sex, which succumbed due to natural causes, unknown causes, attack from other birds, euthanasia for humane reasons or untreatable conditions and management reasons (usually reproductive failure) were used in this study. Deceased birds were from Mabula Ground Hornbill project (Bela-Bela, Limpopo, South-Africa) and were transported under a TOPS permit (Appendix I) to the Faculty of Veterinary Science for post-mortem examination. After the latter, the GIT with the liver, pancreas and spleen, were removed and immersion-fixed in 10% neutral-buffered formalin and stored in plastic buckets. In some instances, not all parts of the digestive tract were included in the study due to obvious pathology, or due to intensive sampling distorting the normal anatomical topography of the organ, especially that of the liver.

For post-mortem examination, the birds were opened on the ventral midline and the breastbone pulled cranially to expose the thoraco-abdominal cavity. The topography of the organs was described and digitally photographed taken at this stage. The digestive system and associated organs were removed from the body cavity by dissecting the alimentary tract cranial to the proventriculus and cranial to the cloaca. Prior to the examination of the formalin-fixed organs, the specimens were rinsed in running tap water for 24 hours. Each part of the digestive system and associated organs was further dissected to reveal parts of the stomach, intestine, accessory organs and blood vessels. The mesentery and fat were removed from the stomach and intestines. The loops (180° turns) of the small intestine were noted and the mesentery incised to enable the loops to be spread out. The hollow organs were cut longitudinally to reveal and describe the inner surfaces. All structures were described and digitally recorded with Go-pro HERO 7 action camera (American technology) and a Samsung A51 smartphone (Samsung electronics, South Africa). The terminology used in this study is that of Nomina Anatomica Avium (Baumel, 1993).

2.3 Results

2.3.1 Coelomic cavity topography (Figs. 2.1 – 2.4)

The description which follows below was based on the available literature, and deviation may be present. This is a result of the sample collection as all the SGH carcasses first underwent post-mortem. During the post-mortem it was not always possible to identify all of the cavities and structures.

The coelomic cavities in the SGH is composed of several discrete spaces that include serosa-lined cavities and air sacs. The serosa-lined cavities from cranial to caudal consist of a pericardial cavity (*Cavum pericardii*), four hepatic peritoneal cavities (*Cavitas peritonealis hepatica*), and an intestinal peritoneal cavity (*Cavitas peritonealis intestinalis*). The air sacs include paired cranial thoracic air sacs (*Sacci thoracici cranialis*), caudal thoracic air sacs (S*acci thoracici caudalis*) and paired abdominal air sacs (*Sacci abdominales*) which are associated with the GIT and liver. The clavicular air sac may be present, however it was not exposed during the post-mortem examination. The coelomic cavity is partitioned by paired dorsal/horizontal (*Septum horizontale*) and ventral/oblique septa (*Septum obliquum*) and a left and right posthepatic septum (*Septum posthepaticum*). The *Septum horizontale* passes ventral to the lungs, dorsal to the *Septum obliquum,* towards the ribs (Figs. 2.2, 2.3). The *Septum obliquum* follows a more ventral course from the thoracic vertebrae towards the edge of the sternum (Figs. 2.2, 2.3). The *Septum posthepaticum* separates the *Cavitas peritonealis intestinalis* from the *Cavitas peritonealis hepatica*. The left partition extends between the dorsolateral parietal peritoneum and the left surface of the ventriculus. The right partition extends between the dorsolateral parietal peritoneum and the right surface of the ventriculus.

The *Cavitas peritonealis hepatica* is divided into four spaces; the left and right dorsal hepatic peritoneal cavities (*Cavitas peritonealis hepatica dorsalis*) and the left and right ventral hepatic peritoneal cavities (*Cavitas peritonealis hepatica ventralis*). The left hepatic ligament (*Ligamentum hepaticum sinistrum*) (Fig. 2.2) divides the left hepatic peritoneal cavity into dorsal and ventral sub-compartments. The right hepatic ligament (*Ligamentum hepaticum dextrum*) divides the right hepatic cavity into dorsal and ventral sub-compartments (Fig. 2.2). The left *Ligamentum hepaticum dextrum* and right *Ligamentum hepaticum sinistrum* connects the liver to the *Septum obliquum* on both lateral sides.

The *Cavitas peritonealis hepatica ventralis* is divided in left and right aspects by the ventral mesentery (*Mesentericum ventrale*) of the liver. The *Dorsal cava hepatica peritoni* is divided in left and right aspects by the dorsal mesentery (*Mesentericum dorsale*) of the liver. The left and right *Cavitas peritonealis hepatica dorsalis* are much smaller than the two *Cavitas peritonealis hepatica ventralis.* The right *Cavitas peritonealis hepatica dorsalis* is blind (Fig. 2.2), while the left *Cavitas peritonealis hepatica dorsalis* connects directly with the intestinal peritoneal cavity

(Fig. 2.3) and houses the proventriculus (Fig. 2.2). These four *Cavitas peritonealis hepatica* are bounded caudally by the transversely oriented posthepatic septum (*Septum posthepaticum)* and separates the *Cavitas peritonealis hepatica* from the *Cavum intestinale peritonei.* The left partition of the *Septum posthepaticum* extends between the dorsolateral parietal peritoneum and the left surface of the ventriculus. The right partition of the *Septum posthepaticum* extends between the dorsolateral parietal peritoneum and the right surface of the ventriculus. The *Septum posthepaticum* encloses the ventriculus on the left lateral side of the *Cavitas peritonealis hepatica ventralis*.

The intestinal peritoneal cavity (*Cavum intestinale peritonei*) is a midline space positioned caudal to the ventriculus. The intestines suspended by mesenteries are enclosed in the *Cavum intestinale peritonei* (Fig. 2.1).

In the *Cavitas peritonealis hepatica ventralis*, the caudo-medial surfaces of the left and right liver lobes contact the cranial part of the ventriculus (Fig. 2.1). The ventriculus is positioned in the left *Cavitas peritonealis hepatica ventralis,* with the *Facies annularis* and the *Centrum tendinuem* visible (Figs. 2.1, 2.3). In the *Cavum intestinale peritonei*, the duodenal loop with the descending duodenum, pancreas and ascending duodenum is located caudal to the ventriculus (Figs. 2.1 – 2.3).

The pear-shaped compound stomach of the SGH consists of the *Pars glandularis* or proventriculus and *Pars muscularis* or ventriculus. The small proventriculus transitions from the esophagus approximately at the apex of the heart and is located cranial to, and empties into the large ventriculus (Figs. 2.2, 2.4). In dorsal recumbence, from a left lateral view the proventriculus lies in the cranial part of the abdominal cavity, dorsal to the caudal part of the sternum (Figs. 2.2, 2.4). The left and right liver lobes (Fig. 2.1) surround the proventriculus. The left liver lobe is situated in the left *Cavitas peritonealis hepatica* and the right liver lobe is situated in the right *Cavitas peritonealis hepatica.*

The ventriculus lies caudal to the sternum and in the full state occupies most of the left *Cavitas peritonealis hepatica ventralis,* displacing the *Septum posthepaticum* distally and reducing the *Cavum intestinale peritonei* to a minimum; in this state the intestinal loops are less visible than in the empty state (Figs. 2.1 - 2.3). The ventriculus lies partially between the two liver lobes, with the cranial part of the ventriculus contacting the caudo-medial surfaces of the left and right liver lobes (Fig. 2.1). There is greater contact with the right liver lobe. The most caudal aspect of the ribcage and sternum is cranial to the ventriculus and only partially covers it (Fig. 2.1). The most caudal aspects of the liver extend beyond the sternum. The right and caudal aspect of the ventriculus contacts the descending duodenum. The duodenal loop (*Ansa duodenalis*), along with the pancreas, is presented in the ventral superficial view in the caudal third section, within the *Cavitas peritonealis intestinalis* (Figs. 2.1-2.3).

The spleen is situated on the craniodorsal aspect of the ventriculus and caudoventral aspect of the proventriculus (Fig. 2.4), and is accommodated in a pocket of visceral peritoneal sac (Fig. 2.2) that is not visible in the superficial ventral view.

2.3.2 Stomach (*Gaster*) (Figs. 2.4 - 2.8)

The stomach is a compound stomach composed of the smaller proventriculus (*Pars glandularis*) and the larger ventriculus (gizzard) (*Pars muscularis*) (Figs. 2.4 - 2.6, 2.8).

The proventriculus is spindle-shaped and forms a double open-ended tube for food to pass through (Fig. 2.8). The cranial end leads from the esophagus (which displays longitudinal folds) (Figs. 2.7, 2.8) and the caudal end leads to the ventriculus. The proventriculus transitions to the ventriculus with a distinct boundary termed the gastric isthmus (*Isthmus gastris*) (Fig. 2.8). Low longitudinal folds are a feature of the lumen (Fig. 2.8). The lumen of the proventriculus is characterised by the openings of the *Gll. proventriculares profundae* present in the glandular region (*Regio glandularis*) (see chapter 3) which occupies the internal surface, except for a small region dorsally, which is gland free (Figs. 2.7, 2.8). The openings of the proventriculus are on a slightly raised projection, and the proventricular papillae are inconspicuous. The glands are visible in the wall of the proventriculus and form the main feature on the cut surface (Figs. 2.7, 2.8). Although the glands in the ventral aspect are more concentrated and the wall in this area is also thicker (Figs. 2.7, 2.8), the glands are distributed throughout the proventricular wall. Some of the glands present in the proventriculus empty into the cranial aspect of the ventriculus, also known as the intermediate zone (*Zona intermedia gastris*) (Figs. 2.7, 2.8).

The ventriculus is a disc-shaped structure with no external compartmentalisation (Fig. 2.2, 2.4, 2.5, 2.6, 2.8). Although the ventriculus is relatively featureless; a round body (*Corpus ventriculi*) with a left and right facing tendinous face (*Facies tendineae*) is distinguishable (Figs. 2.4, 2.5, 2.6). The major curvature (*Curvatura major*) runs from the proventriculus, over the left tendinous centre (*Centrum tendineum*) towards the right to end at the duodenum (Figs. 2.4 - 2.6). The right side, with a right *Centrum tendineum*, displays the minor curvature (*Curvatura minor*) spanning the proventriculus and duodenum, and is largely obscured by blood vessels (Fig. 2.6). The annular face (*Facies annularis*) forms a continuous ring between the left and right sides with muscle fibres (*Stratum circulare*) that are directed from the tendinous centre towards the periphery (Figs. 2.4, 2.5).

On median section various internal features are of note. A small intermediate zone (*Zona intermedia gastris*) with longitudinal folds is apparent and is located on the lesser curvature, between the proventriculus and the angular fold (*Incisura angularis*) of the ventriculus (Fig. 2.8). The angular fold is on the ventral portion of the ventriculus and corresponds to the externally visible acute ventral angle of the *Isthmus gastris*. The wall of the body of the ventriculus is slightly thicker dorsally, than ventrally and caudally, and is lined by the cuticle or koilin membrane (*Cuticula gastrica*), a hardened membrane which is greenish in colour (Figs. 2.7, 2.8). The interior portion corresponding to the *Centrum tendineum* seen externally, marks the centre of the ventriculus where no folds are present (Figs. 2.4, 2.5, 2.6, 2.8). The folds in the ventriculus run from the dorsal aspect of the body, circumferentially around the region of the *Centrum tendineum* in a cranio-caudal direction (Fig. 2.8). The folds on the dorsal surface run perpendicular to the ventriculo-duodenal opening. The pylorus is on the right lateral aspect of the ventriculus and is represented by the slit-like ventriculo-duodenal opening. The *Ostium ventriculopyloricum* also known as the pyloric opening, and the sphincter are found at this opening (Fig. 2.8). The pyloric sphincter is composed of a ventral lip and a dorsal lip, together forming the opening. The dorsal lip of the pyloric opening ends at the junction with the *Centrum tendineum* (Fig. 2.8). Items present in the ventriculus were chicken heads and beaks, bones, some plastic wastes, a small amount of glass, a screw, solid ball of fur and unidentified objects.

2.3.3 Intestinal tract

2.3.3.1 Small intestine (Intestinum tenue) (Figs. 2.1-2.4, 2.9 – 2.11)

The small intestine comprises the duodenum, jejunum and ileum, arranged into five loops. Each intestinal loop is a section of small intestine running parallel to each other with a 180° bend. The two sections are connected by mesentery. There are no remarkable features between the different sections and topography determines the various parts from each other.

The duodenum originates from, and is connected to, the ventriculus on the right cranio-dorsal region at the *Centrum tendineum* and forms the first loop of the small intestine (Figs. 2.9-2.11, 2.13). The duodenum consists of a descending (*Pars descendens*) and an ascending (*Pars ascendens*) duodenum forming a U-shaped loop, the *Ansa duodenalis* (Figs. 2.9-2.11). The descending duodenum lies against the surface of the right caudo-ventral aspect of the ventriculus (Figs. 2.1, 2.9), it then runs from the dorsal surface in a caudo-lateral direction to the ventral surface of the ventriculus where it makes a sharp bend transitioning into the ascending duodenum (Figs. 2.1, 2.9). The descending and ascending duodenum, are connected by a strip of mesentery, the *Ligamentum pancreaticoduodenale,* which houses the ventral lobe of the pancreas (Fig. 2.9).

The duodenum transitions to jejunum (Figs. 2.9, 2.10) at the duodenojejunal flexure (*Flexura duodenojejunalis*) at the point where the pancreatic and bile duct enters the duodenum (Figs. 2.9, 2.12). Internally this is marked by the duodenal papilla (*Papilla duodenalis*), however, it is not easily visualised internally unless bile is squeezed from the ducts. Meckel's diverticulum could not be identified in any of the specimens. There is thus no way to determine the exact jejunal transition to the ileum. The second intestinal loop is considered to be formed by jejunum only and is the jejunal loop (*Ansa jejunales*) (Figs. 2.9 – 2.11). The third and fourth intestinal loops are part of the ileal loops. The third loop is the *Ansa axialis* which has both a jejunal and an ileal component. The fourth and fifth loop are the *Ansae ileales*, with the fourth loop termed the *Ansa supraduodenalis*, and the fifth and final intestinal loop is termed the *Ansa supracecalis* which is also the smallest of the loops.

2.3.3.2 Large intestine (Intestinum crassum) (Figs. 2.1, 2.9 - 2.11)

The large intestine comprises a short straight segment, also known as the rectum. The transition from the ileum to the rectum is marked by the ileocaecal opening that is not identifiable in the SGH. The rectum does not possess any loops and continues from the ileum towards the cloaca (Figs. 2.9 - 2.11). Ceacae were not observed in any of the specimens. The rectum has a slightly larger diameter than that of the small intestine.

2.3.4 Accessory organs

2.3.3.3 Pancreas (Figs. 2.9, 2.14-2.17)

The pancreas is a delicate organ situated in the *Ligamentum pancreaticoduodenale* between the descending and ascending duodenum of the *Ansa duodenalis* (Figs. 2.9, 2.16, 2.17). It is composed of three lobes, the dorsal lobe (*Lobus pancreaticus dorsalis*), the ventral lobe (*Lobus pancreaticus ventralis*) and the splenic lobe (*Lobus pancreaticus splenalis*) (Figs. 2.14, 2.16, 2.17). The *Lobus pancreaticus ventralis* is the largest lobe, extending a distance away from the apex of the duodenal loop to the point where the pancreatic duct enters the distal duodenum, marking the duodenojejunal flexure (Figs. 2.9, 2.16, 2.17). The smaller splenic lobe, extends from the cranial aspect of the ventral lobe of the pancreas towards the spleen (Figs. 2.9, 2.14). The *Lobus pancreaticus dorsalis* is broader but smaller than the ventral lobe and approximately half the length of the ventral lobe (Figs. 2.16, 2.17). Three ducts, known as *Ductus pancreaticus ventralis*, *Ductus pancreaticus dorsalis* and *Ductus pancreaticus accessorius*, are present draining into the ascending duodenum at the duodenal papilla, at the point where the bile ducts enter the ascending duodenum (Figs. 2.16, 2.17).

2.3.3.4 Liver (*Hepar*) (Figs. 2.1 – 2.6, 2.9 - 2.15)

The surface of the liver is covered by a peritoneal layer of mesothelium (Fig. 2.13A). The liver is composed of two lobes, a larger, round right lobe (*Lobus hepaticus dexter*) and a slightly smaller, oval left lobe (*Lobus hepaticus sinister*), with no further lobular subdivisions (Figs. 2.12 - 2.15). Each liver lobe has sharp lateral (*Margo hepaticus lateralis*) and caudal (*Margo hepaticus caudalis*) borders and a straight, blunt medial border (*Margo hepaticus medialis*) (Fig. 2.12 – 2.14). The two lobes are connected dorsally by the interlobar part (*Pars interlobaris*), a parenchymal bridge on the parietal surface (*Facies parietalis*) (Fig. 2.13 - 2.15). The two lobes are separated caudally by a complete deep, median, caudal interlobular incisure (*Incisura interlobaris caudalis*) (Figs. 2.16, 2.15); a cranial incisure is not present (Fig. 2.13). The parietal surface, *Facies ventralis*, of the liver is convex and moulded to the contour of the body cavity wall. The caudal vena cava (*Vena cava caudalis*) runs through a groove (*Sulcus vena cava caudalis*) in the cranial part of the right lobe (Fig. 2.13). The visceral surface (*Facies visceralis*), also the *Facies dorsalis,* is concave and has a number of organs in close proximity situated on this surface, forming impressions (Figs. 2.12, 2.14). The heart forms an impression (*Impressio cardiaca*) on the cranial *Margo hepatica* of the left and right lobe (Figs. 2.1, 2.2, 2.12). Various impressions are formed on the liver, namely the proventriculus (*Impressio proventricularis*), ventriculus (*Impressio ventricularis*), the ascending duodenum (*Impressio duodenalis*) and the spleen (*Impressio splenalis*) (Figs. 2.1 – 2.3, 2.12, 2.14). The gall bladder (*Vesica fellea*) is a small sac and is embedded in the caudal half of the right lobe's *Facies visceralis* and its apex extends to the caudal borders of that lobe (Figs. 2.13 – 2.15). It lies in the gall bladder fossa (*Fossa vesicae felleae*) (Figs. 2.13, 2.15). It is partially fused to the liver parenchyma and partly covered by peritoneum. There are two bile ducts, one passing directly from the right liver lobe to the duodenum, the common hepatoenteric duct (*Ductus hepatoentericus communis*), and the second passing via the gall bladder to the duodenum, the cystoenteric duct (*Ductus cysticoentericus*) (Figs. 2.14 – 2.17).

2.3.3.5 Blood vessels of the GIT (Figs. 2.5, 2.6, 2.9 – 2.11, 2.13 – 2.17)

2.3.4.3.1 Arteries

The larger arteries, with their satellite veins, which are more prominent without specific preservation techniques will be described here. The finer detail is not reported.

A. celiaca is the first visceral branch of the descending aorta, supplying the proventriculus, ventriculus, liver, pancreas, spleen and intestine. The *A. celiaca* has two main branches, the left branch, *Ramus sinister a. celiacae* on the left lateral aspect of the GIT and a right branch, *Ramus dexter a. celiacae* on the right lateral aspect.

The *Ramus sinister a. celiacae* (Fig. 2.5) runs from the left liver lobe, it gives off the ventral proventricular artery (*A. proventricularis ventralis*), ventral gastric artery (*A. gastrica ventralis*) and the left gastric artery (*A. gastrica sinistra*) (Fig. 2.5). *A. proventricularis ventralis* extends caudally along the ventral aspect of the proventriculus and terminates in the isthmus of the stomach. *A. gastrica ventralis* runs over the caudo-ventral midline of the *Facies annularis* of the ventriculus (Figs. 2.5, 2.10, 2.11). *A. gastrica sinistra* extends over the *Facies annularis* towards the *Centrum tendineum* (Fig. 2.5).

Ramus dexter a. celiacae (Fig. 2.6) runs towards the right *Centrum tendineum* on the dorso-lateral surface of the ventriculus, emerging from the visceral side of the spleen. The *Ramus dexter a. celiacae* supplies the spleen, right liver lobe, ventriculus, duodenum and ileum. Branches of the *Ramus dexter a. celiacae* include *A. hepatica dexter*, *Aa. ileocales*, *A. gastroduodenalis, A. pancreaticoduodenalis and R. ventralis* (Fig. 2.6). *A. hepatica dexter* is the first branch off the *Ramus dexter a. celiacae* and is a short artery that via smaller tributaries supply the duodenum, jejunum, left liver lobe and gall bladder. *Aa. ileocales* supply the *Ansa ileocalis*, the last loop of the intestine, and are perpendicular to the *Ramus dexter a. celiaca* (Fig. 2.6)*. A. gastroduodenalis* is a short artery that supplies the duodenum (Figs. 2.16, 2.17). *A. pancreaticoduodenalis* runs from the latter, between the ascending and descending duodenum supplying the duodenum and pancreas (Figs. 2.14, 2.16, 2.17).

The cranial mesenteric artery (*A. mesenteric cranialis*) travels with the cranial mesenteric veins, supplying the small intestine (duodenum, jejunum and ileum) (Figs. 2.10, 2.11). The caudal mesenteric artery (*A. mesenteric caudalis*) travels with the caudal mesenteric veins and supplies the terminal part of the ileum (*Ansa supracecalis*) and large intestine (rectum and cloaca) (Figs. 2.10, 2.11). The *A.*

mesenteric caudalis branches off to form *R. cranialis* that supplies the *Ansa supracecalis* and *R. caudalis* that supplies the rectum and cloaca.

2.3.4.3.2 Veins

The main veins, with their tributaries, which are of relevance for surgery and landmarks, will be described here. The finer detail is not reported.

The left hepatic portal vein (*V. portae sinistrae hepatis*) is a small vessel located on the visceral surface of the dorsal lobe of the liver and the point of the *Incisura angularis* (Fig. 2.5) and receives venous return from the proventriculus and ventriculus. The following four are well-defined venous tributaries to the left hepatic portal vein: ventral proventricular veins (*Vv. proventriculares ventralis*), left proventricular vein (*V. proventricularis sinistra*), left gastric vein (*V. gastrica muscularis sinistra*) and the ventral gastric vein (*V. gastrica muscularis ventralis*). The *Vv. proventriculares ventralis* drains the left ventrolateral aspects of the proventriculus (Fig. 2.5). The *V. proventricularis sinistra* is a fine tributary of the left hepatic portal vein located at the *Isthmus gastris* and receives blood from the left aspect of the *Isthmus gastris* as well as the caudal portion of the proventriculus and the cranial portion of the ventriculus and then opens into the *V. gastrica muscularis sinistra* (Fig. 2.5). The *V. gastrica muscularis sinistra* is the longest of the *V. portae sinistrae hepatis* tributaries, draining all the components of the left aspect of the ventriculus by smaller tributaries (Fig. 2.5). The *V. gastrica muscularis ventralis* is situated along the whole length of the ventral border of the ventriculus (Fig. 2.5).

The right hepatic portal vein (*V. portae dextrae hepatis*) (Figs. 2.13, 2.15) is the largest tributary of the *Vv. portae hepatis* and receives blood from the proventriculus, spleen, pancreas and intestines. There are four main tributaries known as the proventriculosplenic vein (*V. proventriculosplenica*), splenic vein (*Vv. splenicae*), gatropancreaticoduodenal vein (*V. gastropancreatico duodenalis*) and common mesenteric vein (*V. mesenterica communis*). The *V. proventriculosplenica* is the first and or nearest venous tributary of the *V. portae dextrae hepatis* passing between the spleen caudally and most of the upper part of the right lobe of the liver cranially (Fig. 2.). The *Vv. splenicae* are short veins emerging from the splenic hilus (Fig. 2.6). The *V. gastropancreatico duodenalis* is formed by three main tributaries at the same point of entrance; the right gastric vein (*V. gastrica muscularis dextra*) from the right side, the cranial ileocecal vein (*V. ileocecalis*) from the left side and the pancreaticoduodenal vein (*V. pancreaticoduodenalis*) which is considered as its caudal continuation (Figs. 2.11, 2.14, 2.16, 2.17). The *V. pancreaticoduodenalis* is a direct continuation of the of the *V. gastropancreatico duodenalis*, passing between the descending duodenum and the ascending duodenum and in some areas being hidden by the lobes of the pancreas (Figs. 2.11, 2.14, 2.16, 2.17). The common mesenteric vein (*V. mesenterica communis*) is the largest of the *V. portae dextrae hepatis* tributaries and is formed by two great veins at the duodenojejunal flexure, namely, the cranial mesenteric vein (*V. mesenterica cranialis*) and caudal mesenteric vein (*V. mesenterica caudalis*) (Figs. 2.10, 2.11).

The *V. mesenterica cranialis* is the main vein that drains the greater portion of the small intestine from the duodenojejunal flexure to the terminal part of the ileum. It is formed by *Vv. jejunales* that drains the entire jejunum, *Vv. ileae* that drains the initial portion of the ileum and finally the *V. ileocalis* that drains the middle portion of the ileum (Figs. 2.10, 2.11). The *V. mesenterica caudalis* runs from the cloaca to the junction with the *V. mesenterica cranialis* before forming the *V. mesenterica communis* (Figs. 2.10, 2.11).

2.4 Discussion

2.4.1 Topography

As a result of the post-mortems conducted on the carcasses it was not possible to confirm all the partitions and thus some variations may exist.

The size and position of the digestive organs are important when evaluating topography and pathology on diagnostic imaging. The most frequently performed radiographic views in avian species include ventro-dorsal (VD) and left-to-tight lateral (LeRtL) whole body projections (Murray, 1997). Radiodense material can be viewed on both VD and lateral radiographs, caudal and ventral to the proventriculus (Langlois, 2003). The position of the intestinal tract is widely variable between species but it generally occupies the caudal, dorsal abdominal cavity and does not normally contain gas (Murray, 1997; Forbes, 2002). The duodenal loops lie to the right of the ventriculus in the VD view (Murray, 1997). The liver does not usually extend past the sternum on the lateral radiograph

(Forbes, 2002). Abdominal masses usually cause a change in the location of the GIT (Ritchie, 1994). Gastrointestinal symptoms were 43% more common than pulmonary symptoms, with 31% demonstrating gastrointestinal lesions, 10% liver lesions and 43% with both (Lamps *et al.*, 2000). Interestingly, 49% of patients demonstrated gross gastrointestinal features including ulcers. Viral infections pose a big risk to poultry and result in inapparent infection or gastrointestinal disease characterised by proventriculitis or enteritis (Perry, 2006). Impaired HCL and pepsinogen synthesis and nutrient absorption result (Perry, 2006). Gastrointestinal diseases induced by viruses damage only two cells, namely, the glandular epithelium of the proventriculus and enterocytes of the intestine, in turn resulting in impaired HCL and pepsin secretion and nutrient digestion and nutrient and water absorption (Perry, 2006). As noted by Klaphake and Clancy (2005), even though liver neoplasia is uncommon, general hepatic disease is very common in raptor species making liver topography challenging, a similar situation was noted in the specimens from this study on the SGH.

Jenkins (2000) reported a ventral midline approach for laparotomy for foreign body removals. Upon gastro-intestinal surgery it is important to note that the proventriculus does not hold sutures well, and the muscular ventriculus can rather be used to place stay sutures and navigate through the ventriculus (Jenkins, 2000). As noted before foreign body obstruction in the proventriculus is uncommon in the SGH. The most useful approach for foreign body removal, is the left lateral celiotomy, through an incision between the sixth rib to the level of the pubic bone on the left abdominal wall (Forbes, 2002). Ventricular foreign bodies can then be accessed via the *Isthmus gastris*, avoiding the proventricular vessels along the greater curvature (Forbes, 2002). This is important to note as most foreign bodies in the SGH are located in the ventriculus.

2.4.2 Stomach

2.1.1.1 Proventriculus

In most avian species the shape of the proventriculus is fusiform, with variation more often noted in the relative size of the organ (Al-Saffar and Eyhab, 2016). The current study noted a fusiform shape of the proventriculus of the SGH, similar to that described for many bird species including the brown falcon (*Falco berigora*) (Al-taee, 2017), greater rhea (*Rhea americana americana*) (Rodrigues *et al.*, 2012), emu (*Dromaius novaehollandiae*) (Fowler, 1991), southern cassowary (*Casuarius casuarius*) (Fowler, 1991), black-winged kite (*Elanus caruleus*) (Hamdi *et al.*, 2013) and white-backed vulture (Houston and Cooper, 1975). The structural differences of the size in the proventriculus and ventriculus is largely determined by the dietary preferences of the species (Leopold, 1953), and in carnivorous birds that swallow big victuals, there is little distinction between the macroscopic appearance of the proventriculus and the ventriculus (Baumel, 1993). For example, in the omnivorous greater rhea, the proventriculus is much smaller than the ventriculus (Rodrigues *et al.*, 2012), whereas the emu and southern cassowary (Fowler, 1991), and the cattle egret (*Bubulcus ibis*) (Hussein and Rezk, 2016), the proventriculus in relation to the ventriculus, is only slightly larger. The proventriculus of the SGH presented with low, longitudinal folds in the lumen (present study). Longitudinal folds on the mucosal surface of the proventriculus is a common feature for carnivorous and piscivorous species and uncommon in other bird species with plant-based diets (Langlois, 2003). Such folds have been noted in the red-tailed hawk (Langlois, 2003), red-capped cardinal (*Paroaria gularis gularis*) (Catroxo, Lima and Cappellaro, 1997) and eurasian hobby (Abumandour, 2014). In carnivorous and piscivorous bird species, the proventriculus acts as a site of food storage, made possible by the folds which allow for distention (King and McLelland, 1984; Langlois, 2003) and also increases the surface area (Klasing, 1999). The proventriculus is often quite large and distensible in carnivores, so that large food items can pass through, similarly in the SGH the proventriculus is distensible to allow prey to pass through to the ventriculus. In ostriches the proventriculus is also used for water storage (Duke, 1997). The proventriculus of the SGH, although distensible, was relatively smaller than that of the empty ventriculus, and would not be suited to house large prey, such as hares and snakes, which they are known to consume (Kemp and Kemp, 1980). This supports the notion (Duke, 1997) that the ingesta of the SGH would not spend much time within the proventriculus but rather pass through to the ventriculus. Additionally, as the SGH is not known to consume much water (Kemp and Kemp, 1980), it would not likely act as a water storage organ as described in the ostrich (Duke, 1997).

The proventriculus and ventriculus are separated by a constriction (*Isthmus gastris*) in many bird species (Nickel, Schummer and Seiferle, 1977; King and McLelland, 1984; Rossi *et al.*, 2005; Hassan and Moussa, 2012; Hamdi *et al.*, 2013) including the SGH (present study). However, the *Isthmus gastris* was not reported in the cattle egret and the black winged kite, where the proventriculus together with the ventriculus present externally as one chamber (Hamdi *et al.*, 2013; Beheiry, 2018). This area is generally devoid of glands (Denbow, 2000) and in flower-seeking parrots (*Psittaciformes*) this zone has developed into a highly distensible storage organ with very few glands (Farner, 1960). The isthmus and or intermediate zone is of varying lengths in different species. In the SGH, similar to that described in the mallard (*Anas platyrhynchos*) and domestic pigeon (*Columba livia domestica*) (Hassan and Moussa, 2012), it is relatively long, whereas in the chicken it is short (Calhoun, 1954). The ostrich lacks the isthmus and there is a large opening between the proventriculus and the ventriculus, making the surgical removal, or the endoscopic removal of ventricular foreign bodies easier in this species (Fritz *et al.*, 2012). As the SGH is prone to swallowing foreign bodies in captivity (K.N. Koeppel, personal communication) the presence of the isthmus would make this, as described in the ostrich, less feasible. Although this junction is apparently unspecialised and featureless, it has been reported that the *Zona intermedia gastris* is a common place for neoplasms in birds (Langlois, 2003).

The distribution of the proventricular glands is not consistent among avian species (Langlois, 2003). Generally, they are distributed evenly throughout the proventriculus, however, variations exist and they are restricted to longitudinal tracts in owls (strigiformes) and to a circular patch on the greater curvature in ratites (King and McLelland, 1984; Langlois, 2003) and longitudinal folds with gland-free zones are seen in flower-seeking parrots (Farner, 1960). In the SGH (present study) they were more concentrated in the ventral aspect, with a small gland free zone dorsally. The gland-free zones in the flower-seeking parrots makes the organ more distensible (Farner, 1960). Considering the large prey consumed by the SGH, it is possible that the gland-free zone on the dorsal inner surface of the SGH has a similar function. Some of the glands present in the proventriculus empty into the caudal aspect of the proventriculus, also known as the *Zona intermedia gastris*, and cranial aspect of the ventriculus suggesting that the food does not spend a long period of time within the proventriculus but rather that the main digestion occurs within the ventriculus where the gastric juices travel after being secreted into the small proventriculus (Bailey *et al.*, 1997). The proventriculus is the site at which digestion is initiated (Klasing, 1999), and the size, structure and gland distribution in the SGH are all indicators that the proventriculus is not a storage organ.

2.4.2.1 Ventriculus

The structure of the carnivorous ventriculus is much simpler than that of the granivorous bird (Calhoun, 1954; Al-taee, 2017). In the granivorous chicken the ventriculus is much more complex, and has an extremely thick wall with little room for distention as it receives relatively indigestible foods that need to be ground (Klasing, 1999). As an example of a more complex ventriculus, the body of the ventriculus separates the two tapering ends, namely, the *Saccus cranialis* and *Saccus caudalis*, as described in the chicken and houbara bustard (*Chlamydotis undulata*) (Bailey *et al.*, 1997). The ventriculus of the SGH displayed a simple structure and some features are discussed below.

In captivity, for reasons still unknown, the SGH is an indiscriminate eater and has been found to ingest non-food items such as wires, bolts, plastic and stones (K.N. Koeppel, personal communication). In the present study, chicken heads were some of the largest items noted within the ventriculus, as well as other items such as bones, some plastic waste, little glass pieces and unknown objects, confirming the observation that the SGH consumes non-food items. In one SGH specimen a solid ball of fur was present in the ventriculus; this has been noted in raptors where the ventriculus may also be impacted by a hard ball of fur (King and McLelland, 1984). In birds such as the chicken (Sacranie *et al.*, 2012) and ostrich (Fritz *et al.*, 2012), it is well known that stones, grit and rocks are abundant within the ventriculus, consumed by the birds for their role of grinding down plant material. In contrast to the thick-walled ventriculus of granivores, the carnivore/piscivore ventriculus, as described in the SGH (present study), is thin-walled, relatively poorly muscled, and lacks the opposing pairs of thick and thin muscles that are responsible for the contractions that grind the food in many other avian species (Murray, 2014). If the food is soft, as in a meat-based diet, only the action of digestive juices are required for adequate breakdown, and the ventriculus is distensible and has weaker musculature (Farner, 1960); features all described in the SGH. Gastric motility in carnivorous avian species, which lack the thin and thick musculature of granivorous species, starts at the pylorus and proceeds around the greater curvature to mix the gastric content for greater digestion by secretions from the proventriculus rather than grinding by thick musculature (Duke, 1989). The relatively thinner wall and absence of rocks in the ventriculus of the SGH's in the present study, support the notion that the main digestive mechanism occurs by enzymes and not grinding by a thick muscular ventriculus.

A thin koilin layer was present in the ventriculus of the SGH (present study). The koilin layer, or cuticle, varies according to the species, it’s habitat and the food consumed (Abumandour, 2014), additionally, it is not present in all bird species and is absent in the cassowary (Langlois, 2003) and white-backed vulture (Houston and Cooper, 1975). A koilin layer reportedly covers the surface of the proventriculus of the greater rhea (Fowler, 1991), an unfamiliar finding amongst bird species. The cuticle, which is produced by mucosal glands of the ventriculus, functions primarily to protect the mucosa from the gastric juice produced by the proventriculus (Murray, 2014). The ventriculus thus has the ability to distend in order to accommodate whole prey (Ford, 2010), this is due to several longitudinal folds running circumferentially around the tendinous centre (Murray, 2014). These folds and the ability for the ventriculus to hold large prey have been noted in the SGH (present study). Hydrochloric acid (HCL) and pepsin, secreted in the proventriculus, are added to the food and are responsible for chemical digestion (Klasing, 1999). The ventriculus thus acts more as storage organ to allow time for the gastric juices to digest the ingesta (King and McLelland, 1984; Langlois, 2003). A greater volume received in the ventriculus results in a greater retention time and a greater pepsin and HCL secretion (decreasing pH) allowing for enhanced and more rapid digestion in poultry breeds, such as the chicken (Svihus, 2014). As noted above, the ventriculus is the site for enzymatic digestion, and the integrity of the cuticle in the SGH would be especially important for this species. This will be further discussed in Chapter 3.

The pyloric opening resembles a third chamber below the muscular stomach and is found in many aquatic and raptor species (Duke, 1997; Ford, 2010; Murray, 2014). The pyloric region/opening is the region where the liquefied ingesta enters into the small intestine, while trapping or filtering undigested food components such as feathers and bones (Murray, 2014). The filtered content in the pyloric region forms a cast and is egested by reverse peristalsis (Duke, 1997). Raptors normally regurgitate pellets, which are composed of the bones, fur and feathers of their prey (Murray, 2014). The SGH very seldom and uncommonly produces a casting (K.N. Koeppel, personal communication), and likely function similar to Falconiformes that digest bones of their prey and often eat more than one meal before casting (Murray, 2014). Strigiformes have decreased digestibility and often pass pellets with complete skeletons and as often as one pellet per prey that is eaten (Murray, 2014). The osprey (*Pandion haliaetus*) produces pellets that are small and rarely seen, which indicates that most of their dietary items pass through the entire GI tract (Poole, 1989), this has also anecdotally been observed in the SGH. As a result of anatomic and pyloric function in birds of prey, ingested foreign bodies should be confined to the upper alimentary tract and stomach (Ford, 2010).

2.4.3 Intestines

2.4.3.1 Small intestine

Chemical digestion and absorption of food occur in the small intestine (King and McLelland, 1984). It is also the organ which displays less variability between avian species in comparison to other organs, with the only major difference noted being the length among raptors (Murray, 2014), and generally among different avian species (Scanes, 2015). The difference in the length of the small intestine affects digestive efficiency (Murray, 2014); with a shorter digestive tract having lower efficiency. In birds the small intestine is arranged in a series of loops (King and McLelland, 1984). In all species the first loop consists of the duodenum and in some species such as the white-tailed sea eagle (*Haliaeetus albicilla*) and the Jackass penguin (*Spheniscus demersus*) the duodenal loop is thrown into a series of secondary folds (King and McLelland, 1984). The duodenum in the SGH was a single, simple loop (present study).

Each intestinal loop present in the SGH possesses a 180° bend. Such bends are usually, for example those present in the equine ascending colon, prone to obstructions (Cunningham and Klein, 2007). However, despite the presence of 180° bends, obstructions of the intestinal tract are rare in birds of prey, with the occasional urolithiasis in chronically or severely dehydrated individuals (Ford, 2010). Disabled free-living birds of prey may suffer from uroliths during severe water- and food-deprivation due to the efficiency of water resorption in the rectum and cloaca (Ford, 2010). Intestinal foreign bodies are not reported in the SGH (K.N. Koeppel, personal communication).

The intestines are marked by transition points in order to distinguish different sections from one another. The transition from the duodenum to the jejunum is marked by the point where the bile ducts enter the ascending duodenum (Denbow, 2000; Batah and Selman, 2012) and this is also considered the transition in the SGH (present study). Meckel's diverticulum (*Diverticuli vitellinae*) marks the transition from the jejunum to the ileum, such as noted in the chicken (Calhoun, 1954) and common quail (*Coturnix coturnix*) (Zaher *et al.*, 2012). However, it cannot be identified in in some birds including the houbara bustard (*Chlamydotis undulata*) (Bailey *et al.*, 1997) the canary (*Serinus canaria domestica*) (Hristov *et al.*, 2017), black winged kite (Hamdi *et al.*, 2013), the coot bird (Batah and Selman, 2012), and was also not identifiable in the SGH (present study). Meckel's diverticulum may also vary in size and in Passeriform species, woodpeckers (*Picidae*), parrots (*Psittaciformes*), doves (*Columbidae*) and pigeons (*Columbidae*) it is usually rudimentary or not visible (Farner, 1960). Another method to identify transitions other than by anatomical landmarks is to assign an anterior portion to the ceca as the ileum and a posterior portion to the duodenum as the jejunum (Turk, 1982). As the SGH intestine is composed of loops, the present study took the 2nd loop to represent the jejunum only, the 3rd loop to be composed of jejunum and ileum, and the 4th and 5th loops to be ileum only. Alternatively, another reliable way to determine the point of transition, is the point where the last branch of the cranial mesenteric artery supplies the small intestine or the presence of arterial branches which indicate the transition from the jejunum to the ileum (Farner, 1960). Meckel's Diverticulum lies at a point opposite to the distal branches of the cranial mesenteric artery and can be used to divide the jejunum from the ileum (King and McLelland, 1984). In the absence of Meckel's diverticulum, such as in the SGH, the latter method would be more difficult to use in identifying this location. Thus in the SGH there is no reliable way to determine the jejunum from the ileum, other than using the method described by Turk (1982) and by identifying the various loops.

It is known that small intestinal and cecal lengths of red grouse (*Lagopus lagopus scoticus*), derived from the wild, decrease over successive generations when maintained in captivity because of the change in diet (Moss, 1972). Changes in gastrointestinal morphology induced as a consequence of captivity could be a factor influencing the survival of released captive-reared birds (King and McLelland, 1984). However, data on the morphology of the alimentary tract of captive and free-living bustards are scarce (Bailey *et al.*, 1997).

2.4.3.2 Large intestine

The large intestine in the SGH was slightly wider in diameter than the small intestine, was short and unremarkable. In general, the large intestine can be distinguished from the small intestine by a slightly larger diameter of the colon versus that of the ileum (Bailey *et al.*, 1997). Another, more commonly used landmark to identify this junction is the presence of cecae (Scanes, 2015). The main function of the large intestine is to reabsorb water, electrolytes and some of remaining nutrients in the ingesta by antiperistaltic movements (Turk, 1982; Klasing, 1999). There is evidence that in the domestic fowl the cloaca and rectum may have the ability to reabsorb water from ureteral urine and this may be especially important in the water economy of desert avian species (King and McLelland, 1984). Many birds of prey do not require water beyond that provided in their prey, specifically in the wild Ford (2010). This provides a possibility that the SGH, like the domestic fowl mentioned in King and McLelland (1984), also have the ability to reabsorb water in the rectum an cloaca.

Lymphoid type cecae are either very small, vestigial or absent in falciformes such as in eagles, hawks, vultures and other birds of prey (Clench and Mathias, 1995). In general herbivores possess larger cecae than carnivores (Clench and Mathias, 1995). However, the exceptions are many, for example hawks and owls, with similar diets, have cecae diverse in size and histological structure (Clench and Mathias, 1995). This suggests that non-dietary factors may be a more important factor for the presence of cecae than dietary factors (Clench and Mathias, 1995; Bailey *et al.*, 1997). More than two thirds of birds are said to have rudimentary cecae (Klasing, 1999). Thus the function of cecae is still only partly understood but can be that of water absorption, non-protein nitrogen absorption, digestion of carbohydrates and protein, microbial decomposition of cellulose, and microbial synthesis and absorption of vitamins (Farner, 1960). The absence of cecae in the SGH would indicate that the latter functions take place elsewhere in the intestinal tract.

2.4.4 Accessory organs

2.4.4.1 Pancreas

Pancreas size is reported to be smaller in carnivores (King and McLelland, 1984), and is possibly related to the high digestibility of the diet (Murray, 2014). The significance of the size differences according to diet is unknown (Bailey *et al.*, 1997), and is supported by the lack of literature to the topic. The SGH’s pancreas, unlike that of the chicken consisted of 3 lobes, similar to other raptor species (Murray, 2014). The pancreas of Strigiformes extended to half the length of the duodenal loop, the SGH's pancreas extend to about half the length of the duodenum and was even smaller in Falconiformes (Ford, 2010; Murray, 2014) .

The pancreas in the chicken and common quail (*Coturnix coturnix*) is considered to have four lobes (Baumel, 1993) and in the moorhen (*Gallinula*) three lobes (Al-Samarae, Thayer and Swad, 1999). The four lobes consist of the ventral lobe, dorsal lobe, third lobe and splenic lobe, with the third lobe absent in the 3-lobed pancreas (Baumel, 1993). The function of the different lobes is unknown (Paik, Fujioka and Yasuda, 1974).

Considerable differences related to the number, course and opening of the pancreatic duct is noted in the literature. There is generally a single pancreatic duct noted in the ostrich, opening into the ascending duodenum independently of the hepatoenteric duct, while three main ducts are usually expected, as seen in the gallinaceans (Paik *et al*., 1974; Botte and Pelagalli, 1982; Sisson and Grossman, 1982; Nickel *et al*., 1984), two to four ducts are reported in the mallard (*Anas platyrhynchos*) (Liu et al., 1998), and numerous ducts in the starling (*Sturnus vulgaris*) (Vinnicombe and Kendall, 1983). The pancreatic ducts generally drain into the distal part of the ascending duodenum and rarely drain into the descending loop of the duodenum (Scanes, 2015). Similar to that reported in gallinaceans the SGH had 3 pancreatic ducts (present study). The function of the variation in amount of pancreatic ducts is unknown, with most research only referring to the number of ducts only.

Pancreatic pathology is very uncommon, although a case of pancreatic atrophy was reported in a peregrine falcon, occasional pancreatic insufficiency is noted and no reports of any pancreatic neoplasia has been made in raptors (Klaphake and Clancy, 2005).

2.4.4.2 Liver

The liver of avian species can be characterised according to size, weight, consistency and colour, these factors are dependent on breed, age and nutritional status of the individual bird (Nickel, Schummer and Seiferle, 1977; Bailey *et al.*, 1997). The avian liver has two lobes, the right lobe is larger than the left lobe in most species, such as in pigeons (*Columbidae*), houbara bustard (*Chlamydotis undulata*) and ostrich (*Struthio camelus*) (Al-Aaraji, 2015), whereas in raptors (Murray, 2014) and *Galliformes* (Schmidt, Reavill and Phalen, 2003) the size difference is less pronounced. This was also in contrast to the present study on the SGH where the two lobes were of more pronounced size differences. In many species one or both of the liver lobes are partly subdivided (Al-Aaraji, 2015), the left liver lobe of the chicken (*Gallus gallus domesticus*) and turkey (*Meleagris*) is divided by a deep incisure (Baumel, 1993). The coot bird liver also has subdivisions (Batah and Selman, 2012), whilst the liver of the chicken displays different sizes and shapes, but no subdivisions (Lucas and Denington, 1956). The liver of houbara (*Chlamydotis undulata macqueenii*) and Kori (*Ardeotis kori*) bustards (Bailey *et al.*, 1997), the laughing dove (*Spilopelia senegalensis*), white throated kingfisher (*Halcyon smyrnensis*) and common kestrel (*Falco tinnunculus*) (Al-Hamadawi *et al.*, 2017) also had no subdivisions.

The liver's main functions include storing and metabolizing fats, sugars, and vitamins; synthesizing acids, proteins and bile salts; and controlling excretion and detoxification of waste products in the blood (Klaphake and Clancy, 2005). The liver is larger in raptors in comparison to other avian species (Klaphake and Clancy, 2005). Liver size is correlated to the type of diet, with insectivores and piscivores having the largest livers relative to body size (King and McLelland, 1984; Bailey *et al.*, 1997). As an example, ducks that were fed on fish diet had much larger livers than ducks fed on grain or meat diets (Magnan, 1912b). Supporting the variable size of livers in relation to diet, it was shown that the metabolism of proteins, fats, and carbohydrates is higher in the liver of snow geese (*Chen caerulescens*) and the weight of the liver changes in relation to the level of food consumed which is responsive to dietary changes (Ankney, 1977). The large liver of the SGH supports a high metabolic rate, protein, acid and bile salt synthesis, and excretion and detoxification processes.

In the chicken, the liver has a clear transverse cleft or groove on the visceral surface of both liver lobes which reveal the entrance of the large portal veins, hepatic arteries, the two emerging bile ducts and the well-defined fusiform gall bladder (Maher, 2019). Carnivorous species have particularly well developed gall bladders (Ford, 2010; Murray, 2014). Bile is produced and secreted by the liver and is essential for fat digestion and emulsifying lipid for digestion (Scanes, 2015). The gall bladder can store and concentrate the bile in the inter-digestive state and eject it into the duodenum after a meal to assist in lipid digestion and absorption (Romański, 2010). During fasting states the bile is stored, while the remaining bile slowly inflows into the bowel (Romański, 2010). The gall bladder collects and stores bile from the liver, continuously secreting bile into the duodenum for the emulsification of fats (Klaphake and Clancy, 2005). Hepatic malfunction can be measured by raised bile acids (Denbow, 2000). It is of note that the gall bladder is absent in some herbivores, the majority of pigeons, many parrots and the ostrich (King and McLelland, 1984). The SGH forages during the day, going on "foraging trips" in large groups, averaging 8 feeds per day (the number of bill-fulls and not the number of food items) (Kemp and Kemp, 1980). The latter all supports the SGH's well-developed gall bladder would potentially store and concentrate bile in the evening inter-digestive state for daily sporadic feed consumption.

Corresponding to the findings in the bustards the *Ductus cysticoentericus* and *Ductus hepatoentericus* drained separately into the duodenum (Bailey *et al.*, 1997). This is in contrast to the Kori bustard where a single bile duct opened into the duodenum (Maloiy, Warui and Clemens, 1987). Two bile ducts emerge from the right liver lobe, one of these originating from the gall bladder and the second provides a direct connection from the liver to the small intestine in the common quail (Hamdi *et al.*, 2013). This generally occurs on the ascending loop of the duodenum (Klaphake and Clancy, 2005; Hamdi *et al.*, 2013; Murray, 2014). However, in some species, including the ostrich and Columba, the ducts empty into the descending loop of the duodenum (Scanes, 2015). Relatively little is known about biliary secretion in birds possibly due to the complex anatomy in which the bile enters the small intestine via both the common hepatoenteric duct and the cysticoenteric duct (Scanes, 2015). The common hepatoenteric duct drains bile from both the left and right lobes of the liver into the duodenum (King and McLelland, 1984). The cysticoenteric duct directly connects the gall bladder with the duodenum (Baumel, 1993). The latter can be significant in determining the transition from the duodenum to the jejunum in some species, especially in the SGH where the bile ducts enter the ascending duodenum making it possible to use as a landmark for transition, but may not be in other species.

This chapter confirms that the GIT of the SGH is typical as expected for carnivorous birds. The stomach is adapted for chemical digestion and possesses the ability for massive expansion. Although the vasculature is mostly of academic interest, of note in the present study is that surgical access to the ventriculus would best be gained from the left side as the right side is largely covered by the vessels. The GIT is well-vascularised and together with the large liver and pancreas, supports rapid and complete digestion. This morphological description should be used in future to aid in the description and the location of pathologies as well as to describe surgical techniques in the SGH.

2.5 Figures

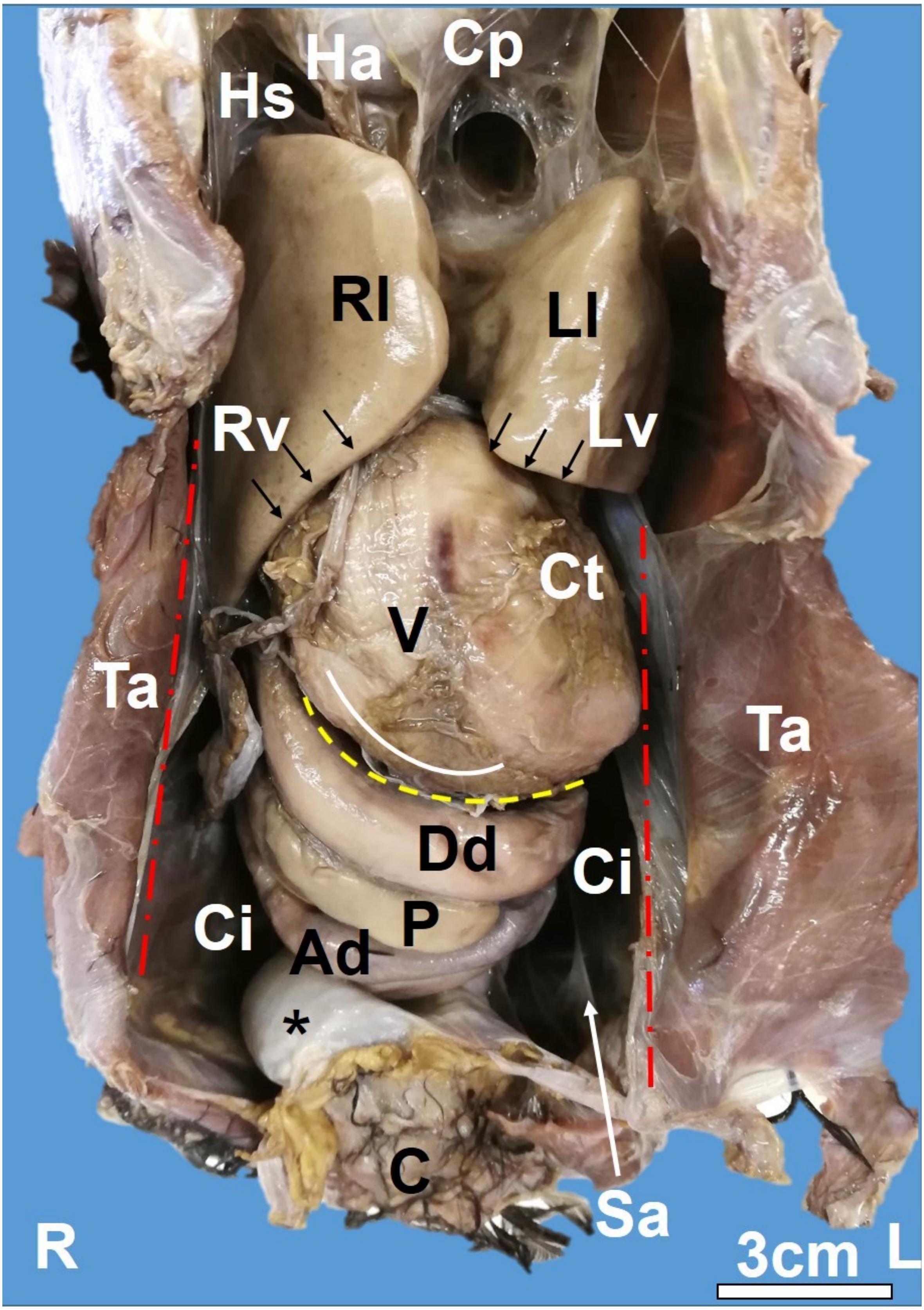

Fig. 2.1: Ventral view of the superficial topography of the coelomic cavity.

Fig. 2.1: Ventral view of the superficial topography of the coelomic cavity. The sternum is reflected cranially (not seen in the image), the ribs transected and the abdominal wall incised in the midline and reflected laterally to the right (R) and left (L). The left (Lv) and right (Rv) ventral *Cavitas peritonealis hepatica*, the caudo-medial surfaces of left (Ll) and right (Rl) liver lobes contact (black arrows) the cranial part of the ventriculus (V). The ventriculus is positioned in the left *Cava hepatica peritonei ventralis* with the *Facies annularis* (white curved line) and the *Centrum tendinuem* (Ct) visible in the superficial view. The *Cavitas peritonealis intestinalis* (Ci) encloses the duodenal loop with the descending duodenum (Dd), pancreas (P) and ascending duodenum (Ad) and the rest of the intestines (not visible in the ventral view). Heart apex (Ha) enclosed in the *Cavitas pericardialis* (Cp). *Septum posthepaticum* (yellow dotted line) seperates the *Cavitas peritonialis hepatica* from the *Cavita intestinale peritonei*. Transverse abdominal muscle (Ta), horizontal septum (Hs), oblique septum (red dotted lines), cloaca (C), unknown structure that was not seen in other specimens (*) and abdominal air sacs (Sa).

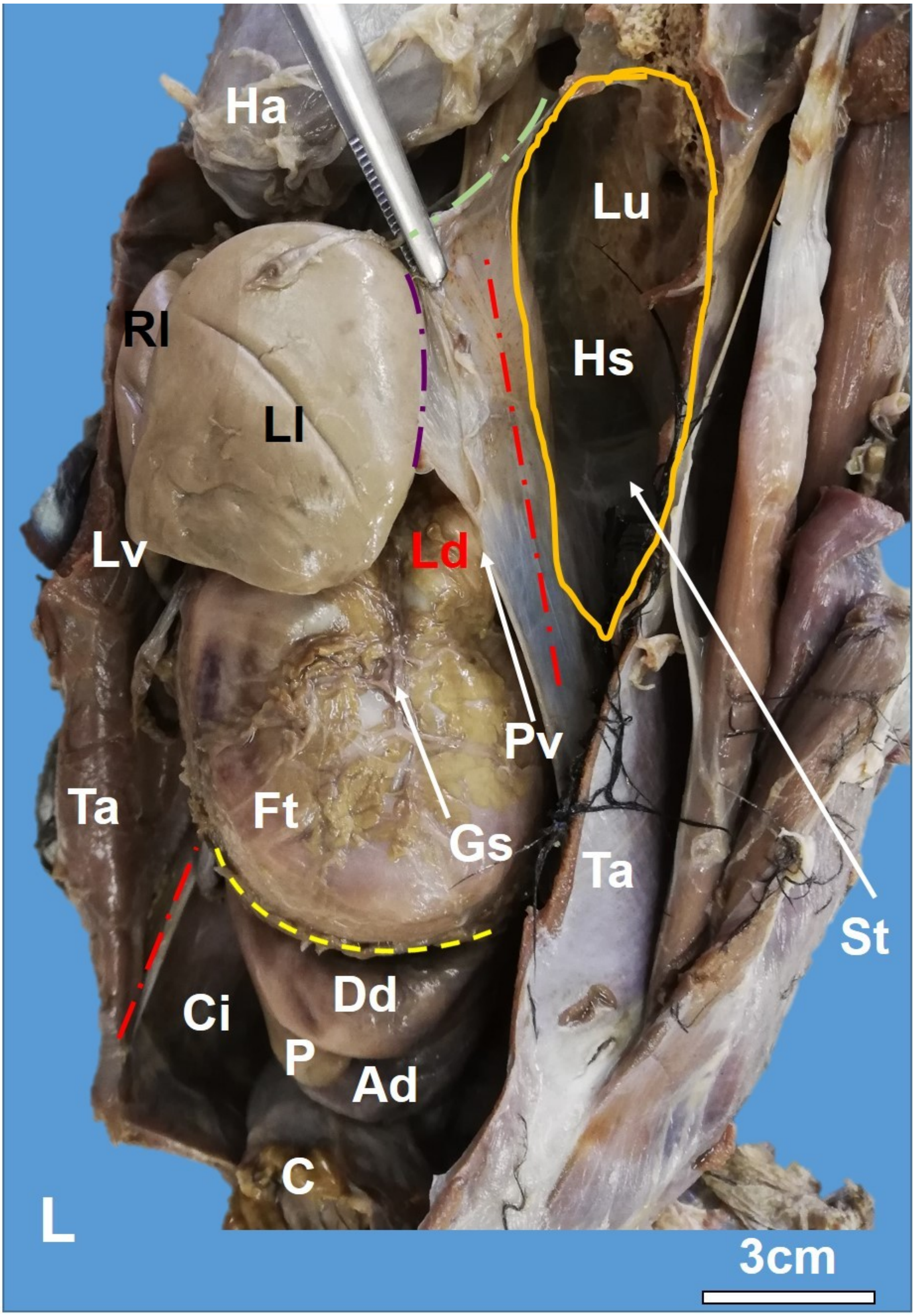

Fig. 2.2: Left lateral view of the superficial topography of the coelomic cavity.

Fig. 2.2: Left lateral view of the superficial topography of the coelomic cavity. The sternum is reflected cranially (not seen in the image), the ribs transected and the abdominal wall incised in the midline and reflected laterally to the left (L). *Septum horizontale* (Hs) situated caudal to the lungs (Lu) and dorsal to the *Septum obliquum* (red dotted line). *Ligamentum hepaticum sinistrum* (green dotted line) connects the liver to the *Septum obliquum* and divides the left *Cava hepatica peritoni ventralis* (Lv) from the left *Cava hepatica peritoni dorsalis* (Ld). The *Saccus thoracicus cranialis* (orange outline) is the open space between the *Septum horizontale* and the *Septum obliquum*. The posthepatic septum (yellow dotted line) seperates the *Cava hepatica peritoni* from the *Cavitas peritonealis intestinalis* (Ci). Descending duodenum (Dd), pancreas (P) and ascending duodenum (Ad) situated within the *Cavitas peritonealis intestinalis* (Ci). Heart apex (Ha), transverse abdominal muscle (Ta), ventriculus (V), proventriculus (Pv), thoracic air sacs (St), *A. gastrica sinistra* (Gs).

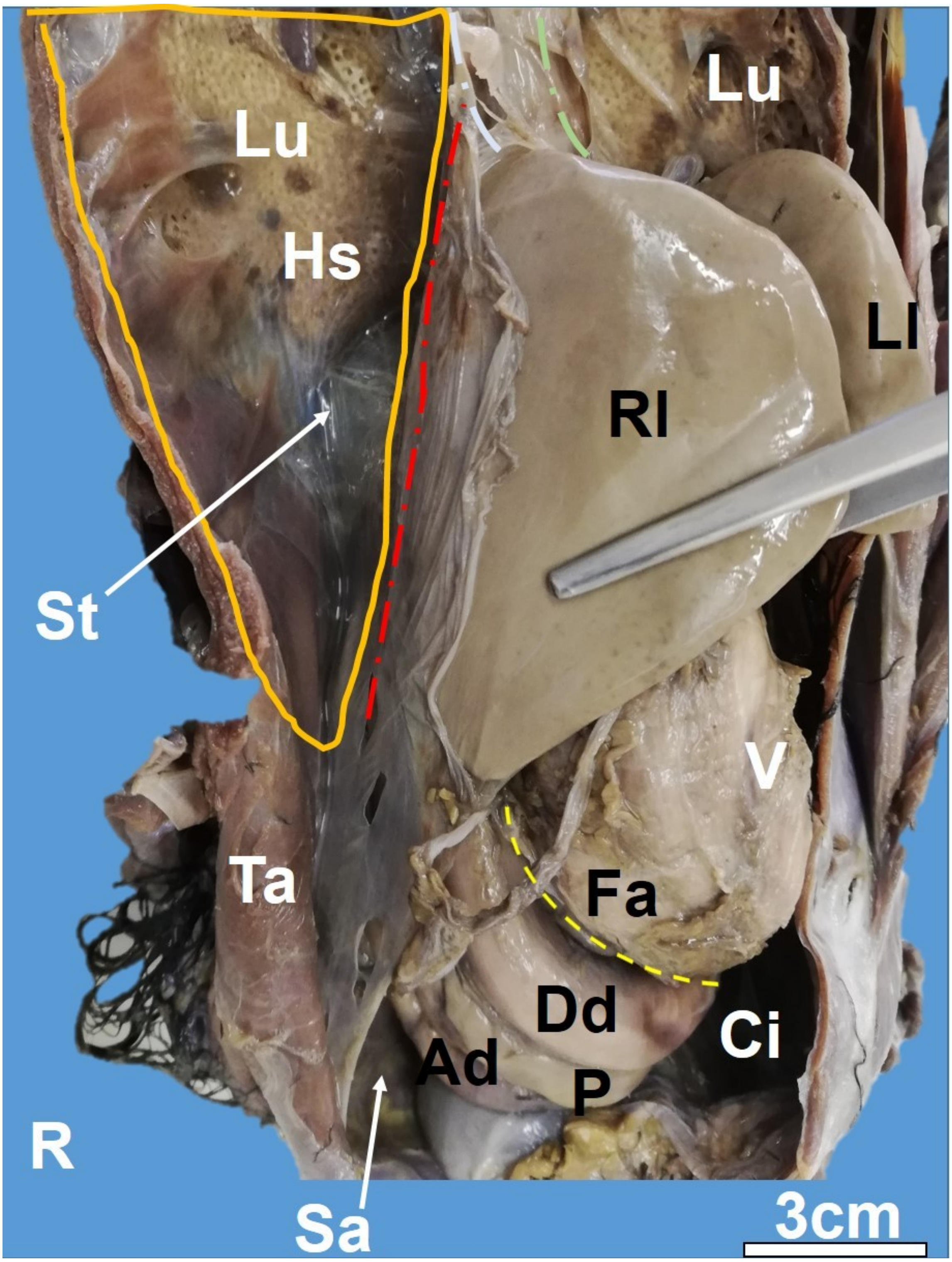

Fig. 2.3: Right lateral view of the superficial topography of the coelomic cavity.

Fig. 2.3: Right lateral view of the superficial topography of the coelomic cavity. The sternum is reflected cranially (not seen in the image), the ribs transected and the abdominal wall incised in the midline and reflected laterally to the right (R), heart removed. *Septum horizontale* (Hs) situated ventral to the lungs (Lu) and dorsal to the *Septum obliquum* (red dotted line). *Ligamentum hepaticum sinistrum* (green dotted line) and *Ligamentum hepaticum dextrum* (blue dotted line) connects the liver to the *Septum obliquum* on both lateral sides. The posthepatic septum (yellow dotted line) seperates the *Cava hepatica peritoni* from the *Cavitas peritonealis intestinalis* (Ci). The thoracic air sacs (St) are situated dorsal to the *Septum obliquum* in the *Dorsal cava hepatica peritoni* and the abdominal airsacs (Sa) are situated dorsal to the intestines in the *Cavitas peritonealis intestinalis* (Ci). The space between *Septum horizontale* and the *Septum obliquum* is the *Saccus thoracicus cranialis* (orange outline). Right liver lobe (Rl), left liver lobe (Ll), descending duodenum (Dd), pancreas (P) and ascending duodenum (Ad) situated within the *Cavitas peritonealis intestinalis* (Ci), transverse abdominal muscle (Ta) and *Facies annularis* (Fa) of the ventriculus (V).

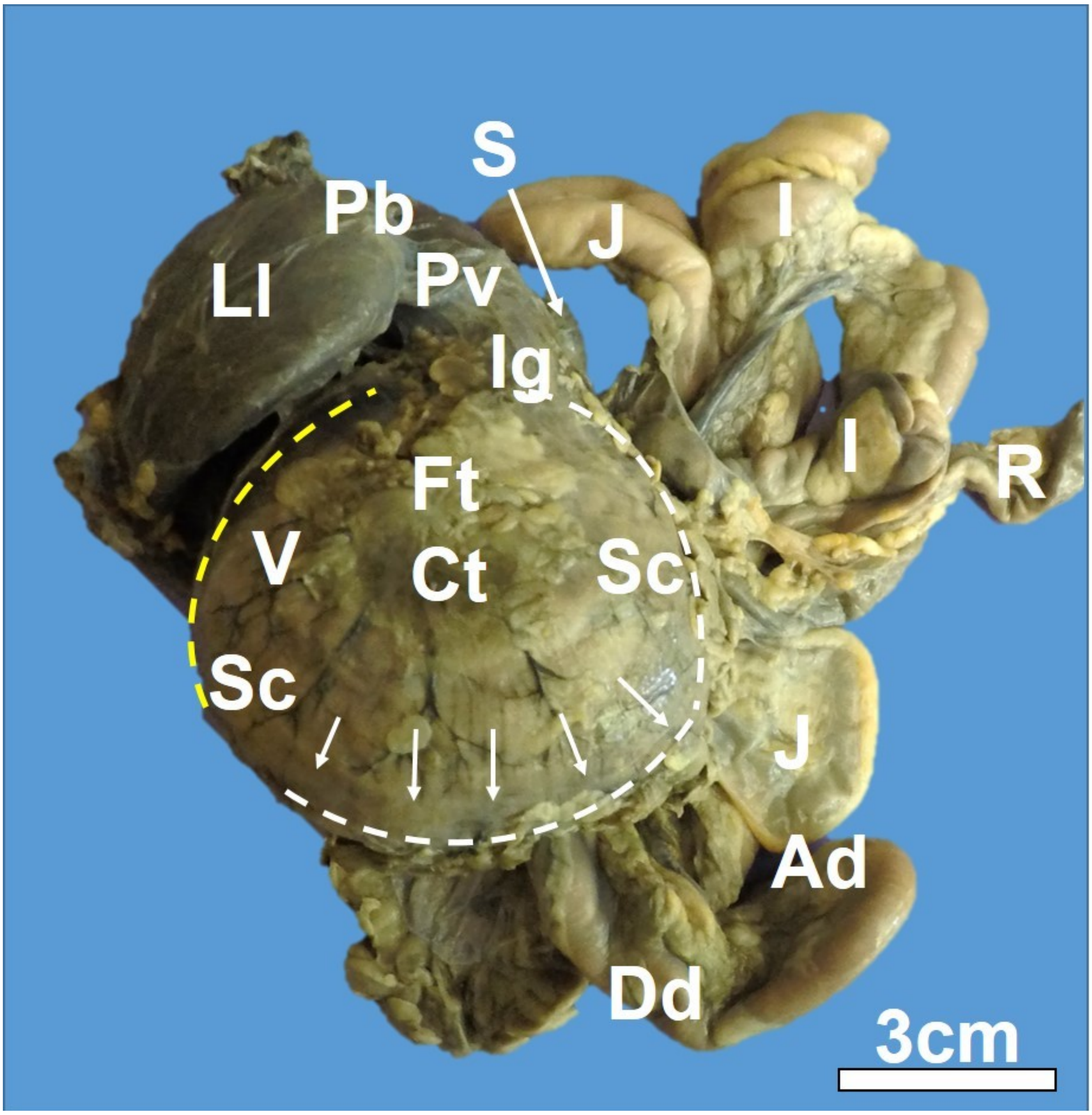

Fig. 2.4: Left caudo-lateral view of the liver and GIT. The GIT has been removed from the coelomic cavity. The Left liver lobe (Ll) is seen surrounding the proventriculus (Pv), and is connected dorsally over the proventriculus by a parenchymal bridge (Pb) to the right liver lobe (not seen). No compartmentalization is evident on the left *Facies tendinea* (Ft) of the ventriculus (V). However, the muscle fibres, *Stratum circulare* (Sc) are seen directing outwards from the *Centrum tendineum* (covered here by fat) (Ct) in a radial manner (white arrows) forming the *Curvatura major* (white dotted line)*. Isthmus gastricis* (Ig), lesser curvature (yellow dotted line), spleen (S), ascending duodenum (Ad), descending duodenum (Dd), jejunum (J), ileum (I), rectum (R).

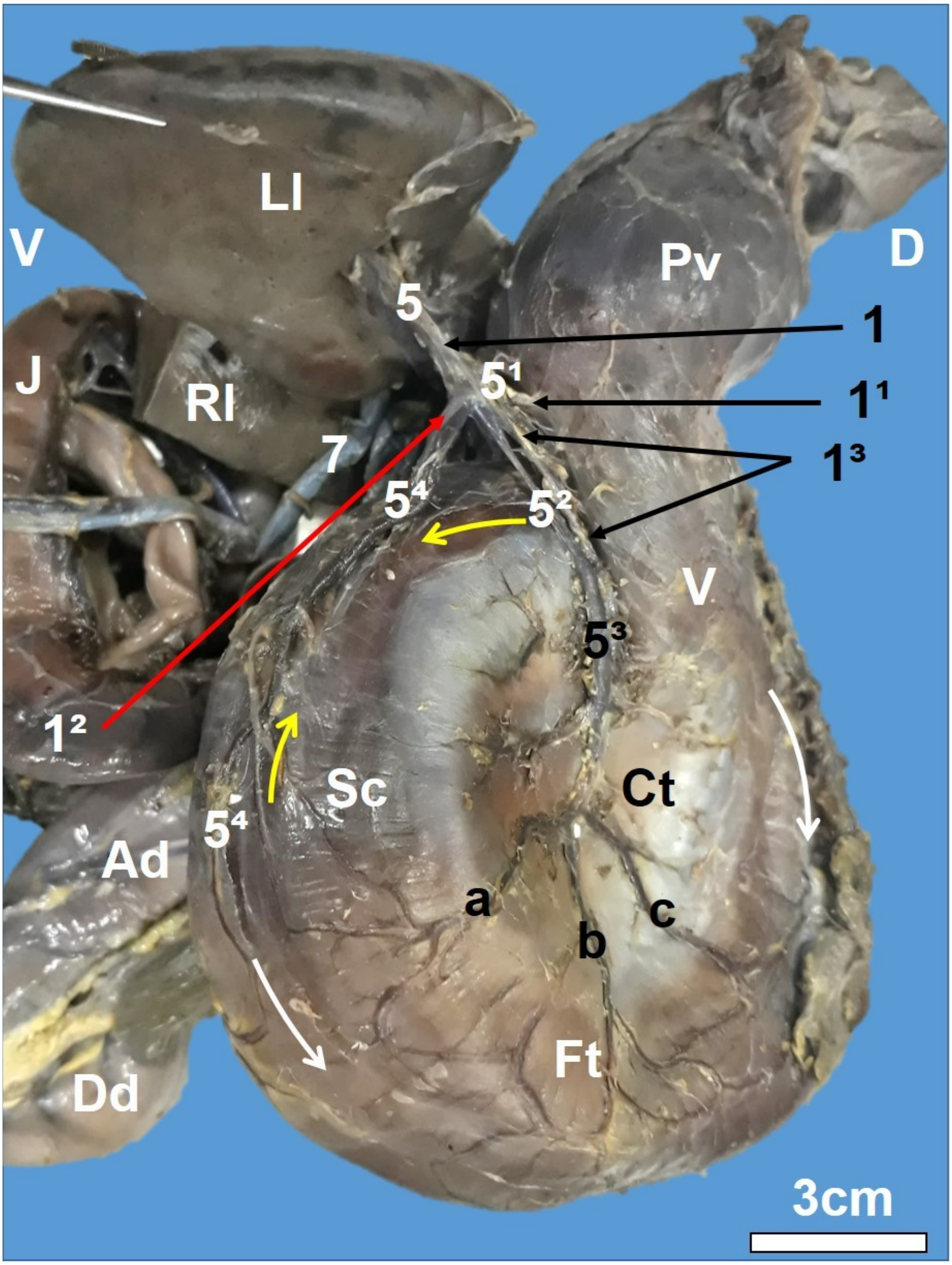

Fig. 2.5: Left caudo-lateral view of the stomach with the left liver lobe (Ll) reflected.

Fig. 2.5: Left caudo-lateral view of the stomach with the left liver lobe (Ll) reflected. The *V. portae sinistrae hepatis* (5) is seen emerging from the hilus of the left liver lobe, where the *Ramus sinister a. celiacae* enters (1), receiving the *Vv. proventricularis ventralis* (5^{1}), *V. proventricularis sinistra* (5^{2})*, V. gastrica muscularis sinistra* (5^{3}) and *V. gastrica muscularis ventralis* (5^{4}). The *Ramus sinister a. celiacae* branch to *A. proventriculares ventralis* (1^{1}), *A. gastrica ventralis* (1^{2}) and *A. gastrica sinistra* (1^{3}). The former courses to the *Centrum tendineum* (Ct) of the left *Facies tedinea* (Ft) of the ventriculus (V) and radiates to drain the *Stratum circulare* (Sc). The *V. gastrica muscularis sinistra* (5^{3}) is a direct continuation of *V. proventricularis sinistra* (5^{2}) and courses towards the *Centrum tendineum* (Ct) where the ventral (a), intermediate (b) and dorsal tributaries (c) meet and drain into the *V. gastrica muscularis ventralis* (5^{4}) runs on the ventral midline from the minor curvature (yellow arrows) towards the major curvature (white arrrows). Right liver lobe (RL), descending duodenum (Dd), ascending duodenum (Ad), jejunum (J) and *V. portalis hepatica dextra* (7).

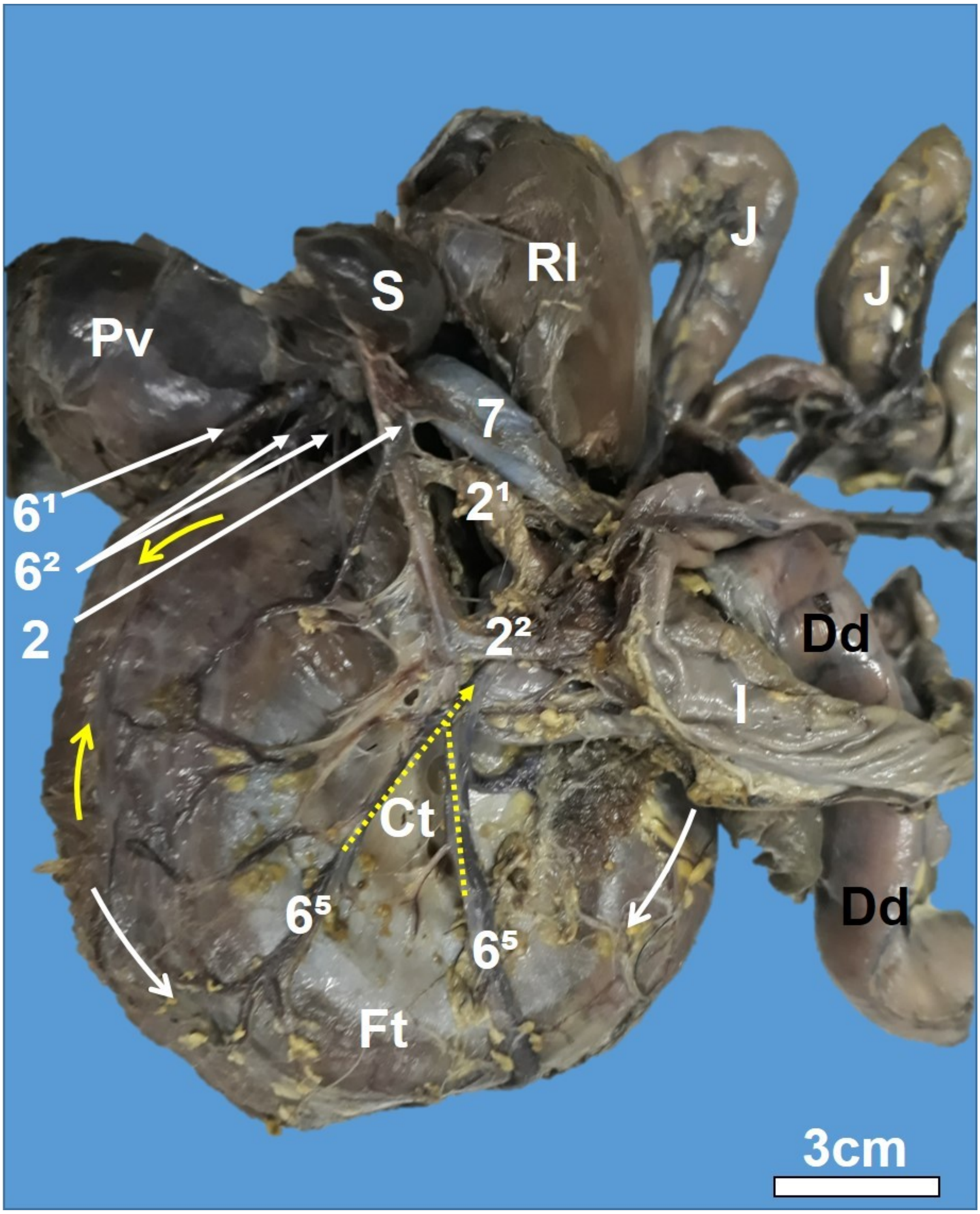

Fig. 2.6: Right caudo-lateral view of the stomach with the right liver lobe (Rl) reflected dorsally.

Fig. 2.6: Right caudo-lateral view of the stomach with the right liver lobe (Rl) reflected dorsally. The *Ramus dexter a. celiacae* (2) is seen emerging from the visceral surface of the spleen. The *A. hepatica dextra* (1^2) is the first branch and supplies the duodenum, jejunum and right liver lobe. *Aa. ileocalis* (2^2) is perpendicular to *Ramus dexter a. celiacae* (2) and supplies the *Ansa ileocecalis. V. gastrica muscularis dextra* (6^5) runs across from the *Facies tendinea* (Ft), towards the *Centrum tendineum* (Ct), draining the right lateral surface of the ventriculus. *V. proventriculosplenica* (6^1) is the first tributary of the *Ramus dexter a. celiacae* and drains part of the spleen and right side of the proventriculus. The *Vv. splenicae* (6^2) are short and drain the spleen. The right liver lobe (Rl), descending duodenum (Dd), jejunum (J), ileum (I), portal vein (V). *Vv. splenicae* (Vs) and *V. portalis hepatica dextra* (7).

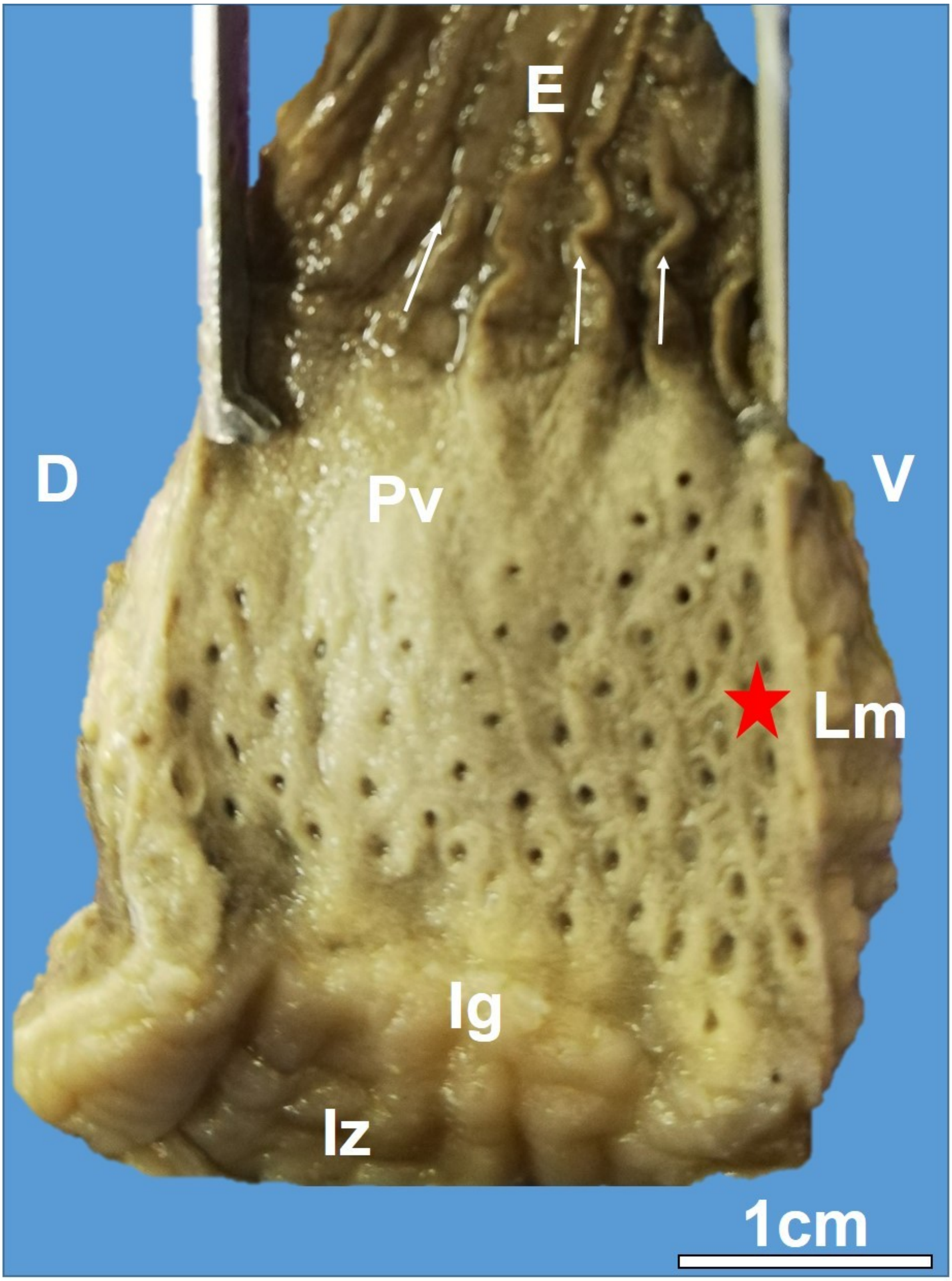

Fig. 2.7: Internal view of the proventriculus, right median section.

Fig. 2.7: Internal view of the proventriculus, right median section. Several gland orifices (small openings) are easily visible representing the surface openings of the underlying *Gll. proventriculares profundae*. Glands in the ventral aspect are more concentrated (red star) and the *Lamina muscularis mucosa* (Lm) in the ventral aspect (V) in this area is also thicker than that of the dorsal aspect (D). Esophagus (E) with longitudinal folds (white arrows), *Isthmus gastris* (Ig), intermediate zone (Iz).

Fig. 2.8: Median section of the stomach. Proventriculus (Pv) wall is slightly thicker on the ventral aspect (V) than that of the dorsal aspect (D) (yellow double arrows). Low longitudinal folds are marked in the proventriculus (Pv). The *Gll. proventriculares profundae* can be seen macroscopically (black outline). The intermediate zone (yellow oval) forms a sac-like structure prior to the narrowing of the *Isthmus gastris* (Ig). Several folds present in the empty stomach (white arrows), running from the pyloric opening circumferentially around the *Centrum tendineum* (Ct). Dorsal ventricular wall (Dw) is slightly thicker than that of the ventral wall. The pyloric opening (*Ostium ventriculopyloricum*) (red curved line) marks the transition from the ventriculus (V) to the descending duodenum (Dd). The pyloric sphinter is composed of a ventral lip (Vl), below the *Incisura angularis* (Ia) and a dorsal lip (Dl) ending at the junction with the *Centrum tendineum* (Ct). Esophagus (E), ascending duodenum (Ad).

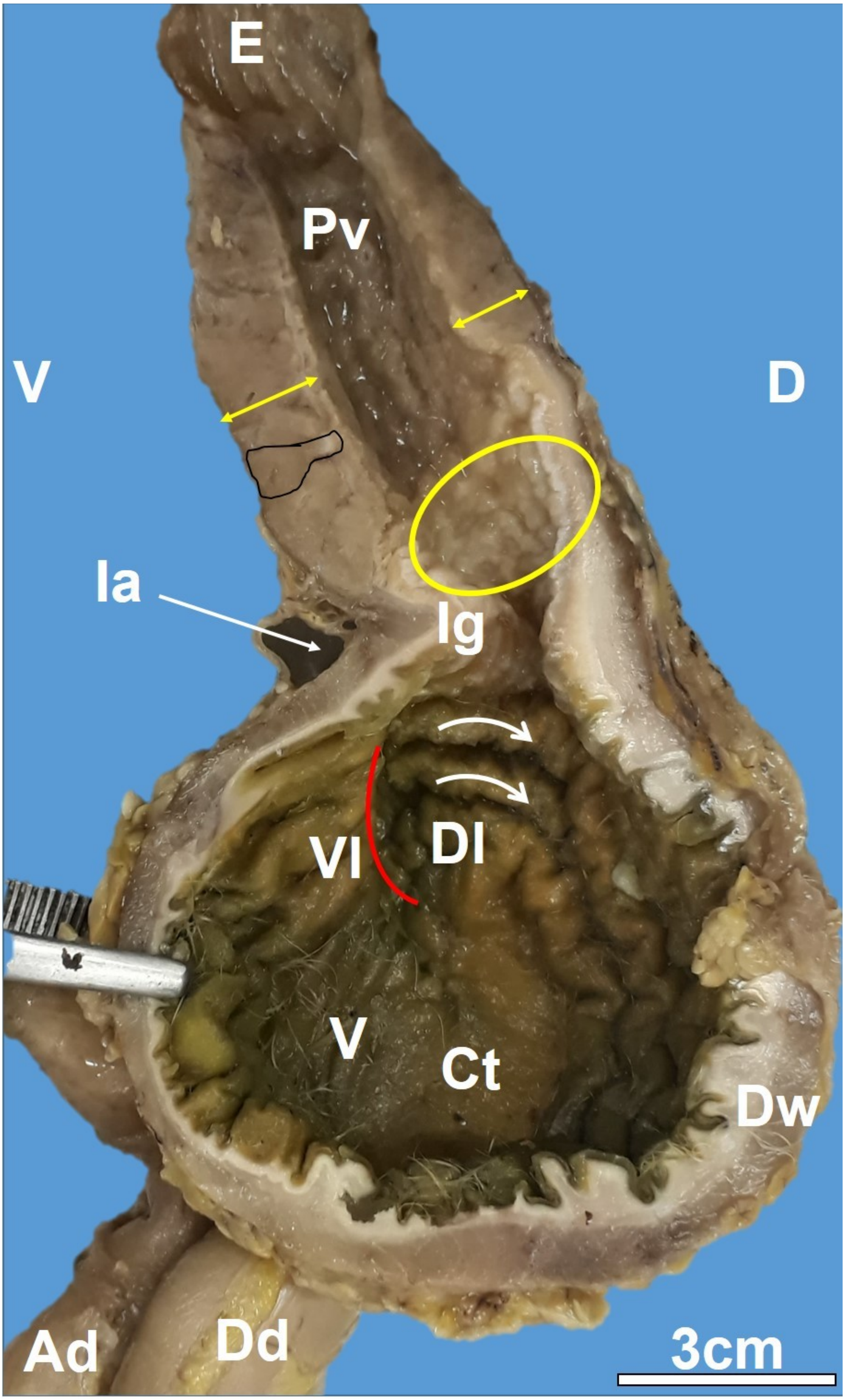

Fig. 2.8: Median section of the stomach

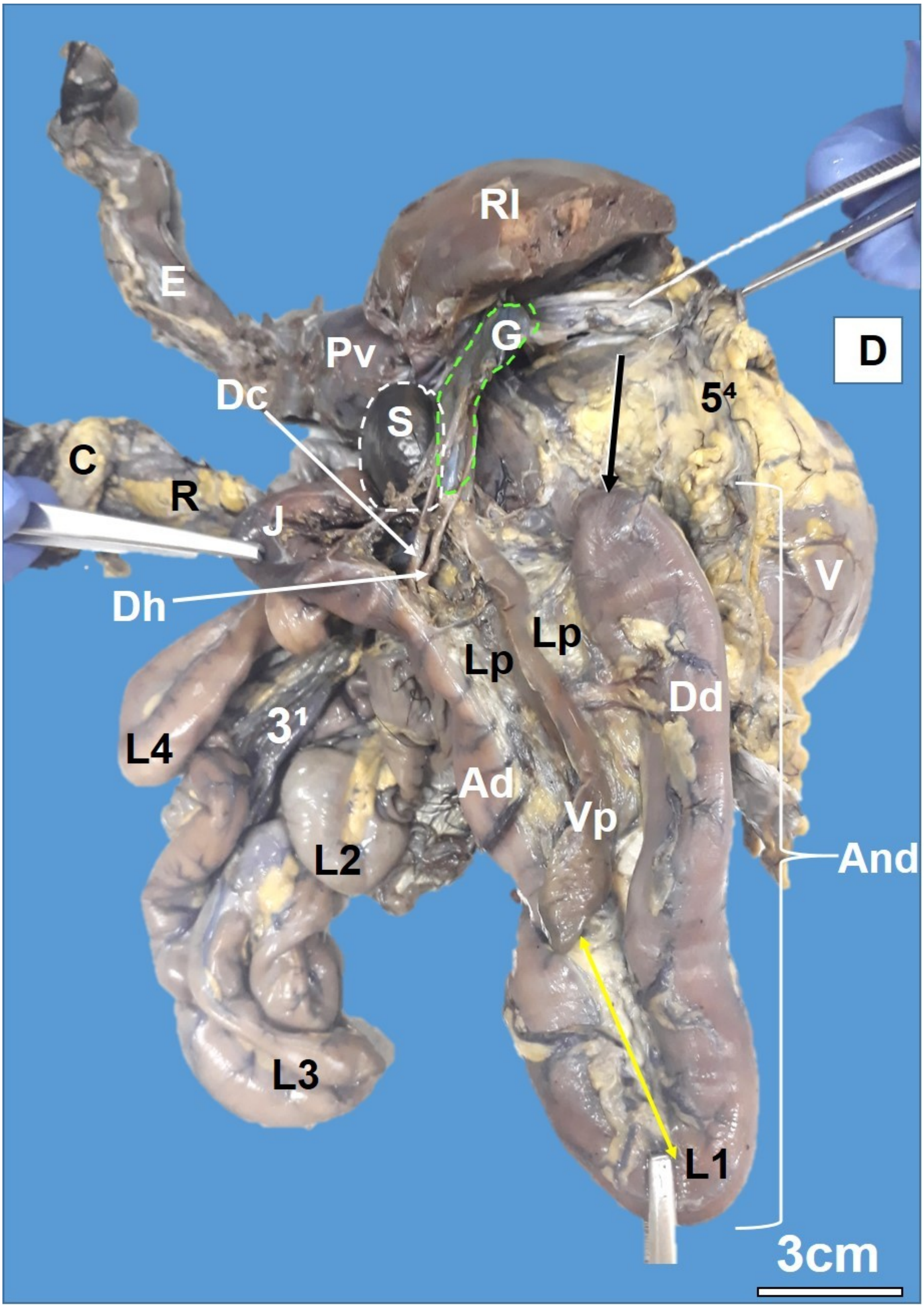

Fig. 2.9: Right caudo-dorsal view of the excised GIT.

Fig. 2.9: Right caudo-dorsal view of the excised GIT. The descending duodenum (Dd) exits the right dorsal region (black arrow) of the ventriculus (V). Ascending duodenum (Ad) forms the other arm of the U-shaped first intestinal loop (L1) of the *Ansa duodenalis* (And). The *Lobus pancreaticus ventralis* (Vp) is situated between the descending and ascending duodenum within the *Lig. pancreaticoduodenuale* (Lp) and does not reach the base of the loop (yellow double headed arrow). The *Ductus cysticoenthericus* (Dc) and *Ductus hepatoentericus communis* (Dh) mark the transition between the duodenum and the jejunum (L2), *Vv. jejunales* (3^1). Esophagus (E), proventriculus (Pv), right liver lobe (Rl), *A. gastrica muscularis ventralis* (5^4), gall bladder (G, green dotted outline), spleen (S, white dotted outline), *Ansae axialis* (L3), ileum (L4), rectum (R) and cloaca (C).

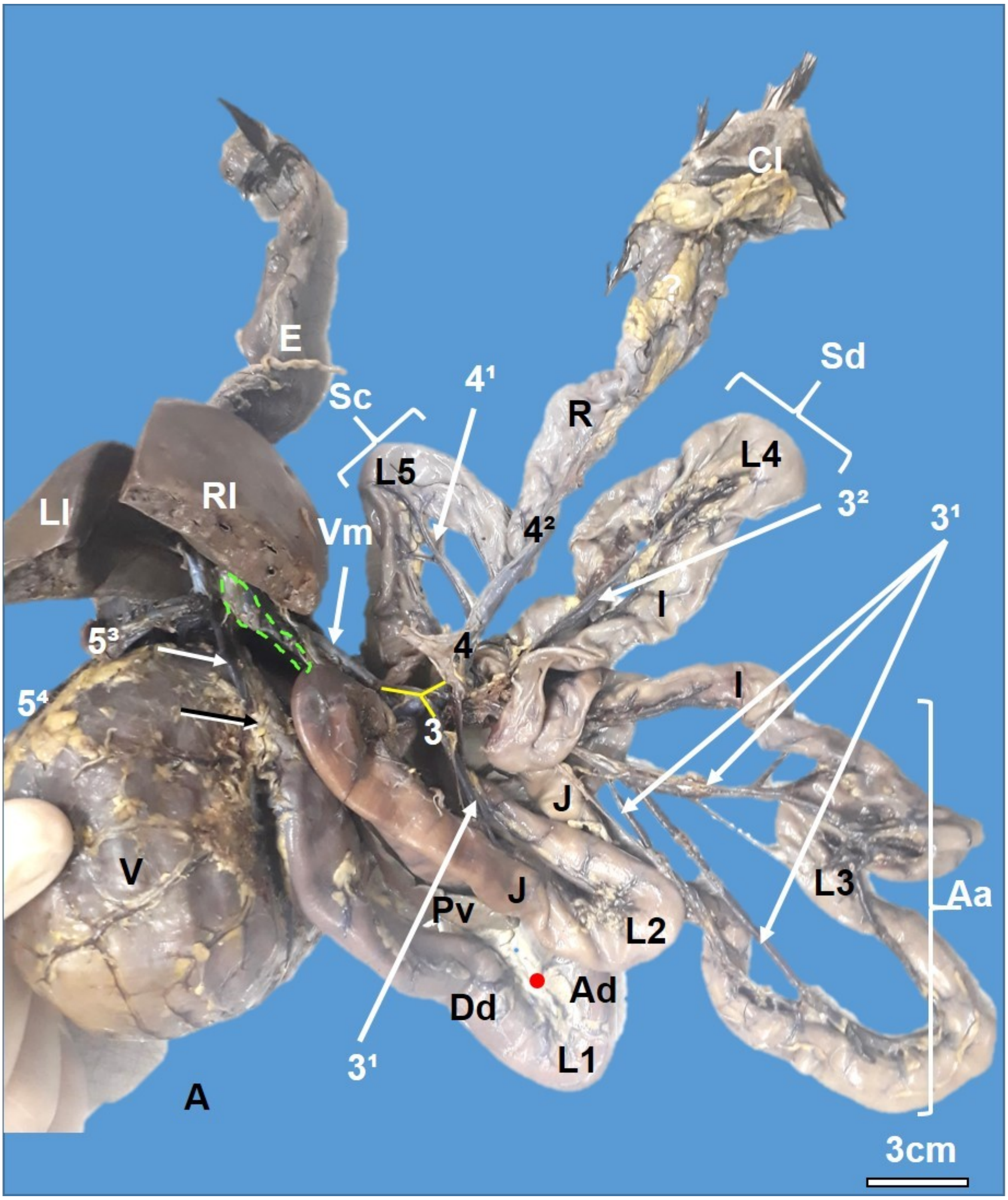

Fig. 2.10: Caudo-ventral view of the excised GIT with the intestinal loops folded open and laid to the right.

Fig. 2.10: Caudo-ventral view of the excised GIT with the intestinal loops folded open and laid to the right. The small intestine forms five intestinal loops. The *Ansa duodenalis* (L1), *Ansa jejunales* (L2) drained by *Vv. jejunales* (3^1), the *Ansa axialis* (Aa) (L3) and *Ansa ilealis /* supraduodenal loop (Sd) (L4) drained by *Vv. ileae* (3^2) and the supracecal loop (Sc) (L5) drained by *V. rectales* (4^1/4^2). The *Ansa axialis* has both a jejunal and ileal component. The greater part of the intestinal drainage unites to form the *V. mesenterica cranialis* (3). The lesser caudal part of the intestine is drained by the *V. mesenterica caudalis* (4). The *V. mesenterica cranialis* and *caudalis* merge to form the *V. mesenterica communis* (Vm) (yellow fork). The *Lobus pancreaticus ventralis* extends to the middle of the *Ansa duodenalis*, with the *Lig. pancreaticoduodenale* (red dot) caudally. Esophagus (E), left (Ll) and right (Rl) liver lobes, ventriculus (V), duodenal origin (black arrow), descending (Dd) and ascending (Ad) duodenum, gallbladder (green dashed outline), jejunum (J), ileum (I), rectum (R), cloaca (Cl), *A. gastrica dextra* (5^3) and *A. gastrica muscularis ventralis* (5^4).

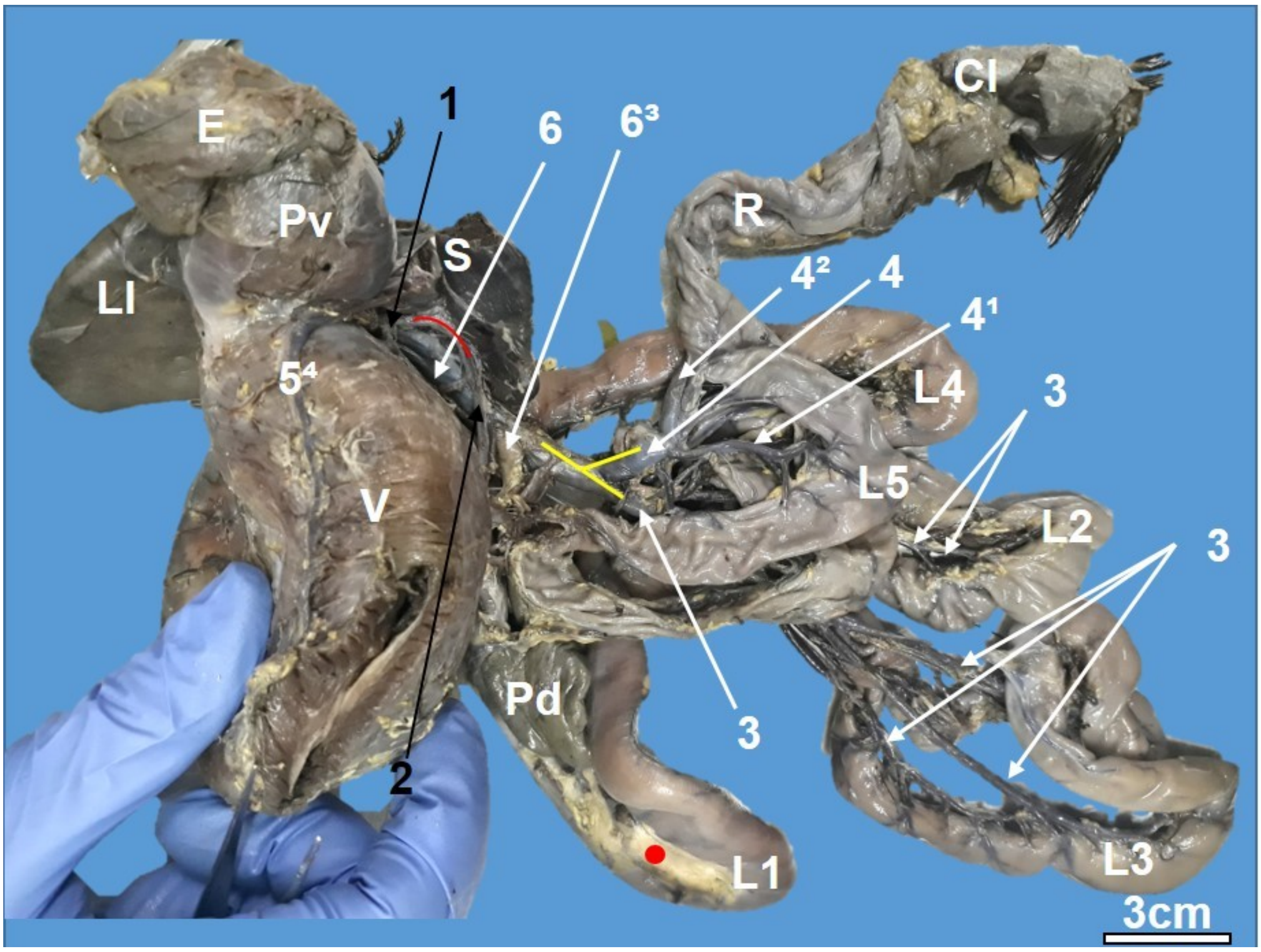

Fig. 2.11: Ventral view of the excised GIT with the intestinal loops folded open. The small intestine forms five intestinal loops. The *Ansa duodenalis* (L1), *Ansae jejunales* (L2) drained by *Vv. jejunales* (3¹), the *Ansa axialis* (L3) and *Ansa ilealis* (L4) that is covered by the supracecal loop (L5) drained by *Vv. ileoceales* (4¹/4²). The greater part of the intestinal drainage unites and are branches of the *V. mesenterica cranialis* (3). The lesser caudal part of the intestine is drained by *V. mesenterica caudalis* (4). The *V. mesenterica cranialis* and *caudalis* merge (yellow fork) to form the *V. mesenterica communis* (Vm). Esophagus (E), left (Ll) liver lobe, spleen (S), ventriculus (V), *Lobus pancreaticus dorsalis* (Pd), *Lig. pancreaticoduodenale* (red dot), rectum (R), cloaca (Cl), *A. gastrica muscularis ventralis* (5⁴), *V. portae dextrae hepatis* (6) and *V. gastropancreaticoduodenalis* (6³).

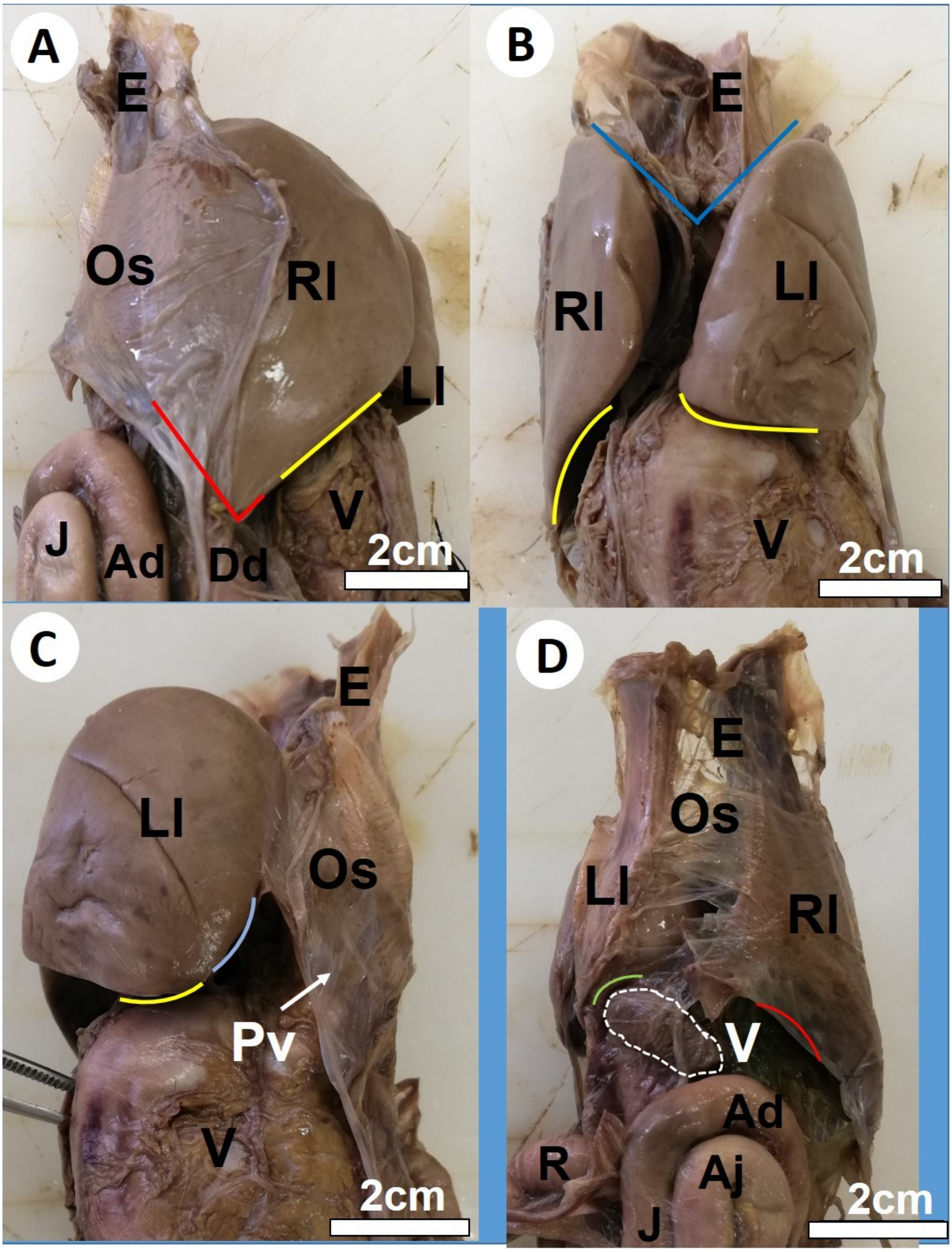

Fig. 2.12: Different views of the liver lobes and their impressions viewed from the *Facies parietalis*.

Fig. 2.12: Different views of the liver lobes and their impressions viewed from the *Facies parietalis*. A). Right lateral view of the liver. The *Septum obliquum* (Os) partially covers the right liver lobe (Rl) over the dorsal *Margo hepaticus*. The ascending duodenum (Ad) makes an impression, the *Impressio duodenalis* (red line) on the dorso-*caudal Margo hepaticus*. The ventriculus (V) makes an impression, the *Impressio ventricularis* (yellow line) on the ventral *Margo hepaticus*. Left liver lobe (Ll), descending duodenum (Dd) and jejunum (J). **B).** Ventral view of the liver. The heart has been removed and the region of contact is the *Impressio cardiaca* (blue lines) made on the cranial *Margo hepaticus* of the left (Ll) and right liver lobes (Rl). The ventriculus (V) makes an impression, *Impressio ventricularis,* on the left and right liver lobes on the caudal *Margo hepaticus* (yellow curves). Eesophagus (E). **C).** Left lateral view of the left liver lobe (Ll). The proventriculus (Pv) makes an impression, the *Impressio proventricularis* (light blue curve) on the dorsal *Margo hepaticus*. The ventriculus (V) makes an impression, *Impressio ventricularis* (yellow curve) on the caudal *Margo hepaticus.* Esophagus (E) and oblique septum (Os). **D).** Dorsal view of the liver and digestive tract. The spleen (white dotted outline) forms the *Impressio splenalis* (green curve) on the dorsal *Margo hepaticus* of the left liver lobe (Ll). The ventriculus (V) forms the *Impressio ventricularis* on the dorsocaudal boarder of the right liver lobe (Rl). The ascending duodenal loop (Ad) forms the *Impressio duodenalis* (red curve) against the dorso-caudal border of the right liver lobe. Esophagus (E), *Ansa jejunales* (Aj), jejunum (J) and rectum (R).

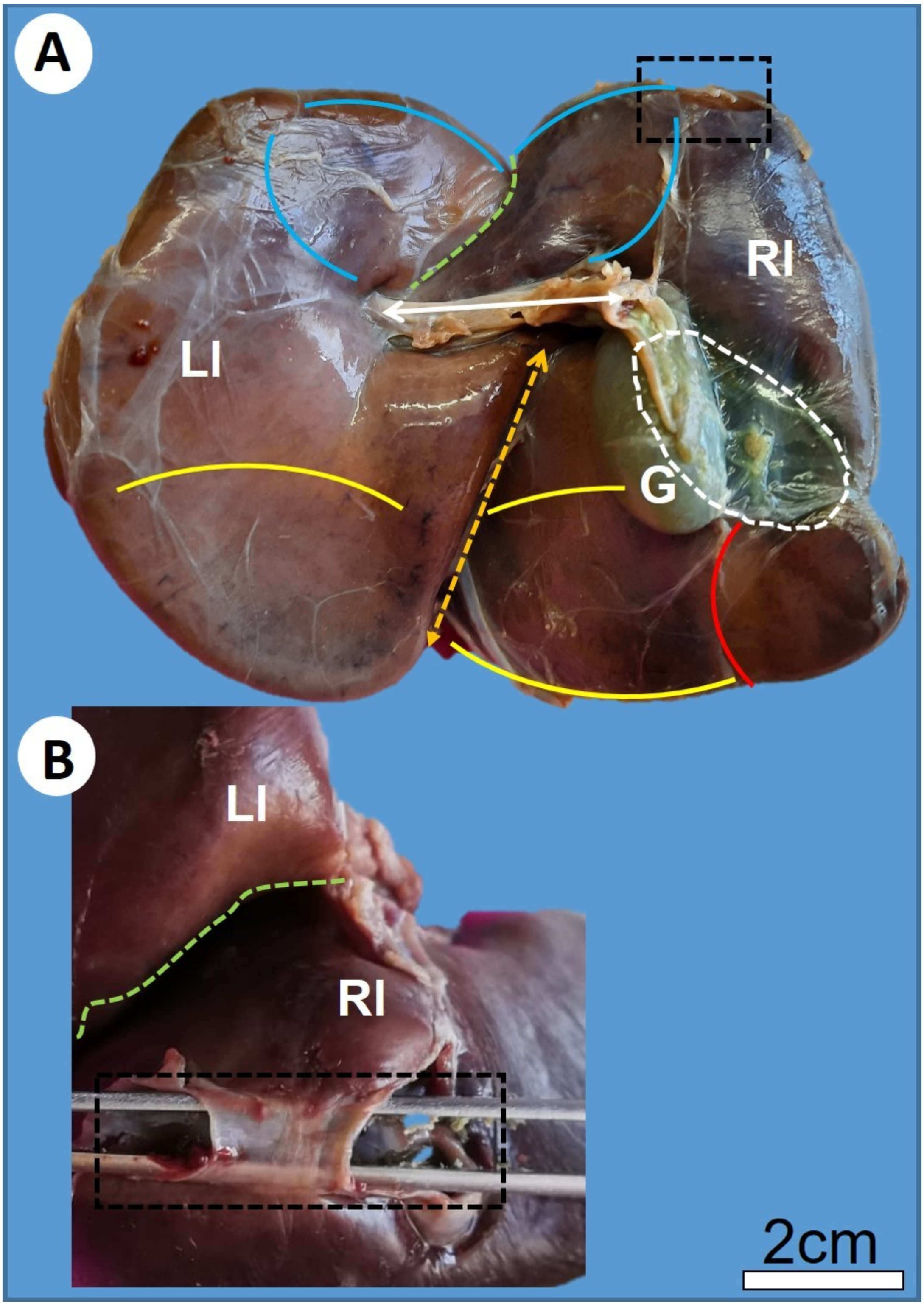

Fig. 2.13: Impressions on the *Facies visceralis* of the liver.

Fig. 2.13: Impressions on the *Facies visceralis* of the liver. A). The deep *Incisura interlobaris caudalis* (orange double-headed arrow) ends at the caudal part of the *Pars lobularis* (white double-headed arrow). The *Incisura interlobaris cranialis* (green dotted line) ends at the cranial part of the *Pars lobularis*. The *V. cava caudalis* runs through the *Sulcus vena cava caudalis* (black square) on the cranial *Margo hepaticus* of the right liver lobe (Rl). The ventriculus and ascending duodenum form the*, Impressio ventricularis* (region between the yellow curves) and *Impressio duodenalis* (red curve), respectively. The *Impressio proventricularis* lies cranially (region between the blue lines). The gallbladder (G) is situated in the *Fossa vesicae felleae* (white dotted outline). **B).** Enlargement of the black square in **A.** The *V. cava caudalis* (forceps run through it) forms a caval groove on the cranial *Margo hepaticus*. *Incisura interlobaris cranialis* (green dotted line).

Fig. 2.14: Accessory organs and the impressions on the *Facies parietalis*. The *Pars lobularis* (Pl) connects the left (Ll) and right liver lobes (Rl). The *Impressio duodenalis* (Id, region between the red curve and the line) is seen on the visceral surface of the right liver lobe and the ventriculus (V), *Impressio ventricularis* (Iv, region under the yellow lines) on the visceral surface of the left and right liver lobes. The gallbladder (Gb) is situated in the *Fossa vesicae felleae* (black outline) of the right lobe. The *Ductus cysticoentericus* (black dotted line) connects the gallbladder to the ascending duodenum (Ad). The *Ductus hepatoentericus communis* (white dotted line) enters the ascending duodenum from the *Pars lobularis*. The ventral (Lv) and splenic lobe (Sl) of the pancreas is situated between the duodenal loops. *V. gastropancreaticoduodenalis* (6^3).

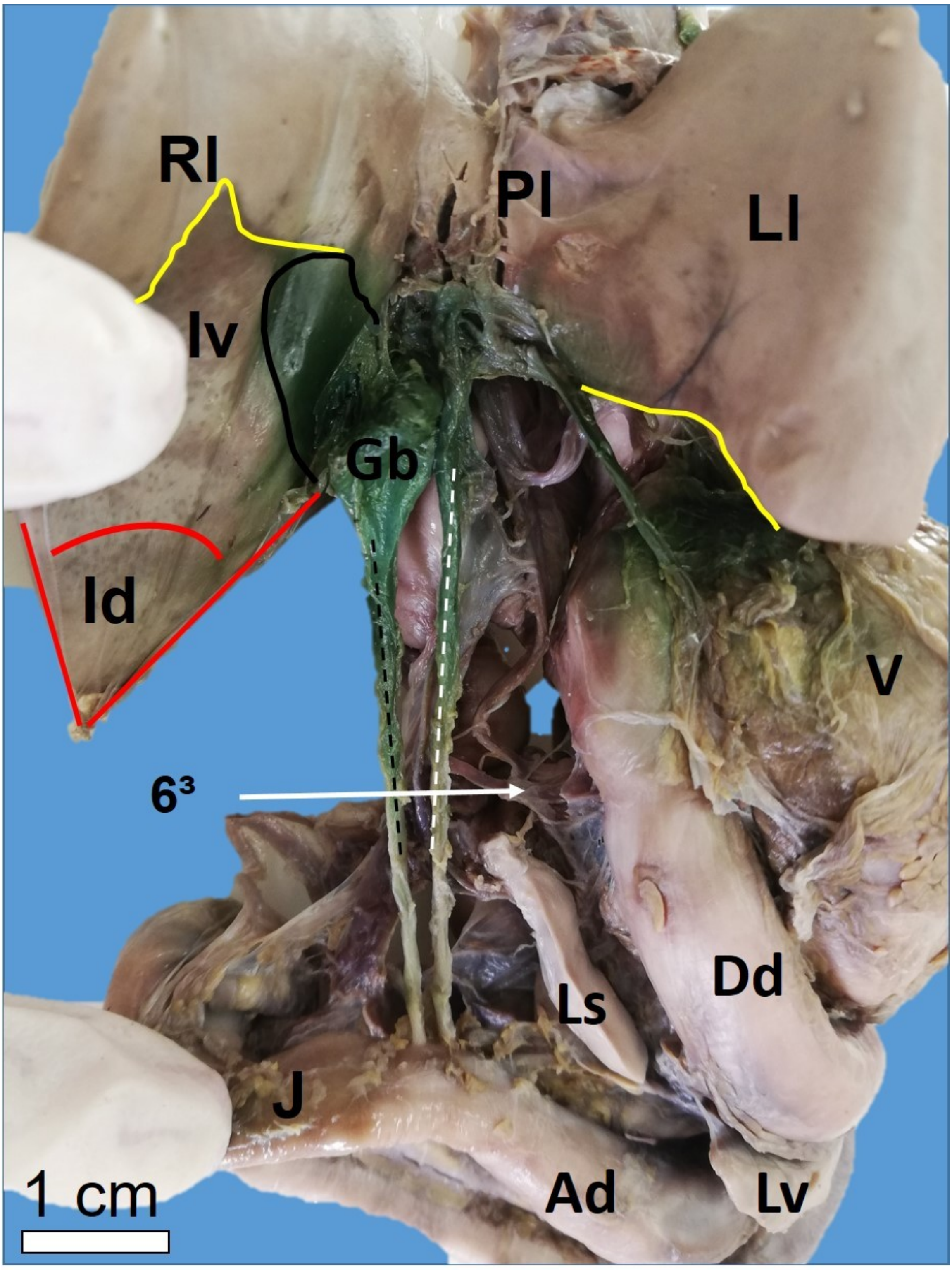

Fig. 2.14: Accessory organs and the impressions on the *Facies parietalis*.

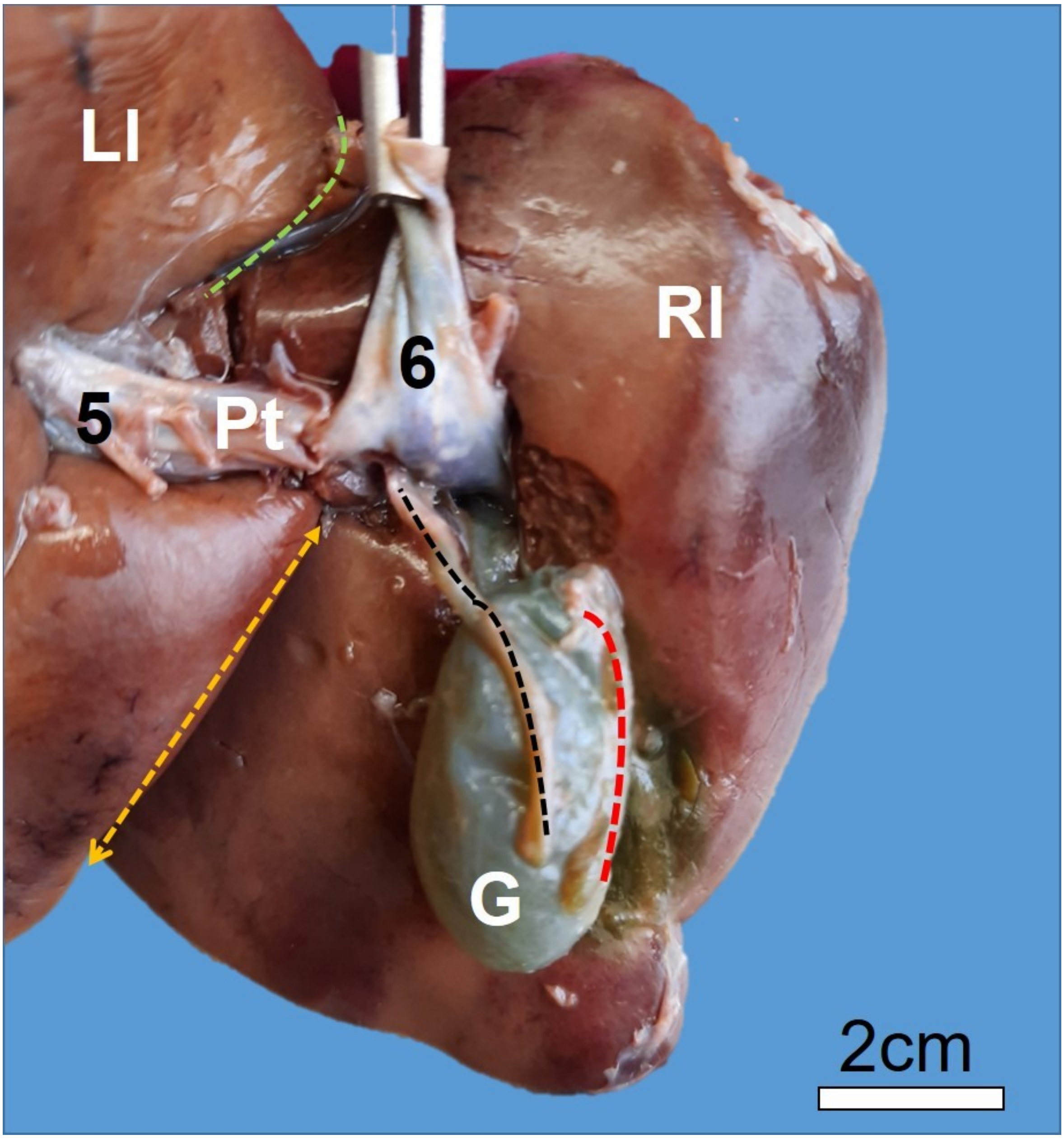

Fig. 2.15: *Pars transversa* and ducts of the gall bladder. The *Pars transversa* (Pt) lies on the *Facies visceralis,* horizontally across the left (LI) and right liver lobe (RI). The *V. portae dextrae hepatis* (Vpd) enters the right liver lobe (RI), with its left branch, *V. portae dextrae hepatis sinister* (Vps). The *Ductus hepatoentericus communis* (red dotted line) is seen exiting underneath the *V. portae dextrae hepatis* and the *Ductus cysticoentericus* (black dotted line) originates from the gallbladder (G). *Incisura interlobaris caudalis* (orange dotted double-headed arrow) and *Incisura interlobaris cranialis* (green dotted line).

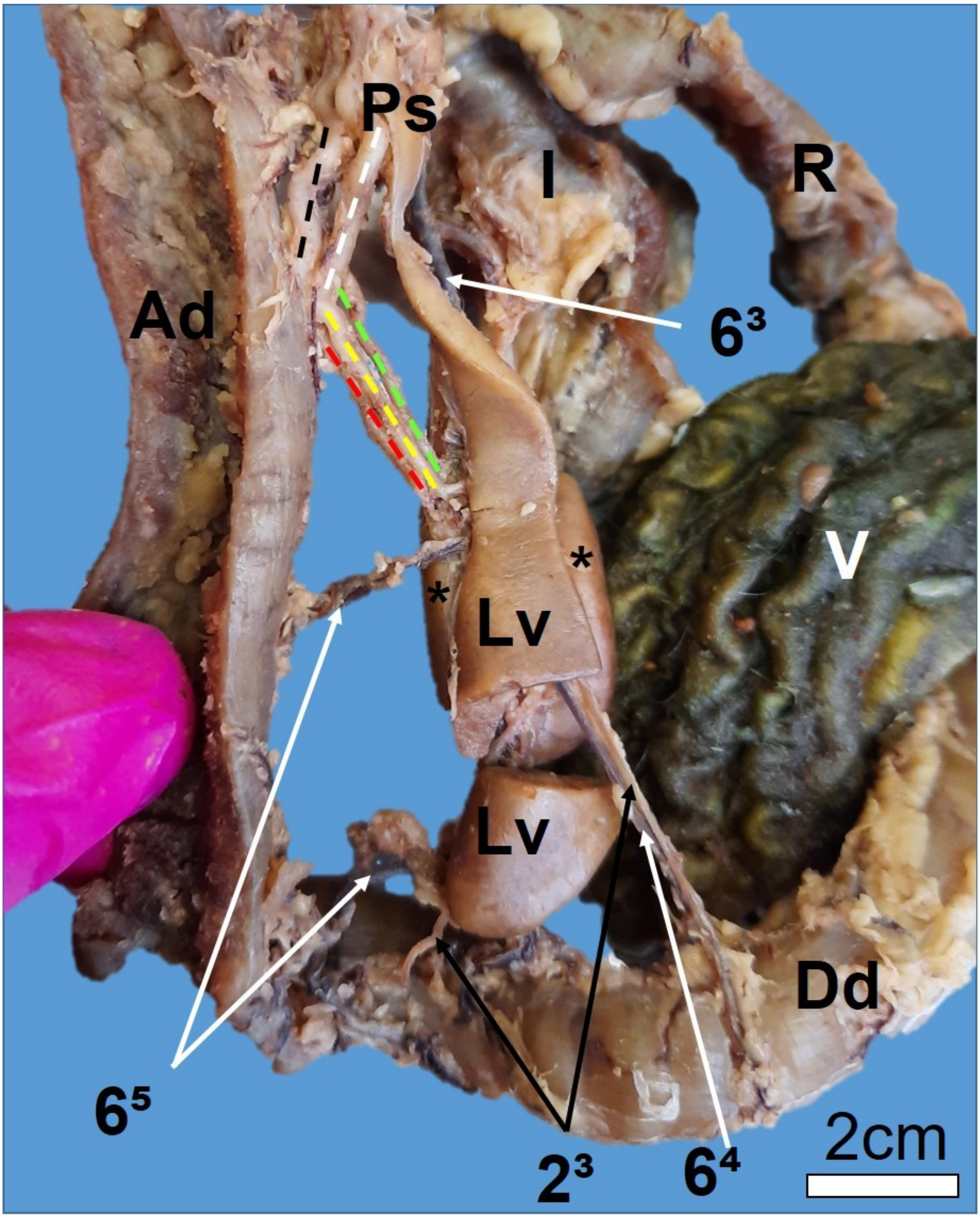

Fig. 2.16: Ventral view of the *Ansa duodenalis* and pancreas.

Fig. 2.16: Ventral view of the *Ansa duodenalis* and pancreas. The pancreatic ducts *Ductus pancreaticus ventralis* (yellow dotted line), *Ductus pancreaticus dorsalis* (red dotted line) and *Ductus pancreaticus accessorius* (green dotted line), enter the ascending duodenum (Ad) at the level of the *Ductus cysticoentericus* (black dotted line) and *Ductus hepatoentericus communis* (white dotted line). The pancreatic ducts exit between the *Lobus pancreatic dorsalis* (*) and *Lobus pancreaticus ventralis* (Lv). The *Lobus pancreaticus splenalis* (Ps) is cranial to the ventral lobe. *V. gastropancreaticoduodenalis* (6^3) drains the entire pancreas. *V. pancreaticoduodenalis* (6^4) drains to the latter. Smaller veins (*Vv. pancreaticae*) (6^5) drain and arteries (*Aa. duodenalis*) (2^3) supply the duodenum. Descending duodenum (Dd), *Vv. jejunales* (3^1), ileum (I), ventriculs (V) and rectum (R).

Fig. 2.17: Dorsal view of the *Ansa duodenalis* and pancreas. The pancreatic ducts *Ductus pancreaticus ventralis* (yellow dotted line), *Ductus pancreaticus dorsalis* (red dotted line) and *Ductus pancreaticus accessorius* (green dotted line), enter the ascending duodenum (Ad) at the level of the *Ductus cysticoentericus* (black dotted line) and *Ductus hepatoentericus communis* (white dotted line). The *Lobus pancreaticus dorsalis* (Ld) is the only lobe visible in on the dorsal view. The *V. jejunalis* (Vj) drains the jejunum (J). *V. gastropancreaticoduodenalis* (6^3), *V. pancreaticoduodenalis* (6^4), *Aa. duodenalis* (2^3), *Vv. pancreaticae* (6^5), *Vv. jejunales* (3^1), ileum (I), ventriculs (V) and rectum (R).

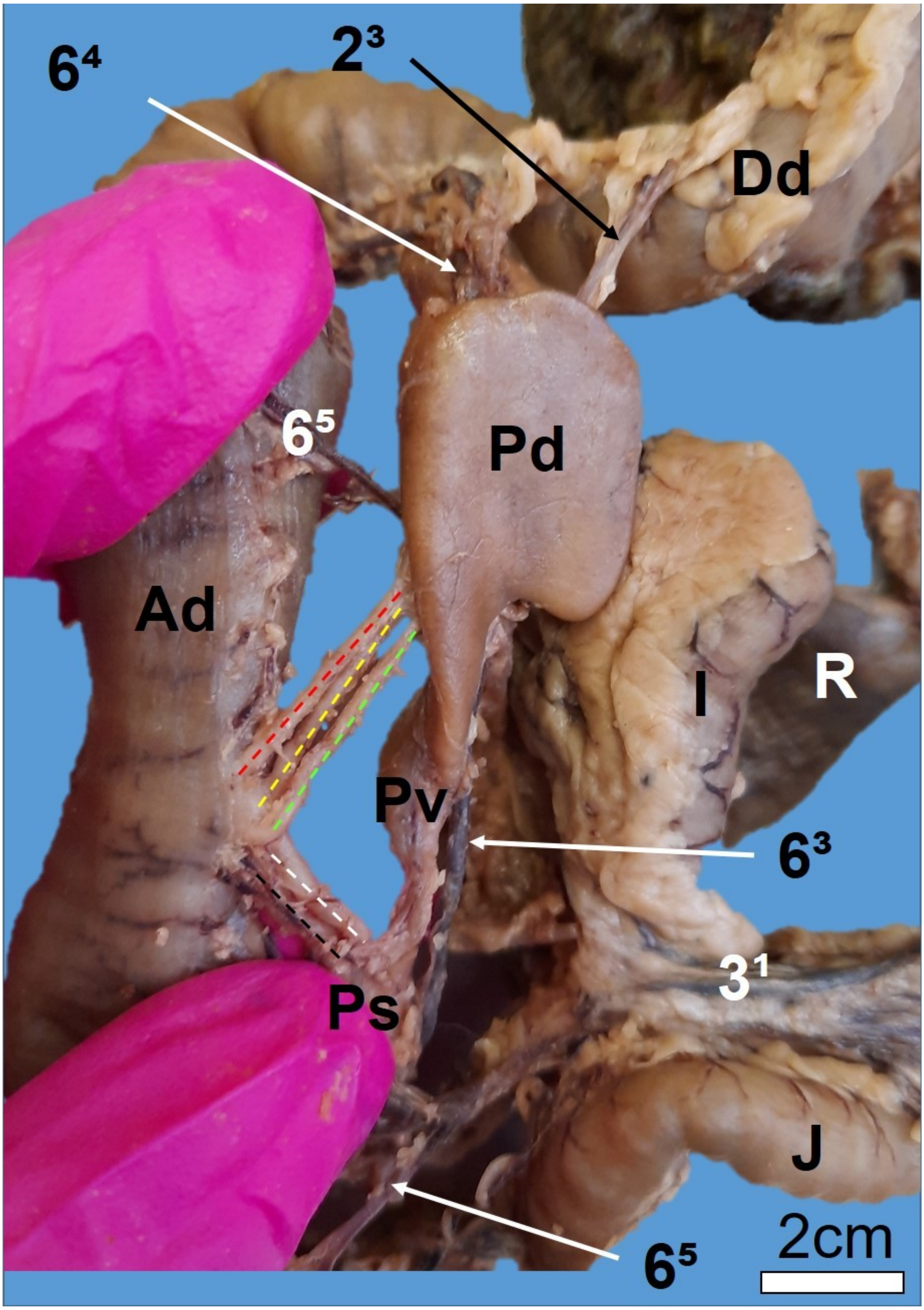

Fig. 2.17: Dorsal view of the *Ansa duodenalis* and pancreas.

CHAPTER 3

HISTOLOGY OF THE GASTRO-INTESTINAL TRACT OF THE SOUTHERN GROUND-HORNBILL

3.1 INTRODUCTION

As a result of it’s economic importance, the histology of the gastro-intestinal tract (GIT) of the domestic chicken (*Gallus gallus domesticus*), serves as the standard reference for avian species (Hodges, 1974; Nickel, Schummer and Seiferle, 1977; Akester, 1986; Baumel, 1993; Tsukahara and Ushida, 2000; Takamitsu, Tsukahara and Ushida, 2000; Ventura *et al.*, 2013; Kohl *et al.*, 2017). The histology of the GIT of some avian species has been studied extensively (Toner, 1964; Houston and Cooper, 1975; Bailey *et al.*, 1997; Al-Aaraji, 2015; North, Movassaghi and Smits, 2016; Sayrafi and Aghagolzadeh, 2020), however, the normal histological features of the Southern Ground-Hornbill (*Bucorvus Leadbeateri*) (SGH) are not known.

The GIT of all avian species is composed of up to six layers, namely, from the lumen outwards, the *Mucosa*; *Lamina epithelialis, Lamina propria* and *Lamina muscularis mucosae*, the *Submucosa*, *Tunica muscularis* and *Serosa* (Hodges, 1974). A brief overview of the parts of the GIT are given below.

The mucosal surface of the proventriculus of the chicken bore several papillae (Rossi *et al.*, 2005) and the surface epithelium consisted of simple columnar cells. The placement of the proventricular glands (*GII*. *proventriculares*), according to some researchers, was in the submucosa (Malewitz and Calhoun, 1958; Bradley and Grahame, 1960) or within the *Lamina propria* (Thomson, 1969). The simple tubular glands in the domestic pigeon (*Columba livia domestica*) and that of the domestic mallard duck (*Anas platyrhhynchos*) were situated in the *Lamina propria* (Hassan and Moussa, 2012). The proventricular glands contributed to the greater part of the thickness of the proventricular wall in the fowl (Hodges, 1974). The submucosal layer mainly consisted of connective tissue and was so thin on some areas that it was almost non-existent (Hodges, 1974). The *Tunica muscularis* of the fowl, domestic pigeon and mallard consisted of a thick inner circular layer and a much thinner outer longitudinal layer of smooth muscle (Hodges, 1974; Akester, 1986; Hassan and Moussa, 2012; Al-Saffar and Eyhab, 2016). The secretions produced by the proventricular glands in birds are important for maintaining the health of the digestive tract and for the digestion of food.

The ventriculus of the fowl contained the layers mentioned above but lacked the *Lamina muscularis mucosae* (Kadhim *et al.*, 2011), however, in species such as the carnivorous Eurasian Hobby (*Falco subbuteo*) this layer was present (Abumandour, 2014). The ventricular glands were tubular, branched, grouped together and separated by septae of *Lamina propria*. Only one type of cell, in different stages of development, was present throughout the pits and glands of the ventriculus of the fowl (Chodnik, 1947).The luminal surface of chicken muscular stomach was lined by a proteinaceous substance similar to keratin and was produced by the ventricular glands (Rossi *et al.*, 2005). The glands produced the material of the hardened membrane of the ventriculus, namely koilin (Toner, 1964).

The intestine of the fowl possessed essentially the same structure throughout the whole of its length, with subdivisions based on different sizes and functions (Hodges, 1974). The jejunum and ileum displayed a slight decreased depth of the mucous membrane, whilst the villi became shorter and broader (Hodges, 1974). The rectum was a thick muscular wall and the villi were long, flat, leaf-shaped structures that filled a large portion of the lumen (Malewitz and Calhoun, 1958).

Southern Ground-Hornbills are carnivorous, consuming mainly arthropods such as snails, frogs and toads and some larger prey items such as lizards, rats, hares, squirrels and tortoises. They occasionally feed on carrion, making them susceptible to lead toxicity due to lead remains from bullets in carcasses (Koeppel and Kemp, 2015). They will also feed on discarded offal left in the veld after a hunt. They are often accidently poisoned by bait intended for pest species such as caracal (*Caracal caracal*) or jackal (*Canis aureus*) (Koeppel and Kemp, 2015). These birds have been studied mainly with a view to species conservation by focussing on habitat and breeding behaviours (Msimanga, 2004; Wilson, Hockey and Marsden, 2013; Carstens *et al.*, 2019). They are extremely sensitive to lead intoxication. However, it is not known how their gut morphology contributes to their sensitivity to lead poisoning and a study of the histology of the GIT is warranted. The aim of this chapter is to provide a histological description of the GIT of the SGH to assist in understanding how the morphology may affect susceptibility to certain factors and conditions.

3.2 MATERIALS AND METHODS

Four of the samples described in Chapter 2.2 were used for this study. The samples were collected from the various segments of the gastrointestinal tract and processed for histology. Samples collected included the junction between the oesophagus and proventriculus, proventriculus, junction between the proventriculus and gizzard, gizzard, duodenum, ileum/jejunum and colon (Figs. 3.1, 3.17). Due to the varying causes of death and the sometimes prolonged period between death and post-mortem, not all of the SGH's were appropriate for histology. Where some tissues were not well preserved, the samples were used to evaluate the various layers.

The samples were dehydrated with 70%, thereafter 80%, 96% and then 2X 100% ethanol. The samples were then further processed through 50:50 ethanol: xylol, 2X xylol and 2X paraffin wax (60-120 minutes per step) using a Shandon model 2LE Automatic Tissue Processor (Shandon, Pittsburgh, PA, USA). Tissue samples were then manually serially imbedded (this was ensured by cutting a notch on the side not to be imbedded) into paraffin wax in plastic moulds. Sections were cut at 3-5 µm and stained with Haematoxylin and Eosin (H&E) (Bancroft and Gamble, 2002), Peroidic Periodic acid–Schiff (PAS) (McManus, 1946) and Masson's Trichrome (Bancroft and Gamble, 2008). Samples were mounted on glass slides with a mounting medium (Etellan) and covered with a glass coverslip.

Slides were viewed, and features of interest described and digitally recorded using an Olympus BX63 light microscope (Olympus Corporation, Tokyo, Japan) equipped with a DP72 camera and Olympus cellSens imaging software (Olympus Corporation, Tokyo, Japan) and annotated.

Samples were stained with haematoxylin and eosin (H&E) to describe the general structure, with Periodic acid–Schiff (PAS) to highlight connective tissue and differentiate acidic mucopolysaccharides (glycogen) and neutral mucus secretions (glycoproteins, glycolipids and mucins) along the epithelium or mucosa of the GI tract. Masson’s Trichrome was used to visualise the various tissue types and layers.

3.2.1 Haematoxylin and eosin (H&E)

The samples were dewaxed and rinsed in xylene for 2 minutes. Thereafter, they were rinsed in 100% ethanol for 2 minutes, 95% ethanol for 2 minutes. The samples were washed in water for 2 minutes. The samples were stained with Hematoxylin for 3 minutes, thereafter washing them with water for 1 minute. Differentiator (mild acid) was added for 1 minute, thereafter washing with water for 1 minute. Bluing was applied for 1 minute and washed with water for 1 minute. The samples were rinsed with 95% ethanol for 1 minute and eosin was added for 45 seconds, thereafter rinsing with 95% ethanol for 1 minute and in 100% ethanol for 1 minute. The slides were cleared with xylene for 2 minutes and the coverslip was added.

Table 1: Haematoxylin and eosin tissue various staining

Collagen	Pale pink
Muscle	Deep pink
Acidophilic cytoplasm	Red
Basophilic cytoplasm	Purple
Nuclei	Blue
Erythrocytes	Cherry red

3.2.2 Periodic acid–Schiff (PAS)

The samples were de-waxed and placed in distilled water for rinsing. Sections were brought to distilled water, there after xylene and ethanol. Samples were then digested using a diastase, hyaluronidase, or sialidase procedure. Oxidize in Periodic Acid was applied for 5 minutes and rinsed in distilled water afterwards. The sample was then placed in Coleman's or another Schiff's Reagent for 15 minutes. The samples were washed in running water for 10 minutes to develop the pink colour. Counterstain was then used with one of the following:

1) Harris' hematoxylin for 6 minutes. The samples were washed in running water and transferred to 1% acid ethanol for 3-10 quick dips. The samples were then washed in distilled water. The sample was then dipped in ammonia water to blue the section. Afterwards the sample was washed in running water for 10 minutes.

2) Light green working solution for 10 seconds. Dehydrated the sample with ethanol, add xylene to clear the slide and mounted a coverslip with Entellan.

Table 2: Periodic acid–Schiff staining of various tissue.

Fungal organism	Magenta
PAS positive material	Magenta
Nuclei	Black/Blue
Other tissue components	Green/Blue
1-2 Glycol	Red

3.2.3 Masson’s Trichrome stain (TRI)

The samples were dewaxed and rinsed in 100% xylene for 5 minutes. They were then rinsed in 100% alcohol for 1 minute, in 96% for 1 minute and in 70% for 1 minute. The dewaxed samples were rinsed in distilled water. They were then stained in filtered Celestine blue solution for 15 minutes and rinsed three times in distilled water. Samples were then stained with Lilly-Mayer haematoxylin for 1 minute. The sample was washed until blue in tap water for 10 minutes. Samples were stained in Biebrich Scarlet Fuchsin solution for 15 minutes and thereafter rinsed in distilled water. Mordant in phosphotunstic-phosphomolybdic acid was applied for 5 minutes. Samples were counter stained in Aniline Blue for 5 minutes, after which the samples was rinsed in distilled water. Samples were differentiated in 1% glacial acetic acid for 3 minutes and subsequently dehydrated in in 96% alcohol and then in 100% alcohol. The slides were cleared with Xylene and the coverslip mounted with Entellan.

Table 3: Masson Trichrome staining of various tissue.

Nuclei	Black
Collagen	Blue
Muscle-fibers, cytoplasm, keratin, intercellular fibers	Red

3.3 RESULTS

The gastrointestinal tract is composed of up to six layers, namely the mucosa; *Lamina epithelialis, Lamina propria* and *Lamina muscularis mucosae*, the Submucosa, *Tunica muscularis* and Serosa. All descriptions will follow from the *Lamina epithelialis* to the Serosa.

3.3.1 Proventriculus (Figs. 3.1 - 3.9)

The proventriculus is composed of the six layers mentioned above (Fig. 3.2). The *Lamina epithelialis,* presents rugae / plicae (*Rugae proventriculares*) lined by simple columnar epithelium. It is supported by the *Lamina propria* that in places is obliterated by internodular lymphoid tissue. The *Lamina propria* and *Lamina epithelialis* form finger-like projections in transverse section (Figs. 3.2 - 3.5). The *Lamina propria* is well vascularised. The rugae are of varying height and the valley's (*Sulci proventriculares*) form simple tubular mucus-secreting glands, the superficial proventricular glands (*Gll.*

proventricularis superficialis) (Figs. 3.4-3.5). The cells of the glands are tall columnar with a large, oval, basally situated nucleus (Figs. 3.5, 3.6). The cytoplasm has a characteristic foamy appearance with all stains (Fig 3.6). In some parts the cytoplasm, distal to the nucleus can be divided into two more-or-less equal portions as seen with PAS and TRI (Fig. 3.6B-D). The cytoplasm adjacent to the nuclei is PAS positive and the distal cytoplasm is red with TRI. The tips of the *Rugae proventriculares* are more strongly PAS positive (Fig. 3.5). The *Lamina propria* is composed mostly of a loose to an irregular dense connective tissue with infiltrations of internodular lymphoid tissue, and it supports the superficial proventricular glands (Figs. 3.2 – 3.6). A *Lamina muscularis mucosae*, which houses the massive, deep proventricular glands (*Gll. proventricularis profundae*) is present and is composed of smooth muscle fibres that are diffusely spread, surrounding each deep proventricular gland (Figs. 3.2 - 3.4). The *Lamina muscularis mucosae* is present at the base of each gland and moves between the lobules of an individual gland (Figs. 3.2 – 3.4). The smooth muscle fibres terminate in the *Lamina propria* before reaching the base of the rugae (Figs. 3.2 – 3.4). The partitions radiate in between the lobules of each gland and terminate toward the central sinus (Figs. 3.2 - 3.3). The deep proventricular glands represent the main feature and thus histological component, of the proventriculus and contribute about 60% of the thickness of the proventriculus (Figs. 3.2 – 3.4). They are compound tubular glands composed of numerous lobules of varying size. All the lobules open into a large central sinus, which represents the secondary duct (Figs. 3.2 – 3.4). The glands in the lobules open into a short tertiary duct which opens into the secondary duct of the proventricular gland (Fig. 3.3). The most apical region of the secondary duct continues to the lumen, forming a short primary duct passing up through the mucosal papillae and opening into the lumen (Figs. 3.3). The primary duct opens to the lumen of the proventriculus via a macroscopic papilla (*Papilla proventricularis*), see also chapter 2 (Fig. 2.7) and there is thus one such papilla present for each deep proventricular gland (Figs. 3.3 - 3.4). The glands are lined by two distinct epithelia; a simple cuboidal and a simple columnar epithelium (Figs. 3.2 - 3.4, 3.7). The primary, secondary and tertiary duct epithelium is composed of columnar epithelial cells (Fig. 3.7A-D) similar to that of the *Lamina epithelialis* (Fig 3.5). The columnar epithelial cells are strongly PAS positive (magenta) showing mucin granules in the cytoplasm. The cells are most strongly PAS positive in the tertiary ducts and least in the primary duct. The epithelium lining the ducts of the deep proventricular glands is continuous with, and similar to, the *Lamina epithelialis*. The lobules are composed of long tubular glands lined by cuboidal epithelium. The cuboidal epithelium represents the oxynticopeptic cells. The walls of the gland lobules are one cell layer thick and adjacent cells are separated by a very thin layer of well vascularised connective tissue (Fig 3.8). The oxynticopeptic cell cytoplasm is densely packed with granules/zymogen/secretory granules, which stain dark red with TRI.

The submucosa is thin, composed of an irregular dense connective tissue and carries larger blood vessels and nerves (Figs. 3.2, 3.9). The *Tunica muscularis* is composed of a thin inner longitudinal (S*tratum longitudinale*) and a much thicker outer circular layer (*Stratum circulare*) of smooth muscle (Fig. 3.9). Connective tissue divides the two layers into various bundles (Fig. 3.9). A thin subserosa, composed of a loose connective tissue supports the serosa.

3.3.2 Ventriculus (Figs. 3.1, 3.10 – 3.16)

The gizzard (ventriculus) is composed of four layers namely the *Lamina epithelialis, Lamina propria- Submucosa*, *Tunica muscularis gastris* and serosa (Figs. 3.10, 3.11). A *Lamina muscularis mucosae* is absent. The lumen of the ventriculus is thrown into well-developed ventricular folds (*Plicae ventriculares*), which can also be seen macroscopically (see Chapter 2, Fig. 2.9). Prominent folds can be seen in the empty state and little to none in the full state. The ventricular folds are supported by the inner longitudinal *Tunica muscularis*, the propria-submucosa and mucosa (Fig. 3.10). The mucosa is characterised by ridges and grooves (*Rugae ventriculares* and *Sulci ventriculares*) which are narrow and deep (Figs. 3.11 - 3.15) and comparable to the intestinal villi (see Figs. 3.18 - 24). The *Lamina epithelialis* is composed of cuboidal to columnar cells and invaginates into the propria-submucosa to form simple branched tubular ventricular glands (*Gll. ventriculares*) (represented by the *Sulci ventriculares*) (Figs. 3.11 - 3.15). The base of the ventricular glands extends to the junction with the submucosa (Figs. 3.10 – 3.12). The epithelium towards the tips (lumen side) of the tubular glands is columnar (Figs. 3.13, 3.14D, 3.15D) whereas the epithelium lining the sides and base of the tubular glands is cuboidal (Figs. 3.13, 3.15A). The main type of cells (chief cells) are found throughout the entire gland, despite regional variation in shape. At and near the base of the tubular gland the cells are low columnar to cuboidal in shape with rounded nuclei (Figs. 3.13, 3.15A-C). In the mid-region of the gland the columnar cells of the epithelium become flattened and the nuclei become more oval (Figs. 3.12, 3.14, 3.15). The surface cells lining the gland at the ventricular lumen are taller than the chief cells, with a low columnar shape and an apical surface which tends to bulge into the lumen (Figs. 3.11 – 3.14). The lumen of each gland differs slightly in the basal region near the *Lamina propria- Submucosa* (Figs. 3.12, 3.13). The koilin membrane forms part of two different secretory phases. The secretions from the chief cells and columnar epithelial cells have a different staining affinity (Figs. 3.10, 3.11, 3.14, 3.15). A strongly eosinophilic (H&E), light red with TRI and PAS negative substance is secreted into the gland lumen from the chief cells, while the other part is secreted by the surface cells, staining PAS positive, a dark red with TRI and less eosinophilic with H&E (Fig. 3.14A). The substance secreted by the surface cells is PAS positive (stains magenta) (Fig. 3.14B), and stains bright red with TRI (Figs. 3.15C&D). This secretion is visible in the apical portion of the surface cells as eosinophilic inclusions (Figs. 3.14D, 3.16A,C,D). The luminal and crypt columnar, chief cells secrete a substance that is less intensely eospinophilic (H&E), is weakly PAS positive (light pink) and stains pale red with TRI (Figs. 3.15A-D). The koilin is secreted in layers in the vertical plane corresponding to the vertical alignment of the glands within the *Lamina propria* (Figs. 3.11, 3.14A-C). The alternating layers of dark and light-staining secretion form layers that merge on the surface, the light layer has the vertical rods and the dark layer the horizontal matrix (*Matrix horizontalis*), together they form the koilin membrane (*Cuticula gsatrica*) (Figs. 3.11, 3.14A-C). The *Lamina propria* and *Lamina propria- Submucosa* merge at the base of the ventricular glands and are composed of an irregular dense connective tissue (Figs. 3.11, 3.12). The smooth muscle fibres between the ventricular glands run vertically towards the surface (Figs. 3.11 - 3.13). The *Lamina propria- Submucosa* is well-vascularised and consists of dense irregular connective tissue. The *Tunica muscularis* is the thickest layer of the ventriculus and is composed of a thinner, more loosely arranged inner longitudinal layer and a thicker, more compact outer circular layer of smooth muscle (Figs. 3.10, 3.11), which also houses the myenteric plexus (Fig. 3.16). The inner circular layer is arranged in well-defined bundles that is separated by thin layers of connective tissue, illustrated especially well with TRI stain (Figs. 3.10, 3.18 – 3.23). The outer longitudinal layer is arranged in continuous thin bands.

3.3.3 Intestine (Figs. 3.17 – 3.24)

The intestine is composed of the six layers mentioned above (Figs. 3.18, 3.19A, 3.20A, 3.23A-C, 3.24A,C,E), namely the *Lamina epithelialis*, *Lamina propria*, *Lamina muscularis mucosae*, submucosa, *Tunica muscularis intestinae* and the serosa. The structure of the entire intestine is similar with small variations that will be mentioned where relevant. No *Plicae circulares* were observed in the intestine.

The *Lamina epithelialis* is a simple columnar epithelium with numerous goblet cells. The goblet cells increase in density from the duodenum to the rectum. The mucus secreted by the goblet cells is basophilic and does not stain with H&E (Fig. 3.24B) and TRI (Fig. 3.24D), it is, however, strongly PAS positive (Fig. 3.24F). The *Lamina propria* is an irregular dense connective tissue. The latter two layers are highly folded and form intestinal villi (*Villi intestinales*) (Figs. 3.18, 3.19, 3.21A, 3.23A-C, 3.24A,C,E) projecting into the lumen, and simple tubular and branched glands projecting towards the *Muscularis mucosa*. The epithelial cells are oval to flask-shaped and those lining the base of the glands bear microvilli (Figs. 3.19B, 3.20C, 3.22A-C, 3.23D). Throughout the length of the small intestine, moving from the duodenum aborally towards the rectum, there is a decrease in the height of the mucosa forming the intestinal villi which in turn become shorter and broader (Fig. 3.18). Villi are densely packed in the duodenum and become spaced further apart towards the rectum (Fig.

3.18). The villi form a zigzag formation in the rectum (Fig. 3.24). The *Lamina propria* houses the duodenal glands (*Gll*. *duodenales*) in the duodenum and the intestinal glands (*Gll*. *intestinales*) in the remainder of the intestine (Figs. 3.18, 3.19, 3.21, 3.23A,B&C, 3.24). Internodular lymphoid tissue is present throughout the *Lamina propria* in the small intestine and rectum (Figs. 3.21, 3.22).

The gland lining cells consist of tall, narrow columnar cells (chief cells). The nuclei are large and oval (Figs. 3.21B, 3.24B,D,F). The base of the glands are slightly dilated and are easily identifiable as flask-shaped structures and rest on the junction to the *Lamina muscularis mucosae* (Figs. 3.18 - 3.20, 3.23D, 3.24A,C,E). Microvilli are absent on the intestinal villi.

The *Lamina muscularis mucosae* is well-developed, continuous and is composed of a longitudinal layer of smooth muscle fibres throughout the length of the intestine. Additionally, an outer circular layer of the *Lamina muscularis mucosae* is present throughout, except for the rectum where a single longitudinal layer is present. In places, autonomic ganglia are present between the two layers of the *Lamina muscularis mucosae* (Figs. 3.22A, 3.25). The submucosa is highly compressed/condensed throughout, and becomes more prominent in the rectum (Fig 3.24A,C,E). It separates the two layers of the *Lamina muscularis mucosae* and carries blood vessels and nerves. The submucosa is continuous with the circular portions of the inner circular layer of the *Lamina muscularis mucosa.* The *Lamina muscularis mucosa* surrounds the base of the intestinal glands (Figs. 3.18 - 3.25). The *Tunica muscularis intestini* consists of a thick inner circular (*Stratum circulare*) and a slightly thinner outer longitudinal (*Stratum longitudinale*) layer of smooth muscle (Figs. 3.18 – 3.20, 3.23A-C, 3.24A,C,E). A well developed and thicker musculature is observed in the small intestine and a thinner musculature within the rectum (Fig 3.18). The submucosa extends into the *Stratum circulare* forming compartments of the smooth muscle. Between the muscle bundles and the two muscle layers there is a very thin connective tissue layer (Figs. 3.20, 3.21, 3.23, 3.23). The serosa forms the outermost layer of the intestine.

3.4 DISCUSSION

The physiology of avian digestion has been studied primarily in Galliformes (Fowler, 1991) and offers insight into understanding motility, the release of gastric secretions and absorption mechanisms. Birds with high-protein diets (carnivores) generally possess less complicated digestive systems than those eating complex carbohydrates (herbivores) (Duke, 1997). The muscular stomach of raptors and fish-eating birds is simple, without the thin and thick pairs of muscles described in granivorous avian species (Calhoun, 1954). The GIT of the SGH broadly resembled that of carnivorous avian species such as the black-winged kite (*Elanus caeruleus*) (Akester, 1986), brown falcon (*Falco berigora*) (Al-taee, 2017), cattle egret (*Bubulcus ibis*) (Hussein and Rezk, 2016) and Eurasian hobby (Abumandour, 2014). Typical adaptations of the carnivorous SGH noted in the present study, such as the distensible ventriculus, a poorly developed ventricular muscle layer and a fairly simple, short intestine, were all common features similar to other meat-eating birds.

3.4.1 The stomach

3.4.1.1 Superficial proventricular glands *(Gll. proventricularis superficialis)*

The structure and function of the proventriculus and ventriculus is fairly universal among birds in that it plays a crucial role in providing an adequate environment for the physical and chemical reduction of the size and molecular complexity of a bird's diet (King and McLelland, 1984; Langlois, 2003). The primary function of the proventriculus is to secrete mucous, hydrochloric acid and pepsinogen into the digestive compartments. The superficial glands of the SGH secreted mucous only (present study), similar to that noted in the chicken (Hodges, 1974).

In the SGH the mucous-secreting cells of the superficial glands were low cuboidal to tall columnar, unlike the typical cuboidal to low columnar cells present in the chicken (Chodnik, 1948; Calhoun, 1954). This shape varies according to the degree of functional activity, with the tall columnar shape suggesting high activity (Chodnik, 1947). Tall columnar cells with large, basally placed nuclei seen in the SGH supported a highly active mucus-secreting cell. The strong positive PAS staining indicated neutral mucin secretions, whereas the weak PAS to PAS negative secretions possibly indicated acid mucin secretions. Distinction between neutral and acid mucins can only be made with different staining (Alcian blue), as PAS only detects neutral mucins (Demirbag *et al.*, 2015). The presence of neutral and acid mucin acts as a barrier to protect the proventricular mucosal surface (Shubich *et al.*, 1978).The main function of mucus is to cover, lubricate, and protect the stomach surface from the corrosive actions of acidic gastric juices of the deep proventricular glands (Zhu, 2015; Kohl *et* *al.*, 2017). The viscoelastic mucus gel provides a physical barrier with low permeability for pepsin and other macromolecules between the lumen and the apical surfaces and is derived from mucin glycoproteins (mucins) (Liman, Alan and Küçük Bayram, 2010). Acid mucins are anti-ulcerogenic as they coat and protect the mucosal surface and inhibit the proteolytic action of gastric juices while neutral mucins aid in the secretion of enzymes (Chikilian and de Speroni, 1996; Sayrafi and Aghagolzadeh, 2020). Feeding habits, diet quality and the quantity of food affect the structure of the digestive system (Chikilian and de Speroni, 1996).

3.4.1.2 Deep proventricular glands *(Gll. proventriculares profundus)*

The distribution of the deep proventricular glands is not consistent among avian species. Generally, they are distributed evenly throughout the proventriculus, however, variations exist and the glands are restricted to longitudinal tracts in owls (*strigiformes*), to a circular patch on the greater curvature (ratites) (King and McLelland, 1984; Langlois, 2003), longitudinal folds with gland-free zones in flower-seeking parrots (Farner, King and Parkes, 2012) and they were more concentrated in the ventral aspect in the SGH (present study), with a small gland free zone dorsally. The gland-free zones in flower-seeking parrots makes the organ more distensible (Farner, 1960). Considering the large prey consumed by the SGH, it is possible that the gland-free zone on the dorsal inner surface of proventriculus of the SGH may have a similar function.

There is contention between different researchers to the position of the proventricular glands in the different layers. In many types of birds the glands penetrate into the

Muscularis mucosae during development, separating it into inner and outer layers (Farner, 1960). The deep proventricular glands are surrounded by smooth muscle fibres from the *Lamina muscularis mucosae* in the common starling (*Sturnus vulgaris*) (Sayrafi and Aghagolzadeh, 2020), brown falcon (Al-taee, 2017) and the ostrich (*Struthio camelus*) (Stornelli *et al.*, 2006). This explanation agrees with the observations (in chickens and the cattle egret) (Calhoun, 1954; Hussein and Rezk, 2016), indicating that the glands occur within the *Muscularis mucosae*, similar to that noted in the SGH (present study). The smooth muscle fibres surrounding the deep proventricular glands likely aid secretion by contracting to push the content into the lumen of the deep proventricular glands where they can empty to the lumen of the proventriculus.

The central cavity of the deep proventricular glands in the SGH was lined by columnar cells that were strongly PAS positive, a feature that was also been noted in the chicken (Hodges, 1974). Neutral mucins are demonstrated in the red jungle fowl (*Gallus gallus*) (Kadhim *et al.*, 2011), whereas in the rock dove (*Columba livia*) (Inforzato and Sasso, 1985), the fowl (*Gallus gallus domesticus*) (Imai *et al.*, 1991) and in the guinea fowl (*Numida meleagris*) (Selvan, Ushakumary and Ramesh, 2008) both acidic and neutral mucins are present. It is possible that neutral (PAS positive) and acid (PAS negative) mucins are secreted in the SGH, however, further staining is required.

Mucous secreting cells also line the main duct of the deep proventricular glands, and the alveoli of the glands are lined by cuboidal, oxynticopeptic cells, which secrete both the hydrochloric acid (HCl) and pepsinogen (McLelland, 1990). The secretions of both HCL and pepsin are produced by a single cell type, cuboidal cells, in birds (Chodnik, 1947). The cuboidal cells in the SGH were densely packed with zymogen/secretory granules that stained dark red with TRI, possibly indicating a large amount of pepsinogen being secreted into the secondary and tertiary ducts and ultimately into the proventriculus, and the HCL secretions stained a slightly less red colour (Present study). The pepsin and HCL are secreted in different staining colours into the central opening of the gland where it is then expelled towards the lumen of the proventriculus (Zhu, 2015). Similar to the ostrich (Bezuidenhout and Van Aswegen, 1990) and unlike the chicken (Menzies and Fisk, 1963), where PAS positive secretions were pepsinogen, the oxynticopeptic cells of the SGH were PAS negative and mucin free (present study).

3.4.2 Ventricular glands (*Gll. ventriculares*)

The ventriculus in carnivorous species is used mainly for allowing time for gastric juices to act on the soft food rather than for mechanical or physical digestion (King and McLelland, 1984; Miguel, 2019). In most species, including the SGH, food passes rapidly through the glandular stomach and is held in the muscular stomach whereby the actions of the gastric secretions (pepsin, HCl, and mucus) take effect (Duke, 1997).

The *Lamina epithelialis* was composed of cuboidal to columnar cells and invaginated into the *Lamina propria* to form simple branched tubular ventricular glands (*Gll. ventriculares*) in the SGH. The ventricular mucosa of the brown falcon was composed of columnar cells (Bailey *et al.*, 1997), whilst that of the coot bird (Batah and Selman, 2012) and mallard (Kohl *et al.*, 2017), was of cuboidal cells. Similarly, the ventricular mucosa of the SGH was also composed of columnar cells, possibly protecting the stomach lining from the highly acidic influx from the proventricular secretions and thus requiring an increased mucous secretion (present study).

The koilin membrane was a noteable feature of the SGH ventriculus. It is likely formed as part of two different secretory phases as described by Eglitis and Knouff (1962). The secretions from the crypts and luminal portion and surface cells have both different structure and staining affinity (Toner, 1964). Two different theories are presented, one suggests that the lining is anchored to the mucosa (Eglitis and Knouff, 1962) and the other suggests that the lining easily moves in relation to the mucosa (Webb and Colvin, 1964). The formation of the koilin layer has been described by a few researchers. Most agree that two different secretions are present; one from the luminal columnar cells and the other from other cells such as the surface cells (Eglitis and Knouff, 1962; Webb and Colvin, 1964; King and McLelland, 1984; Akester, 1986; Whiteside, 2017). The lumen of the tubular glands contained eosinophilic secretions in the turkey (*Meleagris*) (Beheiry, 2018). Similarly, in the SGH eosinophilic secretions and a great amount of mucin secretion were seen in the ventriculus (present study). The columnar cell secretions join up with the secretions from the crypts and luminal portion to form a compact mass in the glandular lumen and are demonstrated as a filamentous structure (Eglitis and Knouff, 1962; Toner, 1964; King and McLelland, 1984). The mass then becomes hardened, consisting of rodlets in the middle and upper regions and surrounded by the secretions from the surface cells, forming the layer of matrix (*Matrix horizontales*) (Whiteside, 2017). The koilin secretions spread on the surface of the epithelium and around the rods before they harden, this process is thought to be due to a decrease in pH as a result of diffusion of hydrochloric acid from the proventriculus (King and McLelland, 1984; Akester, 1986; Whiteside, 2017). The filamentous structure of all the glands open into a crypt, which unites to form vertical rods (King and McLelland, 1984). Hodges (1974) noted that even though the lining is slightly detached from the surface cells it is in fact secreted in a fluid condition. Ultimately, the koilin layer consists of a carbohydrate-protein complex with two distinct components: a scaffolding of interconnecting vertical rods and a *Matrix horizontales* (Toner, 1964; King and McLelland, 1984; Akester, 1986; Whiteside, 2017). The koilin layer of the SGH was softer and uniformly distributed (present study) as noted in frugivores and nectarivores, and is unlike that in the granivorous avian such as the chicken (Langlois, 2003). The *Matrix horizontales* of the SGH consisted of secretions with a strong eosinophilic (H&E), PAS positive and bright red TRI substance secreted by the glandular chief cells, and the vertical rods were less intensely eosinophilic (H&E), weakly PAS positive (light pink) and pale red TRI substance secreted by the surface cells. These secretions form alternating layers of *Matrix horizontales* of softer material and vertical rods of hard koilin in tight clusters in the horizontal plane (Akester, 1986), similarly seen in the laughing dove (*Spilopelia senegalensis*) and rock pigeon (Madkour and Mohamed, 2019), and likely also in the SGH (present study).

The koilin layer continuously wears down, in a patchy fashion, and is in turn continuously replaced by the ventricular glands in the European starling (*Sturnus vulgaris*) (North, Movassaghi and Smits, 2016) and in most other birds (Akester, 1986). However, in some birds such as the common starling, mistle thrush (*Turdus viscivorus*), little owl (*Athene noctua*), cuckoo (*Cuculidae*) and curlew (*Numenius*), the koilin layer as a whole passes through the cloaca before it is replaced (Akester, 1986). The SGH has not been reported to pass the koilin layer whole. Interestingly, the male wrinkled hornbill (*Buceros corrugatus*), after consuming fruit passes the entire koilin layer filled with fruit and presents it to the female incubating the nest (Bartlett, 1869; Flower, 1869; Murie, 1874).

Three muscle layers in the *Tunica muscularis* have been reported in the brown falcon (Al-taee, 2017) and the passeriformes (Ogunkoya and Cook, 2009). However, two layers were noted in the SGH (present study) as well as in the chicken (Calhoun, 1954), parrots (Psittaciformes) (Al-Saffar and Eyhab, 2016), Eurasian hobby (Abumandour, 2014), partrigde (*Rhynchotus rufescens*) (Rossi *et al.*, 2005) and the domestic pigeon (Al-Saffar and Eyhab, 2016). Strands of smooth muscle run perpendicular to the glands that may assist in pulling the glands closer to the muscle layer, having the effect of emptying the gland contents. The thin musculature of the ventriculus would conceivably allow more distensibility in comparison to a very thick-walled muscular ventriculus (Klaphake and Clancy, 2005). The ability of the ventriculus to distend to the extent it does in the SGH makes it easy to house and digest large prey.

3.4.3 The intestines

The structure of the small intestine of the SGH was very similar throughout (present study). There are three different cell types present in the small intestine; chief, goblet and enterochromaffin cells (Bezuidenhout and Van Aswegen, 1990). They multiply from the base of the crypts where they then gradually migrate up the walls of the crypts and villi and eventually shed into the lumen of the tips of the villi (Akester, 1986).

The mucosa of the small intestine in the SGH revealed a strong magenta colouration with PAS positive reaction in the goblet cells of both the villi and the crypts of Leiberkühn as well as the apical plasma membranes of simple columnar epithelial cells. Goblet cells occur throughout the intestine, but become progressively more numerous towards the cloaca (King and McLelland, 1984), a feature also noted in the SGH in the present study. The ileum in the African pied crow (*Corvus albus*) has more goblet cells in comparison to that of the duodenum (Al-Saffar and Al-Samawy, 2015), which was also noted in the SGH. The increased goblet cells may assist in lubrication towards the rectum as most water and nutrients are absorbed and more lubrication is required for expulsion of faeces. The intestines are the principal site of chemical digestion and nutrient absorption (Duke, 1997). The small intestines mainly function to digest and reabsorb nutrients. The primary site of nutrient absorption such as carbohydrates, amino acids and peptides, fatty acids, electrolytes, vitamins are absorbed by villi of the small intestine, and to a lesser degree the rectum (Bartlett, 1869). However, absorption of amino acids is also reported to occur in the proventriculus and gizzard (Denbow, 2000). The simple columnar epithelium lining of the colon has well-developed microvilli, also known as a brush border, increasing the absorption surface area by 15-fold (Klasing, 1999). The intestinal villi of the chicken form a zigzag pattern that slows down flow and increases absorption in the intestine (Denbow, 2000). The zigzag formation was seen in the rectum and together with the presence of more goblet cells in the SGH, supports the notion of the absorptive function of the large intestine.

The *Lamina muscularis mucosae* of the goose gut was thinnest in the duodenum, and thickest in the ileum and only a longitudinal layer was present in the rectum (Kushch *et al.*, 2019), a feature similar to that noted in the SGH (present study). The *Lamina muscularis mucosa* of the SGH also surrounded the base of the glands and contracted to expel the content into the intestinal lumen (present study). The latter indicates a decrease in fine contractility and increase in lubrication. In short, it seems that the small intestine has finer control and more muscle contractility than that of the large intestine when considering the *Lamina muscularis mucosae* described above. The *Tunica muscularis intestini* causes peristaltic contraction to move the chyme from the duodenum towards the rectum.

3.4.4 Gastrointestinal stasis

The two layers of the *Muscularis mucosa* in the duodenum of the ostrich (Stornelli *et al.*, 2006) is similar to the two layers noted in the duodenum, jejunum and ileum of the SGH. These two layers consist of an inner circular and outer longitudinal muscle layer, which are responsible for mixing the digesta and propelling it through the digestive tract (Klasing, 1999). The compartmentalised smooth muscle bundles making up the *Tunica muscularis* in the SGH would also offer more fine control for peristalsis. Bacterial infiltrations, due to GIT stasis is life threatening in the SGH (personal communication, K.N. Koeppel) and possible preventions should be considered. The latest cytoprotective anti-ulcer drug, rebamipide, significantly increases mucin output by 53% in humans (Iijima *et al.*, 2009), and is a potential drug for investigation for wild avians. Cisapride proved to be more effective than metoclopramide to improve duodenal motility in humans (Lux *et al.*, 1994). Interestingly, metoclopramide, the dopamine receptor antagonist used as an antiemetic and gastroprokinetic, has shown to have sedative effects in the domestic chicken in combination with ketamine (Mohammad, Al-Zubaidy and Alias, 2007).

3.4.5 Stress

Stress poses a major risk factor for wild bird species in captivity and the hospital setting (Huber *et al.*, 2017, 2019). A mere 45 seconds of hand restraint in the chicken resulted in increased plasma corticosteroids and after 8 minutes a six-fold increase (Siegel, 1980). Stress is a major contributing factor to mortality when considering the hospitalization of the SGH. Stress, or overexposure to stress, can cause physiological problems, such as weight loss, changes to the immune system and decreased reproductive capacity (Fischer and Romero, 2020). Many people who work with wild animals in captivity assume that they will eventually adjust to their new circumstances, while in fact, captivity may have long-term or permanent impacts on physiology if the stress response is chronically activated (Fischer and Romero, 2020). Widespread empirical evidence across various vertebrate taxa shows that handling wildlife generally induces a severe stress response resulting in increased stress hormones (Huber *et al.*, 2019). It is inevitable that when wild birds such as the SGH, are treated in hospitals, they will experience stress. Siegel (1980) refers to specific (acute stress) and non-specific (chronic stress) regulatory processes that either activate the nervous system or the endocrine system. The nervous system response, is identified by an increase muscle tone, nerve sensibility, respiration rate, blood pressure and blood sugar, whereas the endocrine system activation eventually results in cardiovascular diseases, hypercholesteremia, gastrointestinal lesions, and modification of immunological capability (Siegel, 1980). Short term corticosteroids can have a positive effect on survival but long term effects are detrimental; factors such as suppressing parental behaviour, compromising reproductive success and promoting metabolic disorders are seen (Li *et al.*, 2019). The chemical agent mitotane causes a reversible chemical adrenalectomy, which drastically reduces circulating glucocorticoids (Li *et al.*, 2019). The beta-blocker propranolol also proved to prevent the increase in baseline glucocorticoids that is typically seen in newly-captured members (Fischer and Romero, 2020). Stress also induces gastric ulcers, slows gastric emptying and ion exchange, causes colonic mucin depletion and increased intestinal permeability leading to the passage of antigens to the *Lamina propria* and bacterial translocation (Bhatia and Tandon, 2005; Caso, Leza and Menchen, 2008).

The histological findings noted in this chapter support a finely-controlled movement, efficient absorption and rapid transit of digesta through the gastro-intestinal tract. This compliments the constant foraging behaviour of the SGH. This chapter highlights the need to consider stress and GIT stasis as life-threatening to the SGH.

3.5. Figures

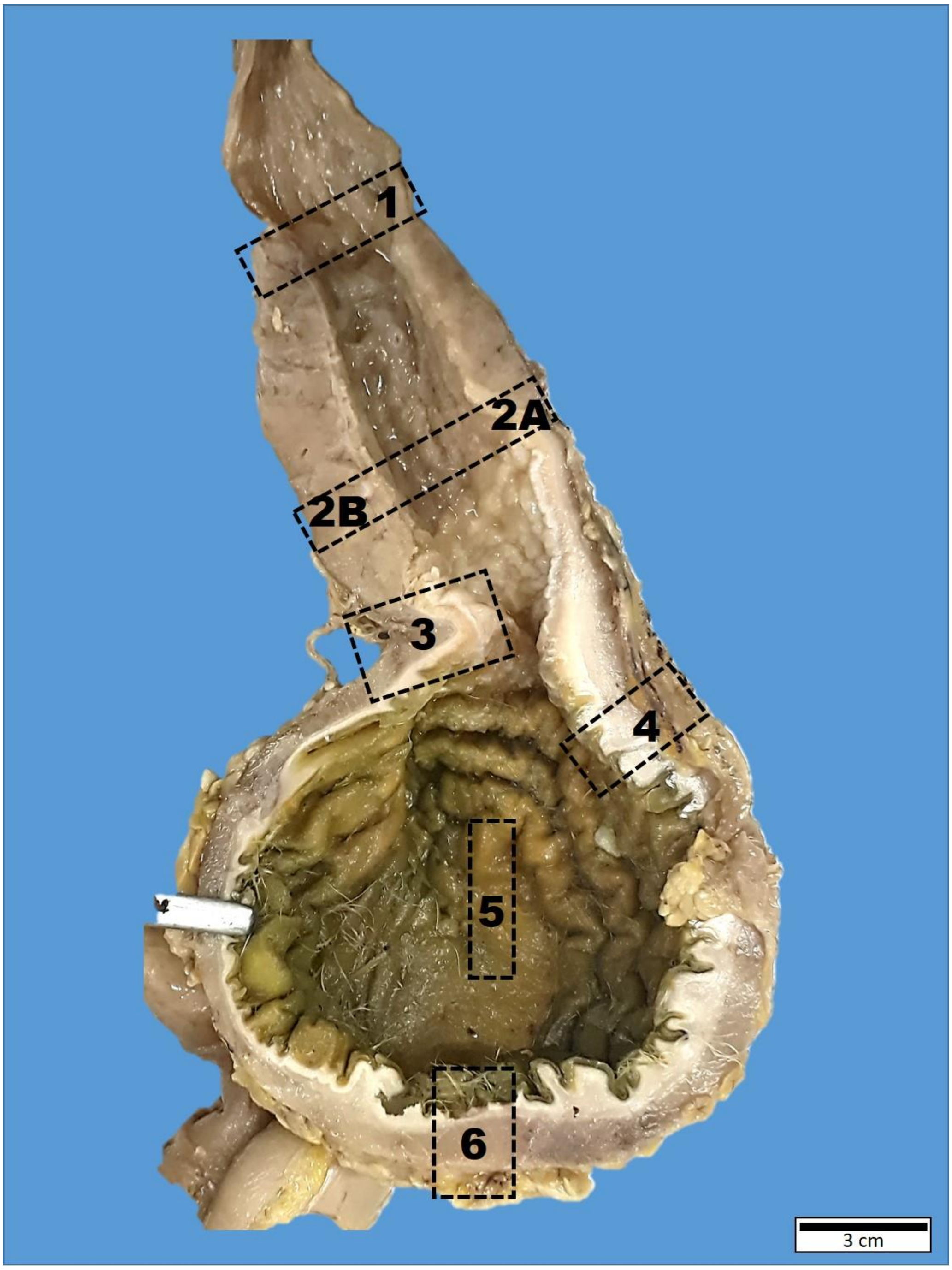

Fig. 3.1: Medial view of the right side of the stomach. Sections for histology were sampled at the junction between the esophagus and proventriculus (1), the proventriculus, dorsal part (2a) and a thicker ventral part (2b), *Isthmus gastris* (3), cranial aspect of the gizzard (4), *Centrum tendinuem* (5) and caudal aspect of the gizzard (6).

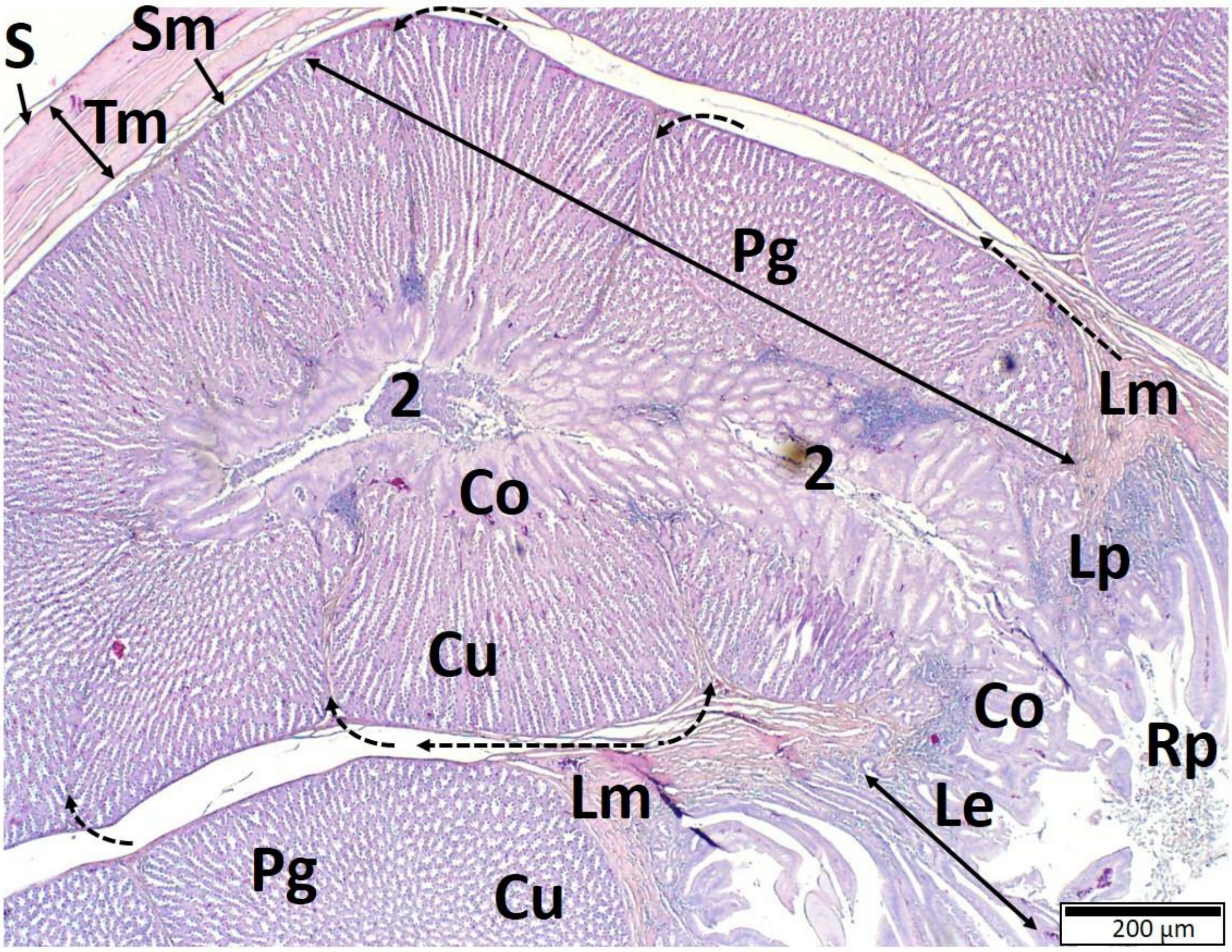

Fig. 3.2: Overview of the proventriculus (dorsal part, 2A in Fig. 3.1) in transverse section (H&E). The *Lamina epithelialis* (Le) presents rugae (*Rugae proventriculares*) (Rp) of varying height, seen as finger-like projections, forming simple tubular mucus-secreting glands, lined by columnar epithelium (Co). Massive proventricular glands (*GII. proventricularis profundus*) (Pg) housed in the *Lamina muscularis mucosae* (Lm) are composed of tubules lined by cuboidal epithelium (Cu). Columnar cells, similar to the *Lamina epithelialis* line the luminal surface of the secondary duct (2). The *Muscularis mucosae* (Lm) surrounds each gland and moves between the lobules of each individual gland (curved black dotted arrows). *Lamina propria* (Lp), submucosa (Sm), *Tunica muscularis* (Tm) and serosa (S).

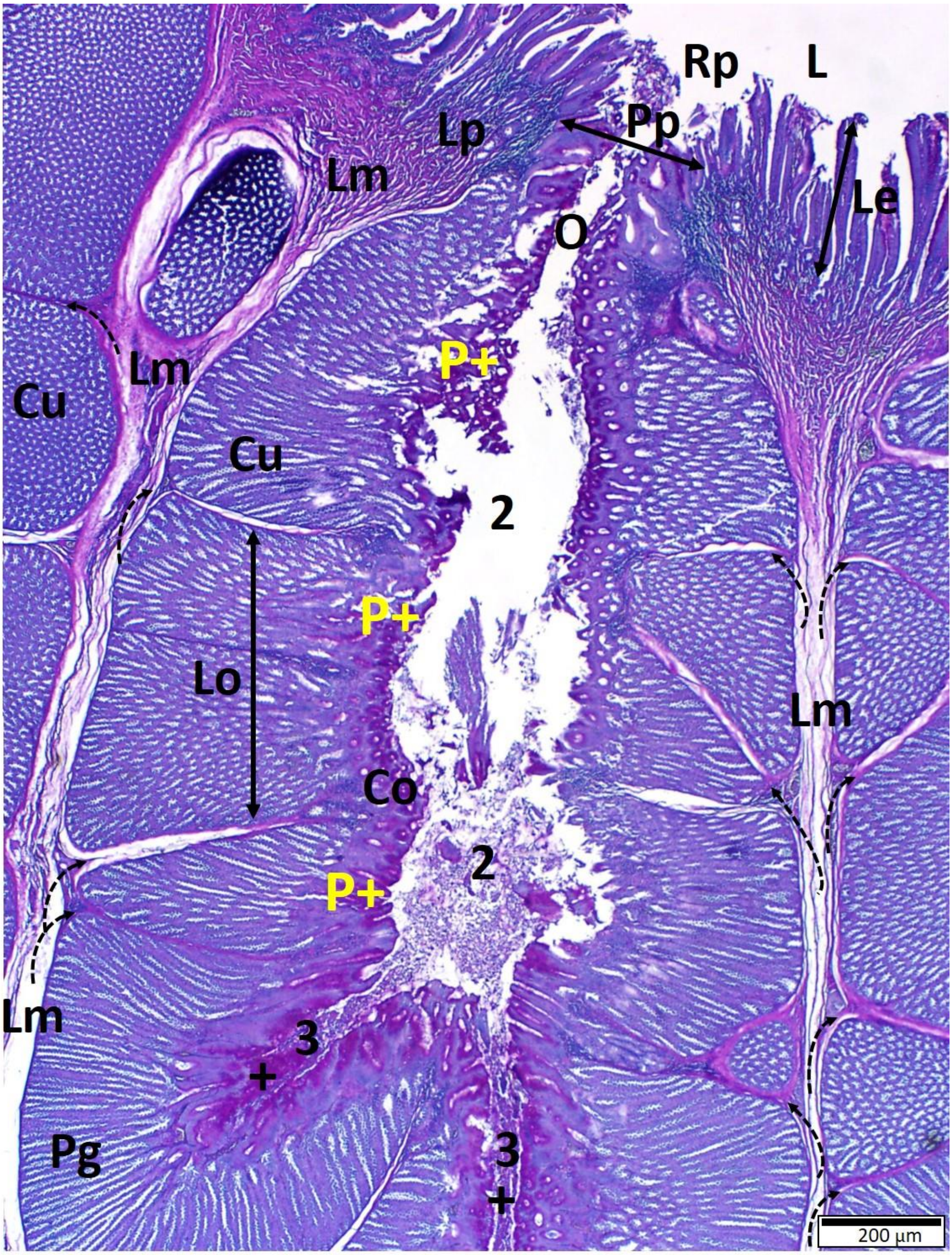

Fig. 3.3: Composite image of the proventricular glands (ventral part, 2A in Fig. 3.1) in transverse section (PAS). The lobules (Lo) of the deep proventricular glands (Pg), are composed of tubular glands lined by cuboidal epithelium (Cu) which changes abruptly to columnar epithelium (Co) lining the tertiary duct (3) and secondary duct (2) that opens to the opening/primary duct (O) on the proventricular papilla (Pp). The columnar cells secrete PAS positive (P+) secretions into the lumen of the deep proventricular glands (Pg), and the tertiary duct cells secrete a stronger PAS positive (+) substance than the secondary duct (yellow P+). *Lamina epithelialis* (Le), *Lamina propria* (Lp), *Lamina muscularis mucosae* (Lm) which surrounds each gland and runs between the lobules of each individual gland (curved black dotted arrows). Rugae proventriculares (Rp) projecting into the lumen (L).

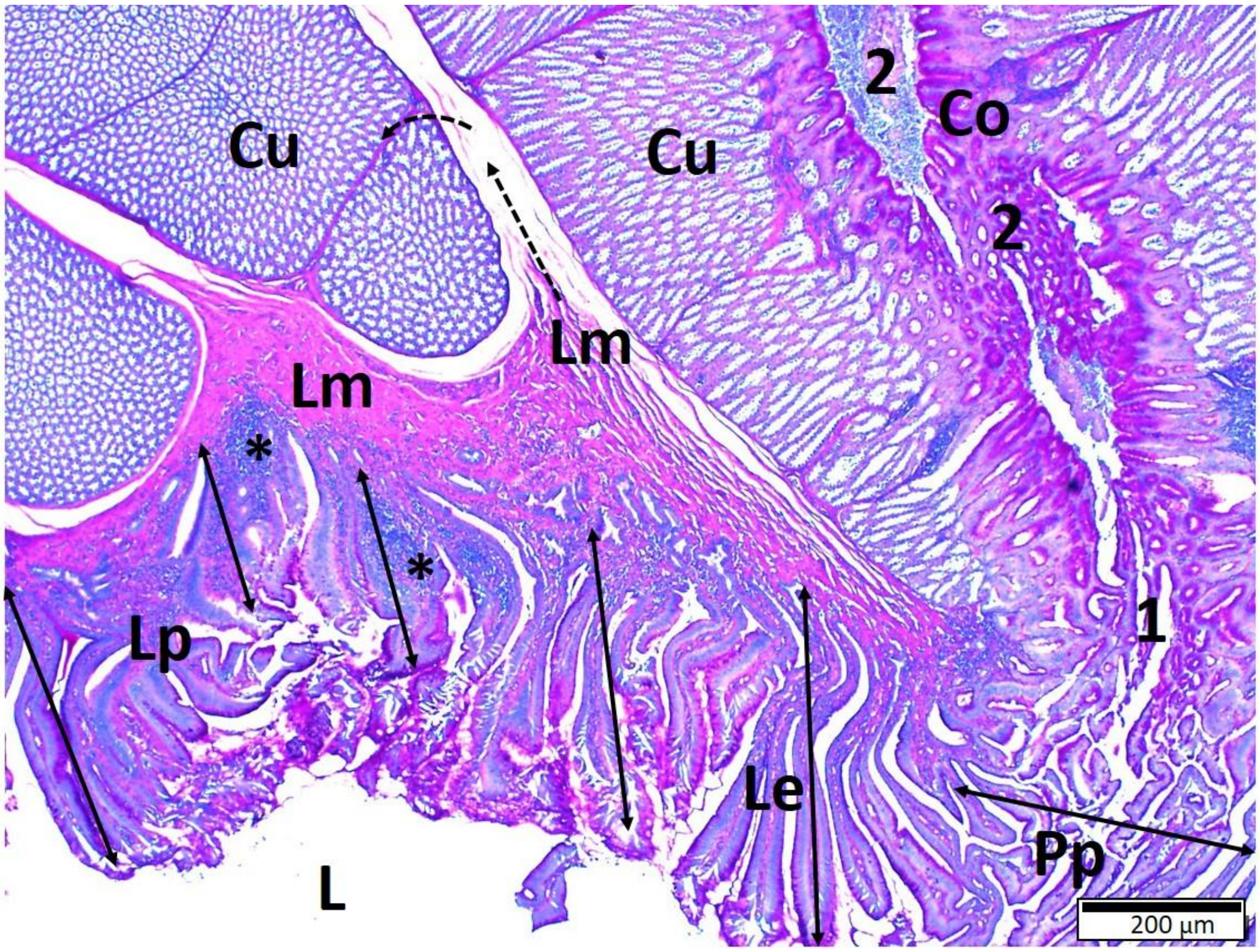

Fig. 3.4: Proventricular lumen and superficial region in transverse section (PAS) (ventral part, 2B in Fig 3.1). The *Lamina epithelialis* (Le) presents rugae (*Rugae proventriculares*) of varying height (vertical black double-headed arrows) forming the superficial proventricular glands between the finger-like projections into the lumen (L). The distinction between the columnar epithelium (Co) opening to the secondary duct (2) and the deeper cuboidal epithelium (Cu) is clear with PAS. The *Lamina muscularis mucosae* (Lm) surrounds each deep gland and divides the lobules (curved black dotted arrows). Primary duct (1) on the proventricular papilla (Pp), leading to the lumen. *Lamina propria* (Lp) with infiltrations of diffuse internodular lymphoid tissue (*).

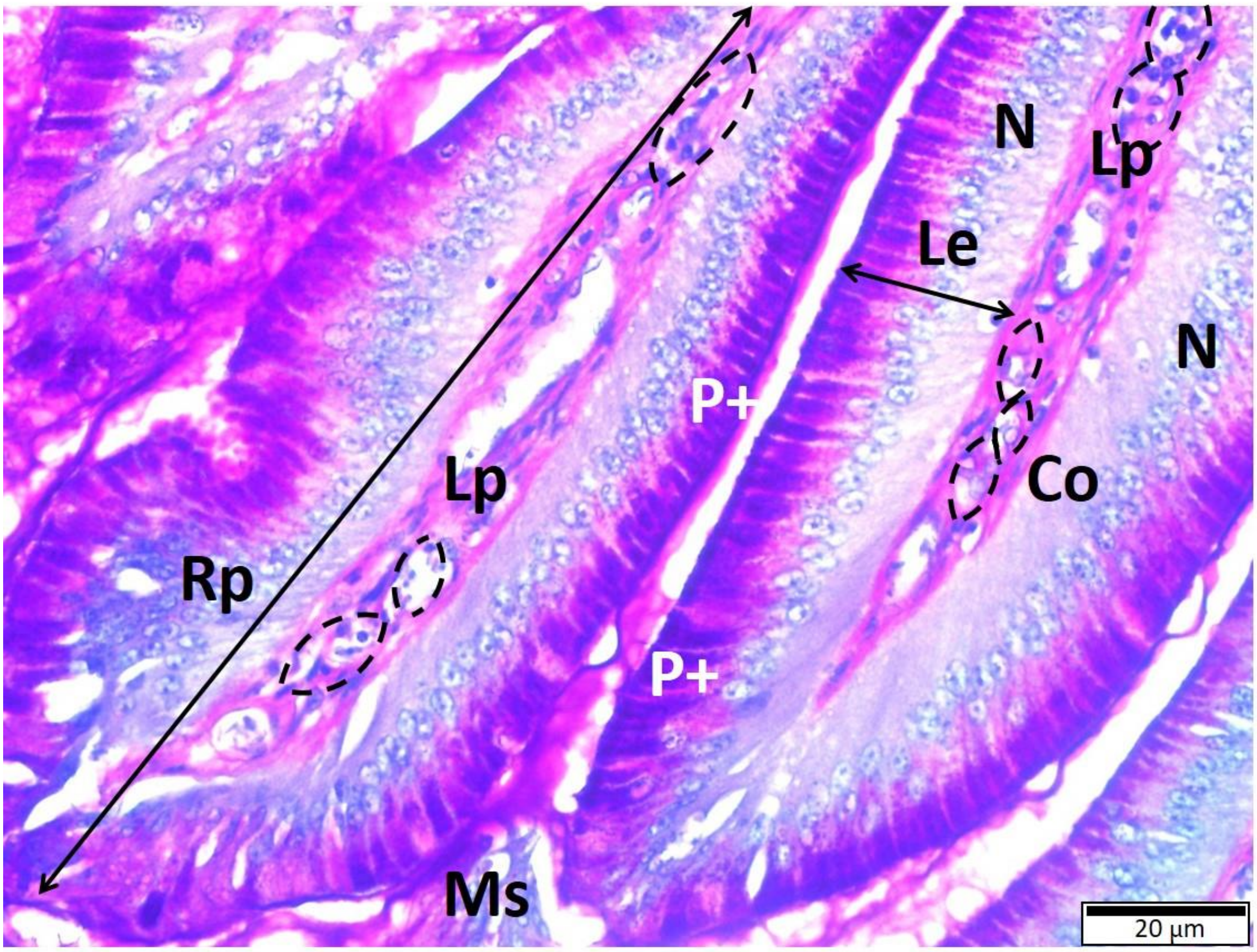

Fig. 3.5: Superficial proventricular glands (PAS) (section 2B in Fig. 3.1)). The *Lamina epithelialis* (Le) and *Lamnia propria* (Lp) form the proventricular rugae (Rp) which form the walls of the simple, tubular mucus-secreting superficial proventricular glands. Note the strongly PAS positive (P+) staining of the distal cytoplasm of the columnar epithelial (Co) cells and the basally situated nuclei (N). Mucus-secretion (Ms) is visible in the lumen. The *Lamina propria* is well vascularised (black dotted circles).

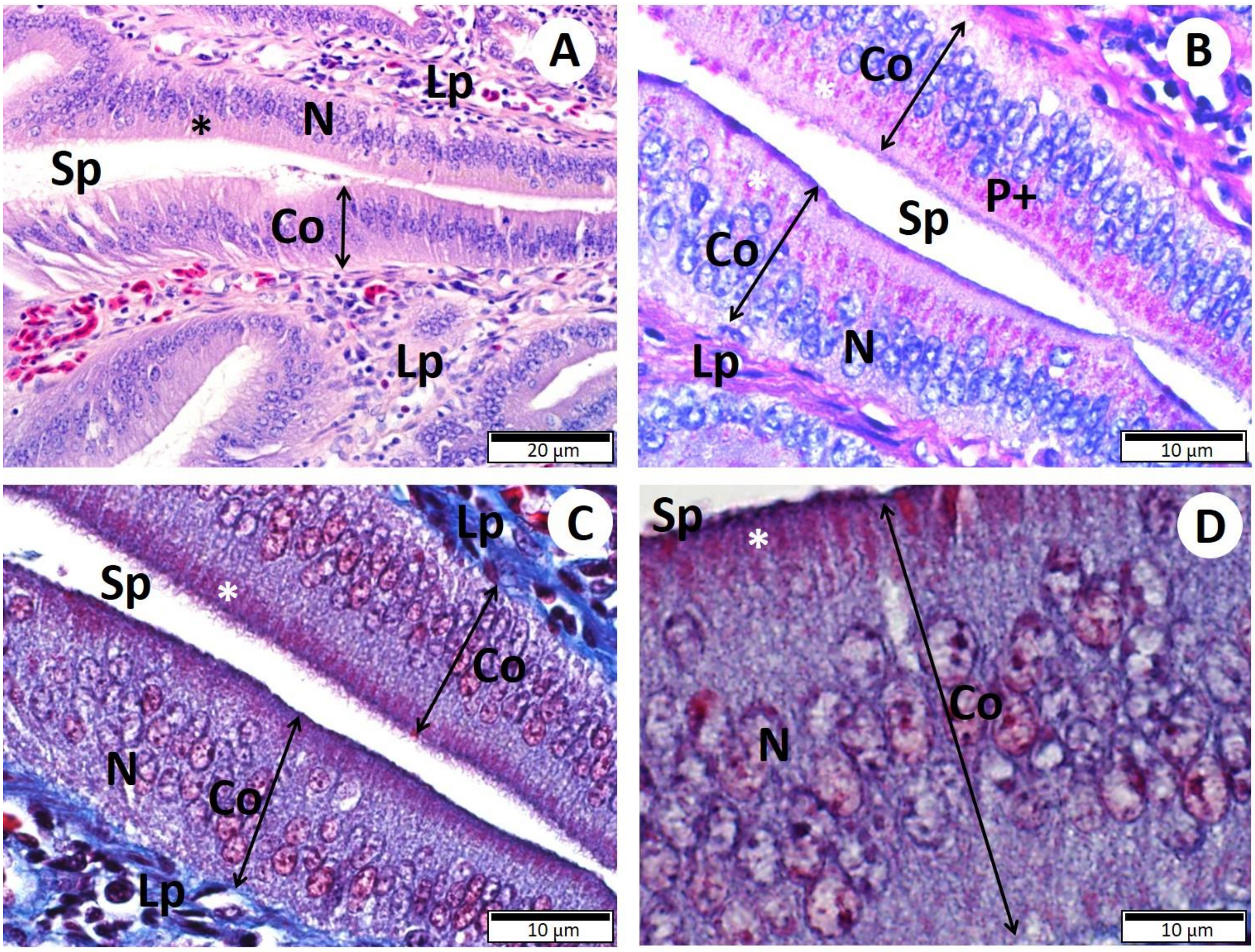

Fig. 3.6: Simple columnar epithelium of the superficial proventricular glands (section 2B in Fig. 3.1) A) H&E, B) PAS and C/D) TRI. **A)** The cytoplasm appears foamy (*) with all the stains and is eosinophilic with H&E. **B)** PAS positive (P+) cytoplasm. **C/D)** Columnar epithelial cells (Co) secreting dark red substance (white *). Basally situated nuclei (N), superficial proventricular gland (Sp), Lamina propria (Lp).

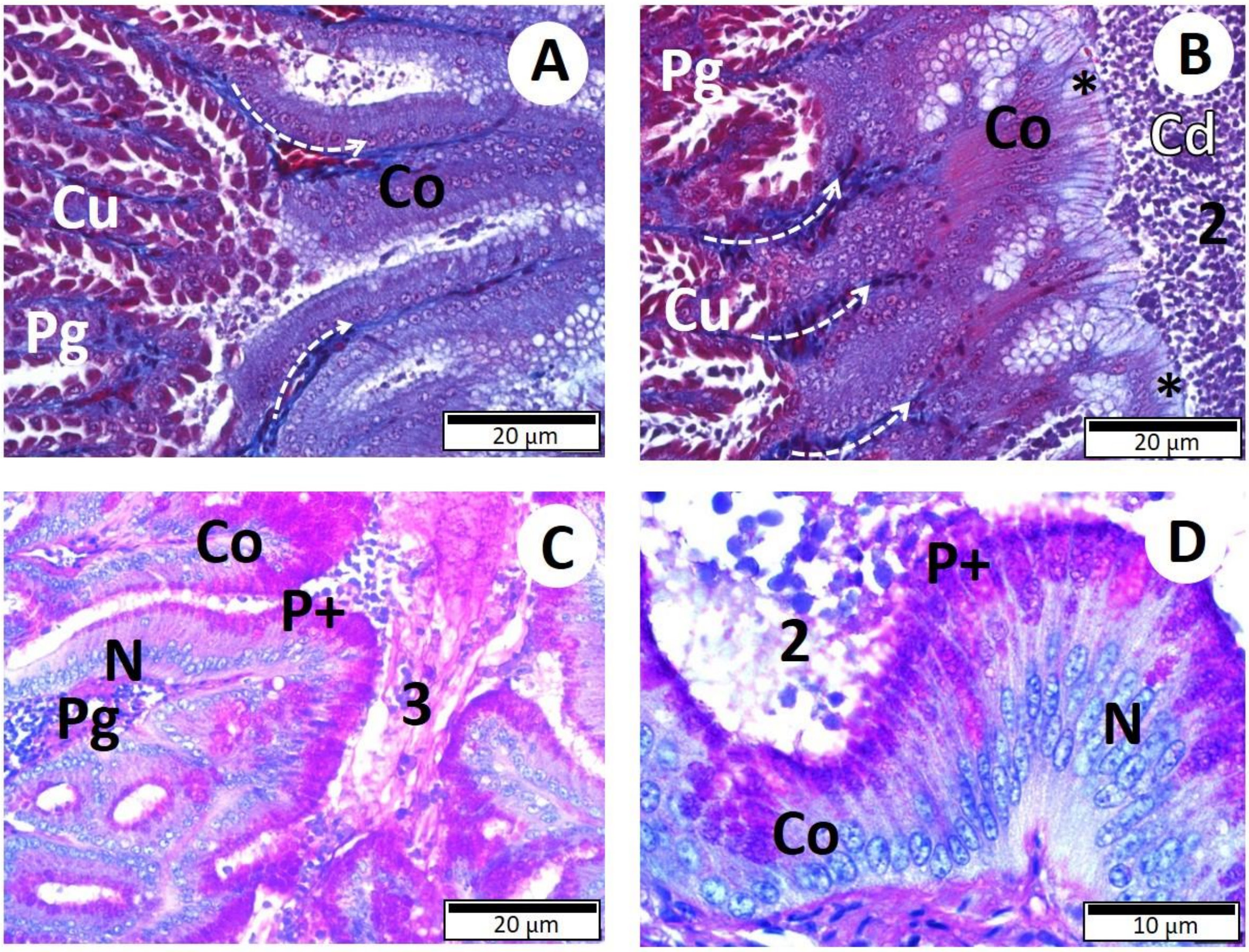

Fig. 3.7: Epithelial transition in the deep proventricular glands (section 2B in Fig. 3.1). A/B) TRI C/D) PAS. A/B) Transition from cuboidal (Cu) to columnar (Co) cells of the deep proventricular gland (Pg). Epithelium of adjacent tubules is separated by a thin layer of connective tissue (white dotted arrows). TRI negative substance (*) secreted into the secondary duct (2). Cellular debris (Cd). **C/D)** Strongly PAS positive (P+) substance secreted into the secondary (2) and tertiary ducts (3) of the deep proventricular gland (Pg).

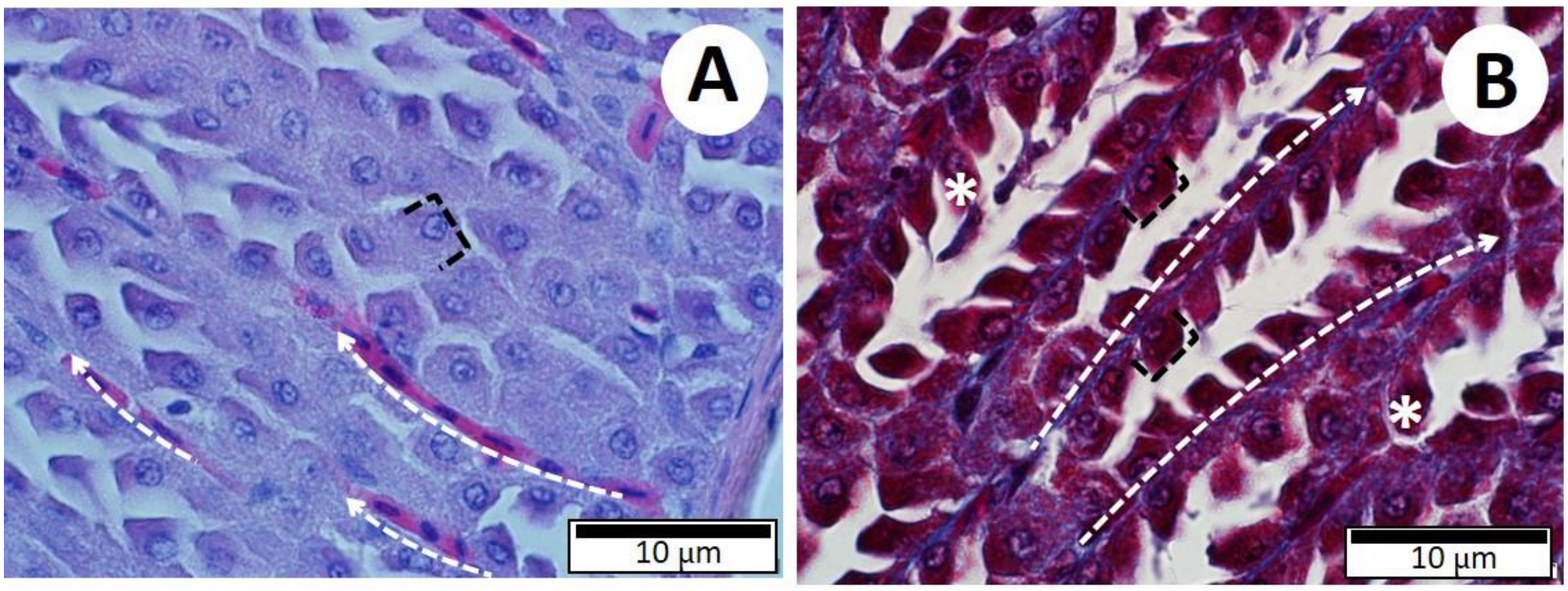

Fig. 3.8: Simple cuboidal epithelium of the deep proventricular glands (section 2B in Fig 3.1). A) H&E and B) TRI. Note the secretory cells are poorly preserved. Rows of single layer cuboidal cells (black dotted cube) separated by a thin connective tissue layer (white dotted arrows), which is well vascularized. **B)** Cytoplasm is densely packed with dark red granules (*).

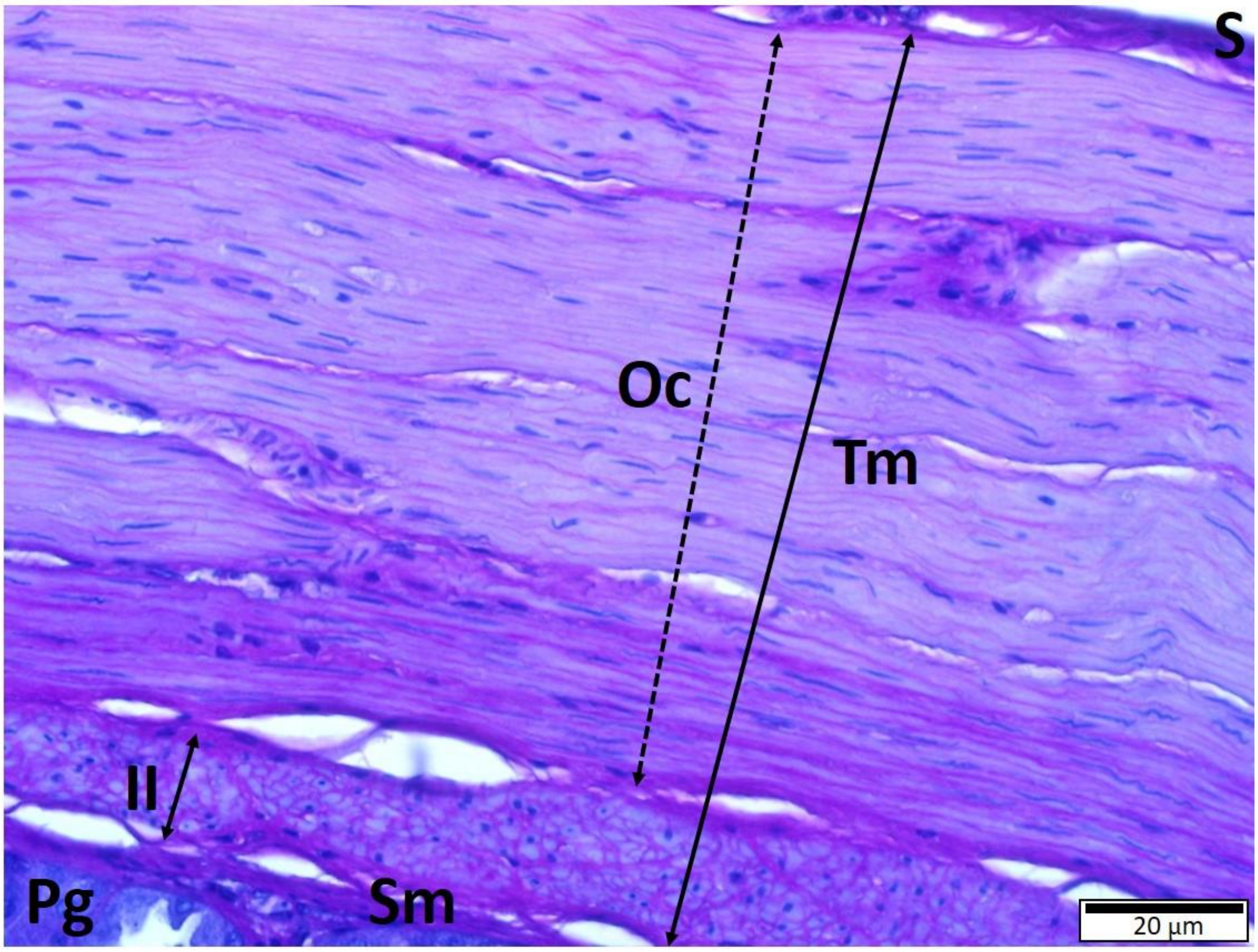

Fig. 3.9: Outer layers of the proventriculus (PAS) (transverse section 2B in Fig 3.1). The submucosa (Sm) is compressed and lies between the base of the deep proventricular glands (Pg) and the *Tunica muscularis* (Tm). The latter is composed of a thinner inner longitudinal (Il) and thicker outer circular (Oc) layer of smooth muscle. Serosa (S).

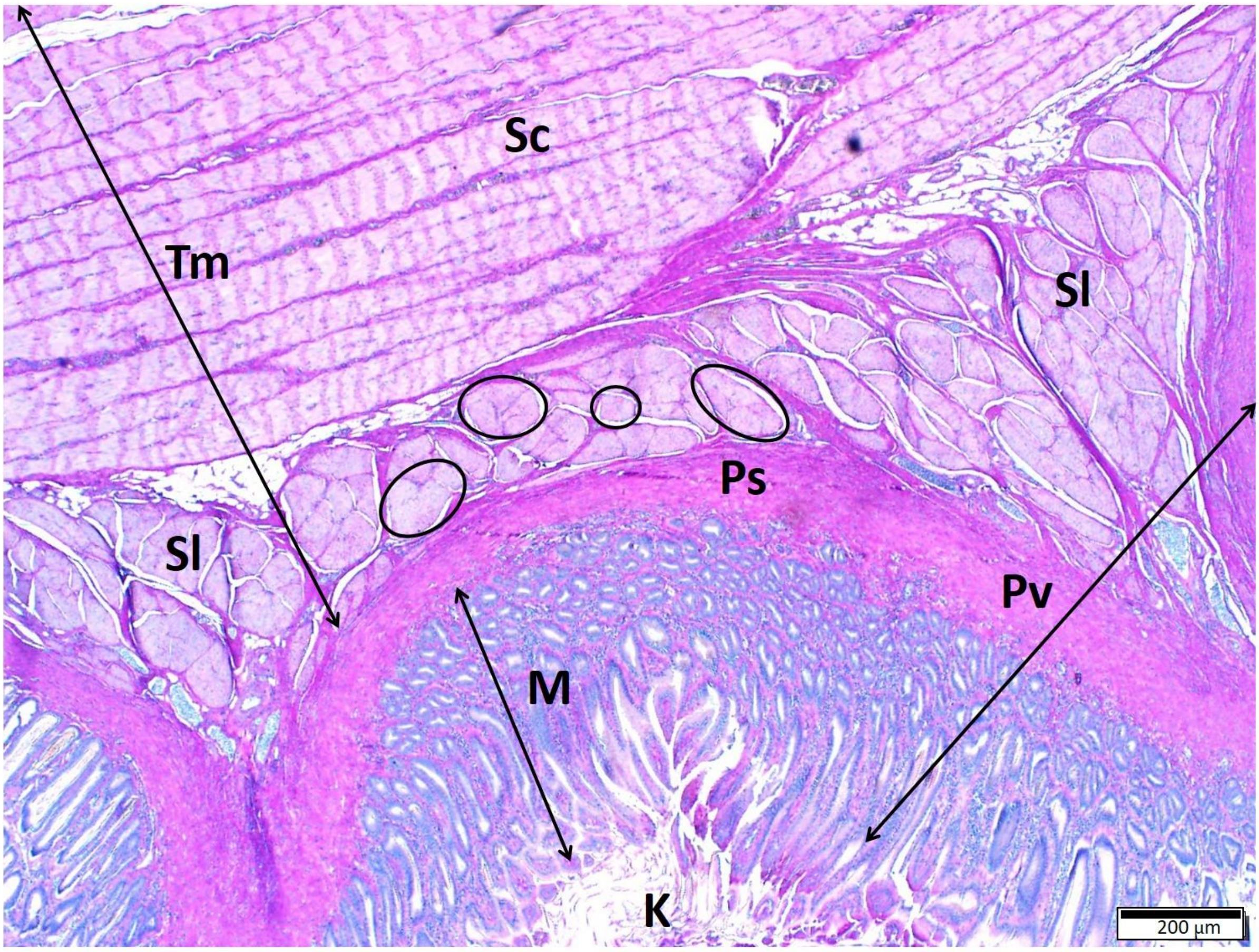

Fig 3.10: Transverse section of the ventriculus (PAS) (section 4 in Fig. 3.1). The *Mucosa* (M), propria-submucosa (Ps) and inner longitudinal layer (*Stratum longitudinale*) (Sl) of the *Tunica muscularis* (Tm) support the ventricular folds (*Plicae ventriculares*) (Pv) seen macroscopically. Koilin layer (*Cuticula gastrica*) (K) and the outer circular layer (*Stratum circulare*) (Sc) of smooth muscle. The inner longitudinal muscle layer (Sl) is arranged in well-defined bundles (black circles).

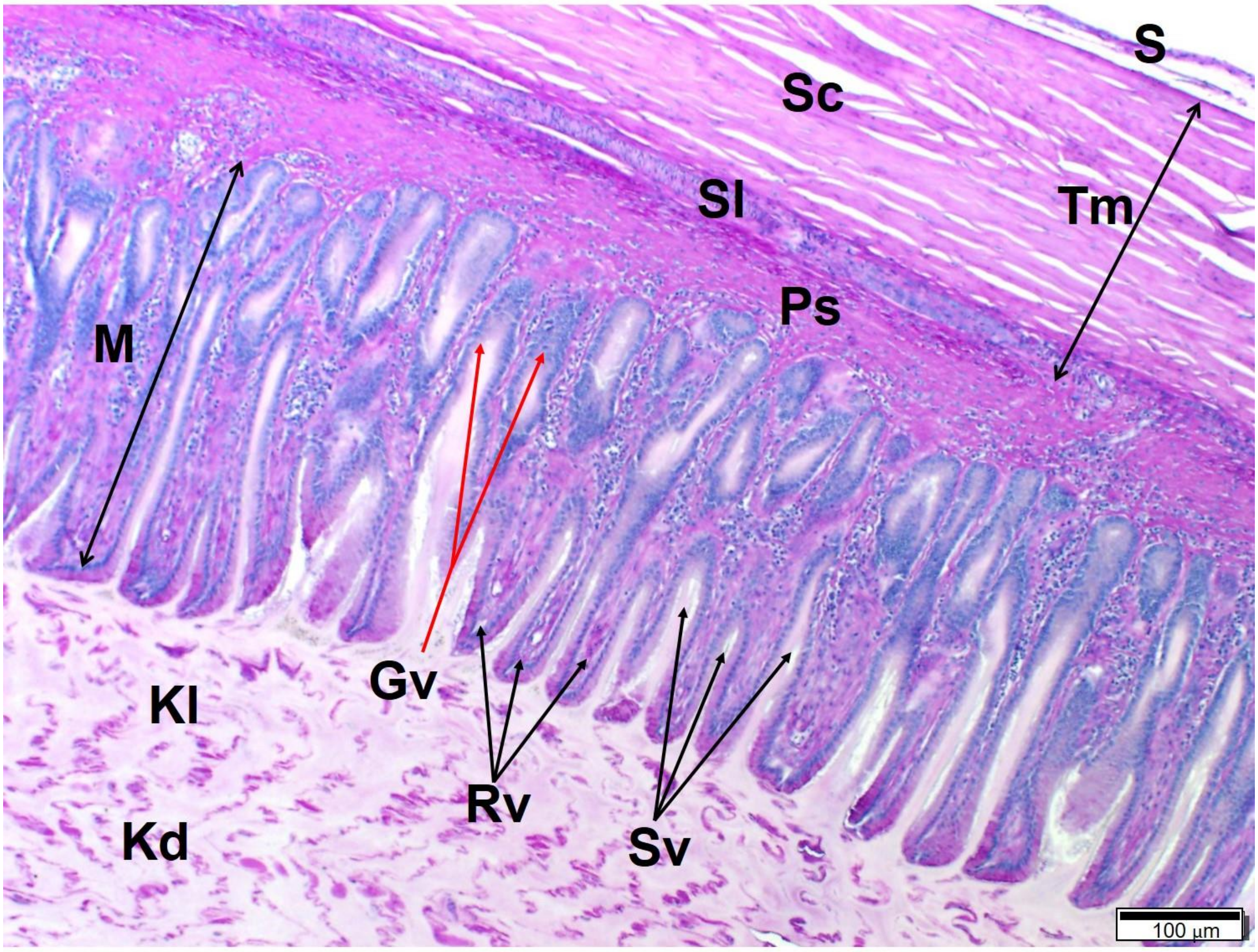

Fig. 3.11: Transverse section of the ventriculus (PAS) (section 4 in Fig. 3.1). The *mucosa* (M) is made up of *Rugae ventriculares* (Rv) and *Sulci ventriculares* (Sv), with the *Sulci ventriculares* forming the simple branched tubular glands (red arrows) (*Gll. ventriculares*) (Gv). The koilin layer (*Cuticula gastrica*) displays alternating layers of strongly PAS+ (Kd) and weakly PAS+ (Kl) staining. A prominent propria-submucosa (Ps) is present. *Tunica muscularis gastris* (Tm) consists of the thin inner longitudinal smooth muscle layer (*Stratum longitudinale*) (Sl) and the thick outer circular smooth muscle layer (*Stratum circulare*) (Sc). Serosa (S).

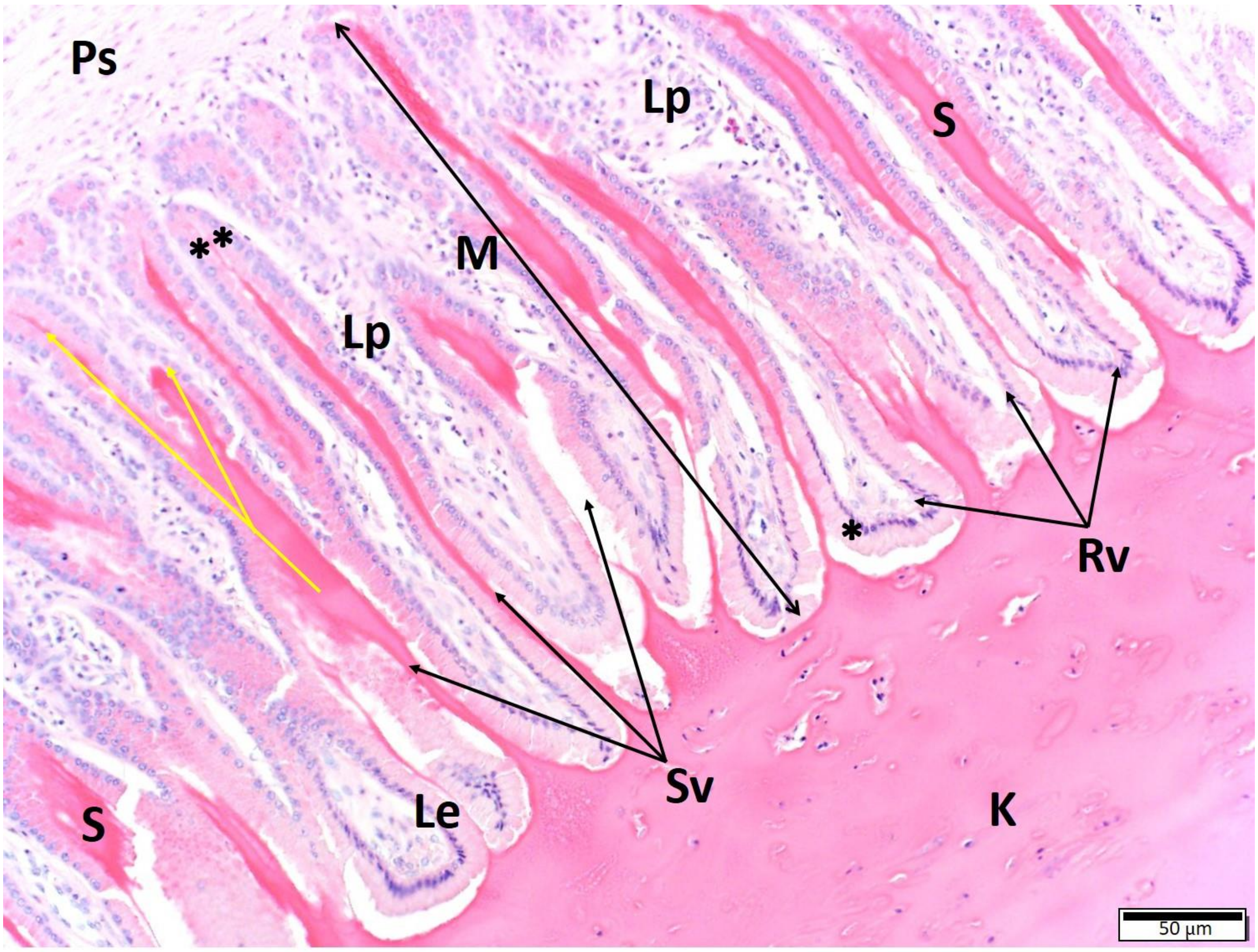

Fig. 3.12: Longitudinal section of the ventriculus (H&E) (section 5 in Fig. 3.1). *Rugae ventriculares* (Rv) lined by a tall columnar epithelium (*) with the corresponding *Sulci ventriculares* (Sv) forming the simple branched tubular glands (yellow arrows) that display a low columnar to cuboidal epithelium at the base (**), secrete (S) the intensely eosinophilic gizzard lining (*Cuticula gastrica*) or koilin (K) characteristic of the ventriculus. The interconnection between the koilin and the pit contents, even though the lining is slightly detached from the surface cells, suggests that the lining is secreted in a fluid state. *Lamina epithelialis* (Le), mucosa (M), *Lamina propria* (Lp) and propria-submucosa (Ps).

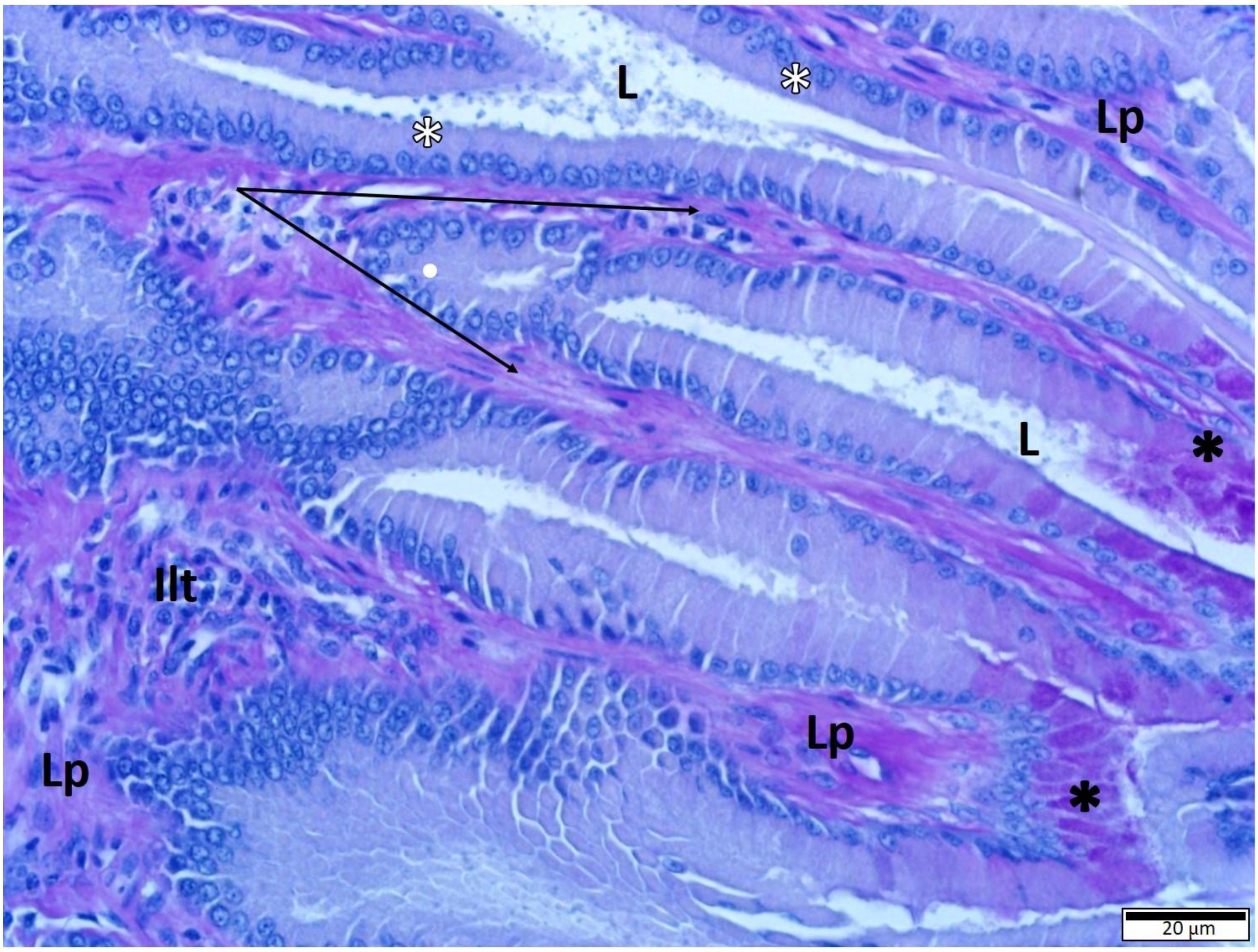

Fig. 3.13: Longitudinal section of the ventricular glands (PAS) (section 4 in Fig. 3.1). Branched tubular glands (black arrows) are separated from each other by fine strands of *Lamina propria* (Lp). The cells at the base of the glands are low columnar to cuboidal with round nuclei (white *), secreting weakly PAS positive substance. Tall columnar cells at the apical portion of the glands secreting PAS positive substance (black *). Internodular lymphoid tissue (Ilt) and gland lumen (L).

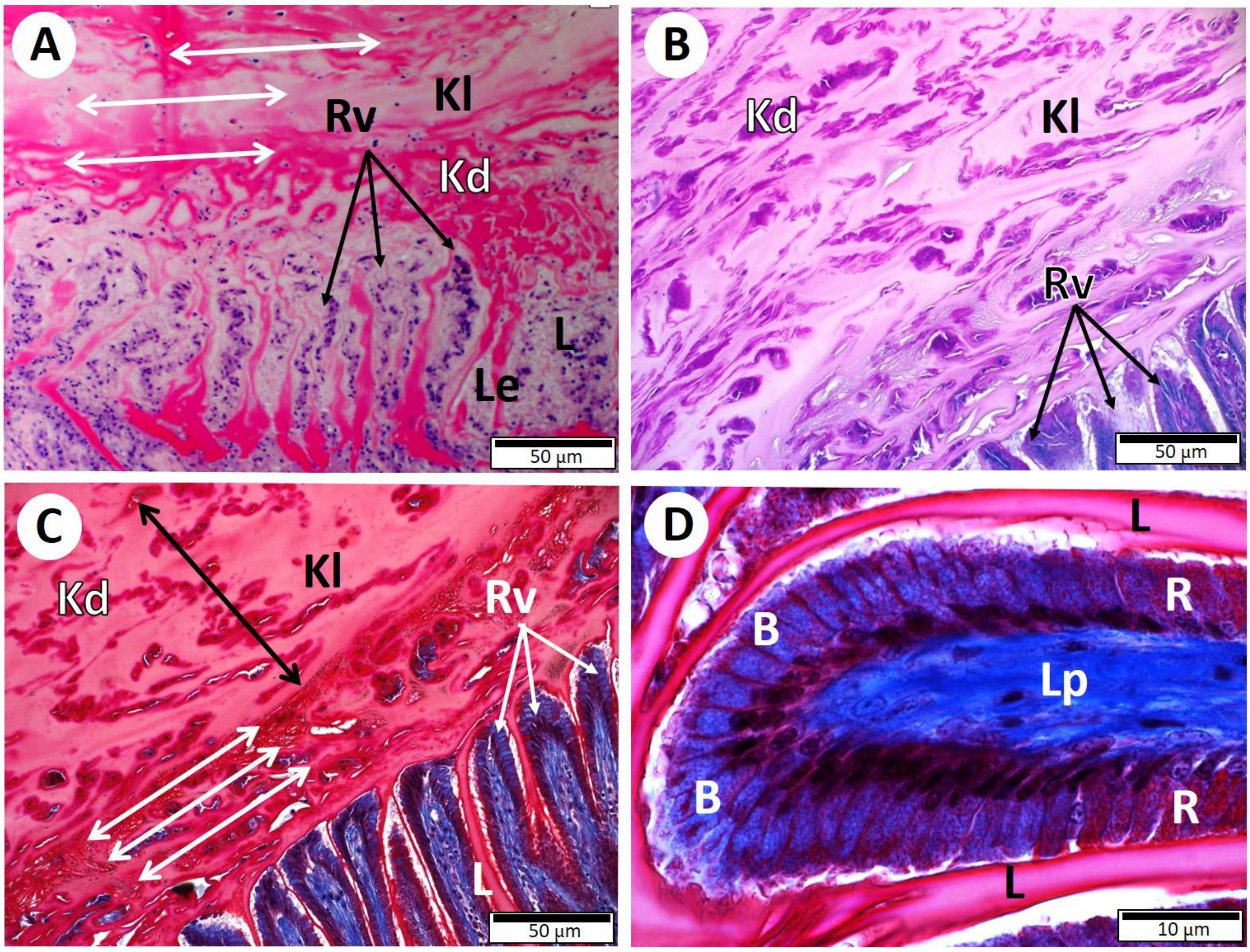

Fig. 3.14: Distal ventricular glands and koilin of the ventriculus demonstrated with A) H&E, B) PAS and C&D) TRI (section 6 from Fig. 3.1). A-C) The koilin displays alternating light (Kl) and dark (Kd) regions with all three staining techniques. Koilin is secreted in layers in the vertical plane corresponding to the horizontal plane of the glands (white arrows), seen in A and C. **D)** With TRI the cells stain dark red at the luminal portion of the gland (R) and demonstrate a blue cytoplasm (B) with no granules on the apical portion of the gland. Gland lumen (L), *Rugae ventriculares* (Rv), *Lamina epithelialis* (Le) and *Lamina propria* (Lp).

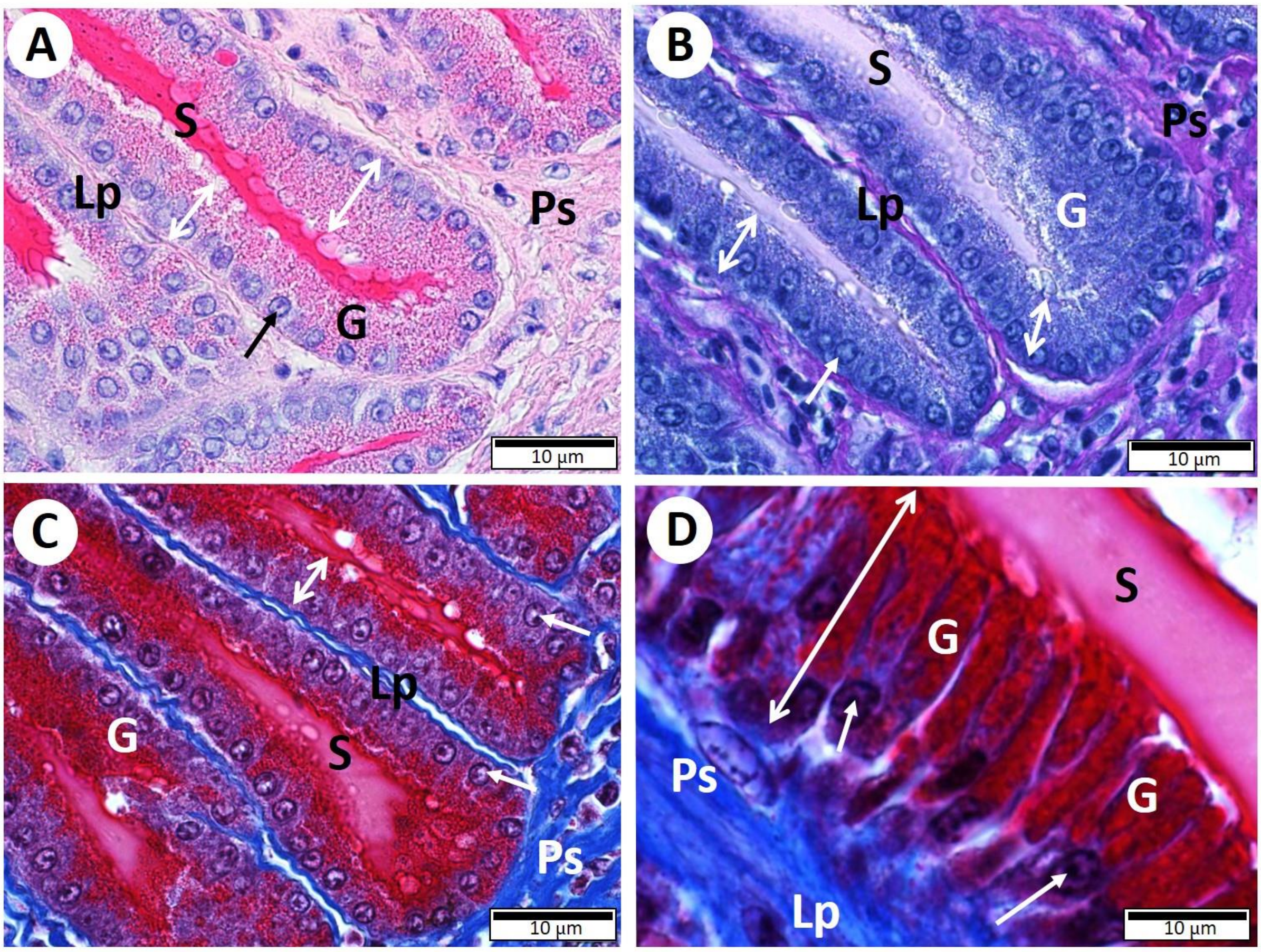

Fig. 3.15: Base of the ventricular glands demonstrated with A) H&E, B) PAS and C) TRI (section 5 from Fig. 3.1). Each gland is lined by chief cells (double headed white arrows) which secrete (koilin) the red hardened, fragmented column of translucent material (S) seen within the lumen. The *lamina propria* (Lp) and propria-submucosa (Ps) merge at the base of the ventricular glands and is composed of an irregular dense connective tissue. Granules (G) inside the apical part of the chief cells. Rounded nuclei (single arrow) **A)** A dark pink substance (S) is secreted at the base and luminal portion of the gland. **B)** Weakly PAS positive substance secreted at the base and luminal portion of the gland. **C/D)** Light red substance (S) is secreted at the base and luminal portion of the gland.

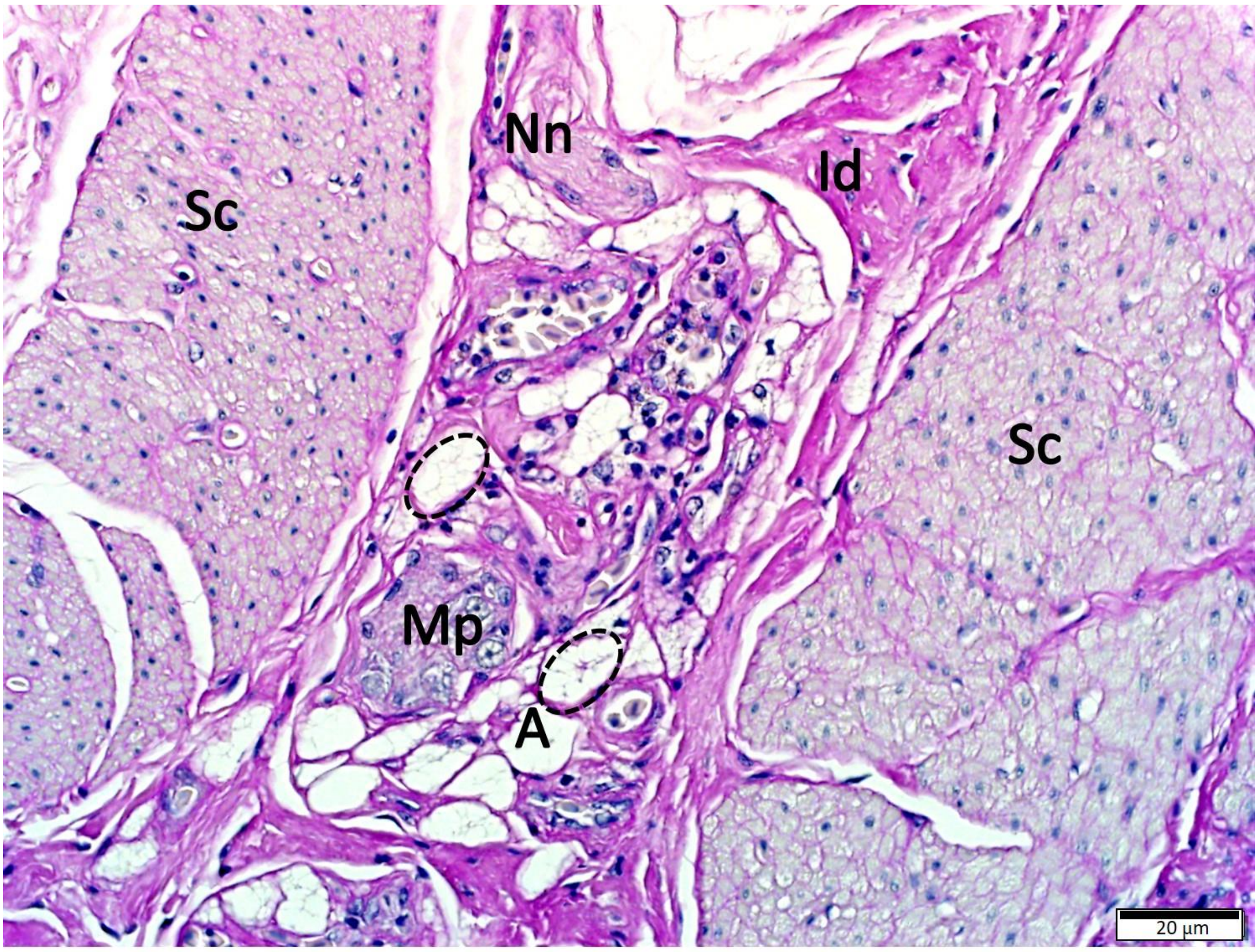

Fig. 3.16: Myentieric plexus of the ventriculus (PAS). The myenteric plexus (Mp) is composed of autonomic ganglia, non-myelinated nerves (Nn) and blood vessels (black dotted circles). The plexus is surrounded by irregular dense connective tissue (Id) situated between the bundles of smooth muscle of the *Stratum circulare* (Sc).

Fig. 3.17: Ventral view of the intestinal loops folded open towards the right. Sections for histology were sampled at the duodenal flexure (1), the jejunum (2), ileum (3) and large intestine (4).

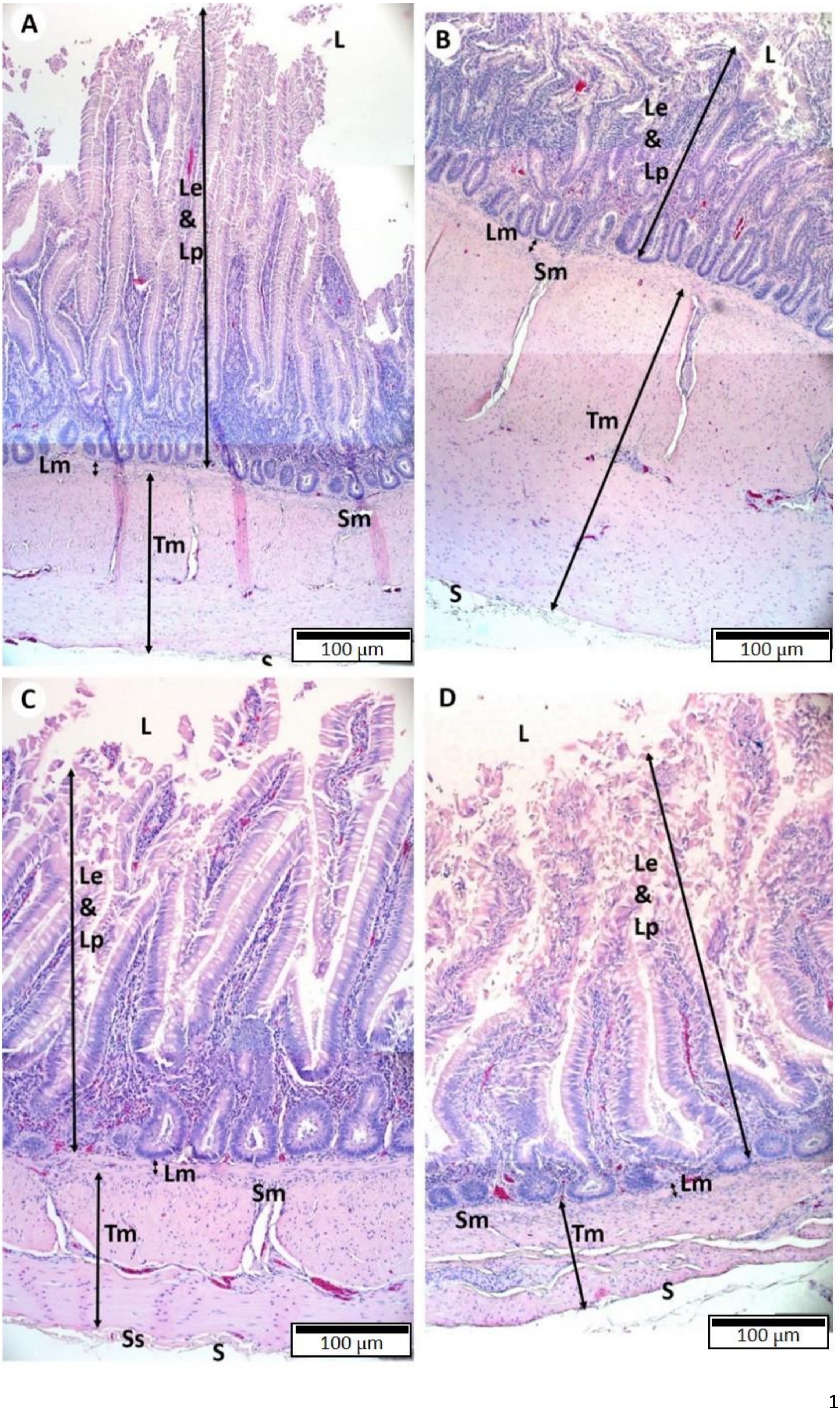
A
L
Le
&
Lp
Lm
Sm
Tm
S
100 µm
B
L
Le
&
Lp
Lm
Sm
Tm
S
100 µm
C
L
Le
&
Lp
Lm
Sm
Tm
Ss
S
100 µm
D
L
Le
&
Lp
Lm
Sm
Tm
S
100 µm

Fig. 3.18: Composite micrographs demonstrating the layers of the duodenum (Section 2 from Fig. 3.17). (A), jejunum (B), ileum (C) and rectum (D). *Lamina epithelialis* and *lamina propria* (Le & Lp), *Lamina muscularis mucosa* (Lm), Submucosa (Sm), *Tunica muscularis* (Tm), subseroa (Ss), serosa (S) and lumen (L). The villi (Le & Lp) become shorter and broader when moving from the duodenum towards the rectum.

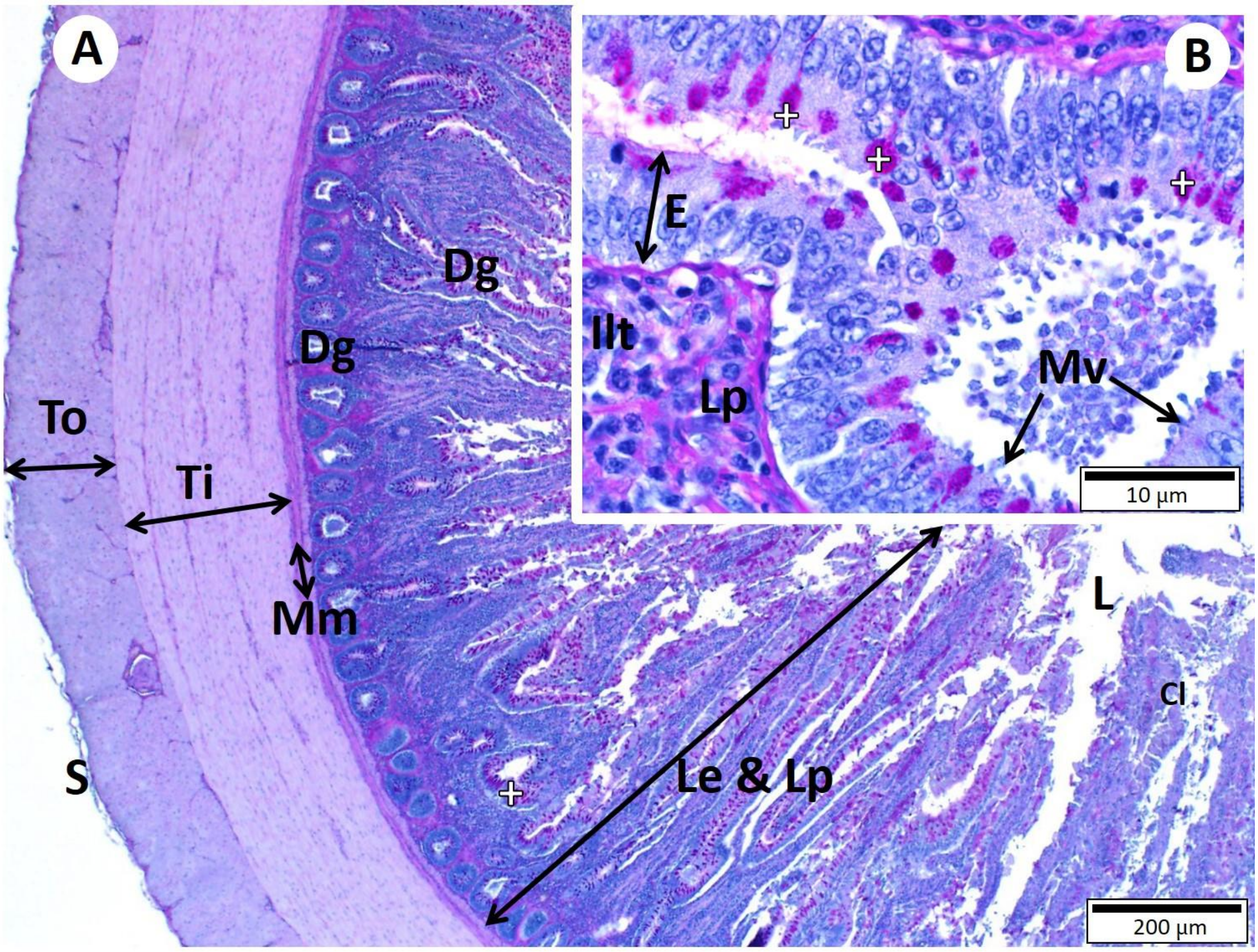

Figure 3.19: Duodenum in transverse section. (A) with an enlargement of the base of the duodenal glands (Dg) in the inset (B). (Section 2 from Fig. 3.17). PAS stain. **A).** The layers of the duodenum are easily identified: *Lamina epithelialis* and *lamina propria* (Le & Lp), *Lamina muscularis mucosa* (Mm), *Tunica muscularis* inner circular layer (Ti) and outer longitudinal layer (To) and serosa (S). Note the strong PAS positive (+) staining of the mucous in the goblet cells of the epithelium (E). **B).** The epithelium (E) is simple columnar with goblet cells filled with PAS positive (+) mucous. The epithelium has prominent microvilli (Mv) which are particularly prominent in the base of the gland. Lumen (L), the internodular lymphoid tissue (Ilt) within the *lamina propria*.

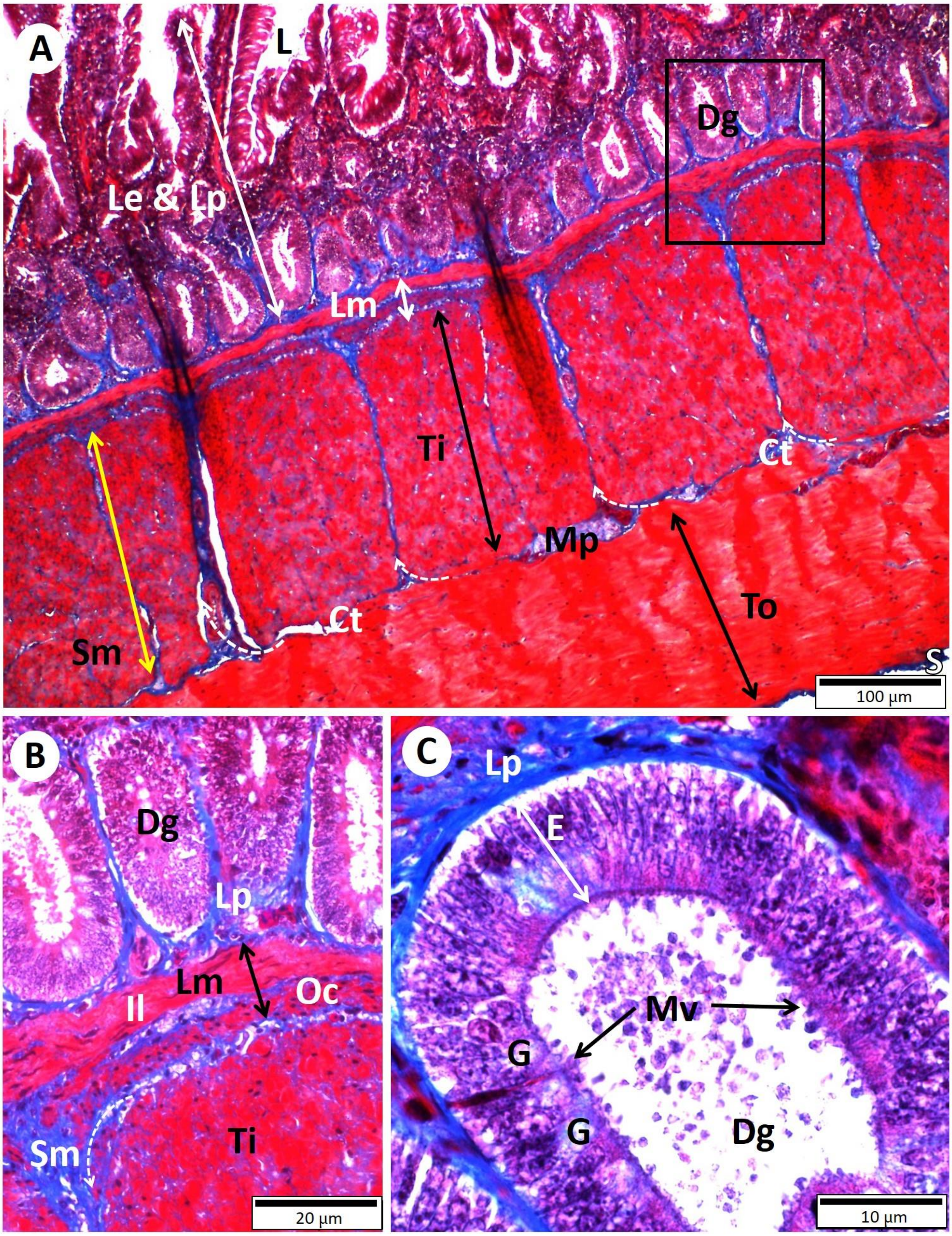
A
L
Le & Lp
Dg
Lm
Ti
Ct
Mp
Ct
To
Sm
S
100 µm
B
Dg
Lp
Lm
Oc
Il
Sm
Ti
20 µm
C
Lp
E
Mv
G
G
Dg
10 µm

Figure 3.20: Duodenum (First loop) in longitudinal section and stained with TRI. (Section 2 from Fig. 3.17). A.) The layers of the duodenum are easily identified with TRI: *Lamina epithelialis* and *lamina propria* (Le & Lp), *Lamina muscularis mucosa* (Lm), submucosa (Sm), *Tunica muscularis* inner circular layer (Ti) and outer longitudinal layer (To) and serosa (S). The inner circular layer is seen in transverse section and the blue staining connective tissue of the submucosa (Sm) (Yellow double sided arrow) is seen to divide this layer into blocks (White dotted arrows). Lumen (L) and myenteric plexus (Mp). **B.)** Enlargement of the square in A. The base of the duodenal glands (Dg) are surrounded by *Lamina propria* (Lp). The *Lamina muscularis mucosa* (Lm) is clearly divided into an inner longitudinal (Il) layer and outer circular (Oc) layer, separated by a thin layer of connective tissue (Ct). **C)**. Enlargement of the base of the duodenal gland (Dg). Microvilli (Mv).

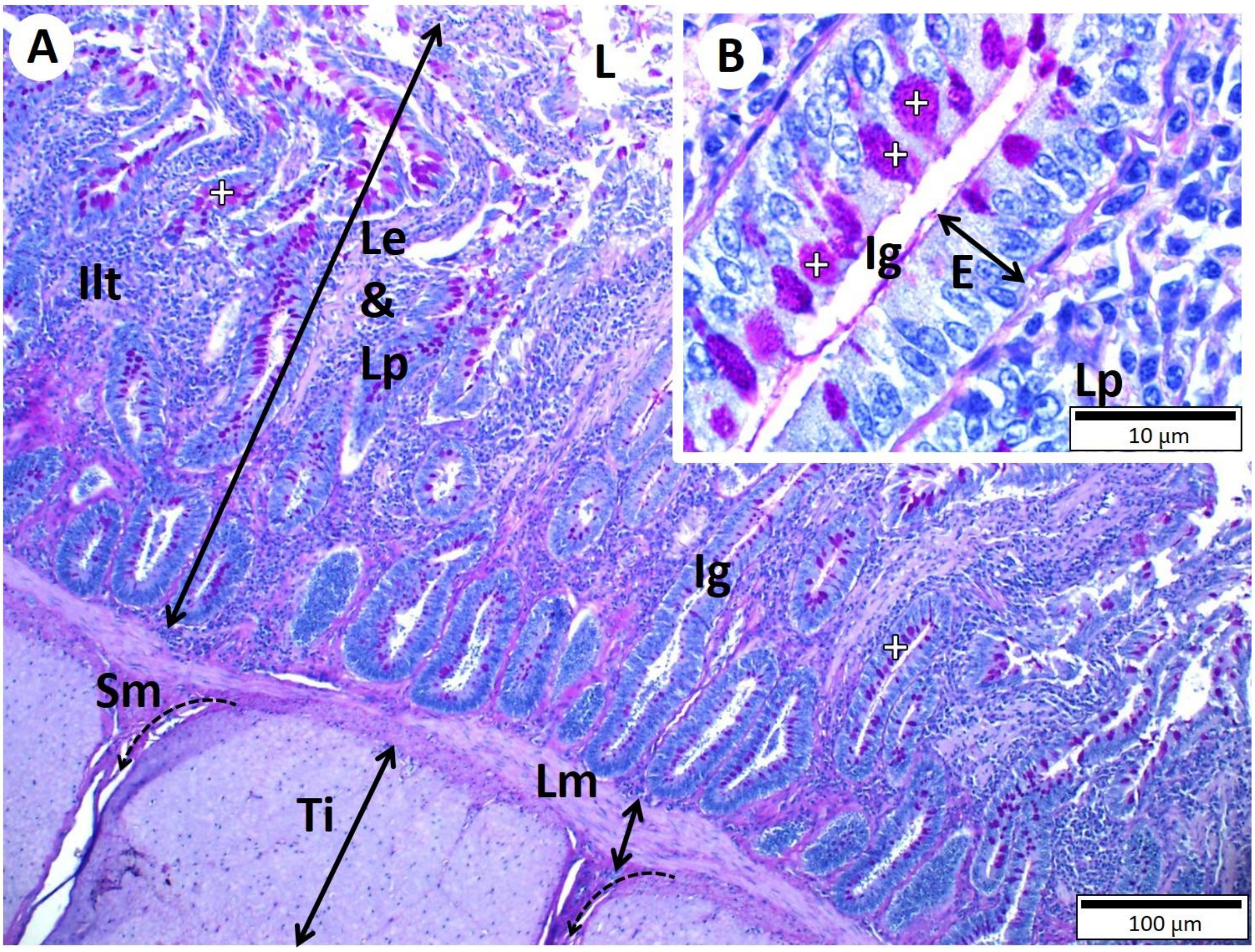

Figure 3.21: **Jejunum of the second loop in longitudinal section. (Section 3 from Fig. 3.18.) PAS stain. A).** The layers of the jejunum are easily identified with PAS: *Lamina epithelialis* and *Lamina propria* (Le & Lp), *Lamina muscularis mucosa* (Lm), submucosa (Sm, black dotted arrow) and *Tunica muscularis* inner circular layer (Ti). Note the strong PAS positive (+) staining of the mucous in the goblet cells of the epithelium lining the intestinal glands (Ig). The *Lamina propria* is infiltrated with internodular lymphoid tissue (Ilt). **B).** The simple ciliated columnar epithelium (E) lining the intestinal gland with goblet cells filled with PAS positive (+) mucous.

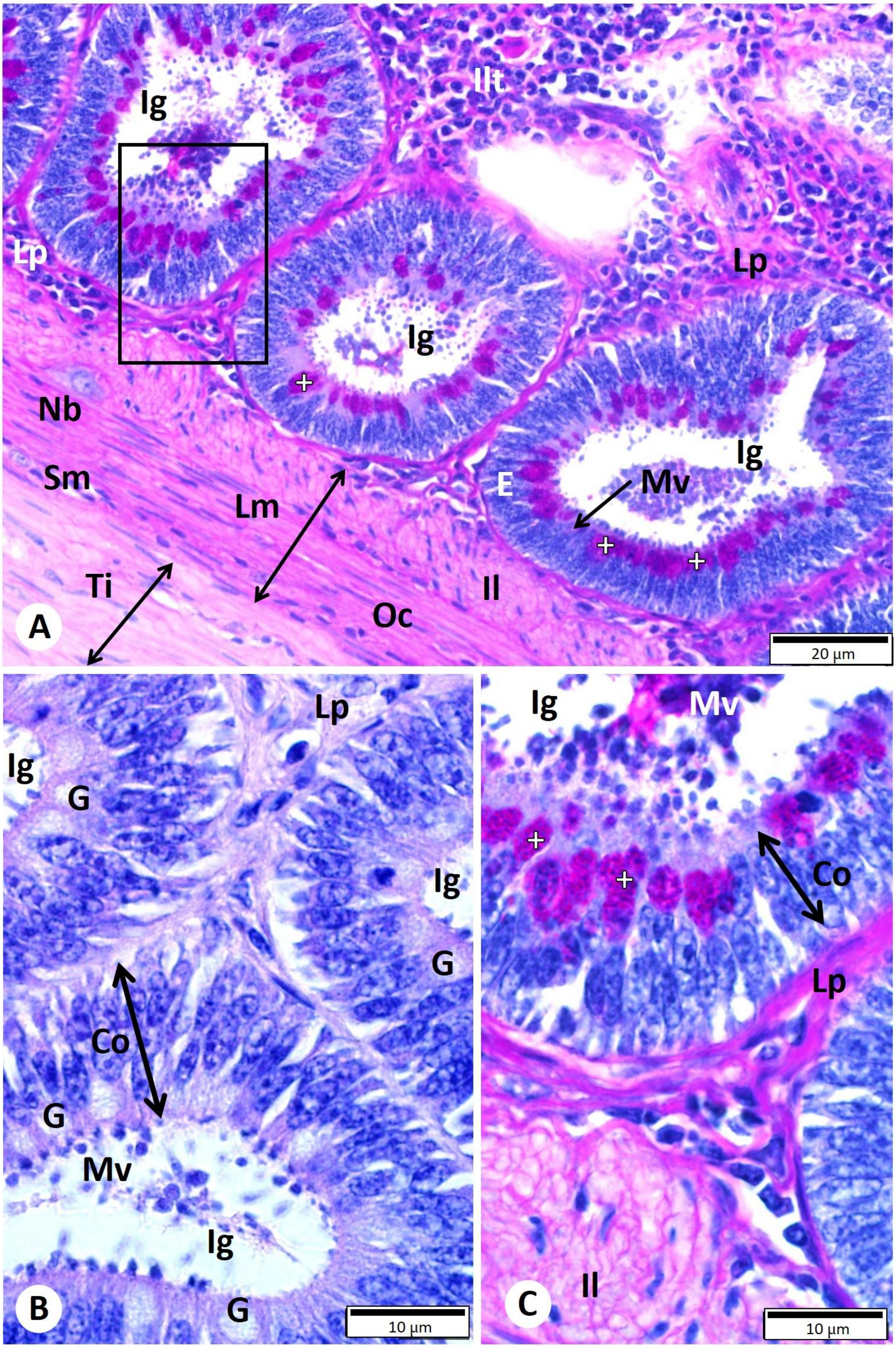
Ig
Ilt
Lp
Lp
Ig
Nb
Sm
Lm
+
Mv
Ig
E
+
+
Ti
Il
Oc
A
20 µm
Lp
Ig
G
Ig
G
Co
G
Mv
Ig
B
G
10 µm
Ig
Mv
+
+
Co
Lp
Il
C
10 µm

Figure 3.22: **Jejunum of the second loop in transverse section. (Section 3 from Fig. 3.18.) PAS stain (A and C) and H&E (B). A).** The intestinal gland (Ig), lined by simple columnar epithelium (Co) are adorned with microvilli (Mv) and goblet cells with PAS positive (+) staining mucous are abundant. The *Lamina muscularis mucosa* (Lm) is well-developed and consists of the inner longitudinal (Il) and outer circular (Oc) layers. The submucosa (Sm) is extremely compressed. Internodular lymphoid tissue infiltrates the *Lamina propria* (Lp). Nerve cell body of an autonomic ganglion (Nb) and Inner circular (Ti) layer of the Tunica muscularis. **B).** Base of the intestinal gland (Ig) showing the simple ciliated columnar epithelium (E) interspersed with goblet cells (G) and adorned by microvilli (Mv). **C).** Enlargement of the square in A. The simple columnar epithelium (E) lining the intestinal gland with goblet cells filled with PAS positive (+) mucous. *Lamina propria* (Lp) and the inner longitudinal layer (Il).

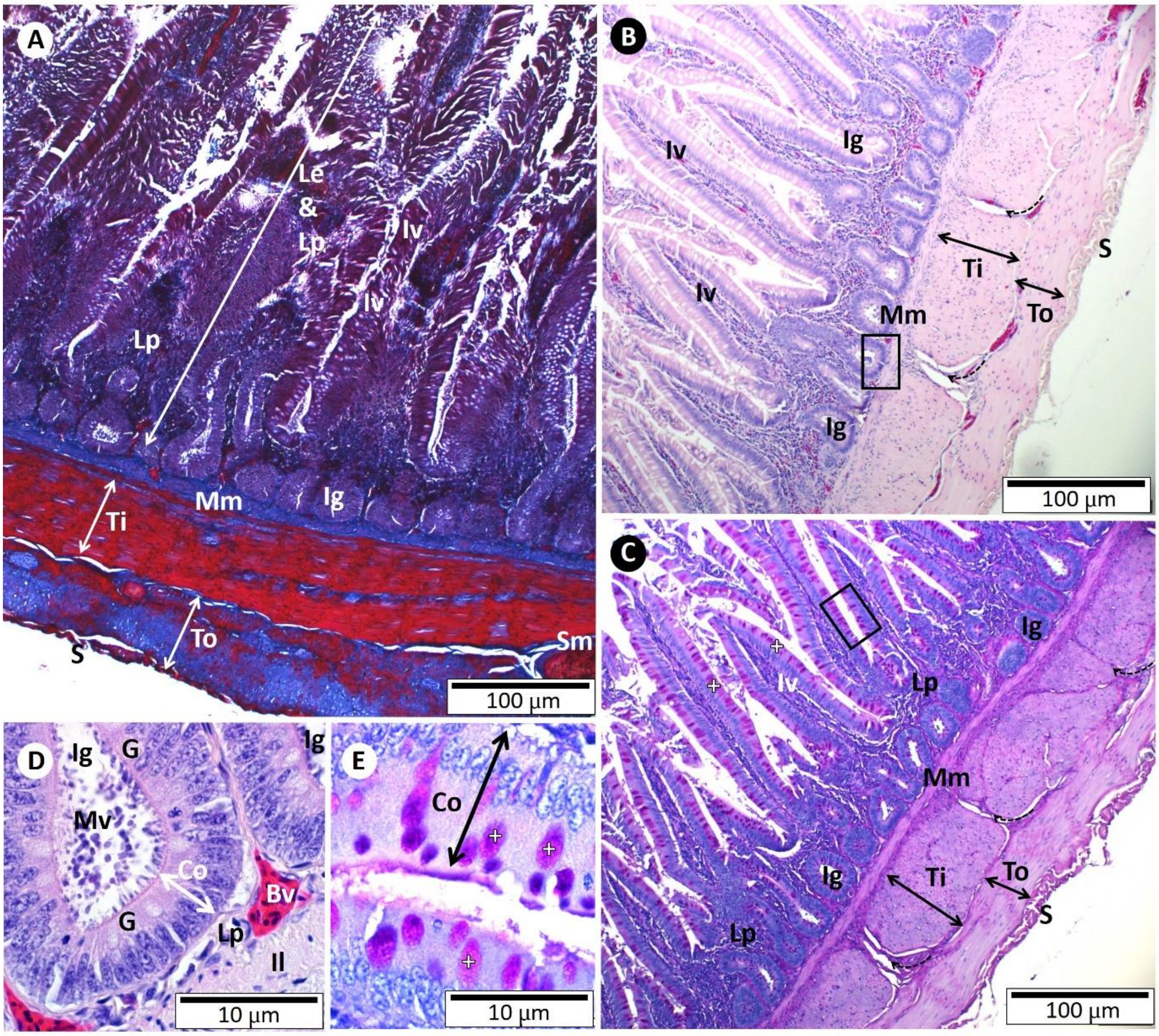

Figure 3.23: **Ileum of the third loop in transverse (A) and longitudinal (B,C) section. (Section 3 from Fig. 3.18.) TRI stain (A), H&E (B and D) and PAS stain (C and E). A-C).** The layers of the ileum are the *Lamina epithelialis* and *Lamina propria* (Le & Lp) forming the intestinal villi (Iv), *Lamina muscularis mucosa* (Lm), submucosa (Sm), *Tunica muscularis* inner circular layer (Ti) and outer longitudinal layer (To). **D).** Enlargement of the square in B. The base of the intestinal glands (Ig), lined by simple columnar epithelium (Co) are adorned with microvilli (Mv) and goblet cells don’t stain with H&E. Blood vessels (Bv) seen within the *Lamina propria* (Lp) **E).** Enlargement of the square in C. Note the strong PAS positive (+) staining of the mucous in the goblet cells of the epithelium lining the intestinal glands.

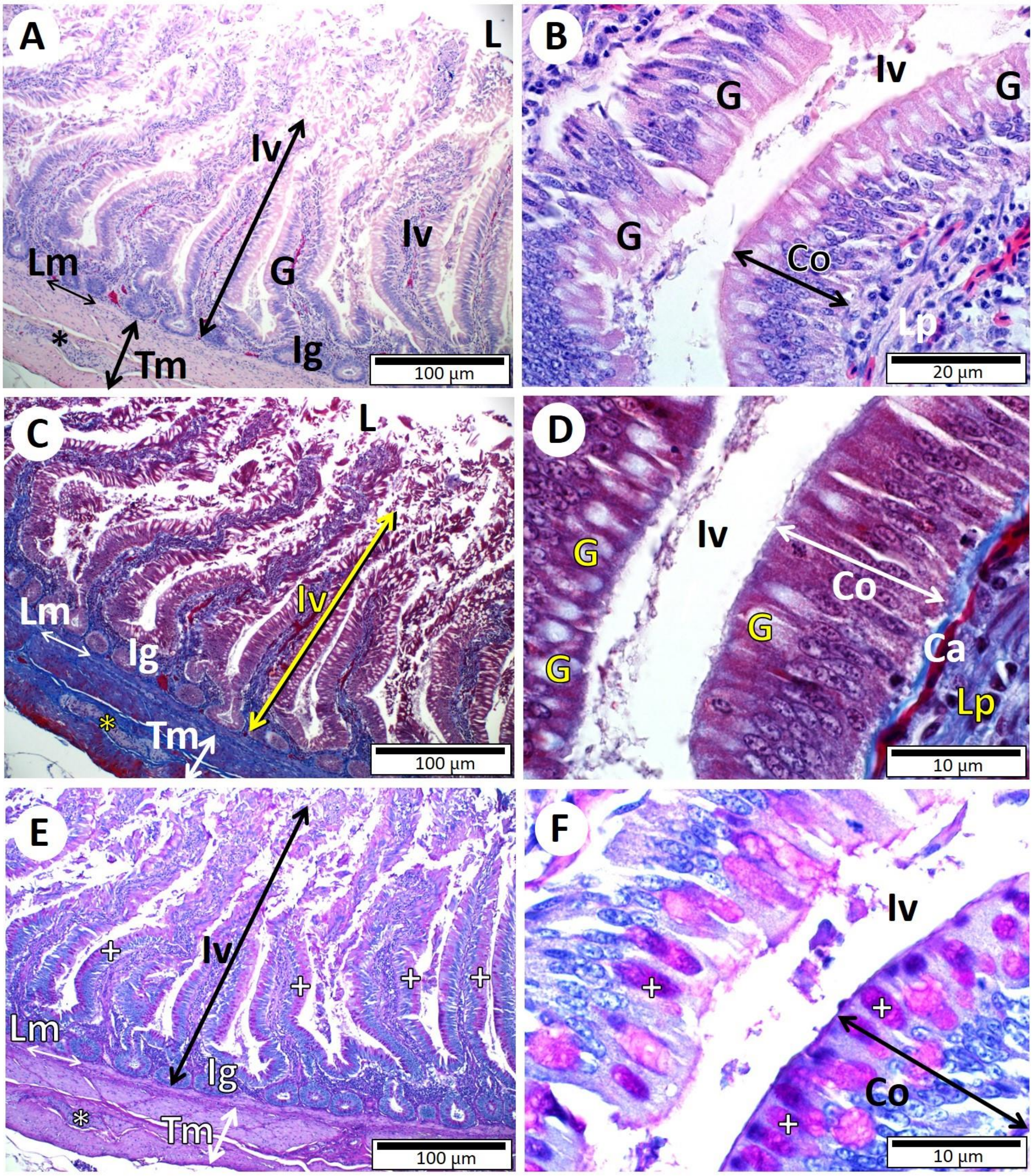

Fig: 3.24: Rectum in longitudinal section. (Section 4 from Fig. 3.18.) H&E stain (A and B), TRI stain (C and D) and PAS stain (E and F). A,C,E). The layers of the rectum are easily identified: *Lamina epithelialis* and *Lamina propria* (Le & Lp) forming the intestinal villi (Iv), *Lamina muscularis mucosa* (Mm), submucosa (*) and *Tunica muscularis* (Tm). **B,D,F).** Intestinal glands (Ig), lined by simple columnar epithelium (E) and goblet cells (G) don’t stain with H&E (B) or TRI (D), and stain PAS positive with PAS (F). Large capillary present in the *lamina propria* (Lp).

CHAPTER 4

General conclusions

4.1 General

The anatomy and histology of the Southern Ground-Hornbill (*Bucorvus leadbeateri*) (SGH) gastrointestinal tract has not been documented prior to this study. It has been the assumption that the morphology resembles that of other carnivorous avian species. The herbivorous chicken has also been used as a standard reference for avian species and inevitably some major differences exist. Although comparisons and assumptions based on other species morphology is sometimes valid, some important characteristics which are of clinical significance were noted. They are elaborated below.

It is important to note that a time lapse existed between death and post-mortem examination as most carcasses needed to be transported from the location of death to Onderstepoort. Some carcasses were also frozen prior to transport and this negatively affected the quality of the histological samples. Some variation may exist between normal and abnormal findings due to pathology as most samples died due to unknown causes.

4.2 Anatomy

The gastrointestinal tract of the SGH was composed of a glandular proventriculus, non-glandular ventriculus, the intestine consisting of five loops and the rectum. The intestinal tract was simple and short, as expected for a carnivorous avian species. The *Tunica muscularis* of the ventriculus was thin, relatively poorly muscled and lacked the apposing pairs of thick and thin muscles that are responsible for the contractions that grind the food in granivorous birds. Objects such as rocks, that assist in grinding, were absent in the SGH ventriculus. The cuticle, which is produced by mucosal glands of the ventriculus, functioned primarily to protect the mucosa from the strong digestive enzymes produced by the proventriculus. The ventriculus was highly distensible and demonstrated the capacity to accommodate whole, and sometimes large, prey. The functions of cecae in birds include include water absorption, non-protein nitrogen absorption, digestion of carbohydrates and protein, microbial decomposition of cellulose, microbial synthesis and absorption of vitamins. The absence of cecae in the SGH would indicate that the latter functions take place elsewhere in the intestinal tract. Pancreas size is reported to be smaller in carnivores, and is possibly related to the high digestibility of the diet. Despite the latter, the SGH pancreas consisted of three lobes, with three pancreatic ducts. The pancreas extends to approximately the midpoint of the *Ansa duodenalis*. The liver was relatively larger than expected for a carnivorous species. A larger liver for the SGH supports its high metabolic rate, protein, acid and bile salt synthesis, and excretion and detoxification processes necessary for a carnivorous diet.

4.3 Histology

The deep proventricular glands of the SGH are seen macroscopically and are concentrated on the ventral surface of the proventriculus, with a small gland-free zone on the dorsal inner surface. Similar to the gland-free zones noted in flower-seeking parrots, these zones function to make the organ more distensible. In the SGH this may aid in allowing, large, whole prey items to pass through the proventriculus into the ventriculus. The koilin layer of the ventriculus is soft and uniformly distributed, thus supporting the function of chemical digestion over grinding.

The intestinal *Lamina muscularis mucosae* is more well-developed and compartmentalised in the small intestine than in the rectum. The goblet cells also become more numerous from the duodenum to the rectum. The decreased length of the intestinal villi, less well-developed musculature towards the rectum and an increased amount of goblet cells towards the rectum support a more finely controlled motility in the small intestine, and increased lubrication towards the rectum. Most water and nutrients are absorbed in the small intestine and more lubrication may be required for expulsion of more solid digesta as it passes along the rectum. Stress induces gastric ulcers, slows gastric emptying and ion exchange, causes colonic mucin depletion, and increases intestinal permeability leading to the passage of antigens to the *Lamina propria* and bacterial translocation. Bacterial infiltrations, due to GIT stasis, is life threatening in the SGH and possible preventions should be considered. Stress is a major contributing factor to mortality when considering the hospitalization of the SGH. The GIT of the SGH is highly adapted for complete and rapid digestion. Thus GIT motility is a major factor and is crucial to considering stress or any disease process that leads to GIT stasis. The latter, together with colonic mucin depletion, are likely to be life-threatening conditions in the SGH.

REFERENCES

ABUMANDOUR, M.M.A., 2014. Histomorphological studies on the stomach of Eurasian Hobby (Falconinae: *Falco subbuteo*, Linnaeus 1758) and its relation with its feeding habits. *Journal of life science*, 11(7), pp.809–819.

AKESTER, A.R., 1986. Structure of the glandular layer and koilin membrane in the gizzard of the adult domestic fowl (*Gallus gallus domesticus*). *Journal of anatomy*, 147, p.1.

AL-AARAJI, A., 2015. Study of some anatomical and histological characteristics in liver og male indigenous turkey (*Meleagris gallopava*). *Department of Anatomy and Histology ,College of Veterinary Medicine, University Baghdad,* pp.150–155.

AL-HAMADAWI, H.A., ALNAALY, A.J., ALUMERI, J.K. AND AL-BIDERI, A.W., 2009. Comparative anatomical and histological study of the liver in three species of wild birds in Iraq. *Journal of global pharma technology*, 10, pp.387–394.

AL-SAFFAR, F.J. AND EYHAB, R.M., 2016. Histomorphological and histochemical studies of the stomach of the Mallard (*Anas platyrhynchos*). *Iraqi journal of veterinary medicine*. Baghdad University, 40(1), pp.89–96.

AL-SAMARAE, N.S., THAYER, A. AND SWAD, A.A., 1999. Topographical and histological study of the pancreas of the moorhen (*Gallinula c.choropus*). *The Veterinarian*, 9, pp.1–7.

AL-TAEE, A. A., 2017. Macroscopic and microscopic study of digestive tract of Brown falcon (*Falco berigora*) in Iraq. *Journal of University of Babylon*, 3(25), pp.915–936.

AL-SAFFAR, F.J. and , AL-SAMAWY, E.R.M., 2015. Histomorphological and histochemical studies of the stomach of the Mallard (*Anas platyrhynchos*). *Asian journal of animal science*, 9(6), pp.280-292.

ANKNEY, C.D., 1977. Feeding and digestive organ size in breeding Lesser Snow Geese. *The Auk*. Oxford University Press, 94(2), pp.275–282.

BAILEY, T.A., MENSAH-BROWN, E.P., SAMOUR, J.H., NALDO, J., LAWRENCE, P. AND GARNER, A., 1997. Comparative morphology of the alimentary tract and its glandular derivatives of captive bustards. *Journal of anatomy*, 191 (3), pp.387–398.

BANCROFT, J.D. AND GAMBLE, M., 2002. *Theory and practice of histological techniques*. Elsevier health science.

BARTLETT, A.D., 1869. Remarks upon the Habits of the Hornbills (*Buceros*). in *Proceedings of the zoological society of London,* 37(1), pp.142-146.

BATAH, A.L. AND SELMAN, H.A., 2012. Histological study for stomach (proventriculus and gizzard) of coot bird (*Fulica atra*). *Diyala journal of agricultural sciences*, 4(1), pp.9–16.

BAUMEL, J.J., 1993. Handbook of avian anatomy: nomina anatomica avium. *Publications of the nuttall ornithological club (USA), no. 23.*

BEHEIRY, R., 2018. Some histological and scanning electron microscopic studies on the gizzard of turkey. *Alexandria journal of veterinary sciences*, 59, pp. 37–43.

BEZUIDENHOUT, A.J. AND VAN ASWEGEN, G., 1990. A light microscopic and immunocytochemical study of the gastro-intestinal tract of the ostrich (*Struthio camelus L*.). *Onderstepoort journal of veterinary research*, 58, pp.37-48.

BHATIA, V. AND TANDON, R.K., 2005. Stress and the gastrointestinal tract. *Journal of gastroenterology and hepatology*, 20(3), pp. 332–339.

BirdLife International, 2016. Bucorvus leadbeateri, *The IUCN Red List of Threatened*

Species. Available at: https://www.iucnredlist.org/species/22682638/92955067.

BRADLEY, O.C. AND GRAHAME, T., 1960. *The structure of the fowl.* Edinburgh (& London): Oliver & Boyd. 4th Edit.

BRUYNS, R.K., WILLIAMS, V.L. AND CUNNINGHAM, A.B., 2013. Finely Ground-Hornbill: the sale of *Bucorvus cafer* in a traditional medicine market in Bulawayo, Zimbabwe. in *Animals in traditional folk medicine*, pp. 475–486.

BUTLER, J. AND DU TOIT, J., 2002. Diet of free-ranging domestic dogs (*Canis familiaris*) in rural Zimbabwe: Implications for wild scavengers on the periphery of wildlife reserves. *Animal conservation*, 5, pp. 29–37.

CALHOUN, M.L., 1954. *Microscopic anatomy of the digestive system of the chicken*. Ames: Iowa State college press.

CARSTENS, K.F., KASSANJEE, R., LITTLE, R.M., RYAN, P.G. AND HOCKEY, P.A., 2019. Breeding success and population growth of Southern Ground Hornbills (*Bucorvus leadbeateri*) in an area supplemented with nest-boxes. *Bird conservation international*, 29(4), pp.627–643.

CASO, J.R., LEZA, J.C. AND MENCHEN, L., 2008. The effects of physical and psychological stress on the gastrointestinaltract: Lessons from animal models. *Current molecular medicine*, pp.299–312.

CATROXO, M.H.B., LIMA, M.A.I. AND CAPPELLARO, C., 1997. Histological aspects of the stomach (Proventriculus and gizzard) of the red-capped cardinal (*Paroaria gularis gularis*, Linnaeus, 1766). *Revista chilena de anatomía*, 15(1), pp.19–27.

CEBALLOS, G., EHRLICH, P.R. AND DIRZO, R., 2017. Biological annihilation via the ongoing sixth mass extinction signaled by vertebrate population losses and declines. *Proceedings of the national academy of sciences*, 114(30), pp.E6089–E6096.

CHIKILIAN, M. AND DE SPERONI, N.B., 1996. Comparative study of the digestive system of three species of tinamou. I. *Crypturellus tataupa, Nothoprocta cinerascens*, and *Nothura maculosa* (Aves: tinamidae). *Journal of morphology*, 228(1), pp.77–88.

CHODNIK, K.S., 1947. A Cytological study of the alimentary tract of the domestic fowl (*Gallus Domesticus*). *Journal of cell science*, 3(4), pp.419–443.

CHODNIK, K.S., 1948. Cytology of the glands associated with the alimentary tract of domestic fowl (*Gallus domesticus*). *Quarterly journal of microscopical science*, 3(5), pp.75–87.

CLENCH, M.H. AND MATHIAS, J.R., 1995. The avian cecum: a review. *The wilson bulletin*, pp.93–121.

COETZEE, H., NELL, W. AND VAN RENSBURG, L., 2014. An exploration of cultural beliefs and practices across the Southern Ground-Hornbill's range in Africa. *Journal of ethnobiology and ethnomedicine*, 10(1), pp. 1–7.

COMBRINK, L., COMBRINK, H.J., BOTHA, A.J. AND DOWNS, C.T., 2017. Habitat structure and diversity influence the nesting success of an endangered large cavity-nesting bird, the Southern Ground-hornbill. *Koedoe,* 59(1), pp.1-8.

COOPER, M. AND JORDAN, L., 2013. Random time-activity budgets in captive Southern Ground Hornbill (*Bucorvus leadbeateri*). *South African Journal of Science*, 109(7-8), pp.1-2.

CUNNINGHAM, J.G. AND KLEIN, B.G., 2007. Veterinary physiology. *Philadelphia: Saunders Elsevier*, pp.347-447.

DAVIES, R.R., 2000). Avian liver disease: Etiology and pathogenesis. *Seminars in avian and exotic pet medicine*, 9(3), pp.115–125.

DEGOLIER, T.F., MAHONEY, S.A. AND DUKE, G.E., 1999. Relationships of avian cecal lengths to food habits, taxonomic position, and intestinal lengths. *The Condor*, 101(3), pp.622-634.

DEMİRBAĞ, E., ÇINAR, K., TABUR, M.A. and AŞTI, R.N., 2015. Histochemical structure of stomach (Proventriculus and Gizzard) in some bird species. *Journal of natural and applied science*, 19(2), pp.115–122.

DENBOW, D., 2000. *Chapter 14*. Gastrointestinal anatomy and physiology. *Sturkie's Avian Physiology*, pp.337-366.

DENBOW, D.M., 2015. *Gastrointestinal anatomy and physiology*. in *Sturkie's Avian Physiology*, pp.337-366.

DUKE, G.E., 1997. Gastrointestinal physiology and nutrition in wild birds. *Proceedings of the nutrition society*, pp.1049–1056.

EGLITIS, I. AND KNOUFF, R.A., 1962. An histological and histochemical analysis of the inner lining and glandular epithelium of the chicken gizzard. *American journal of anatomy*, 111(1), pp.49–65.

FARNER, D.S., 1960. Digestion and the digestive system. *Biology and comparative* *physiology of birds*, 1, pp.411–467.

FARNER, D.S., KING, J.R. AND PARKES, K.C., 2012. *Avian biology*. Academic press.

FISCHER, C.P. AND ROMERO, L.M., 2019. Chronic captivity stress in wild animals is highly species-specific. *Conservation physiology*, 7(1), p.coz093.

FLOWER, W.H., 1869. Note on a substance ejected from the stomach of a hornbill (*Buceros corrugatus*). in *Proceedings of the zoological society of London*, p.150.

FORBES, N.A., 2002. Avian gastrointestinal surgery. *Seminars in avian and exotic pet medicine*, 11(4), pp. 196–207.

FORD, S., 2010. Raptor gastroenterology, *Journal of exotic pet medicine*, 19(2), pp.140-150.

FOWLER, M.E., 1991. Comparative clinical anatomy of ratites. *Journal of zoo and wildlife medicine*, pp.204–227.

FRITZ, J., HAMMER, S., HEBEL, C., ARIF, A., MICHALKE, B., DITTMANN, M.T., MÜLLER, D.W. AND CLAUSS, M., 2012. Retention of solutes and different-sized particles in the digestive tract of the ostrich (*Struthio camelus massaicus)*, and a comparison with mammals and reptiles. *Comparative biochemistry & physiology part a: Molecular & integrative physiology*, 163(1), pp.56–65.

GERRING, E.L. AND KING, J.N.,1989. Cisapride in the prophylaxis of equine post operative ileus. *Equine veterinary journal*, 21(S7), pp.52–55.

GIONFRIDDO, J.P. AND BEST, L.B., 1996. Grit-use patterns in North American birds: the influence of diet, body size, and gender. *The Wilson bulletin*, pp.685–696.

GRIMM, R.J. AND WHITEHOUSE, W.M., 1963. Pellet formation in a great horned owl: A roentgenographic study. *The Auk*. American ornithological society, 80(3), pp.301–306.

HAMDI, H., EL-GHAREEB, A.W., ZAHER, M. AND ABUAMOD, F., 2013. Anatomical, histological and histochemical adaptations of the avian alimentary canal to their food habits: II-Elanus caeruleus. *International journal of scientific & engineering research*, 4(10), p.1355-1364.

HASSAN, S.A. AND MOUSSA, E.A., 2012. Gross and microscopic studies on the stomach of domestic duck (*Anas platyrhynchos*) and domestic pigeon (*Columba livia domestica*). *Journal of veterinary anatomy*, 5(2), pp.105–127.

HAYATI, F., LAKZIAN, A., SHARIATI, E., BAKHTIARI, J., SAYYAH, N., MASOUDIFARD, M. AND VAKILI, T., 2011. Surgical removal of a ventricular foreign body from a common myna (*Acridotheres tristis*): a case report. *Veterinarni medicina*, 59(6), pp.319–323.

HODGES, R.D., 1974. *The histology of the fowl*. Academic press. Available at: https://univofpretoria.on.worldcat.org/oclc/1183978.

HOUSTON, D. C. AND COOPER, J.E., 1975. The digestive tract of the whiteback griffon vulture and its role in disease transmission among wild ungulates. *Journal of wildlife diseases*, 11(3), pp.306–313.

HRISTOV, H., VLADOVA, D., KOSTOV, D. AND DIMITROV, R., 2017. Gross anatomy of some digestive organs of the domestic Canary (*Serinus Canaria*). *Trakia journal of science*, 15(2), pp.106-112.

HUBER, N., FUSANI, L., FERRETTI, A., MAHR, K. AND CANOINE, V., 2017. Measuring short-term stress in birds: Comparing different endpoints of the endocrine-immune interface. *Physiology & behavior*, 182, pp.46–53.

HUBER, N., MARASCO, V., PAINER, J., VETTER, S.G., GÖRITZ, F., KACZENSKY, P. AND WALZER, C., 2019. Leukocyte coping capacity: An integrative parameter for wildlife welfare within conservation interventions. *Frontiers in veterinary science*, 6, p.105.

HUSSEIN, S. AND REZK, H., 2016. Macro and microscopic characteristics of the gastrointestinal tract of the cattle Egret (*Bubulcus ibis*). *International journal of anatomy research*, 4(2), pp.2162–2174.

IIJIMA, K., ICHIKAWA, T., OKADA, S., OGAWA, M., KOIKE, T., OHARA, S. AND SHIMOSEGAWA, T., 2009. Rebamipide, a cytoprotective drug, increases gastric mucus secretion in human: evaluations with endoscopic gastrin test. *Digestive diseases and sciences*, 54(7), pp.1500–1507.

IMAI, M., SHIBATA, T., MORIGUCHI, K., YAMAMOTO, M. AND HAYAMA, H., 1991. Proventricular glands in fowl. *Okajimas folia anatomica Japonica*, 68(2–3), pp.155–160.

INFORZATO, D.L.M. AND SASSO, W.S., 1985. Histochemical detection of glycoproteins in the intestinal epithelium of Columba livia. *Anatomischer Anzeiger*, 159(1–5), p.203.

IUCN, 2019. The IUCN Red list of Threatened Species. *The IUCN Red list of Threatened Species*, 2.

JAIN, D. K. (1976) ‘Histomorphology and proteolytic activity in the gastric apparatus of frugivorous, carnivorous and omnivorous species of birds’, *Acta biologica* *academiae scientiarum hungaricae*, 27(2–3), p.135—145. Available at: http://europepmc.org/abstract/MED/16419.

JENKINS, J.R., 2000. Surgery of the avian reproductive and gastrointestinal systems. *Veterinary clinics of North America: Exotic animal practice*, 3(3), pp.673–692.

JONES, M.P., 1999. Avian clinical pathology. *Veterinary clinics of North America: exotic animal practice*, 2(3), pp.663–687.

JORDAN, M., 2011. Southern ground hornbill *(Bucorvus leadbeateri)* species recovery plan for South Africa. *Johannesburg zoo/endangered wildlife trust, Johannesburg*, pp.1-27

KADHIM, K.K., ZUKI, A.B.Z., NOORDIN, M.M. AND BABJEE, S.M.A., 2011. Histomorphology of the stomach, proventriculus and ventriculus of the red jungle fowl. *Anatomia, histologia, embryologia*, 40(3), pp.226–233.

KADHIM, K.K., ZUKI, A.B.Z., BABJEE, S.M.A., NOORDIN, M.M. AND ZAMRI-SAAD, M., 2011. Morphological and histochemical observations of the red jungle fowl tongue (*Gallus gallus*). *African Journal of Biotechnology*, 10(48), pp.9969–9977.

KEMP, A.C. AND KEMP, M.I., 1980. The biology of the Southern ground hornbill (*Bucorvus leadbeateri*) (Vigors)(Aves: Bucerotidae). *Annals of the Transvaal museum*, 32(4), pp.65–100.

KEMP, A.C., JOUBERT, S.C.J. AND KEMP, M.I., 1989. Distribution of Southern ground hornbills in the Kruger National Park in relation to some environmental features. *South African journal of wildlife research*, 19(3), pp. 93–98.

KEMP, L.V., KOTZE, A., JANSEN, R., DALTON, D.L., GROBLER, P. AND LITTLE, R., 2020. Review of trial reintroductions of the long-lived, cooperative breeding Southern Ground-hornbill. *Bird conservation international*, pp.1-26.

KEMP, A.C. AND WOODCOCK, M., 1995. *The hornbills: Bucerotiformes*. Oxford University Press, USA, (1).

KENDALL, R.J., LACKER JR, T.E., BUNCK, C., DANIEL, B., DRIVER, C., GRUE, C.E., LEIGHTON, F., STANSLEY, W., WATANABE, P.G. AND WHITWORTH, M., 1996. An ecological risk assessment of lead shot exposure in non-waterfowl avian species: upland game birds and raptors. *Environmental toxicology and chemistry: An international journal*, 15(1), pp.4–20.

KING, A.S. AND MCLELLAND, J., 1984. *Birds : their structure and function*. Philadelphia: Bailliere Tindall, (2).

KLAPHAKE, E. AND CLANCY, J., 2005. Raptor gastroenterology. *The veterinary clinics of North America. Exotic animal practice*, 8(2), pp.307–327.

KLASING, K.C., 1999. Avian gastrointestinal anatomy and physiology. *in Seminars in avian and exotic pet medicine* (Vol. 8, No. 2), pp.42–50.

KOEPPEL, K.K. AND KEMP, L.V., 2015. Lead toxicosis in a Southern Ground Hornbill (*Bucorvus leadbeateri*) in South Africa. *Journal of avian medicine surgery*, 29(4), pp.340–344.

KOHL, K.D., CIMINARI, M.E., CHEDIACK, J.G., LEAFLOOR, J.O., KARASOV, W.H., MCWILLIAMS, S.R. AND CAVIEDES-VIDAL, E., 2017. Modulation of digestive enzyme activities in the avian digestive tract in relation to diet composition and quality. *Journal of comparative physiology*, 187(2), pp.339–351.

KRAUTWALD-JUNGHANNS, M.E., STAHL, A., PEES, M., ENDERS, F. AND BARTELS, T., 2002. Sonographic investigations of the gastrointestinal tract of granivorous birds. *Veterinary radiology & ultrasound*, 43(6), pp.576–582.

KUSHCH, M.M., KUSHCH, L.L., FESENKO, I.A., MIROSHNIKOVA, O.S. AND MATSENKO, O.V., 2019. Microscopic features of lamina muscularis mucosae of the goose gut. *Regulatory mechanisms in biosystems*, 10(4), pp.382–387.

LAMPS, L.W., MOLINA, C.P., WEST, A.B., HAGGITT, R.C. AND SCOTT, M.A., 2000. The pathologic spectrum of gastrointestinal and hepatic histoplasmosis. *American journal of clinical pathology*, 113(1), pp.64–72.

LANGLOIS, I., 2003. The anatomy, physiology, and diseases of the avian proventriculus and ventriculus. *The veterinary clinics of North America. Exotic animal practice*, 6(1), pp.85–111.

LEOPOLD, A.S., 1953. Intestinal morphology of gallinaceous birds in relation to food habits. *The Journal of wildlife management*, 17(2), pp.197–203.

LI, M., ZHU, W., WANG, Y., SUN, Y., LI, J., LIU, X., WU, Y., GAO, X. AND LI, D., 2019. Effects of capture and captivity on plasma corticosterone and metabolite levels in breeding Eurasian tree sparrows. *Avian research*, 10(1), p.16.

LIMAN, N., ALAN, E. AND KÜÇÜK BAYRAM, G., 2010. The differences between the localizations of MUC1, MUC5AC, MUC6 and osteopontin in quail proventriculus and gizzard may be a reflection of functional differences of stomach parts. *Journal of anatomy*, 217(1), pp.57–66.

LUCAS, A.M. AND DENINGTON, E.M., 1956. Morphology of the chicken liver. *Poultry science*, 35(4), pp.793–806.

LUX, G., KATSCHINSKI, M., LUDWIG, S., LEDERER, P., ELLERMANN, A. AND DOMSCHKE, W., 1994. The Effect of cisapride and metoclopramide on human digestive and interdigestive antroduodenal motility. *Scandinavian journal of* *gastroenterology*, 29(12), pp.1105–1110.

MADKOUR, F. AND MOHAMED, A., 2019. Macro-microscopical anatomy of the gizzard of Egyptian laughing dove and rock pigeon. *Assiut veterinary medical journal,* 65, pp.278–285.

MAHER, M.A., 2019. Descriptive anatomy of hepatic and portal veins with special reference to biliary duct system in broiler chickens (*Gallus gallus domesticus*): A recent illustration. *Brazilian journal of poultry science*, 21(2), pp.1-11.

MALEWITZ, T.D. AND CALHOUN, M.L., 1958. The gross and microscopic anatomy of the digestive tract, spleen, kidney, lungs and heart of the turkey. *Poultry science*, 37(2), pp.388–398.

MALOIY, G.M.O., WARUI, C.N. AND CLEMENS, E.T., 1987. Comparative gastrointestinal morphology of the kori bustard and secretary bird. *Zoo biology*, 6(3), pp.243–251.

MCLELLAND, J., 1990. *A colour atlas of avian anatomy*. Wolfe medical publications Ltd, Omaha, Nebraska.

MCMANUS, J.F.A., 1946. Histological demonstration of mucin after periodic acid. *Nature*, 158(4006), p.202-202.

MENZIES, G. AND FISK, A., 1963. Observations on the oxyntico-peptic cells in the proventricular mucosa of *Gallus domesticus*. *Journal of cell science*, 3(66), pp.207–215.

MIGUEL, F., 2019. Clinical anatomy and physiology of exotic species structure and function of mammals, birds, reptiles and amphibians. in *Seminars in avian and exotic pet medicine,* 14(3), pp.221-222.

MILLÁN, J., NEGRE, N., CASTELLANOS, E., DE JUAN, L., MATEOS, A., PARPAL, L. AND ARANAZ, A., 2010. Avian mycobacteriosis in free-living raptors in Majorca Island, Spain. *Avian pathology*, 39(1), pp.1–6.

MOHAMMAD, F.K., AL-ZUBAIDY, M.H.I. AND ALIAS, A.S., 2007. Sedative and hypnotic effects of combined administration of metoclopramide and ketamine in chickens. *Lab animal*, 36(4), pp.35–39.

MOORE, B.A., OTTERBEIN, L.E., TÜRLER, A., CHOI, A.M. AND BAUER, A.J., 2003. Inhaled carbon monoxide suppresses the development of postoperative ileus in the murine small intestine. *Gastroenterology*, 124(2), pp.377–391.

MORISHITA, T.Y., LOWENSTINE, L.J., HIRSH, D.C. AND BROOKS, D.L., 1997. Lesions associated with pasteurella multocida infection in raptors. *Avian diseases*, 41(1), pp.203–213.

MOSS, R., 1972. Effects of captivity on gut lengths in red grouse. *The journal of Wildlife Management*, pp.99–104.

MSIMANGA, A., 2004. *Breeding biology of Southern Ground Hornbill (Bucorvus leadbeateri) in Zimbabwe: Impacts of human activities*. *Bird conservation international*, 14(S1), pp.S63-S68.

MURIE, J., 1874. On the nature of the sacs vomited by the Hornbills. in *Proceedings of the zoological society of London*, pp.420–425.

MURRAY, M., 2014. Raptor gastroenterology. *Veterinary clinics: Exotic animal practice*, 17(2), pp.211–234.

MURRAY, M.J., 1997. Diagnostic techniques in avian medicine. *Seminars in avian* *and exotic pet medicine*, 6(2), pp.48–54.

NICKEL, R., SCHUMMER, A. AND SEIFERLE, E., 1977. *Anatomy of the domestic birds*. Berlin; Hamburg: Parey, pp.14-15.

NORTH, M., MOVASSAGHI, A. R. AND SMITS, J., 2016. Anatomy and histology of the gastrointestinal tract of European Starlings (*Sturnus vulgaris*). *Avian biology research*, 9(4), pp.257-264.

OGUNKOYA, Y.O. AND COOK, R.D., 2009. Histomorphology of the proventriculus of three species of Australian passerines: *Lichmera indistincta, Zosterops lateralis* and *Poephila guttata*. *Anatomia, histologia, embryologia*, 38(4), pp.246–253.

OLOWO-OKORUN, M.O. AND AMURE, B.O., 1973. Gastrin activity in the chicken proventriculus. *Nature*, 246(5433), pp.424–425.

PAIK, Y.K., FUJIOKA, T. AND YASUDA, M., 1974. Comparative and topographical anatomy of the fowl, 78: Division of pancreatic lobes and distribution of pancreatic ducts. *Japanese journal of veterinary science,* 36(3), pp.213-229

PERRY, G.C., 2006. *Avian gut function in health and disease* (Vol. 28). *Cabi*, pp.225-272.

PIMM, S., RAVEN, P., PETERSON, A., ŞEKERCIOĞLU, Ç.H. AND EHRLICH, P.R., 2006. Human impacts on the rates of recent, present, and future bird extinctions. *Proceedings of the national academy of sciences*, *103*(29), pp.10941-10946.

POOLE, A.F., 1989. *Ospreys: a natural and unnatural history*. Cambridge, UK: Cambridge University Press, (246).

RITCHIE, B.W., 1994. *Avian medicine principles and application*. Wingers publishing incorporated. Available at: http://10.6.20.12:80/handle/123456789/1791

RODRIGUES, M.N., OLIVEIRA, G.B., DA SILVA, R.S., TIVANE, C., DE ALBUQUERQUE, J.F., MIGLINO, M.A. AND DE OLIVEIRA, M.F., 2012. Gross morphology and topography of the digestive apparatus in rheas (*Rhea americana americana*). *Pesquisa veterinária Brasileira*, 32(7), pp.681–686.

ROMAŃSKI, K., 2010. Functions and importance of the gallbladder in animals. *Życie Weterynaryjne*, 85(4), pp.338–341.

ROSSI, J.R., BARALDI-ARTONI, S.M., OLIVEIRA, D., CRUZ, C.D., FRANZO, V.S. AND SAGULA, A., 2005. Morphology of glandular stomach (*Ventriculus glandularis*) and muscular stomach (*Ventriculus muscularis*) of the partrigde (*Rhynchotus rufescens*). *Ciência rural*, 35(6), pp.1319–1324.

ROSSKOPF JR, J.W. AND WOERPEL, R.W., 1984. Surgery of the avian digestive system. in *The proceedings of the 13th annual veterinary surgical forum, seminar* (No. 10, pp.85-90).

SACRANIE, A., SVIHUS, B., DENSTADLI, V., MOEN, B., IJI, P.A. AND CHOCT, M., 2012. The effect of insoluble fiber and intermittent feeding on gizzard development, gut motility, and performance of broiler chickens. *Poultry science*, 91(3), pp.693–700.

SAYRAFI, R. AND AGHAGOLZADEH, M., 2020. Histological and histochemical study of the proventriculus (*Ventriculus glandularis*) of common starling (*Sturnus vulgaris*). *Anatomia, histologia, embryologia*, 49(1), pp.105–111.

SCANES, C.G., 2015. Sturkie's avian physiology. *Elsevier*.

SCHMIDT, R.E., REAVILL, D.R. AND PHALEN, D.N. 2015. *Pathology of pet and aviary birds*. John Wiley & Sons, pp.1-234.

SELVAN, P.S., USHAKUMARY, S. AND RAMESH, G., 2008. Studies on the histochemistry of the proventriculus and gizzard of post-hatch guinea fowl (*Numida meleagris*). *International journal of poultry science*, 7(11), pp.1112–1116.

SHIVAPRASAD, H.L., 2002. Pathology of birds–an overview. in *CL Davis foundation conference on gross morbid anatomy of animals,* pp.1–48.

SHUBICH, M.G., MOGIL'NAIA, G.M. AND DUDETSKIĬ, V.I., 1978. Histochemical characteristics of the secretory cells of gastric glands compared. *Arkhiv anatomii, gistologii i embriologii*, 74(2), pp.59–66.

SIEGEL, H.S., 1980. Physiological stress in birds. *BioScience*, 30(8), pp.529–534.

STORNELLI, M.R., RICCIARDI, M.P., MIRAGLIOTTA, V., COLI, A. AND GIANNESSI, E., 2006. Morpho-structural study of the pancreas and pancreatic duct in ostrich (*Struthio camelus L.*). *Acta Veterinaria Brno*, 75(2), pp.157–160.

STORNELLI, M.R., RICCIARDI, M.P., GIANNESSI, E. AND COLI, A., 2006. Morphological and histological study of the ostrich (*Struthio Camelus L.*) liver and biliary system. *Italian journal of anatomy and embryology*, 111(1), p.1.

SVIHUS, B., 2014. Function of the digestive system. *Journal of applied poultry research*, 23(2), pp.306–314.

SWEENEY, R., 2016. *Ground Hornbills in American zoos: a case study of the challenges to ex situ population sustainability for conservation.* Association of zoos and aquariums species survival plan, USA.

THERON, N., DALTON, D., GROBLER, J.P., JANSEN, R. AND KOTZE, A., 2013. Molecular insights on the re-colonization of the Limpopo valley, South Africa, by Southern Ground-Hornbills. *Journal of ornithology*, *154*(3), pp.727-737.

THERON, N., JANSEN, R., GROBLER, P. AND KOTZE, A., 2013. The home range of a recently established group of Southern ground-hornbill (*Bucorvus leadbeateri*) in the Limpopo valley, South Africa. *Koedoe*, 55(1), pp.1–8.

TRAIL, P.W., 2007. African hornbills: keystone species threatened by habitat loss, hunting and international trade. *Ostrich-journal of African ornithology*, 78(3), pp.609–613.

THOMSON, D. S., 1969. Histogenesis of the proventricular submucosal gland of the chick as revealed by light and electron microscopy. *The Ohio journal of science*, 69(2), pp.74-84.

TONER, P.G., 1963. The fine structure of resting and active cells in the submucosal glands of the fowl proventriculus. *Journal of anatomy*, 97(Pt 4), pp.575–583.

TONER, P.G., 1964. The fine structure of gizzard gland cells in the domestic fowl. *Journal of anatomy*, 98, pp.77–85.

TSUKAHARA, TAKAMITSU AND USHIDA, K., 2000. Effects of animal or plant protein diets on cecal fermentation in guinea pigs (*Cavia porcellus*), rats (*Rattus norvegicus*) and chicks (*Gallus gallus domesticus*). *Comparative biochemistry and physiology Part A: Molecular & integrative physiology*, 127(2), pp.139-146.

TURK, D.E., 1982. The anatomy of the avian digestive tract as related to feed utilization. *Poultry science*, 61(7), pp.1225–1244.

VENTURA, A., DO NASCIMENTO, A.A., DOS SANTOS, M.A.J., VIEIRA-LOPES, D.A., SALES, A. AND PINHEIRO, N.L., 2013. Histological description of morphogenesis of the gastroesophageal mucosa of *Gallus gallus domesticus* (Linnaeus, 1758). *International Journal of Morphology*, 31(4), pp.1331-1339.

WALLNER-PENDLETON, E.A., ROGERS, D. AND EPPLE, A., 1993. Diabetes mellitus in a red-tailed hawk (*Buteo jamaicensis*). *Avian pathology*, 22(3), pp.631–635

WEBB, T.E. AND COLVIN, J.R., 1964. The composition, structure, and mechanism of formation of the lining of the gizzard of the chicken. *Canadian journal of biochemistry*, 42(1), pp.59–70.

WHITESIDE, D., 2017. Avian medicine and surgery in practice: Companion and aviary birds. *The Canadian veterinary journal*, 58(7), p.702.

WILSON, G., HOCKEY, P.A.R. AND MARSDEN, S., 2013. Causes of variable reproductive performance by Southern Ground-hornbill (*Bucorvus leadbeateri*) and implications for management. *Ibis*, 155(3), pp.476–484.

WYNESS, W., 2011. *Home range use by Southern Ground-Hornbills (Bucorvus leadbeateri) quantifying seasonal habitat selection and vegetation characteristics*. University of Cape Town.

ZACCARONI, A., ANDREANI, G., FERRANTE, M.C., CARPENE, E., ISANI, G. AND LUCISANO, A., 2008. Metal concentrations in the liver and kidney of raptor species from the Calabria region, Italy. *Acta veterinaria*, 58(4), pp.315–324.

ZAHER, M., EL-GHAREEB, A.W., HAMDI, H. AND ABUAMOD, F., 2012. Anatomical, histological and histochemical adaptations of the avian alimentary canal to their food habits: I-Coturnix coturnix. *Life Sci. J*, 9(3), pp.253–275.

ZHU, L., 2015. Histological and histochemical study on the stomach (Proventriculus and Gizzard) of black-tailed crake (*Porzana bicolor*). *Pakistan journal of zoology*, 47(3), pp.607-616.

ZOGHBY, B.A., 2015. *Fine-scale movements and habitat use of the Southern*

Ground Hornbill (Bucorvus Leadbeateri). University of Cape Town.

APPENDICES

Appendix I

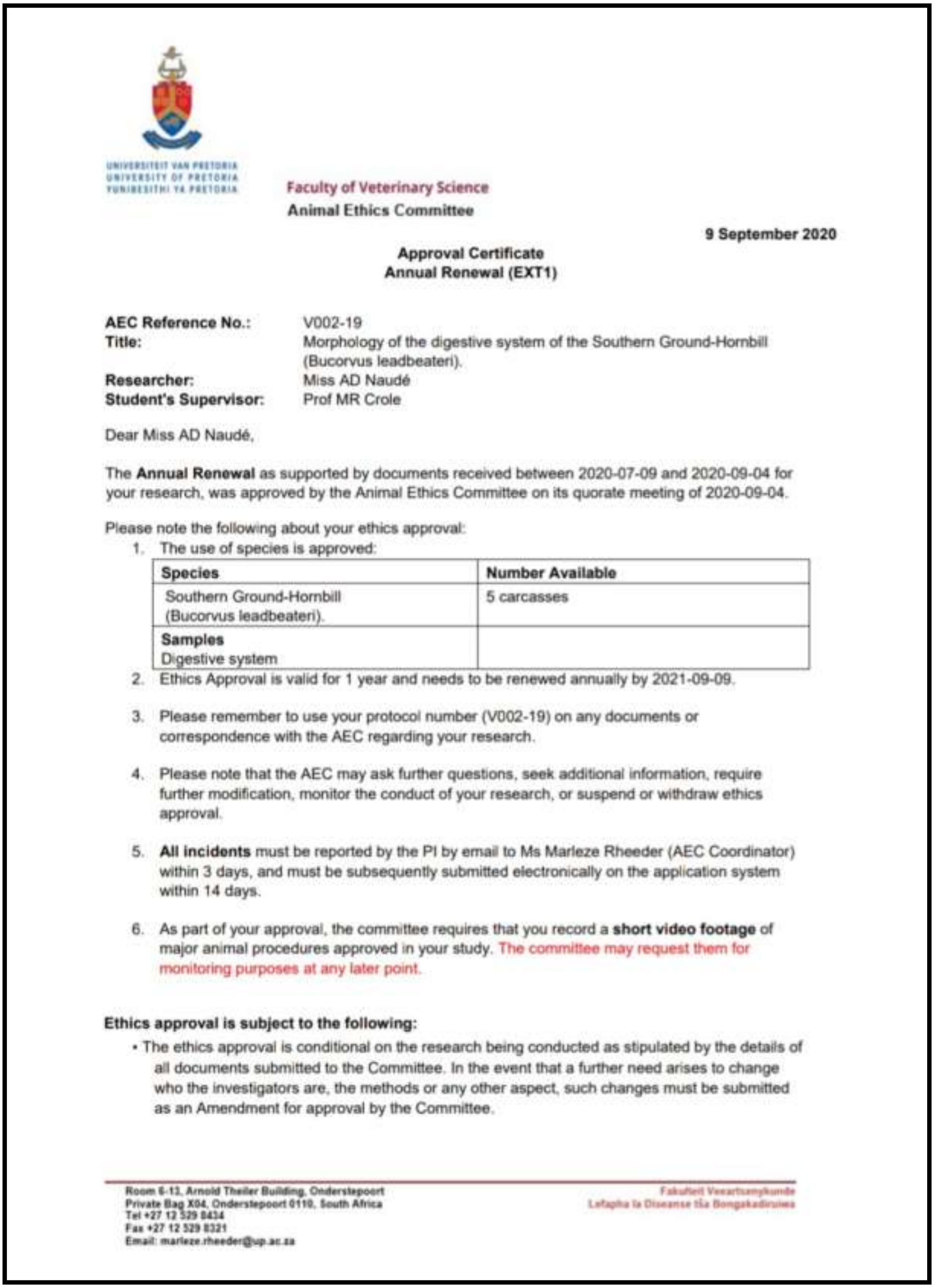

UNIVERSITEIT VAN PRETORIA
UNIVERSITY OF PRETORIA
YUNIBESITHI YA PRETORIA

Faculty of Veterinary Science
Animal Ethics Committee

9 September 2020

Approval Certificate
Annual Renewal (EXT1)

AEC Reference No.:	V002-19
Title:	Morphology of the digestive system of the Southern Ground-Hornbill (Bucorvus leadbeateri).
Researcher:	Miss AD Naudé
Student's Supervisor:	Prof MR Crole

Dear Miss AD Naudé,

The **Annual Renewal** as supported by documents received between 2020-07-09 and 2020-09-04 for your research, was approved by the Animal Ethics Committee on its quorate meeting of 2020-09-04.

Please note the following about your ethics approval:

1. The use of species is approved:

Species	**Number Available**
Southern Ground-Hornbill (Bucorvus leadbeateri).	5 carcasses
Samples Digestive system	

2. Ethics Approval is valid for 1 year and needs to be renewed annually by 2021-09-09.
3. Please remember to use your protocol number (V002-19) on any documents or correspondence with the AEC regarding your research.
4. Please note that the AEC may ask further questions, seek additional information, require further modification, monitor the conduct of your research, or suspend or withdraw ethics approval.
5. **All incidents** must be reported by the PI by email to Ms Marleze Rheeder (AEC Coordinator) within 3 days, and must be subsequently submitted electronically on the application system within 14 days.
6. As part of your approval, the committee requires that you record a **short video footage** of major animal procedures approved in your study. The committee may request them for monitoring purposes at any later point.

Ethics approval is subject to the following:

- The ethics approval is conditional on the research being conducted as stipulated by the details of all documents submitted to the Committee. In the event that a further need arises to change who the investigators are, the methods or any other aspect, such changes must be submitted as an Amendment for approval by the Committee.

Room 6-13, Arnold Theiler Building, Onderstepoort
Private Bag X04, Onderstepoort 0110, South Africa
Tel +27 12 529 8434
Fax +27 12 529 8321
Email: marleze.rheeder@up.ac.za

Fakulteit Veeartsenykunde
Lefapha la Disaense tša Bongakadiruiwa



We wish you the best with your research.
Yours sincerely

Prof V Naidoo
CHAIRMAN: UP-Animal Ethics Committee

Appendix II

Abstract for faculty day 2019

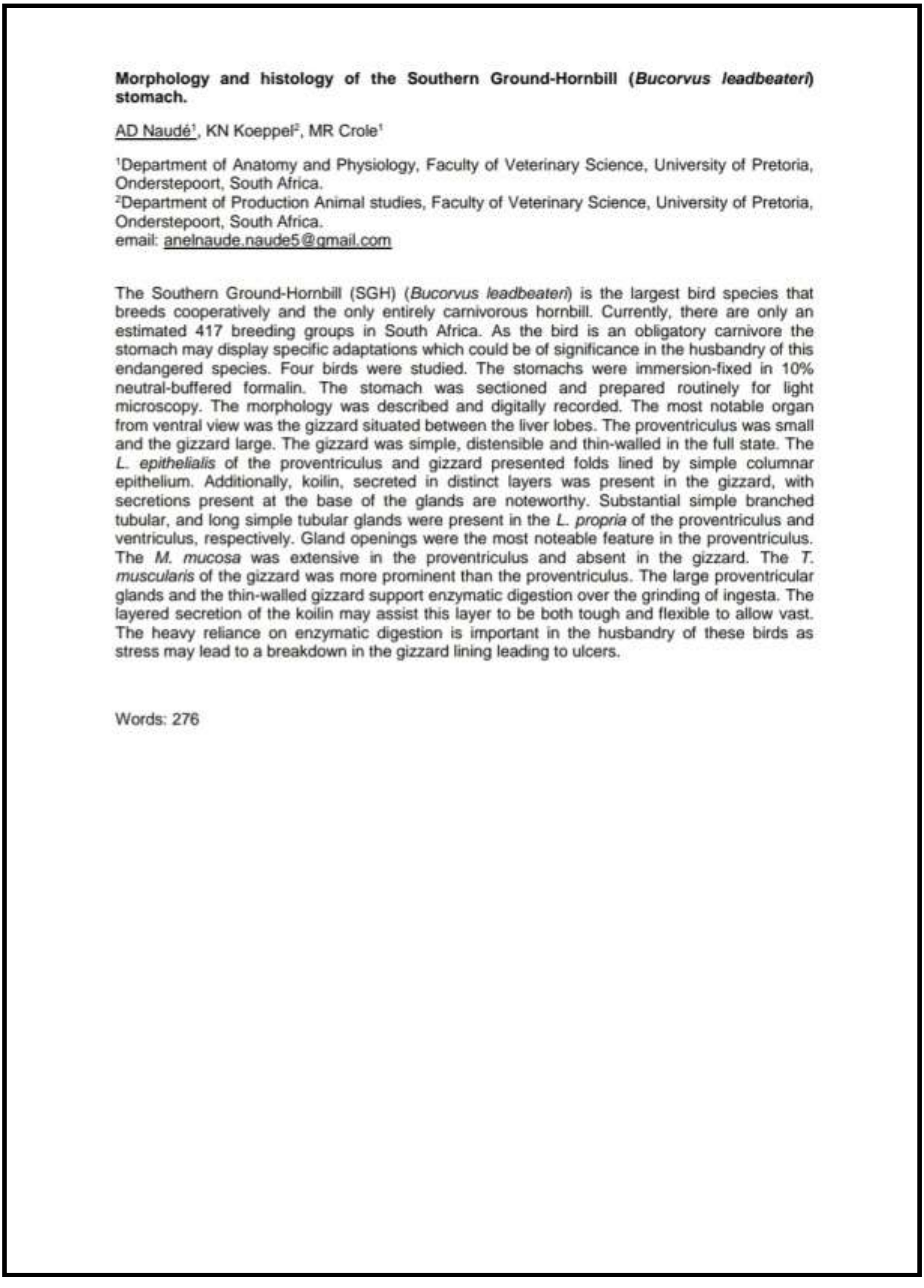

Morphology and histology of the Southern Ground-Hornbill (*Bucorvus leadbeateri*) stomach.

AD Naudé[1], KN Koeppel[2], MR Crole[1]

[1]Department of Anatomy and Physiology, Faculty of Veterinary Science, University of Pretoria, Onderstepoort, South Africa.
[2]Department of Production Animal studies, Faculty of Veterinary Science, University of Pretoria, Onderstepoort, South Africa.
email: anelnaude.naude5@gmail.com

The Southern Ground-Hornbill (SGH) (*Bucorvus leadbeateri*) is the largest bird species that breeds cooperatively and the only entirely carnivorous hornbill. Currently, there are only an estimated 417 breeding groups in South Africa. As the bird is an obligatory carnivore the stomach may display specific adaptations which could be of significance in the husbandry of this endangered species. Four birds were studied. The stomachs were immersion-fixed in 10% neutral-buffered formalin. The stomach was sectioned and prepared routinely for light microscopy. The morphology was described and digitally recorded. The most notable organ from ventral view was the gizzard situated between the liver lobes. The proventriculus was small and the gizzard large. The gizzard was simple, distensible and thin-walled in the full state. The *L. epithelialis* of the proventriculus and gizzard presented folds lined by simple columnar epithelium. Additionally, koilin, secreted in distinct layers was present in the gizzard, with secretions present at the base of the glands are noteworthy. Substantial simple branched tubular, and long simple tubular glands were present in the *L. propria* of the proventriculus and ventriculus, respectively. Gland openings were the most noteable feature in the proventriculus. The *M. mucosa* was extensive in the proventriculus and absent in the gizzard. The *T. muscularis* of the gizzard was more prominent than the proventriculus. The large proventricular glands and the thin-walled gizzard support enzymatic digestion over the grinding of ingesta. The layered secretion of the koilin may assist this layer to be both tough and flexible to allow vast. The heavy reliance on enzymatic digestion is important in the husbandry of these birds as stress may lead to a breakdown in the gizzard lining leading to ulcers.

Words: 276

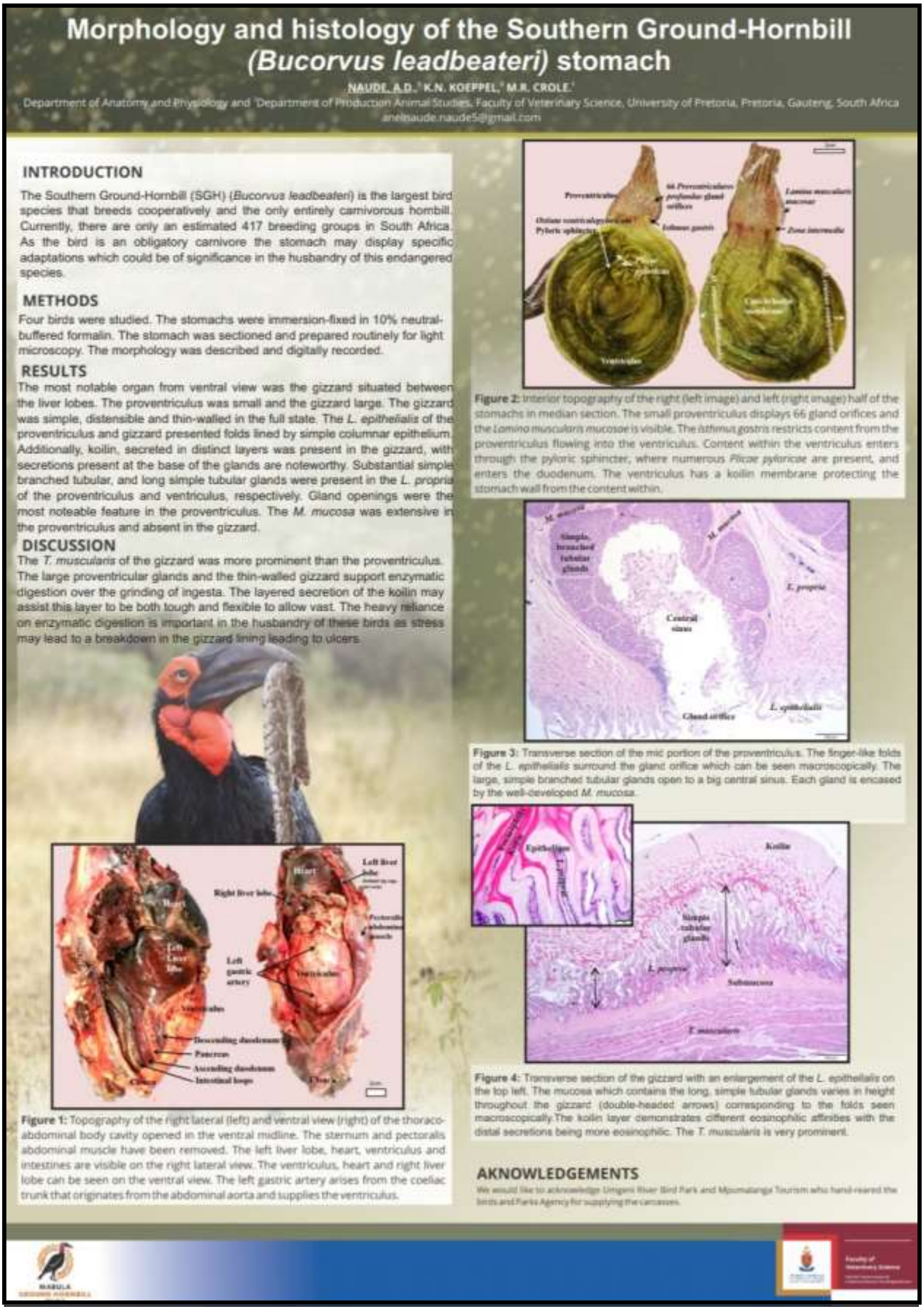

Morphology and histology of the Southern Ground-Hornbill *(Bucorvus leadbeateri)* stomach

NAUDE, A.D.,[1] K.N. KOEPPEL,[2] M.R. CROLE.[1]
[1]Department of Anatomy and Physiology and [2]Department of Production Animal Studies, Faculty of Veterinary Science, University of Pretoria, Pretoria, Gauteng, South Africa
anelnaude.naude5@gmail.com

INTRODUCTION

The Southern Ground-Hornbill (SGH) (*Bucorvus leadbeateri*) is the largest bird species that breeds cooperatively and the only entirely carnivorous hornbill. Currently, there are only an estimated 417 breeding groups in South Africa. As the bird is an obligatory carnivore the stomach may display specific adaptations which could be of significance in the husbandry of this endangered species.

METHODS

Four birds were studied. The stomachs were immersion-fixed in 10% neutral-buffered formalin. The stomach was sectioned and prepared routinely for light microscopy. The morphology was described and digitally recorded.

RESULTS

The most notable organ from ventral view was the gizzard situated between the liver lobes. The proventriculus was small and the gizzard large. The gizzard was simple, distensible and thin-walled in the full state. The *L. epithelialis* of the proventriculus and gizzard presented folds lined by simple columnar epithelium. Additionally, koilin, secreted in distinct layers was present in the gizzard, with secretions present at the base of the glands are noteworthy. Substantial simple branched tubular, and long simple tubular glands were present in the *L. propria* of the proventriculus and ventriculus, respectively. Gland openings were the most noteable feature in the proventriculus. The *M. mucosa* was extensive in the proventriculus and absent in the gizzard.

DISCUSSION

The *T. muscularis* of the gizzard was more prominent than the proventriculus. The large proventricular glands and the thin-walled gizzard support enzymatic digestion over the grinding of ingesta. The layered secretion of the koilin may assist this layer to be both tough and flexible to allow vast. The heavy reliance on enzymatic digestion is important in the husbandry of these birds as stress may lead to a breakdown in the gizzard lining leading to ulcers.

Figure 1: Topography of the right lateral (left) and ventral view (right) of the thoraco-abdominal body cavity opened in the ventral midline. The sternum and pectoralis abdominal muscle have been removed. The left liver lobe, heart, ventriculus and intestines are visible on the right lateral view. The ventriculus, heart and right liver lobe can be seen on the ventral view. The left gastric artery arises from the coeliac trunk that originates from the abdominal aorta and supplies the ventriculus.

Figure 2: Interior topography of the right (left image) and left (right image) half of the stomachs in median section. The small proventriculus displays 66 gland orifices and the *Lamina muscularis mucosae* is visible. The *Isthmus gastris* restricts content from the proventriculus flowing into the ventriculus. Content within the ventriculus enters through the pyloric sphincter, where numerous *Plicae pyloricae* are present, and enters the duodenum. The ventriculus has a koilin membrane protecting the stomach wall from the content within.

Figure 3: Transverse section of the mid portion of the proventriculus. The finger-like folds of the *L. epithelialis* surround the gland orifice which can be seen macroscopically. The large, simple branched tubular glands open to a big central sinus. Each gland is encased by the well-developed *M. mucosa*.

Figure 4: Transverse section of the gizzard with an enlargement of the *L. epithelialis* on the top left. The mucosa which contains the long, simple tubular glands varies in height throughout the gizzard (double-headed arrows) corresponding to the folds seen macroscopically.The koilin layer demonstrates different eosinophilic affinities with the distal secretions being more eosinophilic. The *T. muscularis* is very prominent.

AKNOWLEDGEMENTS

We would like to acknowledge Umgeni River Bird Park and Mpumalanga Tourism who hand-reared the birds and Parks Agency for supplying the carcasses.

Appendix III

Paper presented at a local conference:

NAUDE, A. D., KOEPPEL, K. N. & CROLE, M. R. (2019) Morphology and histology of the Southern Ground-Hornbill (*Bucorvus leadbeateri*) stomach. 47th Annual Conference of the Anatomical Society of Southern Africa (ASSA); Hosted by the University of Pretoria, Kwa Maritane Bush Lodge and Conference Centre, Pilanesberg, South Africa, 7-10 April 2019.

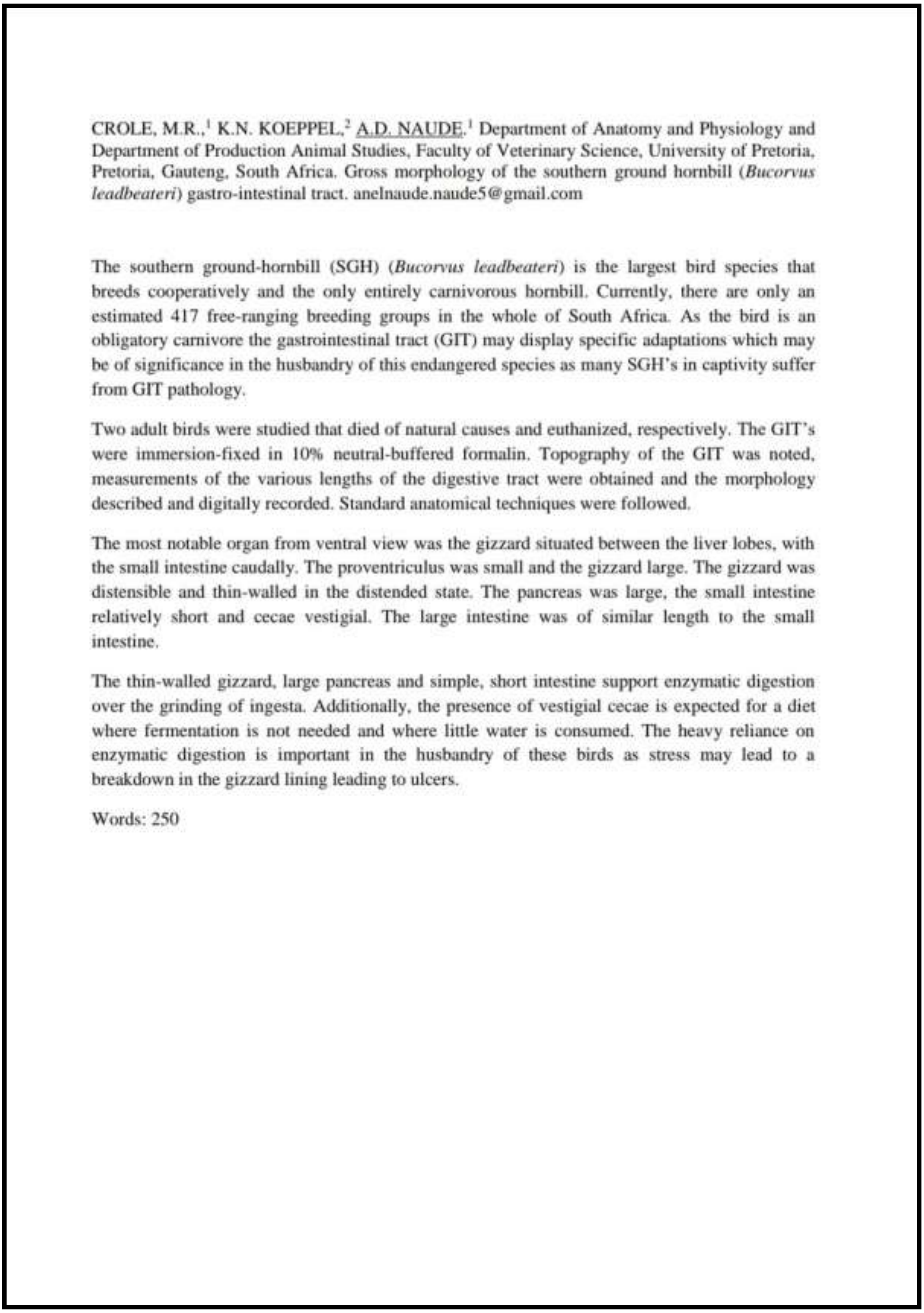

CROLE, M.R.,[1] K.N. KOEPPEL,[2] A.D. NAUDE.[1] Department of Anatomy and Physiology and Department of Production Animal Studies, Faculty of Veterinary Science, University of Pretoria, Pretoria, Gauteng, South Africa. Gross morphology of the southern ground hornbill (*Bucorvus leadbeateri*) gastro-intestinal tract. anelnaude.naude5@gmail.com

The southern ground-hornbill (SGH) (*Bucorvus leadbeateri*) is the largest bird species that breeds cooperatively and the only entirely carnivorous hornbill. Currently, there are only an estimated 417 free-ranging breeding groups in the whole of South Africa. As the bird is an obligatory carnivore the gastrointestinal tract (GIT) may display specific adaptations which may be of significance in the husbandry of this endangered species as many SGH's in captivity suffer from GIT pathology.

Two adult birds were studied that died of natural causes and euthanized, respectively. The GIT's were immersion-fixed in 10% neutral-buffered formalin. Topography of the GIT was noted, measurements of the various lengths of the digestive tract were obtained and the morphology described and digitally recorded. Standard anatomical techniques were followed.

The most notable organ from ventral view was the gizzard situated between the liver lobes, with the small intestine caudally. The proventriculus was small and the gizzard large. The gizzard was distensible and thin-walled in the distended state. The pancreas was large, the small intestine relatively short and cecae vestigial. The large intestine was of similar length to the small intestine.

The thin-walled gizzard, large pancreas and simple, short intestine support enzymatic digestion over the grinding of ingesta. Additionally, the presence of vestigial cecae is expected for a diet where fermentation is not needed and where little water is consumed. The heavy reliance on enzymatic digestion is important in the husbandry of these birds as stress may lead to a breakdown in the gizzard lining leading to ulcers.

Words: 250

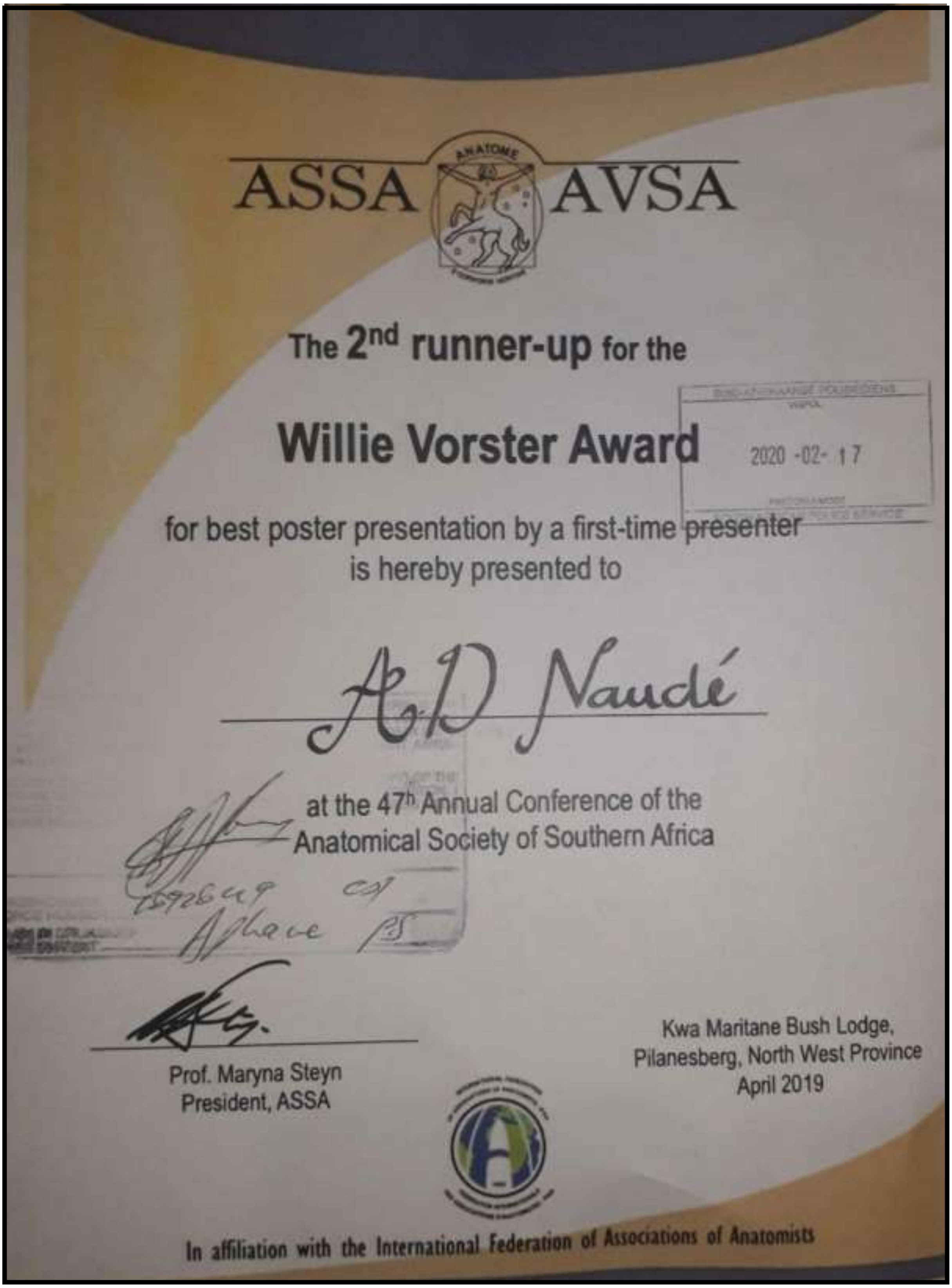

ASSA AVSA

The 2nd runner-up for the

Willie Vorster Award

SUID-AFRIKAANSE POLISIEDIENS
SAPOL
2020 -02- 17
[illegible]
SOUTH AFRICAN POLICE SERVICE

for best poster presentation by a first-time presenter
is hereby presented to

A.D Naudé

at the 47th Annual Conference of the
Anatomical Society of Southern Africa

15926449 Cst
Aphave PS

Prof. Maryna Steyn
President, ASSA

Kwa Maritane Bush Lodge,
Pilanesberg, North West Province
April 2019

In affiliation with the International Federation of Associations of Anatomists

Appendix IIII

Abstract for faculty day 2020

Histology of the Southern Ground-Hornbill (*Bucorvus leadbeateri*) gastro-intestinal tract.

AD Naudé[1], KN Koeppel[2], MR Crole[1]

[1]Department of Anatomy and Physiology, Faculty of Veterinary Science, University of Pretoria, Onderstepoort, South Africa.
[2]Department of Production Animal studies, Faculty of Veterinary Science, University of Pretoria, Onderstepoort, South Africa.
email: anelnaude.naude5@gmail.com

The Southern Ground-Hornbill (SGH) is the largest bird species that breeds cooperatively and the only entirely carnivorous hornbill. As the bird is an obligatory carnivore the gastro-intestinal tract (GIT) may display specific adaptations which could be of significance in the husbandry of this endangered species. Seven birds, which succumbed from trauma or natural causes, were studied. On post mortem, the GIT was removed and immersion-fixed in 10% neutral-buffered formalin. Parts of the GIT were sectioned and routinely prepared for light microscopy. The *Lamina epithelialis* of the proventriculus, ventriculus and intestine presented folds lined by simple columnar epithelium, secreting mucins. Additionally, koilin, secreted in horizontal layers was present in the ventriculus. The *Lamina propria* contains substantial simple, branched tubular glands in the proventriculus and intestine, and long simple tubular glands in the ventriculus. The massive compound tubular proventricular glands, contain cuboidal cells that secrete HCL and pepsin. Infiltrations of internodular lymphoid tissue is present in the *Lamina propria* of the proventriculus and intestine. A single inner longitudinal layer of *Lamina muscularis mucosae* is present in the proventriculus and rectum and an additional outer circular layer in the rest of the intestine, and this layer is absent in the ventriculus. The *Tunica muscularis* consists of an inner longitudinal layer and outer circular layer throughout the GIT. The proventricular glands and the thin-walled gizzard support enzymatic digestion and not the grinding of ingesta. The layered secretion of the koilin may assist the koilin layer to be both tough and flexible to allow vast distention to accommodate large prey items. The heavy reliance on enzymatic digestion is important in the husbandry of these birds as stress may lead to a breakdown in the gizzard lining leading to ulcers. Additionally, the well-developed muscular layers indicate the importance of maintaining intestinal motility, making GIT stasis due to toxins or bacteria a life threatening condition.

Words: 308

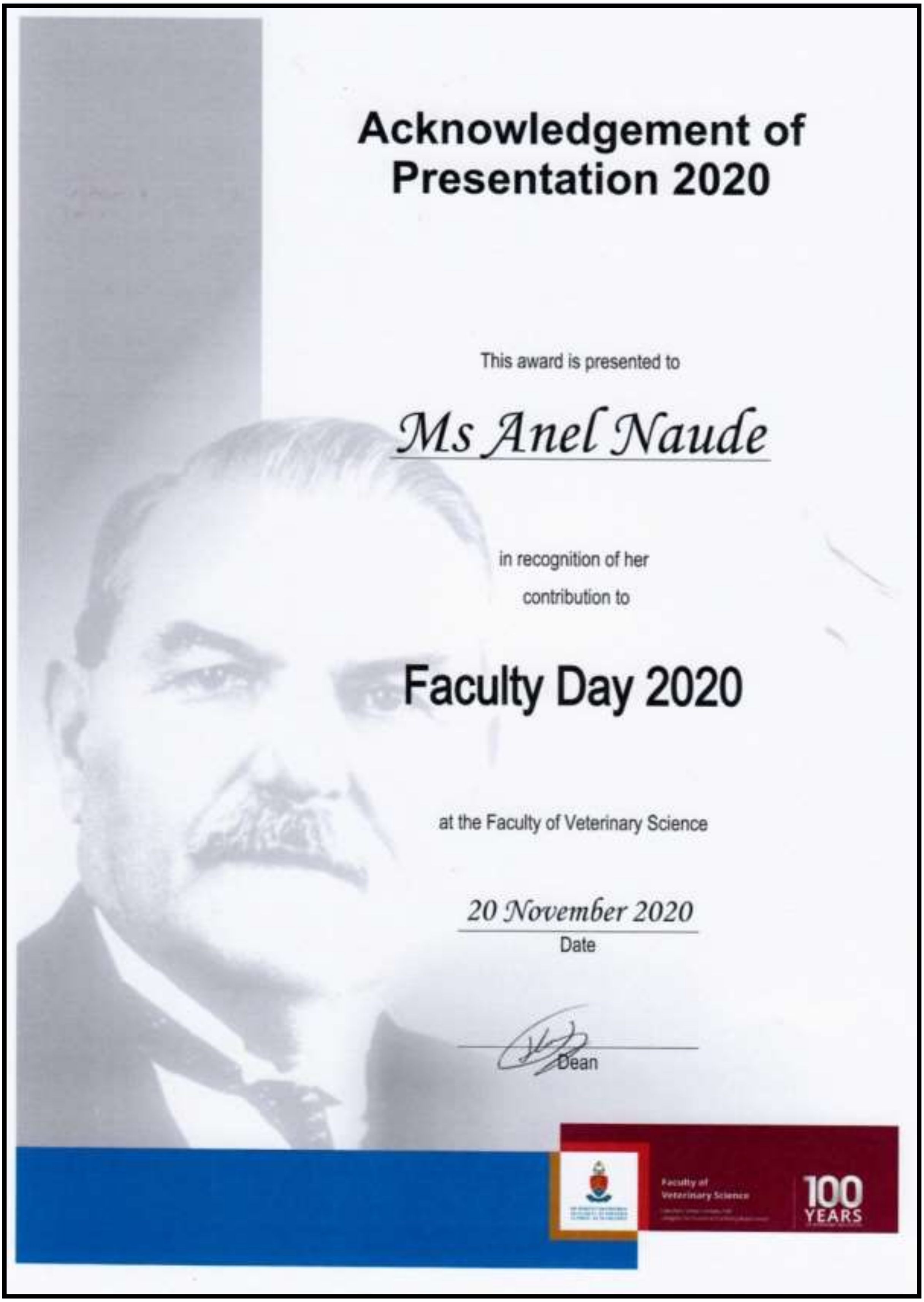

Acknowledgement of Presentation 2020

This award is presented to

Ms Anel Naude

in recognition of her

contribution to

Faculty Day 2020

at the Faculty of Veterinary Science

20 November 2020

Date

Dean

Faculty of Veterinary Science

100 YEARS