

Isoflurane maintenance of neuroanaesthesia in two dogs with hydrocephalus and syringohydromyelia undergoing ventriculoperitoneal shunt surgery

Friederike Pohlin,^{1,2,3,*} Keagan John Boustead,^{1,2} Justin Frederick Grace,^{1,2}

Gareth Zeiler^{1,2}

¹Department of Companion Animal Clinical Studies, University of Pretoria, Onderstepoort, South Africa

²Anaesthesia and Critical Care Service, Valley Farm Animal Hospital, Pretoria, South Africa

³Research Institute of Wildlife Ecology, Department of Interdisciplinary Life Sciences, University of Veterinary Medicine Vienna, Vienna, Austria

*Correspondence to Dr Friederike Pohlin; email: friederike.pohlin@vetmeduni.ac.at

Abstract

A two-year-old spayed female great dane crossbreed dog and a three-year-old spayed female Yorkshire terrier were presented for surgical correction of hydrocephalus and syringohydromyelia. Obstruction of cerebrospinal fluid flow and associated increase in cerebrospinal fluid volume commonly result in an elevated intracranial pressure. During anaesthesia, maintaining an optimal balance between intracranial pressure and cerebral perfusion is crucial to avoid neuronal damage. Volatile anaesthetics are the most commonly used drugs for maintaining anaesthesia in veterinary practice but have the potential to cause an increase in intracranial pressure through vasodilation. This case series describes inhalational maintenance of neuroanaesthesia for ventriculoperitoneal shunt surgery with isoflurane. Interventions applied to manipulate the anaesthetic drug's effects on intracranial pressure to maintain optimal cerebral perfusion are described.

Keywords: anaesthesia; neurosurgery; dogs; neuropathology; central nervous system (CNS)

Background

Hydrocephalus and syringohydromyelia are congenital or acquired neurological disorders in dogs that are characterised by an increased cerebrospinal fluid (CSF) volume within the cranial cavity or central canal, respectively.^{1,2} The increased volume of CSF results from inadequate movement of CSF from its point of production within the ventricular system to its point of absorption into the systemic circulation.¹ The central nervous system consists of three compartments: brain parenchyma, blood and CSF, which are contained within a rigid, non-expandable skull.³ According to the Monro-Kellie doctrine, an increase in volume in one of the compartments will be compensated for by a decrease in volume in one or both of the other two.³ If this intercompartmental volume compensation is exceeded, further accumulation of CSF may lead to an increase in intracranial pressure (ICP) in patients suffering from hydrocephalus.^{1,4} Neurological deficits resulting from hydrocephalus are

unspecific and include abnormal behaviour, cognitive dysfunction, disturbed consciousness, ataxia, circling, blindness, seizures and vestibular dysfunction.^{1, 5} It has been reported that the intensity of clinical signs is dependent on the increase in ICP.⁴ Normal ICP amounts to 14 ± 3 cmH₂O, but pressures as high as 40 cmH₂O have been reported in dogs suffering from hydrocephalus.⁶

Surgical management of hydrocephalus aims to establish a controlled CSF flow from the ventricles into the peritoneal cavity by placing a ventriculoperitoneal shunt.⁷ Anaesthesia for patients undergoing this neurosurgical procedure, and neurosurgery in general (neuroanaesthesia), should provide haemodynamic and cerebral blood flow (CBF) stability, maintain cerebral perfusion pressure (CPP) and cerebral oxygenation, reduce cerebral metabolic rate (CMR), avoid increases ICP and guarantee rapid recovery to allow for prompt neurological assessment of the patient^{5, 8}

To date, two neuroanaesthetic modalities are being used: total intravenous anaesthesia and inhalational anaesthesia.⁹ Propofol on its own, or in combination with opioid agonists or benzodiazepine agonists, is the preferred drug for maintenance of neurosurgical anaesthesia in human and veterinary patients.^{10, 11} It protects cerebral neuronal function in compromised patients and decreases CMR and ICP.⁸⁻¹⁰

However, in patients with elevated ICP, such as animals suffering from hydrocephalus, propofol may significantly drop CPP.¹²

Volatile anaesthetic drugs, in contrast, are the most commonly used anaesthetics for maintaining general anaesthesia in veterinary practice.¹⁰ Isoflurane is a cost-effective inhalant anaesthetic that provides relative haemodynamic stability and allows for rapid change in anaesthetic depth and a swift recovery and neurological assessment.¹³ Even though isoflurane causes a dose-dependent increase in CBF, potentially increasing ICP, accumulated clinical experience with this volatile anaesthetic may improve patient safety.^{8, 14}

In the present case series, isoflurane was used to maintain neuroanaesthesia in two dogs with hydrocephalus and syringohydromyelia undergoing ventriculoperitoneal shunt surgery. Anaesthetic choice together with factors affecting cerebrovascular autoregulation in these patients are discussed.

Case presentation

Case 1

A two-year-old spayed female great dane crossbreed dog, weighing 47.5 kg, presented to Valley Farm Animal Hospital, Pretoria, South Africa, for surgical correction of a hydrocephalus. Panventriculomegaly, an arachnoid diverticle of the fourth ventricle, and syringohydromyelia had been diagnosed seven days before presentation based on an MRI scan (1.5 Tesla; Ingenia MRI system; Phillips, South Africa) (figure 1). An anatomical abnormality obstructing CSF flow through the foramen of Luschka was suspected to be the underlying cause of the dog's condition.

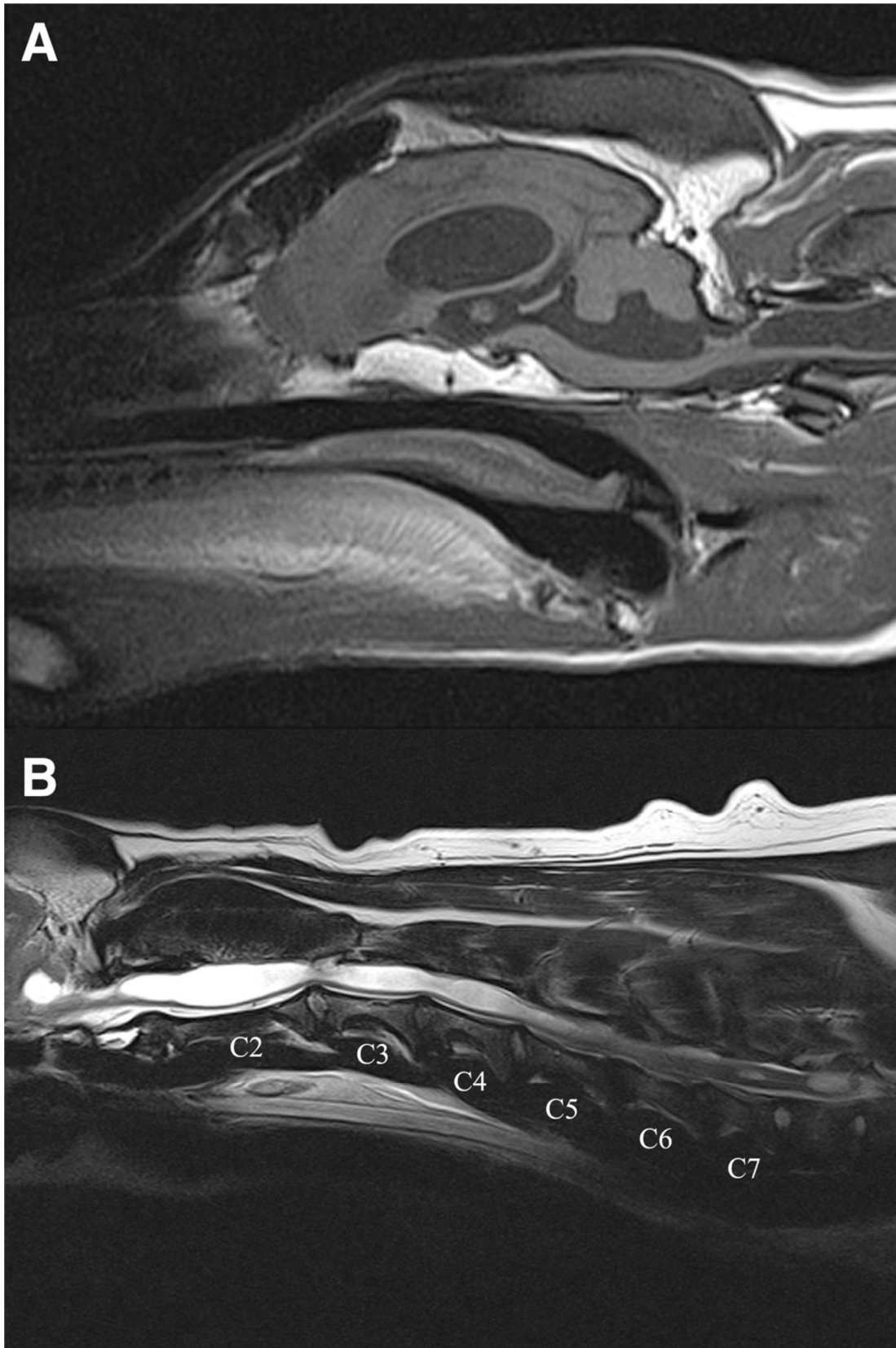


Figure 1. MRI image of a two-year-old female spayed great dane crossbreed dog. (A) A midsagittal T1-weighted MRI of the brain revealing the panventriculomegaly. (B) A midsagittal T2-weighted MRI of the cervical spine revealing the severely diffuse syringohydromyelia. The severe dilation of the central canal extends caudally to L3.

The patient presented bright, alert and responsive with moderate ataxia and a hypermetric gate, leaning towards the right. Cranial nerve examination, segmental spinal reflexes and skin sensation were normal, but a horizontal nystagmus was noticed.

Haematological and serum biochemical findings were within normal reference intervals for dogs. On the day of surgery, an intravenous catheter (18 G Jelco, Smiths Medical Ltd, South Africa) was placed in the left cephalic vein and mannitol (20 per cent, Fresenius, South Africa) 1 g/kg was administered intravenously over 45 minutes before premedication. Oxygen therapy was started at 3 l/minute by nasal insufflation, and an intravenous bolus of medetomidine (Domitor 1 mg/ml, Orion Pharma, South Africa), 5 µg/kg, was administered. Five minutes later, 5 µg/kg fentanyl (500 µg/10 ml, Fresenius) was administered intravenously followed by an intravenous bolus of midazolam (15 mg/3 ml, Accord healthcare, South Africa), 0.3 mg/kg, another five minutes later. An adequate plane of anaesthesia was reached, allowing for endotracheal intubation without additional administration of propofol. The trachea was intubated with the head slightly elevated using a cuffed 12.0 mm internal diameter (ID) endotracheal tube (ETT) (Surgivet, Smith Medical, Pm Inc, USA). General anaesthesia was maintained with isoflurane (Isofor, Safeline Pharmaceuticals, South Africa) in a mixture of oxygen and air with a fraction of inspired oxygen (FiO₂) of 0.7 and with a fresh gas flow of 1.5 l/minute in a circle breathing system.

Following induction, a CT scan was performed, and the dog was prepared for intracranial surgery. During this time, the dog was breathing spontaneously. The urinary bladder was catheterised with a 12.0 French size Foley catheter (SurgiVet, ClearView) to assess intraoperative and postoperative urine production, and the right dorsal pedal artery was catheterised (Arteriofix 20G/160 mm, Braun, South Africa), using the Seldinger technique, for continuous intraoperative and postoperative monitoring of invasive arterial blood pressure (IBP). Constant rate infusions (CRIs) of medetomidine, 1 µg/kg/hour, and fentanyl, 5 µg/kg/hour, were started, and lactated Ringer's solution (LRS) (Intramed Ringer's-Lactate solution, Fresenius Kabi, South Africa) was administered at 5 ml/kg/hour throughout anaesthesia. Meloxicam (Metacam 5 mg/ml, Boehringer Ingelheim, South Africa), 0.2 mg/kg, was administered subcutaneously, and cefazolin (Zefkol, 1.0 g, Litha Pharma, South Africa), 20 mg/kg, was administered intravenously and repeated every 90 minutes during the procedure.

Once in theatre, the dog was positioned in right pelvic lateral recumbency with the head and shoulders in sternal recumbency and the head elevated. The patient was connected to a multiparameter anaesthesia monitor (Carescape B450 monitor, GE Healthcare, South Africa) for continuous monitoring of a lead II ECG, heart rate (HR), oesophageal temperature (TEMP), peripheral capillary oxygen saturation (SpO₂) and end-tidal carbon dioxide partial pressure (PE'CO₂). The IBP electronic strain gauge transducer was zeroed to atmospheric pressure at the level of the *manubrium sterni* and connected to the anaesthetic monitor for continuously displayed systolic (SAP), mean (MAP) and diastolic (DAP) IBP. Intermittent positive pressure ventilation (IPPV) was started (CBS600; GE Healthcare) with a peak inspiratory pressure of 10 cmH₂ O, positive end-expiratory pressure (PEEP) of 4 cmH₂ O and a respiratory rate (RR) of 12 breaths per minute (brmp), maintaining PE' CO₂ of 36–39 mmHg. Blood glucose concentration was measured every hour during the perianaesthetic period using a portable glucometer (Accu-check instant, Roche, South Africa).

After making the burr hole in the caudal aspect of the parietal bone, lateral to the midline, a cross-shaped incision was made in the dura mater. The ventricular catheter was introduced

using the stylet provided with the shunt system (CSF-Shunt Assembly, low-low pressure CSF- Flow Control Valve, Medtronic, Minneapolis, USA) with depth and angle of insertion based on preoperative evaluation of MR images. The anchor was fitted into the burr hole and sutured to the temporalis muscle. The valve was placed in the cervical region ventrocaudal to the left ear. Next, a flank approach to the abdominal cavity was made. The distal part of the shunt was passed into the abdominal cavity, and the muscular layers were sutured closed around the shunt. A subcutaneous tunnel was made from the site of entrance into the abdominal cavity up to the level of the first cervical vertebra and the distal shunt attached to the valve.

Throughout surgery, an expired fraction of isoflurane (FE'Iso) from 1.2 per cent to 1.6 per cent, together with the medetomidine and fentanyl CRI, resulted in a surgical plane of anaesthesia providing haemodynamic stability. Data were recorded at five-minute intervals during the anaesthetic period. HR ranged from 49 to 65 beats per minute (bepm) and MAP from 78 to 91 mmHg, respectively. SpO₂ remained above 92 per cent, and oesophageal temperature dropped to 34.6°C (lowest recorded temperature) despite the use of forced air warming (Bair hugger warming unit – model 505, 3M, South Africa). We allowed for this mild hypothermia, and no other measures for active patient warming were taken. The blood glucose concentration was 4.9 mmol/l at the beginning of the surgery, and thus, the LRS was replaced with a 2.5 per cent dextrose solution (50 ml dextrose 50 per cent Fresenius in 1 litre LRS) administered at 5 ml/kg/hour for the remainder of the procedure.

The duration of anaesthesia was 255 minutes, and surgery time was 130 minutes. There were no surgical complications. Towards the end of surgery, the dog was weaned from IPPV to manual-assisted ventilation and began to breathe spontaneously within five minutes with an RR of 17 brpm and a PE'CO₂ between 54 and 59 mmHg. Twelve minutes after termination of isoflurane, the laryngeal reflex returned, and the dog was extubated without coughing. Recovery was calm and quiet, and the patient regained consciousness rapidly.

For the first hour after anaesthesia, HR, RR, TEMP and IBP were monitored every 15 minutes, then every hour. The patient was quiet but responsive and remained in sternal recumbency exhibiting horizontal nystagmus. The medetomidine and fentanyl CRIs were continued at the same rate as during the surgery, and the 2.5 per cent dextrose solution was continued at maintenance fluid rate. Every four hours, blood glucose concentration was monitored, and the dog was turned from one side to the other. Dexamethasone (Kortico 2 mg/ml, Bayer Animal Health, South Africa), 0.5 mg/kg, was administered intravenously, and antibiotic therapy consisting of subcutaneous enrofloxacin (Baytril 25 mg/ml, Bayer Animal Health), 2.5 mg/kg once daily, was started.

Due to persistent hypertension (IBP SAP >190 mmHg) and an elevated HR (100–120 bepmm) throughout the night and next day, intravenous mannitol was readministered, and treatment with oral amlodipine (Almadin 10 mg, Aspen Pharmacare, South Africa; 5 mg once daily), a calcium channel blocker, was initiated. The medetomidine and fentanyl CRIs were discontinued, and morphine (15 mg/ml, Fresenius), 0.2 mg/kg, was administered slowly intravenously every four hours to continue providing analgesia. Two days after surgery, the dog was able to stand and walk, although still hypermetric and ataxic, and eat, drink and urinate without support. The arterial catheter was removed, and non-invasive (oscillometric) blood pressure monitoring was continued.

Case 2

A 2.3 kg, three-year-old spayed female Yorkshire terrier presented to the same referral hospital with the primary complaint of acute onset intermittent ataxia and seizures. On clinical examination, the dog was alert and responsive with no obvious neurological deficits. A complete blood count and a serum biochemistry profile was performed, and a severely elevated postprandial bile acid concentration (62.17 $\mu\text{mol/l}$) was the only abnormality noted. As a result, the patient was sent for MRI, which revealed the presence of an obstructive hydrocephalus with cerebellar compression and syringohydromyelia (figure 2); most likely due to the presence of an arachnoid diverticulum in the fourth ventricle. Mild periventricular and mesencephalic duct oedema, indicative of raised ICP, were also evident. Surgical correction by ventriculoperitoneal shunt placement was elected. Before surgery, the dog was placed on oral phenobarbitone (Lethyl 15 mg, Litha Pharma, South Africa; 2 mg/kg twice daily), acetazolamide (Diamox 250 mg, Litha Pharma, South Africa; 20 mg/kg twice daily) and prednisolone (Lenisolone 5 mg, Aspen Pharmacare, South Africa; 1 mg/kg twice daily) for four days in an attempt to improve clinical symptoms. At the time of surgery, the dog was still ataxic, but no further seizures had been reported by the owner.

On the day of surgery, no abnormalities were noted on clinical examination. A venous blood gas analysis was performed and indicated a mild compensated metabolic acidosis (pH 7.37, carbon dioxide venous partial pressure: 31 mmHg, base excess: -7.5 mmol/l, bicarbonate: 18.6 mmol/l) most likely resulting from the acetazolamide treatment. Preparation, premedication, induction, maintenance and monitoring of anaesthesia as well as the surgical procedure itself were performed as described in case 1. The trachea was intubated with a cuffed 4.5 mm ID ETT, and isoflurane was delivered in 100 per cent oxygen via a paediatric circle breathing system. FE'Iso was kept between 0.6 per cent and 0.8 per cent throughout the procedure, and medetomidine and fentanyl CRIs were administered at 1 $\mu\text{g/kg/hour}$ and 5 $\mu\text{g/kg/hour}$, respectively. IPPV was performed with a peak inspiratory pressure of 10 cmH₂O, PEEP of 0 cmH₂O and an RR of 20–25 brmp, maintaining PE'CO₂ of between 35 and 40 mmHg. HR ranged from 40 to 77 bpm and MAP from 56 to 121 mmHg throughout the procedure. MAP peaked above 100 mmHg on two occasions but returned to below 100 mmHg without intervention. SpO₂ remained above 95 per cent. Oesophageal temperature dropped to a minimum of 32.5°C but increased to 35.1°C with the use of forced air warming.

The duration of anaesthesia was 125 minutes, and surgery time was 100 minutes. No surgical complications were experienced. At the end of the surgery, the dog was weaned from the ventilator, and isoflurane administration was terminated. Twenty-five minutes after termination of the isoflurane, the dog was extubated on return of the lateral palpebral reflex. Recovery was calm, but the patient remained heavily sedated. Medetomidine and fentanyl CRIs were continued at the same rate during the recovery period and the following 12 hours. HR, RR, TEMP and IBP were monitored continuously during the first hour of recovery and hourly for the following 12 hours. During this period, all measured parameters remained stable with a MAP between 64 and 109, HR between 100 and 110 bpm and a TEMP between 36°C and 38.5°C. The patient, however, remained heavily sedated. Consequently, the medetomidine and fentanyl CRIs were terminated, and within four hours, the patient regained consciousness and was able to walk, although ataxic, eat and urinate. Additional postoperative treatment included cefazolin, 20 mg/kg, administered intravenously every eight hours, phenobarbitone, 2 mg/kg, administered orally twice daily and prednisolone, 1 mg/kg, administered orally once daily.

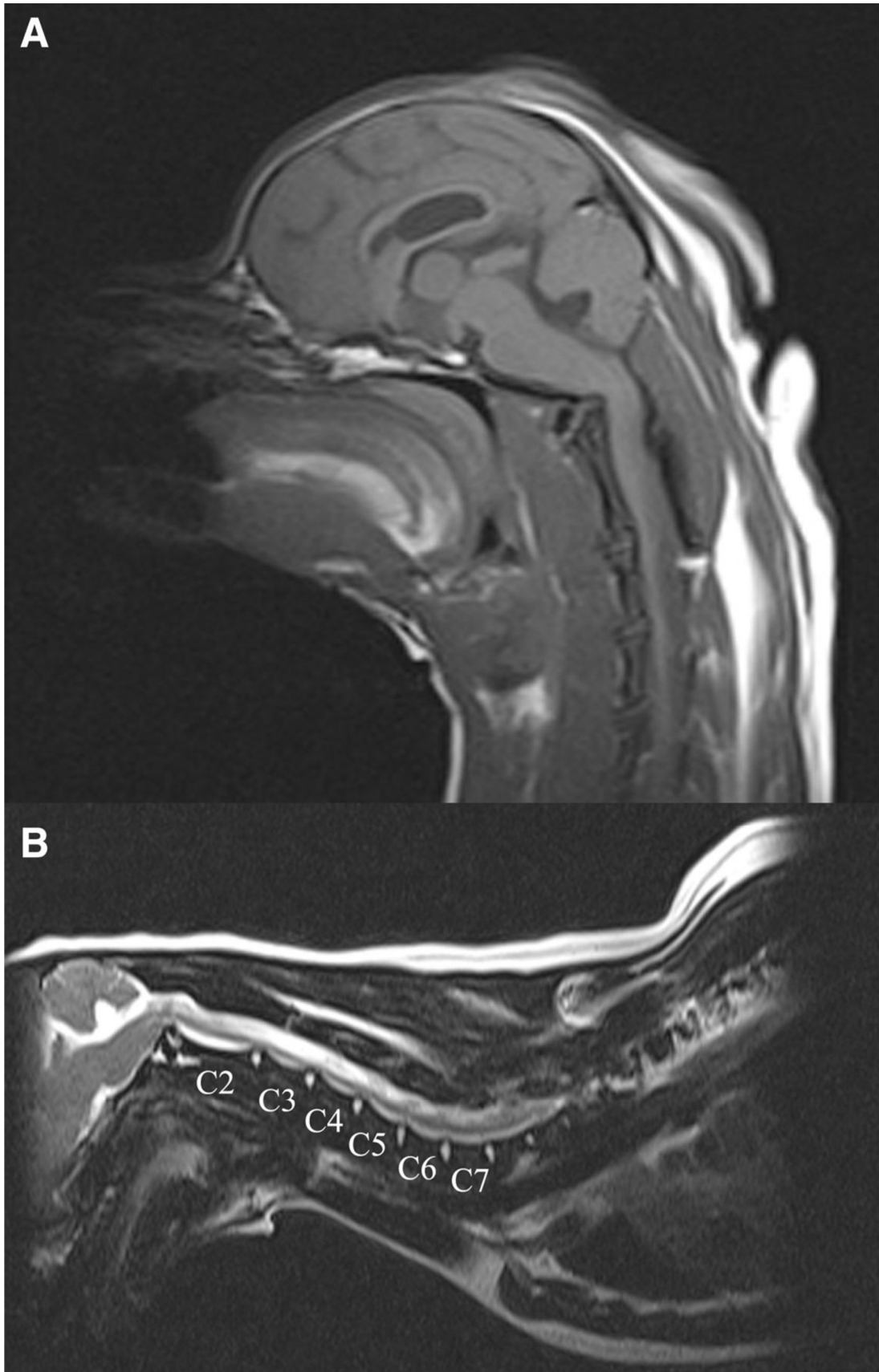


Figure 2. MRI image of a three-year-old female spayed Yorkshire terrier. (A) A midsagittal T1-weighted MRI of the brain revealing the panventriculomegaly. (B) A midsagittal T2-weighted MRI of the cervical spine revealing the diffuse intramedullary lesion consistent with syringohydromyelia.

Outcome and follow-up

Case 1

Clinical symptoms gradually improved over the next five days. One week after surgery, the dog was discharged home with oral marbofloxacin (Zeniquin 100 mg, Zoetis, South Africa; once daily), amlodipine (5 mg once daily), gabapentin (300 mg, Biotech, South Africa; twice daily) and gastro-protectants. Two weeks later, the patient presented for a follow-up physical examination and was bright, alert and responsive with no more nystagmus. Although its gait was no more hypermetric, mild ataxia and leaning towards the right were still present. At the time of writing this case report, the patient was still on amlodipine and gabapentin treatment improving clinically.

Case 2

The dog was discharged four days after surgery with oral prednisolone, 0.5 mg/kg, once daily and oral phenobarbitone, 2 mg/kg, twice daily. Four days postoperatively, the patient presented for a follow-up examination; the patient was bright, alert and responsive but was still experiencing intermittent episodes of ataxia. Similar findings were also found 14 days postoperatively when the patient presented for suture removal. One month following suture removal, a follow-up MRI revealed marked improvement of the hydrocephalus and syringohydromyelia although the intermittent ataxia was still present. The oral prednisolone and phenobarbitone were ended three weeks postoperatively.

Discussion

In this case series, we describe the use of inhalational neuroanaesthesia with isoflurane in two dogs with hydrocephalus and syringohydromyelia undergoing ventriculoperitoneal shunt surgery.

The syringohydromyelia in these dogs was likely the result of an increased pressure gradient between the cranial and spinal systems caused by an increased ICP associated with the hydrocephalus.¹⁵ The neurological signs observed in both patients were also suggestive of an increased or at least high ICP because the compensatory changes in a closed cranial vault were likely at their limits.

The most important goals in the management of anaesthetised patients with hydrocephalus are to maintain cerebral perfusion and oxygenation by maintaining ICP at acceptable levels.⁵ Isoflurane is therefore often avoided in patients with intracranial pathologies as this volatile anaesthetic drug has a cerebral vasodilatory effect reducing cerebrovascular resistance and increasing CBF and ICP.^{8, 9, 16} In both of our cases, specific treatments that aimed towards preventing a further increase in ICP and promoting cerebral autoregulation were implemented allowing for haemodynamic and CBF stability during isoflurane anaesthesia.

First, a thorough preanaesthetic assessment and stabilisation was done in both patients to allow for safe anaesthesia and neurosurgical success.¹⁷ Case 2, which had a history of seizures, received phenobarbitone and acetazolamide in preparation for neuroanaesthesia. At anaesthetic doses, phenobarbitone has shown to protect the brain against ischaemic events and cause dose-dependent changes in CBF and cerebral oxygen consumption.^{18, 19} Acetazolamide, a carbonic anhydrase inhibitor, lowers ICP by decreasing CSF secretion.²⁰

Although anaesthetic doses of phenobarbitone are much higher than those used for the seizure management in our patient, presurgical stabilisation with this drug, together with the acetazolamide, may have had an initial beneficial effect in our patient and may be useful for patients undergoing neuroanaesthesia in general.

In order to reduce ICP before induction and maintenance of anaesthesia, we administered mannitol to both patients. Mannitol is an osmotic diuretic withdrawing fluids into the intravascular compartment effecting initial intracranial decompensation and correction of pre-existing cerebral oedema.⁵ It has antioxidative properties and decreases blood viscosity by increasing blood volume and shrinking red blood cells, thus improving CBF and tissue oxygenation.¹⁷

In order to avoid an increase in ICP associated with sympathetic activation during induction,⁵ we premedicated our patients with a combination of medetomidine, fentanyl and midazolam, administered at five-minute intervals. Alpha2-adrenoceptor-agonists, like medetomidine, have the potential to cause systemic hypotension and reduce CBF via α 2-receptor-mediated cerebral vasoconstriction.²¹ However, the sedative effects of α 2-agonists are mediated via pathways that also make them promising neuroprotective agents. These pathways include sympatholytic, glutamine oxidation stimulating and antiapoptotic effects.²² Because of these effects, alpha2-adrenoceptor agonists are currently gaining popularity in veterinary and even human neuroanaesthesia.^{22, 23} Fentanyl and midazolam only have minimal direct effects on CBF and CMR and are therefore regarded as optimal premedication agents for neurosurgical procedures.⁵ Fentanyl is known to attenuate haemodynamic responses to intubation and midazolam produces depression of upper airway reflexes, facilitating tracheal intubation without increasing ICP through coughing or gagging.²⁴ To reduce the risks of hypoxaemia associated with respiratory depression of the premedication drugs and potential struggle with intubation, we preoxygenated our patients. In both of our cases, premedication and preoxygenation allowed for a smooth induction with a calm and rapid intubation of the trachea without inducing a coughing response.

Anaesthesia was maintained with isoflurane in oxygen. To ensure adequate cerebral oxygenation throughout the procedure, a FiO₂ of 0.7–1.0 was provided. Oxygen is an important factor in neuroanaesthesia as CBF will increase if arterial oxygen partial pressure drops below 60 mmHg.²⁵ Further protection of the brain from any hypoxic injury was achieved by allowing for mild hypothermia (32°C–35°C) and decrease in CMR.^{26, 27} At the same time, the brain's energy requirements were met by monitoring and supplementing blood glucose.

During neuroanaesthesia, it is essential to ensure an adequate CPP and provide constant CBF while avoiding increases in ICP.²³ Isoflurane is known to have a dose-dependent cerebral vasodilatory effect with concentrations below 1.4 per cent in dogs maintaining CBF autoregulation.²⁸ We therefore tried to reduce isoflurane requirements by coadministering medetomidine and fentanyl as CRIs. Both of these drugs have analgesic properties and provide a considerable anaesthetic-sparing effect reducing the minimal alveolar concentration of isoflurane by up to 47.2 per cent^{29, 30} and 76.9 per cent,³¹ respectively. Besides having a remarkable MAC-sparing effect, medetomidine has been shown to have multiple other favourable clinical effects such as the sympatholytic, sedative and opioid sparing effects.²² Harmful cerebral vasodilation induced by the isoflurane may be attenuated by the vasoconstrictive action of the α 2-agonist.²³ The most common adverse effects associated with this drug are hypertension and bradycardia, and therefore, care should be taken when using

medetomidine in cardiovascular-compromised patients.³⁰ The synthetic μ -opioid agonist fentanyl is considered to decrease CMR with minimal change on CBF but may cause marked respiratory depression.³² In case 1, the use of medetomidine and fentanyl CRIs resulted in a consistent requirement for FE'Iso of 1.5 (mean \pm 0.1 SD) per cent, slightly exceeding this vasodilatory threshold. In case 2, the same infusion rates allowed for FE'Iso to be kept below 0.8 per cent. This patient, however, was receiving phenobarbitone that may have contributed to the decreased isoflurane requirements. Increasing the infusion rate of the fentanyl CRI might have been indicated to further reduce sympathetic stimulation and pain associated with the procedure in case 1 and allow for a more successful reduction of isoflurane requirements.³³ Alternatively, the addition of a lidocaine and/or midazolam CRI has been recommended for their inhalant and injectable anaesthetic-sparing effects in veterinary patients undergoing neuroanaesthesia.³⁴ Lidocaine, in particular, may reduce secondary brain injury by preventing sodium influx into ischaemic neurons and is commonly used in head trauma patients.^{33,34}

To minimise any isoflurane-associated cerebral vasodilation and increase in ICP, IPPV was performed in both cases.⁵ By producing hypocapnia through hyperventilation, the vasodilatory effect of the volatile anaesthetic drug concentration can be counteracted.⁷ There is a linear relationship between arterial partial pressure of carbon dioxide (PaCO₂), CBF and ICP, with an approximate increase of 2 per cent–6 per cent in CBF per mmHg CO₂.²⁵ However, there is no advantage to aggressively decreasing the PaCO₂ for prolonged periods of time, as the oxygen–haemoglobin dissociation curve will shift to the left, reducing tissue delivery of oxygen and potentially causing cerebral hypoxia.³⁵ Current recommendations therefore suggest maintaining a low normal PaCO₂ of around 35 mmHg, with PE'CO₂ between 35 and 38 mmHg,²³ which was applied in both cases.

When performing IPPV, excessive inflation pressure or PEEP may cause unnecessary increases in central venous pressure and increase ICP.⁵ However, PEEP is proposed to reduce the incidence of postoperative respiratory complications by preventing atelectasis and improving oxygenation.³⁶ In neuroanaesthesia, PEEP is not routinely applied as controversy exists as to whether a rise in ICP would be the consequence. Shapiro and Marshall³⁷ showed an increase in ICP of up to 10 mmHg after applying 4–8 cmH₂O of PEEP in human patients with head injury.³⁷ Mascia and others,³⁸ in contrast, found that ICP remained stable after applying 5 and 10 cmH₂O of PEEP if alveolar recruitment was caused and hyperinflation was avoided.³⁸ Therefore, to reduce the likelihood of increasing central venous pressure by performing IPPV, we only used conservative airway pressures in our cases. Because we expected a greater risk for the development of atelectasis in case 1, which was a large breed dog, a small PEEP of 4 cm H₂O was applied. In case 2, PEEP was not performed; however, the ascending bellow ventilator has an operational PEEP of 2 cmH₂O. Both patients experienced no complications with regards to ventilation and oxygenation. To further limit any increase in ICP resulting from an increase in central venous pressure and IPPV, we elevated the patients' head and administered intravenous fluids at a conservative rate.¹⁷ These nursing techniques helped reduce blood volume within the CNS by avoiding jugular occlusion and facilitating venous drainage.¹⁷ Importantly, surgery itself also provided intracranial hypertension relief by improving CRF drainage.⁵

To ensure normal postoperative brain function, it is essential to minimise any perioperative secondary brain injury due to ischaemia. This can be achieved by ensuring an adequate CPP and maintaining MAP between 80 mmHg and 100 mmHg.¹⁰ In case 1, despite the relatively high isoflurane requirement, MAP was maintained at 83.4 \pm 3.5 mmHg meeting this

recommendation. The vasoconstrictive action of the medetomidine CRI has likely attenuated the harmful peripheral and cerebral vasodilation associated with the isoflurane.^{22, 39} In case 2, despite the lower isoflurane requirements, MAP was slightly below this recommendation (70.8 ± 3.1 mmHg), but prolonged systemic hypotension did not occur in any of the cases. Feasible intraoperative monitoring of ICP using subdural and intraparenchymal miniature strain-gauge transducers has been described in dogs and may have been useful to provide timely information needed to guide therapeutic intervention and assess the response to the applied treatment strategies in our patients.⁴⁰ Due to the invasiveness, high cost and required expertise, we were not able to apply this monitoring technique. Non-invasive ICP monitoring based on fluid dynamic, otic, ophthalmic and electrophysiological principles has been described in humans but remains to be validated in veterinary patients.⁴¹

Emergence from general anaesthesia, in both cases, was calm without coughing and haemodynamic responses to tracheal extubation. Within the postoperative period of 36 hours, case 1 developed severe hypertension with a SAP of 202 ± 14 mmHg and an HR of 94 ± 20 bpm. Systemic hypertension is a frequent complication in patients that underwent intracranial surgical procedures and is often associated with increased ICP.⁴² In order to maintain CPP, the so-called Cushing reflex, raises systemic blood pressure above ICP, a mechanism accompanied by bradycardia and an altered breathing pattern.¹⁷ In an attempt to reduce the possible increase in ICP, we readministered mannitol without success. We believe that, as case 1 had also had an elevated HR, activation of the sympathetic nervous system might have been a more likely cause of the postoperative systemic hypertension than a Cushing reflex.⁴³ After stopping the CRIs, we continued providing analgesia by administering morphine and, later, gabapentin. Moreover, antihypertensive treatment with amlodipine, a calcium channel blocker, was started and blood pressure decreased gradually over the next four weeks. Unfortunately, in both cases, we did not measure blood pressure before the surgical intervention and were therefore unaware of the patients' initial values. Perioperative blood pressure monitoring is essential for the detection and treatment of hypotension/hypertension and should have been implemented from the beginning.²⁷

In case 2, the medetomidine and fentanyl CRIs caused severe sedation during the recovery period and the following 12 hours. Only once these CRIs were terminated could the patient's neurological status be evaluated. Titration of these infusions soon after end of surgery may have been more beneficial, rather than following strict protocols, to allow for more rapid evaluation of the patients neurological status.

In both patients, the administration of paracetamol or the use of a lidocaine patch or CRI might have been a good alternative to decrease sympathetic activation associated with pain (case 1) and provide analgesia without excessive sedation (case 2).³⁵ Local anaesthetic scalp blockade is commonly performed in human neuroanaesthesia and may have been applicable in our patients together with local anaesthetic infiltration of the abdominal surgery site.³³

Learning points

- Anaesthesia in patients suffering from hydrocephalus can be maintained with isoflurane as long as specific treatments and nursing techniques are implemented that aim towards preventing a further increase in intracranial pressure.
- The coadministration of medetomidine and fentanyl by constant rate infusion decreases isoflurane requirements during the intraoperative period.

- Ventilator adjustments allowing for mild hyperventilation may help counteract the vasodilatory effects of the isoflurane.
- Monitoring heart rate and blood pressure is important in patients suffering from hydrocephalus and should be performed during the entire perioperative period.
- While it is important to provide analgesia, drugs should be titrated to effect considering individual patient needs.

Contributors

All authors were involved with the anaesthetic management of one, or both, cases and contributed to the writing of the case report. All authors have approved the final manuscript.

Funding

The authors have not declared a specific grant for this research from any funding agency in the public, commercial or not-for-profit sectors.

Competing interests

None declared.

Data availability statement

All data relevant to the study are included in the article.

References

- 1 Thomas WB. Hydrocephalus in dogs and cats. *veterinary clinics of North America. Vet Clin North Am Small Anim Pract* 2010; 143– 59.
- 2 Itoh T, Nishimura R, Matsunaga S, et al. Syringomyelia and hydrocephalus in a dog. *J Am Vet Med Assoc* 1996; 209: 934– 6.
- 3 Kim D-J, Czosnyka Z, Kasprowicz M, et al. Continuous monitoring of the Monro-Kellie doctrine: is it possible? *J Neurotrauma* 2012; 29: 1354– 63.
- 4 Przyborowska P, Adamiak Z, Jaskolska M, et al. Hydrocephalus in dogs: a review. *Vet Med* 2013; 58: 73– 80.
- 5 Court MH, Dodman NH, Norman WM, et al. Anaesthesia and central nervous system disease in small animals. Part I: general considerations. *Br Vet J* 1990; 146: 285– 95.
- 6 Schmidt M, Ondreka N. Hydrocephalus in Animals. In: G Cinalli, M Özek, C Sainte-Rose, eds. *Pediatric hydrocephalus*. Springer, 2019: 53– 95.
- 7 Shihab N, Davies E, Kenny PJ, et al. Treatment of hydrocephalus with ventriculoperitoneal shunting in twelve dogs. *Vet Surg* 2011; 40: 477– 84.
- 8 Weglinski MR, Perkins WJ. Inhalational versus total intravenous anesthesia for neurosurgery: theory guides, outcome decides. *J Neurosurg Anesthesiol* 1994; 6: 290– 3.
- 9 Zuleta-Alarcón A, Castellón-Larios K, Nino-de Mejía MC, et al. Total intravenous anaesthesia versus inhaled anaesthetics in neurosurgery. *Rev Colomb Anesthesiol* 2015; 43: 9– 14.
- 10 Rasis AL, Leece EA, Platt SR, et al. Evaluation of an anaesthetic technique used in dogs undergoing craniectomy for tumour resection. *Vet Anaesth Analg* 2007; 34: 171– 80.

- 11 Dinsmore J. Anaesthesia for elective neurosurgery. *Br J Anaesth* 2007; 99: 68– 74.
- 12 Herregods L, Verbeke J, Rolly G, et al. Effect of propofol on elevated intracranial pressure. Preliminary results. *Anaesthesia* 1988; 43 Suppl: 107– 9.
- 13 Keegan RD, Greene SA. Cardiovascular effects of a continuous two-hour propofol infusion in dogs. Comparison with isoflurane anesthesia. *Vet Surg* 1993; 22: 537– 43.
- 14 Brodbelt D. The Confidential enquiry into perioperative small animal fatalities. *Royal Veterinary College, University of London and Animal Health Trust* 2006.
- 15 Bagley RS. Syringomyelia: an emerging spinal disease in dogs. *Ir Vet J* 2007; 60: 35– 8.
- 16 Chohan AS, Greene SA, Keegan RD, et al. Intracranial pressure and cardiopulmonary variables during isoflurane or sevoflurane anesthesia at various minimum alveolar concentration multiples in normocapnic dogs. *Am J Vet Res* 2013; 74: 369– 74.
- 17 Dugdale A. Chapter 45, Background to neuroanaesthesia for the brain. In: *Veterinary anaesthesia: principles to practice*. Oxford, UK: Blackwell Publishing Ltd, 2010: 337– 40.
- 18 Nilsson L, Siesjö BK. The effect of phenobarbitone anaesthesia on blood flow and oxygen consumption in the rat brain. *Acta Anaesthesiol Scand Suppl* 1975; 57: 18– 24.
- 19 Nordström CH, Rehncrona S, Siesjö BK. Effects of phenobarbital in cerebral ischemia. Part II: restitution of cerebral energy state, as well as of glycolytic metabolites, citric acid cycle intermediates and associated amino acids after pronounced incomplete ischemia. *Stroke* 1978; 9: 335– 43.
- 20 Uldall M, Botfield H, Jansen-Olesen I, et al. Acetazolamide lowers intracranial pressure and modulates the cerebrospinal fluid secretion pathway in healthy rats. *Neurosci Lett* 2017; 645: 33– 9.
- 21 Sinclair MD. A review of the physiological effects of alpha2-agonists related to the clinical use of medetomidine in small animal practice. *Can Vet J* 2003; 44: 885– 97.
- 22 Farag E, Argalious M, Sessler DI, et al. Use of $\alpha(2)$ -Agonists in Neuroanesthesia: An Overview. *Ochsner J* 2011; 11: 57– 69.
- 23 Tayari H, Bell A. Dexmedetomidine infusion as perioperative adjuvant in a dog undergoing craniotomy. *Vet Rec Case Rep* 2019; 7: e000727– 6
- 24 Covey-Crump GL, Murison PJ. Fentanyl or midazolam for co-induction of anaesthesia with propofol in dogs. *Vet Anaesth Analg* 2008; 35: 463– 72
- 25 Greene NH, Lee LA. Modern and evolving understanding of cerebral perfusion and autoregulation. *Adv Anesth* 2012; 30: 97– 129
- 26 Mackensen GB, McDonagh DL, Warner DS. Perioperative hypothermia: use and therapeutic implications. *J Neurotrauma* 2009; 26: 342– 58.

- 27 Otto KA. Physiology, Pathophysiology, and Anesthetic Management of Patients with Neurologic Disease. In: KA Grimm, WJ Tranquilli, SA Greene, et al, eds. *Veterinary anaesthesia and analgesia*. 5th edn. Iowa, USA: John Wiley & Sons, Inc, 2015: 559– 83.
- 28 McPherson RW, Traystman RJ. Effects of isoflurane on cerebral autoregulation in dogs. *Anesthesiology* 1988; 69: 493– 9
- 29 Ewing KK, Mohammed HO, Scarlett JM, Short CE, et al. Reduction of isoflurane anesthetic requirement by medetomidine and its restoration by atipamezole in dogs. *Am J Vet Res* 1993; 54: 294– 9
- 30 Rioja E, Gianotti G, Valverde A. Clinical use of a low-dose medetomidine infusion in healthy dogs undergoing ovariohysterectomy. *Can Vet J* 2013; 54: 864– 8.
- 31 Williamson AJ, Soares JHN, Pavlisko ND, et al. Isoflurane minimum alveolar concentration sparing effects of fentanyl in the dog. *Vet Anaesth Analg* 2017; 44: 738– 45.
- 32 Ostapkovich ND, Baker KZ, Fogarty-Mack P, et al. Cerebral blood flow and CO₂ reactivity is similar during remifentanyl/N₂O and fentanyl/N₂O anesthesia. *Anesthesiology* 1998; 89: 358– 63
- 33 Leece E, Seymour M. Neurological disease. In: T Duke-Novakovski, M Vries, M Seymour, eds. *BSAVA manual of canine and feline anaesthesia and analgesia*. 3rd edn. British Small Animal Association, 2018: 392– 408.
- 34 Vieitez V, Álvarez Gómez de Segura I, López Rámis V, et al. Total intravenous anaesthesia in a goat undergoing craniectomy. *BMC Vet Res* 2017; 13
- 35 Solano MEC, Castillo IB, de Mejía MCN. Hypocapnia in Neuroanesthesia: current situation. *Rev Colomb Anesthesiol* 2012; 40: 137– 44.
- 36 Hopper K, Powell LL. Basics of mechanical ventilation for dogs and cats. *Vet Clin North Am Small Anim Pract* 2013; 43: 955– 69.
- 37 Shapiro HM, Marshall LF. Intracranial pressure responses to PEEP in head-injured patients. *J Trauma* 1978; 18: 254– 6
- 38 Mascia L, Grasso S, Fiore T, et al. Cerebro-pulmonary interactions during the application of low levels of positive end-expiratory pressure. *Intensive Care Med* 2005; 31: 373– 9
- 39 Ohata H, Iida H, Dohi S, et al. Intravenous dexmedetomidine inhibits cerebrovascular dilation induced by isoflurane and sevoflurane in dogs. *Anesth Analg* 1999; 89: 370– 7.
- 40 Sturges BK, Dickinson PJ, Tripp LD, et al. Intracranial pressure monitoring in normal dogs using subdural and intraparenchymal miniature strain-gauge transducers. *J Vet Intern Med* 2019; 33: 708– 16.
- 41 Canac N, Jalaleddini K, Thorpe SG, et al. Review: pathophysiology of intracranial hypertension and noninvasive intracranial pressure monitoring. *Fluids Barriers CNS* 2020; 17

42 Basali A, Mascha EJ, Kalfas I, et al. Relation between perioperative hypertension and intracranial hemorrhage after craniotomy. *Anesthesiology* 2000; 93: 48– 54.

43 Haas CE, LeBlanc JM. Acute postoperative hypertension: a review of therapeutic options. *Am J Health Syst Pharm* 2004; 61: 1661– 73.