Salmonella enterica serovar Typhimurium bacteraemia in a puppy with canine parvoviral enteritis.

Josef Hanekom[1,*], Paolo Pazzi[1], Yolandi Rautenbach[1], Alischa Henning[2]

[1]Companion Animal Clinical Sciences, University of Pretoria Faculty of Veterinary Science, Pretoria, Gauteng, South Africa

[2]Paraclinical Sciences, University of Pretoria Faculty of Veterinary Science, Pretoria, Gauteng, South Africa

*Correspondence to Dr Josef Hanekom; joe.hanekom@up.ac.za

SUMMARY

A 12-week-old female intact, pit bull terrier cross breed puppy presented with vomiting and haemorrhagic diarrhoea. Phagocytosed bacterial rods were observed on peripheral and central blood smears. A commercially available canine parvovirus ELISA test and subsequent electron microscopy for viral particles both tested negative on faecal sampling. The owners declined treatment and the puppy was euthanased. The postmortem revealed enteric necrosis, purulent meningoencephalitis, necropurulent hepatitis and diffuse interstitial pneumonia, with heavy *Salmonella enterica* serovar Typhimurium growth on blood and tissue culture. The *Salmonella* species were sensitive to most commonly used antimicrobials including ampicillin. Canine parvovirus enteritis was diagnosed by positive canine parvovirus specific immune-peroxidase staining of intestinal tissue sections. To the authors' knowledge, this is the first paper to describe canine parvoviral enteritis complicated by a salmonella bacteraemia, and the detection of a bacteraemia on a peripheral blood smear in a live dog.

BACKGROUND

This case was of interest as a bacteraemia was detected on a peripheral blood smear examination, during the initial consultation. The authors failed to find other reports of bacteraemia detected on peripheral blood smear in canine patients.

The puppy tested negative on both the canine parvovirus antigen ELISA and negative-staining electron microscopy (EM) with faecal samples. Canine parvovirus enteritis (CPE) was diagnosed only on post-mortem examination by means of immunohistochemistry (IHC).

Salmonella enterica serovar Typhimurium was cultured from blood collected ante-mortem, and organ samples at post-mortem. The presence of Salmonella spp. in the faeces of canine parvovirus (CPV) has been described, but to the

authors' knowledge a bacteraemia with salmonella has not been detected in a dog with CPE before (1).

CASE PRESENTATION

A 12-week-old female intact, pit bull terrier cross breed puppy presented with clinical signs consistent with CPE. The puppy was inappetent, vomiting and had haemorrhagic diarrhoea for the four days before presentation. The puppy was fed standard cooked, commercial dog food. The dog was reported to have been dewormed and had received one initial puppy vaccination, both three weeks before presentation. The owner had no record of the vaccine or deworming products used.

The dog presented as lethargic and severely dehydrated (10-12%), with a low body condition score (2/5), tachycardic (144bpm), tachypnoeic (44bpm), with mild pyrexia (39.3°C), pale pink mucous membranes and a markedly delayed capillary refill time (3-4s). Haemorrhagic diarrhoea and retching were observed during consultation.

INVESTIGATIONS

A peripheral blood smear performed at presentation showed severe leucopenia with toxic neutrophils, reactive monocytes and a moderate thrombocytopenia. Intracellular bacterial rods were noted within the neutrophils and reactive monocytes. No significant findings were detected on faecal floatation and faecal wet preparation examination. A commercially available CPV antigen ELISA test run on the puppy's faeces tested negative (Canine Parvo Antigen Test Kit, SNAP® Parvo, IDEXX Laboratories Inc). Subsequent EM performed on the puppy's faeces was also negative for viral particles.

With the owner's consent, blood was collected, ante-mortem in an EDTA coated, a 3.2% buffered sodium citrate (citrate) and a serum vacuum collection tube (BD Vacutainer®, BD Biosciences Johannesburg) and an additional 10ml of blood was aseptically collected, and injected into a commercially available blood culture medium (BC0102M Oxoid Signal Blood Culture Medium, Oxoid Limited, England) and sent for aerobic culture and antibiogram. Anaerobic culture and antibiogram was not performed. The puppy was then euthanised using intravenous injection of 200mg/kg sodium pentobarbital (Eutha-naze, Bayer, South Africa) and a post-mortem examination performed.

Haematology, canine C-Reactive protein (CRP), and thromboelastography (TEG) was performed within 30 minutes of blood collection. The remaining serum (after clotting) and citrated plasma was spun at 400 rpm or 150 RCF for 8 min in the

Hettich centrifuge (Universal) the serum and citrated plasma decanted and stored at -20℃.

Haematology was performed on the Siemens ADVIA 2120i and the most significant findings were a moderate anaemia, marked leucopenia and a severe thrombocytopenia. (Table 1) Machine differential cell counts could not be calculated due to the severe cellular fragility and marked leucopenia. Central blood smear evaluation revealed that the leukocytes consisted mainly of equal numbers of neutrophils and activated monocytes with very low numbers of small lymphocytes. The majority of the neutrophils displayed a moderate degree of toxicity. Low numbers of phagocytosed bacteria were also noted. (Figure 1)

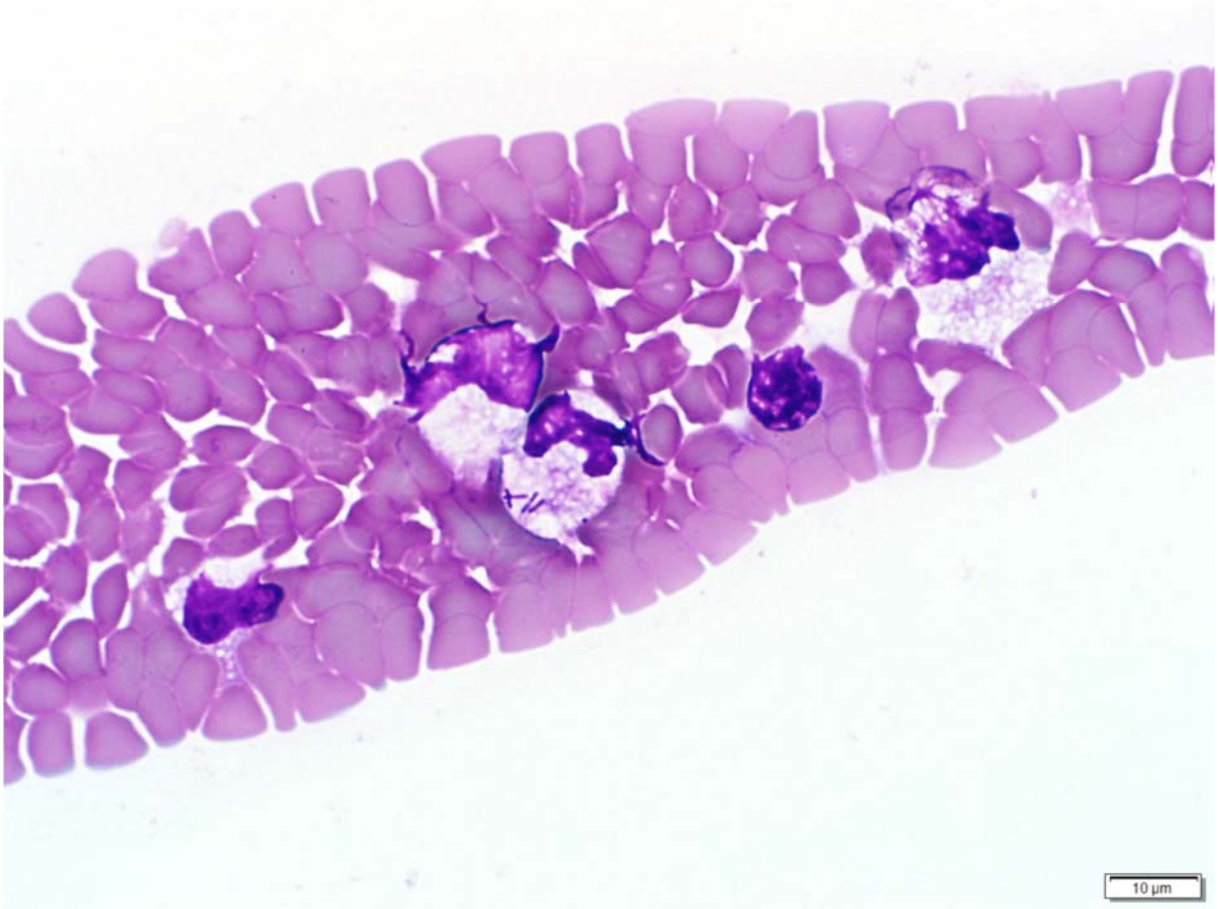

Figure 1 - Blood smear: Low numbers of rod-shaped bacteria present in intracytoplasmic vacuoles in a monocyte along the feather edge of the blood smear. 100 x objective, Diff-Quik stain

Table 1. Haematology results with abnormalities in bold.

Haematology results	Result	Units	Reference Interval
Haemoglobin	**69**	**g/L**	**120-180**
Red cell count	**3.57**	**x10^12/L**	**5.5-8.5**
Haematocrit	**0.22**	**L/L**	**37-0.55**
Mean corpuscular volume	62.7	fL	60-77
Mean corpuscular haemoglobin	19.4	pg	No reference range
Mean corpuscular haemoglobin concentration	**31**	**g/dL**	**32 -36**
Red cell distribution width	15.2	%	No reference range
White cell count	**0.53**	**x10^9/L**	**6 -15**
Platelets	**29**	**x10^9/L**	**200-500**

Serum biochemistry was performed on the stored serum sample, 14 days post collection, on the Cobas Intergra 400 Plus Analyser (Roche) and the most significant findings included a severe hypoalbuminemia, severe hypokalaemia and severely raised CRP. (Table 2) A hand-held glucometer Alphatrak2 (Zoetis), measured a glucose serum concentration of 1.5 mmol/L [RI: 3.3-5.5].

Table 2. Biochemistry results with abnormalities in bold

Biochemical results	Result	Units	Reference interval
Total serum protein	**34.1**	**g/L**	**56-73**
Albumin	**13.7**	**g/L**	**28-41**
Globulin	20.4	g/L	20-41
Alanine aminotransferase	30.9	U/L	9-73
Alkaline phosphatase	**1117**	**U/L**	**10-165**
Creatinine	**<18**	**µmol/L**	**59-109**
Urea	5.9	mmol/L	2.3-8.9
Sodium	137	mmol/L	142-151
Potassium	**2.29**	**mmol/L**	**3.6-5.1**
Canine C- reactive protein	**177**	**mg/l**	**0-10**

Total thyroxine and basal cortisol were performed using the Immulite 2000 Immunoassay System Analyser (Siemens) and were < 6.44 nmol/l [RI: 13 – 41 nmol/l] and 372 nmol/l [RI: 20 – 200 nmol/l], respectively.

Thromboelastography (kaolin activated) revealed a hypocoagulable tracing. (Table 3) Further evaluation of other haemostatic variables could not be performed due to the degradation of the stored citrate plasma samples.

Table 3. Thromboelastography results with abnormalities in bold

Thromboelastography results	Result	Units	Reference interval
R-time (clot initiation)	**8.7**	**minutes**	**1.8-7.3**
K-time (clot kinetics)	1.8	minutes	1-3.6
Angle (clot kinetics)	69.5	degrees	49.1-74.5
MA(clot strength)	**39.8**	**mm**	**48.1-74.5**
G-Value	**3.3**	**dyn/cm**	**4.7-14.4**
Lysis after 30 minutes	0	%	0-2.4
Lysis after 60 minutes	0	%	0-8

Aerobic blood culture isolated a pure culture with heavy growth of *Salmonella spp.*, which was serotyped as *Salmonella enterica* serovar Typhimurium (4,5,12 : i : 1,2). This cultured bacterium was sensitive to amikacin, amoxicillin-clavulanic acid, ampicillin, chloramphenicol, enrofloxacin, gentamicin, polymyxin B, tetracycline and trimethoprim-sulphonamide; with intermediate sensitivity to ceftiofur and doxycycline; and resistance to cephalothin, clindamycin, erythromycin, penicillin and sulphisoxazole.

Macroscopic findings on post mortem examination included, segmental areas of enteric necrosis evident throughout the intestinal tract including the colon, with multifocal petechiae and ecchymoses; moderate, diffuse thymic atrophy; and moderate, diffuse interstitial pneumonia.

The histopathological lesions revealed the following; moderate, segmental enteric necrosis characterised by multifocal areas of crypt necrosis with subsequent proprial collapse and multifocal haemorrhages. There was also widespread lympholysis localised to the gut-associated lymphoid tissue, in addition to the presence of scattered monomorphic, short, rod-shaped bacterial colonies throughout, as well as within the villous tips. (Figure 2) A moderate, diffuse interstitial pneumonia, necro-purulent hepatitis, (Figure 3) and purulent meningoencephalitis, (Figure 4) was observed, all characterised by the presence of monomorphic, short, rod-shaped bacterial colonies of which some were phagocytosed. In the kidney, the same monomorphic, short, rod-shaped bacterial colonies were also present within glomerular tufts. Fresh tissue samples of lung spleen and intestine were submitted for bacterial culture and *Salmonella spp*. was isolated in a pure culture with heavy growth from all of the samples submitted. The tissue *Salmonella spp.* identified was not typed but could reasonably be assumed to be the same serovar to that which was found on blood culture.

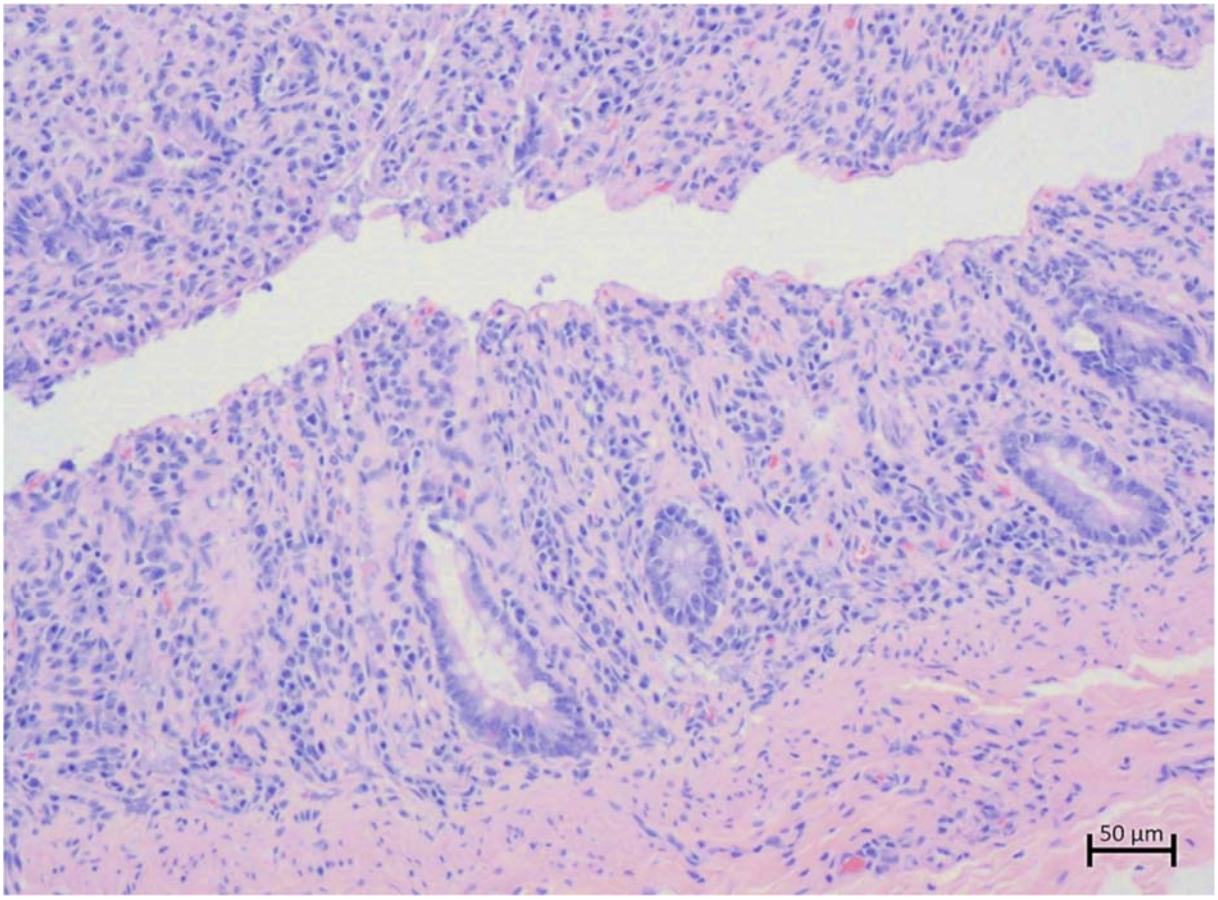

Figure 2: Histopathological lesions revealed segmental enteric necrosis characterised by multifocal areas of crypt necrosis/loss with subsequent proprial collapse. (Heamatoxylin and eosin stain, 100x magnification) 233x172mm (150 x 150 DPI)

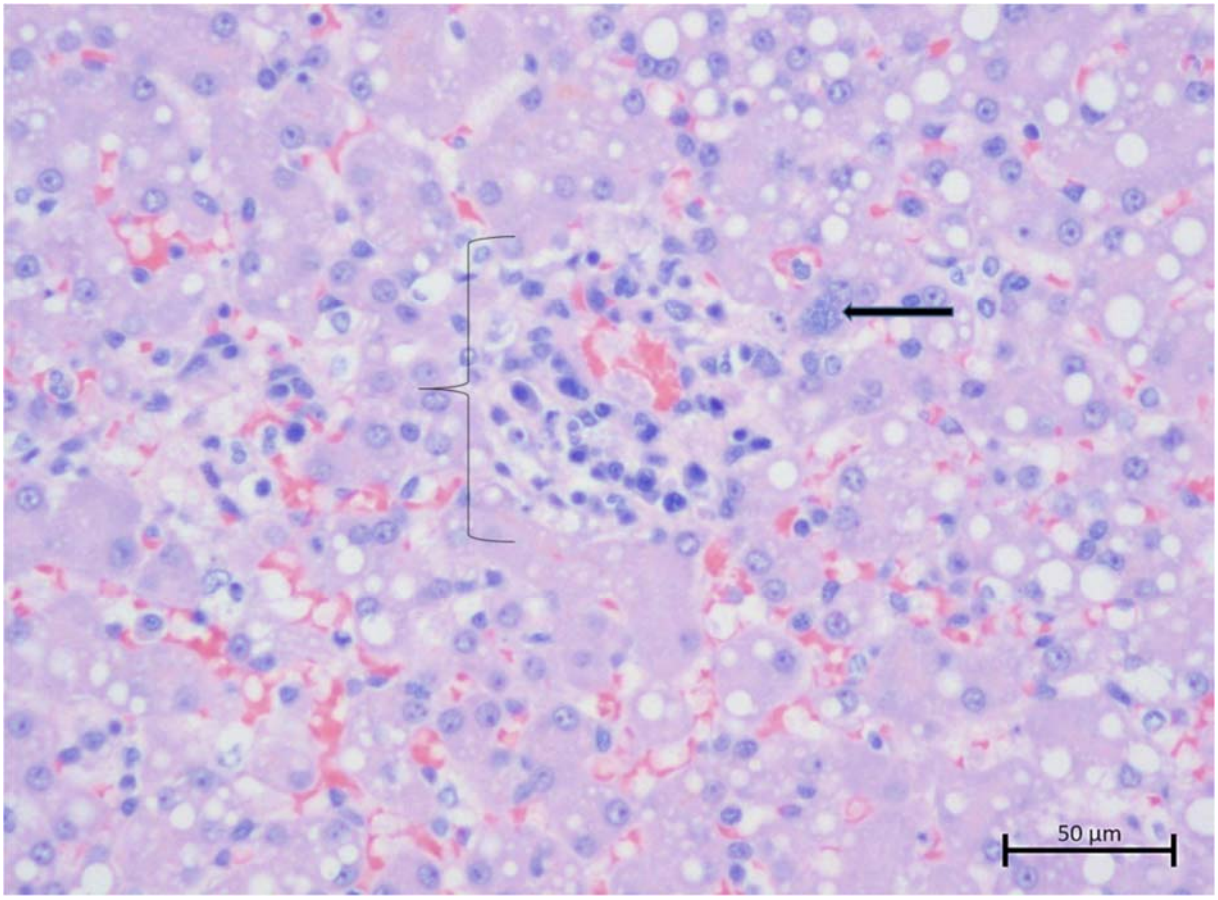

Figure 3: One focus of necropurulent hepatitis (left brace) in association with a colony of monomorphic, short, rod-shaped bacteria (block arrow). (Heamatoxylin and eosin stain, 200x magnification) 233x173mm (150 x 150 DPI)

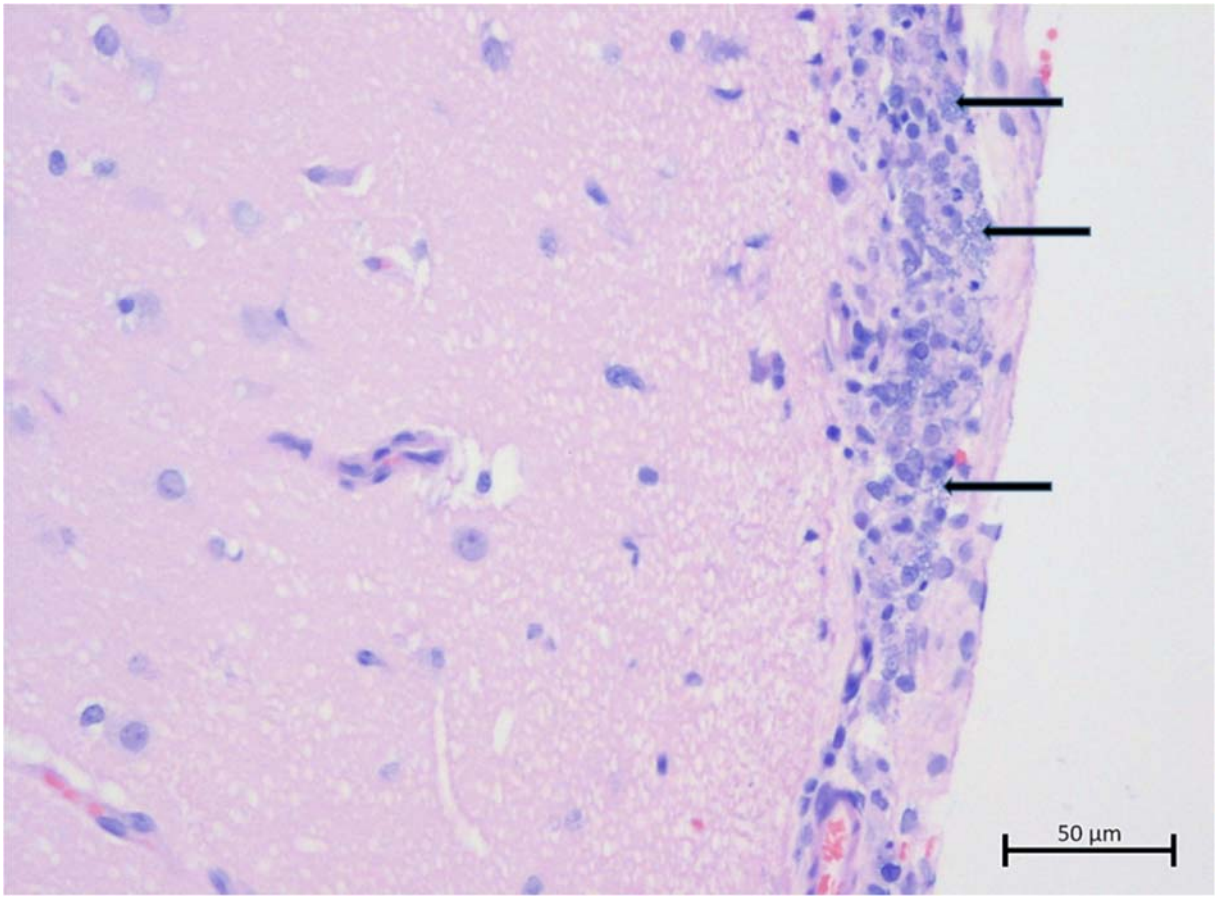

Figure 4: Purulent meningoencephalitis with the presence of numerous monomorphic, short, rod-shaped bacteria (block arrows) throughout. (Heamatoxylin and eosin stain, 100x magnification. 238x176mm (150 x 150 DPI)

Immunoperoxidase staining revealed canine parvovirus-specific positive labelling throughout the intestinal tract. The positive labelling was primarily characterised by intracytoplasmic granular labelling within macrophages. (Figure 5)

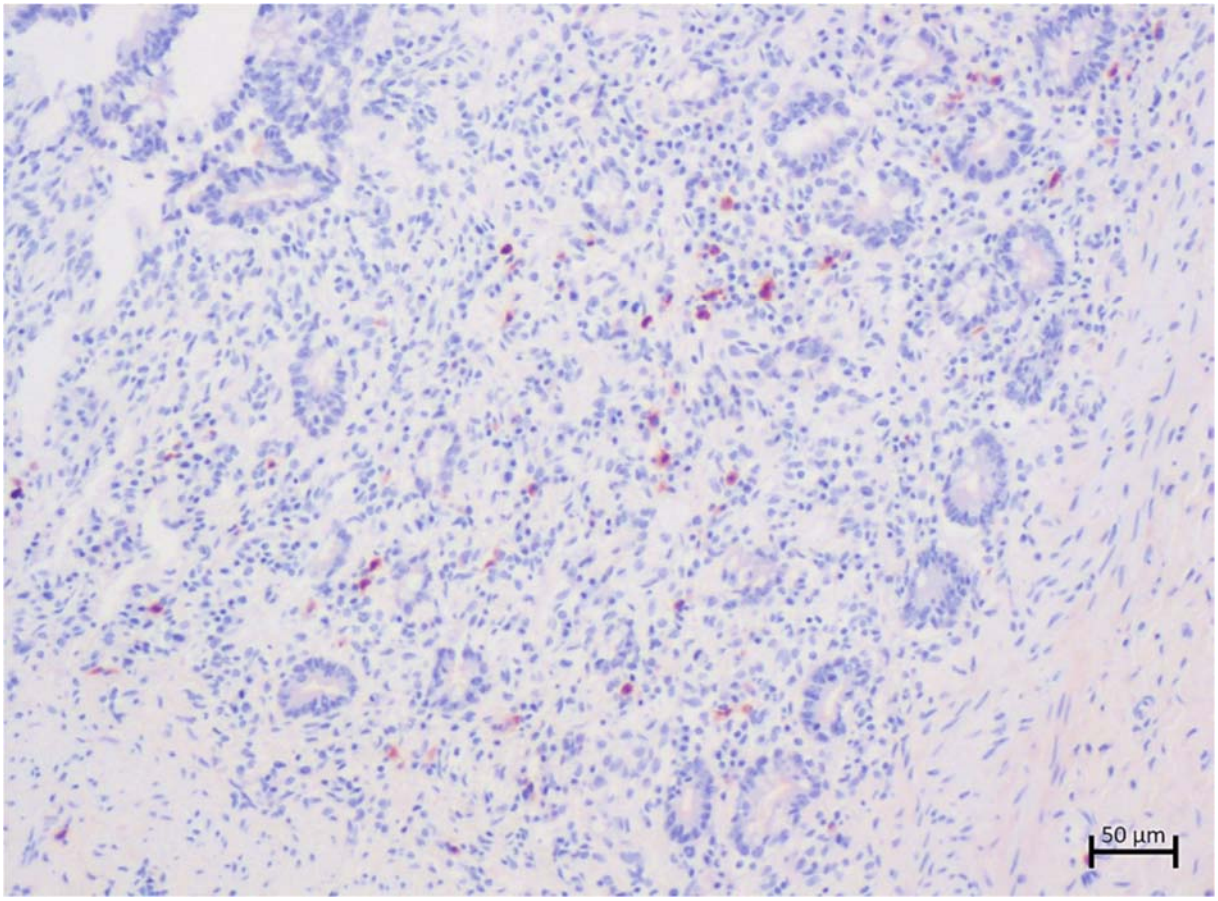

Figure 5: Scattered canine parvovirus-specific positive labelling throughout the intestinal tract. The positive labelling was primarily characterised by intracytoplasmic granular labelling within macrophages. (Avidinbiotin peroxidase complex method, Mayer's haematoxylin counterstain, 100 × magnification) 243x180mm (147 x 147 DPI)

A diagnosis of CPE complicated by *S.* Typhimurium bacteraemia was made based on the above findings.

OUTCOME AND FOLLOW-UP

The owners opted to euthanise the puppy, prior to the commencement of any treatment, due to the puppy's poor condition and the owners' financial constraints. Owners were informed of the potential zoonotic implications of Salmonellosis when culture results were obtained.

DISCUSSION

Canine parvoviral enteritis is caused by small, nonenveloped, single-stranded DNA viruses, canine parvovirus (parvoviridae) that attack rapidly dividing cells. CPE has a high mortality rate (91%) when untreated, with septicaemia being a common cause of death for dogs hospitalised for CPE (2). Otto *et al* found that

82% of dogs with CPE had circulating bacterial endotoxin and Turk *et al* found *Escherichia coli* in the lungs and liver of 90% of fatal CPE cases (3, 4).

Salmonella spp. are gram-negative, rod shaped, facultative intracellular bacteria with the ability to replicate inside phagocytes (5). *Salmonella enterica* is an important zoonotic disease and represents one fifth of all food borne infections in humans worldwide (6). Dogs have been sporadically implicated as the source of zoonotic salmonellosis, with human infections occurring at home, animal shelters and at veterinary practices (7-10). Contaminated commercial dog food and treats also represent potential direct and indirect sources of human salmonellosis (11). *Salmonella spp*. are often detected on faecal culture in healthy dogs and the pathogen's presence does not confirm clinical disease as evidenced by the multiple studies where Salmonella was cultured from asymptomatic dogs' faeces (1, 12-14). Subclinical or carrier status is common with salmonellosis with *Salmonella spp.* detected in up to 93% of faecal samples as was found in a greyhound breeding unit, feeding raw meat (15). However, the presence of *Salmonella spp.* in most populations is usually reported to be less than 5% of canine faecal samples (1, 16, 17).

On examination, the puppy appeared to conform to the typical presentation of a CPE case (2). However, the in-house CPV antigen ELISA test and, subsequently, the EM failed to detect CPV from the faecal samples. The definitive diagnosis of CPE was only made with post-mortem histopathological examination, by the detection of CPV antigen with a positive CPV antigen specific immune-peroxidase staining.

For the diagnosis of CPE, the sensitivity of the CPV antigen ELISA used has been reported to be between 18% to 80% (2, 18, 19). The exact sensitivity of negative staining EM for the diagnosis of CPE could not be found, but has been reported to be low (19-21). Schunck et al reported that negative staining EM detected canine parvovirus in 78% (n=51/65) of suspected CPE dogs' faeces (21). False negative ELISA results for CPE can arise from maternal antibody interference in the intestines, while inadequate sample or low viral load in faecal samples can lead to false negative CPE results on EM (2, 19, 21).

The sensitivities of IHC for the diagnosis of CPE have been reported to range from 76.7% to 95% (22-24). While the exact specificity of IHC for CPE diagnosis is unclear, it is reported to be highly specific with a high degree of reliability (22, 25). Vural and Alcigir (25) stated that by consulting both IHC and histopathological findings, "the diagnosis of especially suspected [CPE] cases would be guaranteed" (p63). False positives in IHC may occur for a variety of technical reasons, such as non-specific background signal, "pseudo-specific" signal, incorrect pre-treatment of the sample, over concentration of antibody and drying out of sample (26, 27). While a false positive IHC result (with true negative results on ELISA and EM) may have been possible, the clinical,

pathological, and histopathological findings strongly support this diagnosis of CPE.

To the authors' knowledge ante-mortem diagnosis of bacteraemia, based on the visualisation of phagocytosed bacteria on a peripheral blood smear, has not previously been reported in a dog. In human patients, bacteria visualised on a peripheral blood smear is rare, and is frequently associated with overwhelming sepsis or "trivial contamination" (28). Bacterial contamination would either be bacterial growth at the site of a central venous catheter or *in vitro* contamination from the skin, glassware or stain. *In vitro* contamination would present with extracellular bacteria unless there was a delay in the examination of the slide and its presence would not be likely to be repeatable (28). In this puppy, there was no intravenous catheter in place. *In vitro* contamination was eliminated, because the bacteria was intra-cellular and the examination of the slide performed immediately after ear prick, and the consistent presence of bacteria on repeated peripheral and central blood smears.

Historical and clinical findings of vomiting, lethargy, anorexia, progressive dehydration with mucoid to haemorrhagic diarrhoea are common to both CPE and salmonellosis (2, 5). Haematological finding of severe leucopenia, lymphopenia and neutropenia is consistent with CPE whereas a normal, regenerative or degenerative inflammatory leukogram would have been expected with salmonellosis alone (2, 29, 30). Although the puppy was likely to be hypoglycaemic, storage time has been shown to decrease serum glucose concentrations (31). If the blood glucose concentration was tested at the time of sample collection, it was likely to have been approximately 10% higher (31). Clinical pathological findings of hypoglycaemia, hypoalbuminemia, elevated alkaline phosphatase activity has been described in both septic salmonellosis and CPE cases (5, 29, 32).

Dogs with CPE have been reported to have laboratory evidence of hypercoagulability without DIC, while a hypercoagulable state and DIC have been described in septic canine salmonellosis (5, 30, 33). The initial stages of DIC dogs is considered to be hypercoagulable but may progress into a hypocoagulable state by means of a consumptive coagulopathy. This more advanced hypocoagulable state of DIC is associated with a significantly higher mortality (34). The hypocoagulable tracing on TEG in this puppy was primarily due to the thrombocytopenia, while the prolonged R-time was most likely due to decreased clotting factor concentration, and/or function. This combination of thrombocytopenia and the hypocoagulable TEG tracing was highly suggestive of the hypocoagulable stage of DIC. Additional coagulation tests such as activated partial thromboplastin time /prothombin time, antithrombin and D-dimer concentration may have confirmed this, but due to sample degradation during storage these tests could not be performed.

Elevated CRP at admission, was found to be a predictor of death in CPE cases with the cut off value of 131.3mg/L, with a sensitivity and specificity of 73.3% and 65% (35). The markedly elevated CRP of 177mg/L demonstrated a severe inflammatory response and poor prognosis in this puppy. Basal serum cortisol and thyroxine concentrations would not be routinely performed in puppies with vomiting and diarrhoea or CPE but have shown to have some use in the prognostication of CPE. Significantly elevated basal cortisol and decreased thyroxine levels, as were seen in this puppy, have been reported in dogs with CPE. Had these findings persisted on day 2 or 3 after admission, they would have been associated with a poor prognosis (36). Additionally, the elevated cortisol levels excluded hypoadrenocorticism as an unlikely cause of vomiting and diarrhoea in this case.

Bacteria is detected frequently by means of peripheral blood culture with a bacteraemia detected in 2% to 40% of healthy dogs (37-40). Dow et al reported a bacteraemia in 45% of critically ill dogs (n=39/86) using blood culture, with no *Salmonella spp.* cultured in any of these cases. This bacteraemia increased the risk of mortality ten-fold in animals with severe disease, but with non-serious disease bacteraemia there was no significant increase in the risk of mortality (41). The visualisation of bacteria on a peripheral blood smear in the absence of contamination, in this dog, would likely represent a clinically relevant, high bacterial load as has been demonstrated in human patients, with similar poor prognoses (28, 42). This bacteraemia was found on blood culture to be a *Salmonella spp.* and serotyped to *Salmonella enterica* serovar Typhimurium (4,5,12 : i : 1,2).

In a case where a bacteraemia of gastrointestinal origin is suspected, both aerobic and anaerobic blood culture should be performed due to the high proportion of anaerobes in the intestines (43). Anaerobic bacteria were detected in 31% of critically ill dogs with bacteraemia (41), with obligate anaerobes such as *Clostridium spp.* regularly reported from anaerobic blood culture (37, 38, 40, 44). In this case unfortunately only aerobic culture was performed and an additional presence of an obligate anaerobe bacteraemia could not be excluded.

Clinical salmonellosis is rare in dogs. Young, old and immunocompromised dogs are more susceptible to clinical salmonellosis. The most common clinical signs of salmonellosis are acute enterocolitis and abortions or still-births in case of in-utero infections (11). In rare instances, this can progress to septicaemia, disseminated intravascular coagulation and endotoxic shock (11).

Dogs with CPE have been shown to shed *Salmonella spp.* in their faeces, however CPE with salmonella bacteraemia has not been reported. Botha *et al* (2018) cultured *Salmonella spp.* in 22% from CPE puppies' faeces. This was not statistically different to healthy control puppies where *Salmonella spp.* was

detected in 31% of faecal samples (1). Prittie (2004), in a review article on CPE, mentioned that salmonella bacteria may cause septicaemia and or endotoxemia, however no specific evidence of this salmonella septicaemia was provide. (2, 44, 45).

S. Typhimurium is one of the most commonly isolated serovars of salmonella isolated in dogs from faecal culture (5, 13, 46-48). The antimicrobial susceptibility/resistance pattern seen in this case was similar to other *Salmonella spp.* reported worldwide (49, 50).

Both salmonellosis and CPE can cause villous atrophy and subsequent lamina proprial collapse within the intestinal tract, as was seen in this case (2, 5, 51, 52). The observed lesions of interstitial pneumonia, nephritis, necro-purulent hepatitis and purulent meningoencephalitis are associated with bacterial septicaemia and are common predilection sites of enteric bacterial translocation (3, 53). The bacterial translocation, the specific organs affected and the subsequent effect in this puppy were similar to previous reports of septicaemic salmonellosis (5, 13, 47, 52, 53). IHC labelling was localised to scattered proprial macrophages especially in areas with significant crypt loss, in contrast to the intra-epithelial positive labelling more commonly observed. This convincing, yet atypical positive IHC labelling confirmed a diagnosis of CPE.

The acute nature of the purulent inflammatory infiltrate especially within the liver and brain with the presence of bacterial colonies in these areas, implied CPE as the primary cause with secondary salmonellosis bacteraemia. The above findings led the authors to the diagnosis of CPE complicated by a secondary S. Typhimurium bacteraemia.

Canine parvovirus causes enterocyte necrosis and atrophy of the intestinal villi and destruction of the leukocyte hematopoietic progenitor cells (54). This decreased production and an increased gastrointestinal consumption of leukocytes induces a leucopenia (lymphopenia, neutropenia, monocytopenia). The leucopenia and enteric damage results in a high susceptibility to bacterial infections in dogs with CPE (54, 55).

Immunosuppression is a reported predisposing factor for the development of clinical salmonellosis in dogs (5). The initial innate immune response preventing intestinal salmonella bacterial colonization involves the recruitment of phagocytic neutrophils and macrophages by intestinal Peyer's patches and mesenteric lymph nodes. Circulating neutrophils recruited by the Kupffer cells are essential to the liver's elimination of salmonella bacteria that enter the blood stream from the intestines (56, 57). T-helper lymphocytes play an important role in activating the innate immune system against intracellular salmonella bacteria both systemically and in the intestines (56). Given that CPE causes neutropenia,

monocytopenia, and lymphopenia, and the high reported prevalence of Salmonella spp in CPE puppies' faeces (1), it is somewhat surprising that salmonella bacteraemia is not regularly reported in CPE cases.

In this puppy's case we hypothesise that, the CPE induced intestinal damage allowed salmonella bacteria to enter the blood stream and the leucopenia caused by CPE allowed the bacteria to evade destruction, spread through the blood stream and proliferate in the organs.

The presence of bacteria on the initial peripheral blood smear on this puppy's presentation prompted the authors to investigate this case further. The diagnosis of primary CPE was only achieved post-mortem with the detection of canine parvovirus antigen using IHC. For clinical practice, this case highlights that a negative CPV antigen ELISA test result does not rule out a diagnosis of CPE, especially in suspicious cases. The IHC detection of CPV antigen and the haematological findings in this case, were the only findings that could separate this puppy from having had CPE with secondary salmonella bacteraemia or septicaemia from salmonellosis alone.

LEARNING POINTS/TAKE HOME MESSAGES

- Visualisation of bacteria on a peripheral blood smear in a live dog has not been described previously
- It is likely that CPE and the resultant leucopenia led to a secondary salmonella bacteraemia in this case. This has not been reported previously.
- The false negative results obtained by the CPV antigen ELISA and negative-staining EM tests highlight their relatively low sensitivities for the diagnosis of CPE.
- Canine patients with primary salmonella septicaemia and those having CPE with secondary bacteraemia can have similar clinical, biochemical, and histological findings on investigation.

REFERENCES

1. Botha WJ, Schoeman JP, Marks SL, Whitehead Z, Annandale CH. Prevalence of Salmonella in juvenile dogs affected with parvoviral enteritis. J S Afr Vet Assoc. 2018;89(0):e1-e6.

2. Prittie J. Canine parvoviral enteritis: a review of diagnosis, management, and prevention. Journal of Veterinary Emergency and Critical Care. 2004;14(3):167-76.

3. Turk J, Miller M, Brown T, Fales W, Fischer J, Gosser H, et al. Coliform septicemia and pulmonary-disease associated with canine parvoviral enteritis - 88 cases (1987-1988). J Am Vet Med Assoc. 1990;196(5):771-3.

4. Otto CM, Drobatz KJ, Soter C. Endotoxemia and Tumor Necrosis Factor Activity in Dogs With Naturally Occurring Parvoviral Enteritis. Journal of Veterinary Internal Medicine. 1997;11(2):65-70.

5. Carter ME, Quinn PJ. Salmonella infections in dogs and cats. In: Wray C WA, editor. Salmonella in domestic animals. Wallingford, UK: CAB International; 2000. p. 231–44.

6. ECDC. The european union summary report on trends and sources of zoonoses, zoonotic agents and food-borne outbreaks in 2011. EFSA 2013;J 3129 3250.

7. Wolff AH, Henderson ND, McCallum GL. Salmonella from dogs and the possible relationship to salmonellosis in man. Am J Public Health Nations Health. 1948;38(3):403-8.

8. Morse EV, Duncan MA, Estep DA, Riggs WA, Blackburn BO. Canine salmonellosis: A review and report of dog to child transmission of Salmonella enteritidis. American Journal of Public Health. 1976;66(1):82-3.

9. Hoelzer K, Moreno Switt AI, Wiedmann M. Animal contact as a source of human non-typhoidal salmonellosis. Veterinary Research. 2011;42(1):34.

10. Caspersen J. A Paratyphoid Outbreak with a Peculiar Origin (Dog). A Paratyphoid Outbreak with a Peculiar Origin (Dog). 1937:138-43.

11. Pitout JDD, Reisbig MD, Mulvey M, Chui L, Louie M, Crowe L, et al. Association between handling of pet treats and infection with Salmonella enterica serotype newport expressing the AmpC beta-lactamase, CMY-2. Journal of clinical microbiology. 2003;41(10):4578-82.

12. Reimschuessel R, Grabenstein M, Guag J, Nemser SM, Song K, Qiu J, et al. Multilaboratory Survey To Evaluate *Salmonella* Prevalence in Diarrheic and Nondiarrheic Dogs and Cats in the United States between 2012 and 2014. Journal of Clinical Microbiology. 2017;55(5):1350-68.

13. Philbey AW, Mather HA, Gibbons JF, Thompson H, Taylor DJ, Coia JE. Serovars, bacteriophage types and antimicrobial sensitivities associated with salmonellosis in dogs in the UK (1954-2012). The Veterinary record. 2014;174(4):94.

14. Amadi VA, Hariharan H, Arya G, Matthew-Belmar V, Nicholas-Thomas R, Pinckney R, et al. Serovars and antimicrobial resistance of non-typhoidal Salmonella isolated from non-diarrhoeic dogs in Grenada, West Indies. Vet Med Sci [Internet]. 2018; 4(1):[26-34 pp.].

15. Morley P, Strohmeyer R, Tankson J, Hyatt D, Dargatz D, Fedorka-Cray P. Evaluation of the association between feeding raw meat and Salmonella enterica infections at a Greyhound breeding facility. J Am Vet Med Assoc. 2006;228:1524-32.

16. Hackett T, Lappin MR. Prevalence of Enteric Pathogens in Dogs of North-Central Colorado. Journal of the American Animal Hospital Association. 2003;39(1):52-6.

17. Lowden P, Wallis C, Gee N, Hilton A. Investigating the prevalence of Salmonella in dogs within the Midlands region of the United Kingdom. BMC Veterinary Research. 2015;11(1):239.

18. Decaro N, Desario C, Beall MJ, Cavalli A, Campolo M, DiMarco AA, et al. Detection of canine parvovirus type 2c by a commercially available in-house rapid test. The Veterinary Journal. 2010;184(3):373-5.

19. Schmitz S, Coenen C, Matthias K, Heinz-Jürgen T, Neiger R. Comparison of Three Rapid Commercial Canine Parvovirus Antigen Detection Tests with Electron Microscopy and Polymerase Chain Reaction. Journal of Veterinary Diagnostic Investigation. 2009;21(3):344-5.

20. Esfandiari J, Klingeborn B. A Comparative Study of a New Rapid and One-Step Test for the Detection of Parvovirus in Faeces from Dogs, Cats and Mink. Journal of Veterinary Medicine, Series B. 2000;47(2):145-53.

21. Schunck B, Kraft W, Truyen U. A simple touch-down polymerase chain reaction for the detection of canine parvovirus and feline panleukopenia virus in feces. Journal of Virological Methods. 1995;55(3):427-33.

22. Romero RAR, Aranda EC, Godoy FS, Watty AD. Diagnóstico del parvovirus canino-2 (pvc-2) por inmunohistoquímica en perros domésticos. Veterinaria México. 2007;38(1):41-53.

23. Oliveira EC, Pescador CA, Sonne L, Pavarini SP, Santos AS, Corbellini LG, et al. Análise imuno-histoquímica de cães naturalmente infectados pelo parvovírus canino. Pesquisa Veterinária Brasileira. 2009;29:131-6.

24. Svara T, Juntes P, Pogacnik M, Gombac M, Hostnik P. Immunohistochemical demonstration of parvoviral antigen in the organs of dogs with canine parvovirs. Slovenian Veterinary Research (Slovenia). 2003.

25. Vural S, Alcigir G. Histopathological and immunohistological findings in canine parvoviral infection: Diagnosis application. Revue de Medecine Veterinaire. 2011;162:59-64.

26. Nuovo G. False-positive results in diagnostic immunohistochemistry are related to horseradish peroxidase conjugates in commercially available assays. Ann Diagn Pathol. 2016;25:54-9.

27. Gown AM. Diagnostic Immunohistochemistry: What Can Go Wrong and How to Prevent It. Archives of Pathology & Laboratory Medicine. 2016;140(9):893-8.

28. van der Meer W, Verwiel JMM, Gidding CEM, de Metz M, de Keijzer MH. Bacteria in Blood Smears: Overwhelming Sepsis or Trivial Contamination. Acta Haematologica. 2002;107(4):220-3.

29. Calvert CA. *Salmonella* infections in hospitalized dogs: epizootiology, diagnosis and prognosis. Journal of the American Animal Hospital Association. 1985(21):499–503.

30. Vera C, Whitacre M, Thakur S, Keelara veerappa S, Fauls M, Breitschwerdt E. Unilateral epididymitis associated with salmonella bacteremia in a dog. Clinical Theriogenology Journal. 2012;4:61-5.

31. Clark ML, Humphreys SM, Frayn KN. Stability of plasma glucose during storage. Ann Clin Biochem. 1990;27 (Pt 4):373-7.

32. Shah s, Sood N, Wani N, Gupta K, Singh A. Haemato-biochemical changes in canine parvoviral infection. Indian Journal of Veterinary Pathology. 2014;37:131-3.

33. Otto CM, Rieser TM, Brooks MB, Russell MW. Evidence of hypercoagulability in dogs with parvoviral enteritis. J Am Vet Med Assoc. 2000;217(10):1500-4.

34. Wiinberg B, Jensen AL, Johansson PI, Rozanski E, Tranholm M, Kristensen AT. Thromboelastographic Evaluation of Hemostatic Function in Dogs with Disseminated Intravascular Coagulation. Journal of Veterinary Internal Medicine. 2008;22(2):357-65.

35. McClure V, van Schoor M, Thompson PN, Kjelgaard-Hansen M, Goddard A. Evaluation of the use of serum C-reactive protein concentration to predict outcome in puppies infected with canine parvovirus. J Am Vet Med Assoc. 2013;243(3):361-6.

36. Schoeman JP, Goddard A, Herrtage ME. Serum cortisol and thyroxine concentrations as predictors of death in critically ill puppies with parvoviral diarrhea. J Am Vet Med Assoc. 2007;231(10):1534-9.

37. Winkler KP, Greenfield CL, Schaeffer DJ. Bacteremia and bacterial translocation in the naturally occurring canine gastric dilatation-volvulus patient. J Am Anim Hosp Assoc. 2003;39(4):361-8.

38. Unterer S, Lechner E, Mueller RS, Wolf G, Straubinger RK, Schulz BS, et al. Prospective study of bacteraemia in acute haemorrhagic diarrhoea syndrome in dogs. The Veterinary record. 2015;176(12):309.

39. Dahlinger J, Marks SL, Hirsh DC. Prevalence and Identity of Translocating Bacteria in Healthy Dogs. Journal of Veterinary Internal Medicine. 1997;11(6):319-22.

40. Harari J, Besser TE, Gustafson SB, Meinkoth K. Bacterial isolates from blood cultures of dogs undergoing dentistry. Veterinary surgery : VS. 1993;22(1):27-30.

41. Dow SW, Curtis CR, Jones RL, Wingfield WE. Bacterial culture of blood from critically ill dogs and cats: 100 cases (1985-1987). J Am Vet Med Assoc. 1989;195(1):113-7.

42. Graham BS. Detection of bacteremia and fungemia: microscopic examination of peripheral blood smears. Infection control : IC. 1984;5(9):448-52.

43. Mentula S, Harmoinen J, Heikkilä M, Westermarck E, Rautio M, Huovinen P, et al. Comparison between cultured small-intestinal and fecal microbiotas in beagle dogs. Appl Environ Microbiol. 2005;71(8):4169-75.

44. Turk J, Fales W, Miller M, Pace L, Fischer J, Johnson G, et al. Enteric Clostridium perfringens infection associated with parvoviral enteritis in dogs: 74 cases (1987-1990). J Am Vet Med Assoc. 1992;200(7):991-4.

45. Sandstedt K, Wierup M. Concomitant occurrence of Campylobacter and parvoviruses in dogs with gastroenteritis. Veterinary research communications. 1981;4(4):271-3.

46. Cole SD, Palermo SM, Rankin SC. Salmonella enterica serovar Typhimurium isolated from the urine of a dog undergoing treatment for immune-mediated polyarthritis. JMM Case Rep [Internet]. 2018; 5(9):[e005153 p.].

47. Giuliano A, Meiring T, Grant AJ, Watson PJ. Acute Hepatic Necrosis Caused by *Salmonella enterica* Serotype I 4,5,12:−:1,2 in a Dog. Journal of Clinical Microbiology. 2015;53(11):3674-6.

48. Wallis CV, Lowden P, Marshall-Jones ZV, Hilton AC. Distinct fermentation and antibiotic sensitivity profiles exist in salmonellae of canine and human origin. BMC Microbiol. 2018;18(1):15-.

49. Thung TY, Mahyudin NA, Basri DF, Wan Mohamed Radzi CWJ, Nakaguchi Y, Nishibuchi M, et al. Prevalence and antibiotic resistance of Salmonella Enteritidis and Salmonella Typhimurium in raw chicken meat at retail markets in Malaysia. Poultry Science. 2016;95(8):1888-93.

50. Peng M, Salaheen S, Almario JA, Tesfaye B, Buchanan R, Biswas D. Prevalence and antibiotic resistance pattern of Salmonella serovars in integrated crop-livestock farms and their products sold in local markets. Environmental Microbiology. 2016;18(5):1654-65.

51. Pollock RV, Parrish CR. Canine parvovirus. Comparative pathobiology of viral diseases. 1985;1:145-77.

52. Thompson H, Wright NG. Canine Salmonellosis. Journal of Small Animal Practice. 1969;10(10):579-82.

53. Nation PN. Salmonella dublin Septicemia in Two Puppies. Can Vet J. 1984;25(8):324-6.

54. Goddard A, Leisewitz AL. Canine parvovirus. Veterinary Clinics: Small Animal Practice. 2010;40(6):1041-53.

55. Goddard A, Leisewitz AL, Christopher MM, Duncan NM, Becker PJ. Prognostic Usefulness of Blood Leukocyte Changes in Canine Parvoviral Enteritis. Journal of Veterinary Internal Medicine. 2008;22(2):309-16.

56. Kurtz JR, Goggins JA, McLachlan JB. Salmonella infection: Interplay between the bacteria and host immune system. Immunol Lett. 2017;190:42-50.

57. Conlan JW. Neutrophils prevent extracellular colonization of the liver microvasculature by Salmonella typhimurium. Infect Immun. 1996;64(3):1043-7.