

Injuries and Deaths from Lightning

Ryan Blumenthal (corresponding author)

MBChB (Pret) MMed(Med Forens) (Pret) Dip For Med(SA) FC For Path (SA) PhD (WITS)

Senior Specialist Forensic Pathologist

Department of Forensic Medicine

University of Pretoria

Prinshof Campus

Pathology Building (level 4)

Pretoria, South Africa

Postal address: P/Bag X 323, Arcadia, 0007

Tel: + 27 (0) 12 323 5298

E-mail: ryan.blumenthal@up.ac.za

Word Count: 4304

Keywords: Injuries, Deaths; Lightning Strikes; Review; Keraunopathology; Keraunomedicine.

“As Ponocrates grew familiar with Gargantua’s vicious manner of studying, he began to plan a different course of education for the lad; but at first he let him go on as before knowing that nature does not endure abrupt changes without great violence.”

Rabelais, “The Old Education and the New”, Gargantua, Book 1.

Translated from the first French edition into English by Sir Thomas Urquhart of Cromarty and Peter Antony Motteux, 1653

ABSTRACT

This paper reviews recent academic research into the pathology of trauma of lightning.

Lightning may injure or kill in a variety of different ways.

Aimed at the trainee, or practicing pathologist, this paper provides a clinicopathological approach.

LIGHTNING INJURIES

'Pathology, (from the Greek pathos, meaning 'suffering' and logos, meaning 'word') deals with the causes and mechanisms of human disease. For this reason, pathology is one of the basic medical sciences and is vital to the understanding of disease and seeing to its appropriate treatment. It is important to realise that, like medicine, pathology is not a clearly delineated science. It owes its development to successive intellectual and technical borrowings from nearby disciplines such as anatomy, physiology, physics, chemistry, microbiology, immunology, genetics, and cell and molecular biology. For this reason, pathology reflects closely the body of knowledge gradually acquired in each of these disciplines', [1].

Forensic pathology is the study of the diseases and injuries of the community. It is the last stronghold of the autopsy, [2-6]. Forensic medicine is that body of medical and paramedical scientific knowledge, which may be used for purposes of administration of the law, [7].

Keraunopathology and electropathology are sub-specialities of forensic pathology. Electropathology concerns itself with the pathology of trauma of electrical injury. Keraunopathology concerns itself with the study of the pathology of trauma of lightning on the human and/or animal body.

This paper will review injuries and deaths from lightning strikes. This paper will focus on recent intellectual and technical developments from other disciplines.

The path of the lightning investigator is usually beset with many difficulties. Lightning flashes cannot be produced on demand; the investigator must be ready with what is deemed *adequate* equipment before the occurrence of a thunderstorm, [8].

A thundercloud has a vertical extent of about 10 km and horizontal dimensions several times as large. The temperature varies from a few degrees above zero at the base of the cloud to about – 50 degrees Centigrade at its top. Violent up-and down draughts and severe turbulence occur in specific regions of the cloud, [8].

According to D. J . Malan (1967) an electrically active thundercloud may be regarded as an electrostatic generator suspended in an atmosphere of low electrical conductivity. It is situated between two concentric conductors, namely, the surface of the earth and the electrosphere, the latter being the highly conducting layers of the atmosphere at altitudes above 50 km to 60 km, [9].

There are different types of lightning discharges: Flashes to ground, ribbon lightning, beaded lightning, air discharges, cloud flashes of intra-cloud discharges and ball lightning, [8].

Figure 1



Lightning (Photo courtesy of N du Plooy).

159x128mm (220 x 220 DPI)

Figure 2



Lightning (Photo courtesy of Mrs Stuart).

159x105mm (220 x 220 DPI)

Rakov & Uman (2003) differentiate four types of cloud-to-ground lightning discharges a) downward negative lightning, b) upward negative lightning, c) downward positive lightning, and d) upward positive lightning. It is believed that downward negative lightning flashes account for 90 % or more of global cloud-to-ground lightning, and that 10 % or less of cloud-to-ground discharges are downward positive lightning flashes. [Insert Figure 2]. Upward lightning discharges are thought to occur only from tall objects (higher than 100 meters or so), or from objects of moderate height located on mountain tops, [9].

The medico-legal and forensic perspectives surrounding a lightning strike have been highlighted in the newer literature from as early as 1995, [10].

Lightning may be defined as a transient, high-current electric discharge whose path length is generally measured in kilometres. The electric current involved in lightning strikes is direct current (DC) in the order of 30 000 to 50 000 Amps, [11]. A lightning flash consists of several successive processes, some of which occur in times of the order of microseconds, while the discharge as a whole occupies an appreciable part of a second, [9].

Lightning is a natural hazard, lethal and destructive on short time scales and with important climatic effects on longer time-scales (through the Nitrogen cycle and forest fire ignition). Lightning forms part of the global electric circuit, [9]. Lightning poses threats to aviation safety and to renewable energy production by wind-turbines, and is known to adversely affect electric power utilities and transmission lines. Although it is hard to precisely predict what future lightning distributions will look like, the combination of large metropolitan areas, increased population and a warmer climate almost guarantee an intensification of the human exposure to lightning hazard, [12].

Some places in the world have a lot of lightning-related injuries and fatalities, whereas other places in the world have fewer lightning-related injuries and fatalities, [13].

'Lightning deaths cannot be other than accidental and provide no real problems for the forensic pathologist. Occasionally the nature of the death may be uncertain if a dead body is discovered in the open with no marks upon it. It is well known that injury from lightning is capricious and unpredictable. Two people can stand side by side during a flash and one may be mutilated and killed while the other is unharmed. The physical damage in fatal lightning strike cases can vary from virtually nil to gross burning, fractures and even tissue destruction', [2].

Five mechanisms have traditionally been described in the mainstream medical literature regarding lightning injury, [14]. Briefly, these mechanisms are:

1. A direct lightning strike;
2. An indirect lightning strike caused by contact with an object such as a pole or a tree that was directly struck;
3. A side flash that could occur from a struck object, such as a tree, to a nearby victim.
4. A person or animal standing near a struck object, or close to a flash of lightning to ground, could be injured by step voltages produced by a lightning current flowing through the resistance of the soil beneath. This earth current can then also flow in another pathway, namely, up one limb and down another of the victim, which could result in injury or even death.
5. Bodies could become sufficiently charged during the lightning leader development process to cause upward streamers to be initiated from them, leading to injuries.
6. Recently, a sixth mechanism of lightning injury was proposed, namely lightning explosive barotrauma, [15].

An understanding of these six mechanisms, together with the keraunopathology associated with these mechanisms, provides the background to this paper.

Most of the fatalities from lightning strikes occur among young people who are engaged in outdoor activities. In Africa, most lightning injuries occur in rural areas, people walking home during the late afternoon which is when thunderstorms occur. Inadequate safe shelters also make Africa unsafe from a lightning-safety point of view.

Death may occur due to a 'bolt out of the blue'. One case study from Conghua, Guangzhou, China demonstrated this phenomenon. Based on a comprehensive analysis, the lightning was concluded to be a negative "bolt from the blue" ground flash with seven return strokes. There was no cloud cover above the head of the victim. The most probable mechanism for the lightning injuries was the side flash, [16].

Lightning victims may present with minor lightning injuries, moderate lightning injuries, or severe lightning injuries. This is almost tantamount to the "dose" of lightning to which the victims were exposed. The "dose" would depend upon aforementioned six mechanisms, [17]. In other words, the "dose" would depend upon the way lightning interacts with the body.

Lightning strike is an environmental electrical injury with high rates of morbidity and mortality, [18].

Due to the fact that lightning is a multi-physics phenomenon, the different physical components may injure the victim in a multitude of different ways. Lightning processes emit electromagnetic signals, for example, [9]. Lightning injuries may also be due to the light component, the heat component, the electrical component or the blast-wave component.

CHIEF MACROSCOPIC PATHOLOGY

Macroscopic findings are chiefly located on the external aspects of the body. Most of the signs of lightning are located externally on the clothing, shoes, jewellery and belt of the victim. This becomes important in cases where no clinical history is available.

Almost any organ system may be involved in lightning strikes, and prognosis depends on multiple factors. The physical injuries may resolve completely or may be associated with long-term effects, including psychological sequelae for the survivors.

The four main, non-kinetic, energy components of lightning (namely light, heat, electricity and barotrauma) account for most of the macroscopic pathology.

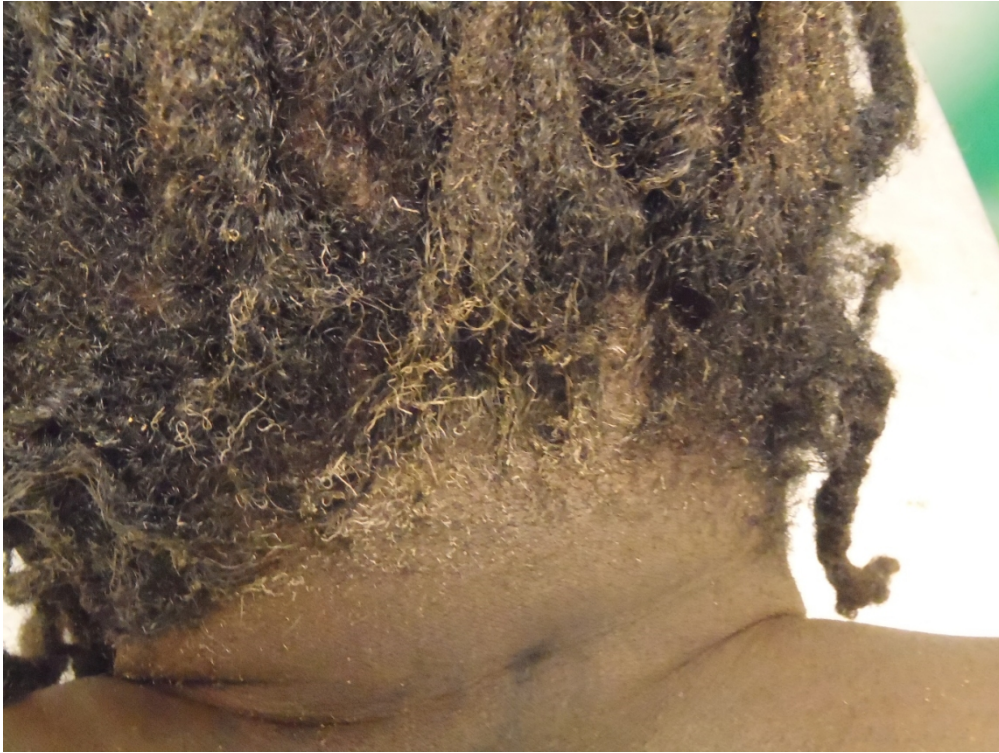1. The Light Component:

The light component of lightning may injure the eye and there is a relatively large body of literature describing such injuries, [19-22]. In ophthalmology, injuries due to lightning strikes have been documented as various entities ranging from keratitis, cataracts, uveitis in the anterior segments to retinal detachments, papillitis, and macular hole formation in the posterior segment [23]. Severe optic injuries have been reported in both fatal and nonfatal lightning injuries.

Cataracts have been known to develop weeks to months post lightning strike. Multiple theories exist as to why cataracts develop post-lightning strike, [24]. One such theory suggests that the intensity of the light component of lightning may affect the crystalline structural proteins of the lens.

2. The Heat Component

Figure 3



An adult female who sustained direct lightning strike. Note the singeing of the scalp hair. (Photograph courtesy of R Blumenthal).

159x119mm (220 x 220 DPI)

Figure 4



Note the scorching of the white material drawstring. This victim sustained direct lightning strike.
(Photograph courtesy of R Blumenthal).

159x119mm (220 x 220 DPI)

Figure 5



A photograph of an adult male found dead next to the side of the road with no medical history. Thorough examination was in keeping with lightning strike. The first clue was melting of synthetic fibres of clothing. (Photograph courtesy of R Blumenthal).

158x105mm (220 x 220 DPI)

The heat component of lightning may affect the clothing or skin. Oftentimes, there are linear, first-degree burns, which may follow the skin creases. These marks may be centimetres long and generally follow the long axis of the body towards the ground. There may be superficial charring of the skin, chiefly over the trunk, [25].

There is often a smell of singeing or burning about the body and its clothing. The hair may be scorched or singed [Insert Figure 3]. The clothing may be scorched or singed [Insert Figure 4]. Sometimes, synthetic clothing may even melt due to heat [Insert Figure 5].

3. The Electrical Component

The electrical component may cause Lichtenberg figures. Lichtenberg figures (arborescent or fern-like injuries), were named after Georg Christoph Lichtenberg (1742-1799), [26]. Lichtenberg figures represent a vital reaction and are most commonly seen on light-skinned lightning strike survivors, [27]. [Insert Figure 6].

A possible explanation for Lichtenberg figures has been localized fractal pattern flow of lightning over body surfaces electrically-interacting with capillaries and the iron within the haemoglobin of the erythrocytes (Mary Ann Cooper – Personal communication). Another possible explanation by Cooray et al. is that the skin is bombarded by energetic electrons during the propagation of streamer discharges along the skin and that the Keraunographic markings are as a result of superficial radiation injury with subsequent inflammation in the epidermis and superficial layers of the dermis, caused by the energetic electrons, [28].

The electrical component of lightning may cause other, somewhat unusual, spark-like lesions, on the skin of victims [Insert Figure 7].

Cardiac Effects of Lightning Injury

The electrical component may cause cardiac arrhythmias, [29]. Lightning strike injuries are considered to be high-voltage injuries, [18]. The effects of the electrical current on the cardiovascular system are one of the main modes leading to cardiorespiratory arrest in these patients. Cardiac effects of lightning strikes may be transient or persistent, and may include benign or life-threatening arrhythmias. Prolonged resuscitation may lead to favourable outcomes especially in young and previously healthy victims.

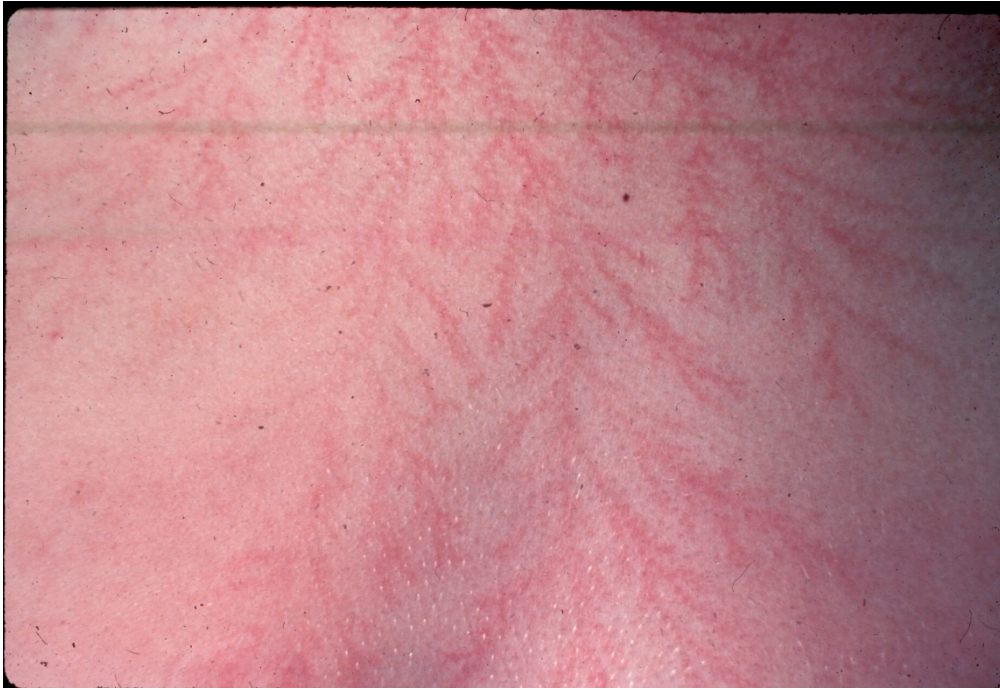
The huge rise in voltage accompanying lightning strikes may result in a massive direct current shock, which in turn is capable of depolarising the entire myocardium, [30,31]. Furthermore, increased autonomic stimulation as a result of the shock received, with an associated catecholaminergic surge may have additive effects on the heart rate and rhythm.

Further research is required to identify prognostic markers, either with regards to the patient's biochemistry or cardiac imaging results, in the acute setting in the 'stable' patient, thus establishing which ones may likely develop more sinister complications later on, as well as those who will benefit from close rhythm monitoring on discharge. The association between electrocardiographic ischaemic changes and underlying coronary obstruction is not fully established, further studies are required in this area to identify which patients require to be rushed to the catheter laboratory at an early stage, thus avoiding unnecessary invasive procedures, [29].

Neurological Effects of Lightning Injury

The electrical component may also cause neurological effects, such as cerebral salt-wasting syndrome. Hyponatremia may result in brain oedema and secondary nausea, headache, altered

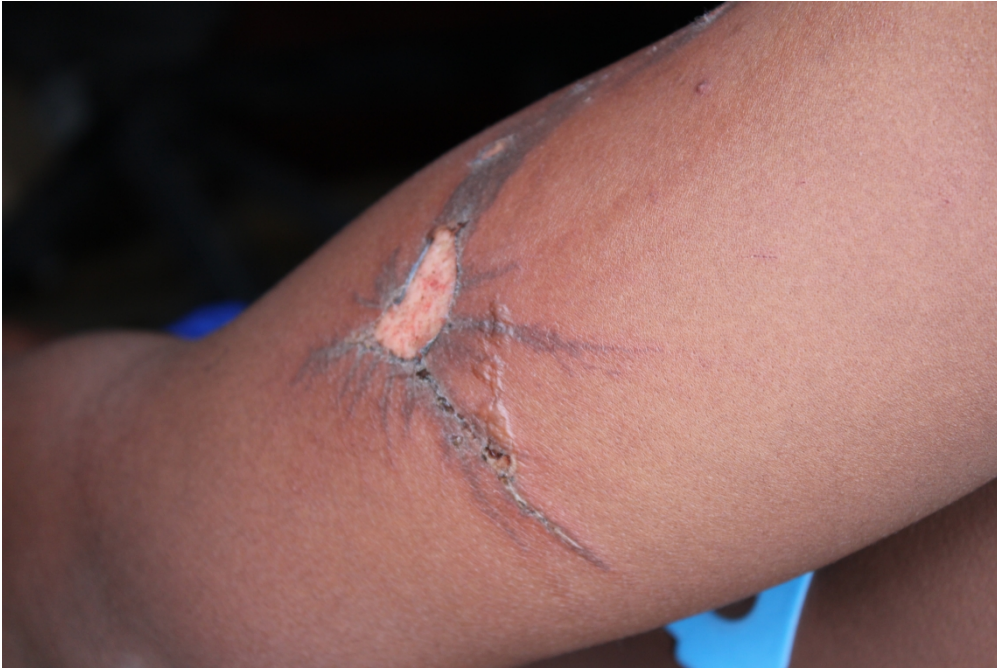Figure 6



A Lichtenberg figure. (Photograph Copyright of Mary Ann Cooper).

423x290mm (96 x 96 DPI)

Figure 7



An unusual spark lesion found on the skin of a lightning strike survivor (Photograph courtesy of R Blumenthal).

consciousness, and sometimes death. Close monitoring of the serum sodium levels and immediate correction of electrolyte abnormalities are therefore necessary after severe brain damage. If left untreated without correct diagnosis, severe hyponatremia may result in seizures and worsening cerebral oedema, [32].

Salt wasting syndrome is a rare complication of lightning strike. There is limited literature on lightning-related salt wasting syndrome, [32, 33]. It is unknown whether it is simply a trauma response, or a specific electrical response.

Post electric shock- or lightning shock syndrome (PELIS) has been proposed in lightning strike survivors, [34]. The major neuropsychological consequences of which include depression and neurocognitive dysfunction with ongoing consequences. The proposed DSM diagnostic criteria insist on a demonstrated context for the injury, both in the shock circumstance and also in the physical consequences.

4. The Barotrauma Component:

The barotrauma component may chiefly injure the ear, [35]. In most of the surviving patients after a lightning strike, audiovestibular abnormalities have been reported. The most frequently reported type of abnormalities is a tympanic membrane perforation with hearing loss and external ear canal burn. However a sensorineural hearing loss and mixed-type hearing loss may also occur, but these occur rarely. A lightning strike may cause serious audiological damage. Therefore, it is necessary to make a careful audiovestibular evaluation of the lightning-struck patient. [Insert Figure 8].

Lightning strike may cause very different effects on the auditory system. These effects may show a simple change in hearing threshold up to total loss of hearing. Audiovestibular pathology has to be considered, and patients admitted to the emergency department after being struck by lightning have to be examined more carefully because of this reason, [36,37].

The barotrauma component may also injure hollow organs, the lung, and the gastrointestinal tract. Lightning may cause pneumomediastinum due to the barotrauma component, [38,39]. There may be blunt force trauma, concussive trauma or other explosive (blast) injuries. It is therefore critical to seek out signs of barotrauma on the clothing [Insert Figure 9], shoes [Insert Figure 10], and skin, before clinically managing the patient.

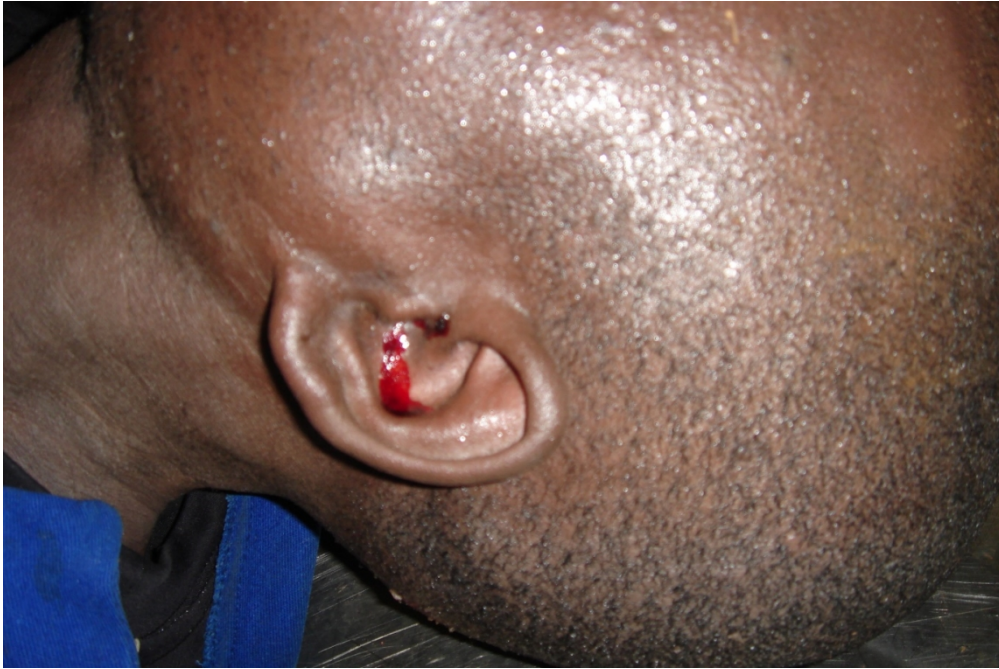CHIEF MICROSCOPIC PATHOLOGY

Internally, there is little to be seen in lightning strike victims. Histologically, most of the positive findings are located in the heart. Wave-like arrangement of the myocardial fibres and myocardial haemorrhage have been described in the literature, [40]. Disruptive injuries of internal organs, caused by the blast-like air displacement of lightning, may occasionally be seen under the microscope. Histological examination of the eye (optic atrophy), the ear (tympanic membrane, vestibular membrane and organ of Corti) and certain nerves (such as the facial nerve) may be justified in some cases, where degenerative changes are suspected, [41].

CLINICAL MANAGEMENT

Management involves diagnosis, initial first aid, triaging of victim, laboratory tests and radiographic examination. Treatment involves fluid therapy, cardiovascular therapy, burn treatment, assessing and managing central nervous system injuries, managing eye injuries and ear injuries, and assessing if pregnant in women (assessing foetal viability).

Figure 8



Photograph of a ruptured tympanic membrane in lightning strike. (Photograph courtesy of R Blumenthal).

158x105mm (220 x 220 DPI)

Figure 9



Legend 10: The right shoe of a lightning strike victim. This victim sustained direct lightning strike. The shoe was found lying separate from the body. Note the tearing and tattering of the leather shoe. (Photograph courtesy of R Blumenthal).

135x101mm (220 x 220 DPI)

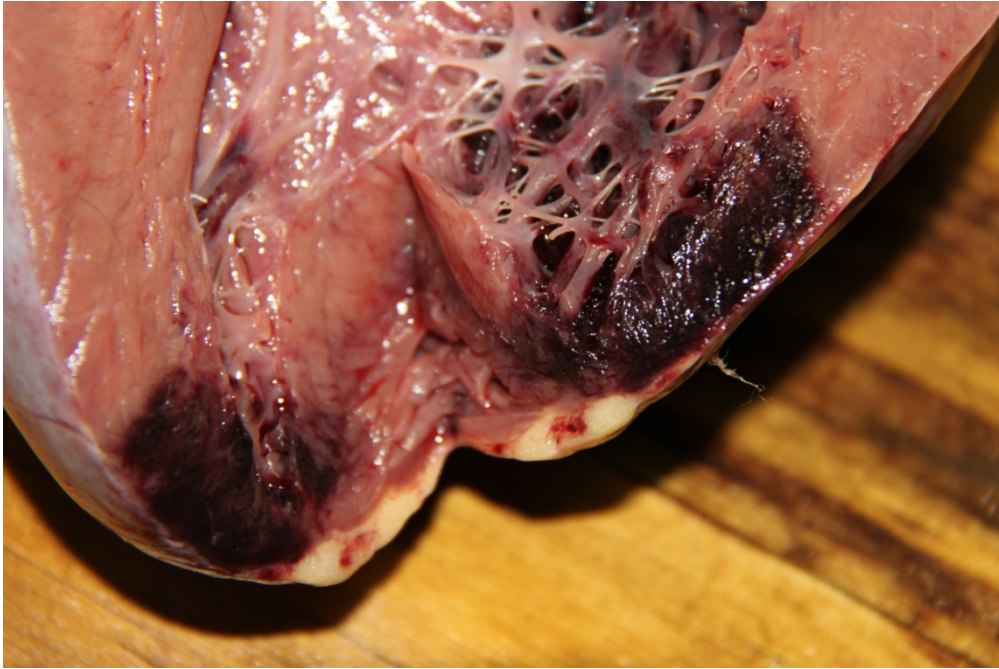Figure 10



The female victim of direct lightning strike. She was found dead in the field, two days after an electrical thunderstorm. Note the tearing and tattering of the yellow t-shirt, which assisted in diagnosing the cause of death. (Photograph courtesy of R Blumenthal).

159x119mm (220 x 220 DPI)

Figure 11



The heart muscle of a 10-year-old girl who survived lightning strike for a period of ten days in intensive care unit before dying. Note the intra-myocardial haemorrhage. (Photograph courtesy of R Blumenthal).

159x106mm (220 x 220 DPI)

Respiratory injuries associated with lightning strikes include pulmonary oedema, pulmonary contusion, acute respiratory distress syndrome, and pulmonary haemorrhage. Although pulmonary involvement is rare, it should always be kept in mind, as well as lightning-induced primary lung damage. Lung contusion should be followed with strict vital signs monitoring.

Fluid resuscitation is important. Various mechanisms of trauma to the thorax or secondary effects due to cardiac damage should be taken into consideration. Lightning strike injuries should be handled as high-energy trauma. Most of the time, a conservative approach and support are sufficient. Resuscitation should be performed in accordance with the recommendations of the latest Resuscitation Council guidelines. Resuscitation of lightning strike cases are considered to be more successful than usual; therefore, physicians should apply vigorous and prolonged resuscitation, [18].

The lightning-struck patient may have sustained blunt force trauma, or barotrauma. It may therefore be rational to approach such patients as multiple trauma patients, [18].

Document and photograph the clothing. Thoroughly examine the skin. Keep the eyes wet and closed. Look inside the ears for tympanic membrane rupture; look for signs of concussive injury; look for singeing of hair, exclude magnetization of metal (which is suspected to be a myth), look for secondary burns from surface discharge of metal or energetic electron burns; look for the 'tip-toe' sign – lightning exit wounds on base of the feet.

The complications of lightning strike may occur either early or late, or they may be local or systemic. The kidneys of lightning strike survivors may develop acute tubular necrosis, chiefly of the ischaemic type due to inadequate blood flow to the kidneys. Rarely, acute tubular necrosis of the toxic type, due to myoglobinuria, may occur. The heart should also be examined, a 10-year-old girl survived ten days in the intensive care unit before succumbing, her heart showed intra-myocardial haemorrhages. [Insert Figure 11].

Most of the resources and management will go into long-term care. Victims may suffer with chronic pain, psychological problems and/or cognitive defects. Key is to refer lightning strike survivors to support groups and other information sources.

In closing, the doctor-patient relationship is critical when it comes to lightning strike patients. These victims may end up consulting ophthalmologists, otorhinolaryngologists, cardiologists, neurologists, physiotherapists, occupational therapists, etcetera, with the consequence that these patients often do not even know who their doctor is. Key is life-long continuity of management.

ACKNOWLEDGEMENT

At the outset, my sincerest gratitude to Professor T Pillay for inspiring this paper. I would like to thank Professor M A Cooper for all her guidance, kindness, friendship and support. Professor V Cooray for assisting with certain insights and providing the necessary references. Special thanks to Doctor C Andrews and to Doctor R Holle for their continuous and wise insights. Thanks to Doctor N du Plooy and Mrs T Stuart for their photographs. The author would like to thank Doctor S Rossouw for proofreading the initial versions. Thanks to Professor G Saayman for initially 'sparking' my interest in the field of lightning research. Finally, a special thanks to Professor I R Jandrell, Professor C Gomes, Professor K Nixon, Mister I McKechnie, Doctor H Hunt, Doctor N J West, and the rest of the lightning team from the School of Electrical and Information Engineering, University of the Witwatersrand.

REFERENCES

1. Damjanov I, Linder J. Anderson's Pathology, Tenth Edition: Mosby Publishers, St. Louis, Missouri. 1996: 1-2.
2. Saukko P, Knight B. Knight's Forensic Pathology. Third Edition: Arnold Publishers 2004: 336 - 337.
3. Mason J K, Purdue B N. The Pathology of Trauma. Third Edition, Arnold Publishers 2000: 93-94.
4. Schwär T G, Loubser J D, Olivier J A. The Forensic ABC in Medical Practice, A Practical Guide. Haum Educational Publishers, Pretoria 1988: 222 and 231 – 233.
5. Wright R K, Tate L G. Forensic pathology, Last stronghold of the autopsy. *Am J For Med and Pathol* 1980;1;1:57 – 60.
6. Gradwohl R B H, Camps F E, Robinson AE, et al. Gradwohl's Legal Medicine. Third Edition: John Wright & Sons Ltd., Bristol 1976: Chapter 1.
7. Smith S. The history and development of forensic medicine. *British Medical Journal* 1951;1: 599-607.
8. Malan D J. Physics of Lightning. The English Universities Press Ltd. London. 1963. Introduction, xiii.
9. Rakov V A, Uman M A. Lightning Physics and Effects. Cambridge University Press. 2003: 4-6.
10. Jumbelic M I. Forensic perspectives of electrical and lightning injuries. *Seminars in Neurology* 1995;15;4:342 – 349.
11. Uman M A. Lightning. McGraw-Hill Book Company, 1969, USA 1969:1-13.
12. Yair Y. Lightning hazards to human societies in a changing climate. *Environ. Res. Lett.* 2018;13:123002
13. Sleiwah A, Baker J, Gowers C, et al. Lightning injuries in Northern Ireland. *Ulster Med J* 2018;87(3):168-172.
14. Auerbach P S. Wilderness Medicine, Sixth Edition: Elsevier Saunders. Philadelphia. 2012:60 - 101.
15. Blumenthal R, Jandrell I R, West N J. Does a Sixth Mechanism Exist to Explain Lightning Injuries? Investigating a Possible New Injury Mechanism to Determine the Cause of Injuries Related to Close Lightning Flashes. *Am J Forensic Med Pathol.* 2012;33;3: 222–226. doi: 10.1097/PAF.0b013e31822d319b
16. Fana X, Zhanga Y, Yind Q, et al. Characteristics of a multi-stroke “bolt from the blue” lightning-type that caused a fatal disaster. *Geomatics, Natural Hazards and Risk* 2019;10;1: 1425–1442.
17. Blumenthal R. Lightning and the Forensic Pathologist. *Acad Forensic Pathol.* 2018;8;1: 98-111.
18. Uzel Şener M, Demir A, Şener A. Lightning-strike-induced acute lung injury: a case report. *Ulus Travma Acil Cerrahi Derg* 2019;25:198-201.
19. Norman M E, Albertson D, Younge B R. Ophthalmic manifestations of lightning strike. *Surv Ophthalmol.* 2001;46;1:19-24. PMID: 11525786. [https://doi.org/10.1016/s0039-6257\(01\)00232-6](https://doi.org/10.1016/s0039-6257(01)00232-6).
20. Handa J T, Jaffe G J. Lightning maculopathy. A case report. *Retina* 1994;14;2):169-72. PMID: 8036327. <https://doi.org/10.1097/00006982-199414020-00011>.
21. Lee M S, Gunton K B, Fischer D H, et al. Ocular manifestations of remote lightning strike. *Retina.* 2002;22;6:808-10.

22. Espallat A, Janigian R Jr, To K. Cataracts, bilateral macular holes, and rhegmatogenous retinal detachment induced by lightning. *Am J Ophthalmol.* 1999;127;2:216-7. PMID: 10030571.
23. Pradhan E, Khatri E, Ahmed A A, et al. Lightning Injury to Eye: Brief Review of the Literature and Case Series. *Clinical Ophthalmology* 2020;14: 597-607.
24. Rogers G J, Grotte R. Unilateral, isolated, paediatric lightning-induced cataract: a case report. *Case Rep Ophthalmol Med.* 2011;2011:724395.
25. Saukko P, Knight B. Deaths from lightning. In: Knight's forensic pathology. 4th edition. CRC Press. Boca Raton 2016:336-337.
26. Mahajan A L, Rajan R, Regan P J. Lichtenberg figures: cutaneous manifestation of phone electrocution from lightning. *J Plast Reconstr Aesthet Surg.* 2008;61;1:111-3.
27. Resnik B I, Wetli C V. Lichtenberg figures. *Am J Forensic Med Pathol.* 1996;17;2:99-102.
28. Cooray V, Cooray G K and Cooray C. On the possible mechanism of keraunographic markings on lightning victims. *Journal of Atmospheric and Solar-Terrestrial Physics* 2015;136:119-123.
29. Christophides T, Khan S, Ahmad M, et al. Cardiac Effects of Lightning Strikes. *Arrhythmia & Electrophysiology Review* 2017;6;3:114-7. DOI: 10.15420/aer.2017:7:3
30. Browne B J, Gaasch W R. Electrical injuries and lightning. *Emerg Med Clin North Am* 1992;10:211-29.
31. Lifschultz B D, Donoghue E R. Deaths caused by lightning. *J Forensic Sci* 1993;38:353-8. PMID: 8454996.
32. Emet M, Caner I, Cakir M, et al. Lightning injury may cause abrupt cerebral salt wasting syndrome. *Am J Emerg Med.* 2010;28;5: 640.e1-3.
33. Weeramanthri T S, Puddey I B, Beilin L J. Lightning strike and autonomic failure--coincidence or causally related? *J R Soc Med.* 1991 Nov;84(11):687-8.
34. Andrews C J, Reisner A D, Cooper M A. Post electrical or lightning injury syndrome: a proposal for an American Psychiatric Association's Diagnostic and Statistical Manual formulation with implications for treatment. *Neural Regen Res.* 2017;Sep;12(9):1405-12.
35. Mahfuz T, Ferhat K, Nazim B, et al. Isolated Sensorineural Hearing Loss as a Sequela after Lightning Strike. *Case Reports in Otolaryngology* 2015, Article ID 738416, 4 pages.
36. Glunčić I, Roje Z, Glunčić V, et al. Ear injuries caused by lightning: report of 18 cases. *J Laryngol Otol.* 2001;115;1:4-8.
37. Modayil P C, Lloyd G W, Mallik A, et al. Inner ear damage following electric current and lightning injury: a literature review. *European Archives of Oto-Rhino-Laryngology,* 2014;271;5: 855-861.
38. Halldorsson A, Couch M H. Pneumomediastinum caused by a lightning strike. *J Trauma* 2004;57;1:196-7.
39. Blumenthal R, Saayman G. Case report: lightning-induced pneumomediastinum. *Am J Forensic Med Pathol.* 2017;38;2:94-6.
40. Jansen W. Death through lightning stroke. Wave-like arrangement of myocardial cells. In: *Forensic Histopathology.* Springer-Verlag Berlin Heidelberg. 1984: 271.
41. Perper J A, Wecht C H. *Microscopic Diagnosis in Forensic Pathology.* Charles C Thomas Publisher. 1980: 265-267.