

## Central odontogenic fibroma: an international multicentric study of 62 cases

Ana Luiza Oliveira Corrêa Roza DDS, MSc<sup>a</sup>, Emanuel Mendes Sousa DDS, MSc<sup>b</sup>, Amanda Almeida Leite DDS, MSc<sup>a</sup>, Gleyson Kleber Amaral-Silva DDS, MSc<sup>a</sup>, Thayná Melo de Lima Morais DDS, MSc<sup>a</sup>, Vivian Petersen Wagner DDS, PhD<sup>a</sup>, Lauren Frenzel Schuch DDS, MSc<sup>a</sup>, Ana Carolina Uchoa Vasconcelos DDS, PhD<sup>c</sup>, José Alcides Almeida Arruda DDS, MSc<sup>d</sup>, Ricardo Alves Mesquita DDS, PhD<sup>d</sup>, Felipe Paiva Fonseca DDS, PhD<sup>a,d,i</sup>, Aline Corrêa Abrahão DDS, PhD<sup>b</sup>, Michelle Agostini DDS, PhD<sup>b</sup>, Bruno Augusto Benevenuto de Andrade DDS, PhD<sup>b</sup>, Ericka Janine Dantas da Silveira DDS, PhD<sup>e</sup>, René Martínez-Flores DDS, MSc<sup>f</sup>, Benjamin Martínez Rondanelli DDS, PhD<sup>g</sup>, Javier Alberdi-Navarro DDS, PhD<sup>h</sup>, Liam Robinson BChD, PDD (Maxillofacial Radiology), PDD (Forensic Odontology)<sup>i</sup>, Constanza Marin DDS, MSc<sup>j</sup>, José Narciso Rosa Assunção Júnior DDS, PhD<sup>k</sup>, Renato Valiati DDS, PhD<sup>l</sup>, Eduardo Rodrigues Fregnani DDS, PhD<sup>m</sup>, Alan Roger Santos-Silva DDS, PhD<sup>a</sup>, Marcio Ajudarte Lopes DDS, PhD<sup>a</sup>, Keith D. Hunter BDS, PhD, FRC Path<sup>j,i</sup>, Syed Ali Khurram BDS, PhD, FRC Path<sup>j</sup>, Paul M. Speight BDS, PhD, FRC Path<sup>j</sup>, Adalberto Mosqueda-Taylor DDS, MSc<sup>n</sup>, Willie F.P. van Heerden BChD, MChD, FCPATH(SA) Oral, PhD, DSc<sup>i</sup>, Román Carlos DDS<sup>o</sup>, John M. Wright DDS, MSP<sup>p</sup>, Oslei Paes de Almeida DDS, PhD<sup>a</sup>, Mário José Románach DDS, PhD<sup>b,1</sup>, Pablo Agustin Vargas DDS, PhD, FRC Path<sup>a,i,1</sup>

<sup>a</sup>Oral Diagnosis Department, Piracicaba Dental School, University of Campinas (UNICAMP), São Paulo, Brazil

<sup>b</sup>Department of Oral Diagnosis and Pathology, School of Dentistry, Federal University of Rio de Janeiro (UFRJ), Rio de Janeiro, Brazil

<sup>c</sup>Diagnostic Center of Oral Diseases, School of Dentistry, Federal University of Pelotas (UFPEL), Pelotas, Brazil

<sup>d</sup>Department of Oral Surgery and Pathology, Federal University of Minas Gerais (UFMG), Belo Horizonte, Brazil

<sup>e</sup>Post-Graduate Program in Dentistry Sciences, Dentistry Department, Federal University of Rio Grande do Norte (UFRN), Natal, Brazil

<sup>f</sup>Department of Oral Pathology and Oral Medicine, Dentistry Faculty, Andrés Bello University, Viña del Mar, Chile

<sup>g</sup>Department of Oral Pathology and Oral Medicine, Dentistry Faculty, Mayor University, Santiago, Chile

<sup>h</sup>Oral Medicine and Oral and Maxillofacial Pathology Unit, Dental Clinic Service, Department of Stomatology II, University of the Basque Country (UPV/EHU), Leioa, Spain

<sup>i</sup>Department of Oral Pathology and Oral Biology, School of Dentistry, Faculty of Health Sciences, University of Pretoria, Pretoria, South Africa

<sup>j</sup>Academic Unit of Oral and Maxillofacial Medicine and Pathology, School of Clinical Dentistry, University of Sheffield, Sheffield, UK

<sup>k</sup>School of Dentistry, Metropolitan University of Santos (UNIMES), Santos, Brazil

<sup>l</sup>School of Dentistry, Planalto Catarinense University (UNIPLAC), Lages, Brazil

<sup>m</sup>Centro de Oncologia Molecular, Hospital Sírio Libanês, São Paulo, Brazil

<sup>n</sup>Departamento de Atención a la Salud, Universidad Autónoma Metropolitana Xochimilco, Mexico City, Mexico

<sup>o</sup>Pathology Section, Centro Clínico de Cabeza y Cuello/Hospital Herrera Llerandi, Guatemala City, Guatemala

<sup>p</sup>Department of Diagnostic Sciences, Texas A&M University College of Dentistry, College Station, TX, USA

\*Correspondence to: Pablo Agustin Vargas Oral Pathology Oral Diagnosis Department Piracicaba Dental School University of Campinas (UNICAMP) Av. Limeira 901 Areão Piracicaba São Paulo Brazil Postal code: 13414-903. Email: pavargas@unicamp.br

## Abstract

**Objective:** The aim of this study was to report the clinicopathologic features of 62 cases of central odontogenic fibroma (COdF).

**Study Design:** Clinical and radiographic data were collected from the records of 13 oral pathology laboratories. All cases were microscopically reviewed, considering the current World Health Organization classification of tumors and were classified according to histopathologic features.

**Results:** There were 43 females and 19 males (average age 33.9 years; range 8–63 years). Clinically, COdF lesions appeared as asymptomatic swellings, occurring similarly in the maxilla (n = 33) and the mandible (n = 29); 9 cases exhibited palatal depression. Imaging revealed well-defined, interradicular unilocular (n = 27), and multilocular (n = 12) radiolucencies, with displacement of contiguous teeth (55%) and root resorption (46.4%). Microscopically, classic features of epithelial-rich (n = 33), amyloid (n = 10), associated giant cell lesion (n = 7), ossifying (n = 6), epithelial-poor (n = 3), and granular cell (n = 3) variants were seen. Langerhans cells were highlighted by CD1a staining in 17 cases. Most patients underwent conservative surgical treatments, with 1 patient experiencing recurrence.

**Conclusions:** To the best of our knowledge, this study represents the largest clinicopathologic study of COdF. Most cases appeared as locally aggressive lesions located in tooth-bearing areas in middle-aged women. Inactive-appearing odontogenic epithelium is usually observed within a fibrous/fibromyxoid stroma, occasionally exhibiting amyloid deposits, multinucleated giant cells, or granular cells.

### Statement of Clinical Relevance

Our international, collaborative study contributes 62 additional cases of central odontogenic fibroma from 8 countries, representing the largest series in the English-language literature, with detailed clinicopathologic descriptions of this intriguing odontogenic tumor.

Central odontogenic fibroma (COdF) is an uncommon mesenchymal proliferation of dense to fibromyxoid connective tissue arising in the jaws and containing islands and cords of inactive odontogenic epithelium that vary in number and size.<sup>1,2,3</sup> The tooth-bearing areas of the anterior maxilla and of the posterior mandible of middle-aged females are most commonly affected, usually causing displacement and root resorption of adjacent teeth.<sup>1,2,3</sup> Despite its locally aggressive clinical appearance, most cases of COdF seem to exhibit limited growth rate, and a conservative surgical procedure, with maintenance of adjacent teeth and periodontal preservation, is usually recommended. Recurrence is rarely observed and is associated mainly with incomplete surgical removal.<sup>1,2,3</sup>

Microscopically, COdF may exhibit a wide spectrum of variants, including amyloid, giant cell lesion (GCL), ossifying, and granular cell types, causing a diagnostic challenge that pathologists face due to the rarity of the lesion.<sup>2,3,4</sup> Studies have reported the presence of Langerhans cells (LCs) in odontogenic fibromas,<sup>3,5,6</sup> mainly in the amyloid variant<sup>2,4;</sup>

**Table I.** Summarized data of series comprising of more than 10 cases of central odontogenic fibroma published in the English-language literature

Authors, y	Country	N	Gnd (F/M)	Mean age (range)	Site		Microscopic subtype	Palatal depression	Root resorption	Treatment (N) / Follow-up (months)	
					Max	Mand					
1	Günhan, 1990	Turkey	18	8/10	23.4 (15–51)	5	13	Conventional (18)	Na	Na	Na
2	Handlers, 1991	United States	19	15/4	37.2 (14–72)	16	3	Conventional (19)	5	5	CE (4)
3	Daley, 1994	Canada	25	Na	Na	Na	Na	Na	Na	Na	Na
4	Sriran & Shetty, 2008	India	12	5/7	37.8 (14–70)	6	6	Na	Na	Na	Na
5	Luo & Li, 2009	China	21	13/8	28 (12–60)	6	15	Na	Na	Na	Na
6	Mosqueda-Taylor, 2011	Mexico, Guatemala, & Brazil	14	7/7	31.8 (14–51)	8	6	Conventional (11) GCL (3)	2	1	CE (14) / 32.5
7	Eversole, 2011	United States	25	Na	Na	13	12	Conventional (17) Amyloid (4) GCL (2) Ossifying (2)	Na	Na	CE (25) / 32
8	Zhou & Li, 2018	China	17	10/7	33 (10–76)	12	5	Conventional (11) Amyloid (6)	6	13	CE (16), PR (1) / 6–170
9	Present study, 2020	Brazil, United States, United Kingdom, Mexico, South Africa, Chile, Gua- temala, and Spain	62	43/19	33.9 (8–63)	33	29	Conventional (36) Amyloid (10) GCL (7) Ossifying (6) Granular (3)	9	13	CE (33), PR (1) / 42

CE, conservative excision; F, female; GCL, giant cell lesion; Gnd, gender; M, male; Mand, mandible; Max, maxilla; N, number; Na, not available; PR, partial resection.

however, the pathologic significance of these cells and the possible role they play in different growth patterns remains unclear.

Accumulated evidence from the few studies reporting more than 10 cases of COdF published in the English-language literature<sup>2, 3, 4, 7, 8, 9, 10, 11</sup> (Table I) has indicated that the biologic behavior of COdF remains intriguing and poorly understood. Therefore, we hope to contribute our clinicopathologic findings of 62 additional cases of COdF from different countries, representing, to our knowledge, the largest series reported to date.

## Material and Methods

The present retrospective cross-sectional study included 62 cases of COdF retrieved from the archives of 13 oral pathology diagnostic services in 8 countries: 20 cases from Brazil (8 cases from University of Campinas, Piracicaba; 5 cases from Federal University of Rio de Janeiro, Rio de Janeiro; 4 cases from Federal University of Pelotas, Pelotas; 2 cases from Federal University of Minas Gerais, Belo Horizonte; and 1 case from Federal University of Rio Grande do Norte, Natal); 19 cases from the United States (Texas A&M University College of Dentistry, Dallas, TX); 5 cases from the United Kingdom (University of Sheffield, Sheffield); 5 cases from Mexico (Universidad Autónoma Metropolitana Xochimilco, Mexico City); 5 cases from South Africa (University of Pretoria, Pretoria); 5 cases from Chile (4 cases from Mayor University, Santiago; 1 case from Andrés Bello University, Viña del Mar); 2 cases from Guatemala (Centro Clínico de Cabeza y Cuello, Guatemala City); and 1 case from Spain (University of the Basque Country, Leioa).

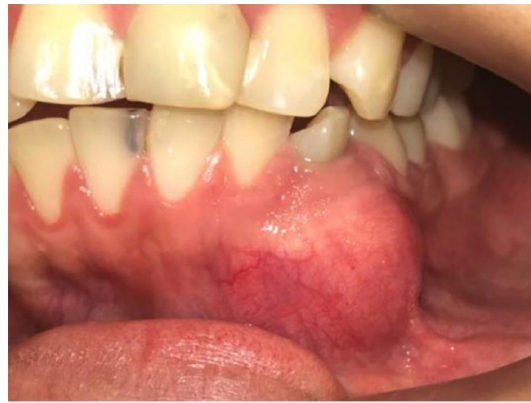Demographic, clinical, and radiographic data were obtained from laboratory archives for the period between 1980 and 2019. Cases with no clinical data or those of pericoronary lesions were excluded. All cases were analyzed under conventional optical microscopes by using 5- $\mu$ m sections on histologic slides stained with hematoxylin and eosin (H&E). The final diagnosis of COdF was confirmed and revised by 3 oral pathologists (A.L.O.C.R., M.J.R., and P.A.V.) considering the current World Health Organization (WHO) criteria established by Van Heerden et al.<sup>1</sup> Immunohistochemistry with the use of monoclonal antibody against CD1a (1:300, clone 010; Dako, Carpinteria, CA) was carried out for the identification of LC. In addition, reactions for pan-cytokeratin (1:500, clone AE1/AE3; Dako, Carpinteria, CA) were performed in 10 cases of epithelial-rich COdF, and for CD163 (1:300, 10 D6; Leica Biosystems, Buffalo Grove, IL) and CD138 (1:200, MI15; Dako, Carpinteria, CA) in 2 cases of granular cell COdF. Antigen retrieval with citrate was performed, and the slides were incubated with secondary antibodies conjugated with biotin (LSAB + System-HRP, mouse/rabbit; Dako, Carpinteria, CA) for 30 minutes at 37°C, followed by streptavidin-horseradish peroxidase (Dako, Carpinteria, CA) for another 30 minutes, and developed with chromogenic substrate (3,3'-diaminobenzidine; Sigma, St Louis, MO, USA). Positive controls were included in all analyses. Congo red staining was performed, and slides were examined under polarized light. The presence of green birefringence was considered to be indicative of amyloid material. A descriptive analysis of histopathologic and immunohistochemical findings was performed. This study was carried out according to the tenets of the Helsinki Declaration for studies involving human subjects and was approved by the local research ethics committee (FOP-UNICAMP, process no. 23616619.4.0000.5418).

## Results

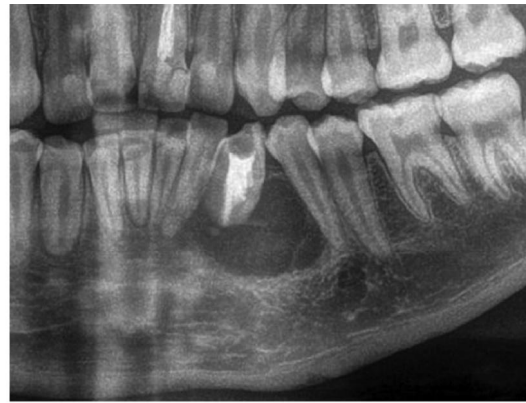
The clinical and radiographic data of the 62 cases of COdF are summarized in Supplemental Table S1 (available at <https://rb.gy/3za8h0>). Forty-three patients (69%) were females and 19 (31%) were males (mean age 33.9 years; range 8–63 years). The tumors were distributed exclusively in the gnathic bones, with 33 tumors (53%) affecting the maxilla and 29 tumors (47%) affecting the mandible. Of the maxillary tumors, 24 (73%) presented anterior to the first molar, 6 (18%) in the posterior maxillary region, and 2 (6%) in both the anterior and posterior regions, and in 1 (3%), the location was not specified. Mandibular lesions mainly involved the posterior region (17 cases [59%]) compared with tumors located anterior to the first molar (12 cases [41%]). The main clinical presentations were asymptomatic swellings confined to the area between dental roots causing cortical expansion; 9 maxillary tumors (27%) presented with palatal depression and a single mandibular tumor presented extensive alveolar bone resorption (Figure 1).

Radiographic examination results were available in 21 cases (37%), and information regarding detailed radiographic features was collected from descriptions of biopsy results in 36 cases (63%). Tumors were mainly described as well-defined radiolucent defects (52 cases [91%]) and occasionally presented as mixed radiolucent–radiopaque lesions (5 cases [9%]); there were 27 unilocular (47%) and 12 multilocular (21%) lesions, with an average size of 2.2 cm (range 1–5.5 cm). From the available radiographic information, 26 tumors (46%) were located exclusively in the periradicular region, and only 2 (4%) showed extension to the periapical region of vital teeth. There was associated displacement of contiguous teeth in 22 cases (55%) and root resorption in 13 cases (46%) (Figure 2).

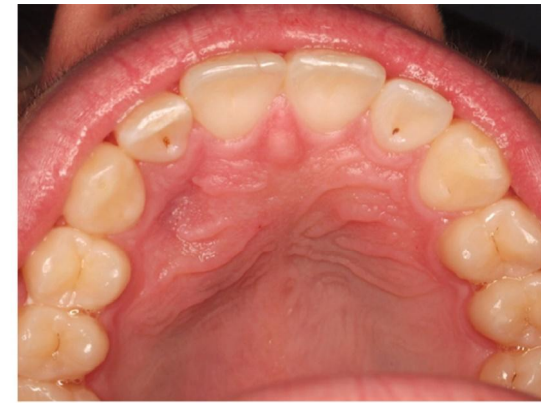Microscopically, 33 cases were classified as conventional epithelial-rich COdF (53%), demonstrating abundant odontogenic epithelium arranged in islands and cords immersed in a collagenous stroma (Figure 3), and only 3 tumors presented as epithelial-poor COdF (5%) (Supplemental Table S2; available at <https://rb.gy/5b7vus>). Ten cases of COdF classified as amyloid-variant COdF (16%) showed positive Congo red staining with green birefringence under polarized light; 7 cases were associated with GCL (11%), 6 cases were classified as ossifying-variant COdF (10%), and 3 cases met the diagnostic criteria for classification as granular cell-variant COdF (5%). The stroma was predominantly fibromyxoid in 43 cases (70%), 15 tumors (25%) exhibited mainly dense collagen fibers, and 3 (5%) exhibited granular stroma. Chronic inflammatory infiltrate and hemorrhage were commonly seen in the surrounding connective tissue in 38 cases (62%) and 37 cases (61%), respectively. Vacuolated clear epithelial cells were observed in 36 cases (59%), of which only 7 cases (11%) were associated with juxtaepithelial hyalinization deposits. Twenty-five cases (41%) contained perilesional bone trabeculae, and 10 cases (16%) showed occasional dystrophic calcification. Four cases contained odontogenic epithelial islands with cystic degeneration, and a single case demonstrated an uncommon ameloblastomatoid appearance. Immunohistochemical staining for CD1a was performed in 35 cases. Dendritic LCs intermingled within the odontogenic epithelium were highlighted in 17 cases (49%): 7 cases were classic epithelial-rich COdF; 6 were of amyloid-variant COdF; 3 were granular cell COdF; and 1 was COdF-GCL. Ten cases were submitted to immunohistochemical staining for AE1/AE3, and all of them stained positive in their epithelial islands and cords. Two cases of



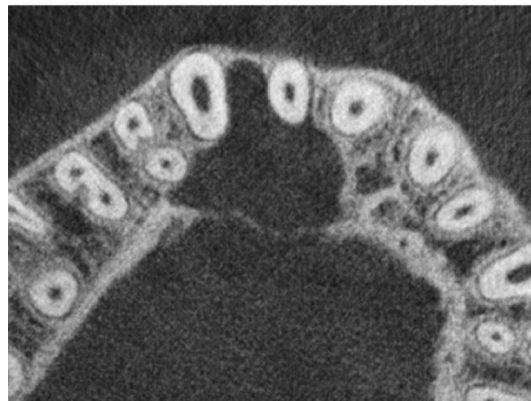(a)



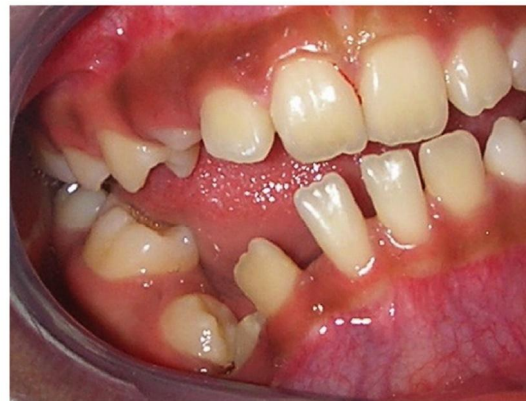(b)



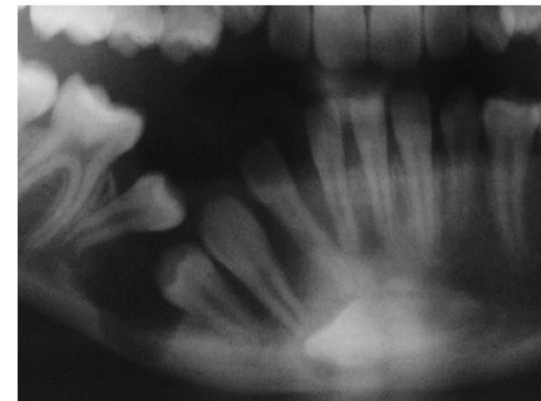
(c)



(d)

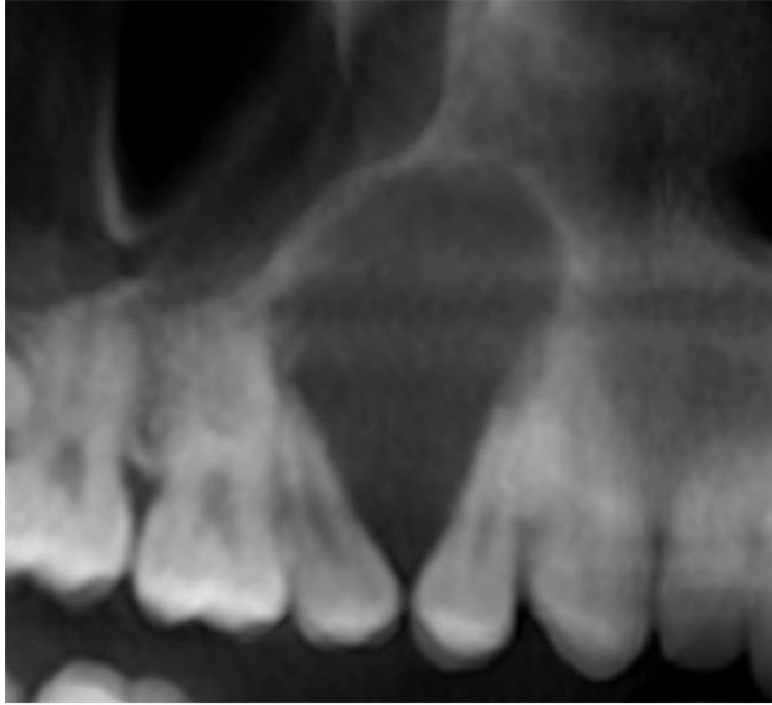


(e)

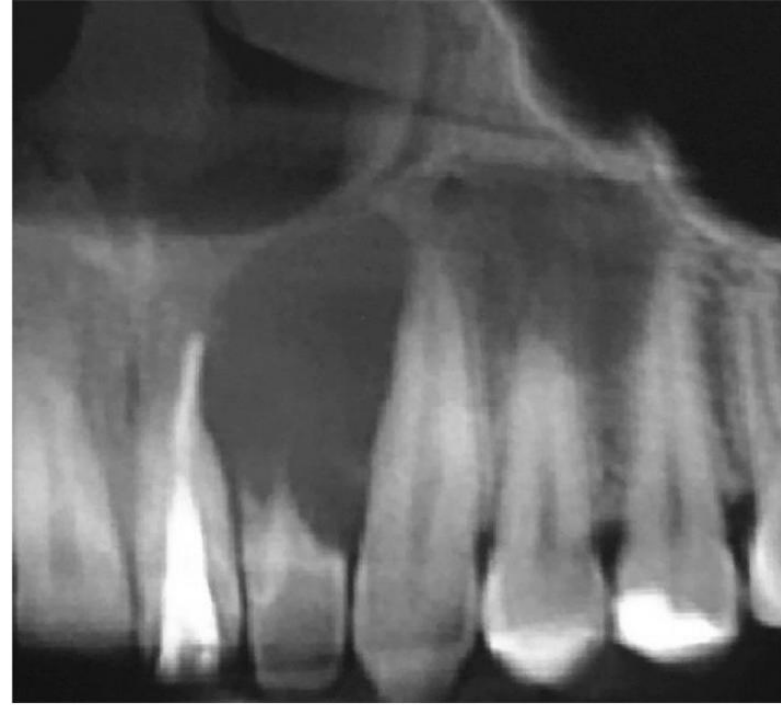


(f)

Fig. 1. Clinical and radiographic features of central odontogenic fibromas. A, Asymptomatic tumor causing buccal cortical bone swelling in anterior mandible of a Guatemalan patient. B, The tumor appears as a periradicular well-defined radiolucency causing tooth displacement (case 61). C, Anterior maxillary tumor causing palatal depression in a Spanish patient. D, Radiographically, the tumor appeared as a well-defined unilocular hypodense lesion causing palatal bone thinning (case 62). E, Extensive alveolar ridge depression in mandibular body of a 12-year-old female Guatemalan patient. F, The tumor appeared as a well-defined radiolucency causing exuberant alveolar bone resorption (case 60).



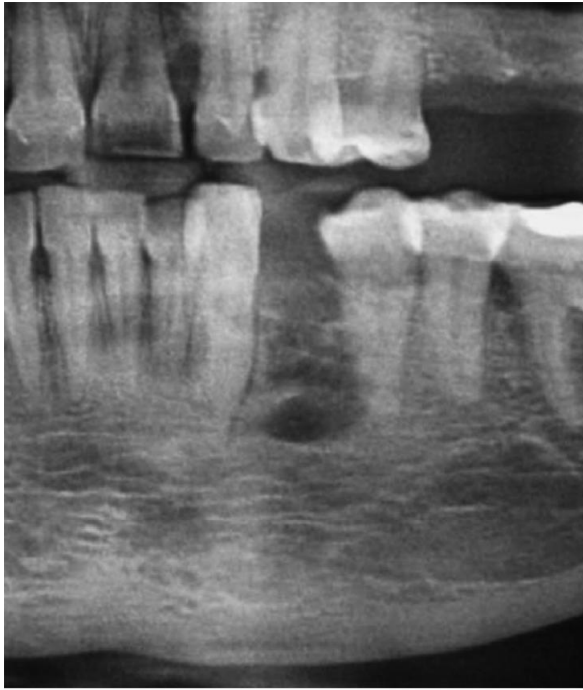**(a)**



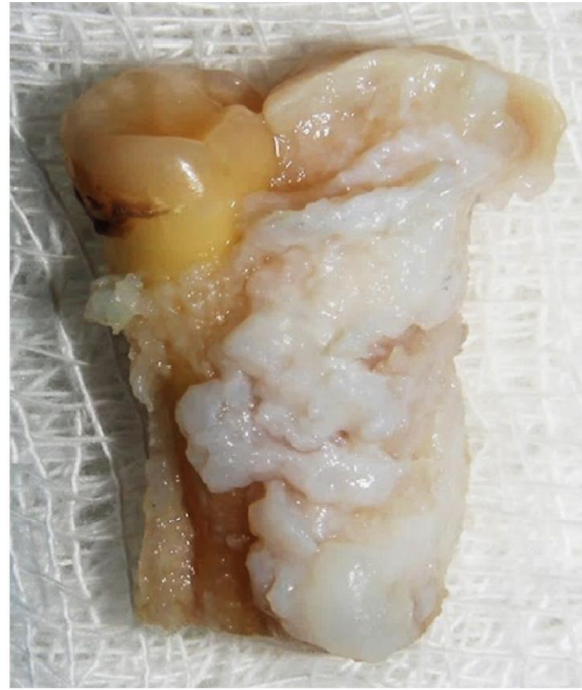**(b)**

Fig. 2. Radiographic features of central odontogenic fibroma (COdF). A,B, Well-defined radiolucent maxillary COdFs located anterior to the first molar causing tooth displacement and extensive root resorption (A, case 32; B, case 19).

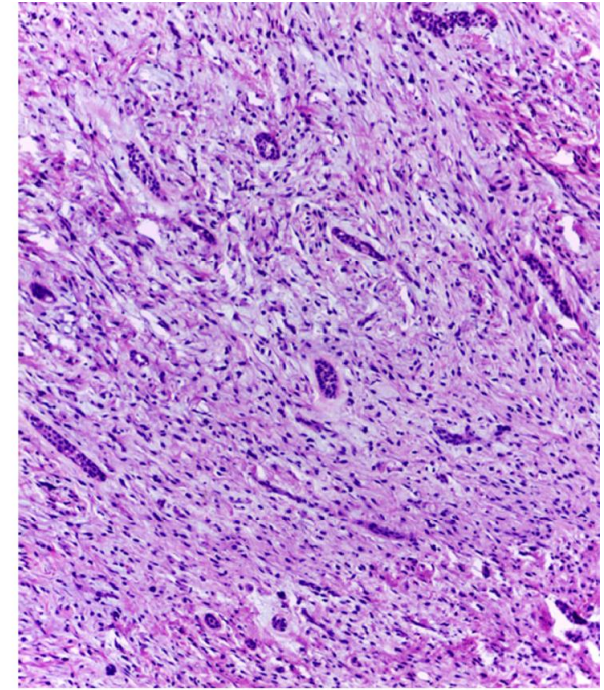




**(a)**



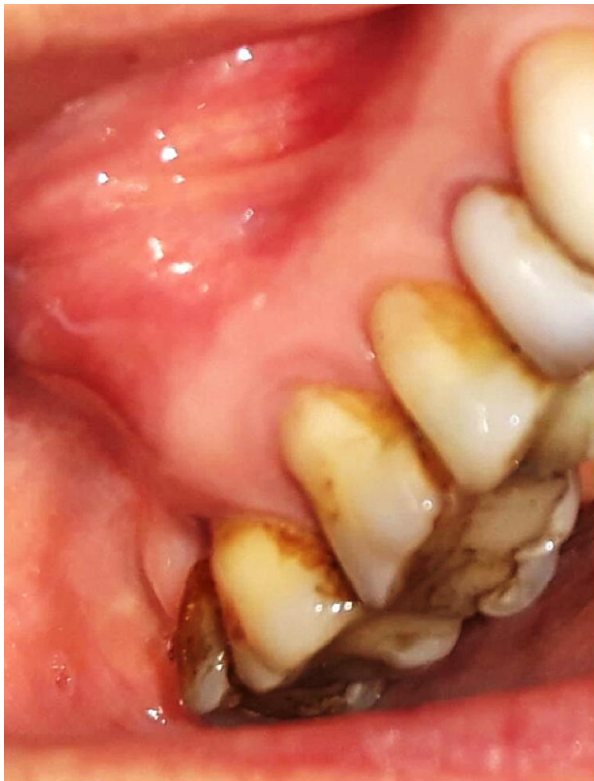**(b)**



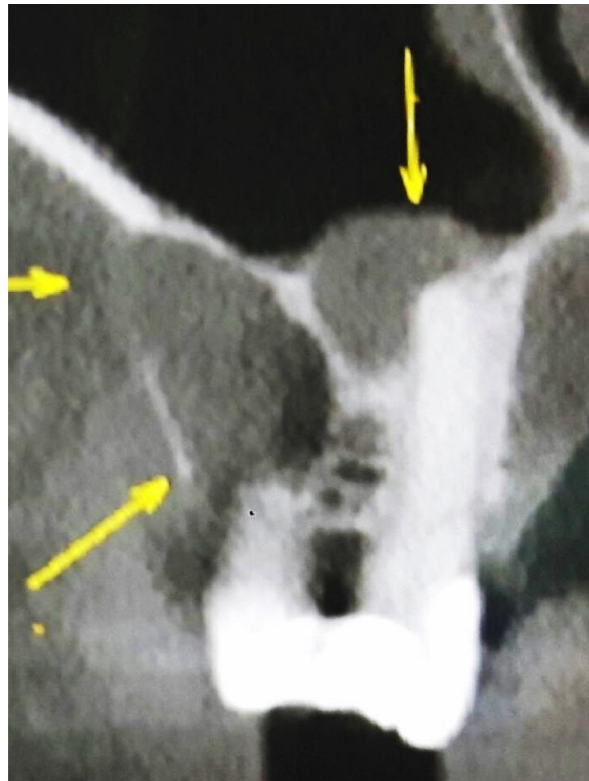
**(c)**

Fig. 3. Radiographic, macroscopic, and microscopic features of epithelial-rich central odontogenic fibroma (case 2). A, Periradicular multilocular radiolucency causing tooth displacement. B, Soft tissue tumor enveloping a tooth root. C, Microscopic appearance as a proliferation of numerous odontogenic epithelium arranged in islands and cords immersed in a fibromyxoid stroma (hematoxylin and eosin [H&E];  $\times 40$ ).

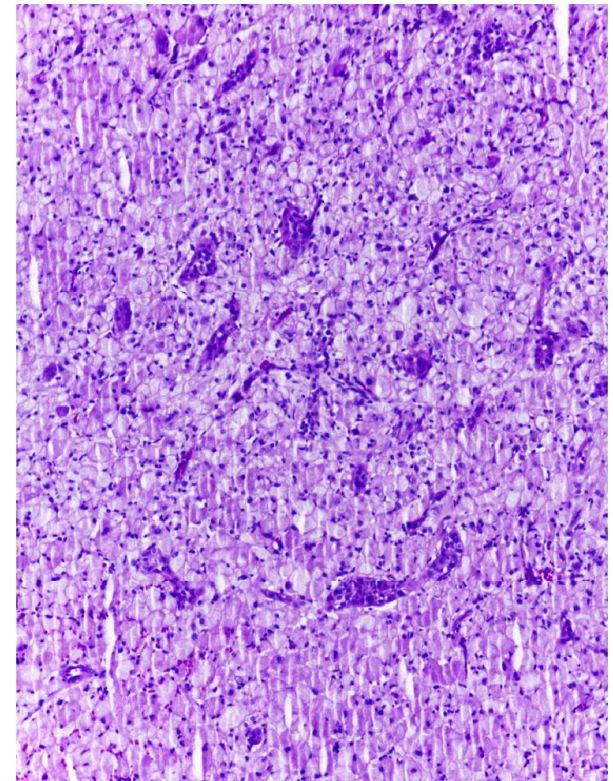




**(a)**



**(b)**



**(c)**

Fig. 4. Central odontogenic fibroma, granular cell variant (case 4). A, Asymptomatic buccal swelling located in the posterior maxilla in an elderly Brazilian woman. B, Image examination revealed a bilocular hypodense lesion in close relationship to tooth roots. C, Microscopically, the tumor exhibited nests and cords of odontogenic epithelium in a granular stroma (hematoxylin and eosin [H&E];  $\times 100$ ).



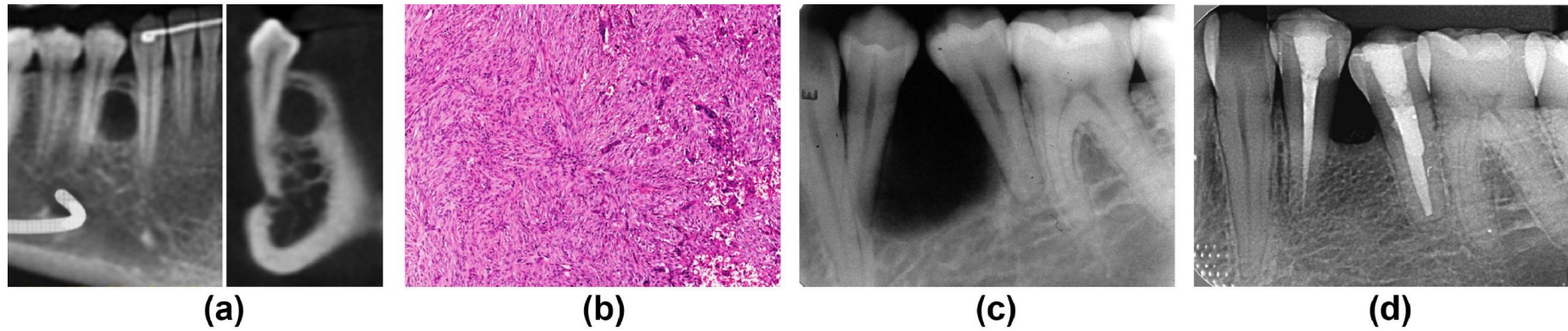


Fig. 5. Central odontogenic fibroma associated with giant cell lesion (COdF-GCL). A, Tomographic imaging showing an asymptomatic interradicular, well-defined, unilocular radiolucency in the body of mandible, located between permanent premolars in a 17-year-old Brazilian patient (case 17). B, Microscopically, the tumor exhibited features of both COdF and GCL. C, Interradicular COdF-GCL in a 22-year-old Brazilian woman (case 6). D, The tumor demonstrated bone neoformation throughout 8 years after conservative surgical removal, with no signs of recurrence (A, panoramic reconstruction and coronal sections; B, hematoxylin and eosin [H&E];  $\times 100$ ).

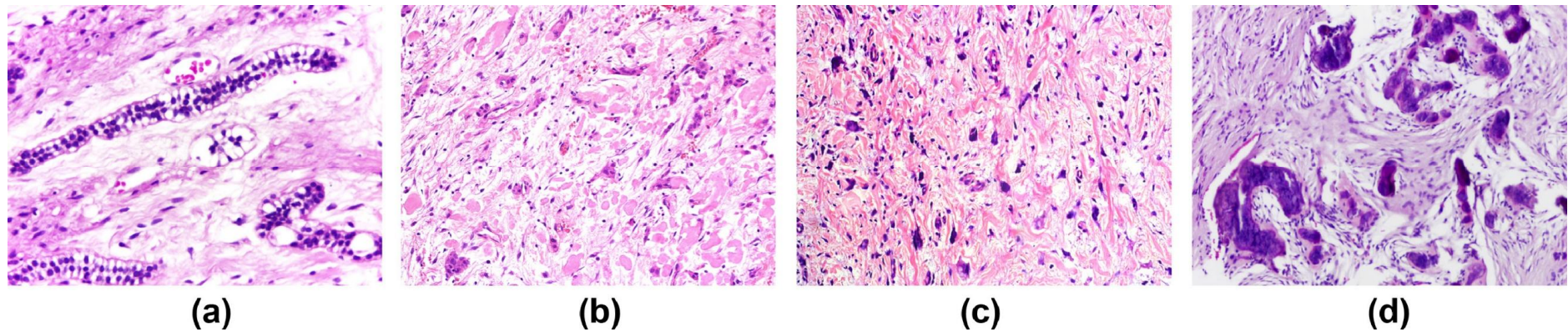


Fig. 6. Microscopic features of central odontogenic fibroma. Strands and islands of inactive odontogenic epithelium (A), exhibiting cytoplasmic vacuolation in close association with blood vessels and (B) in a fibromyxoid stroma secreting eosinophilic amorphous globules compatible with amyloid deposits. Stromal components presented with numerous plump, floret-like fibroblasts (C) and occasional ossified material (D) (hematoxylin and eosin [H&E]; A,  $\times 200$ , B-D,  $\times 100$ ).

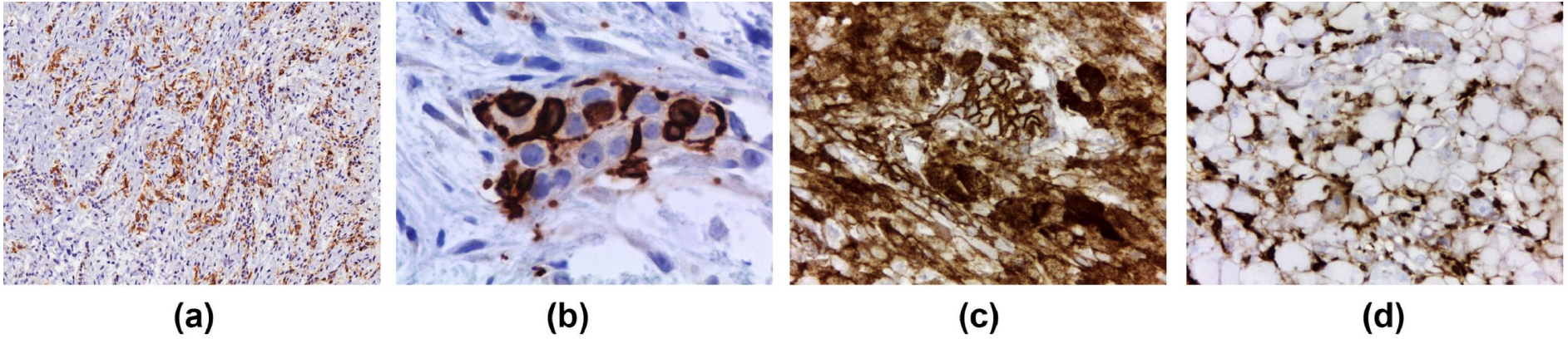


Fig. 7. Immunohistochemical features of central odontogenic fibroma. A,B, CD1a stain highlighting Langerhans cells intermingled within odontogenic epithelium. C, Epithelial and granular cells were positive for CD138. D, Only granular cells were positive for CD163 (Immunohistochemistry; A,  $\times 100$ ; B,  $\times 400$ ; C,D,  $\times 200$ ).

granular cell COdF showed positivity for CD163 in granular cells and for CD138 in both epithelial and granular cell components (Fig. 4, Fig. 5, Fig. 6, Fig. 7).

Data regarding treatment was available for 34 cases (55%); 33 patients were treated with conservative surgical excision and 4 with additional extraction of adjacent teeth, and 1 patient received partial block resection. Follow-up data were available in 18 cases, with an average follow-up of 3.5 years (range 6 months to 15 years); recurrence was observed in 1 patient 3 years after initial surgical enucleation.

## Discussion

Despite the early descriptions of the so-called odontogenic fibroma by Thoma and Goldman,<sup>12</sup> many authors debated its acceptance as a distinct clinicopathologic entity due to controversial misdiagnoses of hyperplastic dental follicles and desmoplastic fibromas.<sup>13, 14, 15, 16, 17</sup> It was not until 1971 that the diagnostic criteria for odontogenic fibroma were established in the first WHO classification of odontogenic tumors, recognizing a WHO type (epithelial-rich) and simple type (epithelial-poor).<sup>18</sup> Currently, COdF is defined as a relatively uncommon fibroblastic odontogenic tumor that may arise from the mesenchymal portion of the tooth germ or the periodontal membrane, justifying its close relationship to tooth roots.<sup>1</sup>

According to the literature, COdF has a decided predilection for female patients and affects a wide age range, with an even distribution throughout the second to the sixth decades.<sup>19</sup> In the present study, 69% of patients were women, representing a ratio of 2.2:1, slightly higher than those reported by Eversole<sup>2</sup> (3:2) and Mosqueda-Taylor et al.<sup>3</sup> (1:1), with mean age being 33.9 years, and included 38 patients diagnosed between the second and the fourth decades of life. Generally, the jaws are equally affected in most case series. Nonetheless, Günhan et al.<sup>7</sup> reported a disproportionate rate of preference in their study, with the mandible (72%) favored over the maxilla (28%), whereas Handlers et al.<sup>8</sup> reported contrasting results, with the maxilla (84%) being more commonly affected than the mandible (16%). In the present study, the maxilla was slightly more affected compared with the mandible, a pattern also previously reported in other studies,<sup>2, 3, 4, 8</sup> with 38 cases (61%) located anterior to the first molar. The preference for the anterior portions of the gnathic bones contrasts with other odontogenic tumors, which are more commonly observed in the posterior mandible, with exception of the adenomatoid odontogenic tumor.<sup>20</sup>

Nine maxillary cases (27%) presented clinically as palatal depressions, and a single Guatemalan patient presented with extensive alveolar bone depression in the anterior mandible, an additional clinical feature that is often associated with COdFs located anterior to the first molars. Brannon<sup>19</sup> attributed this finding to palatal bone perforation, which provokes the adjacent mucosa to collapse, forming a cleft. Additionally, although the present cases with palatal depression lacked morphologic differences, we also speculate that the mesenchymal nature of some considerably fibromyxoid to sclerosing COdFs might contribute to this unique retraction phenomenon.

COdF is usually described as a periradicular unilocular or multilocular radiolucency with well-defined or corticated borders.<sup>19, 21, 22</sup> The present study showed 52 radiolucent and 5



mixed radiolucent–radiopaque lesions. Tumors mainly manifested as periradicular unilocular (27 cases) or multilocular (12 cases) lesions, with an average size of 2.2 cm. Interestingly, Kaffe and Buchner<sup>21</sup> noted that most small tumors usually show a unilocular presentation and tend to become multilocular as they grow; they also observed root resorption in 29% of cases, a percentage far lower than that found in the present study (46%). Although COdF rarely measures greater than 3 cm, many cases show aggressive clinical and radiographic appearances, including cortical bone expansion with perforation, displacement of contiguous teeth, and significant root resorption. Therefore, the radiographic differential diagnosis of COdF should include other odontogenic lesions that may appear as periradicular radiolucencies, such as lateral periodontal cyst, odontogenic keratocyst, central GCL, ameloblastoma, odontogenic myxoma, and squamous odontogenic tumor.<sup>23</sup>

COdF is typically a fibrous tumor consisting of connective tissue with varying cellularity and containing differing amounts of inactive-looking odontogenic epithelium.<sup>1</sup> In the present study, 33 cases presented with the classic histologic features of epithelial-rich COdF, characterized by abundant inactive odontogenic epithelium organized in islands and strands in a fibroblastic proliferation, and only 3 cases presented as epithelial-poor COdF. Mosqueda-Taylor et al.<sup>3</sup> also reported a single case of epithelial-poor COdF and were not able to differentiate these subtypes through immunohistochemical and ultrastructural analyses, reaffirming the 2 possible microscopic patterns as conventional COdF. The mesenchymal component of all cases was reviewed, and they varied from loose to dense collagen fibers, with most cases presenting a fibromyxoid appearance (70%), followed by a background of dense collagen fibers (25%). Areas of epithelial-rich COdF can be seen in hamartomatous proliferations in dental follicles; nevertheless, pericoronary lesions were excluded in this study. As proposed by Slootweg and Müller,<sup>24</sup> central jaw fibromas that lack the typical morphology of desmoplastic fibroma and present irregular small calcified particles should be considered epithelial-poor COdF.

In addition, 10 cases (16%) presented considerable amounts of amyloid deposits, showing positive Congo red staining with green birefringence under polarized light. Nine (90%) of these cases were located in the anterior maxilla and 1 (10%) in the posterior mandible, fulfilling the diagnostic criteria for amyloid-variant COdF. The amorphous and eosinophilic concentric globules consistent with amyloid deposits, previously reported as *odontogenic ameloblast-associated protein*,<sup>2</sup> were found near the epithelial component or lying free in the fibromyxoid component. Gardner<sup>25</sup> was one of the first to describe the possible presence of amorphous eosinophilic material within COdF and was later reported also by Eversole<sup>2</sup> and Zhou and Li.<sup>4</sup> Some studies have detected the presence of LCs within the epithelial component, causing diagnostic confusion and controversy among oral pathologists, some who have alternatively designated these tumors as noncalcifying Langerhans cell–rich variant of calcifying epithelial odontogenic tumor (NCLC-CEOT). Recently, Ide et al.<sup>26</sup> provided a detailed review of the NCLC-CEOT, concluding the categorization of this tumor as COdF due to clinical and microscopic similarities between both entities.

In the present study, 7 COdF lesions were associated with GCL (11%), of which 6 (86%) were located in the mandible and 1 (14%) in the maxilla. Five of these (71%) were located anterior

to the first molar (average patient age 30.7 years; range 12–63 years). Since the first report from Germany,<sup>27</sup> the concomitant occurrence of COdF with GCL, although uncommon, has been well documented in the literature; however, whether this finding represents a reactive phenomenon, part of the microscopic spectrum, or a hybrid tumor remains unclear. Eversole<sup>2</sup> questioned the lack of association between GCL and other odontogenic neoplasms and disagreed with the suggestion of a reactive phenomenon. Six of the present cases were classified as ossifying-variant COdF (10%), of which 4 (67%) were located in the mandible and 2 (33%) in maxilla, demonstrating lack of preference for either the anterior or the posterior region. The unique coexistence of COdF and ossifying fibroma has been scarcely reported in the literature. Eversole<sup>2</sup> described this particular subtype as 2 entities that fully integrate, as opposed to COdF–GCL, where both are juxtaposed to each other. We postulate that COdF could be considered a fibrous tumor that contains unique periodontal stem cells with the potential to differentiate into osteoid producing cells, osteoclast-like multinucleated giant cells, and fibroblast-like cells. It may be difficult to determine whether the OsF and GCL variants of COdF are hybrid tumors or not; however, it seems reasonable to think that COdF, OsF, and GCL might have a certain relationship with each other—possibly a common origin from the odontogenic mesenchymal tissue of the periodontium. Care must be taken to distinguish between curetted reactive bone at the periphery of the lesion and a truly integrated fibro-osseous component of the tumor.

In rare instances, COdF may also be composed of variable amounts of large granular cells, as was seen in 3 (5%) of the cases in the present study. Formerly known as *granular cell odontogenic tumor*, this unusual subtype is now considered under the umbrella term *COdF*. This particular variant occurs mainly in older women and favors the posterior mandibular region. Similarly, among all our cases, women were more affected (average age 50.3 years); however, in 2 cases, the tumors affected the posterior maxilla and in a single case the posterior mandible. Immunohistochemical and ultrastructural studies of the granular cells have shown, respectively, positive stains for CD68 and cytoplasmic structures consistent with lysosomes.<sup>28</sup> In 2 cases of the present study (cases 4 and 45), granular cells were positive in membrane pattern for CD163, a monocyte-/macrophage-derived differentiation antigen limited to neoplasms of monocyte/histiocyte derivation, indicating a histiocytic differentiation of stromal granular cells of COdF. CD138 (syndecan-1) is a cell surface proteoglycan that modulates epithelial–stromal interactions, cell–cell adhesion, and cell proliferation. In the present study, the odontogenic epithelium showed membrane positivity, and stromal granular cells also stained positive in a cytoplasmic pattern (cases 4 and 45), as also observed by Mesquita et al.,<sup>29</sup> indicating reciprocal interactions between the odontogenic epithelium and granular cells. These findings may corroborate the hypothesis that precursor mesenchymal stem cells of COdFs may retain a wide capacity for differentiation within the fibrohistiocytic phenotype spectrum.

Chronic inflammatory cell infiltration and hemorrhage were observed in the surrounding connective tissue in 62% and 61% of the present cases, respectively. The presence of an inflammatory infiltrate may be explained by the close relationship that tumors have with tooth surfaces and may cause difficulty in identifying the epithelial component. Rarely, COdF may show considerably increased amounts of odontogenic epithelial islands and cords in highly fibrous stroma, which may share overlapping histologic features with the so-called sclerosing odontogenic carcinoma,<sup>30</sup> a rare malignant odontogenic neoplasm recently added



in the latest WHO classification. In the present study, all cases showed a bland appearance of both epithelial and mesenchymal components, with no perineural invasion. Considering their rarity, the microscopic distinction between selected cases of COdF and sclerosing odontogenic carcinoma may still represent a current challenge for many oral pathologists.<sup>31,32</sup>

In the present study, 25 cases (41%) presented with perilesional bone trabeculae, with occasional dystrophic calcification (16%) in the stromal tissue. However, hard tissue within the mesenchymal component is described as part of the microscopic spectrum for COdFs. Curiously, a single case presented with numerous plump, floret-like fibroblasts embedded within a fibrous stroma, an uncommon microscopic finding rarely reported in COdF.<sup>33</sup> In 4 of the present cases, the tumors exhibited an attempt to form microcystic degeneration within the odontogenic epithelial cords, as similarly described by Dunlap.<sup>34</sup> In a single case, an American patient (case 29), the tumor demonstrated an uncommon ameloblastomatoid appearance within the epithelial component, a peculiar feature that has been previously reported in 2 cases by Ide et al.<sup>35</sup> Care should be taken not to misinterpret ameloblastomatoid epithelium in COdFs as ameloblastoma, to avoid overtreatment.

Clear cells within epithelial islands and nests were observed in 59% of COdFs, occasionally associated with juxtaepithelial hyalinization. LCs represent a unique cell type with a dual identity, arising from macrophage precursors and further acquire dendritic cell properties.<sup>36</sup> Because the oral and odontogenic epithelia originate from the same embryonic source, varying amounts of LCs, morphologically characterized by indented nuclei and clear cytoplasm, intermingled within the epithelial component is expected.<sup>1, 2, 3,5,6</sup> CD1a-positive LCs within the odontogenic epithelial islands were highlighted in 17 of 35 COdFs examined, accounting for 7 epithelial-rich COdF, 6 amyloid-variant COdF, 3 granular cell COdF, and 1 COdF-GCL. Interestingly, all granular cell COdFs and 60% of amyloid variant were strongly positive for CD1a, which may indicate possible induction of stromal mesenchymal differentiation in the presence of LCs.

Patients diagnosed with COdF have been treated successfully with conservative surgical excision, with minimal recurrence rates,<sup>19</sup> as was seen in the cases in the present study. Treatment methods were available for 34 cases, with only 1 patient experiencing recurrence. Although COdFs may show relative radiographic aggressiveness, maintenance of adjacent teeth as much as possible after conservative tumor enucleation seems to be the acceptable approach in most cases and yields good outcomes.

## Conclusions

In summary, this represents the largest clinicopathologic study of COdF, to date, in the English-language literature. Most cases appeared as a swelling or palatine depression affecting the tooth-bearing areas in middle-aged women, with a rare tendency to recur after conservative surgery. The mesenchymal fibromyxoid tumor may exhibit variable amounts of inactive-appearing odontogenic epithelium intermingled with LCs and may occasionally show amyloid deposits, multinucleated giant cells, osteoid deposition, and granular cells. These features may likely represent the wide differentiation potential of periodontal stem cells. Further large series are needed to expand our knowledge of COdF and its variants.

## References

1. Van Heerden WFP, Kusama K, Neville BW. Odontogenic fibroma. In: El-Naggar AK, Chan JKC, Grandis JR, Takata T, Slootweg PJ, eds. *WHO Classification of Head and Neck Tumors*, 4th ed., Lyon, France: IARC; 2017. p. 228.
2. Eversole LR. Odontogenic fibroma, including amyloid and ossifying variants. *Head Neck Pathol.* 2011; 5: 335-343.
3. Mosqueda-Taylor A, Mart\_inez-Mata G, Carlos-Bregni R, et al. Central odontogenic fibroma: new findings and report of a multicentric collaborative study. *Oral Surg Oral Med Oral Pathol Oral Radiol Endod.* 2011; 112: 349-358.
4. Zhou CX, Li TJ. A clinicopathologic study on central odontogenic fibroma: with special reference to amyloid variant. *Oral Surg Oral Med Oral Pathol Oral Radiol.* 2018; 126: 513-520.
5. Wu YC, Wang YP, Chang JY, Chen HM, Sun A, Chiang CP. Langerhans cells in odontogenic epithelia of odontogenic fibromas. *J Formos Med Assoc.* 2013; 112: 756-760.
6. Mittal N, Hyam D, Jain S, Lui M, Dahlstrom J. Central odontogenic fibroma of maxilla: significance of coexisting Langerhans cells. *Pathology.* 2014; 46: S9-S10.
7. G€unhan O, Erseven G, Ruacan S, et al. Odontogenic tumours. A series of 409 cases. *Aust Dent J.* 1990; 35: 518-522.
8. Handlers JP, Abrams AM, Melrose RJ, Danforth R. Central odontogenic fibroma: clinic-pathologic features of 19 cases and review of the literature. *J Oral Maxillofac Surg.* 1991; 49: 46-54.
9. Daley TD, Wysocki GP, Pringle GA. Relative incidence of odontogenic tumors and oral and jaw cysts in a Canadian population. *Oral Surg Oral Med Oral Pathol.* 1994; 77: 276-280.
10. Sriram G, Shetty RP. Odontogenic tumors: a study of 250 cases in an Indian teaching hospital. *Oral Surg Oral Med Oral Pathol Oral Radiol Endod.* 2008; 105: e14-e21.
11. Luo HY, Li TJ. Odontogenic tumors: a study of 1309 cases in a Chinese population. *Oral Oncol.* 2009; 45: 706-711.
12. Thoma KH, Goldman HM. Odontogenic tumors: a classification based on observations of the epithelial, mesenchymal, and mixed varieties. *Am J Pathol.* 1946; 22: 433-471.
13. Pincock LD, Bruce KW. Odontogenic fibroma. *Oral Surg Oral Med Oral Pathol.* 1954; 7: 307-311.
14. Dixon WR, Ziskind J. Odontogenic fibroma. *Oral Surg Oral Med Oral Pathol.* 1956; 9: 813-816.
15. Silverman LM. Odontogenic fibroma of the maxilla: report of a case. *Oral Surg Oral Med Oral Pathol.* 1958; 11: 128-131.
16. Hamner J.E. 3rd, Gamble JW, Gallegos GJ. Odontogenic fibroma. Report of two cases. *Oral Surg Oral Med Oral Pathol.* 1966; 21: 113-119.
17. Mallow RD, Spatz SS, Zubrow HJ, Kline SN. Odontogenic fibroma with calcification. Report of a case with a review of the literature. *Oral Surg Oral Med Oral Pathol.* 1966; 22: 564-568.
18. Pindborg JJ, Kramer IRH, Torloni H. Histological typing of odontogenic tumours, jaw cysts and allied lesions. In: Sobin LH, ed. *International Histological Classification of Tumours. No. 5*, Geneva, Switzerland: World Health Organization; 1971.
19. Brannon RB. Central odontogenic fibroma, myxoma (odontogenic myxoma, fibromyxoma), and central odontogenic granular cell tumor. *Oral Maxillofac Surg Clin North Am.* 2004; 16: 359-374.

20. Roza ALOC, Carlos R, van Heerden WFP, et al. An international collaborative study of 105 new cases of adenomatoid odontogenic tumors. *Oral Surg Oral Med Oral Pathol Oral Radiol*. 2020 Jun 9. <https://doi.org/10.1016/j.oooo.2020.06.001>. S2212-4403(20)31033-6. Epub ahead of print.
21. Kaffe I, Buchner A. Radiologic features of central odontogenic fibroma. *Oral Surg Oral Med Oral Pathol*. 1994; 78:811-818.
22. Hara M, Matsuzaki H, Katase N, et al. Central odontogenic fibroma of the jawbone: 2 case reports describing its imaging features and an analysis of its DCE-MRI findings. *Oral Surg Oral Med Oral Pathol Oral Radiol*. 2012; 113: e51-e58.
23. Wright JM, Devilliers P, Hille J. Squamous odontogenic tumor. In: El-Naggar AK, Chan JKC, Grandis JR, Takata T, Slootweg PJ, eds. *WHO Classification of Head and Neck Tumors*, 4th ed., Lyon, France: IARC; 2017:219-220.
24. Slootweg PJ, M€uller H. Central fibroma of the jaw, odontogenic or desmoplastic. *Oral Surg Oral Med Oral Pathol*. 1983; 56: 61-70.
25. Gardner DG. The central odontogenic fibroma: an attempt at clarification. *Oral Surg Oral Med Oral Pathol*. 1980; 50: 425-432.
26. Ide F, Matsumoto N, Miyazaki Y, Kikuchi K, Kusama K. What is the non-calcifying Langerhans cell-rich variant of calcifying epithelial odontogenic tumor? *Head Neck Pathol*. 2019; 13: 489-491.
27. Wangerin K, Harms D. Seltene Variationen des ameloblastischen Fibroms. *Dtsch Z Mund Kiefer GesichtsChir*. 1985; 9: 227-231.
28. Yih WY, Thompson C, Meshul CK, Bartley MH. Central odontogenic granular cell tumor of the jaw: report of case and immunohistochemical and electron microscopic study. *J Oral Maxillofac Surg*. 1995; 53: 453-459.
29. Mesquita AT, Santos CR, Gomez RS, Jorge J, Le\_on JE, de Almeida OP. Central granular cell odontogenic tumor: a histopathologic and immunohistochemical study. *Ann Diagn Pathol*. 2009; 13: 405-412.
30. Odell EW, Koutlas I. Sclerosing odontogenic carcinoma. In: El-Naggar AK, Chan JKC, Grandis JR, Takata T, Slootweg PJ, eds. *WHO Classification of Head and Neck Tumors*, 4th ed., Lyon, France: IARC; 2017: 209-210.
31. Koutlas IG, Allen CM, Warnock GR, Manivel JC. Sclerosing odontogenic carcinoma: a previously unreported variant of a locally aggressive odontogenic neoplasm without apparent metastatic potential. *Am J Surg Pathol*. 2008; 32: 1613-1619.
32. Todorovic E, Berthelet E, O'Connor R, et al. Sclerosing odontogenic carcinoma with local recurrence: case report and review of literature. *Head Neck Pathol*. 2019; 13: 371-377.
33. G€unhan O, G€urb€uzer B, Gardner DG, Demiriz M, Finci R. A central odontogenic fibroma exhibiting pleomorphic fibroblasts and numerous calcifications. *Br J Oral Maxillofac Surg*. 1991; 29: 42-43.
34. Dunlap CL. Odontogenic fibroma. *Semin Diagn Pathol*. 1999; 16: 293-296.
35. Ide F, Sakashita H, Kusama K. Ameloblastomatoid, central odontogenic fibroma: an epithelium-rich variant. *J Oral Pathol Med*. 2002; 31: 612-614.
36. Deckers J, Hammad H, Hoste E. Langerhans cells: sensing the environment in health and disease. *Front Immunol*. 2018; 1: 9. 93.