

Urginea macrocentra (Baker): Its Toxic Effects on Ruminants.

D. T. MITCHELL, M.R.C.V.S., Sub-Director of Veterinary Research,
Allerton, Natal.

IN South Africa three species of liliaceous plants occur to which the common name of Slangkop (snake head) has been given, all of which have been blamed for many years as a cause of mortality in stock. They are—

- Urginea burkei* (Baker)—Transvaal Slangkop;
- Urginea macrocentra* (Baker)—Natal Slangkop;
- Ornithoglossum glaucum* (Salisb.)—Cape Slangkop.

Urginea burkei occurs throughout the greater part of the middle and south-western Transvaal, the north-eastern Free State, and in the northern Cape Province (Kuruman and Bechuanaland).

Ornithoglossum glaucum is distributed over the greater part of the Cape Province, being plentiful in the Karoo and Kalahari regions.

Urginea macrocentra occurs along the coast-belt of Natal, extending as far south as the Transkeian Territories (Cape). It is also found in the Natal midlands up to altitudes of 3,000 feet. Specimens have been identified from the following areas:—

Inanda, Qudeni, Karkloof, Claridge, Umvoti District, Ifafa (South Coast).

GENERAL PROPERTIES.

Urgineas are very closely related to the Scillas, and many of them contain a very active toxic glucoside. The commercial "Squills" is derived from *Urginea maritima*, and has been recognized from earliest times as a valuable therapeutic agent. It was one of the objects of worship by the ancient Egyptians. Epimenides, who lived in the thirtieth Olympiad, is said to have made much use of it. Thophrastus recognized its virtues. Hippocrates used it externally, internally, and as a pessary. Pythagoras wrote a volume on the plant, and Dioscarides was the first to prepare and use the now well-known pharmacopœia preparation *Acetum scillae*.

The glucoside present in many of the Urgineas is Scillitoxin or Scillain, a substance possessing many of the therapeutic and toxic properties of the Digitalis group.

Squills in medicinal doses slows the action of the heart, raises the blood pressure, and arrests the heart in diastole. It stimulates bronchial secretion and acts on the kidneys, causing increase in the quantity of urine excreted. In its diuretic action it resembles Digitalis.

Urginea macrocentra is known to the Zulus under the name "U-Jobo," and the bulb is highly esteemed as an anthelmintic agent.

DESCRIPTION OF "URGINEA MACROCENTRA."

Urginea macrocentra is described in Medley Wood's "Natal Plants" as follows:—

"A bulbous plant found in damp or marshy ground. Bulb ovoid, $\frac{3}{4}$ to $1\frac{1}{2}$ in. diameter, tunics white. Leaves appearing after the flowers, cylindrical, tapering to an acute point, usually a little shorter than the peduncles, dark green, glabrous, and shining. Peduncles cylindrical, tapering very gradually from base to apex, 3 to 4 feet long, dark green, glabrous and shining. Raceme 4 to 8 inches long, 1 inch diameter, laxly many flowered, pedicels ascending, $\frac{1}{2}$ to $\frac{3}{4}$ in. long. Bracts deciduous, lowest ones spurred, erect, oblong, acute, margins strongly infolded, about two lines long, spur linear acute, very strongly reflexed, reaching to $1\frac{1}{2}$ in. long; upper ones small, membranous, oblong, margins strongly infolded. Flowers fragrant, lilac or pinkish when dried. Perianth campanulate $\frac{1}{4}$ in. long, cucullate at apex, segments 6, free nearly to base, oblanceolate, inner lobes narrowest, all with a dark central band on the upper half, which is most conspicuous on the outer surface, the inner surface white or pinky-white. Stamens shorter than the perianth, erect, filaments flattened, white. Anthers oblong, small, dark coloured. Ovary ovoid, green, 3-celled. Capsule globose-triquetrous, loculicidally 3-valved."

Medley Wood describes a variety under the name *Urginea lilacina*, in which the flowers are a lilac colour, becoming pinkish when dried, and possessing no spurs. In a later publication this author considers that the two varieties are identical. The spurs are early deciduous, and this explains their absence in the *Urginea lilacina* type specimens.

HABIT OF GROWTH.

Urginea macrocentra occurs in localized patches associated with small vleis or swamps. While it seems to require a liberal supply of moisture for its growth, an excess of water prevents its development. The plants will not grow under natural conditions in dry, well-drained areas, and thus we find it distributed around the margins of water-logged swamps and in vleis in which it is just possible to walk with boots in the rainy season without getting one's feet wet. The bulb is comparatively shallow rooted and easily dug out. Frequently the bulbs are found in the elevated accumulations of soil made by the tufts of grass in the vlei. The bulbs vary in size from $\frac{3}{4}$ to 2 inches in diameter, and are of a round ovoid shape. The scales are white, fleshy, and brittle. Growth commences in the early spring before there is any sign of growth in the surrounding grasses or sedges, etc. The flowering head is first to appear, and at the height of 6 to 8 inches the flowers of the immature inflorescence are closely packed together at the tip, giving an appearance very much resembling the scales on the head of a snake. The colour is a light green tinged with purple, the purple colour deepening towards the base, where it is very distinct. At this stage it is a very conspicuous and attractive object for stock, contrasting vividly with the surrounding winter vegetation. The development of the flowering head depends on the climatic conditions. On the coast it grows to a height of 4 ft. 8 in., but in the

upland areas at altitudes of 2,000 to 3,000 feet it rarely reaches 2 ft. 6 in. As the flowering head approaches its full development, the single leaf is produced from the side of the same bulb. Only a small percentage of the bulbs in an area will be found in flower. The majority, especially the smaller bulbs, produce only a single cylindrical leaf.

Under cultivation the bulbs grow readily in well drained heavy soil, but here the development is later than under natural conditions. The flowering head is stunted and the leaves are long but very slender.

The flower seeds freely, and in the vleis at Ifafa (South Coast) there was evidence of a high germination percentage in the numbers of isolated bulbs of varying sizes from that of a bean upwards.

The occurrence of the plant on some of the vleis in this area and its absence in others where the conditions requisite for growth appeared to be fulfilled could not be explained, nor was there anything to indicate how spread of the plant might occur from vlei to vlei. It was, however, noted that vleis which contained a considerable quantity of bush were free from the plant, but open or sparsely bushed vleis contained large quantities of the bulbs. Where a vlei originated from a series of springs in the rising ground, the bulbs were rare or absent at the source, becoming increasingly numerous as the vlei widened out on the low-lying ground.

SEASON OF THE YEAR WHEN CASES OCCUR.

The occurrence of cases of poisoning by bulbous plants in general is during the early spring.

The reserve food and moisture in the bulbs assists in making these plants to a certain extent independent of the climatic conditions prevailing, and early in the season, or where rains are late and spring growth of fibrous rooted plants is retarded, the young flowering heads of *Urginea macrocentra* become very attractive to stock.

It is commonly supposed that the toxicity of the young shoot varies according to the rainfall and that in a very dry spring they attain their maximum toxicity. There is no experimental evidence in support of this, and while it may be correct, there is the greater likelihood of the shoots being eaten in a prolonged dry spell, and the results noted by the farmers may only be due to the variations in the amount ingested. From observations made on a number of areas where mortality was occurring, it would appear that the young shoots up to about six inches long constitute the greater danger, as they are most readily eaten. The longer shoots, whether leaf, stem, or flowering head, are seldom touched, although many may show old scars where the top has been browsed while the shoot was still young.

The bulbs do not appear to be eaten by cattle. In a few cases, where it was found that the bulbs which had been growing very superficially were pulled out, there was no evidence of an attempt to eat the bulb, although from its whitish colour and fleshy appearance one would have expected it to be readily eaten.

ANIMALS AFFECTED.

Under natural conditions mortality has only been reported in bovines.

Goats did not appear to eat *Urginea macrocentra* on the farms visited. This might be accounted for by their different grazing habits, as goats on these farms preferred the higher ground and bush areas to swampy ground for grazing purposes.

No cases have been reported naturally in sheep, but the numbers of sheep exposed to the plant on the farms visited were insufficient to form any definite conclusions. The same may be said in respect of horses and donkeys.

Animals reared on an area usually develop a tolerance to the local poisonous plants, or perhaps as a result of a previous experience poisonous plants are not eaten. This rule, however, has exceptions. In the case of hungry animals, such as oxen, when turned out after a day's work, there is increased liability to feed on plants which normally would not be touched. With *Urginea macrocentra* there appears to be no relation between the mortality and the previous residence or otherwise on the area. Introduced or local cattle appear to suffer in about equal numbers.

The mortality among adult breeding stock was greater in the outbreaks investigated than in younger stock, even when grazing in the same camp. As with many diseases, farmers report that it is usually the fattest cows or best milkers which are affected.

SYMPTOMS.

The symptoms shown under natural conditions of ingestion show a very great variation in severity. There is always an early depression indicated by dullness, loss of appetite, cessation of rumination, and little desire to move around. In the early stages there is usually considerable Tympanites which, if treated by puncture, recurs rapidly and persistently. There is constipation in the majority of cases, which responds fairly readily to the ordinary purgatives. In acute cases a persistent diarrhœa may be present, associated with evidence of abdominal pain, resulting in rapid loss of condition. The temperature is not elevated. Respirations are deepened, but not markedly increased. Thirst is present in the majority of cases. In the sub-acute cases, after the animal has been sick for some days, it may refuse to rise, or if compelled to get up soon goes down again. The head may be carried low or turned round to either chest wall. Respirations are slow and deep, the expiratory phase being marked by an audible grunt. Food is refused, but small quantities of water may be drunk at frequent intervals. Constipation is present, the rectum at this stage being usually full of dry balls of dung. There is rarely evidence of enteritis or colitis, the balls of dung being usually glossy on the surface.

In all cases, whether acute or sub-acute, there is a greater or less degree of polyurea present. This is perhaps more noticeable in oxen and bulls than in females. Unless the animal is in a stable, or the herd-boy particularly observant, this symptom is frequently missed.

Death is relatively slow, occurring from four to fourteen days after the first symptoms are observed. It is usually preceded by a long comatose period, during which the animal lies flat on the side or, if propped up, on the brisket, with the head resting on the chest wall. Grunting respirations, retracted eyeball, contracted pupils, and cold extremities are always present at this stage.

DIAGNOSIS.

In poisoning by *Urginea macrocentra* a diagnosis is comparatively easy to arrive at. The season of the year, the area where the mortality is occurring, the sub-acute symptoms indicating digestive

trouble, and the absence of a definite febrile reaction will indicate a possible plant poisoning, and the finding of the plant in the areas indicated with evidence of cropping of the young shoots confirms the diagnosis.

MORTALITY.

The mortality is not usually higher than 5 per cent. in the herd, even in very bad seasons, but double this number of cattle may show symptoms from which they recover under treatment.

The effects appear to persist for a considerable time, and cases which were responding to treatment may have a relapse after ten days and die a few days later. Great variations in occurrence and mortality occur from year to year, so it is almost impossible to give any definite figures.

The symptoms shown by the various animals under experimental conditions were more definite than those noted in the veld. This can be accounted for by the fact that the factors and conditions were known and the animals were under conditions where observation was comparatively easy. The dose given was either a single one or over a comparatively short period, whereas in the veld the daily quantity consumed may be small, and the effects produced may result from the effect of numerous small doses having an accumulative effect and slowing the onset of perceptible symptoms.

The clinical changes noted were as follows:—

Cattle.—The effects of the poison are rapidly produced. Symptoms can generally be noted after the second day.

Salivation appears as one of the first symptoms and persists throughout the period of illness; the faeces become soft, and in a day or two diarrhoea has set in, resulting in a flood of brownish yellow fluid faeces. Tympanites is present, and persists even after the diarrhoea is established. The respirations are either slow and deep or rapid and jerky with occasional very deep inspirations at intervals of about eight inspirations. The pulse is intermittent and the rate is increased. The extremities are cold and the visible mucous membranes are slightly injected. Lachrymation is a constant symptom, and may be profuse, a constant stream trickling down the face. The eyes are sunken, the pupils in some cases dilated.

Rumination is suspended early, and the animal refuses food and water and the head is carried high. There is an anxious look about the animal which the staring coat and paddling movement of the legs as the animal changes the body weight from foot to foot appear to make more noticeable. Abdominal pain is an early indication, and this is not relieved by treating for tympanites.

During the early stages and while symptoms of abdominal pain are present, the temperature may show considerable fluctuations, but there is no well-defined febrile reaction.

The animal may spend a considerable part of the time in the recumbent position, and it rises with difficulty, frequently toppling over in the attempt to do so. On standing there is lateral swaying of the quarters associated with continuous movement of the corresponding feet. If the animal rests against the stall it gains some assistance, and the movements are diminished and limited only to the feet. When walked, the animal progresses slowly and with difficulty. The forelegs are lifted higher than normal and put

down as though the animal was feeling its way. The back is arched, and there are continuous movements from side to side and plaiting movements of the legs, indicating lack of co-ordination. Occasional grunting is noticed.

If the patient survives from five to seven days the faeces become firmer and less in quantity, later being covered with mucous which may show blood staining or even blood clots. Acute tympany disappears, but there still remains some distension of the rumen. There is excessive micturition, urine being passed in large quantities at intervals. There is no evidence of irritation of the bladder or urinary passages. The urine is clear or slightly yellow.

Muscular tumours affecting the flank, elbow region, limb muscles, or muscles of the mouth are noted. Salivation is profuse, and there may be partial paralysis of the tongue, the tip of which protrudes from between the teeth. Intermittent grinding of the teeth is present. Food is refused, but water, in small quantities, may be partaken of frequently. There is evidence of nausea. The pulse is slow and full, with occasional faint impulses, not occurring at regular intervals.

Respiration is slow and laboured, the abdominal muscles taking an active part in the expiratory effort, which is accompanied by a regular "grunt." The animal lies persistently and rises only with difficulty.

Only a short period of coma, lasting for a few hours, precedes death.

In cases where a large quantity has been fed, the period during which clinical lesions are shown may be limited to a few hours. Salivation, lachrymation, increased respirations with grunting, paralysis of the tongue, and excitement due to the poisoning or to abdominal pain are the clinical manifestations which are present in an acute degree. Death occurs suddenly in a paroxysm.

In Goats.—The symptoms are similar to those present in cattle. The initial diarrhoea results in rapid loss of condition, and the patient looks miserable. The action on the kidneys does not appear to be marked in goats. The cases under experiment showed only slight increase in urine secretion.

In Sheep.—The plant produces symptoms of acute abdominal pain which the animal shows by stamping of the feet and pawing the ground. The head is held high. Respirations are very much increased. Diarrhoea is not a marked symptom, or was not noted in the experimental cases. The toxic effect on sheep is very rapid, and death may occur within twenty-four hours when sufficient quantity has been eaten.

EXPERIMENTAL WORK.

The first reference to experimental work on this plant is contained in Reprint No. 35 from the *Agricultural Journal of South Africa* of May, 1914. In this article the author, Dr. J. Medley Wood, Director of the Natal Herbarium, refers to a feeding test with 2½ lb. of bulb, supplied by Mr. Deane, of Seven Oaks, which was carried out at the Veterinary Research Laboratory, Pietermaritzburg.

Reference to records in this office shows that a test on one animal was carried out in 1913.

In this experiment reference is made to bulbs throughout, though why this particular part of the plant which is never eaten under natural conditions was utilized in the experimental work is difficult to understand.

It will be noted later that this same amount of bulb did not kill a beast when dosed experimentally, and it is therefore presumed that in this original experiment the whole plant was fed.

In the experiments carried out at Allerton Laboratory in 1923-1924 with this plant, it was found very difficult to force the experimental animals to eat the requisite dose even when they had been starved for twenty-four to forty-eight hours, and the plant was given chopped up and mixed with a feed which the animals usually relished.

It was realized that if accurate results were to be obtained some surer method of administration would have to be resorted to, and, after preliminary trials, two methods were adopted, viz., (a) drenching with a mince made of the plant by soaking in water and passing it through a mincing machine, and (b) drenching with an infusion. This was prepared by soaking the chopped-up plant, in water sufficient to cover, for twelve hours, and then expressing as much of the absorbed fluid as possible and administering this as a drench.

These methods of dosing have much to recommend them over the usual method of feeding the plant, as the dose is known and can be administered at once without wastage. There is the disadvantage that in animals which are difficult to drench the giving of large quantities of semi-fluid mince may cause choking in some cases, and the subsequent results are complicated by bronchitis or bronchopneumonia. It is necessary, therefore, if utilizing this method, to select fairly quiet animals and to have the drench administered with the greatest care.

It was not possible to weigh the animals previous to drenching, so average size beasts were selected of approximately the following weights:—

Cattle	500 lb.
Goats	120 lb.
Sheep	80 lb.

In the case of the cattle, these were constantly stabled during the experiments, and the sheep and goats were allowed to run in a small paddock within view of the laboratory, so that they could be under constant supervision.

The first material received from Qudeni, where a few deaths in cattle were occurring under circumstances which led the owner to suspect vegetable poisoning, was not recognized botanically on account of the changes which had occurred during delay in transit and the absence of flowering heads. As is usual under such circumstances, the sender was asked for sufficient material to do a feeding test and for complete specimens with flowers. Numerous inflorescences were forwarded at intervals, and these were submitted to Professor Bewes, Natal University College, who reported that none had a history of toxic properties. Tests with the plant demonstrated its poisonous nature, but it was not until the following flowering season (1924) that complete specimens were collected and identified.

EXPERIMENTAL FEEDING TESTS.

Cattle.

- C. 358.
 25.11.23. Drenched infusion of 3 lb. plant in quart of water.
 26.11.23. Fed 3 lb. plant, chopped.
 27.11.23. Fed 4 lb. plant, chopped.
 28.11.23. Drenched infusion of 2 lb. plant.
 29.11.23. Respirations slightly increased; slight lachrymation.
 5.12.23. Fed 2 lb. plant.
 6.12.23. Drenched infusion of 2 lb. plant.
 7.12.23. Drenched infusion of 2 lb. plant.
 8.12.23. Drenched infusion of 2 lb. plant.
 9.12.23. Drenched infusion of 2 lb. plant.
 10.12.23. Faeces normal; respirations slightly increased; feeding.
 11.12.23. Dead.

Remarks.

In this test 9 lb. of chopped-up plant were fed and infusion from 13 lb. drenched before death occurred.

It is pointed out, however, that in these earlier tests with material from Qudeni the bundles of plants took many days to arrive. There was no attempt made to dry the consignments before dispatch, and as it was during the hot, rainy season, the lots arrived in a sodden condition and full of mould. Fermentative changes had been actively proceeding, and it is possible that this may have had some effect in reducing the toxicity which could afterwards be demonstrated. In the feeding tests the fallacy of loss by wastage undoubtedly occurred.

The drenching experiments were kept up for four days before symptoms became apparent, and the subsequent rapid death indicated that the toxic dose had been greatly exceeded.

Cattle.

- C. 328.
 10.1.24. Fed 4 lb. plant. Consumed readily.
 11.1.24. Fed 4 lb. plant. Consumed readily.
 12.1.24. Fed 1 lb. plant. Consumed readily.
 13.1.24. Off feed; respirations slightly increased; lachrymation.
 4 p.m. lying on side; head resting on flanks; faeces normal.
 14.1.24. No symptoms apparent. Fed further 4 lb.; about 1 lb. only eaten.
 15.1.24. Fed 1 lb. fresh plant. Not eaten. Turned out to graze in paddock.

Remarks.

Thirteen pounds of plant were fed during a period of six days without producing any ill effect. This result is difficult to understand, as undoubtedly the earlier quantities of plant were eagerly consumed.

Cattle.

- C. 88.
 15.1.24. Fed 3 lb. plant. Readily consumed.
 16.1.24. Fed 6 lb. plant. Readily consumed.
 17.1.24. Fed 1½ lb. plant.
 21.1.24. Fed 4 lb. plant. 2 lb. only eaten.
 22.1.24. Fed 1 lb. plant. Consumed.
 23.1.24. Fed 1 lb. plant. Refused.
 Total consumed, 13½ lb.
 28.1.24. Drenched with juice from 7 lb. plant (1.5 litres), 2 p.m.
 29.1.24. 9 a.m. Tympanitic; staring coat; marked muscular tremors; marked symptoms commenced 9.10 a.m., the beast suddenly pulling back on rein; respirations short and rapid; grunting; grinding teeth; tip of tongue protruding from mouth; profuse salivation and froth; marked lachrymation. Much mucus passed from rectum. Beast suddenly collapses on to floor; weaving of head; throwing head on to abdomen; death taking place very suddenly, e.g. eleven minutes after commencement of symptoms.

Remarks.

The results of the preliminary feeding tests in this case were similar to C. 328. This animal was the first which was treated by drenching with infusion, and the result indicated that many times the toxic dose had been given.

The post-mortem findings were similar to those seen subsequently in experimental peracute cases. At this stage in the experimental work the tests were temporarily discontinued owing to the material arriving from this area (Qudeni) in a very fermented and decomposed state.

The following spring an assistant was sent for a supply of material for feeding tests with instructions to collect some flowering heads. About the same time an outbreak of cattle disease was reported from the South Coast, and an investigation of the area showed that an apparently similar plant was the cause of the trouble. Flowering heads from both areas were collected, and when compared were found to be identical except in one feature. In the plant from Qudeni the petals were white, while the specimens from the coast (Ifafa) showed lilac-coloured petals. Specimens from both areas were forwarded to the Division of Botany and reported on as *Urginea macrocentra* (Baker).

With the material from the coast, from which the supplies could readily be obtained, a series of tests were initiated in cattle, sheep, and goats.

Cattle.

- C. 388. Drenched, 2½ lb. minced stems.
- 28.10.24. R. (Respirations) 20. P. (Pulse rate) 66. Faeces normal.
- 29.10.24. R. 16. P. 68. 9 a.m. Faeces normal; pulse jerky; irregular; marked salivation.
12 noon. Temperature 104° F.; purging; lying down; occasional grunting; off feed.
- 30.10.24. R. 60. P. 50. 9 a.m. Faeces very liquid, dark greenish colour; extreme salivation; lachrymation; respirations laboured and grunting; slight inco-ordination; pulse slow and full; extremities cold; muzzle moist and cold; slight dilatation of pupil; refuses water and food.
12 noon. Continually on the move; paddling motion; refuses water; attempts to place head on side of body; hanging back on head chain.
4 p.m. Condition remains unchanged; again refuses water.
- 31.10.24. Dead.
- C. 90. Drenched 2½ lb. minced leaves.
- 28.10.24. R. 16. Faeces normal.
- 29.10.24. R. 20. 9 a.m. Eyes slightly sunken; faeces normal; slight salivation.
12 noon. Faeces softer than normal.
- 30.10.24. R. 20, deep. 9 a.m. Faeces very liquid; marked salivation; occasional deep respirations; refuses water; off feed.
12 noon. Large quantity very fluid faeces passed; off feed; refuses water.
- 31.10.24. R. 26. 9 a.m. Excessive purging; faeces yellow-brown colour; no food taken over night; water taken; eyes sunken; also flanks.
- 1.11.24. R. 20. 9 a.m. Eyes sunken; losing condition; refusing all feed and water; faeces not so liquid.
- 2.11.24. R. 28. 9 a.m. Faeces less liquid; excessive micturation; no food or water taken; lying down greater part of the day.
- 3.11.24. R. 22. 9 a.m. No change; faeces improving in consistency; less urine passed.
- 4.11.24. R. 24. 9 a.m. Tympanites marked; no food or water taken; no faeces or urine passed last 24 hours; marked lachrymation; incessant grunting; eyes much sunken.

- 5.11.24. R. 16. 9 a.m. Eyes, m.m. injected; no tympanites; eyes not sunken; no food or water taken; very small amount soft faeces covered with bloody mucus; grunting; marked salivation; flanks sunken; no urine passed.
- 6.11.24. R. 18. 9 a.m. Eyes, m.m. injected; small quantity of water taken; no food; no faeces or urine passed; straining; muscular tremors fore limbs; vibration of right leg; general appearance very dull.
- 7.11.24. R. 18. 9 a.m. Normal quantity of urine; no food; small quantity of hard faeces passed, mixed with blood-stained mucus; water taken.
- 8.11.24. R. 16. 9 a.m. Marked loss of condition; muscular tremors pronounced, especially lips and muzzle; profuse diarrhoea; no blood or mucus; grinding teeth; no food; arched back; water taken in sips; general appearance dull.
- 9.11.24. 9 a.m. Condition same as previous day.
- 10.11.24. R. 18. 9 a.m. Profuse diarrhoea mixed with blood and mucus; profuse micturation; marked loss of condition; off feed; water taken; faeces dark greenish-brown colour; grinding teeth; muscular tremors pronounced; lying down a great deal during day.
- 11.11.24. R. 16. 9 a.m. Small quantity of food taken; eyes bright; general appearance shows some slight improvement.
- 12.11.24. Faeces slightly firmer; feeding slightly; profuse micturation. Beast on being led out of the stable shows lateral swaying and plaiting of fore limbs in order to secure balance.
Destroyed for post-mortem 9.20 a.m.
- C. 381. Drenched, 2½ lb. minced bulb.
- 28.10.24. R. 16. P. 46. Faeces normal.
- 29.10.24. R. 32. P. 66. Faeces normal; slight salivation.
- 30.10.24. R. 34. P. 64. Faeces slightly softer than normal; slight dilatation of pupil.
- 31.10.24. R. 22. P. 48. Faeces normal; no change.
- 1.11.24. R. 26. P. 52. Faeces normal; no change.
- 2.11.24. R. 22. P. 48. Faeces normal; no change.
- 3-7.11.24. No change; *animal discharged.*

REMARKS ON TESTS.

Cattle.—The weight of plant used in these tests was limited to the amount which it was considered an animal might pick up under natural conditions, i.e. 2½ lb., and the tests were arranged with the object of indicating any variation in toxicity in the different parts of the plant.

It will be noted that the most acute results followed dosing minced stems, rather less acute results from minced leaves, and only slight effects were produced as a result of drenching with minced bulbs.

This would appear to correspond with the experience in the veld, where ingestion of the flowering heads in the early stages of growth of the plant produces the heaviest mortality. The leaf is produced at a later period than the flowering head, and though there is the possibility that there is then not the same liability on the part of the animal to feed on it on account of the commencing growth of other vegetation, leaves are undoubtedly eaten without being associated with such a heavy mortality.

In comparing the results of these tests in cattle with those of the previous season on material from Qudeni, it will be noted that either the toxicity of the plants collected from these two areas showed remarkable variation or, what is considered more likely, that the fermentative and decomposition changes occurring in transit from Qudeni affected the potency of the toxic glucoside.

Goats.

G. 1. Drenched, 5 oz. leaf infusion.

- 31.10.24. Drenched 12.45 p.m.
3.30 p.m. R. 28. No change.
1.11.24. R. 20. No change.
2.11.24. R. 20. No change.
3-5.11.24. No change.

Discharged—Negative.

G. 4524.

- 31.10.24. 12.45 p. . Drenched, 15 oz. leaf infusion.
3 p.m. R. 34. No change.
1.11.24. R. 24. No change.
2.11.24. R. 22. No change.
3.11.24. R. 28. Purging; grinding teeth; tremors hind quarters; stretching and forcing nose in upwards direction.
4.11.24. R. 38. Diarrhœa; muscular tremors over whole of body; stretching; head turned upwards; acute tympanites; salivation and nasal discharge; lying down most part of day.
5.11.24. R. 38. Symptoms unchanged; small quantity of blood-stained mucus in faeces.
6.11.24. R. 40. No faeces passed; off feed and water; lying down continuously; grinding teeth; continuous vibration of head; when roused, rises with difficulty; breathing deep; at each breath abdomen deeply contracts; mouth held open; tongue protruding (paralysis of tongue?); severe abdominal pain; profuse salivation; eyes much sunken.
7.11.24. R. 36. Faeces soft; some blood-stained mucus; tympanites dispersing; acute abdominal pain; no food or water taken.
8.11.24. R. 30. Faeces soft; some blood-stained mucus; grinding teeth continuously; slight tympanites; respirations deep and laboured; animal shows slight improvement generally.
10.11.24. R. 26. No faeces or urine passed; eyes, m.m. pale.
11.11.24. R. 24. Respirations deep and lifting; marked loss of condition; profuse salivation; straining; no faeces passed; normal amount urine passed; weak; staggering.
12.11.24. No faeces passed; no food taken.
9.20 a.m. *Destroyed for post-mortem.*

G. 3.

- 31.10.24. 12.55 p.m. Drenched, 3 oz. stem infusion.
3 p.m. R. 30. No symptoms apparent.
1.11.24. R. 64. Respirations increased; otherwise no change.
2.11.24. R. 24. No change.
3-4.11.24. R. 28. No change.
5.11.24. R. 40. Increased respirations; otherwise no change.
6.11.24. R. 32. No change.
7.11.24. R. 30. No change.
8.11.24. R. 26. No change.
9-11.11.24. No change.
Discharged.

G. 4.

- 31.10.24. 12.55 p.m. Drenched, 9 oz. stem infusion.
3 p.m. R. 32. No symptoms apparent.
1.11.24. R. 30, deep. Purging; visibly sick; off feed.
2.11.24. R. 20, deep. Purging; off feed; top lip twitching and turned up from teeth; losing condition; lying down frequently. Dead 2.30 p.m.

REMARKS ON TESTS.

Goats.—In these animals the results compared favourably with those noted in cattle.

Owing to the difficulty of drenching these animals and to the possible complications which might result from accidents, a strained infusion of the plant was utilized for drenching.

As with cattle the stem of the flowering head appeared to be more toxic than the leaf.

The results of this test on goats are very interesting, as it is commonly considered that goats are resistant to many plant poisons. It is evident that their immunity to poisoning with *Slangkop* is only the result of instinct, experience, or of grazing habits.

The intestinal symptoms produced were of a more violent character than in the case of cattle. Acute diarrhoea was an early symptom, and was rapidly followed by an acute dysenteric enteritis in the case which persisted for some time before terminating fatally.

Sheep.

S. 1635.

31.10.24. 12.45 p.m. Drenched with 5 oz. leaf infusion.
3 p.m. R. 26.
4 p.m. Stamping and pawing at ground continuously; occasionally walking backwards; coughing frequently; head held forward, with nose in the air; lying down frequently; evidence of much abdominal pain.
1.11.24. Dead.

S. 16323.

31.10.24. 12.45 p.m. Drenched, 15 oz. leaf infusion.
3 p.m. R. 58. Respirations increased; otherwise no change.
4.30 p.m. Stamping occasionally.
1.11.24. Dead.

S. 3.

31.10.24. 12.55 p.m. Drenched, 3 oz. stem infusion.
3 p.m. R. 80. Shallow and jerky.
1.11.24. R. 64. Shallow; feeding; no diarrhoea.
2.11.24. R. 54. Shallow; no diarrhoea; faeces normal.
3.11.24. R. 40. Grunting continuously; feeding; faeces normal.
4.11.24. R. 28. Grunting ceased; feeding; faeces normal.
5.11.24. R. 80. Respirations increased; otherwise no change; feeding.
6.11.24. R. 36. No change.
Discharged.

S. 16351.

31.10.24. 12.55 p.m. Drenched, 9 oz. stem infusion.
3 p.m. R. 160. Rapid; much salivation; faeces normal.
1.11.24. R. 128. High temperature; respiration rapid; salivating; no diarrhoea.
2.11.24. Dead.

REMARKS ON TESTS.

Sheep.—The plant appears to be slightly more toxic to sheep than goats. All the experimental animals died except one, which received a relatively small dose of stem infusion, and this animal showed a marked clinical reaction. In most cases the deaths were so rapid that little clinical evidence could be recorded, but it was apparent that there was more nervous disturbance than was noted with cattle or goats, greater abdominal pains, and no evidence of purgation.

The difference in toxicity of flowering stem and leaf noted in the case of cattle and goats was also evident in sheep.

In sheep and goats which were kept in a camp and not in the stable while undergoing test, it was not possible to ascertain whether diuresis was present or not. The animals did not micturate more frequently than normal, but the quantity may have been increased.

TOXIC DOSES FOR THE VARIOUS ANIMALS.

It is only possible from these results to give a weight which could be regarded as the approximate minimum lethal dose, and in view of the variation in results in material from different sources there may be the added factor of variation in toxicity in the various districts or under varying climatic conditions.

Of the coastal variety it is assumed that the following quantities would kill:—

Cattle (about 500 lb.)... $1\frac{1}{2}$ lb. flower stems; $2\frac{1}{2}$ lb. leaves.
 Goats (about 120 lb) ... 5 ozs. flower stems; 10 ozs. leaves.
 Sheep (about 80 lb) ... 3 ozs. flower stems; 4 ozs. leaves.

LESIONS PRESENT ON POST-MORTEM.

The extent and intensity of the pathological lesions which are present on post-mortem depend to a considerable extent on the duration of the sickness which has been produced. In peracute cases the changes in such organs as the lungs, mucosa of the bronchi, trachea, linings of the heart are very marked. Lesions in the intestines and kidneys are present. These are the tissues on which the primary action of the poison is manifested. In sub-acute cases where there has been an opportunity for prolonged action of the poison on the tissues the lesions in general are of an inflammatory nature and are more deeply seated.

In the annexures, post-mortem reports of the various animals used in the experiments are given, and in the case of cattle and goats a post-mortem report of a per-acute and a sub-acute case of each is given. The macroscopic lesions produced may be briefly summarized as follows:—

RESPIRATORY SYSTEM.

The initial lesions are a diffuse pulmonary congestion and slight oedema, which to a great extent clear up later. There is no pulmonary consolidation even in old standing cases. The presence of air bullae and patches of emphysema throughout the lung tissue indicate destruction of pulmonary tissues which have occurred as a sequel to the congestive changes. This is most marked in the anterior lobes, but is also present in isolated patches in the interlobular spaces throughout the greater part of the lungs.

The mucosa of the bronchi and trachea shows intense congestive changes which persist for a considerable time. The mucosa, lining the whole respiratory tract, shows an early intense hypermaeia with a resulting thickening of the mucosa and profuse outpouring of secretion, which may be bloodstained or contain so much blood that it coagulates, forming a dark red clot. The mucosa lining the pharynx and larynx is congested and in some cases cyanosed. Congestion of the lymphoid tissue in this region is present. The bronchial and mediastinal glands are enlarged, and in most cases intensely congested.

CIRCULATORY SYSTEM.

Marked increase of fluid in the pericardial sac is present. In some cases the quantity is so great as to cause distention of the sac, and the fluid contained may be bloodstained. The epicardium shows numerous and extensive sub-endothelial haemorrhages. The two ventricles show petechiae and extravasations, a few being usually

found in the right ventricle, but in the left ventricle the lesions are well marked and diffuse, occurring under the endothelium covering the wall septum and papillary muscles. The myocardium is softer than normal; the muscle fibres are somewhat paler in colour, and may show muscular haemorrhages on section.

Spleen.—Congestion of this organ may be present, but this indication is not constant.

DIGESTIVE GLANDS.

Liver.—The lesions presented by this organ show marked variation. Congestion appears to be a common condition in peracute cases, but the organ may be shrunken and bloodless. Lobulation is not distinct, and the surface of section gives a mottled appearance. On manipulation the perenchyma feels rubbery or tough. Even in acute cases the gall bladder is distended with bile, which shows little departure from the normal.

DIGESTIVE TRACT.

Stomachs.—There is usually congestion or subcuticular haemorrhages in patches in the omasum. The abomasum shows marked hyperaemia of varying degree and thickening of the folds of the mucous membrane.

Duodenum.—Thickening of the mucosa and hyperaemia are the most constant lesions in this organ. These vary in degree in individual cases, but are always present and well defined.

Jejunum and Ileum.—The lesions present in this portion of the digestive tract are similar to those found in the duodenum. The patches of hyperaemia of the mucosa are irregular in their occurrence. In some cases the upper portion of the jejunum shows definite lesions, but more frequently the acute lesions are found in the final portion of the ileum, i.e. the last two or three feet. Occasionally the fluid contents of the intestines are deeply bloodstained or chocolate brown in colour, and the general appearance is then rather suggestive of arsenical poisoning.

Large Intestines.—The contents are usually fluid throughout the caecum and double colon. Acute patchy hyperaemia of the mucosa of these organs is usually present in a greater or lesser degree. The contents of the floating colon become pasty in consistence. In the rectum longitudinal hyperaemic lines are sometimes noticed in the mucosa. The thickening of the mucous membrane of the large intestines was not so marked as was noted in the case of the small intestines.

EXCRETORY ORGANS.

Kidneys.—There is acute congestion of the kidneys in the peracute cases, and if the animal lives long enough this is followed by a commencing acute nephritis. In the congestive stage the structure of intermediary zone and cortex is obscured by the intense hyperaemia, and later the organ becomes softer to the touch and a section of it does not break on bending. The vessels of the cortex are sharply indicated as bright red radiating lines in a pale greyish background of altered cortical tissue. The capsule strips easily. The bladder seldom shows changes, but hyperaemic patches in the mucosa have been noted.

TREATMENT AND PREVENTION.

Various remedies have been suggested for the treatment of cases of poisoning by *Urginea*, but the results seem to depend more upon the quantity of the plant which has been eaten than on the remedial agent used. Epsom salts and similar purgatives seem to aggravate the symptoms, and do not produce a good effect. Better results are obtained by oleaginous purgatives such as raw linseed oil, castor oil, and demulcants such as white of egg, well boiled flour gruel, etc. In cases of acute tympany puncture of the rumen affords a quick relief, but owing to continuous gas formation in the rumen, the result is only temporary, and should be supplemented by the administration of antiseptics such as carbolic acid well diluted and given as a drench.

PREVENTIVE TREATMENT.

Once the area in which the plant occurs on the farm has been located, prevention should be a simple matter, and depends entirely upon measures directed against allowing the animals access to the place. This may be done by any of the following methods:—

1. Grazing the animals during the dangerous season of the year in a part of the farm where the plant does not occur.

2. If the area in which the plant occurs is limited it may be fenced off.

3. The bulbs are shallow rooted and can easily be dug up. This is best done during the spring when the plant is in full growth, as at other seasons of the year the bulbs are difficult to locate. The plant appears to seed easily, and a high percentage of germination may occur during favourable seasons, so the eradication must be persisted in over several seasons before one can be certain that all the plants and seed have been dealt with.

REFERENCES.

- (1) "Poisonous Plants of South Africa," Stent and Curson, 1922.
- (2) "Natal Plants," Vol. II, J. Medley Wood, 1902.
- (3) "Pharmacology and Therapeutics," Cushny, 1918.
- (4) "Pharmacology and Therapeutics," Murrell, 1896.
- (5) "Note on Natal Slangkop, or Poison Bulb," *Agricultural Journal of South Africa*, J. Medley Wood, 1914.
- (6) Transvaal Department of Agriculture Annual Report, 1903-4, Burt-Davy, p. 302, *et seq.*

PLATES.

- (1) Photograph of *Urginea macrocentra*, showing various stages of growth, leaves, and flowering heads.
- (2) Sketch of plant, showing detailed structure.

EXPERIMENT No. 27.

Period of Illness: Fifteen days.

P.M. No. 320.
D.O.B. No. 90.

Date of Death: 12.11.24. Species: Bovine.
Sex: Male. Age: Aged. Colour: Red and white

Condition	Fair.
Abdomen	Normal.
Interim	Killed for post-mortem.
Rigor mortis	Not present.

Natural openings and visible mucous membranes	Normal.
Blood, flesh, and subcutaneous tissue	Normal.
Salivary glands	Bronchial glands: Slight gelatinous infiltration, not markedly increased in size.
Lymphatic glands	Normal.
Tongue	Normal.
Oesophagus	Normal.
Peritoneal cavity	Fluid not increased.
Diaphragm	Normal.
Pleural cavities	No fluid increase.
Respiratory organs	Lungs: Not collapsed. Pleural surface of right lung very pale, blanched appearance. Left lung fleshy coloured; intra-lobular septa of both lungs—particularly in anterior and cardiac lobes—very pronounced, and show air bullae. The whole lung appears distended with air. No appreciable collapse on section. On section lung tissue normal in appearance. Interlobular space throughout very pronounced, the lobules sliding apart very freely. Smaller bronchi on section show food contents and ingesta. No surrounding hyperaemia apparent.
	Dorsal trachea: Food contents which form a plug behind the bifurcation of the trachea, mucosa of trachea, and bronchi show some scattered patches of hyperaemia, not pronounced.
	Larynx: Impacted with a bolus of food; no hyperaemia; some food contents in the cervical portion of the trachea; lymph follicles show very slight hyperaemia, but considerable enlargement.
Pericard	220 c.c. Straw-coloured fluid with plasma coagulum.
Circulatory organs	Heart: Epicard normal. Right ventricle some blood coagulum. Endocardium shows remains of old extravasations now becoming organized whitish-yellow in colour.
	Left ventricle empty; numerous recent extravasations on the septum under the coronary muscles involving about one-third of the total area of the endocardium.
Periportal glands	Normal.
Liver	Capsule tense; organ firm and rubbery to the touch. Numerous greyish patches under the capsule; irregular in shape on the anterior surface of the right lobe. The whole anterior surface has a greyish mottled appearance, due to diffuse thickening of the capsule. On section the organ shows venous stasis, lobulation very indistinct; dark brownish-red in appearance, becoming yellowish towards the upper border of the anterior surface under the capsule. The consistency is firm.
	Gall bladder: Distended to about eight times its normal size, with a golden yellow semi-fluid bile containing numerous yellow flocculi, the bile having a consistence of a badly set jelly.
Pancreas	Normal.
Splenic glands	Normal.

Kidneys	Well surrounded by kidney fat. Both organs very dark in colour. On section dense to profuse hyperaemia of the organ is seen. Vessels of the cortex very prominent, with greyish lines in between. The intermediary zone shows intense hyperaemia, which becomes less marked towards the medulla, but is still present in this portion of the organ to a well-marked degree. Capsule strips easily; organ firm on manipulation, and breaks with a rough granulated fracture.
Spleen	Normal.
Stomach	Abomasum: Folds not markedly increased in thickness; slight diffuse hyperaemia. Omasum: Normal. Reticulum: Normal.
Small intestines	Duodenum: Mucosa very much wrinkled and thickened; contents fluid; mucosa shows slight diffuse hyperaemia. In the upper portion the contents are catarrhal and tenacious; the mucosa slightly thickened, corrugated. In the middle portion contents gelatinous in appearance; yellowish mucoid. Mucosa corrugated; marked diffuse hyperaemia. Ileum: Jelly-like mucoid contents with some food material apparent; greenish and tenacious. Slight diffuse hyperaemia with localized patches of acute hyperaemia. Mucosa thickened. Hyperaemia in zebra markings. In the lower portion contents mucoid; tenacious; mucosa thickened; hyperaemia in longitudinal lines and streaks.
Large intestines	Caecum: Acute diffuse hyperaemia; mucosa slightly thickened. Cecum: Mucosa thickened; corrugated; patches of acute hyperaemia. Floating colon: Mucosa thickened in longitudinal lines; well marked diffuse; irregular patches of hyperaemia; surface covered with a tenacious material resembling white of egg. Rectum: Mucosa thickened in longitudinal lines which show well-marked hyperaemia.
Nervous system	Normal.
Bladder	Normal.
Sexual organs	Normal.
Pathological anatomical diagnosis				Pulmonary emphysema. Endocarditis. Venous and bile stasis liver. Nephritis. Enteritis. Colitis.
Etiological diagnosis	<i>Urginea macrocentra</i> poisoning.

EXPERIMENT No. 27.

Ex Mills, Ifafa.

Period of Illness: Three days.

P.M. No. 313.
DOB No. 388.

Date of Death: 31.10.24. Species: Bovine.
Sex: Female. Age: 3 years. Colour: Black.

Condition	Good. Tympanites.
Abdomen	Normal.
Interim	Six hours.
Rigor mortis	Present.

Integument	Eyeballs sunken; mucoid nasal discharge.
Natural openings and visible mucous membranes	Normal.
Blood, flesh, and subcutaneous tissue	Muscle rather pale. The organs of the animal are still warm. The muscular tissue on skinning is rather pale, and on section shows a number of small haemorrhagic areas disseminated throughout the muscular tissue, not sharply circumscribed, and may be caused by muscular haemorrhages during struggling before death. The muscular tissue darkens very rapidly on exposure to air.
Salivary glands	Normal.
Lymphatic glands	Pharyngeal twice normal size, and resemble haemo-lymph glands on section; blood flows freely from surface of section.
Tongue	On section of muscles forming base of tongue numerous muscular haemorrhages are observed.
Oesophagus	Larynx and pharynx deep slaty-blue in colour. The pillars of the fauces intensely haemorrhagic; lymph. follicles in this position show acute hyperaemia on section. Very much enlarged, and surrounded by an area of acute hyperaemia.
Peritoneal cavity	Fluid not increased.
Cervical trachea	Some foam; mucous membranes deeply ingested.
Pleural cavities	Normal.
Respiratory organs	Lungs not collapsed; both show congestion; interlobular septa very distinct and show numerous gas bubbles, especially marked in the anterior lobe. On section, lobules vary in colour from a light cherry-red to a light brick-red to a dark purple, giving surface of section a marbled appearance. Right lung: Pleura, which is in contact with the costal pleura, shows numerous irregular fibrous thickenings; no adhesions. Trachea: Mucosa deeply injected; dark purple-brown in colour; contains blood-clots, which extend from the trachea into the bronchi. Surrounding this and half filling the lumen of the trachea is a frothy bloodstained fluid. Mucous membrane of the bronchi show on washing with water numerous large irregular sub-mucous haemorrhages with a more or less normal mucosa between these, giving the mucosa a well-marked mottled appearance. The blood-clot in the bronchi practically fills the lumen of the tubes, is dark red in colour throughout, and shows no indication of coagulated plasma.
Pericard	The bronchial glands are slightly enlarged and deep red on section, resembling a haemo-lymph gland. Mediastinal lymphatic glands: Ditto.

Circulatory organs	The outer surface of the pericard shows well marked infiltration by fat. Pericard fluid about 40 c.c. Dark; bloodstained. Epicard shows numerous minute petechiae and ecchymosis distributed for the most part over the covering of the right ventricle. The pericard over whole surface of the heart, and particularly marked over the right oracle, is faintly blood-stained. Right ventricle contains a well-formed blood-clot, which fills the entire cavity and extends into the coronary artery and into the oracle. Endocard shows numerous extravasations, particularly marked on the wall and at the junction of the wall and septum, the whole surface being slightly bloodstained. Left ventricle: A well-formed blood-clot which partly fills the cavity. Endocard shows well-marked extravasations of large size over the wall of septum, but particularly marked on the capillary muscles. Myocard: Firm; on section shows a few diffuse muscular haemorrhages.
Periportal glands	Normal.
Liver	Pale in appearance before section; slaty-gray in colour; on section the organ is bloodless and has a boiled looking appearance. Lobulation indistinct. Venous stasis contains a small amount of semi-fluid blood. In consistence the parenchyma feels putty-like, and the cut surface retains impressions of the thumb. The organ feels tough on manipulation.
Pancreas	Gall bladder distended with dark yellowish-green semi-fluid bile.
Portal lymphatics	No change.
Splenic glands	Normal.
Spleen	Slightly larger than normal. On section the pulpa bulges slightly on the cut surface. Soft in consistence. Trabecula indistinct. Malph. bodies indistinct.
Supra renal glands	Normal.
Kidneys	Left kidney shows hypostatic congestion diffusely red on surface of section. Right kidney: Cortex very pale; structure indistinct and slight hyperaemia of hylum. Capsule easily stripped.
Stomach	Abomasum: Semi-fluid contents; mucosa shows slight injection of folds; folds slightly thickened; otherwise normal. Omasum: Mucous membranes covering the leaves strip readily; sub-mucous tissue of the leaf shows an acute hyperaemia at the point of attachment to the wall and tapering off rapidly towards the free border. The affected area not exceeding $1\frac{1}{2}$ inch. The veins, which ramify from the point of attachment towards the free border, are distinct all the way. Contents normal in consistency. Reticulum: Mucous membranes stripping rapidly; no pathological change. Rumen: Mucosa strips readily; sub-mucous tissue normal.

Small intestines	Duodenum: Mucosa slaty colour; slightly thickened; no hyperaemia.
	Jejunum: Contents fluid; brownish-yellow in colour; mucosa slaty-grey colour; slight thickening; no hyperaemia. The junction of the ileum with the jejunum contents yellowish-brown; mucoid tenacious; mucosa thickened, and here commences acute hyperaemia of the mucosa in lines which are for the greater part longitudinal. The upper part of the jejunum before opening appears to be internally injected; deep red in colour. The contents here are mucoid and bloodstained; chocolate-brown in colour. The lower portion of the ileum shows mucosa considerably thickened. Acute hyperaemia in longitudinal and transverse lines. Contents brownish-yellow. Bloodstained contents appear to cease about 10 feet above the ileo-caecal valve, and are replaced by contents which are a deep brownish-yellow.
Large intestines	Caecum shows greenish-brown liquid, but no trace of solids, feeling gummy in consistence. Mucosa stained a brownish tint with occasional streaks of hyperaemia. Similar condition throughout large intestines. Slight hyperaemia of longitudinal folds at the rectum; mucosa not altered in thickness.
Mesenteric glands	Normal.
Mesentery	Normal.
Bladder	Empty and contracted; mucosa shows areas of hyperaemia disseminated over the whole surface, but separated from each other by areas of mucosa of normal colour. Border of hyperaemia areas is not sharply defined.
Sexual organs	Normal.
Nervous system	Normal.
Skeleton	Normal.
Pathological anatomical diagnosis	Laryngitis. Sub-epicarditis. Pharyngitis. Endocarditis. Kidneys: Slight commencing nephritis. Spleen: Congestion. Lungs: Hyperaemia; haemorrhage into bronchi; acute enteritis. Liver: Congestion and degeneration. Lymphatic glands: Haemorrhage and hyperaemia. Muscular haemorrhages.
Etiological diagnosis (disease) ...	<i>Urginea macrocentra</i> poisoning.

EXPERIMENT No. 27.

Period of Illness: Twelve days.

P.M. No. 321.
DOB No. 4524.

Date of Death: 12.11.24. Species: Caprine.
Sex: Male Age: 4 years. Colour: White, red face
Case No. 2.

Condition	Good.
Abdomen	Normal.
Interim	Killed for post-mortem.
Rigor mortis	Not present.
Integument	Normal.

Natural openings and visible mucous membranes	Normal.
Blood, flesh, and subcutaneous tissue	Normal.
Salivary glands	Normal.
Lymphatic glands	Normal.
Tongue	Normal.
Oesophagus	Normal.
Peritoneal cavity	Normal.
Diaphragm	Normal.
Pleural cavities	Fluid not increased.
Respiratory organs	Lungs: Collapsed. Normal. Dorsal trachea: Vessels of mucosa injected. Bronchi: Vessels of mucosa injected. Cervical trachea: Vessels of mucosa slightly injected. Otherwise normal.
Pericard	Fluid not increased.
Circulatory organs	Epicard normal. Right ventricle: Well-formed blood coagula. Left ventricle: Ditto. Endocard: Normal.
Periportal glands	Normal.
Liver	Capsule normal. On section lobulation not distinct. No pathological changes seen. Gall bladder: Three times normal size; greenish semi-fluid bile.
Pancreas	Normal.
Splenic glands	Normal.
Spleen	Capsule tense. Pulpa soft and projects on section. Malp. bodies distinct. Trabeculae indistinct.
Supra renal glands	Normal.
Kidneys	Cortex rather pale. Intermediary zone acute hyperaemia extending into the medulla. Organ firm; rubbery-like to the touch; does not break on bending.
Stomach	Abomasum: Folds of mucosa very much thickened; dark purple-brown in colour; thickening particularly marked at free border. Whole organ dark purple-red in colour. Diffuse hyperaemia.
Small intestines	Duodenum: Mucosa slightly thickened; few hyperaemic patches; contents fluid; upper portion normal; lower portion walls of intestine very thin. No hyperaemia. Jejunum: Normal. Ileum: Slight diffuse hyperaemia of lower third.
Large intestines	Caecum: Fluid contents; mucosa stripping easily; vessels slightly injected; blue discoloration. Colon: Greenish fluid contents; mucosa normal. Rectum: Contents firm. Mucosa normal.
Mesenteric glands	Normal.
Mesentery	Normal.
Bladder	Normal.
Sexual organs	Normal.
Nervous system	Normal.
Skeleton	Normal.
Pathological anatomical diagnosis	Enlarged spleen. Very slight enteritis. Well-marked gastritis. Nephritis.
Etiological diagnosis (disease) ...	<i>Urginea macrocentra</i> poisoning.

EXPERIMENT No. 27.

Period of Illness: One day.

P.M. No. 318.
D.O.B. No. 4523.

Date of Death: 2.11.24. Species: Caprine.
Sex: Male. Age: Aged. Colour: Black.
Case No. 4.

Condition	Good.
Abdomen	Normal.
Interim	Three hours.
Rigor mortis	Present.
Integument	Normal.
Natural openings and visible mucous membranes				Small quantity greenish fluid ingest from nostrils.
Blood, flesh, and subcutaneous tissue				Normal.
Salivary glands	Normal.
Lymphatic glands	Normal.
Tongue	Normal.
Oesophagus	Normal.
Peritoneal cavity	Fluid not increased.
Diaphragm	Normal.
Pleural cavities	Fluid not increased.
Respiratory organs	Lungs not collapsed. Left lung slight hypostatic congestion; no signs of hepatization or collapse. Right lung anterior lobe marked emphysema; main lobe on section shows diffuse hyperaemia blood flows freely from surface of section. Dorsal trachea: Some bloodstained foam; mucosa slightly injected in transverse bands corresponding to the tracheal rings. Bronchi: Some bloodstained foam; a few blood-clots in the smaller bronchi. Cervical trachea: Slight diffuse hyperaemia particularly marked on the rays; vessels of the mucosa deeply injected.
Pericard	Fluid not increased.
Circulatory organs	Epicard: Numerous petechiae and extravasations diffuse. Right ventricle: Well-formed blood coagulum; endocard normal. Left ventricle: Well-formed blood coagulum extending into the orifice. Numerous well-formed extravasations on septum and capillary muscles. Myocard firm; dark in colour and in patches.
Periportal glands	Normal.
Liver	Capsule tense; borders sharp. On section lobulation not distinct. Parenchyma friable. Gall bladder distended with pale coloured bile.
Pancreas	Normal.
Splenic glands	Normal.
Spleen	Normal.
Supra renal glands	Normal.
Kidneys	Acute diffuse hyperaemia of both, with reddish lines in the cortex radiating from the capsule.

Stomach	Rumen: Contents semi-fluid; cuticle firmly adherent, but on being scraped off shows patches of acute hyperaemia of varying sizes in the underlying tissue. Reticulum: Few patches of hyperaemia under cuticle not sharply defined. Omasum: Cuticle strips readily from folds; the underlying tissue shows acute hyperaemia, very acute at point of attachment of the fold, and diminishing as one passes to the free border. Abomasum: Contents fluid; organ three-quarters full of greenish watery fluid; diffusely hyperaemic; mottled in appearance; density of hyperaemia varying from a light cherry to a purple-red colour; areas not sharply defined; folds of mucosa very much thickened, particularly towards free border, the condition being most apparent near the omasum above opening in the folds.
Small intestines	Duodenum: Contents very fluid; acute hyperaemia showing local variations in intensity; mucosa thickened. Jejunum: Contents milky in appearance; towards lower portion patches of acute hyperaemia involving six to eight inches of the intestines, distributed at intervals of a foot or so throughout its entire length; intervening portions show slight diffuse hyperaemia and thickening of the mucosa. Ileum: Similar conditions to the jejunum, hyperaemic areas becoming even more acute towards the ilio-caecal valve. Intervening portions show hyperaemia in transverse bands (zebra markings). Contents of bowel creamy white and watery in consistence.
Large intestines	Caecum: Contents, greenish-brown in colour, fluid; mucosa shows irregular patches of acute hyperaemia, particularly towards the blind extremity. Colon: Contents pasty; numerous adult oesophagostomes; few hyperaemic patches.
Mesenteric glands	Normal.
Mesentery	Normal.
Bladder	Normal.
Sexual organs	Normal.
Nervous system	Normal.
Skeleton	Normal.
Pathological anatomical diagnosis					Hyperaemia and emphysema of lungs. Hyperaemia kidneys. Tracheitis. Enteritis. Bronchitis. Helmanthiasis.
Etiological diagnosis (disease)	...				<i>Urginea macrocentra</i> poisoning.

EXPERIMENT No. 27.

Period of Illness: One day.

P.M. No. 317.

D.O.B. No. 570/16351.

Date of Death: 2.11.24. Species: Ovine.

Sex: Hamel. Age: Aged. Merino.

Case No. 4.

Condition	Good.
Abdomen	Normal.
Interim	Four hours.

Rigor mortis	Rigor present; commencing.
Integument	Normal.
Natural openings and visible mucous membranes	Some mucous discharge from nostrils.
Blood, flesh, and subcutaneous tissue	Sub. tissue pale, darkening rapidly on exposure.
Salivary glands	Normal.
Lymphatic glands	Bronchial glands: Intensely haemorrhagic. Mediast. glands: Slight hyperaemia; greyish miliary nodules in cortex.
Tongue	Normal.
Oesophagus	Mucosa bluish; cyanosed.
Peritoneal cavity	Fluid not increased.
Diaphragm	Normal.
Pleural cavities	Fluid not increased.
Respiratory organs	Lungs: Not collapsed; slight diffuse hyperaemia in both. No acute congestion and no consolidation. Anterior lobes not increased in size. On section, surface dry, but on squeezing some foam and bloodstained serum exudes. Dorsal trachea: Mucosa intensely injected; plum coloured, the colour deepest at the middle of the cartilag. rings. Sub-mucous haemorrhages numerous, but almost obscured by the deep coloration of the mucosa. On stripping the mucosa from the trachea these haemorrhages can be seen distinctly in the reverse. Some bloodstained foam in the trachea. Bronchi: Condition similar to trachea, but even more acute; a quantity of frothy bloodstained serum and blood present, which is partly coagulated. Cervical trachea: Similar in appearance to dorsal. Pharynx and larynx: Cyanosed; intense hyperaemia; bluish-purple in colour, most pronounced at entrance to glottis.
Pericard	Distended with bloodstained fluid; not coagulated.
Circulatory organs	Epicard: Few petechiae present, inhibition. Right ventricle: Well-formed blood coagulum. Endocard imbibition. Left ventricle: Well-formed blood coagulum; endocard slight diffuse imbibition and numerous extravasations on papillary muscles and septum.
Periportal glands	Slightly hyperaemic.
Liver	Shrunken and bloodless in appearance; putty-like and colourless in consistence; greyish mottled patches under capsule. On section bloodless; surface shows little appearance of structure; cut surface pits on pressure of thumb; organ has a rubbery feel on manipulation. Gall bladder distended with normal bile.
Pancreas	Normal.
Splenic glands	Normal.
Spleen	Enlarged; borders rounded; pulpe distends capsule; pultaceous on manipulation. On section pulpa projects from the cut surface. Jam-like in consistency. Malp. bodies distinct. Trabeculae indistinct.
Supra renal glands	Normal.
Kidneys	Slight diffuse hyperaemia. Cortex has a parboiled appearance, with a few dark red streaks radiating from the capsule. Organ firm in consistency. Capsule easily stripped.

Stomach	Rumen: Contents normal. Subcuticular tissue shows patchy hyperaemia. Cuticle comes away easily. Reticulum: Ditto. Omasum: Well-marked hyperaemic patches in subcutile tissue. Abomasum: Acute diffuse hyperaemia. Mucosa cherry red to bluish-red colour. All folds of mucosa very much thickened, in some $\frac{3}{4}$ in. in section, particularly towards the omasum. Abomasum orifice: Thickening due to coagulated lymph. Jelly-like on section.
Small intestines	Duodenum: Slight diffuse hyperaemia, with patches and longitudinal lines of acute hyperaemia. Condition becomes more pronounced to about middle of jejunum, where the mucosa becomes slaty-blue in colour and few hyperaemic patches and lines. Six to eight feet from ilio-caecal valve diffuse hyperaemia again appears, increasing to about two feet from ilio-caecal valve, where the mucosa again becomes slaty-blue.
Large intestines	Caecum: Patchy hyperaemia. Contents fluid. Large intestines: Contents fluid, becoming more concentrated towards the rectum, but still fluid; pasty. Rectum: Lines of acute hyperaemia in mucosa, increasing in intensity to the anus.
Mesenteric glands	Normal.
Mesentery	Normal.
Bladder	Normal.
Sexual organs	Normal.
Nervous system	Normal.
Skeleton	Normal.
Etiological diagnosis (disease)	<i>Urginea macrocentra</i> poisoning.
Pathological Diagnosis—					
Lymphatic glands	Hyperaemia.
Lungs	Hyperaemia.
Trachea	Submucous haemorrhages.
Circulation	Subendothelial extravasations.
Liver	Degeneration.
Spleen	Congestion.
Kidneys	Nephritis.
Intestines...	Congestion of mucosa.


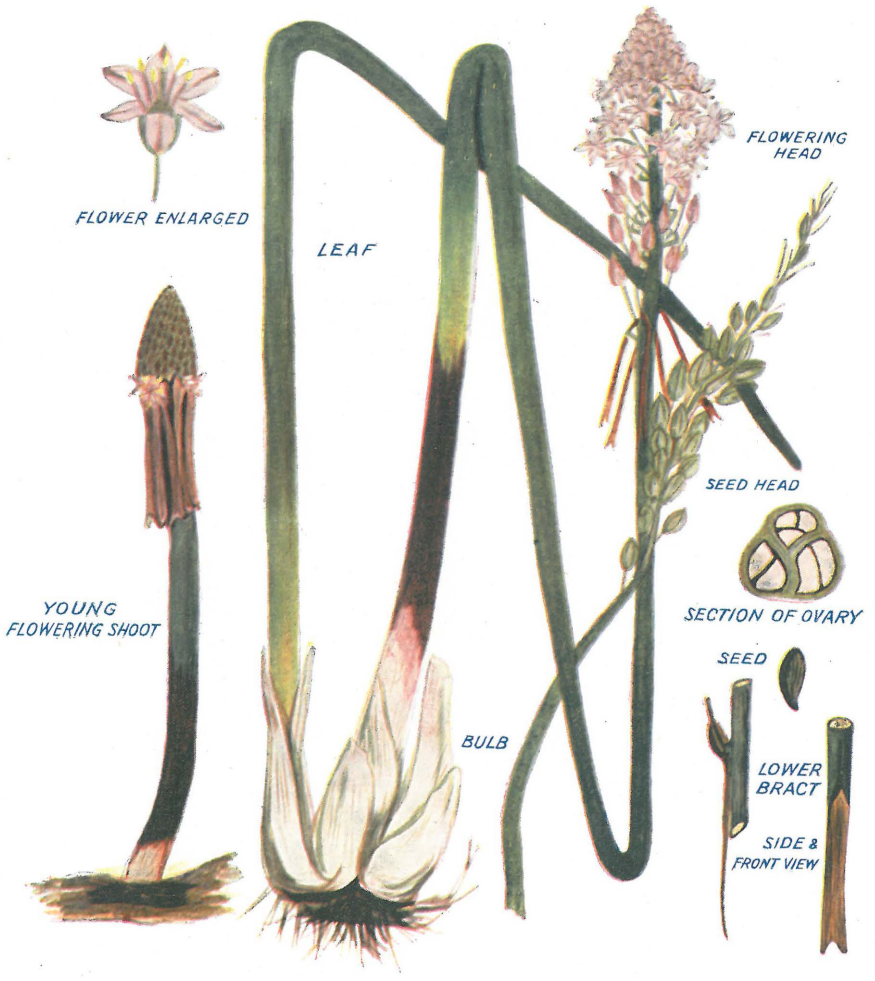


Plate I.]

URGINEA MACROCENRTA (BAKER).

[*D. T. Mitchell.*



Del. L. Hill.

PLATE II.

Urginea Macrocentra (Baker).]

[*D. T. Mitchell.*