

Sleepiness Score-Specific Outcomes of a Novel Tongue Repositioning Procedure for the Treatment of Continuous Positive Airway Pressure-Resistant Obstructive Sleep Apnea

Rushdi Hendricks¹, Malika Davids¹, Hoosain Khalfey¹, Hilda J Landman², Anne E Theron³, Eugene Engela⁴, Keertan Dheda^{1,5}

¹Centre for Lung Infection and Immunity, Division of Pulmonology, Department of Medicine and UCT Lung Institute & South African MRC/UCT Centre for the Study of Antimicrobial Resistance, University of Cape Town, Cape Town, South Africa, ²Department of Medicine, Stellenbosch Mediclinic, Stellenbosch, ³Department of Physiology, Faculty of Health Sciences, University of Pretoria, ⁴Department of Medicine, Cape Town Mediclinic, Cape Town, South Africa, ⁵Department of Immunology and Infection, Faculty of Infectious and Tropical Diseases, London School of Hygiene and Tropical Medicine, London, UK

Abstract

Background: The gold standard of treatment for obstructive sleep apnea (OSA) is continuous positive airway pressure (CPAP). However, more than a third of patients have such difficulty with its chronic use such that they seek other options or choose to remain untreated. We evaluated sleepiness score-specific outcomes and the use of CPAP after tongue repositioning surgery for the treatment of OSA. **Patients and Methods:** A self-administered questionnaire was completed pre- and postoperatively by 10 patients who underwent tongue repositioning surgery for the treatment of OSA from October 2010 to December 2012. The questionnaire included the Epworth Sleepiness Scale (ESS) for the assessment of daytime somnolence and questions regarding CPAP use and overall satisfaction. **Results:** Preoperatively, 6 patients were “very sleepy” (ESS ≥ 16), 4 patients were “sleepy” (ESS = 10–16), and 0 patients were “not sleepy” (ESS ≤ 10). 30 days postoperatively, sleepiness scores decreased (10 patients were “not sleepy” (ESS ≤ 10) with 0 patients “very sleepy” or “sleepy;” $P = 0.002$). Thus, the median ESS score for the “very sleepy” and “sleepy,” decreased from 20 to 4 and 13 to 5, respectively, and the “nonsleepy” group increased from 0 to 4. After a 180-day review, the improved ESS scores remained unchanged (the median for “very sleepy” decreased to 3.5 that for “sleepy” remained at 5, and the median for “not sleepy” decreased to 3.5). Surgery decreased CPAP use by 100%. The surgery was judged to be worthwhile by all 10 of patients using a questionnaire, and all 10 patients said that they would recommend the treatment to other patients with OSA. **Conclusions:** These preliminary data indicate that tongue-repositioning surgery for the treatment of OSA may be effective in improving excessive daytime sleepiness. These proof-of-concept data require confirmation in an appropriately powered controlled study.

Keywords: Genioplasty, score-specific outcomes, sleep apnea, tongue base surgery

INTRODUCTION

Obstructive sleep apnea (OSA) is a debilitating condition with significant morbidity and mortality affecting approximately 2%–4% of the adult population in western countries.^[1] Patients suffering from OSA have sleep fragmentation and deprivation, as they are unable to achieve adequate rapid eye movement sleep resulting in a nonrefreshing sleep pattern. The major symptom of OSA is excessive daytime sleepiness (EDS). As a result, lack of concentration and memory, changes in mood and personality, and an increase in workplace and traffic accidents have been linked to EDS.^[2] Furthermore, comorbidities with OSA include obesity, cardiovascular, endocrine complications, and premature death.^[3,4]

While most studies have looked at objective outcomes of surgery for the treatment of OSA, for example, the apnea-hypopnea index (AHI) and the lowest oxygen saturation, successful treatment outcome from a patient’s perspective is directly related to positive changes in their symptoms and

Address for correspondence: Prof. Keertan Dheda, Department of Medicine, Division of Pulmonology, Faculty of Health Sciences, University of Cape Town, Private Bag X3, Rondebosch 7701, South Africa. E-mail: keertan.dheda@uct.ac.za

This is an open access journal, and articles are distributed under the terms of the Creative Commons Attribution-NonCommercial-ShareAlike 4.0 License, which allows others to remix, tweak, and build upon the work non-commercially, as long as appropriate credit is given and the new creations are licensed under the identical terms.

For reprints contact: reprints@medknow.com

How to cite this article: Hendricks R, Davids M, Khalfey H, Landman HJ, Theron AE, Engela E, *et al.* Sleepiness score-specific outcomes of a novel tongue repositioning procedure for the treatment of continuous positive airway pressure-resistant obstructive sleep apnea. *Ann Maxillofac Surg* 2019;9:28-36.

Access this article online

Quick Response Code:



Website:
www.amsjournal.com

DOI:
10.4103/ams.ams_151_18

elimination of the use of continuous positive airway pressure (CPAP). The diagnosis of OSA relies on a thorough clinical history, physical examination, body mass index (BMI), cephalometric analysis,^[5,6] a polysomnogram (PSG) with emphasis on the AHI, respiratory distress index, and subjective sleepiness scales, for example, the Epworth Sleepiness Scale (ESS) questionnaire.^[7]

The current gold standard in the management of OSA worldwide is CPAP.^[1,8,9] This therapy splints the airway and maintains an anterior position of the tongue. This modality, however, is poorly tolerated by a significant minority of patients and is, therefore, linked to poor compliance in these individuals.^[10] A significant proportion (46%) of those so diagnosed, either do not initiate or eventually abandon therapy.^[11] Therefore, alternate methods of treatment have been investigated.

Van de Heyning *et al.* have shown that electrical stimulation of the hypoglossal nerve can improve OSA.^[12] Similar improvements in mild forms of OSA have also been achieved through the use of oral appliances.^[13] However, these therapies tend to be effective only in mild OSA. Given that the genioglossus muscle is the most significant dilator (adductor) of the pharynx, it is conceivable that anterior positioning and maintenance of the tongue in that position would obviate obstruction of the airway in the Fujita type III obstructive cases.^[14] Such repositioning is achievable through a novel surgical technique.

Indeed, this article describes a novel surgical technique for patients who have failed CPAP use. The biological basis thereof was to provide a new “check ligament” for the tongue to prevent its collapse against the posterior pharyngeal wall and also by advancing the tongue base by 10 mm, thus simultaneously improving compliance of the lateral pharyngeal wall. This technique was performed together with adjuvant procedures, including radiofrequency ablation of the uvula (RF) and/or partial glossectomy to reduce tongue mass in macroglossia, depending on the patient profile. The purpose of this study was to evaluate the subjective outcomes and the use of CPAP after tongue repositioning surgery for the treatment of OSA.

PATIENTS AND METHODS

Patients

As this is a novel procedure, a pilot study was conducted from October 2010 to December 2012. Eleven patients underwent the procedure. All patients were male aged between 25 and 75 years with a median age of 45.3 years. Inclusion criteria incorporated CPAP resistance and/or noncompliance. As part of the diagnostic and clinical preparation, BMI analysis, comprehensive clinical examination, and medical history, preoperative PSG's and ESS questionnaires were performed on each patient. The BMI ranged from 29 to 47 kg/m² (average 36.5). The AHI ranged from 10 to 98.4 events/h (average 50.4). Cephalometric radiographs were analyzed pre- and postoperatively. Patients were examined by a

pulmonologist to assess cardiovascular comorbidities and determine anesthetic risk. All patients were counseled extensively about the experimental nature and all potential risks of this procedure. A voluntary written informed consent was obtained.

Methods

Under general anesthesia, the lower lip is exposed, and local anesthetic consisting of a mixture of 1% lidocaine and 0.01% adrenaline is infiltrated into the submucosal region of the lip. A circumvestibular incision is made to gain access to the prominence of the chin. A chin retractor is used to expose the lower border of the chin [Figure 1a and b].

A bony window is then created using a tungsten carbide burr (SS White™ #701) from the outer cortex toward the inner cortex of the chin not <5 mm below the apices of the incisor teeth. In so doing, the vitality of the incisor teeth is preserved [Figure 1c].

The outer cortex of the chin is removed in two separate blocks after using the burr and osteotome [Figure 1d]. To prevent the inner cortex of the chin from inadvertently being displaced into the floor of the mouth, a titanium screw is placed into the inner cortex to assist in the removal of the inner cortex after the osteotomy is done [Figure 1e].

In Figure 1f via illustration, it can be seen that the floor of the mouth is now accessible through a fenestration made in the chin. #59 refers to the lower incisor, #55 refers to the alveolar bone, #57 refers to the fenestration, and #55 refers to the lower border of the chin, respectively.

An incision of about 3 cm is then made on the dorsum of the tongue just anterior to the circumvallate papillae [Figure 1g]. Sharp dissection is carried out toward the base of the tongue so that the intrinsic muscle of the tongue remains intact and is not frayed by the trauma of lateral dissection [Figure 1h]. 3 anchorage sutures (Vicryl™ 3/0, Ethicon, Johnson and Johnson) are then placed into the intrinsic muscle of the tongue in the posterior, medial, and lateral aspects of the dissected muscle bed. The sutures will be used to secure the polypropylene mesh [Figure 1i]; (Prolene Physiomesht™ Ethicon, Johnson and Johnson).

In Figure 1j, it can be seen that the 1 cm wide ribbon cut in the shape of an anchor from the polypropylene mesh is prestretched by 10%. The Prolene™ mesh was embedded in gentamicin solution (Fresenius 80 mg/2 mL vials) and care was taken not to have contact with the skin during surgery. The mesh is then secured to the deep aspect of the tongue muscle by tying knots within the Vicryl™ sutures. The needles are cutoff and disposed.

In Figure 1k, it can be seen that the anchorage of the polypropylene mesh is first tested before the push-through method is carried out toward the fenestration in the chin. In Figure 1l, it can be seen that the polypropylene mesh is passed through the base of the tongue through the floor of the mouth

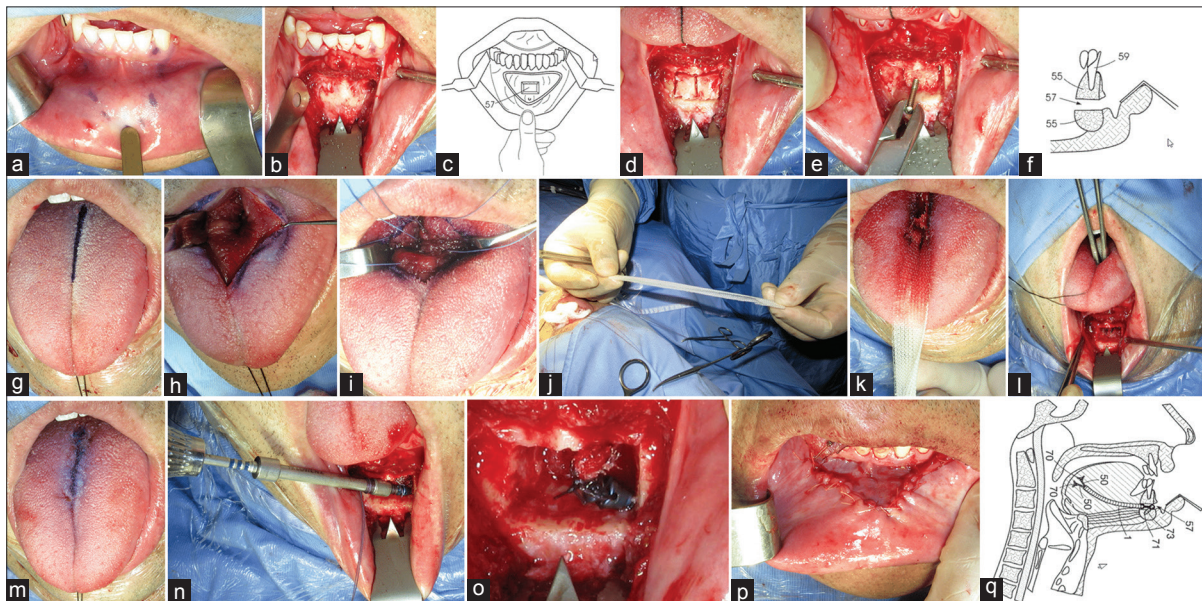


Figure 1: (a) Outline of circumvestibular incision in lower lip mucosa. (b) Dissection through Mentalis Muscle to expose prominence of chin. (c) Diagram to show position of bicortical fenestration of chin into floor of mouth. (d) Osteotomy of outer cortex of chin measuring approximately 15 mm × 10 mm. (e) Use of titanium screw facilitating removal of inner cortex of chin. (f) Diagram of lateral view of the fenestration in chin indicated by #57; #59 refers to lower incisor teeth; #55 refers to alveolar bone; #55 refers to lower border of mandible. (g) Marking for dorsal incision on tongue. (h) Sharp dissection towards tongue base without fraying of tongue muscle. (i) Position of 3 anchorage sutures, namely, proximally, medially and laterally within intrinsic muscle of tongue. (j) Creation of anchor strip from polypropylene mesh and prestretching of 10% of its length. (k) Testing for anchorage stability of mesh. (l) Push through method using blunt artery forceps to advance mesh from dorsum of tongue, through the floor of mouth, into the chin fenestration. (m) Dorsal repair of tongue mucosa. (n) Insertion of titanium screw into medulla of chin. (o) Tight knot securing polypropylene mesh to titanium screw using Vicryl 3/0™ suture. (p) Repair of lip incision using interrupted 5/0 Vicryl™ sutures. (q) lateral illustration from patent document showing position of the polypropylene mesh and advancement of tongue base; #57 refers to fenestration; #73 to lower border of chin; #71 refers to titanium screw; #1 refers to polypropylene mesh; #50 refers to Vicryl™ suture material; #70 refers to tied knots of Vicryl™ suture material

into the fenestration of the chin where it is pulled through from the labial aspect.

By keeping the dissection within the center of the tongue muscle, the vital structures, namely the lingual arteries, veins as well as nerves are avoided. The dorsum of the tongue is then closed in layers and a 3/0 Chromic™ (Ethicon, Johnson and Johnson) continuous suture is used for the closure of the keratinized mucosa [Figure 1m].

By means of distance markings and using the outer chin cortex as a guide, a 10-mm interval is measured, and the mesh and tongue base complex are advanced by 10 mm. The mesh is secured in that position by means of a 3/0 Vicryl™ (Ethicon, Johnson and Johnson) suture passing through the mesh and tied to a 9-mm titanium screw (Zimmer Biomet Microfixation, Florida, USA) which is placed into the medulla of the chin [Figure 1n]. In Figure 1o, it can be seen that the polypropylene mesh is fairly well secured to the titanium screw through the Vicryl™ suture. The mentalis muscle is then repaired using 4/0 Vicryl™ suture material, and the labial mucosa is closed using 5/0 Vicryl™ interrupted sutures [Figure 1p]. Figure 1q is a lateral illustration showing the position of the polypropylene mesh in relation to the base of the tongue and the chin: #1 refers to the polypropylene mesh, #71 refers to the titanium screw #73 refers to the lower border of the chin #57 refers to the fenestration within the

chin #50 refers to the Vicryl™ material suture material and #70 refers to the knots that are tied within the intrinsic muscle of the tongue.

Additional procedures such as partial glossectomy in cases of overt macroglossia, which was the case in 5 of the 10 patients, was carried out concurrently with the anchorage procedure, five patients presented with elongated uvulae, and required radiofrequency to these structures.

Using standard techniques, namely median resection of the tongue, a median keyhole tongue reduction was performed. Figure 2a shows the outline of the keyhole approach and the dissection in the right-hand figure of the median aspect of the tongue. The dissection is carried out in a manner where the superior aspect is tailored medially when dissecting from the dorsal to the ventral side so that the vital structures are not interfered with during the resection. Figure 2b on the left-hand side shows the splayed tongue without any damage to the vital structures and the picture on the right shows the placement of 3 retention Vicryl™ sutures, namely medially laterally and proximally. In Figure 2c, it can be seen that the polypropylene mesh is again secured as before. By using a blunt artery forceps, the polypropylene mesh is pushed through the floor of the mouth into the fenestration of the chin as can be seen in Figure 2d. A 9-mm titanium screw is again placed and the polypropylene mesh is again secured using a Vicryl™ suture as before. Figure 2e

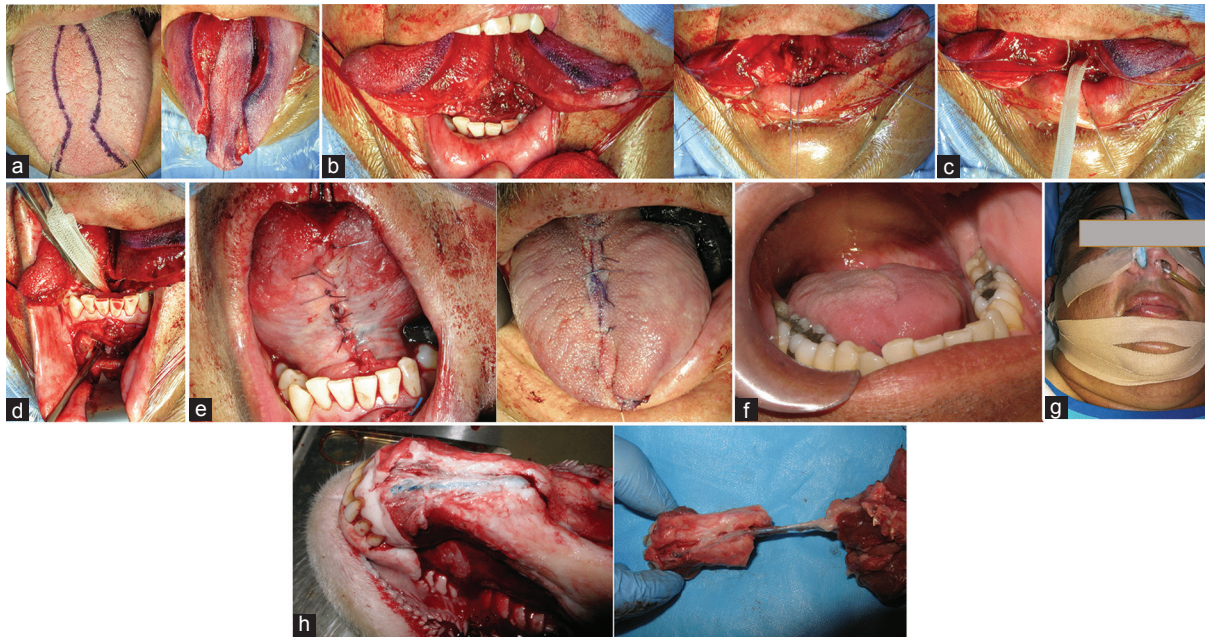


Figure 2: (a) Show keyhole outline on left hand side and the dissection profile on the right hand side for medial resection of tongue. (b) Shows splayed lateral borders of tongue after removal of median section on the left picture and the position of the 3 retention sutures before placement of mesh. (c) Polypropylene mesh is secured in position. (d) Polypropylene mesh is easily advanced through the chin fenestration followed by layered closure of the tongue muscle. (e) ventral closure of tongue in left picture and dorsal closure on right-hand side. (f) Healing of resected tongue after 30 days. Note comfortable position. (g) Immediate postoperative status of patient following tongue reduction. Note pressure taping and *in situ* position of endotracheal tube. (h) Picture on left shows polypropylene mesh *in situ* at 32 weeks postinsertion in sheep model. The polypropylene extends from the base of tongue to the sheep chin. The nonresorbable material remains intact and does not disintegrate. The picture on the right shows the integrity of the material in the sheep floor of mouth and tongue at 32 weeks

on the left side shows the repair of the ventral mucosa and on the right-hand side shows the repair of the dorsal mucosa. Figure 2g shows the pressure taping of the chin to secure the degloved Mentalis muscle to the bone and reduce postoperative swelling. Also to be noted is the *in situ* endotracheal tube for overnight intubation. The polypropylene mesh used in this study, when implanted in a sheep model, does not disintegrate even after 32 weeks [Figure 2h]. Postoperatively, as a precaution to protect the airway, overnight intubation and high intensity observation was carried out in the intensive care unit under the care of a specialist physician/pulmonologist. Arterial line insertion and arterial blood gas monitoring was mandatory for 48 h after the surgery together with pulse oximetry to screen for airway obstruction. After extubation on day #1 postoperatively, patients were monitored for an additional night in the intensive care unit. The patients were subsequently transferred to the general ward for an additional 2-day observation. A soft diet was introduced on day #1 postoperatively, and a strict oral hygiene regimen was prescribed. All patients received perioperative Cefazolin™ 1 g (GlaxoSmithKline) with a 5-day follow-up of 250 mg orally twice a day and 8 mg dexamethasone (Pharmacare, Port Elizabeth) for 3 consecutive doses. Figure 2f shows the healing of the resected tongue after 1 month.

Data analysis

Patients were split into three groups based on the results of the ESS scores. The groups were referred to as “not sleepy”

Table 1: The Epworth Sleepiness Score

Situation*	Chance of dozing
	0 = would never doze
	1 = slight chance of dozing
	2 = moderate chance of dozing
	3 = high chance of dozing

- Sitting and reading
- Watching TV
- Sitting, inactive, in a public place
- As a passenger in a car for an hour
- Lying down in the afternoon
- Sitting and talking to someone
- Sitting quietly after a lunch without alcohol
- In a car, while stopped for a few minutes in traffic
- Total

*Refers to your usual way of life in recent times. Even if you have not done some of these things recently, try to work out how they would have affected you

(ESS ≤10), “sleepy” (ESS = 10–16), and “very sleepy” (ESS ≥16). Pre- and post-operative groups were compared.

The Wilcoxon matched-pairs signed-rank test for nonparametric data was used for group comparison. All statistical analyses

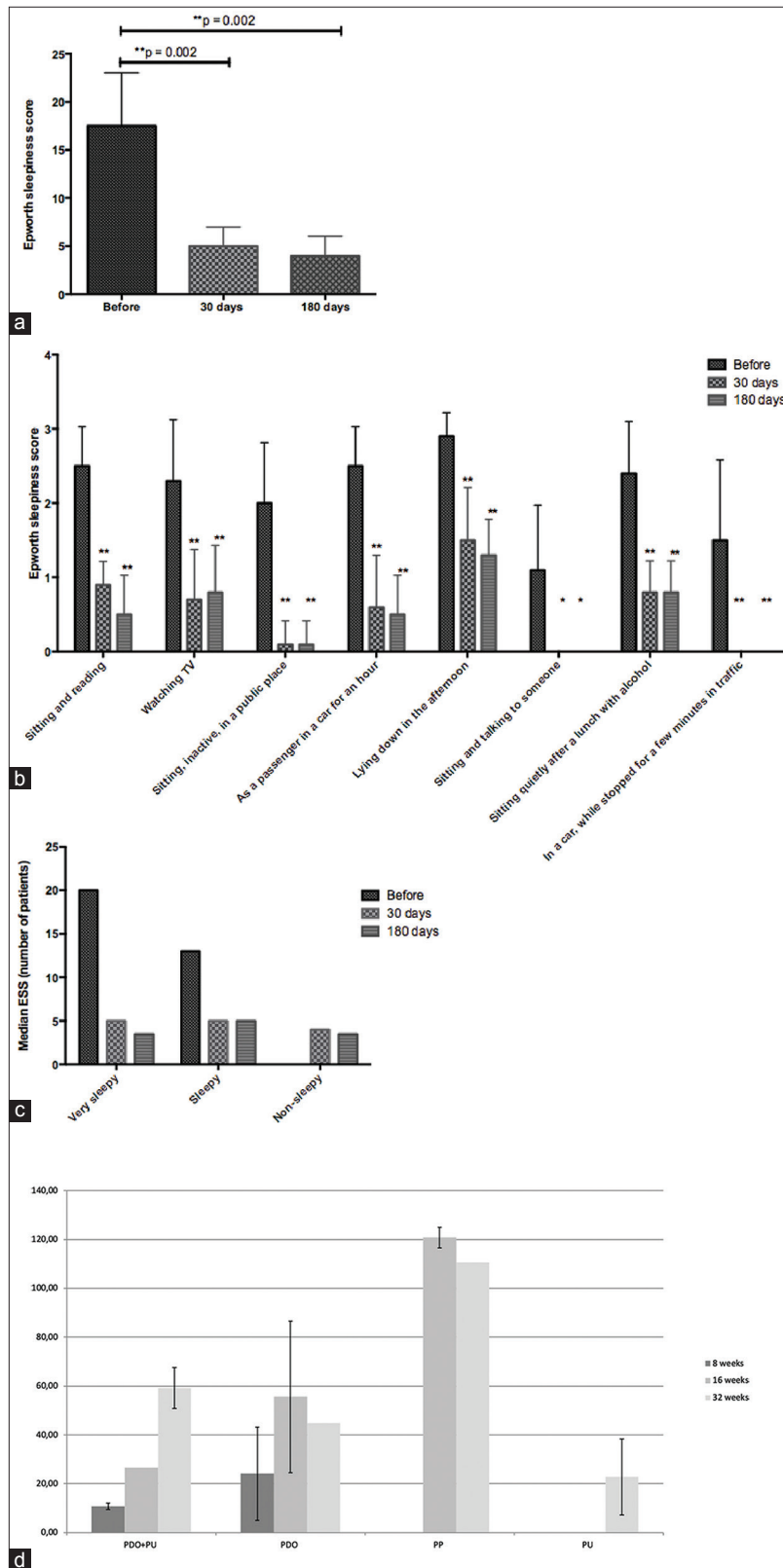


Figure 3: Epworth Sleepiness Score, (a) comparison in the total Epworth sleepiness score preoperatively to 30-day and 180-day postoperatively. (b) A comparison of the Epworth sleepiness score before and after surgery, stratified by the patient's location and activity. (c) Illustration of the Epworth sleepiness score before and after surgery, stratified by group (very sleepy, sleepy and nonsleepy). (d) Shows bench testing load analysis of polypropylene (pp) at 16 and 32 weeks after placement in a sheep model. Note that in the third set of graphs that the breaking strength changed from 120 Newtons at 16 weeks to 110 newtons at 32 weeks. This illustrates the reliability of this material as a tethering device. Graph from patent document WO2017/212449A1. $P < 0.05$ were considered significant (Wilcoxin matched paired test) and error bars represent the interquartile range

were carried out using GraphPad Software, San Diego, California, USA (version 6.0).

RESULTS

Responses as defined by the Epworth Sleepiness Scale

The ESS questionnaire was used as the main measurement of success of the procedure by evaluating the outcome pre- and postoperatively. An example of the questionnaire is given in Table 1.

Ten patients with OSA confirmed by PSG's underwent the Tongue Anchorage procedure as a pilot study. There were no early episodes of OSA events as charted by the intensive care notes during the early postoperative stages.

The median ESS decreased significantly from 17.5 preoperatively to 5, 30-day postoperatively [Figure 3a; $P = 0.002$]. Figure 3b demonstrates a significant reduction within the individual parameters of the scale. Figure 3c illustrates the ESS before and after surgery, stratified by group. Preoperatively, six patients were "very sleepy" (ESS ≥ 16), four patients were "sleepy" (ESS = 10–16), and 0 patients were "not sleepy" (ESS ≤ 10). Postoperatively, 0 patients were "very sleepy," 0 patients were "sleepy," and 10 patients were "not sleepy." The median ESS score for the "very sleepy" and "sleepy," decreased from 20 to 4 and 13 to 5, respectively, and the "nonsleepy" group increased from 0 to 4. After a 180-day review of the ESS scores, the medians for "very sleepy" decreased to 3.5 and that for "sleepy" remained at 5, and the median for "not sleepy" decreased to 3.5. These figures not only indicate early stability of the surgical outcome, but also further improvement in daily sleepiness experience. Tongue repositioning surgery obviated CPAP use in all the cases. Figure 3d shows the bench testing load analysis of polypropylene (pp) after placement in a sheep model, indicating its superiority as a tethering device.

Complications

One patient developed a sublingual hematoma, speculated to be related to premature administration of his anticoagulation medication. There were no serious sequelae, and this resolved without drainage after 5 days. One patient died after the procedure while in the intensive care unit. He is thought to have had a cardiac event unrelated to the surgery as reported on the autopsy findings. There was no evidence of airway obstruction either by intra-oral/tracheal clot formation or extra-tracheal or pharyngeal compression due to swelling seen on autopsy. In the perioperative stage, all the vital observations were within normal limits. In the absence of hypotension, anemia, arrhythmias or electrolyte imbalances, his death could be deemed as unrelated to the surgical procedure.

Furthermore, the surgery was well tolerated by the patients, and no further complications were reported. Due to financial constraints, only one patient received a postoperative PSG.

The surgery was judged to be worthwhile by all 10 patients, and all patients indicated that they would recommend the treatment to other patients with OSA. In addition, all the

individual patient responses on the improved quality of lives were highly positive.

DISCUSSION

The clinical results achieved from the procedure described in this pilot study of patients who were either CPAP resistant or noncompliant, suggest that this novel procedure may have a role in the treatment of OSA. The main observation of this study was the dramatic decline in ESS after surgery. These results remained stable and even improved slightly after 180 days. Patient satisfaction through the questionnaire was very positive and all stated that they would recommend the procedure to others. The results of this study compare favorably to a similar study conducted by Gooday and Bourque (2012) on maxillomandibular advancement surgery (MMA) currently regarded as the surgical gold standard.^[15] The authors evaluated 116 patients over 10 years using the ESS. In the "very sleepy" group, they found a reduction from 40% to <1% (this study showed reduction from 60% to 0%). In the "sleepy" group, they found a reduction from 32% to 9% (this study showed a reduction from 40% to 0%). The "not sleepy group" improved from 28% to 90% (this study showed an improvement from 0% to 100%). There were no serious complications with the surgical procedure.

This is a novel surgical procedure that, to the best of our knowledge, has not been attempted before. Thus, there are no similar studies previously reported. The biological rationale behind this technique is to improve the compliance of the lateral pharyngeal wall by advancing the tongue base and maintaining it in that new position. This aligns aptly with the hypothesis that the tongue base is the main adductor of the hypo-pharynx and lends compliance to the patency thereof.^[16] This procedure relieves the obstruction at the Fujita III level. When performed in conjunction with the Fujita level I procedures (such as RF ablation of the uvula), multilevel obstruction sites involved in OSA are simultaneously relieved. A 180-day postoperative outcome review by all patients indicated not only early stability of the surgical outcome but also further improvement in daily sleepiness experience. This technique can, therefore, be considered as being both reliable and stable in the longer term as a new "tendon" is created to anchor the tongue to the chin. It has been shown that supraglottic laryngeal collapse is a significant risk factor for surgical failure in the multilevel surgical management of OSA. This is due to the posterior displacement of the epiglottis resulting from the collapse of the base of the tongue. Thus, the advancement of the tongue base not only improves compliance of the lateral pharyngeal wall but also improves the rate of surgical success.^[17] In this study, the tongue was advanced by 10 mm in all 10 cases.

Speech and swallowing were not affected in the medium and long term as recorded by telephonic interrogation after 36 months. In the 5 cases where macroglossia complicated tongue advancement of 10 mm, simultaneous tongue reduction procedures were carried out as illustrated in Figure 2a-f.

Previous attempts at surgical solutions involving tongue base advancement have failed in the longer term. The Repose[®] device has only limited efficacy.^[18] This device also utilizes the suture and screw concept. Again, the gains are only short term as they relapsed after 6 months due to slippage or migration of the suture through the tongue muscle.^[18-24] The Harvard Pilgrim Healthcare Medical policy on surgical tongue base suspension published in September 2008, stated that “*the Repose system does not result in permanent anatomical change in the posterior airway*” and this is due to the slippage that occurs in the long term with this particular method. Furthermore in the ERS Taskforce publication by Randerath *et al.* 2011, on page 1015 paragraph 2^[25] it is stated that “*As the aim of the tongue suspension is to stabilize and support the tongue base rather than to advance it is not surprising that Miller *et al.*^[22] and Terris *et al.*^[26] fail to find relevant changes in the posterior airway space.*” This confirms the concept that tongue advancement is the way forward in the surgical management of OSA.

When directly compared in randomized trials, oral appliances are generally preferred by patients over CPAP, even when only partly successful in elimination of disordered breathing events. Thus, oral appliances should be considered for patients who have failed or refused CPAP treatment, snoring or mild OSA, and those who do not respond to Fujita type I surgery. While the latter technique probably reduces retropalatal collapse, the oral appliance decreases retroglossal collapse, but only in mild cases of OSA.^[27] This concept vindicates the theory of tongue base advancement being germane to successful upper airway patency. In this study, the severity of OSA was very significant (AHI average of 50.4 events/h), clearly indicating the successful outcome of tongue base advancement.

This study clearly demonstrates the efficacy of surgical tongue base advancement in the prevention of upper airway collapse by splinting the lateral pharyngeal wall during sleep. The current surgical approach by most otorhinolaryngologists is to resort to the uvulopalatopharyngoplasty (UPPP), first described by Fujita *et al.* in 1981, in which the uvula and redundant soft tissue of the soft palate is resected.^[28] The long term success of UPPP is only 20% after 2 years.^[29] The role of UPPP without tongue base advancement surgery for treatment of OSA is, therefore, limited.

Hyoid suspension techniques have shown only early promising results. A 13-year retrospective analysis done in 2013 by Canzi *et al.* showed a success rate of 67% for a limited period of 18 months in 140 patients with AHI's of <30.^[30]

Radiofrequency of the tongue base produced promising early results but was not consistent in the long term.^[31] Multilevel surgery involving the Fujita type II approaches is probably the most predictable way forward.^[32]

Newer surgical approaches such as laser-assisted palatal procedures and radiofrequency ablation techniques to the tongue base have also been disappointing. Neither of these techniques has been effective in the treatment of OSA.^[33,34]

However, in patients whose main complaint is snoring, with little or no apnea found on formal testing, these procedures may be considered. An interesting area of investigation would be to correlate tongue base advancement with the severity of snoring.

There exists a strong relationship between obesity and OSA. It has been reported that 60%–90% of patients suffering from OSA have a BMI of ≥ 30 kg/m². Indeed, in this study, the BMI ranged from 29 to 47 kg/m² (average 36.5). Furthermore, the AHI ranged from 10 to 98.4 events/h (average 50.4).

In spite of the high BMI and AHI indices found in our cohort of cases, the outcome of tongue base advancement was found to be very encouraging. It must also be noted that these patients constitute a high risk for surgery; hence, intensive pre, peri and postoperative care is mandatory and demand a multi-disciplinary approach.

As the prevalence of obesity increases, there is likely to be a parallel increase in OSA. In the adult population, the prevalence of OSA is estimated at 25%, rising to 45% in obese individuals.^[35] The prevalence of obesity has escalated to very high proportions in South Africa with rates as high as 57% in adult females and 29% in adult males.^[36]

Bariatric surgery for morbidly obese patients with OSA has shown promising results. Several studies^[37-39] have shown long-term improvements in AHI after gastric stapling. However, some results have shown recurrence of apnea after surgery for weight loss in the absence of substantial weight gain.^[40] Thus, the role of bariatric surgery, despite its increasing popularity, is still unclear and not without attending risk and complications.

In addition, the cost of bariatric surgery is much higher than this novel procedure.

While the proof of concept of tongue base advancement through surgery has already been established, further studies are proposed to test this hypothesis on a level 1 basis. The outcomes must be measured in terms of pre- and post-operative PSGs for every patient, ESS, and other recognized sleep scale questionnaires, cone-beam volumetric airway analysis and quality-of-life assessment.

There are several limitations to this study. Due to the lack of funding, the PSG's to monitor AHI and other important parameters were not performed. In addition, the sample size was limited, and there were no standardized controls. However, this study was intended to be a “proof-of-concept” study, and controlled trials are now warranted. To this end, a new much larger study is planned, where a biological tendon will replace the Prolene[™] mesh in achieving the same outcomes. Finally, adjunct procedures to the uvula and tongue (for macroglossia) may have impacted the positive results. However, even in half the patients who did not have such interventions, the results were good.

CONCLUSIONS

This study has provided a proof of concept that can be further evaluated and possibly provide the basis for a successful surgical

solution to the management of OSA in a manner that reconstitutes the physiology of normal airway patency during sleep.

Acknowledgments

The authors would like to thank Assoc. Professor George Vicatos, Department of Engineering, University of Cape Town and Professor Donavon C. Hiss, Department of Medical Biosciences, University of the Western Cape for their invaluable assistance with this manuscript.

The proof of concept and surgical technique in this study is protected by University of Cape Town. International patent filed under "Hendricks Biological Tendon": International Publication number WO 2017/212449A1. The illustrations used in this manuscript are from the patent document.

Financial support and sponsorship

Nil.

Conflicts of interest

There are no conflicts of interest.

REFERENCES

- Epstein LJ, Kristo D, Strollo PJ Jr, Friedman N, Malhotra A, Patil SP, *et al.* Clinical guideline for the evaluation, management and long-term care of obstructive sleep apnea in adults. *J Clin Sleep Med* 2009;5:263-76.
- Young T, Finn L, Peppard PE, Szklo-Coxe M, Austin D, Nieto FJ, *et al.* Sleep disordered breathing and mortality: Eighteen-year follow-up of the Wisconsin sleep cohort. *Sleep* 2008;31:1071-8.
- Vgontzas AN, Bixler EO, Chrousos GP. Sleep apnea is a manifestation of the metabolic syndrome. *Sleep Med Rev* 2005;9:211-24.
- Marin JM, Carrizo SJ, Vicente E, Agustí AG. Long-term cardiovascular outcomes in men with obstructive sleep apnoea-hypopnoea with or without treatment with continuous positive airway pressure: An observational study. *Lancet* 2005;365:1046-53.
- Yao M, Utley DS, Terris DJ. Cephalometric parameters after multilevel pharyngeal surgery for patients with obstructive sleep apnea. *Laryngoscope* 1998;108:789-95.
- Liao YF, Huang CS, Chuang ML. The utility of cephalometry with the muller maneuver in evaluating the upper airway and its surrounding structures in Chinese patients with sleep-disordered breathing. *Laryngoscope* 2003;113:614-9.
- Johns MW. A new method for measuring daytime sleepiness: The epworth sleepiness scale. *Sleep* 1991;14:540-5.
- Kushida CA, Littner MR, Hirshkowitz M, Morgenthaler TI, Alessi CA, Bailey D, *et al.* Practice parameters for the use of continuous and bilevel positive airway pressure devices to treat adult patients with sleep-related breathing disorders. *Sleep* 2006;29:375-80.
- Sullivan CE, Issa FG, Berthon-Jones M, Eves L. Reversal of obstructive sleep apnoea by continuous positive airway pressure applied through the nares. *Lancet* 1981;1:862-5.
- Gay P, Weaver T, Loube D, Iber C; Positive Airway Pressure Task Force, Standards of Practice Committee. Evaluation of positive airway pressure treatment for sleep related breathing disorders in adults. *Sleep* 2006;29:381-401.
- Wolkove N, Baltzan M, Kamel H, Dabrusin R, Palayew M. Long-term compliance with continuous positive airway pressure in patients with obstructive sleep apnea. *Can Respir J* 2008;15:365-9.
- Van de Heyning PH, Badr MS, Baskin JZ, Cramer Bornemann MA, De Backer WA, Dotan Y, *et al.* Implanted upper airway stimulation device for obstructive sleep apnea. *Laryngoscope* 2012;122:1626-33.
- Dieltjens M, Vanderveken OM, Heyning PH, Braem MJ. Current opinions and clinical practice in the titration of oral appliances in the treatment of sleep-disordered breathing. *Sleep Med Rev* 2012;16:177-85.
- Carrera M, Barbé F, Sauleda J, Tomás M, Gómez C, Agustí AG. Patients with obstructive sleep apnea exhibit genioglossus dysfunction that is normalized after treatment with continuous positive airway pressure. *Am J Respir Crit Care Med* 1999;159:1960-6.
- Goodday R, Bourque S. Subjective outcomes of maxillomandibular advancement surgery for treatment of obstructive sleep apnea syndrome. *J Oral Maxillofac Surg* 2012;70:417-20. doi: 10.1016/j.joms.2011.02.122. Epub Jul 16.
- White DP. Pathogenesis of obstructive and central sleep apnea. *American J Respiratory and Critical Care Med* 2005;172:1363-70.
- Soares D, Sinawe H, Folbe AJ, Yoo G, Badr S, Rowley JA, *et al.* Lateral oropharyngeal wall and supraglottic airway collapse associated with failure in sleep apnea surgery. *The Laryngoscope* 2012;122:473-9.
- Woodson BT, Steward DL, Mickelson S, Huntley T, Goldberg A. Multicenter study of a novel adjustable tongue-advancement device for obstructive sleep apnea. *Otolaryngology--head and neck surgery: Official J American Academy of Otolaryngology-Head and Neck Surg* 2010;143:585-90.
- Fernandez-Julian E, Munoz N, Achiques MT, Garcia-Perez MA, Orts M, Marco J. Randomized study comparing two tongue base surgeries for moderate to severe obstructive sleep apnea syndrome. *Otolaryngology--Head and Neck Surgery: Official J American Academy of Otolaryngology-Head and Neck Surgery* 2009;140:917-23.
- Fibbi A, Ameli F, Brocchetti F, Mignosi S, Cabano ME, Semino L. Tongue base suspension and radiofrequency volume reduction: A comparison between 2 techniques for the treatment of sleep-disordered breathing. *American J Otolaryngology* 2009;30:401-6.
- Handler E, Hamans E, Goldberg AN, Mickelson S. Tongue suspension. *The Laryngoscope* 2014;124:329-36.
- Miller F. Role of the tongue base suspension suture with The Repose System bone screw in the multilevel surgical management of obstructive sleep apnea. *Otolaryngology - Head and Neck Surgery* 2002;126:392-8.
- Pavelec V, Hamans E, Stuck BA. A study of the new generation of the advance system tongue implants: Three- and six-month effects of tongue to mandible tethering for obstructive sleep apnea. *The Laryngoscope* 2011;121:2487-93.
- Woodson BT, Derowe A, Hawke M, Wenig B, Ross EB, Katsantonis GP, *et al.* Pharyngeal suspension suture with Repose bone screw for obstructive sleep apnea. *Otolaryngology -- Head and Neck Surgery* 2000;122:395-401.
- Randerath WJ, Verbraecken J, Andreas S, Bettge G, Boudewyns A, Hamans E, *et al.* Non-CPAP therapies in obstructive sleep apnoea. *The European Respiratory J* 2011;37:1000-28.
- Terris DJ, Kunda LD, Gonella MC. Minimally invasive tongue base surgery for obstructive sleep apnoea. *The J Laryngology and Otology* 2002;116:716-21.
- Millman RP, Rosenberg CL, Carlisle CC, Kramer NR, Kahn DM, Bonitati AE. The efficacy of oral appliances in the treatment of persistent sleep apnea after uvulopalatopharyngoplasty. *Chest* 1998;113:992-6.
- Fujita S, Conway W, Zorick F, Roth T. Surgical correction of anatomic abnormalities in obstructive sleep apnea syndrome: uvulopalatopharyngoplasty. *Otolaryngol Head Neck Surg* 1981;89:923-34.
- Boot H, van Wegen R, Poublon RML, Bogaard JM, Schmitz PIM, van der Meché FGA. Long-term results of uvulopalatopharyngoplasty for obstructive sleep apnea syndrome. *The Laryngoscope* 2000;110:469-75.
- Canzi P, Berardi A, Tinelli C, Montevecchi F, Pagella F, Vicini C, *et al.* Thirteen years of hyoid suspension experience in multilevel OSAHS surgery: The short-term results of a bicentric study. *Int J Otolaryngology* 2013;2013:263043.
- Li KK. Surgical therapy for adult obstructive sleep apnea. *Sleep Med Rev* 2005;9:201-9.
- Lin H-C, Friedman M, Chang H-W, Gurpinar B. The Efficacy of Multilevel Surgery of the Upper Airway in Adults With Obstructive Sleep Apnea/Hypopnea Syndrome. *The Laryngoscope* 2008;118:902-8.
- Malhotra A, Loscalzo J. Sleep and cardiovascular disease: An overview. *Progress in Cardiovascular Diseases* 2009;51:279.

34. Faccenda JF, Mackay TW, Boon NA, Douglas NJ. Randomized placebo-controlled trial of continuous positive airway pressure on blood pressure in the sleep apnea-hypopnea syndrome. *American J Respiratory and Critical Care Med* 2001;163:344-8
35. Romero-Corral A, Caples SM, Lopez-Jimenez F, Somers VK. Interactions between obesity and obstructive sleep apnea: implications for treatment. *Chest* 2010;137:711-9.
36. van der Merwe MT, Pepper MS. Obesity in South Africa. *Obes Rev* 2006;7:315-22.
37. Sugerman HJ, Fairman RP, Sood RK, Engle K, Wolfe L, Kellum JM. Long-term effects of gastric surgery for treating respiratory insufficiency of obesity. *Am J Clin Nutr* 1992;55(2 Suppl):597S-601S.
38. Scheuller M, Weider D. Bariatric surgery for treatment of sleep apnea syndrome in 15 morbidly obese patients: Long-term results. *Otolaryngol Head Neck Surg* 2001;125:299-302.
39. Karason K, Lindroos AK, Stenlof K, Sjostrom L. Relief of cardiorespiratory symptoms and increased physical activity after surgically induced weight loss: Results from the Swedish Obese Subjects study. *Arch Intern Med* 2000;160:1797-802.
40. Pillar G, Peled R, Lavie P. Recurrence of sleep apnea without concomitant weight increase 7.5 years after weight reduction surgery. *Chest* 1994;106:1702-4.