

Surgical resection of a squamous cell carcinoma in the perianal region of a 25-year-old crossbred American Paint gelding using sharp surgical excision, laser excision and chemotherapy

L. Poore^{†*}, Y. Smit[†], N. Duncan[‡] and J. Williams[‡]

[†]The Department of Companion Animal Clinical Studies, and

[‡]Section of Pathology, Department of Paraclinical Sciences, Faculty of Veterinary Science, University of Pretoria, Onderstepoort, South Africa

*Corresponding author email: luke.poore@up.ac.za.

Summary

A 25 year-old American Paint gelding was referred to the Onderstepoort Academic Veterinary Hospital with an ulcerated lesion of nonpigmented skin at the right lateral aspect of the perianal region. An infiltrating squamous cell carcinoma was suspected. Surgical excision and ablation with sharp surgical excision and a diode laser was performed although complete excision was not possible due to the tumour location. Intralesional chemotherapy was performed at the completion of the surgical excision and continued in the post-operative period. Histological examination of the excised lesion confirmed a diagnosis of squamous cell carcinoma and revealed incomplete resection margins at the medial, dorsal and ventral aspects of the surgical site. The surgical site healed uneventfully and a re-examination at 6 months post-surgery revealed the gelding to have normal clinical parameters with no perianal lesions.

Keywords: horse; equus caballus; intralesional chemotherapy; laser excision; neoplasia; papillomavirus 2; perianal; squamous cell carcinoma; surgical excision

Introduction

Tumours of the equine skin represent up to 65% of skin lesions in the horse (Schaffer *et al.* 2013) and account for 50% of all equine neoplastic lesions in general (Baker and Leyland 1975). Squamous cell carcinomas (SCCs) are malignant neoplasms of epithelial origin and are one of the most commonly diagnosed skin tumours in the horse (Valentine 2006; Schaffer *et al.* 2013; Knowles *et al.* 2016). Squamous cell carcinomas occur in various areas of the equine body and are especially common at mucocutaneous junctions (Sundberg *et al.* 1977; Newkirk *et al.* 2014). Reported locations in the horse have included the eye, skin, external genitalia, urogenital tract, oesophagus, stomach and nasal cavity (Sundberg *et al.* 1977; Valentine 2006; Van Den Top *et al.* 2010; Newkirk *et al.* 2014). Squamous cell carcinoma in the perianal region of horses has been rarely reported (Wilson 1994; Arnold *et al.* 2018). In humans, certain papillomaviruses have been identified as the causative agents of SCCs of genital and other mucosal and cutaneous regions (Sykora and Brandt 2017). *Equus caballus* papillomavirus 2 (EcPV2) has relatively recently been associated with most genital squamous cell carcinomas in horses (Sykora and Brandt 2017). A single anal SCC was tested and found to be EcPV2 positive (Bogaert *et al.* 2012), however, the association of EcPV2 in perianal SCCs is as yet unreported. Treatment of squamous cell carcinoma in horses usually depends on the size and locality of the lesion (Arnold *et al.* 2018). At easily accessible locations, a sole surgical therapy may allow the entire tumour to be removed (Dietz 2006). If the

anatomical site is difficult to access, surgery infrequently provides satisfactory results (Hewes and Sullins 2006; Arnold *et al.* 2018).

Chemotherapy has been described as a suitable treatment for neoplasms of the skin and external genitalia in horses (Fortier and Mac Harg 1994; Paterson 1997; Hewes and Sullins 2006). Successful outcomes have been reported with small lesions or in addition to surgical reduction (Hewes and Sullins 2006; Arnold *et al.* 2018).

There are few previous reports of perianal squamous cell carcinoma in the horse, with no previous reports of combination therapy using sharp surgical excision, laser excision and intralesional chemotherapy.

This paper reports the successful treatment of a perianal squamous cell carcinoma in a horse with surgical and laser excision and intralesional chemotherapy under standing sedation.

Case details

A 25-year-old American Paint gelding weighing 375 kg was presented to the Onderstepoort Veterinary Academic Teaching Hospital (OVAH), University of Pretoria, for evaluation of an ulcerated mass of non-pigmented skin of the right perianal region. The owner had reported that the mass had increased in size gradually over 12 months (Figs 1 and 2) with ulceration shown in the last 4 weeks of this period, prompting referral. The pony had shown no dyschezia, weight loss or change in demeanour during the previous 12-month period.

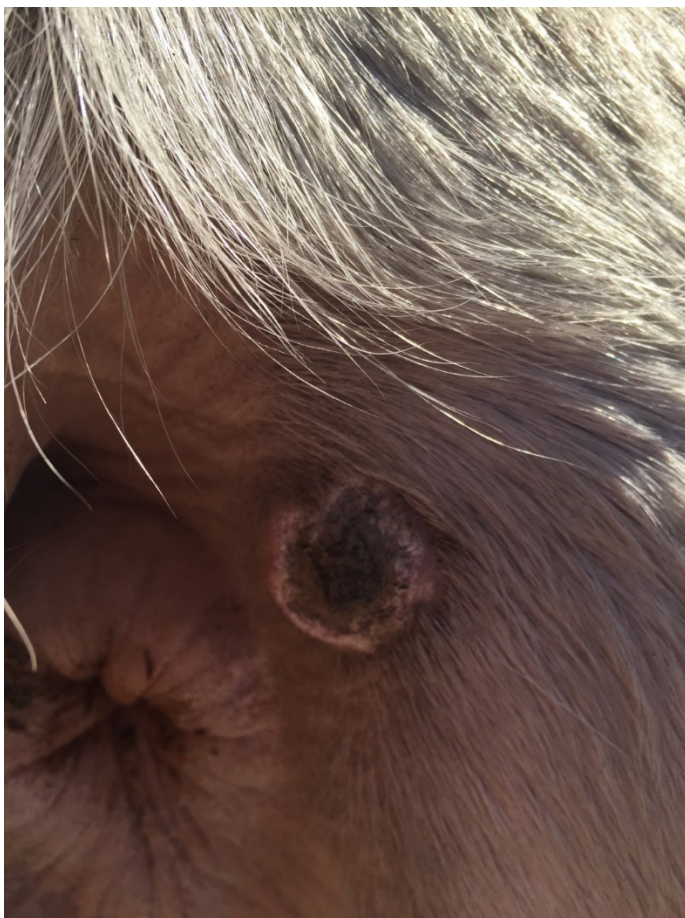

Figure 1. The mass approximately 12 months prior to presentation.

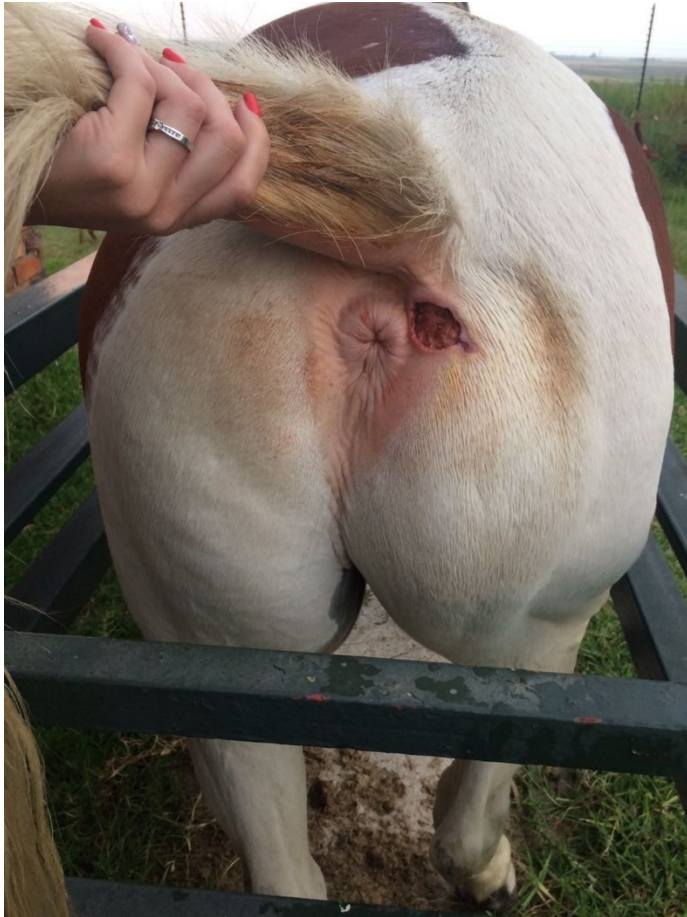

Figure 2. The mass at presentation.

General physical examination at presentation revealed normal clinical parameters and mentation with no evidence of right hindlimb regional lymphadenopathy or obvious lymph node metastasis. Palpation of the perianal region revealed a nonpainful, irregular, ulcerated cutaneous mass of 4 cm in diameter in the hairless, nonpigmented skin of the right mid-perianal region. The adjacent skin lateral to the lesion was thickened and the subcutaneous tissue exposed below the ulcer had a granular appearance. A squamous cell carcinoma was suspected and surgical excision was discussed with the owner. In view of the proximity of the medial aspect of the lesion to the right anal wall, a combination of sharp surgical excision, laser excision and chemotherapy was planned, understanding sedation and with epidural anaesthesia.

A peripheral venous blood sample obtained on the day of admission revealed no haematological abnormalities. The gelding was admitted to the hospital and feed withheld for 6 h prior to surgery, but with water allowed ad libitum.

Prior to surgery, faeces were manually removed from as far proximally in the rectum as possible and the perineum was aseptically prepared. An intravenous catheter (Extended Use Milocath, Mila International¹) was aseptically placed in the left jugular vein and pre-operative medication included intramuscular procaine penicillin (13 mg/kg bwt; Benzyl penicillin²), intravenous gentamicin sulphate (6.6 mg/kg bwt; Genta 50³) and intravenous flunixin meglumine (1.1 mg/kg bwt; Finadyne⁴).

The gelding was restrained in a metal crush and sedated with intravenous detomidine hydrochloride (10 µg/kg bwt; Domosedan⁵) and butorphanol tartrate (0.1 mg/kg bwt; Torbugesic⁶). An epidural catheter (Epidural pain management kit; Mila International¹) was placed into the first intercoccygeal space and lignocaine hydrochloride (0.2 mg/kg bwt; 2% Lignocaine⁷) and xylazine (0.2 mg/kg bwt; Rompun⁷) were administered intrathecally.

In preparation for the surgical procedure, all entrances to the surgical suite were locked and laser warning signs placed on doors leading to the surgical suite. Personnel in the surgery room wore dedicated laser safety glasses.

The lateral, ventral and dorsal borders of the lesion were resected using sharp surgical incision with borders of 2 cm achieved. The medial border was resected using a diode laser (980 nm Diode Laser System, Diodevet⁸) due to the proximity to the anal wall. Laser incision was performed with the laser in a continuous mode and 30 W of power. An initial skin incision was completed and traction was placed on the lesion with towel clamps. After removal of the mass, subcutaneous tissue and skin margins, the entire surgical site was ablated in two directions with the diode laser at 90 degrees to each other (Fig 3). Ablation was considered complete when the tissue was dark yellow to brown and appeared desiccated.

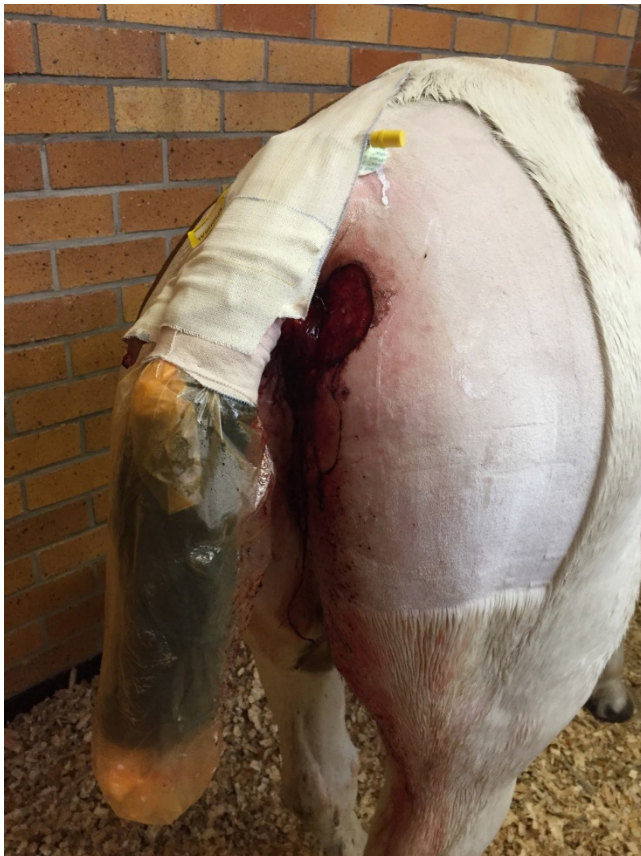

Figure 3. The surgical site in the immediate post-operative period.

Finally, cisplatin (1 mg of cisplatin per cubic centimetre of tissue; P&U Cisplatin⁹) was injected into the medial, ventral and dorsal borders of the incision site. These injections were conducted according to occupational safety and health administration guidelines. Protective eyewear was worn by all personnel in the surgery room and additional gloves were worn by the clinician administering the cisplatin. Luer-locking syringes were used to minimise spraying of the chemotherapeutic agent through a poorly attached syringe and needle. Sterile

swabs were held over each injection site to absorb any excess cisplatin. After administration, all syringes, capped needles, remaining drug, swabs and protective clothing were immediately placed in a chemotherapeutic disposal bag.

The excised mass was submitted for histopathological analysis and margin evaluation.

Post-operative treatment with twice daily intramuscular procaine penicillin (13 mg/kg bwt; Depocillin²), once daily intravenous gentamicin sulphate (6.6 mg/kg bwt; Gentacin³) and once daily flunixin meglumine (1.1 mg/kg bwt; Finadyne⁴) was administered for a further 4 days. Intercoccygeal intrathecal morphine sulphate (0.2 mg/kg bwt; Morphine Sulphate⁵) was administered at 12 h intervals for 24 h post-operatively, after which the epidural catheter was removed (Fig 3).

Further intralesional chemotherapy treatment (1 mg of 5-fluorouracil per cubic centimetre tissue; Fluracedyl¹⁰) was performed at 2-week intervals for a total of 4 treatments. Prior to each treatment, flunixin meglumine (1.1 mg/kg bwt; Finadyne⁴) was administered to the patient and a sedation protocol was achieved using intravenous detomidine hydrochloride (10 µg/kg bwt; Domosedan⁵) and butorphanol tartrate (0.1 mg/kg bwt; Torbugesic⁶). The tumour site was clipped, aseptically prepared and infiltrated with 2% lignocaine (20 mg of lignocaine per cubic centimetre tissue; 2% Lignocaine⁷). Using sterile technique, 20 gauge needles were placed in parallel (0.5 cm apart) to provide uniform distribution of 5-fluorouracil at the tumour site and for a 1 cm zone in circumference around the entire surgical site. Five-fluorouracil was administered at 50 mg/cm³ with proper handling and disposal according to occupational safety and health administration guidelines. Two pairs of gloves, protective eyewear and a gown was worn by the clinician administering the 5-fluorouracil to minimise skin and eye exposure. Luer locking syringes were used to minimise leakage of the chemotherapeutic agent and all needles were preplaced prior to injection to avoid overlapping needle tracts and to minimise leakage from the injection sites. Sterile swabs were placed over the injection sites to absorb any excess external 5-fluorouracil. After administration, all syringes, capped needles, swabs, protective clothing and remaining 5-fluorouracil were placed in a chemotherapeutic disposal bag.

The progress of the surgical site was assessed at 2, 5 and 26 weeks post-operatively and photographic records obtained (Figs 4-6).

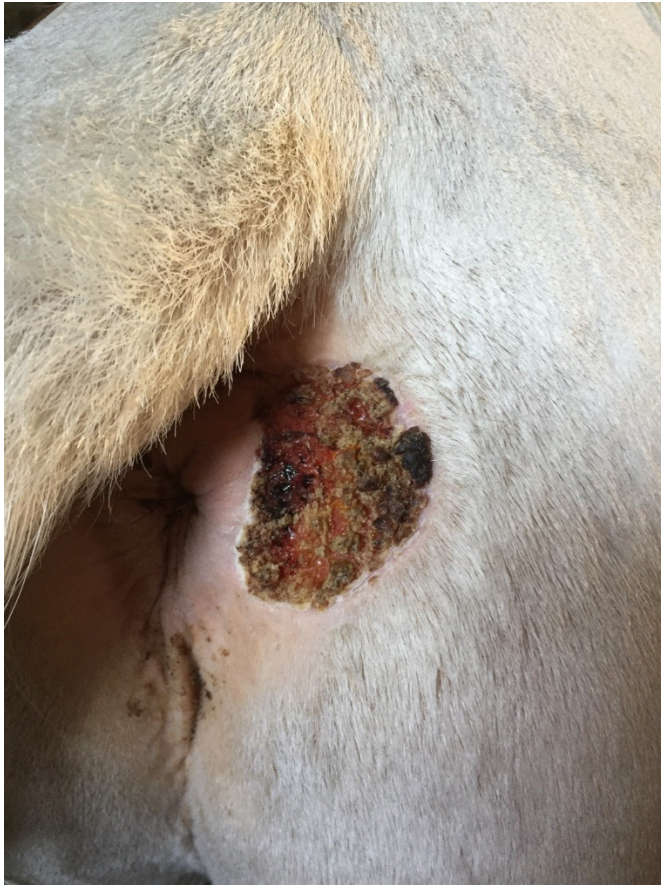

Figure 4. The surgical site at 2 weeks post-operatively.

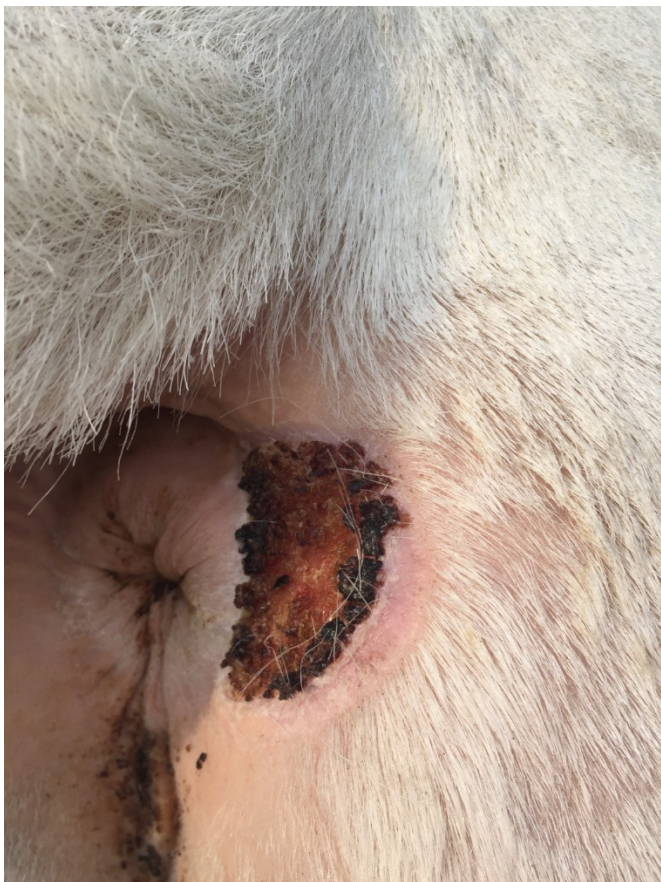

Figure 5. The surgical site at 5 weeks post-operatively.

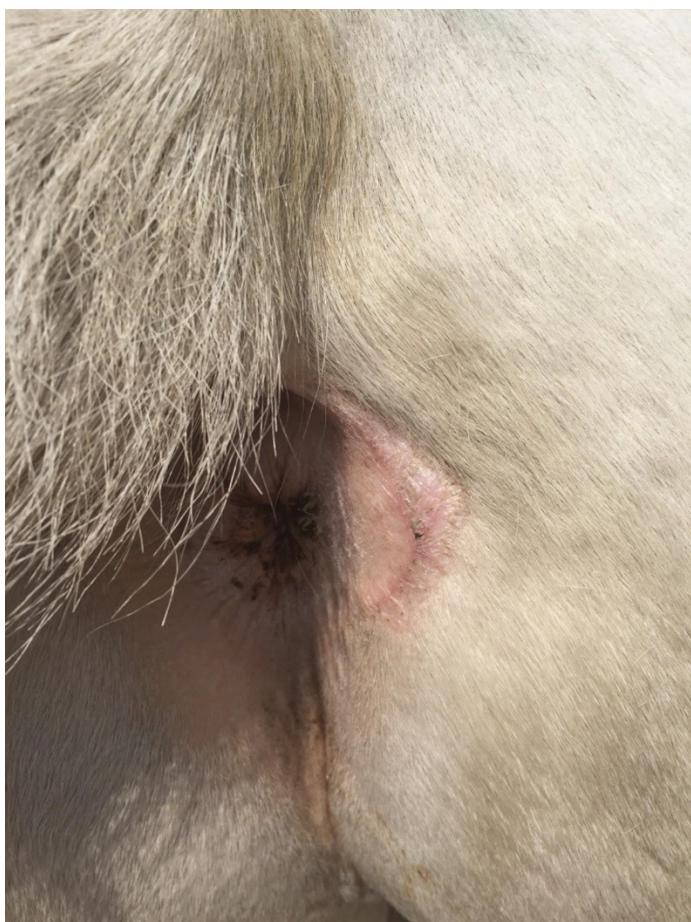

Figure 6. The surgical site at 26 weeks (6 months) post-operatively.

At re-examination 26 weeks post-surgery the pony was clinically healthy with no visible lesions of the anus and perianal region (Fig 6). The owner reported that the horse had not had difficulty defecating, had appeared normal in the post-operative period and had not shown weight loss.

Histopathological examination

Histological examination was performed on routinely prepared, labelled sections of surgical edges and the centre of the excised mass, stained with haematoxylin and eosin, using light microscopy. Central and some margin sections revealed invading cords of neoplastic epithelial cells with large nuclei and finely granular chromatin. Abnormal keratinisation and keratin pearl formation were present within the invading cords (Fig 7). There was an associated perivascular reaction consisting mainly of lymphocytes and plasma cells with a scattering of eosinophils. Overlying necrosis and ulceration were evident in some sections and had elicited an inflammatory reaction zone of degenerated leucocytes (neutrophils and macrophages) at the necrotic edge where there were scattered bacterial colonies. Adjacent skin showed carcinoma in situ featuring epidermal hyperplasia, acanthosis, variable basal cell atypia, dyskeratosis and superficial dermal fibrosis (Fig 7). Characteristics that differentiated this lesion from granulation tissue, papilloma, sarcoids and other neoplasms included the histological features of adjacent skin carcinoma in situ, central infiltrative basaloid-type pleomorphic to anaplastic epithelial cells (Fig 8) with abnormal mitotic figures and overlying ulceration.

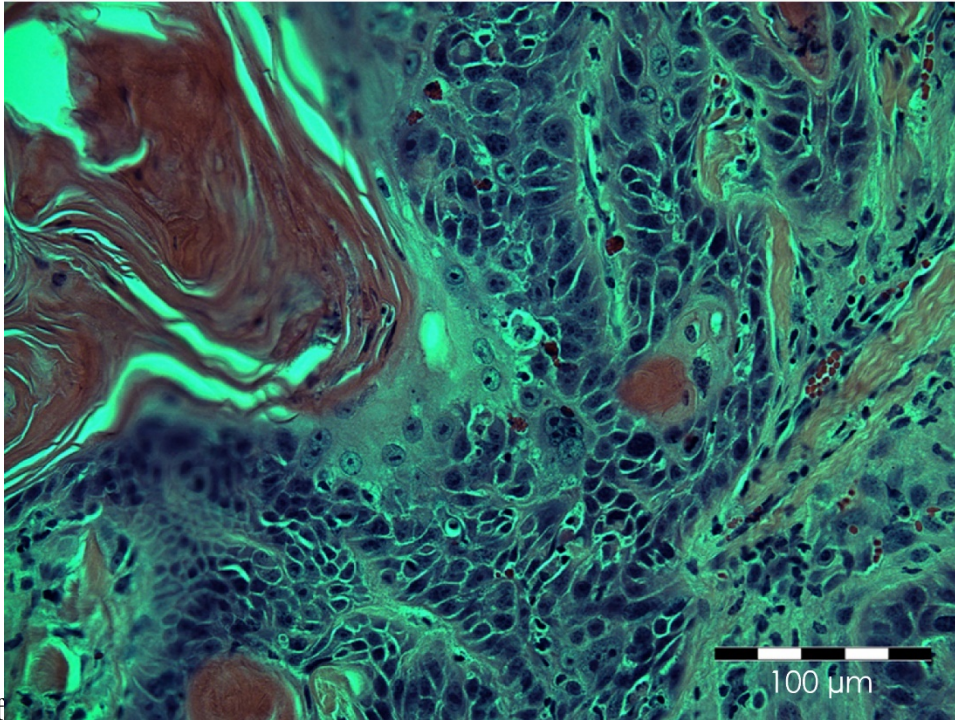


Figure 7. Infiltrating SCC with keratin pearl (upper left of image), basal cell atypia and pleomorphism (Haematoxylin and eosin; magnification 400×).

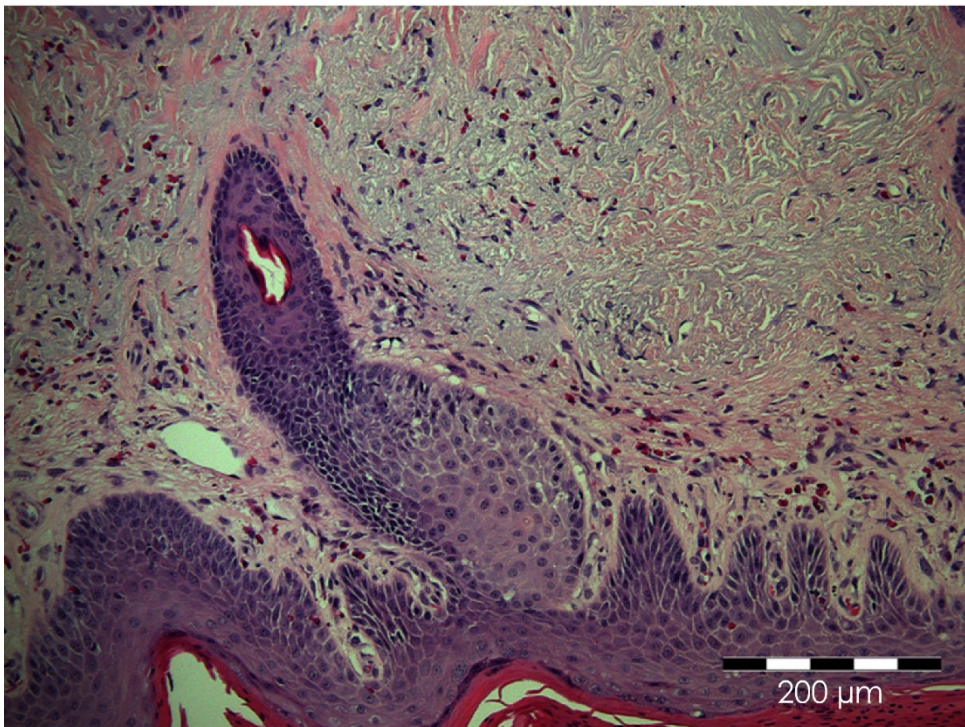


Figure 8. Carcinoma in situ at one of the surgical margins of the excised squamous cell carcinoma (H&E; magnification ×200).

A diagnosis of squamous cell carcinoma was made with incomplete resection at the medial, ventral and dorsal margins.

Discussion

Squamous cell carcinomas are malignant neoplasms of epithelial origin commonly arising in skin or in organs with stratified epithelium (Garma-Avina 1994; Perrier *et al.* 2010; Gibbons *et al.* 2015). Following equine sarcoid, SCC is the second most common tumour type found in the horse (Scott and Miller 2003) and the most common malignant skin tumour of horses (Sykora and Brandt 2017).

Squamous cell carcinomas commonly occur at the eyelids and external genitalia with only rare reports as primary tumours in other locations (Perrier *et al.* 2010). The location of SCC in this case in the perianal region is extremely unusual with few previous reports (Wilson 1994; Arnold *et al.* 2018). The difficulty in treating squamous cell carcinomas of the perianal region has been reported, with proximity to the anus and difficulties in performing complete excision emphasised (Arnold *et al.* 2018). Alternative treatment with immunotherapy and permanent colostomy have been advocated instead of surgical resection (Wilson 1994; Arnold *et al.* 2018).

Squamous cell carcinoma is common in older horses, as in this case (Howarth *et al.* 1991; Mair *et al.* 2000; Van den Top *et al.* 2008; Knowles *et al.* 2016), with the mean age of horses with vulva, perianal and anal skin SCCs reported as 19 years (Valentine 2006).

The aetiology of squamous cell carcinoma has been shown to be multi-factorial with genetics of skin pigmentation, ultraviolet light exposure, trauma, chronic irritation, smegma, *Equus caballus* papilloma virus 2 (EcPV-2) infection and age implicated (Wilson 1994; Elce 2009; Reid 2009; Sykora and Brandt 2017). There were several possible aetiological factors in the current case, with ultraviolet light exposure of the unpigmented skin at the site being the main suspected causative factor although the age and the American Paint breed of the gelding may also have been contributing factors (Valentine 2006; Schaffer *et al.* 2013). Unfortunately we did not have access to testing of tumour tissue by either PCR or in situ hybridisation for viral DNA of EcPV2, nor antibody for immunohistochemistry for PV. One anal SCC which was tested for DNA was positive for EcPV2 in another study (Bogaert *et al.* 2012).

The time before referral by the owner, 12 months, was longer than that in the majority of case reports (Scheck 2005; Tornago *et al.* 2017). Interestingly, however, the two other reports of perianal squamous cell carcinoma had been identified for 12 months and 3 years, respectively, before referral (Wilson 1994; Arnold *et al.* 2018). The time delay in the current case was due to lack of owner recognition of the lesion as being possibly neoplastic, despite the age of the pony. The under-recognition by owners of neoplastic disease in older horses, has been previously identified and reported (Ireland *et al.* 2012). Despite the delay between tumour occurrence and recognition, there was no evidence of metastasis and SCCs have been reported to show slowly progressive development (Howarth *et al.* 1991; Head *et al.* 2002).

The histopathological diagnosis in this case was consistent with the clinical presentation and surgical findings. However, whilst the lack of a clean resection margin at the medial aspect of the surgical site was anticipated, the lack of resection margins at the ventral and dorsal aspects of the incision site did not correlate with the surgical findings.

Various treatments of cutaneous SCC have been described, with surgical excision, cryotherapy with or without excision, hyperthermia, laser ablation, radiotherapy, immunotherapy, chemotherapy and electrochemotherapy reported (Strafuss 1976;

MacFadden and Pace 1991; Burney *et al.* 1992; Théon *et al.* 1993; McCauley *et al.* 2002; Arnold *et al.* 2018; Spugnini *et al.* 2017). In future, preventative immunisation against PV-related SCCs may become feasible in horses, as is practiced in humans (Sykora and Brandt 2017).

Surgical excision of squamous cell carcinoma has been recommended at easily accessible sites (Johnson 1998; Dietz 2006). However, in cutaneous locations that are difficult to access, surgical excision alone often does not provide satisfactory results (Hewes and Sullins 2006; Arnold *et al.* 2018). Tumour recurrence after incomplete tumour removal is a common complication (Théon *et al.* 1994). Treatment failure has also been shown to alter the biological behaviour of some tumours resulting in more aggressive growth and an increased potential for local extension or metastasis following recurrence (Gunduz *et al.* 1979; Théon *et al.* 1994). In view of the location of the tumour in this case, surgical excision alone was not felt to be justified.

Laser excision has been widely reported in the treatment of cutaneous neoplasia in horses (Carstanjen *et al.* 1997; Martens *et al.* 2001; McCauley *et al.* 2002; Mair and Fews 2016). Advantages of this therapeutic modality include reduced damage to the surrounding tissue as laser light is associated with minimal transmission of heat, and therefore little latent thermal necrosis (Palmer 1989, 1990, 1996; Leffell and Thompson 1992; Carstanjen *et al.* 1997; McCauley *et al.* 2002). Additionally, coagulation of small blood vessels, lymphatic vessels and nerves by the laser results in reduced intra-operative haemorrhage, post-operative oedema and pain (Palmer 1989, 1990, 1996; Leffell and Thompson 1992; McCauley *et al.* 2002). These specific advantages were clearly evident in this case.

A further advantage of laser excision is the reduced spread of malignant cells to surrounding tissue when compared with conventional surgery (Carstanjen *et al.* 1997; McCauley *et al.* 2002). It was felt that this property of laser excision was particularly important for excision of the medial border of the tumour in this case as obtaining a tumour-free resection margin was not possible.

Chemotherapeutic treatment has been described as a suitable method to treat neoplasms in horses (Théon *et al.* 1993, 1994; Fortier and Mac Harg 1994; Paterson 1997). Intralesional administration of various chemotherapeutic agents has been reported as an adjunct or alternative to excision of cutaneous neoplasia in horses (Théon *et al.* 1993, 1994) and was used in this case in conjunction with laser application on the medial margin where a tumour-free resection margin was not possible. Electrochemotherapy has been reported to have been used successfully in a squamous cell carcinoma of an equine foot that was difficult to access and has been recommended when incomplete excision of tumours in horses is not possible (Spugnini *et al.* 2017). Electrochemotherapy was considered in this case but was not utilised due to lack of availability of a clinical electroporator.

The benefits of intralesional administration of chemotherapeutic agents include minimising adverse systemic effects while providing exposure of tumour cells to high concentrations of the agent (Hewes and Sullins 2006).

Intralesional administration of cisplatin and 5-fluorouracil has been commonly used for treatment of cutaneous tumours in horses and found to be effective against a variety of solid tumours (Loehrer and Einhorn 1984; Théon *et al.* 1993, 1994, 1997, 1999; Stewart *et al.*

2006). Reported protocols include multiple treatments, for instance, four treatments administered at 2 week intervals (Théon *et al.* 1993), which was adopted in this case.

Difficulties associated with intralesional injection of cisplatin include leakage of the cisplatin solution following injection, unpredictability in the stability and consistency of the solution and risk of accidental injection of the veterinarian performing the injection (Hewes and Sullins 2006). None of these difficulties were encountered in this case. The concerns regarding stability of the cisplatin solution were raised by authors using cisplatin in an oil emulsion whilst we used undiluted cisplatin (P&U Cisplatin⁹). The risks of self-injection were judged to be low in this case as the pony had an excellent temperament and was restrained both physically and chemically during each administration. The first injection was performed under epidural anaesthesia and subsequent injections were performed using standing sedation. Epidural anaesthesia has been widely utilised in surgical conditions of the equine perineum (LeBlanc and Caron 1990; DeRossi *et al.* 2004; Climent *et al.* 2009). The placement and use of an epidural catheter in this case was an important component of both the anaesthetic and analgesic components in the intra- and post-operative periods, respectively.

Complications associated with intralesional cisplatin have included tissue oedema, erythema and crusting (Théon *et al.* 2007). None of these complications occurred in this case.

To avoid the potential complications with intralesional injection of cisplatin, various slow release delivery systems have been implanted at tumour sites (Ike *et al.* 1992; Suzuki *et al.* 1995; Ehrhart *et al.* 1999; Lana *et al.* 2004; Marr *et al.* 2004; Withrow *et al.* 2004). Biodegradable cisplatin-containing beads have been shown to be an effective treatment with or without tumour debulking for cutaneous neoplasms in horses (Hewes and Sullins 2006). Such a slow release system could have been utilised in this case if the temperament of the horse had been challenging or difficulties in administration had been encountered.

The decision to use 5-fluorouracil in the post-operative period was made as it is inexpensive, has relatively few adverse effects and can provide beneficial macroscopic cytoreduction (Pucket and Gilmour 2014). It is an alternative to other intralesional chemotherapy drugs and does not require specialised preparation or equipment to deliver (Pucket and Gilmour 2014). The use of intralesional 5-fluorouracil has been described for treatment of dermatological neoplasia in human patients (Kraus *et al.* 1998; Longley *et al.* 2003; Good *et al.* 2010; Kirby and Miller 2010).

Other potential therapeutic treatment options for this case were radiotherapy and immunotherapy. Radiotherapy as a treatment for equine tumours, has been previously reported (Frauenfelder *et al.* 1982a, b; Wyn-Jones 1983; Byam-Cook *et al.* 2006; Montgomery 2014; Hollis 2019) but is infrequently used due to the necessity for special equipment and concerns regarding management of patients receiving radiotherapy (Van Den Top *et al.* 2010; Hollis 2019). This technique was not available for the current case and would have been cost-prohibitive. Immunotherapy has successfully treated cutaneous neoplasms in horses (Lavach *et al.* 1985; Vanselow *et al.* 1988) with autologous dendritic cells reportedly used for perianal SCC (Arnold *et al.* 2018). Immunotherapeutic techniques would be of benefit to cases similar to the current horse with advantages of safe administration and reduced side effects compared with chemotherapeutic agents (Arnold *et al.* 2018).

Clinical relevance

To our knowledge, there are no previous reports of a combined treatment approach to perianal squamous cell carcinoma in the horse. Squamous cell carcinoma should be considered in the differential diagnosis of perianal lesions in horses. A combined treatment approach with surgical excision using conventional surgical technique and laser excision with intralesional chemotherapy enabled a full resolution of the squamous cell carcinoma in this case report and is recommended in the treatment of perianal carcinomas in horses where complete excision is difficult or not possible.

Authors' declaration of interests

No conflicts of interest have been declared.

Ethical animal research

No ethical review was required as this is a case study. The owners of the mare described in the present case gave their consent for publication.

Source of funding

None.

Antimicrobial stewardship policy

The mare in this case report did not receive quinolones, extended spectrum beta lactam antimicrobials or macrolides.

Acknowledgements

The authors thank Professor Gareth Zeiler from the Department of Anaesthesia, University of Pretoria for assistance with the sedation and analgesia protocols in this case.

Authorship

L. Poore and Y. Smit were responsible for the surgical aspects of this case and post-operative management. N. Duncan and J. Williams were responsible for the pathological assessment and production of the images. All authors gave their final approval of the manuscript.

Manufacturers' addresses

¹MILA International, Florence, Kentucky, USA.

²Fresinus Kabi, Midrand, South Africa.

³Virbac, Centurion, South Africa.

⁴MSD Animal Health, Kempton Park, South Africa.

- ⁵Pfizer Animal Health, Sandton, South Africa.
- ⁶Fort Dodge Animal Health, Midrand, South Africa.
- ⁷Bayer, Isando, South Africa.
- ⁸Diodevet, Newark, Delaware, USA.
- ⁹Pfizer Laboratories, Sandton, South Africa.
- ¹⁰Teva Pharmaceuticals, Roodeport, South Africa.

References

- Arnold, C., Dreher, I., Grammel, T. and Schusser, G.F. (2018) Immunotherapy of a squamous cell carcinoma in the perianal region using autologous dendritic cells in a horse. *Equine Vet. Educ.* 30, 576- 582.
- Baker, J.R. and Leyland, A. (1975) Histological survey of tumours of the horse, with particular reference to those of the skin. *Vet. Rec.* 197, 419- 422.
- Bogaert, L., Willemsen, A., Vanderstraeten, E., Bracho, M.A., De Baere, C., Bravo, I.G. and Martins, A. (2012) EcPV2 DNA in equine genital squamous cell carcinomas and normal genital mucosa. *Vet. Microbiol.* 158, 33- 41.
- Burney, D.P., Theisen, S.K. and Schmitz, D.G. (1992) Identifying and treating squamous cell carcinoma of horses. *Vet. Med.* 87, 588.
- Byam-Cook, K.L., Henson, F.M. and Slater, J.D. (2006) Treatment of periocular and non-ocular sarcoids in 18 horses by interstitial brachytherapy with iridium-192. *Vet. Rec.* 159, 337- 341.
- Carstanjen, B., Jordan, P. and Lepage, O.M. (1997) Carbon dioxide laser as a surgical instrument for sarcoid therapy-a retrospective study on 60 cases. *Can. Vet. J.* 38, 773- 776.
- Climent, F., Ribera, T., Argüelles, D., Nomen, C. and Prades, M. (2009) Modified technique for the repair of third-degree rectovaginal lacerations in mares. *Vet. Rec.* 164, 393- 396.
- DeRossi, R., Sampaio, B.F.B., Varela, J.V. and Junqueira, A.L. (2004) Perineal analgesia and hemodynamic effects of the epidural administration of meperidine or hyperbaric bupivacaine in conscious horses. *Can. Vet. J.* 45, 42- 47.
- Dietz, O. (2006) Verhornungssforungen, Hauthombildung und Tumoren. In: Handbuch Pferdepraxis, 3rd edn., Eds: O. Dietz, B. Huskamp, Enke, Stuttgart, pp 220- 221.
- Ehrhart, N., Dernell, W.S., Ehrhart, E.J., Hutchison, J.M., Duple, E.B., Brekke, J.H., Straw, R.C. and Withrow, S.J. (1999) Effects of a controlled-release cisplatin delivery system used after resection of mammary carcinoma in mice. *Am. J. Vet. Res.* 60, 1347- 1351.

- Elce, Y.A. (2009) The aetiopathogenesis of squamous cell carcinoma in horses. Where are we? *Equine Vet. Educ.* 21, 17- 18.
- Fortier, L.A. and Mac Harg, M.A. (1994) Topical use of 5-fluorouracil for treatment of squamous cell carcinoma of the external genitalia of horses: 11 cases (1988-1992). *J. Am. Vet. Med. Assoc.* 205, 1183- 1185.
- Frauenfelder, H.C., Blevins, W.E. and Page, E.H. (1982a) ^{90}Sr for treatment of periocular squamous cell carcinoma in the horse. *J. Am. Vet. Med. Assoc.* 180, 307- 309.
- Frauenfelder, H.C., Blevins, W.E. and Page, E.H. (1982b) ^{222}Rn for treatment of periocular fibrous connective tissue sarcoma in the horse. *J. Am. Vet. Med. Assoc.* 180, 310- 312.
- Garma-Avina, A. (1994) The cytology of squamous cell carcinomas in domestic animals. *J. Vet. Diagn. Invest.* 6, 238- 246.
- Gibbons, P.M., Lamb, L. and Mansell, J. (2015) Presentation, treatment, and outcome of squamous cell carcinoma in the perineal region of 9 goats. *Can. Vet. J.* 56, 1043- 1047.
- Good, L.M., Miller, M.D. and High, W.A. (2010) Intralesional agents in the management of cutaneous malignancy: a review. *J. Am. Acad. Dermatol.* 64, 413- 422.
- Gunduz, N., Fisher, B. and Saffer, E.A. (1979) Effect of surgical removal on the growth and kinetics of residual tumor. *Cancer Res.* 39, 3861- 3865.
- Head, K.W., Else, R.W. and Dubielzig, R.R. (2002) Tumours of the alimentary tract. In: *Tumours in Domestic Animals*, 4th edn., Ed: D.J. Meuten. Iowa State Press, Ames, IA, pp 401- 481.
- Hewes, C.A. and Sullins, K.E. (2006) Use of cisplatin-containing biodegradable beads for treatment of cutaneous neoplasia in equidae: 59 cases (2000-2004). *J. Am. Vet. Med. Assoc.* 229, 1617- 1622.
- Hollis, A.R. (2019) Radiotherapy for the treatment of periocular tumours in the horse. *Equine Vet. Educ.* 31, 647- 652.
- Howarth, S., Lucke, V.M. and Pearson, H. (1991) Squamous cell carcinoma of the equine external genitalia: a review and assessment of penile amputation and urethrostomy as a surgical treatment. *Equine Vet. J.* 23, 53- 58.
- Ike, O., Shimizu, Y., Wada, R., Hyon, S.H. and Ikada, Y. (1992) Controlled cisplatin delivery system using poly (D, L-lactic acid). *Biomaterials* 13, 230- 234.
- Ireland, J.L., Clegg, P.D., McGowan, C.M., McKane, S.A., Chandler, K.J. and Pinchbeck, G.L. (2012) Comparison of owner-reported health problems with veterinary assessment of geriatric horses in the United Kingdom. *Equine Vet. J.* 44, 94- 100.
- Johnson, P.J. (1998) Dermatologic tumours. *Vet. Clin. N. Am.: Equine Pract.* 14, 643- 650.

- Kirby, J.S. and Miller, C.J. (2010) Intralesional chemotherapy for non-melanoma skin cancer: a practical review. *J. Am. Acad. Dermatol.* 63, 689- 702.
- Knowles, E.J., Tremaine, W.H., Pearson, G.R. and Mair, T.S. (2016) A database survey of equine tumours in the United Kingdom. *Equine Vet. J.* 48, 280- 284.
- Kraus, S., Miller, B.H., Swinehart, J.M., Shavin, J.S., Georgouras, K.E., Jenner, D.A., Griffin, E., Korey, A. and Orenberg, E.K. (1998) Intratumoral chemotherapy with fluorouracil/epinephrine injectable gel: a nonsurgical treatment of cutaneous squamous cell carcinoma. *J. Am. Acad. Dermatol.* 38, 438- 442.
- Lana, S.E., Dernell, W.S., Lafferty, M.H., Withrow, S.J. and LaRue, S.M. (2004) Use of radiation and a slow-release cisplatin formulation for treatment of canine nasal tumors. *Vet. Radiol. Ultrasound.* 45, 577- 581.
- Lavach, J.D., Sullins, K.E., Roberts, S.M., Severin, G.A., Wheeler, C. and Lueker, D.C. (1985) BCG treatment of periocular sarcoid. *Equine Vet. J.* 17, 445- 448.
- LeBlanc, P.H. and Caron, J.P. (1990) Clinical use of epidural xylazine in the horse. *Equine Vet. J.* 22, 180- 181.
- Leffell, D.J. and Thompson, J.T. (1992) Lasers in dermatology and ophthalmology. *Dermatol. Clin.* 10, 687- 700.
- Loehrer, P.J. and Einhorn, L.H. (1984) Drugs five years later. Cisplatin. *Ann. Intern. Med.* 100, 704- 713.
- Longley, D.B., Harkin, D.P. and Johnston, P.G. (2003) 5-fluorouracil: mechanisms of action and clinical strategies. *Nat. Rev. Cancer* 3, 330- 338.
- MacFadden, K.E. and Pace, L.W. (1991) Clinical manifestations of squamous cell carcinoma in horses. *Comp. Cont. Educ. Pract. Vet.* 13, 669- 677.
- Mair, T.S. and Fewes, D. (2016) Detection of sarcoid tissue at 2 cm resection margins following CO2 laser excision. *Equine Vet. J.* 48, 20.
- Mair, T.S., Walmsley, J.P. and Phillips, T.J. (2000) Surgical treatment of 45 horses affected by squamous cell carcinoma of the penis and prepuce. *Equine Vet. J.* 32, 406- 410.
- Marr, A.K., Kurzman, I.D. and Vail, D.M. (2004) Preclinical evaluation of a liposome-encapsulated formulation of cisplatin in clinically normal dogs. *Am. J. Vet. Res.* 65, 1474- 1478.
- Martens, A., De Moor, A., Vlaminck, L., Pille, F. and Steenhaut, M. (2001) Evaluation of excision, cryosurgery and local BCG vaccination for the treatment of equine sarcoids. *Vet. Rec.* 149, 665- 669.
- McCauley, C.T., Hawkins, J.F., Adams, S.B. and Fessler, J.F. (2002) Use of a carbon dioxide laser for surgical management of cutaneous masses in horses: 32 cases (1993-2000). *J. Am. Vet. Med. Assoc.* 220, 1192- 1197.

- Montgomery, K.W. (2014) Equine ocular neoplasia: a review. *Equine Vet. Educ.* 26, 372-380.
- Newkirk, K.M., Hendrix, D.V., Anis, E.A., Rohrbach, B.W., Ehrhart, E.J., Lyons, J.A. and Kania, S.A. (2014) Detection of papillomavirus in equine periocular and penile squamous cell carcinoma. *J. Vet. Diagn. Invest.* 26, 131- 135.
- Palmer, S.E. (1989) Carbon dioxide laser removal of a verrucous sarcoid from the ear of a horse. *J. Am. Vet. Med. Assoc.* 195, 1125- 1127.
- Palmer, S.E. (1990) Clinical use of a carbon dioxide laser in equine general surgery practice. *Proc. Am. Assoc. Equine Practnrs.* 35, 319- 329.
- Palmer, S.E. (1996) Instrumentation and techniques for carbon dioxide lasers in equine general surgery. *Vet. Clin. N. Am.: Equine Pract.* 12, 397- 414.
- Paterson, S. (1997) Treatment of superficial ulcerative squamous cell carcinoma in three horses with topical 5-fluorouracil. *Vet. Rec.* 141, 626- 628.
- Perrier, M., Schwarz, T., Gonzalez, O. and Brounts, S. (2010) Squamous cell carcinoma invading the right temporomandibular joint in a Belgian mare. *Can. Vet. J.* 51, 885- 887.
- Pucket, J.D. and Gilmour, M.A. (2014) Intralesional 5-fluorouracil (5-FU) for the treatment of eyelid squamous cell carcinoma in 5 horses. *Equine Vet. Educ.* 26, 331- 335.
- Reid, N. (2009) Squamous cell carcinoma and suspect peripheral nerve sheath tumour in a 10 year old Paint horse. *Can. Vet. J.* 50, 1195- 1197.
- Schaffer, P.A., Wobeser, B., Martin, L.E., Dennis, M.M. and Duncan, C.G. (2013) Cutaneous neoplastic lesions of equids in the central United States and Canada: 3,351 biopsy specimens from 3,272 equids (2000-2010). *J. Am. Vet. Med. Assoc.* 242, 99- 104.
- Scheck, J.L. (2005) Treatment of an ocular squamous cell carcinoma in a stallion with atrial fibrillation. *Can. Vet. J.* 46, 922- 924.
- Scott, D. and Miller, W. (2003) Neoplastic and non-neoplastic tumours. In: *Equine Dermatology*, Eds: D.W. Scott, W.J. Miller, Saunders, St. Louis, MO, pp 698- 795.
- Spugnini, E., Bolaffio, C., Scacco, L. and Baldi, A. (2017) Isolated limb perfusion electrochemotherapy for the treatment of an advanced squamous cell carcinoma of the hoof in a mare. *Open Vet. J.* 7, 192- 196.
- Stewart, A.A., Rush, B. and Davis, E. (2006) The efficacy of intratumoural 5-fluorouracil for the treatment of equine sarcoids. *Aust. Vet. J.* 84, 101- 106.
- Strafuss, A.C. (1976) Squamous cell carcinoma in horses. *J. Am. Vet. Med. Assoc.* 168, 61.
- Sundberg, J.P., Burnstein, T., Page, E.H., Kirkham, W.W. and Robinson, F.R. (1977) Neoplasms of Equidae. *J. Am. Vet. Med. Assoc.* 170, 150- 152.

- Suzuki, K., Nakamura, T., Matsuura, H., Kifune, K. and Tsurutani, R. (1995) A new drug delivery system for local cancer chemotherapy using cisplatin and chitin. *Anticancer Res.* 15, 423- 426.
- Sykora, S. and Brandt, S. (2017) Papillomavirus infection and squamous cell carcinoma in horses. *Vet. J.* 223, 48- 54.
- Théon, A.P., Pascoe, J.R., Carlson, G.P. and Krag, D.N. (1993) Intratumoral chemotherapy with cisplatin in oily emulsion in horses. *J. Am. Vet. Med. Assoc.* 202, 261- 267.
- Théon, A.P., Pascoe, J.R. and Meagher, D.M. (1994) Perioperative intratumoral administration of cisplatin for treatment of cutaneous tumors in equidae. *J. Am. Vet. Med. Assoc.* 205, 1170- 1176.
- Théon, A.P., Pascoe, J.R., Madigan, J.E., Carlson, G. and Metzger, L. (1997) Comparison of intratumoral administration of cisplatin versus bleomycin for treatment of periocular squamous cell carcinomas in horses. *Am. J. Vet. Res.* 58, 431- 436.
- Théon, A.P., Pascoe, J.R., Galuppo, L.D., Fisher, P.E., Griffey, S.M. and Madigan, J.E. (1999) Comparison of perioperative versus postoperative intratumoral administration of cisplatin for treatment of cutaneous sarcoids and squamous cell carcinomas in horses. *J. Am. Vet. Med. Assoc.* 215, 1655- 1660.
- Théon, A.P., Wilson, W.D., Magdesian, K.G., Pusterla, N., Snyder, J.R. and Galuppo, L.D. (2007) Long-term outcome associated with intratumoral chemotherapy with cisplatin for cutaneous tumors in equidae: 573 cases (1995-2004). *J. Am. Vet. Med. Assoc.* 230, 1506- 1513.
- Tornago, R., Sabattini, S., De Simoi, A., Bettini, G., Furlanello, T., Baldassarre, V., Cornali, M., Mazzucato, M., Carlin, S. and Gentilini, F. (2017) Treatment of oral squamous cell carcinoma in a horse by surgical debulking followed by metronomic chemotherapy. *Equine Vet. Educ.* 29, 208- 212.
- Valentine, B.A. (2006) Survey of equine cutaneous neoplasia in the Pacific Northwest. *J. Vet. Diagn. Invest.* 18, 123- 126.
- Van den Top, J.G., de Heer, N., Klein, W.R. and Ensink, J.M. (2008) Penile and preputial tumours in the horse: a retrospective study of 114 affected horses. *Equine Vet. J.* 40, 528- 532.
- Van Den Top, J.G., Ensink, J.M., Gröne, A., Klein, W.R., Barneveld, A. and van Weeren, P.R. (2010) Penile and preputial tumours in the horse: literature review and proposal of a standardised approach. *Equine Vet. J.* 42, 746- 757.
- Vanselow, B.A., Abetz, I. and Jackson, A.R. (1988) BCG emulsion immunotherapy of equine sarcoid. *Equine Vet. J.* 20, 444- 447.
- Wilson, D.A. (1994) Management of perianal squamous cell carcinoma with permanent colostomy in a mare. *J. Am. Vet. Med. Assoc.* 205, 1430- 1431.

Withrow, S.J., Liptak, J.M., Straw, R.C., Dernell, W.S., Jameson, V.J., Powers, B.E., Johnson, J.L., Brekke, J.H. and Double, E.B. (2004) Biodegradable cisplatin polymer in limb-sparing surgery for canine osteosarcoma. *Ann. Surg. Oncol.* 11, 705- 713.

Wyn-Jones, G. (1983) Treatment of equine cutaneous neoplasia by radiotherapy using iridium 192 linear sources. *Equine Vet. J.* 15, 361- 365.