

Amputation to treat osteomyelitis of the metatarsus in two partially domesticated springboks (*Antidorcas marsupialis*)

Luke Alexander Poore^{1,*}, Katja Koeppel² and Gerhard Steenkamp¹

¹Companion Animal Clinical Studies, Faculty of Veterinary Sciences, University of Pretoria, Pretoria, South Africa

²Production Animal Clinical Studies, Faculty of Veterinary Sciences, University of Pretoria, Pretoria, South Africa

*Correspondence to Dr Luke Alexander Poore; luke.poore@up.ac.za

Abstract

Two springboks were diagnosed with chronic osteomyelitis of the metatarsus of the left hindlimb. The springboks had both suffered open fractures of the metatarsus of the left hindlimb 12 weeks and one week prior to presentation. External coaptation had initially been used to give stability and encourage fracture healing. This had proved unsuccessful in both cases and an infection and osteomyelitis had developed at the fracture sites. Two amputations had been subsequently performed in case 1 but had failed to resolve infection of the skin and subcutaneous tissues. An osteomyelitis of the underlying metatarsus had developed. No treatment apart from external coaptation had been performed before referral in case 2. Surgical amputation of the metatarsus and tarsus was performed as salvage procedures in both cases. The springboks adjusted to the loss of the left tarsus and metatarsus with no orthopaedic disorders at re-examinations 12 months after surgery.

Background

Reports of appendicular skeleton fractures in small antelopes are unusual in the veterinary literature.^{1–6} There are no previous reports of fracture fixation or amputation to treat fractures of the appendicular skeleton in springboks.

Case presentation

Case 1

A three-year-old female springbok, kept as a partially domesticated animal, was presented to the Onderstepoort Veterinary Academic Hospital (OVAH) for evaluation of a chronic non-healing amputation site at the left metatarsus region of approximately 12 weeks' duration. The owners had reported that the springbok had been rejected by its mother at birth and had subsequently been hand-reared on their farm becoming partially domesticated in the process. An open comminuted fracture of the left metatarsus had occurred 12 weeks prior to presentation after a male springbok had kicked her. Attempts to stabilise the fracture by external coaptation had failed. A fracture site infection had subsequently developed and two attempts to resolve the infection by amputation at the level of the mid-metatarsus had failed.

Clinical examination at presentation revealed the springbok to have normal clinical parameters and mentation although to be mildly agitated. Palpation of the amputation site at the left metatarsus revealed a malodorous proximal mid-metatarsus with purulent discharge and necrosis of the skin and subcutaneous tissues evident. The temperature of the skin and subcutaneous tissues at the amputation site was cold. The limb distal to the proximal mid-metatarsus was absent, consistent

with the history of previous amputations. No other abnormalities were evident on a general physical examination.

An osteomyelitis of the left metatarsus and infection of the skin and subcutaneous tissues was suspected and a decision to perform a radiographic evaluation of the left metatarsus region under general anaesthesia was made.

Case 2

A two-week-old female springbok, kept as a partially domesticated animal, was presented to the OVAH for evaluation of a fracture of the left metatarsus region. The springbok was kept on a small farm of approximately 7 ha with 10 other springboks and five Burchell's zebras (*Equus quagga burchelli*). One of the zebras had kicked the springbok resulting in the fracture approximately seven days prior to presentation. An open comminuted fracture had been suspected and stabilisation of the fracture using external coaptation had been attempted. An infection of the skin and subcutaneous tissues surrounding the fracture site had subsequently developed.

Clinical examination at presentation revealed the springbok to have normal clinical parameters and mentation. Palpation of the left metatarsus revealed a complete open mid-metatarsus fracture to be present. A significant malodour was associated with the fracture site and both purulent discharge and necrosis of the skin and subcutaneous tissues were evident (figure 1). No other abnormalities were evident on a general physical examination. An osteomyelitis of the left metatarsus and infection of the skin and subcutaneous tissues was suspected and a decision to perform a radiographic evaluation of the left metatarsus region under general anaesthesia was made.

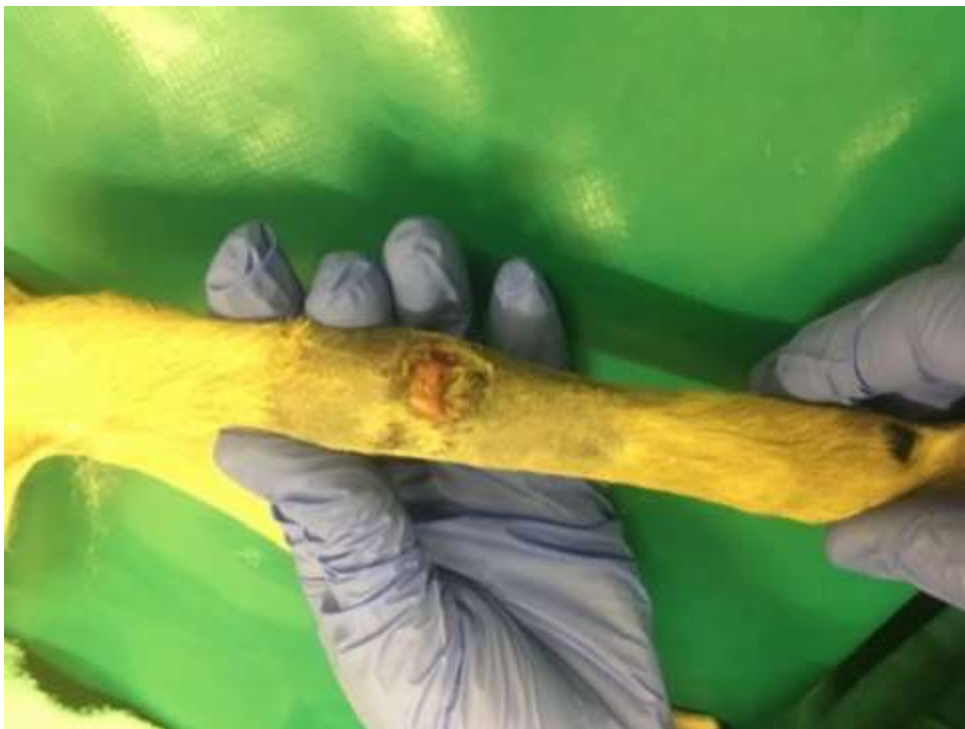

Figure 1. The left metatarsus of the springbok in case 2 at presentation. The open comminuted fracture of the mid-metatarsus is evident. Extensive soft tissue swelling and necrotic subcutaneous tissue are visible.

Investigations

Case 1

An intravenous catheter was aseptically placed in the left jugular vein and the springbok was sedated with 0.05 mg/kg bodyweight (bwt) intravenous medetomidine hydrochloride (Domitor, Zoetis, Sandton, South Africa) and 7.5 mg/kg bwt intravenous ketamine hydrochloride (Ketamine, Fresenius Kabi, Midrand, South Africa). General anaesthesia was induced using 1 mg/kg bwt intravenous propofol (Propofol, Fresenius Kabi) and 0.3 mg/kg bwt intravenous diazepam (Valium, Roche, Sandton, South Africa) after which the springbok was intubated and transferred to the imaging suite. Anaesthesia was subsequently maintained with 15 mg/kg bwt 3 per cent isoflurane (Isofor, Safeline Pharmaceuticals, Roodepoort, South Africa).

The radiographic evaluation ([figures 2 and 3](#)) revealed structural changes of the remaining left metatarsus consistent with osteomyelitis. These included areas of bone resorption with regions of radiolucency in the medulla of the proximal mid-metatarsus. A radiographic evaluation of the right metatarsus was also performed to allow for comparative measurements to be obtained and production of a prosthesis if required in the future.

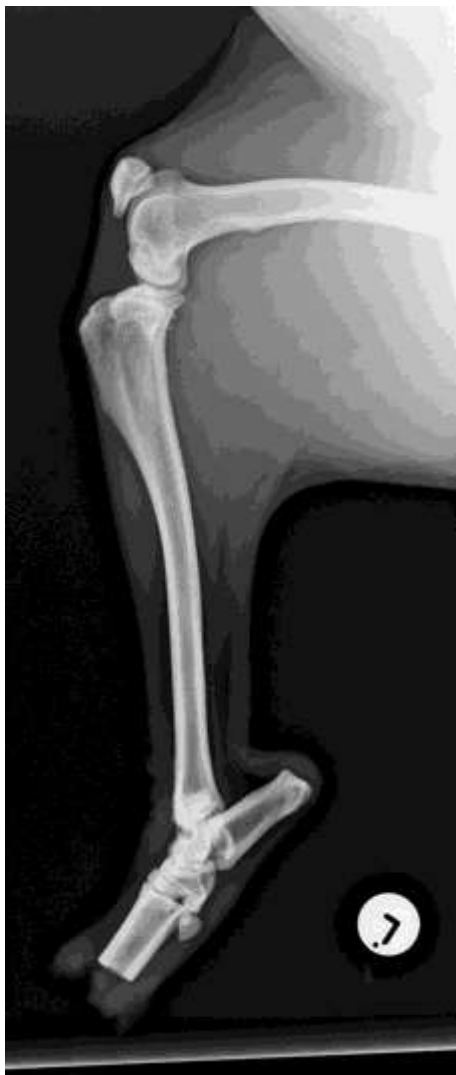

Figure 2. A lateromedial radiograph of the left tarsus and previous amputation site at the left metatarsus of case 1. Lysis of the medullary cavity of the metatarsus is evident consistent with osteomyelitis.

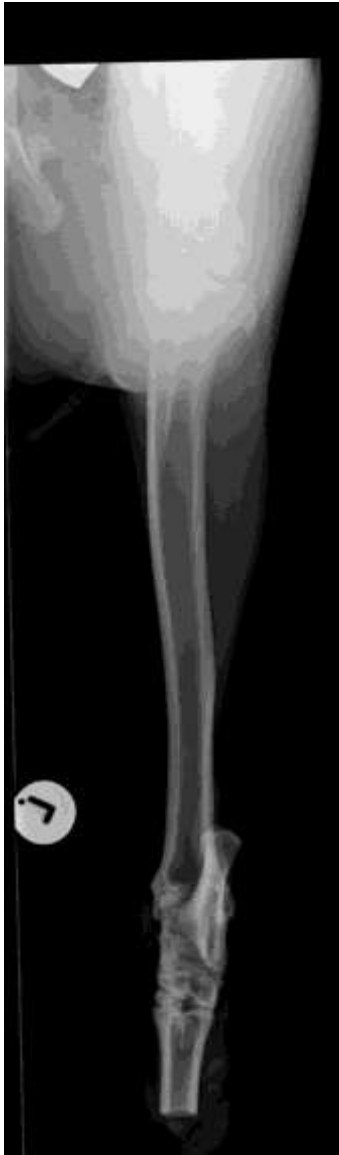

Figure 3. A dorsoplantar radiograph of the left tarsus and previous amputation site at the left metatarsus of case 1. Lysis of the medullary cavity and sclerosis of the remaining metatarsus are evident, consistent with osteomyelitis.

A provisional diagnosis of osteomyelitis of the proximal mid-left metatarsus was made and surgical excision via amputation at the level of the tibiotarsal joint under a general anaesthesia protocol was subsequently decided upon. This amputation site was selected to allow for the placement of a prosthesis which was planned as a second surgical procedure.

Case 2

An intravenous catheter was aseptically placed in the left jugular vein and general anaesthesia was induced using 7.5 mg/kg bwt intravenous ketamine hydrochloride (Ketamine; Fresenius Kabi) and 1.5 mg/kg bwt intravenous midazolam (Midazolam; Wildlife Pharmaceuticals, White River, South Africa). This anaesthesia regime was selected due to the very young age of the animal, which made it more tractable and easier to handle than the animal in case 1.

Intubation was performed and anaesthesia was maintained with 15 mg/kg bwt 2 per cent isoflurane (Isofor, Safeline Pharmaceuticals). The springbok was transferred to the imaging suite.

The radiographic examination (figure 4) revealed a comminuted mid-metatarsus fracture with significant craniomedial displacement of the distal limb. There was evidence of osteomyelitis of the mid to proximal metatarsus with areas of bone resorption and regions of radiolucency in the medulla of the metatarsus. Significant soft tissue swelling was evident at the fracture site.

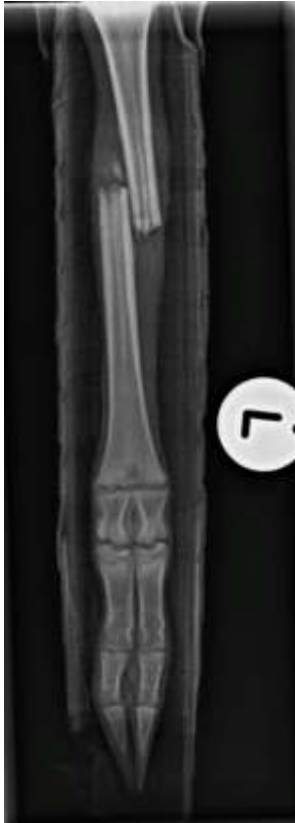

Figure 4. A dorsoplantar radiograph of the left metatarsus at time of presentation in case 2. Soft tissue swelling and osteomyelitis of the proximal metatarsus are evident.

Due to a poor prognosis for fracture fixation, a decision to perform amputation at the level of the tibiotarsal joint was made. The amputation site was selected to allow for the placement of a prosthesis at a later date as in case 1.

Treatment

Case 1

The general anaesthesia protocol was continued and the springbok moved to the operating room. Preoperative medication included 10 mg/kg bwt subcutaneous amoxicillin clavulanic acid (Augmentin, GlaxoSmithKline, Johannesburg, South Africa) and 0.6 mg/kg bwt subcutaneous meloxicam (Metacam, Boehringer Ingelheim, Randburg, South Africa). A tibial nerve block was performed using 0.13 mg/kg bwt ropivacaine hydrochloride (Naropin, AstraZeneca, Sandton, South Africa) and 0.1 mg/kg bwt intramuscular morphine sulphate (Morphine, Akacia Health Care, Kempton Park, South Africa) was administered as a further component of the analgesic regime. After

routine draping and skin preparation, a circumferential incision was made at the distal aspect of the tibia. The gastrocnemius and superficial digital tendons were transected and disarticulation of the tibiotarsal joint was performed with sharp dissection. The tarsus and proximal aspect of the metatarsus were amputated and a skin flap created. The gastrocnemius and superficial digital tendons were sutured to the subcutaneous tissue on the cranial aspect of the tibia using polyglactin 910 (Vicryl, Ethicon, Cincinnati, USA) in a simple interrupted suture pattern. The subcutaneous tissue and skin were then closed in two layers. The subcutaneous tissues were closed using polyglactin 910 (Vicryl, Ethicon) in a combination of simple and horizontal mattress suture patterns. The skin was closed using polypropylene (Ethilon, Ethicon) in a simple interrupted suture pattern as previously described.⁷ A radiographic evaluation was performed at the completion of the surgical procedure (figure 5). A modified Robert Jones dressing was placed at the amputation site and the springbok discharged. The owners were requested to maintain the dressing at the amputation site and to have the skin sutures removed 12 days postoperatively. Postoperative medication included 10 mg/kg bwt subcutaneous amoxicillin clavulanic acid (Synulox, Pfizer, Sandton, South Africa) once daily and 0.6 mg/kg bwt subcutaneous meloxicam (Metacam, Ingelheim Pharmaceuticals, Randburg, South Africa) once daily for a 72-hour period.

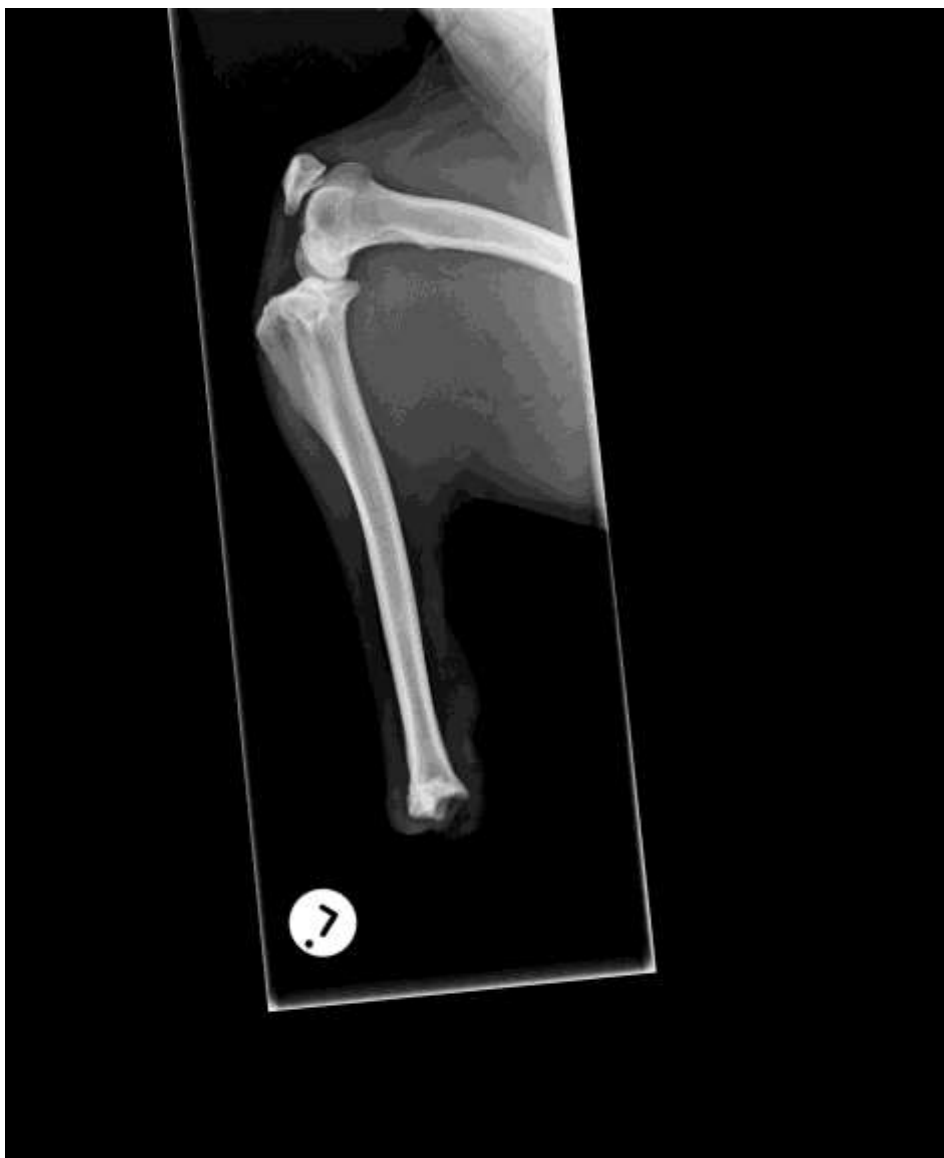

Figure 5. A lateromedial radiograph of the left tibia after amputation at the level of the tibiotarsal joint in case 1.

The surgical site healed uneventfully and the skin sutures were removed as requested 12 days postoperatively.

Case 2

The surgical approach and technique was the same as in case 1 (figure 6). Postoperative care included 2.5 mg/kg bwt/hour intravenous fluid therapy (Ringers Lactate; Fresenius Kabi) for a 24-hour period, 0.1 mg/kg bwt intravenous butorphanol tartrate (Butorphanol; Kyron Laboratories, Johannesburg, South Africa) once daily for a 24-hour period, 10 mg/kg bwt subcutaneous amoxicillin clavulanic acid (Synulox; Pfizer) once daily for a 72-hour period and 0.6 mg/kg bwt subcutaneous meloxicam (Metacam, Ingelheim Pharmaceuticals) once daily for a 72-hour period.

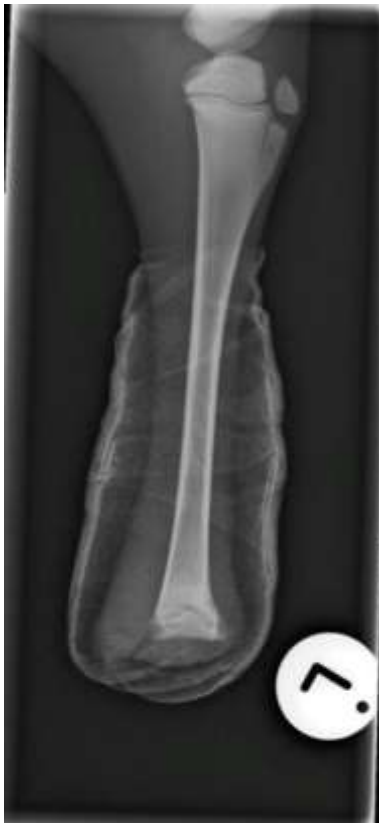

Figure 6. A lateromedial radiograph of the left tibia after amputation at the level of the tibiotarsal joint in case 2.

Outcome and follow-up

Case 1

Twelve months later, the springbok was clinically unremarkable with a normal appearance to the distal tibia, no residual swelling and no drainage (figure 7). No related orthopaedic or medical problems were identified and the quality of life as judged by the owner was good. The owner felt that amputation had not affected the comfort or sociability of the springbok. Furthermore, there was no evidence of a decrease in interaction with the owners, no deterioration in the ability of the springbok to manoeuvre, no decrease in stamina during exercise and no changes in the general attitude of the springbok after amputation. In view of the excellent progress shown by the springbok

in the postoperative period and the satisfaction of the owners with the amputation, the second surgical procedure to place the prosthesis was declined.




Figure 7. The springbok in case 1, twelve months after surgery; from (A) back and (B) side.

Case 2

Twelve months later, the springbok was clinically unremarkable with a normal appearance to the distal tibia, no residual swelling and no drainage. As in case 1, no related orthopaedic or medical issues had been identified and the quality of life as judged by the owner was good. The owner felt that amputation had not affected the comfort or sociability of the springbok. Furthermore, there was no evidence of a decrease in interaction with the owners, no deterioration in the ability of the springbok to manoeuvre, no decrease in stamina during exercise and no changes in the general attitude of the springbok after amputation. In view of the excellent progress shown by the springbok, postoperatively and the satisfaction of the owners with the amputation, the second surgical procedure to fit the prosthesis was declined as in case 1.

Discussion

Fractures of the appendicular skeleton in small antelopes have been infrequently reported in the veterinary literature.^{3 5 6 8 9} Reports of surgical treatment of springbok are especially rare.¹⁰ There are no previous reports of osteomyelitis or fractures in the springbok and no reports of either surgical amputation or detailed anaesthetic regimes. This paper reports the first confirmed cases of osteomyelitis of the metatarsus in springboks treated by surgical excision performed under general anaesthesia.

Amputation of the distal limbs in small animals has been widely reported as a common treatment for osteomyelitis and ischaemic necrosis.^{11–14}

Open fractures are the most common aetiology of adult human osteomyelitis, with the tibia often implicated.¹⁴ An open fracture of the left metatarsus was the initial clinical problem, leading to osteomyelitis, in both the springboks in this case series. The cause of both fractures in this series was trauma due to kick wounds from other animals which has not been previously reported. Fractures in springbok have however been associated with darting.¹⁵ Due to their small size and wary nature,

chemical restraint from a distance is usually required and darting is the preferred option for capture of springbok.¹⁵ Fracture fixation in both of these cases at the time of fracture may have prevented the salvage amputation subsequently performed.

Clinical signs of chronic osteomyelitis include inflammation of the soft tissues in the area and the animal is often feverish, depressed and partially anorexic.¹⁶ Other clinical signs of systemic disease are frequently lacking and haematological abnormalities are usually mild or absent.¹⁶ These findings correlated with the clinical findings in these cases where the owners reported partial anorexia and some depression but no evidence of fever or other evidence of systemic disease.

Radiographic evidence of chronic osteomyelitis includes lysis of the medullary cavity, sequestra and the development of involucrum with sclerosis and lysis becoming interspersed throughout cortical and medullary bone at the site of infection.^{16,17} The initial radiographic evaluation of the left metatarsus in both cases revealed lysis and sclerosis of the medullary cavity consistent with osteomyelitis.³

Amputation of a limb is frequently recommended in small animal veterinary medicine as a component of treatment protocols for neoplasia, traumatic injury, peripheral neuropathies, vascular compromise, infection, or disability resulting from degenerative or congenital processes.^{11–13, 18–20} Amputation was deemed to be the most appropriate surgical procedure to treat the osteomyelitis in both these springboks. Full limb amputation of a pelvic limb in dogs is normally recommended and performed by either disarticulation of the limb at the coxofemoral joint or osteotomy of the femur at the mid-diaphysis.²⁰ These amputation sites are normally selected with the aim of reducing unnecessary weight that the animal must carry and reducing the incidence of pressure sores developing.²⁰ A more distal amputation site was selected for both the springboks in this case series with amputation performed at the tibiotarsal joint level. This site was selected to allow for the placement of a prosthesis at a second surgery. Interestingly, neither springbok developed pressure sores at the amputation sites and had no complications with the weight of the amputation site. The athletic ability of springboks has been previously reported with leaps of 2 m and speeds of up to 88 km/hour recorded.²¹ It is our opinion that this athletic ability allowed the springboks in this case series to adapt well to the amputation and that the surgical site was high enough to prevent contact between the amputated limb and the ground.

Most dogs and cats adapt well and quickly after a limb amputation although having obvious gait abnormalities.^{22–25} The springboks in this series also adapted very quickly to the amputation but maintained a gait abnormality. Despite the success of adaptation in dogs, many dog owners are reluctant to pursue surgery.²⁶ The owners of the springboks in this case series were totally committed to the surgical procedure although careful counselling of the owners and their connections was performed before the springboks were referred. Additionally, the amputations were discussed as a first line of treatment, with a second surgical procedure initially planned to place a prosthesis in both cases, which may have reassured the owners of the springboks. Owner anxiety exists even though limb amputation frequently represents the safest, least demanding and most cost-effective treatment option for a variety of pathological changes affecting canine limbs.²⁵ In a survey conducted in 1999, the most common owner concerns about limb amputation included cosmetic appearance and reduced mobility after surgery.²⁴ The owners of the springboks in this case series were not concerned about the cosmetic appearance but very concerned about reduced mobility after surgery. Their concerns reduced with time postoperatively as adaptation by each springbok to the amputation developed.

Contraindications to limb amputations most commonly cited among veterinarians include extreme obesity or coexisting orthopaedic or neurologic disease.^{20, 24, 26} The animals in this case series were in

good body condition with no evidence of obesity and had no coexisting orthopaedic or neurological disorders.

Force plate analysis has shown that the loss of a limb in dogs caused significant changes in the ground reaction forces and contact times of the remaining limbs as well as in the dog's centre of gravity, with greater changes seen with thoracic limb versus pelvic limb amputation.^{7,24} These findings were explained to the owners and referring veterinarians of the springboks in this case series who monitored the remaining three limbs very carefully in the 12 months after surgery. No adverse effects became evident or were reported, although facilities for force plate analysis were not available at the OVAH or at the clinics of the referral veterinarians.

Postoperative management of antelopes is challenging with handling and dressing changes resented even in partially domesticated springbok. Additionally, there are few studies considering complications after amputation. A retrospective evaluation of 67 amputations in dogs and cats revealed a 20.9 per cent postoperative infection or inflammation wound complication rate and a 9 per cent infection rate.⁷ Age was the only significant predictor of postoperative infection or inflammation following pelvic or thoracic limb amputation when univariate analysis was performed and remained significant after multivariate logistic regression.¹³ Springboks have been reported to have a lifespan of up to 19 years in captivity²⁰ so the springboks in this case series were not regarded as aged.

Only a small number of studies have assessed predictive factors for surgical site infection or inflammation in small animal surgery. One study found predictive factors included duration of anaesthesia, duration of postoperative intensive care unit stay, wound drainage, increased bodyweight, dirty surgical site and antimicrobial prophylaxis.²⁷ Both the springboks in this case series had dirty surgical sites and relatively long anaesthesia durations to allow both diagnostic and therapeutic interventions under the same anaesthesia regime. Neither springbok was judged as overweight and no drainage was evident from either amputation site in the postoperative period. The duration of postoperative intensive care unit stay was minimised in both cases with case 1 returning home immediately after surgery and case 2 returned home three days after surgery.

Another study evaluating dogs and cats found entire males, animals with endocrinopathies and longer total surgery and anaesthesia times led to an increased risk of developing a postoperative infection.²⁸ Brown *et al*²⁹ reported that longer surgery time, and if surgical sites were clipped before anaesthesia, increased the risk of wound infection in dogs and cats. Neither springbok in this case series was male, had evidence of endocrinopathy and neither surgical site was clipped before the use of anaesthesia. Beal *et al*³⁰ reported that duration of anaesthesia was a significant risk factor for postoperative wound infection, independent of the duration of surgery in dogs and cats. An increased risk of infection and inflammation was found in the use of staples versus sutures for skin closure following cranial cruciate ligament surgery in dogs,³¹ although another study reported that closing skin with staples was associated with decreased inflammation rates.³² The skin was closed with sutures in both cases and no surgical site infections were encountered.

Anaesthesia protocols of antelopes have been poorly reported and owners or referring veterinarians are often concerned that an antelope with a fracture will not tolerate the anaesthesia necessary to allow amputation or fracture fixation. Antelopes are prone to regurgitation, especially if animals are not starved prior to anaesthesia, and intubation is recommended in procedures lasting longer than one hour.³³ Both springboks were intubated and no regurgitation was evident in either case. Salivation, vomiting and tympany are common side effects of α_2 -adrenoceptor agonists such as medetomidine and xylazine in antelopes.³⁴ These side effects are usually more pronounced in lateral recumbency. Medetomidine was used as a component of the sedation regime in case 1 and both

springboks were placed in lateral recumbency for the surgical procedures. No side effects were seen in either case.

Due to the risk of using highly potent opioids in clinical settings, animals are often anaesthetised with a combination of medetomidine, ketamine, diazepam and/or midazolam as in these cases. Intravenous fluid therapy was used as a component of the postoperative therapeutic protocol in one of the cases described due to concerns regarding the age of the patient.

Surgical amputation was used to successfully treat extensive osteomyelitis of the metatarsus in both springboks in this case series.

References

- ¹ Singh G, Mogha I, Arora B. Compound fracture of the radius and ulna in deer (*Axisaxis*) - A case report. *Indian J Vet Surg* 1982a;3:38–44.
- ² Singh J, Peshin P, Singh A. Repair of a metatarsal fracture in a Barking deer. *Haryana Vet J* 1982b;21:48–49.
- ³ Bailey J, Badtram G, Farrow C. Unusual bone healing in a white tailed deer. *Canadian Vet J* 1983;24:335–337.
- ⁴ Thiruthainathan R, Swaminathan D. Tibial fracture and its management in Samber Deer (*Axis-axis*) - A case report. *Indian J Vet Res* 1996;5:42–43.
- ⁵ Kumar A. Management of metacarpal fracture in a black buck (*Antelope cervicapra*). *Zoos Print J* 2006;21:2174.
- ⁶ Gahlod B, Akhare S, Thorat M. Tibial fracture and its surgical management using internal and external fixation in a Blackbuck. *Intas Polivet* 2012;13:466–468.
- ⁷ Raske M, McClaran JK, Mariano A. Short-term wound complications and predictive variables for complication after limb amputation in dogs and cats. *J Small Anim Pract* 2015;56:247–252.
- ⁸ Bharathidasan M, Prasad A, William B, et al. Plate-rod technique with engraftment of platelet rich plasma seeded hydroxyapatite for fracture management of tibia in a Blackbuck (*Antelope cervicapra*). *Int J Livest Res* 2015;5:90–97.
- ⁹ Reillo P, Paul R, Clubb SL. Natural metacarpus fracture remodelling in a bottle-reared mountain bongo antelope calf (*Tragelaphus eurycerus isaaci*) with presumed failure of passive transfer. *Int J App Res Vet Med* 2015;13:89–92.
- ¹⁰ Mann LN, Case JB, Heard DJ, et al. Surgical management of a cervical thymoma in a springbok (*Antidorcas marsupialis*). *Vet Quart* 2013;33:172–174.
- ¹¹ Kirpensteijn J, van den Bos R, Endenburg N. Adaptation of dogs to the amputation of a limb and their owners' satisfaction with the procedure. *Vet Rec* 1999;144:115–118.
- ¹² Drygas KA, Taylor R, Sidebotham CG, et al. Transcutaneous tibial implants: a surgical procedure for restoring ambulation after amputation of the distal aspect of the tibia in a dog. *Vet Surg* 2008;37:322–327.
- ¹³ Fitzpatrick N, Smith TJ, Pendegrass CJ, et al. Intraosseous transcutaneous amputation prosthesis (ITAP) for limb salvage in 4 dogs. *Vet Surg* 2011;40:909–925.
- ¹⁴ Parsons B, Strauss E. Surgical management of chronic osteomyelitis. *Am J Surg* 2004;188:57–66.
- ¹⁵ Kock M, Burroughs R. Stress and capture related death. In: *Chemical and physical restraint of wild animals: A training and field manual for African species*. 2nd edn. IWVS Africa, 2012: 81–88.
- ¹⁶ Hulse D, Johnson A. Other diseases of bones and joints. In: *Small animal surgery*. St Louis: Fossum Mosby, 1997: 1027–1029.
- ¹⁷ Astor D, Valdes-Martinez A, Hoelzler M. What is your diagnosis? Osteomyelitis. *J Am Vet Med Assoc* 2008;233:1849–1850.
- ¹⁸ Madewell BR, Leighton RL, Theilen GH. Amputation and doxorubicin for treatment of canine and feline osteogenic sarcoma. *Eur J Cancer* 1978;14:287–293.

- ¹⁹ Marcellin-Little D, Sellon R, Kyles A, et al. Chronic localized osteomyelitis caused by atypical infection with *Blastomyces dermatitidis* in a dog. *J Am Vet Med Assoc* 1996;209:1877–1879.
- ²⁰ Seguin B, Weigel J. Amputations. In: *Veterinary surgery: small animal*. Missouri: Tobias and Johnston Elsevier, 2012: 1029–1036.
- ²¹ Skinner JD, Chimimba CT. Springbok. In: *The mammals of the South African sub region*. Cape Town: Skinner and Chimimba Cambridge University Press, 2005: 689–693.
- ²² Withrow S, Hirsch V. 'Owner response to amputation of a pet's leg'. *Vet Med Small Animal Clin* 1979;74:334.
- ²³ Carberry C, Harvey H. Owner satisfaction with limb amputation in dogs and cats. *J Am Animal Hosp Assoc* 1987;23:227–232.
- ²⁴ Kirpensteijn J, van den Bos R, van den Brom WE, et al. Ground reaction force analysis of large breed dogs when walking after the amputation of a limb. *Vet Rec* 2000;146:155–159.
- ²⁵ Forster LM, Wathes CM, Bessant C, et al. Owners' observations of domestic cats after limb amputation. *Vet Rec* 2010;167:734–739.
- ²⁶ Dickerson VM, Coleman KD, Ogawa M, et al. Outcomes of dogs undergoing limb amputation, owner satisfaction with limb amputation procedures, and owner perceptions regarding postsurgical adaptation: 64 cases (2005–2012). *J Am Vet Med Assoc* 2015;247:786–792.
- ²⁷ Eugster S, Schawalder P, Gaschen F, et al. A prospective study of postoperative surgical site infections in dogs and cats. *Vet Surg* 2004;33:542–550.
- ²⁸ Nicholson M, Beal M, Shofer F, et al. Epidemiologic evaluation of postoperative wound infection in clean-contaminated wounds: a retrospective study of 239 dogs and cats. *Vet Surg* 2002;31:577–581.
- ²⁹ Brown D, Conzemius G, Shofer F, et al. Epidemiologic evaluation of postoperative wound infections in dogs and cats. *J Am Vet Med Assoc* 1997;210:1302–1306.
- ³⁰ Beal MW, Brown DC, Shofer FS. The effects of perioperative hypothermia and the duration of anesthesia on postoperative wound infection rate in clean wounds: a retrospective study. *Vet Surg* 2000;29:123–127.
- ³¹ Frey TN, Hoelzler MG, Scavelli TD, et al. Risk factors for surgical site infection-inflammation in dogs undergoing surgery for rupture of the cranial cruciate ligament: 902 cases (2005–2006). *J Am Vet Med Assoc* 2010;236:88–94.
- ³² Etter SW, Ragetly GR, Bennett RA, et al. Effect of using triclosan-impregnated suture for incisional closure on surgical site infection and inflammation following tibial plateau leveling osteotomy in dogs. *J Am Vet Med Assoc* 2013;242:355–358.
- ³³ Ball R. Antelope. In: *Zoo Animal and Wildlife Immobilization and Anaesthesia*. 613. Oxford: West, Heard and Caulkett Oxford, Blackwell Publishing, 2007.
- ³⁴ Wiesner H. "Anästhesie von Zoo- Und Wildtieren". *Tierärztliche Umschau* 1988;43:36–42.