

COMPUTED TOMOGRAPHIC FINDINGS IN A BLUETICK COONHOUND WITH A LONGITUDINAL THORACIC TRACHEAL TEAR

Authors:

- SUMARI C. DANCER¹
- JOHANNES VAN DER ZEE¹
- ROBERT M. KIRBERGER¹

Keywords: canine, computed tomography, pneumomediastinum, subcutaneous emphysema.

¹From the Department of Companion Animal Clinical Studies, Faculty of Veterinary Science, University of Pretoria, Private bag X04, Onderstepoort, 0110, South Africa

Address correspondence: Sumari Dancer, Department of Companion Animal Clinical Studies, Faculty of Veterinary Science, University of Pretoria, Private bag X04, Onderstepoort, 0110, South Africa Email: sumari.dancer@up.ac.za

Abstract:

A 9-year-old intact male Bluetick Coonhound presented for progressive subcutaneous emphysema of five days' duration due to a suspected tracheal tear. Cervical and thoracic computed tomography (CT) were performed after failure to identify the tracheal tear with tracheoscopy. A longitudinal tracheal tear was identified starting 4.3 cm cranial to the tracheal bifurcation and extending caudally over a distance of 3.6 cm. Severe pneumomediastinum, subcutaneous emphysema and retroperitoneal gas were also present. A follow-up CT seven days postoperatively confirmed the successful repair of the tear with partial resolution of the presurgical secondary pathology and the patient recovered uneventfully.

1. Signalment, History and Clinical Findings

A 9-year-old intact male Bluetick Coonhound presented to our Veterinary Academic Hospital after being referred for progressive subcutaneous emphysema of five days' duration due to a suspected tracheal tear. The owners reported that the dog initially appeared restless and the next day they noticed that he had developed subcutaneous emphysema. There was no known history of trauma, recent procedures that required general anesthesia and intubation or prior conditions requiring medical treatment with corticosteroids, however, the patient was a working hunting dog. Clinical evaluation revealed severe diffuse cervical, thoracic and abdominal subcutaneous emphysema, which extended to involve the distal extremities, with no other clinical abnormalities. Hematology and biochemistry were performed and revealed mild thrombocytopenia, mild hypoalbuminemia and mild left-shift neutrophilia.

2. Imaging, Diagnosis and Outcome

Right lateral, left lateral and dorsoventral thoracic radiographs were made (Apelum Baccara 90/20, Italy), using a Fuji CR console system (Fujifilm Medical Systems, Stamford, USA) with kVp and mAs settings based on a technique chart constructed by the hospital's radiology department (102 kVp, 6.3mAs). The radiographs showed severe extensive subcutaneous emphysema, pneumomediastinum, pneumoretroperitoneum and suspected unilateral mild right-sided pneumothorax. The dorsal tracheal wall of the terminal trachea had a bisecting radiolucent line which extended from the third to the fourth intercostal spaces, however, no tracheal defect could be seen (Fig. 1). Tracheobronchoscopy as well as an esophagoscopy were performed and bloody foam on the mucosal surface of the esophagus was observed at the level of the thoracic inlet. Neither a tracheal tear nor any evidence of secondary tracheal changes were observed.

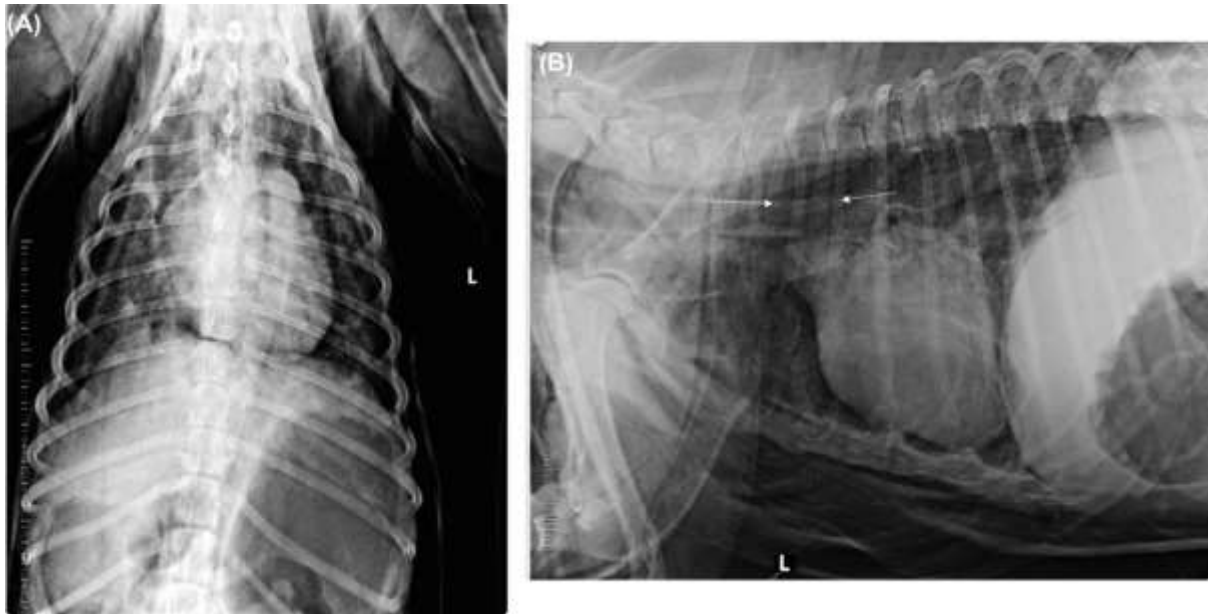


FIG. 1. Dorsoventral (A) and left lateral recumbency (B) preoperative thoracic radiographs illustrating marked subcutaneous emphysema, pneumomediastinum and a suspected right-sided pneumothorax. The dorsal tracheal wall of the terminal trachea has a bisecting radiolucent line (between arrows), extending from the third to the fourth intercostal spaces, however, no tracheal defect could be detected.

Cervical and thoracic computed tomography (CT) were performed (Siemens Somaton Emotion Duo, Siemens, Germany), with the patient in sternal recumbency. Image acquisition consisted of 3 mm-thick helical transverse images, pitch 1.95, tube rotation time 0.8 s, kV 130 and mAs 60 and were acquired from C1 to L4 using a soft tissue algorithm (Window Width = 400 Hounsfield Units (HU); Window Level = 40 HU). The images were reconstructed into 1.5 mm intervals using a bone algorithm (Window Width = 1500HU; Window Level = 450 HU) and a lung algorithm (Window Width = 1200 HU; Window Level = -600 HU). Multi-planar reformatting and windowing were performed after image acquisition. On CT images, a disruption of the dorsal tracheal membrane with mild to moderate overlapping of the membrane, starting 4.3 cm cranial to the tracheal bifurcation and extending caudally over a distance of 3.6 cm was identified in the transverse images. Approximately 0.5 cm cranial to the bifurcation, a focal loss of the dorsal tracheal membrane,

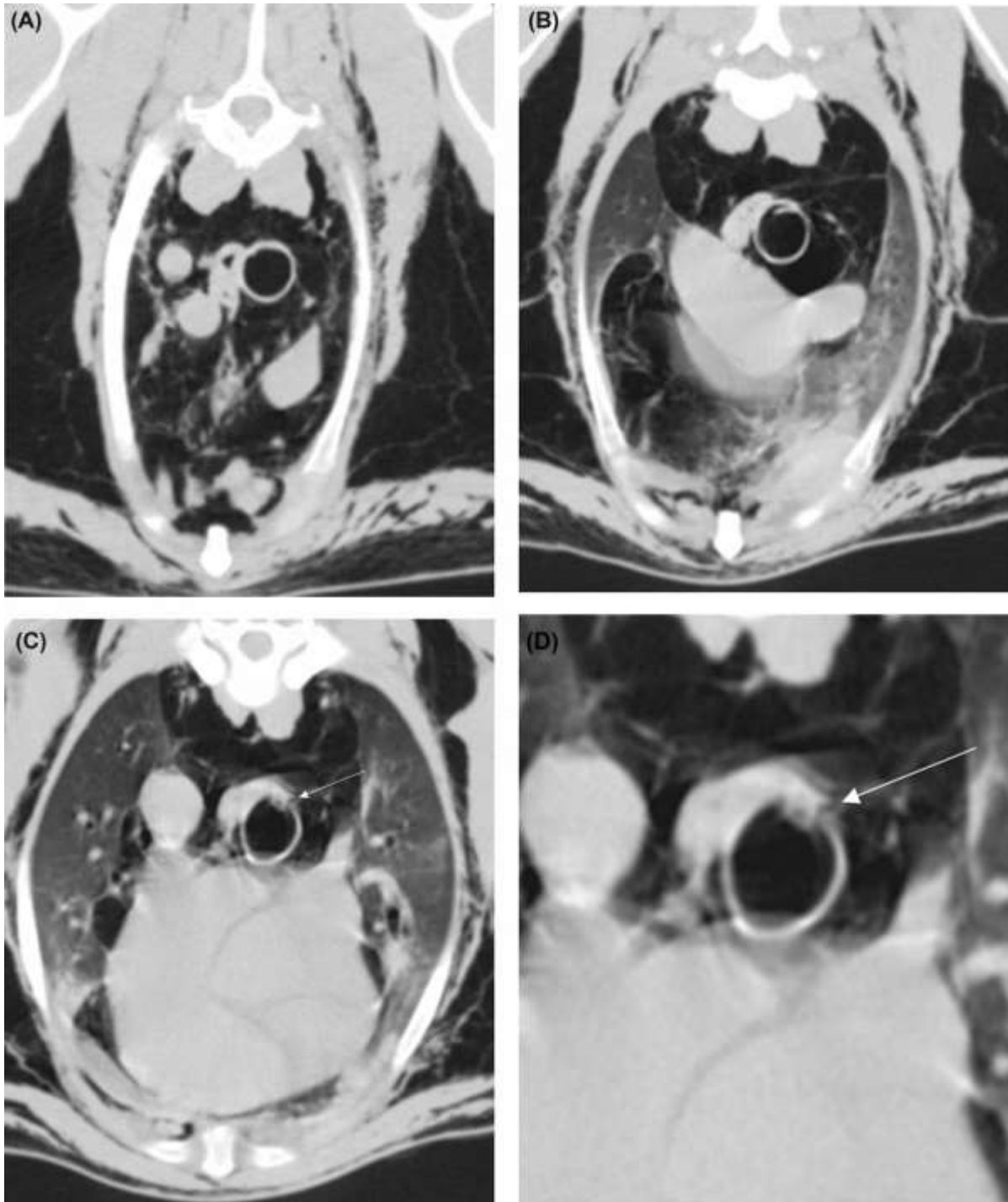


FIG. 2. Transverse CT images of the thorax pre-operatively at the level of the second (A), third (B) and fourth (C &D) thoracic vertebrae. The trachea is normal in the cranial thoracic region. Note the severe subcutaneous emphysema and pneumomediastinum (A). There is disruption of the dorsal tracheal membrane with moderate overlapping of the membrane (B). There is a focal loss of the dorsal tracheal membrane, lateralizing dorsolaterally to the right (arrow) (C). Close up of the trachea in C to illustrate tear (D). There is also severe lung lobe retraction evident. Right is to the right-side of the images. Window width 1200 HU; window level-600 HU.

lateralizing dorsolaterally to the right was evident on transverse images (Fig. 2). The tracheal tear could not be visualized in the sagittal reconstruction since the overlapping dorsal tracheal membrane obscured the tear. Severe pneumomediastinum, which extended cranially to involve the cervical fascial planes and caudally to involve the retroperitoneal space, was also evident. Moderate dorsal displacement of the ventral tips of the right middle lung lobe and the caudal part of the left cranial lung lobe, together with mild, diffuse, mostly homogenous, hyperattenuation of the lungs were apparent due to compression atelectasis from the severe pneumomediastinum. It was concluded that the patient suffered from a full thickness right-sided dorsolateral, longitudinal tracheal tear, with severe secondary pneumomediastinum, pneumoretroperitoneum and mild compression atelectasis of the lungs. Virtual tracheoscopy using the CT-work station's imaging software was attempted but the defect could not be visualized.

A thoracotomy was performed through the right 4th intercostal space. The tracheal tear was identified as described in the CT-findings and measured approximately four centimeters in length intra-operatively. No gross pathology of the trachea was observed that would explain why the trachea tore and thus no biopsies were collected. The tear was closed with simple interrupted sutures of 3/0 polydioxanone. Routine closure of the thorax was performed with placement of a thoracostomy tube. Continuous negative pressure was applied to the tube to aid in draining air from the thorax. The patient recovered uneventfully from the surgery. Post-operative clinical examinations over the next few days showed an improvement of the subcutaneous emphysema and habitus of the patient. A thoracic CT was repeated seven days post-operatively. Computed tomography findings confirmed the successful repair of the tracheal tear. Subcutaneous emphysema, pneumomediastinum and pneumoretroperitoneum were still evident but had markedly improved (Fig. 3). The compression atelectasis of the lungs as previously described had dramatically improved and only the portion of the left lung

lobe adjacent to the heart still showed mild hyperattenuation. The patient was discharged without any complications. The owners were contacted two months later and confirmed that the patient had recovered with complete resolution of the subcutaneous emphysema. The patient subsequently returned to work a month after discharge.

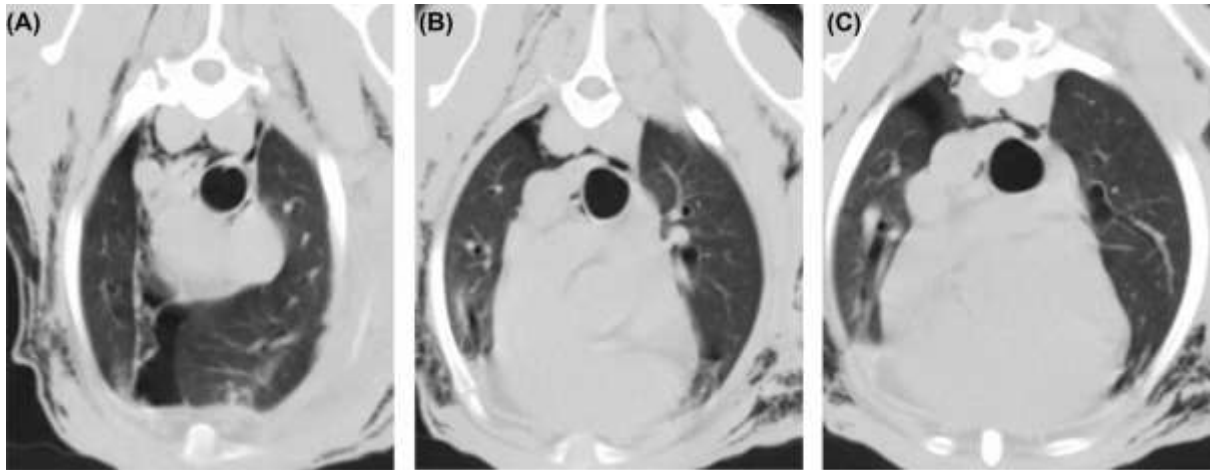


FIG. 3. Transverse computed tomographic images of the thorax seven days post-operatively at the level of the second (A), third (B) and the region of the third and fourth (C) thoracic vertebrae. The trachea is normal in the cranial thoracic region (A). There is no overlapping of the dorsal tracheal membrane evident (B). No dorsal tracheal membrane defect or overlapping can be appreciated after the repair of the tracheal tear (C). The subcutaneous emphysema, pneumomediastinum and lung lobe retraction have markedly improved. Right is to the right-side of the images. Window width 1200 HU; window level -600 HU.

3. Discussion

Tracheal tearing is an uncommon clinical presentation in small animals, which can be life threatening.¹⁻⁴ Tracheal tears in small animals usually occur secondary to trauma, such as blunt or penetrating injuries.¹⁻³ Cervical tracheal tears are more common than thoracic tracheal ruptures and are typically associated with bite wound injuries to the neck, choke chain injuries and traumatic intubation.^{2,3,5-7} Thoracic tracheal ruptures or avulsions have been described infrequently and only in cats secondary to thoracic blunt trauma.⁵ The trachea typically ruptures one to four centimeters cranial to the carina due to hyperextension of the

head and neck.^{3,5,6} The carina is in a fixed anatomic position and thus hyperextension of the head and neck leads to stretching of the trachea and eventual rupture.^{5,6} To the authors' knowledge, this is the first report of an intrathoracic longitudinal tracheal tear described in a dog. Longitudinal tracheal tears have typically been described as a sequel to endotracheal tube intubation and usually occur at the thoracic inlet.^{6,7} The patient described in this case report however had no history of a recent medical procedure and the location of the tear was inconsistent with reported intubation induced longitudinal tears. Another peculiarity of this case was that the patient presented with no known history of trauma. The patient was however a hunting dog and may have acquired a traumatic injury during work, without the owners' knowledge.

The diagnosis of a tracheal tear is often a diagnostic challenge, especially in patients that present with minimal signs of respiratory distress.⁶ Radiologic signs may also be non-specific and may only reflect the consequence of a tracheal tear as was demonstrated in this case.⁶ Severe pneumomediastinum and subcutaneous emphysema made the interpretation of pneumothorax challenging on radiographs and CT was required to confirm the absence of pneumothorax. Although a suspicious bisecting radiolucent line was visualized on the lateral thoracic radiographs at the approximate location of the tracheal tear, the significance of that finding was uncertain and could have represented a normal anatomical structure highlighted by the presence of pneumomediastinum. Identifying the location of the tear is important for surgical repair and tracheoscopy is often used to locate the tear.⁶⁻⁸ In humans, tracheoscopy is employed to diagnose a tracheal tear and appears to be a reliable method of diagnosis.⁹ Limitations have however been identified because blood and mucus may obscure tracheal injury.¹⁰ Tracheoscopy is considered an ineffective method for diagnosing tracheal tears in cats.⁷ Causes for the inaccuracies are secondary to the narrow feline trachea, operator limitations, and draping of the dorsal tracheal membrane over the tear.⁷ In this case, an

experienced operator investigated the entire trachea and main stem bronchi and the reason for failure to identify the tracheal tear on tracheoscopy was uncertain. It was suspected that folding-over of the torn dorsal tracheal membrane might have contributed to inadequate visualization of the tear. In humans, CT is a common modality used in trauma patients with a sensitivity of 85% in detecting tracheal tears.^{9,11-13} Computed tomography also enables optimal visualization of secondary changes associated with a tracheal tear.^{9,11-15} Three-dimensional virtual tracheoscopy using CT has been employed to identify tracheal tears with the same accuracy as that of tracheoscopy.¹⁶ Virtual tracheoscopy was employed to further evaluate the patient's tracheal tear, but this technique was unsuccessful. This was possibly due to folding-over of the dorsal tracheal membrane, which resembled normal draping of the dorsal tracheal membrane and thus obscured the visibility of the tracheal tear.

To the authors' knowledge, only one report describing the CT-appearance of a tracheal tear in a cat has been published.⁷ This report demonstrated the successful use of CT in identifying the exact location and extent of a thoracic tracheal tear in a dog as evidenced by an overlapping dorsal tracheal membrane and a focal mural gas radiolucency. Computed tomography enables multiplanar reconstructions of an anatomic location, which aids visualization of tracheal defects and allows for a more accurate assessment of the secondary changes associated with a tracheal tear.⁷ Computed tomography may be advantageous in unstable patients since safe sedation protocols with rapid image acquisition can make CT a safer modality compared to tracheoscopy, which requires general anesthesia.

In conclusion, this report demonstrated the advantage CT had over other diagnostic modalities in identifying a tracheal tear and should be employed in cases where tracheoscopy is unsuccessful or contra-indicated. This was also the first description of a longitudinal tracheal tear in the thoracic trachea in a canine patient.

List of Author Contributions

Category 1

- (a) Conception and Design: RM Kirberger
- (b) Acquisition of Data: SC Dancer
- (c) Analysis and Interpretation of Data: SC Dancer

Category 2

- (a) Drafting the Article: SC Dancer
- (b) Revising Article for Intellectual Content: RM Kirberger; J van der Zee

Category 3

- (a) Final Approval of the Completed Article: RM Kirberger; J van der Zee

Acknowledgments

The authors would like to thank Nicollete Cassel for her contribution in writing the initial CT-report and Christelle le Roux's input and supervision of the follow-up CT.

References

1. Morath U, Gendron K, Reves NV, Adami C. Perioperative and anesthetic management of complete tracheal rupture in one dog and one cat. *J Am Anim Hosp Assoc* 2015;51:36-42.
2. Kellagher REB, White RAS. Tracheal rupture in a dog. *J Small Anim Pract* 1987;28:29-38.
3. Burton C. Surgical diseases of the trachea in the dog and cat. *In Pract* 2003;25:514-527.
4. Rocken H, Rocken M. Tracheal rupture in a dog. *Prakt Tierarzt* 1983;64:678, 680-681.
5. Hill F. Repair of a traumatic rupture in the trachea of a dog. *Vet Rec* 1974;95:265-266.
6. Basdani E, Papazoglou LG, Patsikas MN et al. Upper airway injury in dogs secondary to trauma: 10 dogs (2000-2011). *J Am Anim Hosp Assoc* 2016;52:291-296.

7. White RNR, Milner HR. Intrathoracic tracheal avulsion in three cats. *J Small Anim Pract* 1995; 36:343-347.
8. Lawrence DT, Lang J, Culvenor J, Mischol G, Haynes S, Swinney G. Intrathoracic tracheal rupture. *J Feline Med Surg* 1999;1:43-51.
9. Sauermann AL, Rubio-Guzman A, Bosmans T, Vanderperren K, Rooster HD. Iatrogenic tracheal rupture in a British shorthair. *Vlaams Diergeneeskd Tijdschr* 2013;82:75-80.
10. White RNR, Burton CA. Surgical management of intrathoracic tracheal avulsion in cats: long-term results in 9 consecutive cases. *Vet Surg* 2000;29:430-435.
11. Bhandal J, Kuzma A. Tracheal rupture in a cat: diagnosis by computed tomography. *Can Vet J* 2008;49:595-597.
12. Mitchell SLS, McCarthy R, Rudloff E, Pernell RT. Tracheal rupture associated with intubation in cats: 20 cases (1996-1998). *J Am Vet Med Assoc* 2000;216:1592-1595.
13. Chen J-D, Shanmuganathan K, Mirvis SE, Killeen KL, Dutton RP. Using CT to diagnose tracheal rupture. *Am J Roentgenol* 2001;176:1273-1280.
14. Le Guen M, Beigelman C, Bouhemad B, Wenjïe Y, Marmion F, Rouby J-J. Chest computed tomography with multiplanar reformatted images for diagnosing traumatic bronchial rupture: a case report. *Crit Care* 2007;11:R94.
15. Roh J-L, Lee J-H. Spontaneous tracheal rupture after severe coughing in a 7-year-old boy. *Pediatrics* 2006;118:e224-e227.
16. Moriwaki Y, Sugiyama M, Matsuda G, et al. Usefulness of the 3-dimensionally reconstructed computed tomography imaging for diagnosis of the site of tracheal injury (3D-tracheography). *World J Surg* 2005;29:102-105.