

Case report: A toddler with anasarca caused by congenital nephrotic syndrome

Tumelo M. Satekge¹, Olivia Kiabilua¹, Gertruida van Biljon², Komala Pillay³, Tahir S. Pillay^{1,4}

¹ *Department of Chemical Pathology1, Faculty of Health Sciences, University of Pretoria and NHLS Tshwane Academic Division, Pretoria, South Africa*

² *Department of Paediatrics, University of Pretoria and Steve Biko Academic Hospital, South Africa*

³ *Division of Anatomical Pathology, University of Cape Town and Red Cross Children's Hospital and NHLS, South Africa*

⁴ *Division of Chemical Pathology, University of Cape Town, South Africa*

INFO

Corresponding author:

Prof. Tahir S. Pillay
Department of Chemical Pathology
Faculty of Health Sciences
University of Pretoria
Arcadia, Pretoria, 0007
South Africa
Phone: 012-319-2114
E-mail: tspillay@gmail.com

Key words:

congenital nephrotic syndrome,
proteinuria, generalised edema

Disclosures:

No conflicts of interest declared.

TS, OK and TSP conceived the idea and wrote and edited the manuscript. GvB was the paediatrician managing the patient and contributed to the manuscript. KP was the anatomical pathologist who analysed the biopsies and contributed to the manuscript.

ABSTRACT

Congenital nephrotic syndrome is a rare inherited disorder arising from defects in the proteins of the cells in the glomerular basement membrane and develops either in utero or at birth. The clinical presentation is the result of massive protein loss in the urine with associated compensatory mechanisms.

Here we present a clinical case of a female toddler with a history of anasarca (severe generalised edema) from birth and who presents with the classical biochemical laboratory findings of nephrotic syndrome, together with the more pronounced features that arise from protein loss including abnormal thyroid function testing and a marked hypercholesterolaemia. Renal biopsy indicated congenital nephrotic syndrome of the Finnish type. This clinical-diagnostic case report represents an example of the broad spectrum of pathophysiological findings of a severe congenital nephrotic syndrome.

INTRODUCTION

Congenital nephrotic syndrome (CNS)

CNS manifests normally at birth to 3 months of life and is associated with inherited defects in one of the three components of the glomerular basement barrier namely fenestrated endothelium, glomerular basement membrane and podocytes (1-3). Mutations in podocytes lead to congenital nephrotic syndrome of the Finnish type (CNS-F) where podocyte foot processes form filtration slits covered by the slit diaphragm (1-4). The responsible NPHS1 gene was the first described and encodes for nephrin, a type - 1 transmembrane protein of the immunoglobulin superfamily and is a pivotal component of the slit diaphragm. Almost 50 mutations so far have been described in the NPHS1 gene and the autosomal recessive gene maps to 19q13.1 (4, 5). CNS-F presents with massive non-selective proteinuria *in utero* allowing for prenatal screening (1). Other features include premature birth (35 – 38 weeks) with low birth weight and neonatal edema as they were present in this case. Other mutations may occur in podocin (NPHS2) and is associated with autosomal recessive, steroid-resistant focal segmental glomerulosclerosis (FSGS). Autosomal dominant FSGS can result from TRCP6 and CD2AP mutations causing defects in the podocyte. Also, mutations in Wilms' tumor suppressor gene can occur in the Denys-Drash syndrome (glomerulopathy in combination with Wilms' tumor and male pseudohermaphroditism). Although the common histological finding is mesangial sclerosis, this diagnosis was excluded by the absence of ambiguous genitalia and abdominal mass (2, 4).

CASE REPORT

Clinical features

A 15-month-old first-born female toddler presented with a history of generalised body swelling since birth and neurodevelopmental delay. The

first presentation was at 2 weeks after full-term normal vaginal delivery with low birthweight of 2.3 kg. The mother was HIV-positive during pregnancy and received anti-retroviral drugs. She reported unsatisfactory growth of the new-born with motor and speech delay. The child was fed breast milk until 4 months and afterwards with infant formula. On examination, she was below the 3rd percentile for height and weight (weight 6.5 kg; length 64 cm and head circumference 44.5 cm). Despite having Harrison's sulci, the child was un-distressed with no dysmorphic features. There were generalised edema and hypoplastic teeth. Central nervous system examination revealed delayed social and motor milestones with no smile, reaching or sitting and decreased tone and muscle power with normal reflexes. Based on these clinical presentations, congenital nephrotic syndrome was suspected and specific laboratory testing was performed and renal biopsy was done for immuno-histochemical work-up to establish diagnosis.

Laboratory findings

The urine dipstick resulted with 3+ for proteinuria, no signs of haematuria. Blood testing showed a significant depressed C3 level of 0.638 g/L (reference interval 0.9-1.8 g/L) and hypoalbuminaemia of 2.0 g/L (reference interval 27-43 g/L) indicating nephrotic syndrome (NS). Whole blood count revealed anaemia with haemoglobin of 8.0 g/L and there was thrombocytosis with $656 \times 10^9/L$. Plasmatic coagulation tests were found within normal ranges, as well as liver enzymes and renal function testing and electrolytes. Total- and LDL cholesterol levels were markedly increased; TSH and PTH were also significantly elevated together with hypocalcaemia and hyperphosphatemia as outlined in Table 1. Serologic testing for active infections including hepatitis, toxoplasmosis, anti-streptolysin-O titer, cytomegalo virus and syphilis gave negative results, HIV-antibody ELISA was negative and HIV-RNA was not detectable.

Histological and immunochemical findings

A renal biopsy showed mesangial hypercellularity, focal microcystic dilatations of the tubules and a mild interstitial inflammatory infiltrate (Figure 1A). 4+ foot process effacement and increased tubular lipid droplets were visualised on electron microscopy. Immunofluorescence displayed focal 1+ IgM mesangial positivity.

Clinical course

After establishing diagnosis, optimal supportive treatment including Enalapril p.o., intravenous albumin, furosemide, low salt intake, high caloric- and protein diet were given along with

calcitriol and thyroxine. Poor compliance to thyroxine contributed to neurodevelopment delay. Treatment was not effective and was hampered by persistent proteinuria.

Unilateral nephrectomy was performed showing massive lymphoplasmocytic inflammatory infiltrates, focal segmental glomerulosclerosis with microcystic tubular dilatation, hypertensive vascular changes and ascending pyelonephritis (Figure 1B). Unfortunately, renal function dramatically deteriorated with volume overload, subsequent bacterial peritonitis and the patient died from septic shock.

Figure 1A Renal biopsy histology showing mesangial hypercellularity and focal microcystic dilatations of tubules

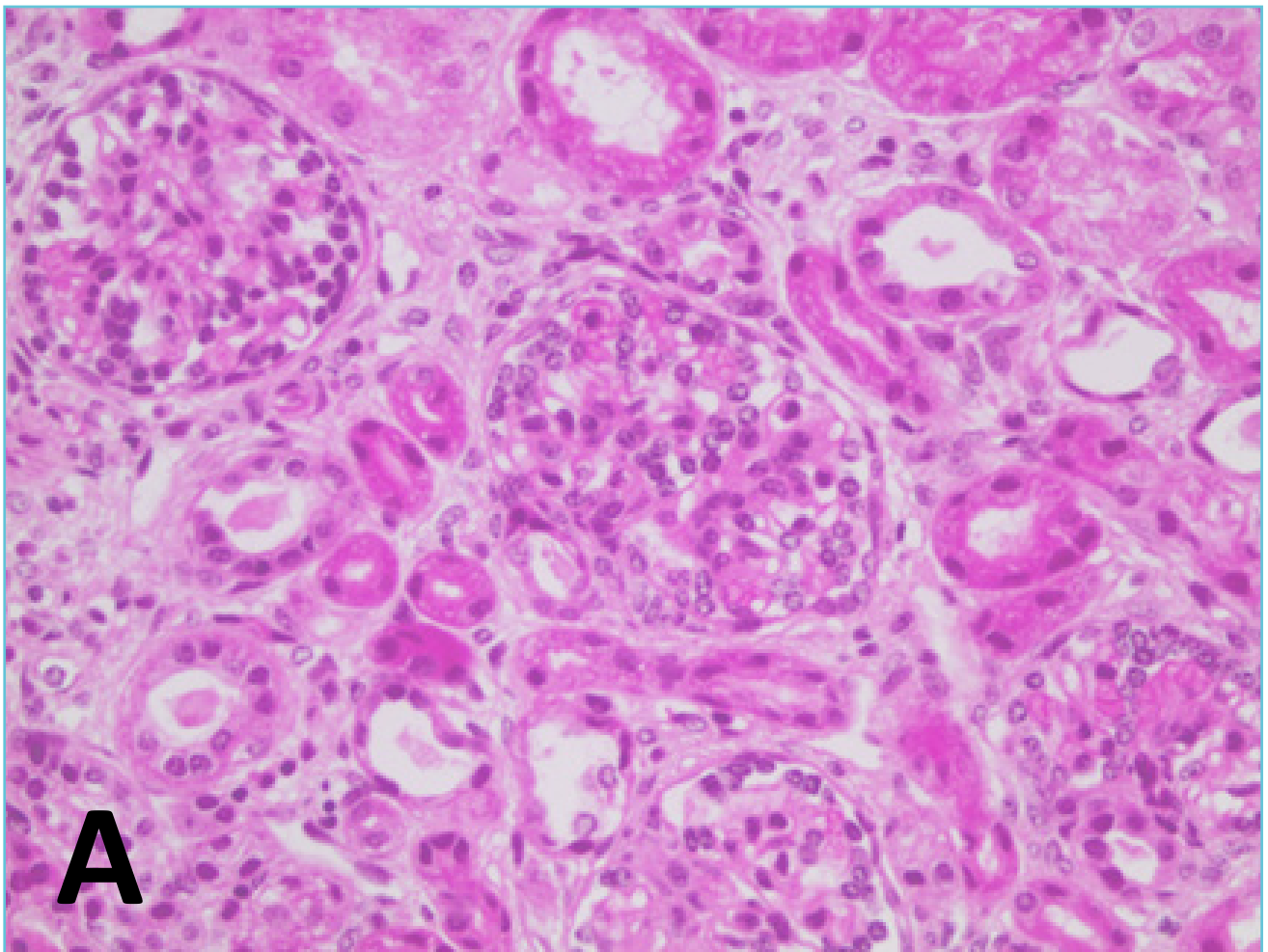
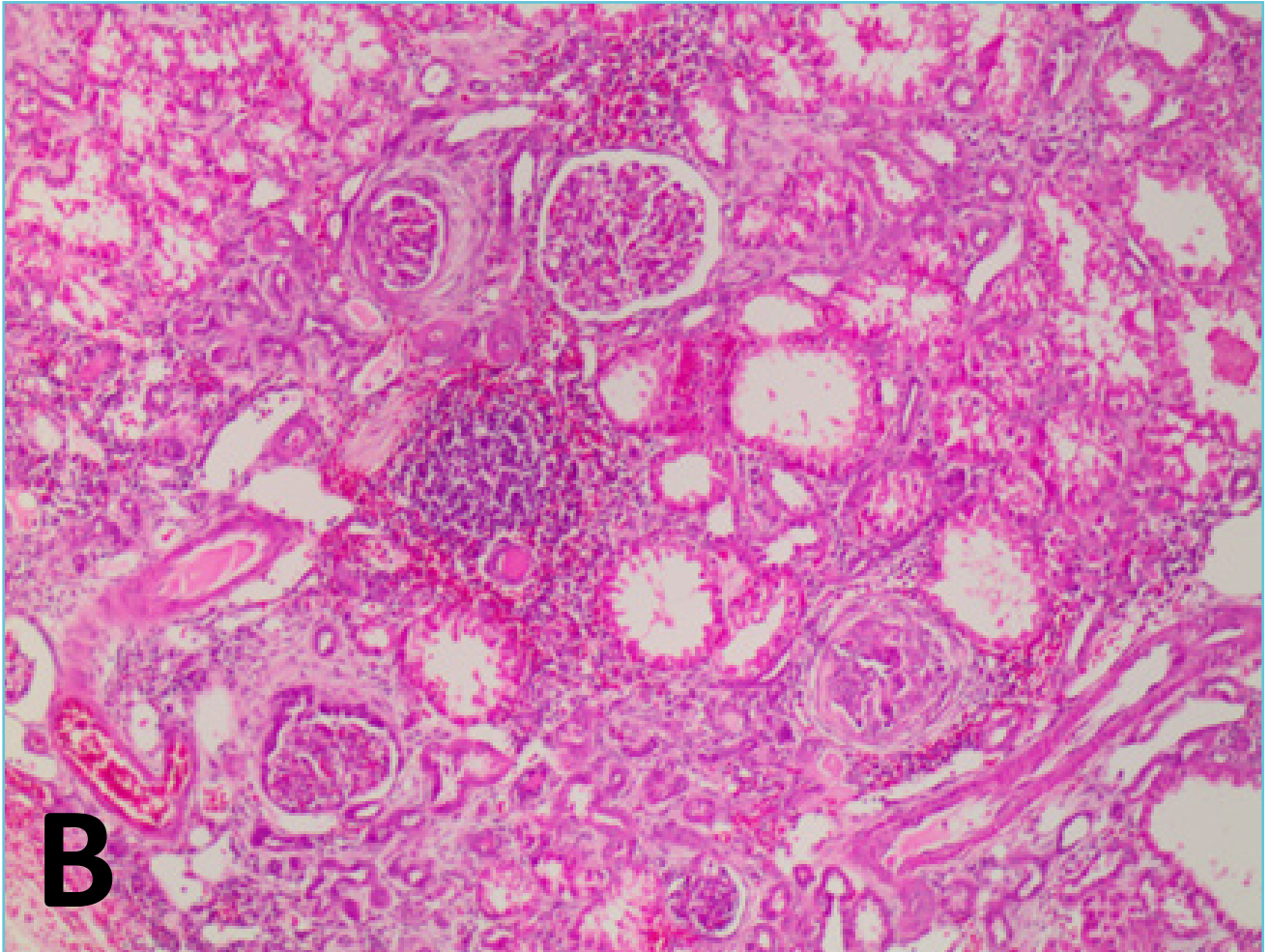


Figure 1B Left kidney histology post nephrectomy demonstrating interstitial lymphoplasmocytic inflammatory infiltrates, microcystic dilatations of tubules, fibrosis and tubular atrophy



DISCUSSION

Generalised edema can result from renal disease, liver disease, allergic reactions, cardiac disease, malnutrition or protein-losing enteropathy. In children, the most common cause is renal disease. First, evaluation can commence with simple tests such as urine dipstick and urine microscopy to identify proteinuria and casts. In our case, edema is a hallmark of NS but the pathogenesis is not fully understood (6, 7). Selective loss of albumin leads to hypoalbuminemia and decreased capillary oncotic pressure resulting in net fluid flux outwards and renal

losses not compensated with increased albumin production in the liver. Sequestration of fluid in the interstitium triggers renal sodium reabsorption and fluid retention to maintain intravascular volume and blood pressure balanced (the “underfill” hypothesis) (6, 7).

In NS associated with glomerulonephritis the extent of proteinuria is variable and a reduction in GFR is common. Intravascular fluid volume is typically normal or expanded because of inappropriately stimulated sodium and fluid retention together with decreased GFR results in an “overfill” state. Distinguishing between these two

states is critical to the management of edema in NS. Protein loss in the urine leads to further complications including hypogammaglobulinaemia.

In NS, there is increased risk of thromboembolism owing to increased pro-coagulants and decreased anticoagulants (urinary loss of anti-thrombin III, plasminogen and protein S) (8). In our patient, we found thrombocytosis which is one of the prothrombotic factors in NS; however the rest of the coagulation profile was unremarkable and there were no clinical signs of a thromboembolic state. As part of nephrotic syndrome workup to exclude secondary causes, relevant infections particularly in the presence of pre-natal HIV exposure were sought and testing was found negative for all pathogens tested.

The markedly elevated total and LDL cholesterol is probably due to over-compensated lipoprotein synthesis for reduced plasma oncotic pressure due to depleted albumin (9). This is associated with an increased risk of cardiovascular events (9). The hypothyroid state in the nephrotic syndrome could also be a contributory factor to the hypercholesterolemia. The elevation of Apo B containing lipoproteins is a prominent feature in nephrotic syndrome and in severe cases is accompanied by hypertriglyceridemia (9). Thyroid hormone alterations in Congenital Nephrotic syndrome of the Finnish type (CNS-F) without renal impairment are well documented (10). Thyroid binding globulin is lost with proteinuria leading to low total T4 and T3. Correspondingly, free thyroid hormones are expected to be normal or even elevated with normal TSH. In severe CNS-F, as in this case, FT4 is lost in urine proportionally with massive proteinuria without commensurate compensation by the thyroid gland. This in turn stimulates the hypothalamic-pituitary axis as demonstrated by high elevated TSH (10). Low FT3 in this case can be explained by the catabolic nature of NS as a non-thyroidal illness characterised by impaired peripheral conversion of T4 to T3.

There was persistent hypocalcaemia with no other overt signs of rickets. She had poor neurodevelopment including motor milestones, Harrison sulci and hypoplastic teeth. Vitamin D-binding protein loss is a likely cause for calcidiol depletion owing to its greater affinity for 25OHD₃. However, 1,25(OH)2D₃ and 24,25(OH)2D₃ can also be low in patients with nephrotic syndrome without renal impairment (11). This can be explained by depletion of the precursor in the form of 25-OHD₃ and to a lesser extent to loss of binding protein in severe cases. Tubular damage as a result of exceeded reabsorption of filtered protein can lead to destabilisation of 1 α -hydroxylase resulting in low calcitriol level (11). It has been hypothesized that corrected total calcium overestimates hypocalcemia; this was also evident in our case (Table 1). Ionised calcium and vitamin D metabolites were unfortunately not measured. Depleted total calcium was associated with an elevated PTH on more than two occasions (Table 1) indicative of secondary hyperparathyroidism leading to bone demineralization (11).

The histology was typical of CNS-F where immunofluorescence did not detect immune deposits. Microcystic changes of proximal and distal tubules are common findings in CNS of Finnish type, but it may also be present in other histological subtypes of NS. Mostly, CNS-F shows slower progression even with marked proteinuria and renal function tests can be normal early on. If signs of deterioration are present despite optimal supportive treatment, bilateral nephrectomy, dialysis and subsequent transplantation should be the definitive approach to prevent further severe deterioration by reversing the biochemical abnormalities and hormonal disturbances with minimal risk of recurrence after surgery (12). However, in our case a rapid dramatic deterioration occurred with septic shock leading to fatal outcome.

Table 1 Laboratory testing

	Result	Reference interval
Urine		
Protein	4.9 g/L	
Creatinine	0.6 mmol/L	
Protein/creatinine ration	8.17	<0.015 g/mmol
Urea and electrolytes		
Sodium	141	136-145 mmol/L
Potassium	5.2	3.4-4.7 mmol/L
Chloride	112	98-107 mmol/L
Urea	27.0	1.1-5.0 mmol/L
Creatinine	124	15-31 umol/L
Bicarbonate	13	23-29
Anion gap	21	9-16
Liver function tests		
Total protein	26	48-70 g/L
Albumin	<10	27-43 g/L
Total Bilirubin	6	6-21 mmol/L
Direct Bilirubin	1	0-6 mmol/L
Alanine transaminase (ALT)	11	2-25 U/L
Aspartate transaminase (AST)	28	0-49 U/L
GGT	129	15-132 U/L
ALP	191	48-406 U/L
Calcium	1.66	2.12-2.59 mmol/L
Corrected calcium	2.39	2.19-2.64 mmol/L (low albumin)
Magnesium	0.92	0.7-0.99mmol/L
Phosphate	2.13	1.10-1.95 mmol/L

TSH	>100	0.95-6.52mIU/L
FT4	5.8	7.6-16.1pmol/L
FT3	2.9	4.5-10.5pmol/L
PTH	103.4	1.3-9.3pmol/L
Lipids		
Total Cholesterol	13.36 mmol/L	
Triglycerides	6.55 mmol/L	
LDL-Cholesterol	9.19 mmol/L	
HDL-Cholesterol	0.68 mmol/L	
Complete blood count		
WBC	20.56	6-18x10 ⁹ L
Hb	8.0	10.7-13g/L
MCV	93.3	70-86fl
Haematocrit	0.255	0.32-0.420
Platelet	656	180-440x10 ⁹ L
Iron	4.9	9.0-21.5 umol/L
Transferrin	<0.70	1.49-3.82 g/L
Ferritin	34	36-84 ug/L

TAKE HOME MESSAGES / LEARNING POINTS

- Anasarca in neonates requires a systemic approach to rapidly establish the correct diagnosis. Bedside testing with urine dipstick is an essential screening tool to guide further investigations; a 3+ proteinuria on dipstick is highly suggestive of nephrotic syndrome to be confirmed by appropriate laboratory work-up.
- Nephrotic syndrome is characterised by proteinuria, edema, hyperlipidaemia, hypoproteinaemia and may be associated with coagulopathy. Early diagnosis will necessitate aggressive supportive treatment in preparation for definitive treatment with surgery for restoration of growth and development.
- Always exclude secondary causes of congenital nephrotic syndrome because they tend to occur more frequent than primary causes showing better treatment response.
- Various mutations in CNS have been described; CNS-F resulting from nephrin gene mutations is not uncommon worldwide and affects both sexes equally. Genetic counselling and antenatal screening for congenital nephrotic syndrome - Finnish type with

haplotype analysis is often required and should therefore be considered early on.

- In congenital nephrotic syndrome, thyroid hormones and Vitamin D status must be evaluated.
- Renal biopsy is mandatory in CNS to further differentiate and support diagnosis and to better estimate the severity of clinical progression regarding renal failure.

REFERENCES

1. Spahiu L, Merovci B, Jashari H, Kepuska AB, Rugova BE. Congenital nephrotic syndrome - finish type. *Med Arch* 2016;70:232-4.
2. Rapola J. Congenital nephrotic syndrome. *Pediatric nephrology* 1987;1:441-6.
3. Wang JJ, Mao JH. The etiology of congenital nephrotic syndrome: Current status and challenges. *World J Pediatr* 2016;12:149-58.
4. Tryggvason K. Unraveling the mechanisms of glomerular ultrafiltration: Nephrin, a key component of the slit diaphragm. *J Am Soc Nephrol* 1999;10:2440-5.
5. Holthofer H, Ahola H, Solin ML, Wang S, Palmén T, Lui-mula P, et al. Nephrin localizes at the podocyte filtration slit area and is characteristically spliced in the human kidney. *Am J Pathol* 1999;155:1681-7.
6. Siddall EC, Radhakrishnan J. The pathophysiology of edema formation in the nephrotic syndrome. *Kidney international* 2012;82:635-42.
7. Bockenhauer D. Over- or underfill: Not all nephrotic states are created equal. *Pediatric nephrology* 2013;28:1153-6.
8. Mahmoodi BK, ten Kate MK, Waanders F, Veeger NJ, Brouwer JL, Vogt L, et al. High absolute risks and predictors of venous and arterial thromboembolic events in patients with nephrotic syndrome: Results from a large retrospective cohort study. *Circulation* 2008;117:224-30.
9. Wheeler DC, Bernard DB. Lipid abnormalities in the nephrotic syndrome: Causes, consequences, and treatment. *Am J Kidney Dis* 1994;23:331-46.
10. Ito S, Kano K, Ando T, Ichimura T. Thyroid function in children with nephrotic syndrome. *Pediatric nephrology* 1994;8:412-5.
11. Nielsen CA, Jensen JE, Cortes D. Vitamin d status is insufficient in the majority of children at diagnosis of nephrotic syndrome. *Dan Med J* 2015;62.
12. Slaughenhaupt BL, Lohrasbi FF, Harrison HL, Van Savage JG. Urologic management of congenital nephrotic syndrome of the finnish type. *Urology* 1998;51:492-4.