



# What Is Your Diagnosis?

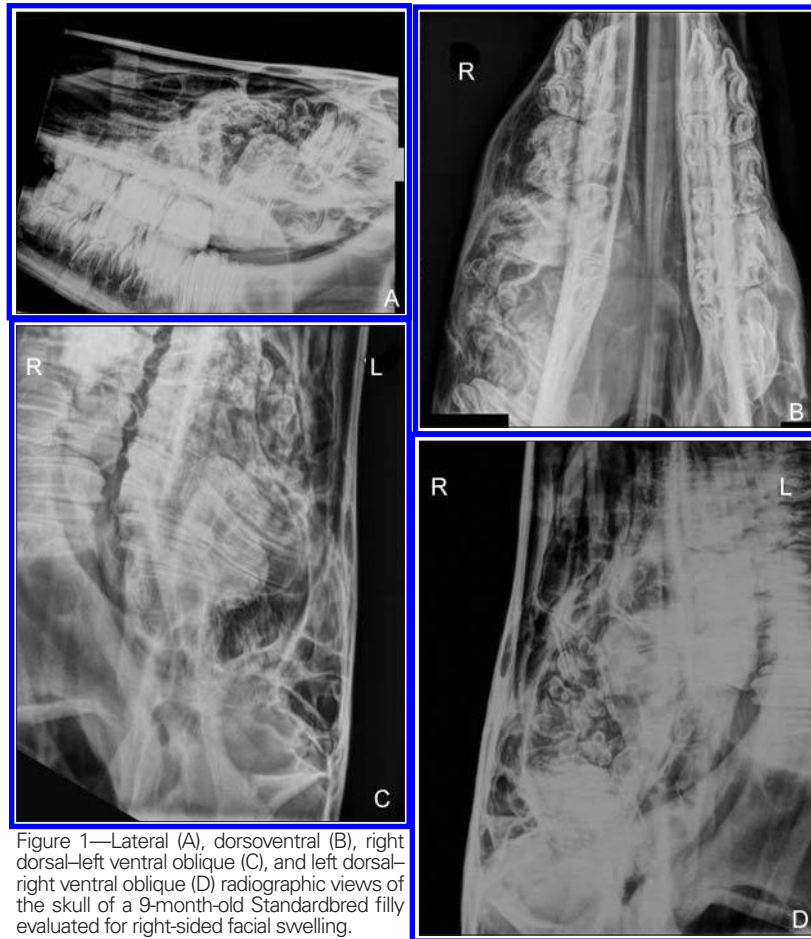


Figure 1—Lateral (A), dorsoventral (B), right dorsal–left ventral oblique (C), and left dorsal–right ventral oblique (D) radiographic views of the skull of a 9-month-old Standardbred filly evaluated for right-sided facial swelling.

## History

A 9-month-old Standardbred filly was admitted to the veterinary teaching hospital for evaluation of a right-sided facial swelling. Swelling over the right maxillary bone had been first noticed at 3 months of age. At that time, the site had been drained, and the swelling resolved. Four months later (2 months prior to hospital admission), the swelling developed again at the same location and gradually increased in size. Mild right-sided nasal and ocular discharge and intermittent respiratory noise were also observed.

On physical examination, the filly was in good general condition and heart rate, respiratory rate, and body temperature were all within reference ranges. A hard, cool, apparently nonpainful facial swelling (10 × 15 cm) was present over the right maxilla. Mild mucous discharge was present from the medial canthus of the right eye. Airflow from the right nostril was decreased. Percussion over the maxillary sinus resulted in muffled sounds. Radiographs of the skull were obtained (Figure 1).

**Determine whether additional imaging studies are required, or make your diagnosis from Figure 1—then turn the page →**

This report was submitted by Luis M. Rubio-Martínez, DVM, PhD, DVSc, DACVS; Stephanie Nykamp, DVM, DACVR; and Don Trout, DVM, PhD, DACVS; from the Department of Clinical Studies, Ontario Veterinary College, University of Guelph, Guelph, ON N1G 2W1, Canada. Dr. Rubio-Martínez's present address is the Department of Companion Animal Clinical Studies, Faculty of Veterinary Science, University of Pretoria, Private Bag X04 Onderstepoort 0110, Republic of South Africa. Address correspondence to Dr. Rubio-Martínez (luis.rubiomartinez@up.ac.za).

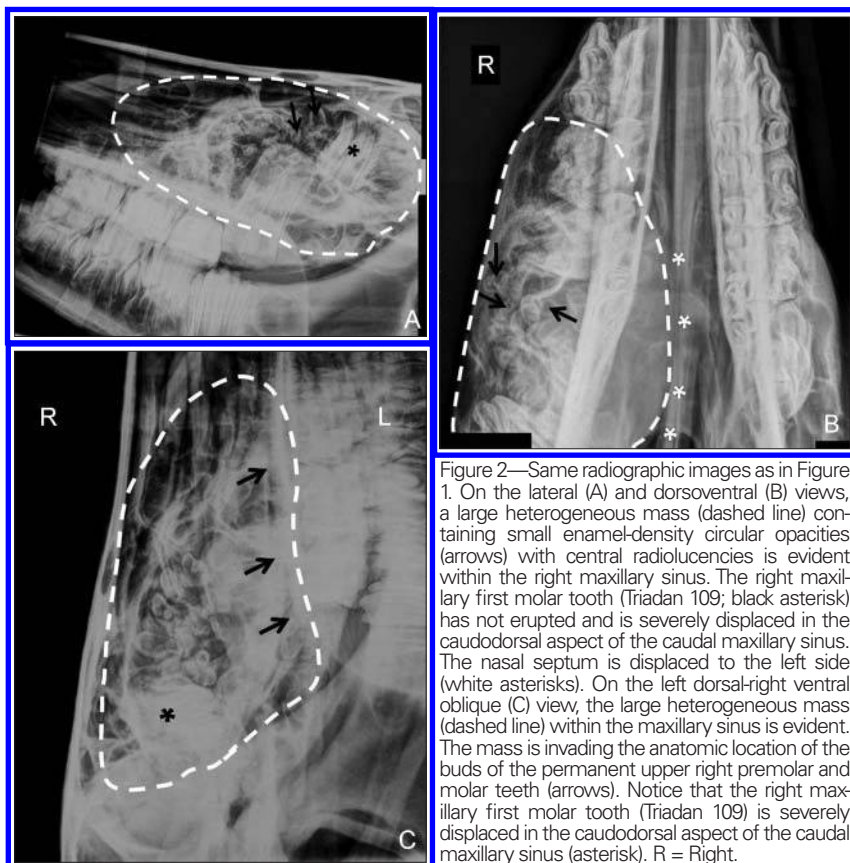


Figure 2—Same radiographic images as in Figure 1. On the lateral (A) and dorsoventral (B) views, a large heterogeneous mass (dashed line) containing small enamel-density circular opacities (arrows) with central radiolucencies is evident within the right maxillary sinus. The right maxillary first molar tooth (Triadan 109; black asterisk) has not erupted and is severely displaced in the caudodorsal aspect of the caudal maxillary sinus. The nasal septum is displaced to the left side (white asterisks). On the left dorsal-right ventral oblique (C) view, the large heterogeneous mass (dashed line) within the maxillary sinus is evident. The mass is invading the anatomic location of the buds of the permanent upper right premolar and molar teeth (arrows). Notice that the right maxillary first molar tooth (Triadan 109) is severely displaced in the caudodorsal aspect of the caudal maxillary sinus (asterisk). R = Right.

lar teeth. Therefore, a guarded to poor long-term prognosis was given because of the high risk of an abnormal upper right premolar and molar arcade, with likely teeth loss, eating difficulties, malnutrition, and chronic pain.

Euthanasia was performed. A postmortem examination confirmed that the tumor mass contained dental material and that the mass had obliterated the maxillary sinus and destroyed the developing permanent premolar and molar teeth as previously suspected. The first molar tooth was displaced dorsocaudally, and the tumor had invaded adjacent turbinate bones in the right nasal cavity. The mass had obliterated the maxillary sinus, and the common and ventral nasal meatus were collapsed. The circular radiopaque areas were found to resemble teeth. No signs of metastasis were evident in regional or distant lymph nodes or organs. Histologically, the mass was composed of loosely arranged stromal tissue within which multiple dental structures were embedded in various stages of tooth formation. Histologic examination of the tumor confirmed that it was a compound odontoma (a tumor of dental origin).

### Radiographic Findings and Interpretation

A large heterogeneous mass containing small enamel-density circular opacities with central radiolucencies is evident within the right maxillary sinus (Figure 2). These lesions resemble small teeth. The right maxillary first molar tooth (Triadan 109) has not erupted and is severely displaced to the caudodorsal aspect of the caudal maxillary sinus. The mass is invading the anatomic location of the buds of the permanent upper right premolar and molar teeth. The nasal septum is displaced to the left side. This complex mass of the right maxillary sinus is consistent with tumor originating from dental tissue (ie, odontoma) or from embryological origin (teratoma).

### Comments

Surgical removal of the tumor was considered. However, the upper right first molar tooth was severely displaced and could not erupt normally, which would likely prevent normal eruption of the second and third molar teeth at a later stage. Radiographic findings were also indicative of involvement of the buds of the upper right permanent premo-

Surgical resection of compound odontomas has been successful in 2 affected horses.<sup>1</sup> Surgical procedures are difficult, requiring extensive and aggressive surgical resection, intensive postoperative management, and sometimes multiple surgical procedures.<sup>1</sup> Extraoral alimentation may be necessary, and complications are common.<sup>1</sup>

Radiographs of the filly of this report permitted differentiation of tooth-like structures within the mass, which was consistent with a primary diagnosis of compound odontoma. Tumor invasiveness was also evidenced with the displacement of the first molar tooth, suspected involvement of the buds of the permanent premolar teeth, and deviation of the nasal septum. Use of computed tomography could have provided more detailed information about extensiveness,<sup>2</sup> but it was not available or necessary in this case.

1. Brounts SH, Hawkins JF, Lescun TB, et al. Surgical management of compound odontoma in two horses. *J Am Vet Med Assoc* 2004;225:1423-1427.
2. Heufelder B, Mettenleiter E, Tietje S, et al. Fallbericht eines Komplexen Odontoms beim Pferd-klinik, Rontgen, Sonographie und Computertomographie. *Tierarztl Prax* 1994;22:155-158.