

Emergency Surgery for Major Pulmonary Injury

Taole Mokoena

ABSTRACT

Severely shocked patients with thoracic injury often require emergency thoracotomy before a definite diagnosis can be made. A method of management of pulmonary injury is described by performing exploratory resuscitative anterolateral thoracotomy which can be extended across the sternum to the opposite side, if necessary. Control of haemorrhage from the lung is achieved by mass clamping of the hilum and waiting for further resuscitation. After adequate resuscitation, specific management of the lung injury is performed as indicated. This approach was used in 26 cases of life-threatening pulmonary injury. Exposure of the injured lung was good in all cases. Pneumonography was performed in 8, segmental resection in 8 and pneumonectomy in 5 cases. Surgery and resuscitation were abandoned in 5 unsalvageable cases. Eleven patients (42%) survived. All general and trauma surgeons should be able to perform emergency thoracotomy for trauma. The method described here is simple, needs no special equipment and is suitable for most instances.

Key Words: Thoracic trauma. Major pulmonary injury. Bilateral clam-shell thoracotomy.

INTRODUCTION

There are several causes of severe shock in patients with thoracic trauma. Some can be readily diagnosed clinically, such as tension pneumothorax and cardiac tamponade. However, the surgeon is often confronted with a patient in *extremis* due to cardiovascular collapse as a result of pulmonary or cardiac injury. Some patients may require an emergency resuscitative thoracotomy in the absence of an anatomical diagnosis, if they should be salvaged. Mortality is high in such cases. The author proposes a management plan in such cases, which entails an exploratory anterolateral thoracotomy with possible transsternal contralateral extension as necessary. This affords access for both pulmonary and cardiac injuries.

METHODOLOGY

Severely shocked patients with thoracic injury were initially resuscitated aggressively following standard principles and protocols. Tube thoracostomy was performed as indicated by clinical examination or plain chest X-rays. A patient with non-responsive shock or in whom significant bleeding continues through the intercostal drain, was rapidly transferred to the operating theatre.

Surgical technique: The patient was positioned supine on the operating table. The chest was cleaned and draped open (if time allows). A wide anterolateral

thoracotomy in the 5th intercostal space was performed on the side of probable intra-thoracic injury. If the cause of shock was not found on that side, the incision was extended across the sternum to the corresponding opposing intercostal space as depicted in Figure 1-A. The sternum was readily transected with heavy shears or even a scalpel in younger patients. The internal thoracic arteries were cut in the process and managed later, when they began to bleed once adequate circulatory blood volume had been re-established. The whole chest could then be opened in the manner of a clam-shell and injury to either lung, the heart or other mediastinal structures could be readily accessed (Figure 1-B).

The following description only addresses the topic of pulmonary injury.

Pulmonary injury: After removal of blood and clots, the lung was assessed for injury. Severe haemorrhage from the lung was usually due to an injury near the hilum. When there was active haemorrhage from the lung, the whole pulmonary pedicle was cross clamped. Once haemorrhage was controlled, further surgery was halted and resuscitation continued. When the patient was adequately resuscitated, further determination and

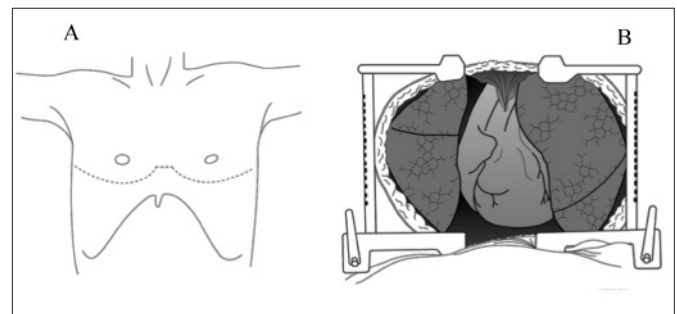


Figure 1: Illustration of incision for bilateral thoracotomy with extension across the sternum to the opposite side (A), opened as a "clam-shell" (B).

Department of Surgery, University of Pretoria, Arcadia, South Africa.

Correspondence: Prof. Taole Mokoena, Department of Surgery, Faculty of Health Sciences, University of Pretoria, Private Bag x323, Arcadia-0007, South Africa.

E-mail: taole.mokoena@up.ac.za

Received: May 30, 2015; Accepted: September 11, 2015.

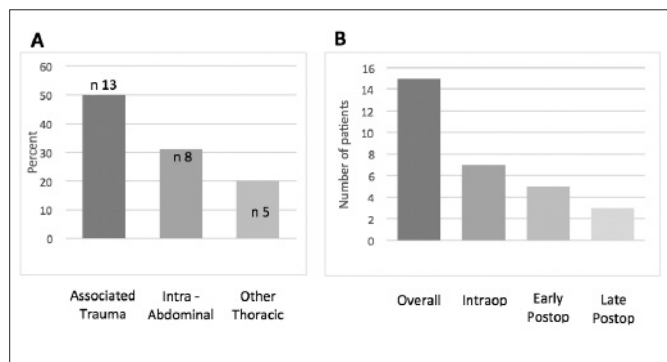


Figure 2: Associated injuries in 26 patients with pulmonary injury (A) (%), (n) and mortality during the course of their management (B).

Table 1: Indications for emergency thoracotomy (A) and pulmonary procedures (B) performed in 26 patients.

A. Indications	
Continued ICD# bleeding	9
Active external bleeding	6
Cardiac arrest	6
Circulatory collapse	6
B. Procedures	
Pneumonorrhaphy	8
Segmental resection	8
Pneumonectomy	5
Surgery abandoned	5*

ICD = Intercostal drain; *Surgery was abandoned due to irreversible shock

definition of the exact injury was made. Major vascular injuries were repaired, if amenable. However, it was mostly judicious to curtail the procedure by pneumonectomy with either stapled resection or en-masse ligation of the pedicle. If bleeding was from an injury in distal to the pulmonary pedicle, a lobectomy or segmentectomy was effected, either by stapled resection or local resection and mass suture. Speed was of the essence, so surgery was performed in minimal time as a form of damage control before prolonged hypothermia and acidosis resulted in coagulopathy with uncontrollable haemorrhage.

Results of the technique: We have used this approach for major chest trauma with circulatory collapse or severe bleeding. Here only the patients with pulmonary injury are described. Twenty-six patients were treated by this method. In all cases, adequate exposure was achieved by this surgical approach, described above. All, except one case were due to penetrating injury: 14 gunshot and 11 stab wounds. Indications for thoracotomy included ongoing bleeding from an intercostal drain in 9, active external bleeding in 6, cardiac arrest in 6, and circulatory collapse in 3 cases (Table I-A). A number (50%) had associated injuries, mostly extrathoracic (Figure 2-A). The surgical procedures performed were pneumonography in 8, segmental resection in 8 and pneumonectomy in 5 cases (Table I-B). Surgery and resuscitation were abandoned in 5 cases with irreversible circulatory

collapse. Eleven patients survived (42%) and 15 died (58%); 7 during surgery, 5 soon after surgery (Figure 2-B), 3 died later during the course of their hospitalisation and treatment. A number (31%) had associated extra thoracic injuries, mainly intra-abdominal (Figure 2-A).

DISCUSSION

Surgery is seldom necessary for thoracic trauma. Minor haemorrhage and pneumothorax are successfully managed conservatively or by tube thoracostomy alone. However, up to 10% of patients require emergency surgery for refractory shock.¹ In such cases, there is no time to transfer the patient to a referral hospital or wait for arrival of a specialist thoracic surgeon. In these circumstances, time is of the essence and niceties of sterility and meticulous dissection sometimes have to be sacrificed in order to save a life. A method of rapid access to intra-thoracic structures should be used.² The author found the method described above to be very useful for the management of major pulmonary injury as well as for cardiac injury, in contradistinction to sternotomy (or initial posterolateral thoracotomy). It is a simple procedure that requires no special equipment and can be practised by any general or trauma surgeon in a regional hospital.

Cross-clamping the hilum of the lung is a rapid and efficient method of gaining immediate control of haemorrhage and affords time for the anaesthetic team to resuscitate the patient before the surgeon continues to define the exact nature and extent of the injury.³ Such manoeuvre can salvage a number of patients with severely damaged pulmonary vessels. The mortality in such cases is high and even otherwise inevitable, especially in patients who require pneumonectomy in whom this procedure can nevertheless be life-saving. Reported survival rates for emergency thoracotomy in general range between 5 - 38%, and for true emergency department thoracotomy, this can be as low as 0%.³ Mortality for pulmonary lobectomy is up to 35% and for pneumonectomy up to 70%.⁴ This concurs with the high mortality rate of patients described above. Those procedures were desperate rescue operations: 9 cases were moribund on arrival and suffered cardiac arrest either pre- or intra-operatively. Half of the patients had associated organ injuries which contributed to mortality. Despite that, 42% were salvaged by rapid control of haemorrhage through the above approach and compare very favourably with the best published reports.

Recommendation: Patients with severe haemorrhage from thoracic trauma need emergency surgical intervention, if they are to be saved. All general surgeons should be able to perform resuscitation thoracotomy, which is easier and quicker than median sternotomy. This "across chest" thoracotomy as described above gives good access to both pulmonary

and cardiac injuries and should be within the realm of the general surgeon's technical competence.

REFERENCES

1. Hunt PA, Greaves I, Owens WA. Emergency thoracotomy in thoracic trauma: a review. *Injury* 2006; **37**:1-9.
2. Van Natta TL, Smith BR, Bricker SD. Hilar control in penetrating chest trauma: a simplified approach to an underutilized manoeuvre. *J Trauma Injury Infect Crit Care* 2009; **66**:1564-9.
3. Wise D, Davies G, Coats T, Lockey D, Hyde J, Good A. Emergency thoracotomy: how to do it. *Emerg Med J* 2005; **22**:22-4.
4. Huh J, Wall MJ, Estrera AL. Surgical management of traumatic pulmonary injury. *Am J Surg* 2003; **186**: 620-4.

