

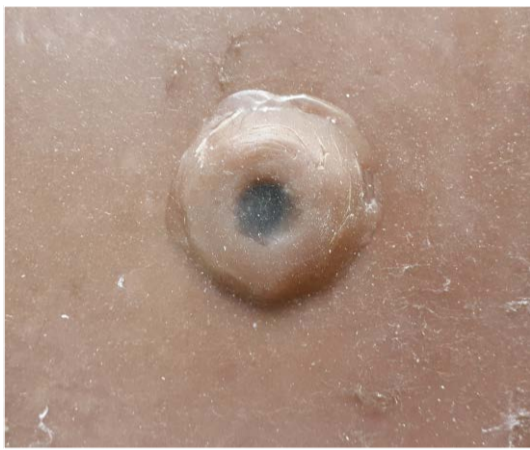Development of a diagnostic intradermal tuberculin test model for bovine tuberculosis

Michel AL.¹, Annandale A¹, Kok L¹

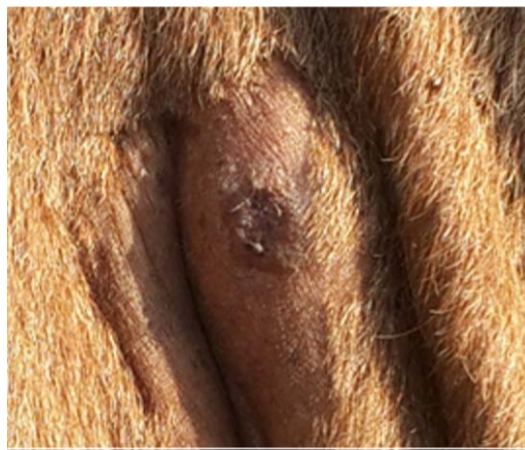
¹Faculty of Veterinary Science, University of Pretoria, South Africa



Reading of skin fold thickness by means of calipers in the live animal and the skin model



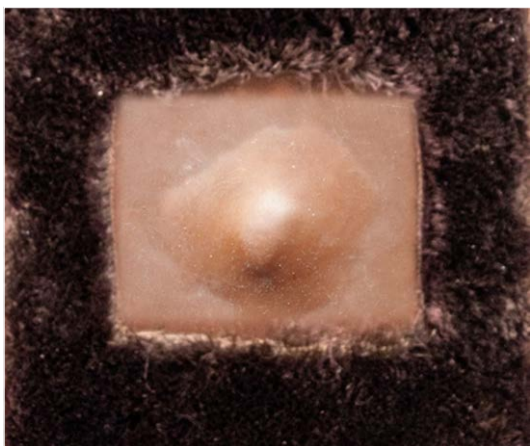
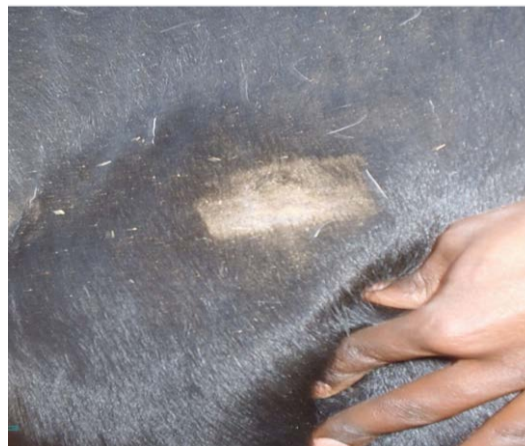Swelling with central necrosis



Circumscribed swelling



Oedema with diffuse swelling and adhesion



Oedema with diffuse swelling



Bovine tuberculosis (BTB), caused by *Mycobacterium bovis*, is a chronic debilitating infectious disease with a worldwide distribution. It affects a wide range of domestic and wild animal species as well as humans. In South Africa domestic cattle and African buffalo (*Syncerus caffer*) serve as reservoir hosts of this state controlled disease. Measures to control BTB are largely based on the intradermal tuberculin test.

The intradermal tuberculin test involves the evaluation of the host's delayed hypersensitivity reaction 72 hours after the intradermal injection of bovine and avian tuberculin. Interpretation of skin test reactions is based on measuring the increase in skin thickness using calipers, as well as the subjective evaluation of any clinical signs observed at the two injection sites such as oedema, necrosis, pain, heat and adhesion between the skin and subcutaneous tissue. The quality of the test outcome is highly dependent on the operator's acquired skills and experience in performing this test. Practical training of veterinary students in the correct execution of the skin test and interpretation of its outcome is therefore a critical Day 1 competency.

Materials

Bovine skin models were made of dragon skin and platinum cure silicon placed on aluminium clipper frames measuring 20x30 cm and covered with artificial hair. Five models were prepared simulating the following test outcomes:

- Prepared skin area for measurement and tuberculin injection
- Oedema with soft and diffuse swelling
- Circumscribed, hard swelling
- Swelling with adhesion between skin and subcutaneous tissue
- Swelling with central necrosis

A training manual describing all steps of the skin test procedure in detail and supported by illustrations was compiled to accompany the skills training using the skin models.



Skin test Training Manual



Faculty of
Veterinary Science

Fakulteit Veerartserykunde
Lefapha la Diseense tsa Bongakadiruwa