

Achalasia: Outcome in children

Anell Meyer^{1,2}, Anthony Catto-Smith^{1,3,4,5}, Joe Cramer⁶, Di Simpson¹, George Alex¹, Winita Hardikar^{1,3,4}, Donald Cameron^{1,3,4}, Mark Oliver^{1,3,4}

¹Department of Paediatric Gastroenterology, The Royal Children's Hospital Melbourne

² Department of Pediatrics and Child Health, University of Pretoria, South Africa

³Department of Paediatrics, University of Melbourne

⁴Murdoch Children's Research Institute, Melbourne

⁵Queensland University of Technology and Lady Cilento Children's Hospital, Brisbane

⁶Department of Surgery, The Royal Children's Hospital Melbourne.

Correspondence

Professor Anthony G Catto-Smith

Department of Gastroenterology, Hepatology and Liver Transplantation

The Lady Cilento Children's Hospital

501 Stanley St

South Brisbane

Queensland 4101

Australia

Email: acattosmith@gmail.com

Potential conflict of interest:

None of the authors have any conflicts of interest to disclose.

Additional Files

Figures 3

Tables 1

Supplementary data 1

Word count of manuscript

(4,428)

ABSTRACT

Background

Oesophageal achalasia is well-recognized but relatively rare in children, often appearing as “Triple A” syndrome (with adrenal insufficiency and alacrima). Treatment modalities based on adult practice are not curative, often needing further interventions and spurring the search for better management. The outcome for syndromic variants is unknown. We sought to define the efficacy of treatments for children with achalasia with and without Triple A syndrome.

Methods

We conducted a retrospective analysis of presentation and outcomes for 42 children with achalasia presenting over 3 decades to a major paediatric referral centre. Long term impact of the diagnosis was assessed by questionnaire.

Results

42 children, of median age 10.8 years were identified, 6 with triple A syndrome, with median follow-up 1593 days. Initial Heller myotomy in 17 required further interventions in 11 (65%), while initial treatment with botulinum toxin (n=20) was ultimately followed by myotomy in 17 (85%). Ten out of 35 patients who underwent myotomy required a repeat myotomy (29%). Patients with triple A syndrome were more underweight at diagnosis and at last follow up. Only 8 questionnaires were returned (19%). These suggested the condition had a significant ongoing deleterious impact on the quality of life of children and their families.

Conclusion

The outcome for children with achalasia remains disappointing. Many relapse after initial treatment, undergoing multiple, different procedures, despite which symptoms persist and impact

on quality of life. Symptoms develop earlier in patients with triple A syndrome, but the diagnosis is delayed and this has substantial nutritional impact.

(249 WORDS)

KEY WORDS

botulinum toxin, myotomy, complications, intervention, nutrition

INTRODUCTION

Achalasia is a rare condition in children, with an estimated incidence of approximately 1 case per 1,000 000 children.[1] It is characterized by failure of the lower oesophageal sphincter to relax completely during swallowing and the failure of the oesophageal smooth muscle to produce adequate peristalsis.[2] It has been proposed to result from oesophageal smooth muscle denervation after infection in a genetically susceptible patient.[2] An association is recognised with trisomy 21[3] and there is also a syndromic form - the so-called "Triple A syndrome" (achalasia, alacrima, and adrenal insufficiency).[4]

Adults and older children often present with progressive dysphagia, regurgitation of poorly digested food, weight loss and chest pain.[2] In contrast, vomiting, anorexia and chronic cough are said to be more common presenting features in children under five years of age.[5]

Diagnosis in children is based on criteria that have been established in adult patients and include a combination of oesophageal contrast studies, manometry and endoscopy.[2]

Treatment options aim to control symptoms by relieving the obstruction provided by the non-relaxing lower oesophageal sphincter. Importantly, none of these treatments provides a complete cure. Surgical intervention in the form of myotomy has been the traditional approach via either a laparotomy or thoracotomy.[6] Since the 1990's laparoscopy and thoracoscopy have been employed[7] with more recently peroral endoscopic myotomy (POEM).[8, 9] Other approaches include pneumatic balloon dilatation,[10, 11] against which myotomy is often contrasted.[12, 13] Botulinum toxin has been used successfully in selected patients, given by an endoscopically directed injection into the oesophageal muscle around the lower oesophageal sphincter.[14, 15] Pneumatic balloon dilatation and botulinum toxin injection have been proposed to be more effective, with fewer complications and less costly, but most adult studies still rank myotomy as the gold standard, reserving other treatments for selected cases or treatment failure.[9, 15] However, the advent of

modern manometric techniques has reinforced the recognition that there is a wide clinical spectrum of achalasia.[16] Differing treatment approaches may be more likely to be effective in some subtypes, and many patients may never proceed to any therapeutic intervention at all.[16, 17] The relative efficacy of myotomy and pneumatic dilatation in children remains controversial.[13]

The Royal Children's Hospital Melbourne [RCH] as a major referral centre for children in the state of Victoria, Australia, has embraced these changing approaches to treatment of achalasia in children over the years. In the 1980's surgical myotomy was the only treatment modality available. Pneumatic balloon dilatation was introduced in 1992 and this was followed by intramuscular botulinum toxin in 1997.[18] Laparoscopic and thoracoscopic surgical approaches to myotomy were introduced in 1999. Fundoplication at the time of the primary surgery has not been advocated by the surgical team over the last 3 decades. POEM has yet to be introduced at this site.

The aims of our study were 1) to describe the clinical findings, therapeutic interventions and long-term outcome, including nutritional status, of a 3 decade cohort of children with achalasia, 2) contrast the outcome of initial treatment with myotomy as against botulinum toxin, 3) and to determine if an association with triple AAA syndrome influenced diagnosis or outcome.

METHODS

Patients treated for achalasia at RCH from 1982 to 2013 were identified from the hospital information systems using the ICD 10 code for achalasia. Records were assessed and patients were included in the study only if they had a confirmed diagnosis of achalasia which was required to include 1) a barium swallow that was consistent with the diagnosis and included the radiological findings of a bird's beak appearance of the lower oesophageal sphincter (LOS) with incomplete opening, loss of primary peristalsis and poor oesophageal clearance and/ or 2) oesophageal manometry showing aperistalsis and/or low amplitude of oesophageal contractions in the lower two thirds of this organ plus failure of complete relaxation of the LOS,[19] and 3) upper gastrointestinal endoscopy and oesophageal biopsies excluding conditions such as a peptic stricture and eosinophilic oesophagitis. Patients with an alternative diagnosis were excluded.

Once patients were identified as having achalasia based on the above-mentioned diagnostic criteria, data were collected from the medical record and included demographics, symptoms at presentation, associated syndromes and diseases, details of investigations, treatment options and outcomes. We then attempted to obtain further follow up information by questionnaire. The questionnaire included current symptoms possibly related to achalasia, medical follow-up, treatment interventions and the impact of achalasia on the patients' quality of life. An attempt was made to contact patients no longer receiving treatment at the RCH. If the patient had not been seen at the RCH since 01 July 2011 a letter was sent to the last known patient address in the medical records. Patients were invited to respond by post, e-mail or telephone if they were willing to participate in the study. A questionnaire and informed consent form was then sent to all respondents who indicated that they were willing to participate.

The primary surgical intervention was myotomy performed by one of eight staff surgeons; the surgical approach used for each patient being chosen by the surgeon. This varied over the 3 decade study period and included both open and minimally invasive approaches which were performed

according to standard accepted techniques. Non-surgical interventions included: 1) the use of calcium channel blockers at recommended doses, 2) endoscopic intra-sphincteric injection of Clostridium botulinum toxin type A (Botox, Allergan Australia Pty Ltd, Gordon, NSW, Australia), [14, 18] and 3) pneumatic dilation using either air or fluid filled balloons performed by either by radiologists or gastroenterologists.

Failure to respond to treatment was determined by the gastroenterologist caring for the child and was defined as regular symptoms (often noted in the medical record as every 1-2 days) consistent with achalasia and interfering with the quality of life based on the physician's clinical review. In selected patients, repeat contrast and manometry studies were performed. Subsequent interventions were also chosen by the gastroenterologist caring for the child. These were documented as were the outcomes and complications.

Analysis

Normally distributed data are presented as mean \pm standard deviation, or as median and interquartile range (IQR) if skewed. Analyses were performed using GraphPadPrism 5 (GraphPad Software Inc. La Jolla, CA, USA) using appropriate tests for normally distributed or non-parametric data.

Ethical considerations

The Royal Children's Hospital Human Research Ethics Committee approved project HREC33226, which was carried out in accordance with the ethical standards laid down in the 1964 Declaration of Helsinki and its later amendments. Informed consent was obtained from all patients completing the questionnaire.

RESULTS

Demographics

Forty-seven children had been coded with the diagnosis of achalasia during the study period. Five had been incorrectly coded, two having had oesophageal strictures while the others had eosinophilic oesophagitis, familial dysautonomia or scleroderma. There was an equal distribution of both genders [21 males and 21 females]. The median age at diagnosis was 10.8 years (IQR 7.8, 13.1). The median duration of symptoms prior to diagnosis was 233 days (IQR 146, 617). The median follow up was 1593 days (IQR 391, 3143).

Six patients were diagnosed between 1982-1993, 15 from 1994-2003 and 21 from 2004-2013.

Associated syndromes/disorders

Nine of 42 (21%) had an associated syndrome or chromosomal abnormality. Six patients were diagnosed with triple A syndrome and two patients with trisomy 21. Another infant presented with psoriasis and a chromosomal abnormality (deletion of chromosome 8p23.3p23.1 and duplication of chromosome 12p13.33p13.31).

Symptoms at presentation (Table 1)

The main symptoms were: regurgitation of poorly digested food, dysphagia, weight loss and vomiting.

Diagnostic investigations

All 42 patients underwent an upper gastrointestinal barium contrast study, with all fulfilling the radiological requirements for diagnosis. Manometry was performed in 38 patients. Two had been too young to tolerate the procedure, and the result was not available in the records of a further two patients. Confirmatory manometric studies had been performed by 3 gastroenterologists, using

Table 1: Presenting Features

Symptom or clinical feature	n=42 (%)
Regurgitation of poorly digested food	34 (83%)
Dysphagia	31 (76%)
Weight loss	31 (76%)
Vomiting	27 (66%)
Nocturnal cough	23 (56%)
Recurrent respiratory infections	16 (39%)
Chest pain	14 (34%)
Choking	13 (32%)
Alacrima	7 (17%)
Addison's disease	5 (12%)
Nausea	2 (5%)

either a water perfused system with station pull-through technique (n=33) or more recently high resolution manometry (n=5). All had undergone gastroscopy with oesophageal biopsies. One child additionally had eosinophilic oesophagitis whilst all the others had nonspecific histopathological findings.

Primary surgical treatment and outcomes (Figure 1).

Seventeen of the 42 patients underwent a myotomy as first-line treatment. Persistent or recurrent symptoms in 11 (65 %) required further interventions after a median 1993 days (IQR 223, 2196). Of these 11, 5 received botulinum toxin after the initial failed myotomy, and 5 had a pneumatic dilatation. Two of the 5 who received botulinum toxin as a secondary treatment had a sustained response, whereas 4 of the 5 who received a pneumatic dilatation as a secondary treatment had a sustained response ($p=0.52$). Five children of the 11 (41 %) ultimately underwent a second myotomy.

Primary non-surgical treatment and outcomes (Figure 2)

Twenty-four patients had non-surgical primary treatment (botulinum toxin [n=20], pneumatic dilatation [n=3] and medical treatment [n=1]). One patient did not receive any treatment.

Further injections of botulinum toxin were provided if and when the effect wore off. The median total number of additional botulinum toxin injections per patient was 2.0 (IQR 1.8, 6.5) and maximum 15. No complications were recorded in the patient records for the 112 Botulinum toxin injections. At the time of this report, 3 of these 20 patients had transitioned to adult care without receiving alternative therapies after 11, 10 and 5 years of botulinum toxin treatments. Of the 17 other patients, all ultimately underwent a Heller's myotomy as a subsequent procedure, which had to be repeated in five patients. The median interval before receiving an alternative intervention was 434 days (IQR 69, 1367).

Figure 1.
Outcome after myotomy as a primary procedure.

Figure 1

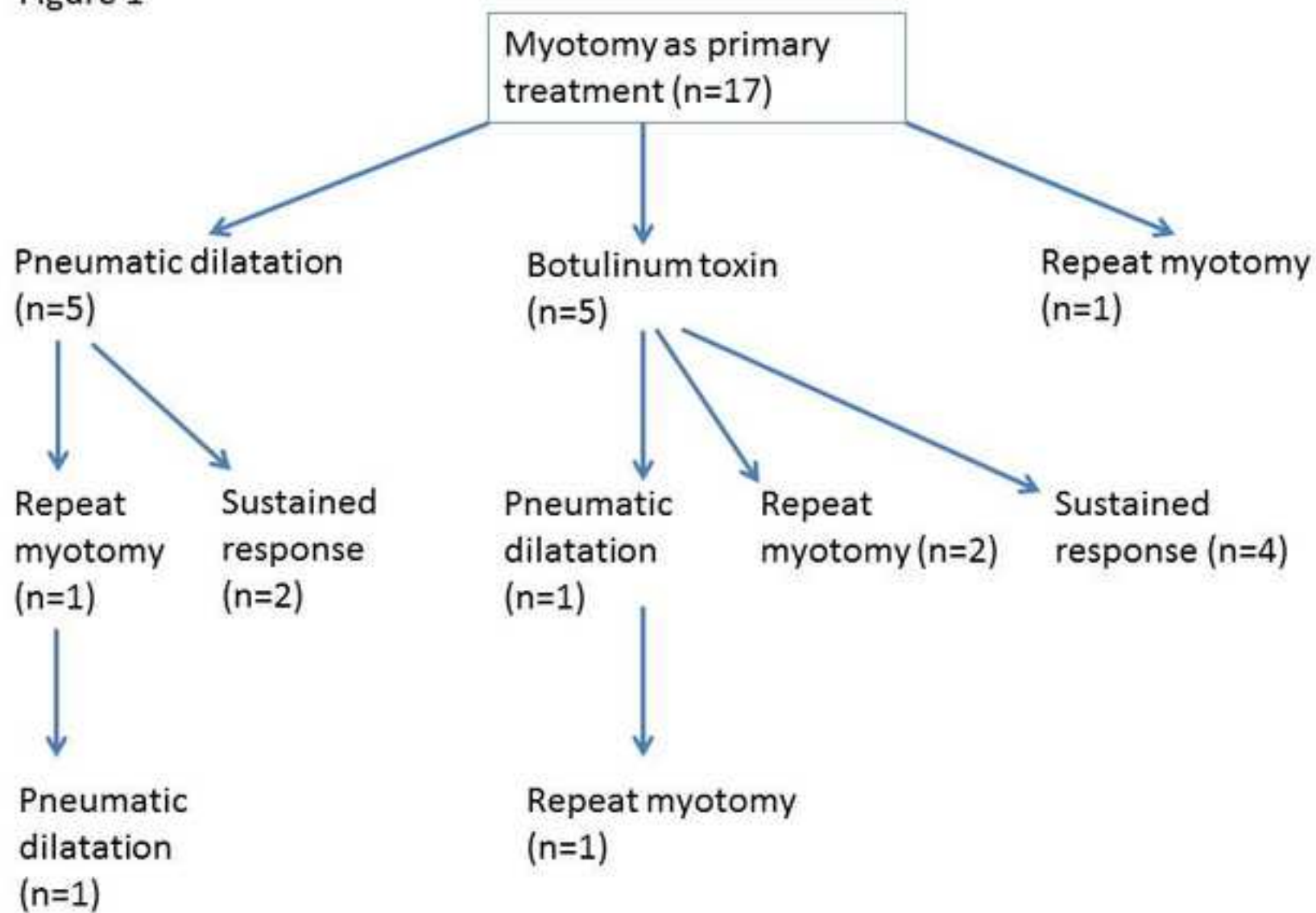
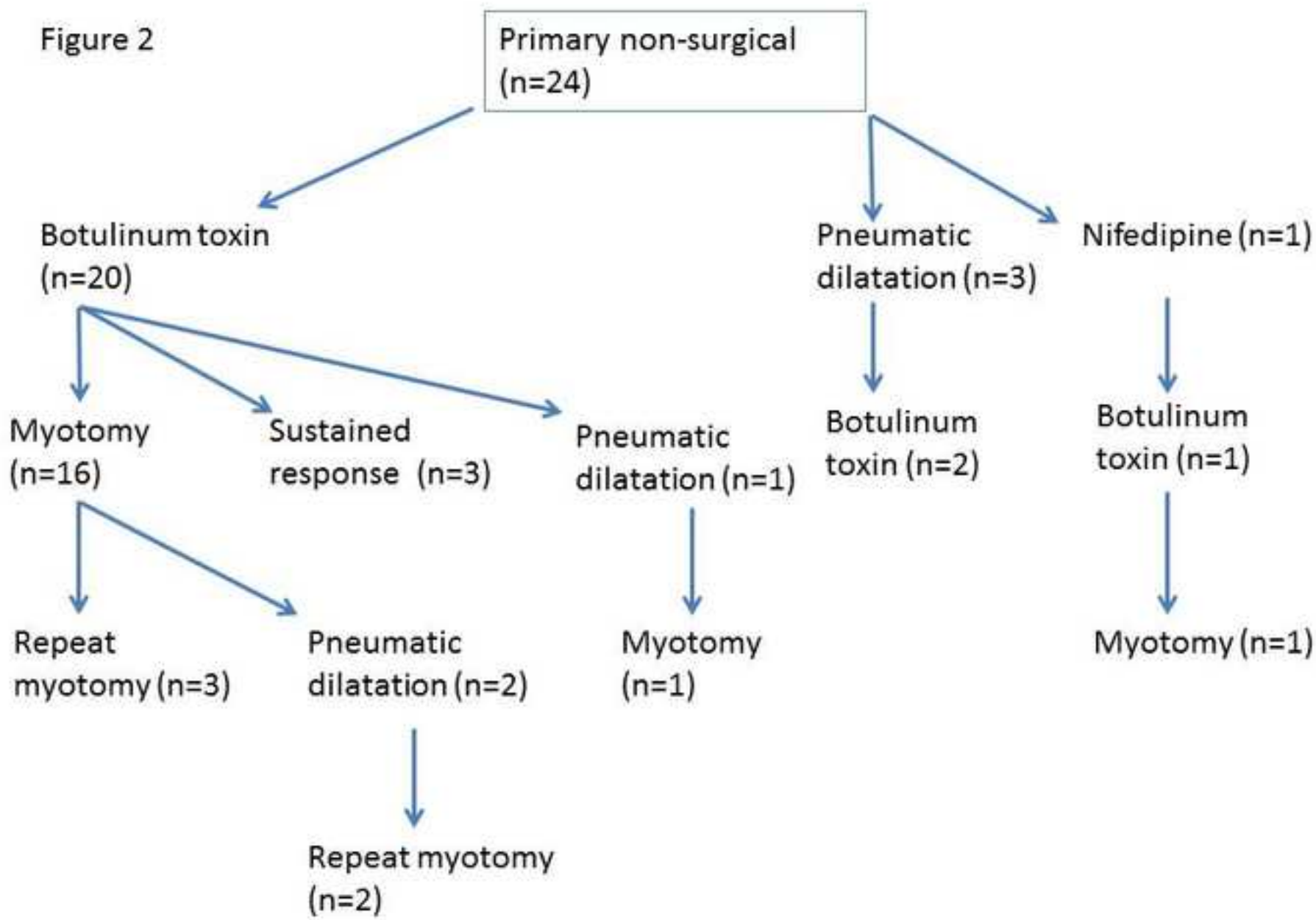


Figure 2.
Outcome after a non-surgical primary approach.



Of the 17 patients who underwent a myotomy after botulinum toxin, 3 had a major complication in the immediate post-operative phase. Two had gastric perforations and one child developed a pneumomediastinum.

Comparison of myotomy and Botulinum toxin as primary procedures (Figure 3)

85% of patients who had botulinum toxin injections as their first treatment received an alternate form of therapy. This occurred after a median 434 days. By comparison, where a myotomy was offered as the first treatment, 65% were offered further therapy after a median 1993 days (fig 3). Neither the proportion who failed to achieve a sustained response, nor the interval before a secondary treatment was offered, was significantly different between the two groups ($p=0.46$, $p=0.22$ respectively).

Overall, 35 patients underwent a myotomy either as a primary or subsequent procedure. In 27/41 patients, a myotomy was the final intervention provided, but 10 patients required 2 myotomies.

The likelihood of proceeding to a second myotomy was not influenced by the primary treatment. Of those patients who had an initial myotomy, 5/17 required a repeat myotomy. Of those who had Botulinum toxin initially but then proceeded to a myotomy, 5/15 required a repeat myotomy.

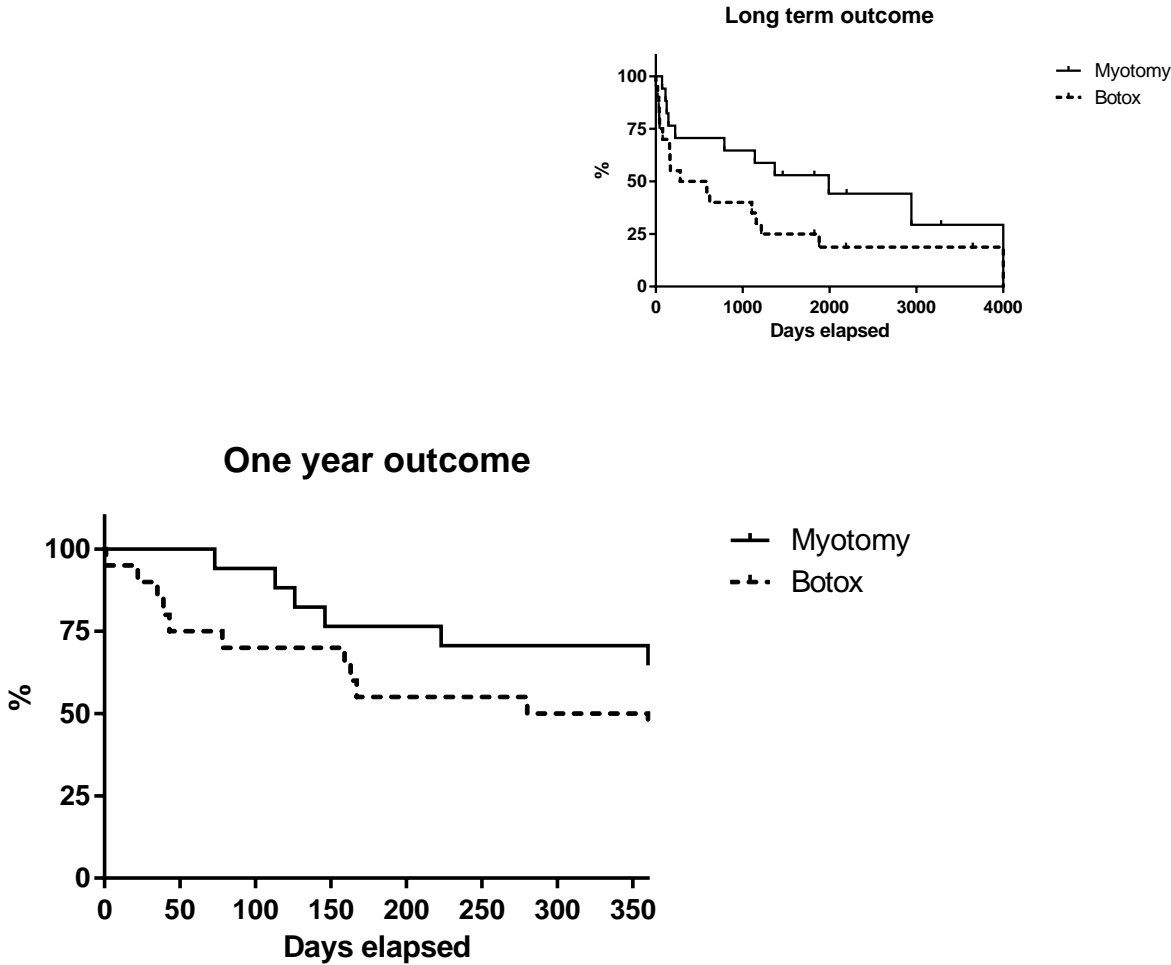
Eight surgeons operated on the patients over 30 years. One surgeon performed 21 of 40 operations that were documented in the medical records. Comparison of the outcomes of this surgeon with those of the other 7 with regard to surgical failure and need for a re-do operation, showed no statistically significant differences, with a failure rate of 31 % vs 26 %, $p=0.84$.

Number of interventions and subsequent duration of response

Excluding repeated injections of botulinum toxin, 84 interventions were performed on 41 patients. Of those 28 who were treated with botulinum toxin at any stage, the median number of repeat treatments was 2 (IQR 1, 6), but with a maximum of 15.

Figure 3.

Proportion of patients proceeding to further treatment because of failure of the initial therapy with either myotomy or Botulinum toxin. There was no significant difference in the median interval before subsequent treatment (log-rank test; $p=0.15$).



Myotomy was the preferred “second-line” therapy after failure of the initial intervention (n=16), with Botulinum toxin being used as a “second-line” therapy in 8 patients, and pneumatic dilatation in 6.

When a third type of intervention was offered, myotomy was preferred (n=7), with 3 receiving pneumatic dilatation.

Two patients underwent a fundoplication for reflux as part of a myotomy as a second or third intervention.

Nutritional status

The mean weight-for-age Z-score (WAZ) at presentation was -1.05 ± 1.53 . This had improved significantly after all treatment interventions had been completed (WAZ -0.74 ± 1.49 ; $p < 0.005$).

The type of initial intervention, myotomy or Botulinum toxin, did not impact on the ultimate likelihood of a statistically significant WAZ gain, and there was no significant difference in the degree of gain in WAZ between the two (supplementary data).

Triple A syndrome

The six patients with triple A syndrome were compared to the 33 who did not have either a syndrome or recognised chromosomal abnormality. Although those with triple A syndrome developed their first symptoms significantly earlier (6.2 ± 3.7 yr vs 9.7 ± 3.8 yr; $p < 0.05$), these symptoms were present for a greater length of time before the diagnosis was achieved (549 ± 510 days vs 328 ± 340 days; $p < 0.01$). There was no significant difference between the two groups in type of presenting symptom. However, those with triple A syndrome were significantly underweight at diagnosis (WAZ -2.9 ± 1.6) compared to those who had neither a syndrome nor chromosomal abnormality (WAZ -0.6 ± 1.2 ; $p < 0.001$).

The choice of initial therapy was similar for the two groups, whether Heller procedure (1/6 vs 15/33) or botulinum toxin (3/6 vs 16/33). Where botulinum toxin was used, both had a similar number of treatments (4.7 ± 3.6 vs 3.9 ± 4.1 ; $p=0.42$). However, there was a suggestion that those with triple A syndrome waited a longer time before a second therapy was offered (triple A 1670 ± 1639 days vs 732 ± 1071 days; $p=0.068$).

Patients with triple A syndrome achieved significant weight gain between diagnosis and at last follow up (mean improvement in triple A WAZ 1.25 ± 1.11 ; $p<0.05$). However, their mean weight remained significantly less than the general population after a mean follow up period of 4363 ± 3100 days (WAZ -1.67 ± 1.77 ; $p<0.05$). In those without a syndromic or chromosomal association the mean change in WAZ after treatment was 0.40 ± 1.03 ($p=0.07$). Their WAZ at last recorded follow up (after a mean 1800 ± 1640 days) was -0.46 ± 1.39 . This was not significantly different from the general population ($p=0.10$).

Questionnaire

Questionnaires were sent to 42 patients or families. Thirty of these did not respond, 3 refused to participate, one had died of other causes and 8 completed and returned the questionnaires. The mean age at completion of the questionnaire was 18.6 ± 3.7 yr (5M:3F).

Apart from one patient, who was still receiving regular botulinum toxin injections, all had either initially or ultimately undergone a Heller's myotomy. The median interval since the myotomy (or repeat procedure if necessary), was 43 mo (IQR 7.5, 94.4).

All but one of the 8 patients was still seeing a medical practitioner regularly, either monthly ($n=1$), 6 monthly ($n=3$), or annually ($n=3$). Four had developed further medical problems or undergone further surgical procedures since being discharged from the Children's Hospital.

Episodes of “food-sticking in the throat” occurred daily in 6 out of the 8 or at least weekly in the other two. Five of the eight patients who completed the questionnaire reported difficulty in eating in public or with their peers. Chest pain was experienced daily by 3, at least weekly by 2 and at least monthly by 3 of the 8. Regurgitation was present on a daily basis for 2 patients, weekly for 1, 2 monthly for 2 but hardly ever in 3 of the 8. Their mean BMI was 19.5 ± 2.6), but two of the patients aged over 18 were underweight with a BMI less than 18.5 (15.4, 17.8).

Five of the eight reported that achalasia had a significant impact on their quality of life. Complete avoidance of social gatherings was reported by four of the five patients. Three of the five patients had been diagnosed with an anxiety disorder. One patient reported that his significant weight loss was traumatic for his parents, because of accusations by the community and health care workers that they had been underfeeding him.

DISCUSSION

Our study has described the therapeutic approaches, short and long term outcome of a group of 42 children diagnosed with oesophageal achalasia over three decades in one institution.

Achalasia is an oesophageal neuropathy which results in loss of normal peristaltic function in the oesophageal body and impaired emptying from failure of normal relaxation of the lower oesophageal sphincter. Current treatments are designed to destroy the function of the lower oesophageal sphincter and do not address the intrinsic neuropathy.[2]

We identified 42 patients over this period, corresponding to an identification rate of approximately 0.13 per 100,000 children aged less than 16 years (the birth rate in Victoria is approximately 62,000pa). This is similar to the incidence rate identified in the UK (0.18 per 100,000 people aged less than 16yr)[1] and suggests a high rate of recruitment.

Recognising that no one treatment appears to be perfect, there have been changing approaches to therapy over time, with a willingness to provide alternatives to myotomy. The limitations of this study are also the range of treatments offered, with the choice of initial therapy coming from agreement between the practitioner and family, recognising that surgical myotomy was not a cure-all.

Primary myotomy, which was the main initial approach historically, was only effective by itself in approximately one third of patients, with two thirds going on to have a further procedure. One limitation of the retrospective nature of this study is that failure of the initial procedure was judged by the provision of a secondary procedure. There may have been patients with recurrent symptoms who did not proceed to other procedures. The median interval before a secondary treatment was carried out – nearly 6 years – suggested protracted symptoms, or perhaps progressive disease. Alternative therapies may have not been easily available for some of the

patients in this study. The first half of this study predated the availability of botulinum toxin for this condition.

Botulinum toxin, which was offered as a primary therapy in approximately half of the patients, had a temporary impact. It was on average repeated up to twice or occasionally many more times than this, with most patients ultimately proceeding to a myotomy. About one third of this group required further surgery after the myotomy. There were no significant complications associated with the botulinum toxin treatments themselves, though each required day case endoscopy.

Several quite significant complications occurred after myotomy in the group initially treated with botulinum toxin. An increased risk of complications after prior endoscopic therapy has previously been suggested.[2] Both botulinum toxin and pneumatic dilatation have been implicated as adding to that risk.[20] Intraoperative oesophageal and gastric perforations are the most commonly reported immediate complications, occurring in about 6% of procedures[2], but are usually recognised and repaired intraoperatively without clinical consequence.

Most children were significantly underweight by the time they had surgery, but this improved significantly after both myotomy and botulinum toxin injection.

Pneumatic dilatation was also offered in this group of patients, but too few to offer statistical inference. Recent trials of pneumatic dilatation against myotomy have suggested the two are broadly comparable.[21]

Some authors suggest that up to 90% of patients treated for achalasia can achieve near normal swallowing and quality of life after a combination of current treatments.[22] The difficulty is that even in the best of centres, most need further multiple treatments.[2] The disease is also progressive.

We attempted to evaluate long term outcome for quality of life. Unfortunately, only 20% of our patients or families consented to the evaluation. Most of these patients were not doing well, with many having persistent symptoms and a poor quality of life. Several were significantly underweight. It may be dangerous to extrapolate from this small group, but it would be safe to say that significant symptoms do appear to persist in at least a small proportion, with long term impact on the family and patient.

Recognising the failure of any one therapy to be uniformly successful, it has been suggested that treatments be directed to clinical subtypes.[2] Evidence suggests that manometric subtyping can help predict likelihood of response to surgery.[23] Patients with type III disease appear to respond better to Heller myotomy than pneumatic dilatation,[23] whereas there is little difference between the two for type I and II disease.

There do appear to be clear differences in the presentation of achalasia in children with triple A syndrome compared to those without either a triple A syndrome or a chromosomal abnormality. For some reason, although symptoms developed earlier, they took longer to diagnose and these children were significantly malnourished by the time diagnosis and treatment were offered. They were still significantly underweight at the time of last follow up. Whether this was related to the syndrome itself or was a legacy of the prolonged malnutrition prior to diagnosis and treatment is not clear. Certainly, their response to treatment appeared no different to other children, and they did not receive palliative therapy. This may well represent a high risk group who merit close postoperative follow up with attention to nutritional rehabilitation.

There are no clear separate recommendations for treatment of children with achalasia, but there is increasing agreement for treatment pathways in adults which do inform therapeutic decisions in children.[24] Healthy patients with achalasia should be offered graded pneumatic dilatation or myotomy. Myotomy is likely to be more effective treatment in adolescents and younger adults, especially men and possibly patients with type III achalasia. Women and older

adults do well with either myotomy or pneumatic dilatation. It is not clear if these same gender implications exist in children. Botulinum toxin should be the first line treatment in frail patients because it is safe and likely only to be needed to be repeated every 9-12 months. Pneumatic dilatation has also been suggested as a safe alternative for frail patients but with the caveat it be used in high volume centres, which excludes paediatric units. Although there is experience of using the promising[25] and more recently introduced peroral endoscopic myotomy (POEM) in children[8], its role has yet to be more closely defined.

It has been argued that routine post-operative manometric evaluation should be used to help predict outcome and better define those patients who are likely to need further intervention. [2] The following functional parameters have been associated with poor outcome after treatment in adults: 1) failure to empty the oesophagus of barium after 5min upright, 2) failure to completely relieve symptoms after the primary intervention, 3) post-procedure lower oesophageal sphincter pressures greater than 10-15mmHg, and 4) limited distensibility of the oesophago-gastric junction.[2]

There is a strong case to be made for the routine evaluation of physiological function after treatment of achalasia in children to help inform and guide subsequent interventions, particularly in high risk clinical subtypes.

REFERENCES

1. Marlais M, Fishman JR, Fell JM, Haddad MJ, Rawat DJ. UK incidence of achalasia: an 11-year national epidemiological study. *Arch Dis Child*. 2011;96(2):192-4. Epub 2010/06/03.
2. Boeckxstaens GE, Zaninotto G, Richter JE. Achalasia. *Lancet*. 2014;383(9911):83-93. Epub 2013/07/23.
3. Moore SW. Down syndrome and the enteric nervous system. *Pediatr Surg Int*. 2008;24(8):873-83. Epub 2008/07/18.
4. Milenkovic T, Zdravkovic D, Savic N, Todorovic S, Mitrovic K, Koehler K, et al. Triple A syndrome: 32 years experience of a single centre (1977-2008). *Eur J Pediatr*. 2010;169(11):1323-8. Epub 2010/05/26.
5. Lee CW, Kays DW, Chen MK, Islam S. Outcomes of treatment of childhood achalasia. *J Pediatr Surg*. 2010;45(6):1173-7. Epub 2010/07/14.
6. Nau P, Rattner D. Laparoscopic Heller myotomy as the gold standard for treatment of achalasia. *J Gastrointest Surg*. 2014;18(12):2201-7. Epub 2014/09/11.
7. Stefanidis D, Richardson W, Farrell TM, Kohn GP, Augenstein V, Fanelli RD. SAGES guidelines for the surgical treatment of esophageal achalasia. *Surg Endosc*. 2011;26(2):296-311. Epub 2011/11/03.
8. Li C, Tan Y, Wang X, Liu D. Peroral endoscopic myotomy for treatment of achalasia in children and adolescents. *J Pediatr Surg*. 2015;50(1):201-5. Epub 2015/01/20.
9. Caldaro T, Familiari P, Romeo EF, Gigante G, Marchese M, Contini AC, et al. Treatment of esophageal achalasia in children: Today and tomorrow. *J Pediatr Surg*. 2015;50(5):726-30. Epub 2015/03/19.
10. Di Nardo G, Rossi P, Oliva S, Aloï M, Cozzi DA, Frediani S, et al. Pneumatic balloon dilation in pediatric achalasia: efficacy and factors predicting outcome at a single tertiary pediatric gastroenterology center. *Gastrointest Endosc*. 2012;76(5):927-32. Epub 2012/08/28.
11. Tanaka Y, Iwakiri K, Kawami N, Sano H, Umezawa M, Kotoyori M, et al. Predictors of a better outcome of pneumatic dilatation in patients with primary achalasia. *J Gastroenterol*. 2009;45(2):153-8. Epub 2009/11/19.
12. Hamdy E, El Nakeeb A, El Hanfy E, El Hemaly M, Salah T, Hamed H, et al. Comparative Study Between Laparoscopic Heller Myotomy Versus Pneumatic Dilatation for Treatment of Early Achalasia: A Prospective Randomized Study. *J Laparoendosc Adv Surg Tech A*. 2015;25(6):460-4. Epub 2015/05/08.
13. Sharp NE, St Peter SD. Treatment of Idiopathic Achalasia in the Pediatric Population: A Systematic Review. *Eur J Pediatr Surg*. 2015. Epub 2015/02/03.
14. Pasricha PJ, Ravich WJ, Hendrix TR, Sostre S, Jones B, Kalloo AN. Intraspincteric botulinum toxin for the treatment of achalasia. *N Engl J Med*. 1995;332(12):774-8. Epub 1995/03/23.
15. Familiari P, Greco S, Volkanovska A, Gigante G, Cali A, Boskoski I, et al. Achalasia: current treatment options. *Expert Rev Gastroenterol Hepatol*. 2015;9(8):1101-14. Epub 2015/07/18.
16. Torresan F, Ioannou A, Azzaroli F, Bazzoli F. Treatment of achalasia in the era of high-resolution manometry. *Ann Gastroenterol*. 2015;28(3):301-8. Epub 2015/07/02.
17. Yeung JC, Finley C, Hanna WC, Miller L, Ferri L, Urbach DR, et al. Treatment choices and outcomes of patients with manometrically diagnosed achalasia. *Dis Esophagus*. 2015. Epub 2015/03/27.
18. Ip KS, Cameron DJ, Catto-Smith AG, Hardikar W. Botulinum toxin for achalasia in children. *J Gastroenterol Hepatol*. 2000;15(10):1100-4. Epub 2000/12/06.
19. Vaezi MF, Richter JE. Diagnosis and management of achalasia. American College of Gastroenterology Practice Parameter Committee. *Am J Gastroenterol*. 1999;94(12):3406-12. Epub 1999/12/22.

20. Portale G, Costantini M, Rizzetto C, Guirroli E, Ceolin M, Salvador R, et al. Long-term outcome of laparoscopic Heller-Dor surgery for esophageal achalasia: possible detrimental role of previous endoscopic treatment. *J Gastrointest Surg.* 2005;9(9):1332-9. Epub 2005/12/08.
21. Boeckstaens GE, Annese V, des Varannes SB, Chaussade S, Costantini M, Cuttitta A, et al. Pneumatic dilation versus laparoscopic Heller's myotomy for idiopathic achalasia. *N Engl J Med.* 2011;364(19):1807-16. Epub 2011/05/13.
22. Vela MF, Richter JE, Wachsberger D, Connor J, Rice TW. Complexities of managing achalasia at a tertiary referral center: use of pneumatic dilatation, Heller myotomy, and botulinum toxin injection. *Am J Gastroenterol.* 2004;99(6):1029-36. Epub 2004/06/08.
23. Rohof WO, Salvador R, Annese V, Bruley des Varannes S, Chaussade S, Costantini M, et al. Outcomes of treatment for achalasia depend on manometric subtype. *Gastroenterology.* 2013;144(4):718-25; quiz e13-4. Epub 2013/01/02.
24. Richter JE, Boeckstaens GE. Management of achalasia: surgery or pneumatic dilation. *Gut.* 2011;60(6):869-76. Epub 2011/02/10.
25. Patel K, Abbassi-Ghadi N, Markar S, Kumar S, Jethwa P, Zaninotto G. Peroral endoscopic myotomy for the treatment of esophageal achalasia: systematic review and pooled analysis. *Dis Esophagus.* 2015. Epub 2015/07/16.

Supplementary data

Change in mean WAZ with treatment (\pm standard deviation). NS = not statistically significant

	WAZ	WAZ		WAZ	
Initial therapy	At diagnosis	At discharge	P value	Change	P value
Botulinum toxin	-0.97 \pm 1.58)	-0.86 \pm 1.48)	<0.05	0.38 \pm 0.71)	NS
Myotomy	-0.87 \pm 1.46)	-0.32 \pm 1.48)	<0.05	0.84 \pm 1.45)	
Overall	-1.05 \pm 1.53)	-0.74 \pm 1.49)	<0.05		