

An insight into the malocclusion of cleidocranial dysplasia

SADJ June 2012, Vol 67 no 5 p216 - p220

WR Nel¹, SM Dawjee², AW van Zyl³

"The Journal recognises the celebration of the Department of Orthodontics, University of Pretoria... a fiftieth birthday this year! Over the years so many developments, so many achievements, so wonderful a service to the profession and, importantly, to the country. This paper is part of those celebrations! Every congratulation!" - Editor



INTRODUCTION

Cleidocranial dysplasia (CCD), formerly known as Cleidocranial dysostosis, is a rare congenital disorder of bone that is characterised by aplasia of, or deficient, clavicular formation, delayed and imperfect ossification of the cranium, relatively short stature and a variety of other skeletal abnormalities. Oral manifestations include a delayed exfoliation of primary teeth, delayed or failed eruption of the permanent teeth, and multiple supernumerary teeth, as many as 63 having been reported in one patient.¹

According to Gorlin, Cohen and Hennekam,² clavicular defects were first reported by Martin in 1765 and the term Cleidocranial dysplasia was first used by Marie and Sainton in 1897.

GENETIC PROFILE

The gene responsible for CCD has been mapped on the short arm of chromosome 6p21, core binding factor α -1 (CBFA1). This rare disorder can be caused by a mutation in transcription factor CBFA1 (RUNX2).³⁻⁵

The CBFA1 gene controls differentiation of progenitor cells into osteoblasts and is thus pivotal in bone formation, which may be related to delayed ossification of the skull, pelvis, and clavicles.⁶

CCD affects one per million children and has autosomal dominant inheritance. Twenty to forty percent of cases present as new mutations.²

CLINICAL FEATURES

Extra-oral

Hypoplasia or aplasia of the clavicles is the most characteristic and pathognomonic feature of this disorder, which results in hypermobility of the shoulders allowing the patients to approximate the shoulders in the midline. The skull and

facial appearance may also be characteristic. Delayed ossification of the cranial sutures and fontanelles occurs and may remain open throughout life. The skull is usually large and broad with a brachycephalic appearance.^{7,8} Patients are moderately small with abnormally short arms and legs.⁹ Other extra-oral features include brachycephalism, frontal and parietal bossing, hypertelorism, narrow and drooped shoulders, retarded growth of the long bones expressed as dwarfism and a long neck.

Intra-oral

According to Becker *et al.*¹⁰ common dentoalveolar characteristics include:

1. over-retained primary teeth with unresorbed roots;
2. developing permanent teeth that are displaced by supernumerary teeth and subsequent obstruction of their eruption;
3. retarded eruption;
4. reduction of lower facial height and a skeletal Class III tendency due to underdevelopment of the maxilla and an upward and forward mandibular rotation. Reduced vertical development of alveolar bone, with shallow buccal and lingual sulci;
5. a late, but spontaneous, eruption of first and usually second permanent molars in both jaws;
6. permanent teeth with delayed root development, in some cases by up to three years.

It has been hypothesised that incomplete or delayed resorption of the dental lamina results in the formation of supernumerary teeth.¹¹

Delayed tooth eruption may be attributed to:

1. greater than normal bone density of the jaws;¹²
2. failure of bone to resorb;^{13,14}
3. a reduced capacity of the periodontal ligament cells to induce differentiation to active osteoclasts.¹⁵

1. **WR Nel:** BChD, Dip.Odont(Perio), PDD(Ortho). Department of Orthodontics, University of Pretoria.
2. **SM Dawjee:** BChD, BChD(Hons), MSc(Odont), MDent(Ortho), PGDiplRE, PhD. Department of Orthodontics, University of Pretoria.
3. **AW van Zyl:** BChD, MChD(OMP). Department of Periodontics and Oral Medicine, University of Pretoria.

Corresponding author

WR Nel:
Tel : 012 319 2510. Cell: 072 820 8656. E-mail: Wally.Nel@up.ac.za



Figure 1a: Frontal view

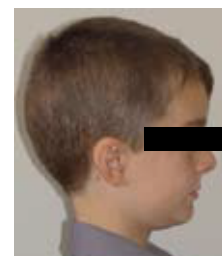

Figure 1b: Lateral view




Figure 1c: Shoulders approximating

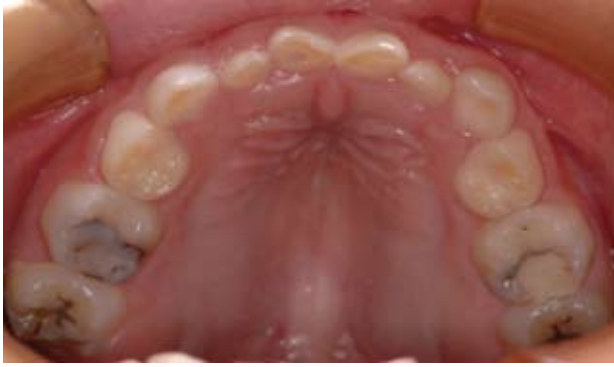

Figure 2: Maxillary arch.

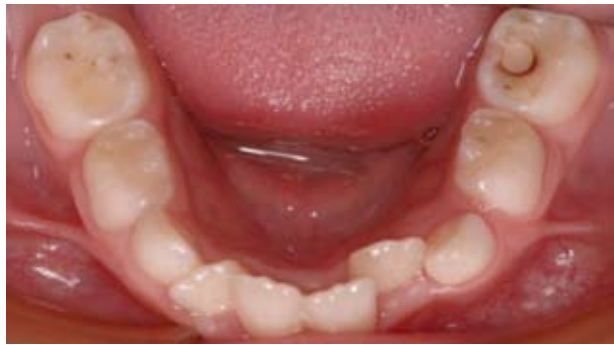

Figure 3: Mandibular arch.

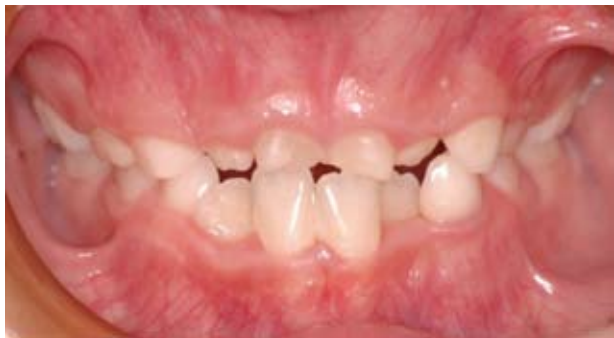

Figure 4: Frontal in occlusion.

Other oral manifestations include high arched palate, sub-mucous cleft palate, poor development of the premaxilla and delayed union of the mandibular symphysis.²

DIAGNOSIS

Where the condition has a suspected family history, the diagnosis can be made prenatally by:

- ultra- sound scanning (sonography); and/or
- molecular studies - mutation analysis of the CBFA1 gene.

Children afflicted with CCD are of normal intelligence and the dental complications are usually detected during routine dental examinations.²

TREATMENT

Guidelines for the treatment of cleidocranial dysplasia are difficult to find in the literature, and as it is such a rare condition, few practitioners have treated enough cases to be in a position to make definite recommendations.¹⁰

Serious consideration should be given to the problem of the patent fontanelle and the discontinuance in the protection normally offered by the cranial vault. A multidisciplinary treatment approach should therefore include a consultation with a neurologist.

A variety of treatment strategies for the dental management of CCD have been developed, including surgical and orthodontic options.

Surgical techniques

Various surgical interventions include: the Toronto-Melbourne, the Jerusalem and the Belfast-Hamburg approaches.¹⁶⁻²⁰

These techniques basically involve multiple surgical interventions, involving timely extractions of primary teeth. Extraction stages are determined by the extent of dento-alveolar development. The supernumerary teeth as well as bone overlying the unerupted teeth are removed during surgical intervention.

Orthodontic approach

After extraction of retained primary and supernumerary teeth, normal eruption and root development may occur due to an increase in eruptive potential.¹⁰ However, the possibility of non-eruption remains.¹⁶

A rigid fixed anchor unit can be designed to accommodate long spans to support accessories such as elastics which may be used to mechanically promote eruption of submerged permanent teeth.

Should primary incisors be extracted, the aesthetic concerns should be addressed.

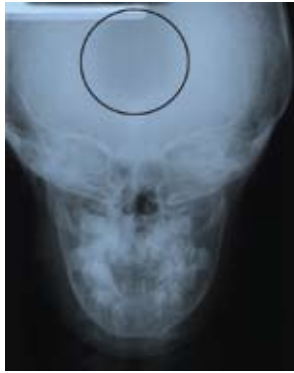

Figure 5: Postero-anterior radiograph. Patent anterior fontanelle encircled

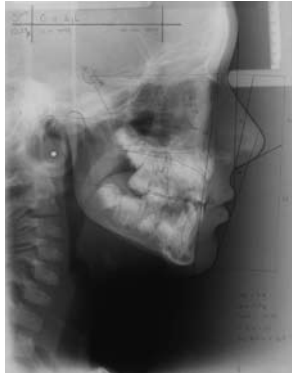

Figure 6: Lateral cephalogram.

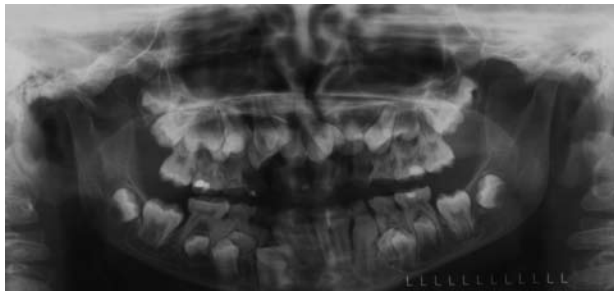

Figure 7: Panoramic radiograph.

CASE REPORT

A 10.5-year old boy was referred from the Department of Periodontics and Oral Medicine at the University of Pretoria to the Department of Orthodontics for an assessment of his CCD status. The patient's mother has CCD, a high dental IQ and an in-depth knowledge about their condition.

Upon examination the following was found:

- The child is of normal intelligence.
- He has a small build, frontal cranial bossing, patent anterior fontanelle, macrocephaly, brachycephaly, long neck, narrow sloping shoulders, underdeveloped clavicles (shoulders can touch), convex facial profile and a skeletal Class II tendency (Figures 1a, b, c).
- The mother, who is of short stature, is the only other family member known with this condition.

In the maxillary arch the following teeth were present: All the primary incisors and canines; primary first and second molars; first permanent molars (Figure 2).

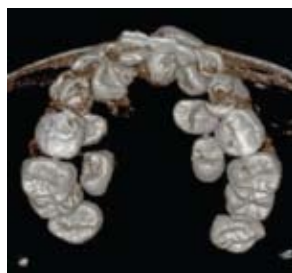

Figure 8: 3D Maxillary palatal view taken with cone beam computed tomography, (VatechPax-Zenith 3D - E-Woo Technology). Easy Dent V4 Viewer Software used in the analysis.

Table 1: Lateral Cephalometric analysis

Parameter	Normal value	Patient value	Diagnosis
ANB	0°	5°	Class II
Wits Appraisal	0mm	4mm	Class II
Mandibular Plane Angle	32°	29°	Slightly horizontal
Facial Contour Angle	100°	118°	Convex
Upper Incisor Inclination	22°	19°	Retroclined
Lower Incisor Inclination	25°	19°	Retroclined
Growth Direction Y axis	66°	64°	Slightly horizontal

In the mandibular arch the following teeth were present: All four permanent incisors; primary canines; first and second primary molars (Figure 3).

SPECIAL DIAGNOSTIC INVESTIGATIONS

Radiological

On the postero-anterior skull radiograph a patent anterior fontanelle is visible (Figure 5). Cephalometric analysis indicated a mild Class II with a horizontal growth tendency. The patient has a convex profile with an increased facial contour angle. Both the upper and lower incisors were retroclined (Table 1, Figure 6).

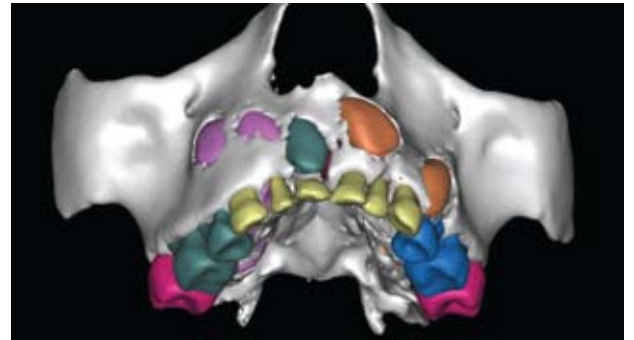


Figure 9a: Simplant 3D conventional frontal maxillary view..

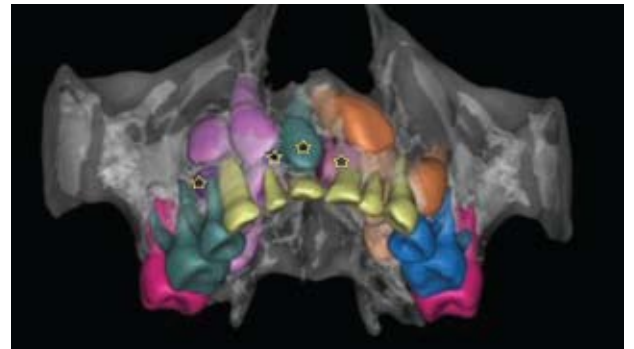


Figure 9b: Simplant 3D transparency function activated * Supernumerary teeth..

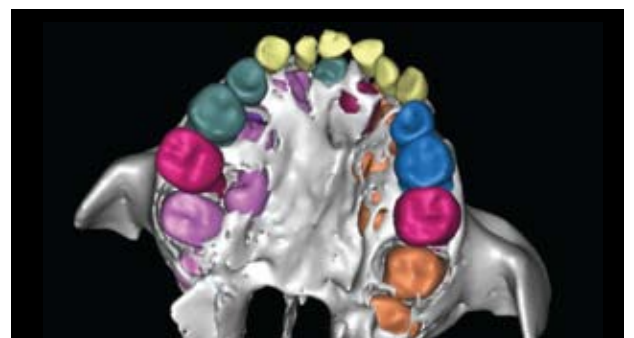


Figure 10a: Simplant 3D palatal view.

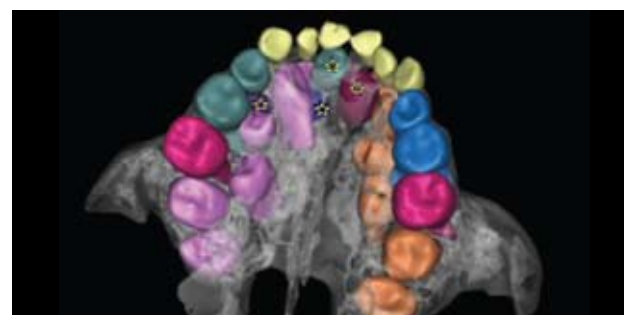


Figure 10b: Simplant 3D palatal view, transparency function activated. * Supernumerary teeth.



Figure 11a: Simplant 3D conventional frontal mandibular view.

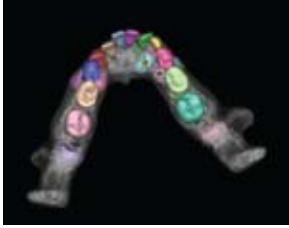

Figure 11b: Simplant 3D transparency function activated. *Supernumerary teeth.

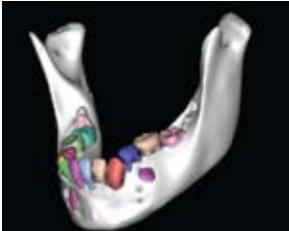


Figure 12a: Simplant 3D lateral mandibular view.

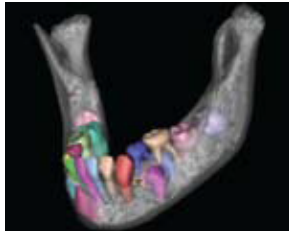


Figure 12b: Simplant 3D lateral mandibular view, transparency function activated. *Supernumerary teeth.

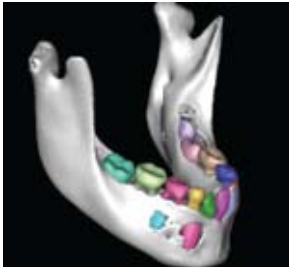

Figure 13a: Simplant 3D occlusal mandibular view.

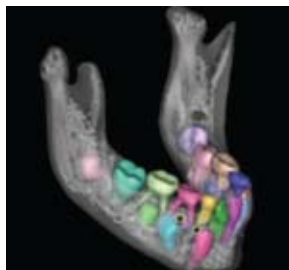

Figure 13b: Simplant 3D occlusal mandibular view, transparency function activated. *Supernumerary teeth.

The panoramic radiograph indicated the presence of unerupted mandibular first permanent molars, which were not visible during clinical examination. Supernumerary teeth were present in the following areas: maxilla: 11, 14 and 24 areas; mandible: 44 and 34 areas. A narrow ascending ramus and lack of vertical development of the corpus was also evident on the panoramic radiograph (Figure 7).

Cone beam computed tomography (CBCT) scanning revealed supernumerary teeth palatal of the 11 and in the 43 and 44 lingual areas. Supernumerary teeth were not found in the 14 and 24 areas but the scan showed palatally positioned maxillary premolars left and right sides (Figure 8). The CBCT data was captured with a VatechPax-Zenith 3D (E-Woo Technology) and the analysis was done with the Easy Dent V4 Viewer Software.

Due to the difficulty of identifying the multiple supernumerary teeth in this patient and in order to avoid repeated surgical interventions, a medical CT was requested.

The medical CT was reformatted with Simplant Software and each tooth individually coloured for distinction between primary, permanent and supernumerary teeth. (Simplant, Materialise Dental NV, Leuven, Belgium). Reformatting with Simplant software consisted of preparing industry-standard DICOM datasets on the CT scanners and importing into SimplantMaster Software. Surface rendering with realistic shading was applied to generate 3D views of the maxilla and mandibula. Bone reconstruction algorithms were used with slice thicknesses of 1mm and slice increments of 0.5mm or less (Siemens Somatom Sensation Cardiac 64. Software used Syngo 2007A).

Simplant reformatting revealed supernumerary teeth in the 14, 12, 11, 21, 43 (lingual), 44 (lingual) and 34 (lingual) areas.

This patient provides a classical example of CCD, as he has a familial history of the condition and exhibits many of the signs and symptoms of the malady. The treatment objective for this patient, as with any other orthodontic patient, is to meet the requirements of Jackson's Triad, i.e., to improve function, aesthetics and stability of the end result. The challenges to treatment in this patient having cleidocranial dysplasia include:

- retained primary teeth;
- age of the patient;
- multiple supernumerary teeth;
- delayed eruption of permanent teeth.

CONCLUSION

The delayed eruption of teeth is cause for great concern among patients and parents and will initiate a visit to seek dental advice. While CCD is a rare condition and is usually asymptomatic and without any generalised complications, patients seek psychosocial fulfilment, and present at an age when they are concerned about their malformed teeth and appearance. Dentists and orthodontists are often the first professionals to examine these patients and if supernumerary teeth are found, further radiographic investigation is essential. It is important, therefore, to

have a clear understanding of the condition and to reassure such patients that treatment is available and the prognosis excellent.²¹

Declaration: No conflict of interest declared

References

1. Yamamoto H, Sakae T, Davies JE. Cleidocranial dysplasia: a light microscope, electron microscope, and crystallographic study. *Oral Surg Oral Med Oral Pathol.* 1989 ;68(2):195-200.
2. Gorlin RJ, Cohen MM, Jr, Hennekam RCM. *Syndromes of the head and neck.* Fourth ed. New York: Oxford University Press; 2001.
3. Machuca-Tzili L, Monroy-Jaramillo N, González del Angel A. New mutations in the CBFA1 gene in the two Mexican patients with cleidocranial dysplasia. *Clin Genet.* 2002;61.
4. Mundlos S, Mulliken JB, Abramson DL, Warman ML, Knoll JH, Olsen BR. Genetic mapping of cleidocranial dysplasia and evidence of a microdeletion in one family. *Hum Mol Genet.* 1995;4(1):71-5.
5. Mundlos S, Otto F, Mundlos C, Mulliken JB, Aylsworth AS, Albright S, *et al.* Mutations involving the transcription factor CBFA1 cause cleidocranial dysplasia. *Cell.* 1997; 30;89(5):773-9.
6. Mundlos S. Cleidocranial dysplasia: clinical and molecular genetics. *J Med Genet.* 1999 ;36(3):177-82.
7. Farronato G, Maspero C, Farronato D, Gioventu S. Orthodontic treatment in a patient with cleidocranial dysostosis. *Angle Orthod.* 2009 ;79(1):178-85.
8. Golan U, Baumert B, Hrala P, Müßig D. Early craniofacial signs of cleidocranial dysplasia. *Int J Paed Dent.* 2004; 14:49-53.
9. Gonzalez Lopez BS, Ortiz Solalinde C, Kubodera Ito T, Lara Carrillo E, Ortiz Solalinde E. Cleidocranial dysplasia: report of a family. *J Oral Sci.* 2004 ;46(4):259-66.
10. Becker A, Lustmann J, Shteyer A. Cleidocranial dysplasia: Part 1--General principles of the orthodontic and surgical treatment modality. *Am J Orthod Dentofacial Orthop.* 1997 ;111(1):28-33.
11. Jensen BL, Kreiborg S. Dental treatment strategies in cleidocranial dysplasia. *Br Dent J.* 1992 ; 21;172(6):243-7.
12. Fleischer-Peters A. Histopathology of the alveolar process in cleidocranial dysostosis. *Stoma (Heidelb).* 1970 ;23(4):212-5.
13. Hitchin AD. Cementum and other root abnormalities of permanent teeth in cleidocranial dysostosis. *Br Dent J.* 1975 ; 21;139(8):313-8.
14. Rushton MA. The failure of eruption in cleidocranial dysostosis. *Br Dent J.* 1937;63.
15. Lossdörfer S, Abou Jamra B, Rath-Deschner B, Götz W, About Jamra R, Braumann B, Jäger A. The role of periodontal ligament cells in delayed tooth eruption in patients with cleidocranial dysostosis. *J Orofac Orthop.* 2009;70:495-510.
16. Smyliski PT, Woodside DG, Hamett BE. Surgical and orthodontic treatment of cleidocranial dysostosis. *Int J Oral Surg.* 1974;3(6):380-5.
17. Hall RK, Hyland AL. Combined surgical and orthodontic management of the oral abnormalities in children with cleidocranial dysplasia. *Int J Oral Surg.* 1978 ;7(4):267-73.
18. Becker A, Shteyer A. A surgical and orthodontic approach to the dentition in cleidocranial dysostosis (Abstract). *Trans Eur Orthod Soc.* 1987;63.
19. Richardson A, Swinson T. Combined orthodontic and surgical approach to cleidocranial dysostosis (Abstract). *Trans Eur Orthod Soc.* 1987;63.
20. Behlfelt K. cleidocranial dysplasia: diagnosis and treatment concept. (Abstract). *Trans Eur Orthod Soc.* 1987(63).
21. Dawjee SM, Nkhumeleni F. Cleidocranial dysplasia--a case report. *SADJ.* 2002 ;57(5):187-90.