

simultaneous proliferation of cells of the lymphocytic series on a more malignant grade than that mentioned above, i.e. as lymphocytomatous (lymphosarcomatous) instead of the more benign (lymphomatous) proliferation described. This would give glio-lymphocytoma (instead of glioma lymphomatosum). Such cases have not, however, been observed in the brain in this series. But see the liver tumours to be described below as lesions concomitant with glioma.

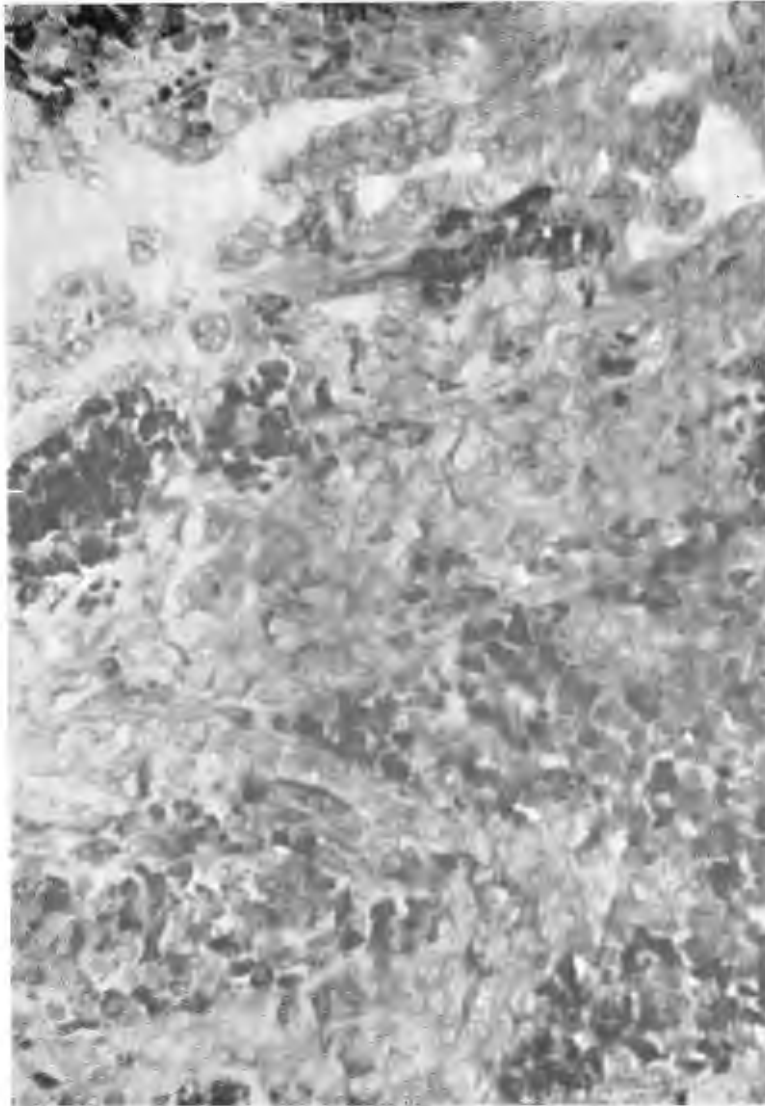


FIG. 74.—Carcinoma (cholangiocellulare) myelocytomatosum of the liver, a lesion concomitant with glioma. Neoplastic bile-duct epithelium in adenocarcinomatous arrangement above, but in solid carcinomatous arrangement below—admixed with (darkly staining) myelocytomatous tissue. (Giemsa.) X 480. (36251.)

## 7. Liver Tumours Concomitant with Glioma.

In my first report of fowl gliomas (*loc. cit.*), one of the two gliomas described was accompanied by multiple foci in the liver, the nature of which at that time remained uncertain. Since then, the experience gained has cleared up the essential nature of such lesions, and light is also thrown on the mystery surrounding Fox's (1912) somewhat discussed case diagnosed as glioma (of the brain of a parakeet) "with slightly atypical metastasis in the liver". Fox's case, although not doubted by Slye *et al.* (1931) or Jackson (1936), was acceptable neither to Joest and Ernesti (1916), nor to Jungherr and Wolf (*loc. cit.*)—not surprisingly, since gliomas do not undergo haematogenous metastasis or spread outside the cranial cavity. Faced with this difficulty, Joest and Ernesti (*loc. cit.*) and Joest (1936) suggested that the brain tumour was a sarcoma; and Jungherr and Wolf (*loc. cit.*) that it was secondary. Yet although Fox's own interpretation—metastasis of glioma to the liver—was erroneous, it will be seen that it was wrong to reject the gliomatous nature of this brain tumour in order to overcome the difficulty.

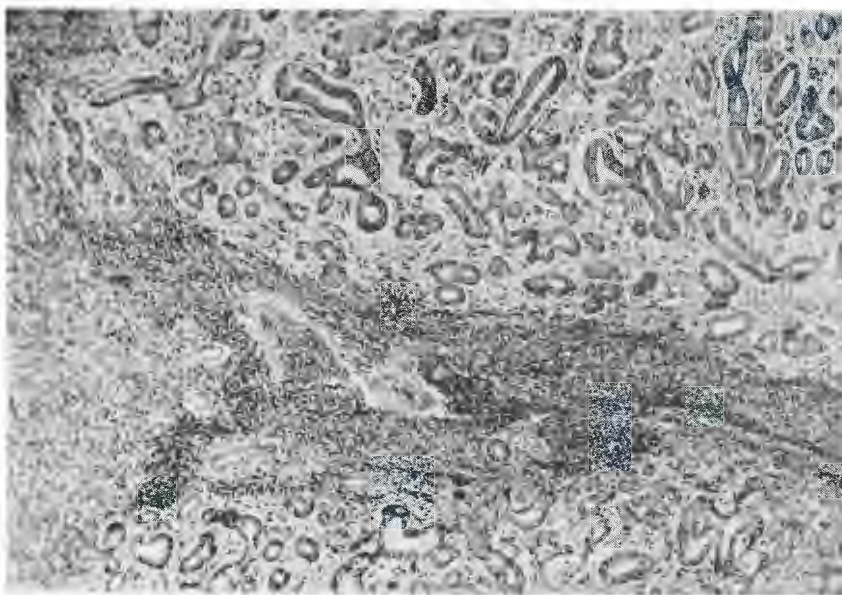


Fig. 75.—Adenocarcinoma (cholangiocellulare) myelocytomatousum of liver, concomitant with glioma—same case as Fig. 74. Neoplastic bile-duct epithelium in purely adenocarcinomatous arrangement, admixed with myelocytomatous tissue (centre). Left—lack of encapsulation and invasive spread of both components into the liver tissue. (Giemsa.) X 100. (36251.)

From the present series of cases one is able to report three further examples of gliomas being accompanied by liver tumours. Detailed report of these cases will be found in Appendix II, but in summary these cases were as follows:—

## Case 36251.

Multiple gliomas (Type II) of the cerebrum. There were in addition two liver tumours, both unencapsulated and growing invasively. One has the structure of cholangiocellular carcinoma admixed with myelocytomatous neoplasia (fig. 74).



FIG. 76.—Adenoma (cholangiocellulare et hepatocellulare) myelocytomatosum of liver, concomitant with glioma. Above—the tumour tissue (the dark areas being the myelocytomatous moiety). Centre—the thick collagenous capsule, demarcating the tumour from the liver tissue (below). [Van Gieson.] X 100. (9805.)

GLIOMAS OF THE DOMESTIC FOWL.

The other is cholangiocellular adenocarcinoma, again admixed with myelocytomatous tissue (fig. 75). Diagnosis: (1) Advanced multiple gliomatosis of the cerebrum. (2) Carcinoma (cholangiocellulare) myelocytomatosum of the liver (multiple).

*Case 9805.*

This was a bird with a well-developed glioma (type II) of the central grey matter of the cerebellum [the second of the two cases reported previously (Jackson, 1936)]. In addition there were multiple liver tumours which at that time remained undiagnosed. These tumours are thickly encapsulated and have the structure of admixed cholangiocellular and hepatocellular adenomas, together with myelocytomatous proliferation (fig. 76). Diagnosis: (1) Advanced glioma of cerebellum. (2) Multiple adenoma (cholangiocellulare et hepatocellulare) myelocytomatosum of the liver.



FIG. 77.—A liver tumour, concomitant with glioma monoblastomatosum (see Figs. 71, 72 and 73), showing characters transitional between adenoma and adenocarcinoma myelocytomatosum. Above, right—the tumour tissue (left) is encapsulated, but below it has broken through the capsule to invade the surrounding liver tissue (extreme right). The groups of darkly stained cells are the myelocytes (see Fig. 79) and the rest is the epithelial moiety, which is of admixed hepatocellular and cholangiocellular type (see Figs. 78 and 79). (H.E.) X 120 (34607.)

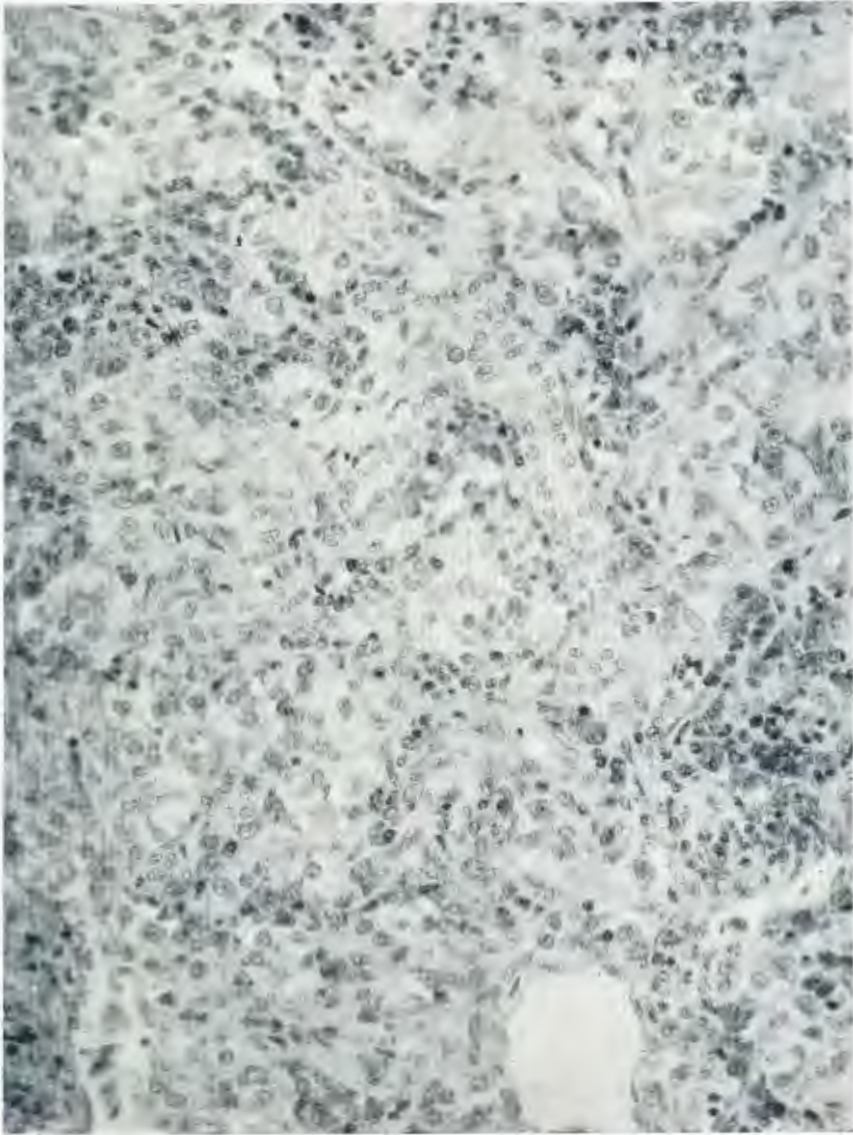


FIG. 78.—Detail of the tumour tissue in the case shown in Fig. 77, showing admixture of cholangiocellular and hepatocellular acini, with nests of proliferating myelocytes. (H.E.) X 510. 34607.)

GLIOMAS OF THE DOMESTIC FOWL.

Case 34607.

Multiple gliomas [Type II (*b*)] of right cerebral hemisphere and left optic lobe. In addition there were two closely juxtaposed liver tumours which are partly encapsulated. At certain points the capsule has become broken through by the tumour tissue, which then becomes re-encapsulated; and at other points the capsule is deficient, with direct invasive spread in the surrounding liver tissue (fig. 77). The structure is admixed hepatocellular and cholangiocellular proliferation, again with a myelocytomatous moiety (figs. 78 and 79). Diagnosis: (1) Multiple glioma monoblastomatosum of the brain. (2) Adenocarcinoma (hepatocellulare et cholangiocellulare) myelocytomatosum of the liver showing transition from adenoma to malignancy.

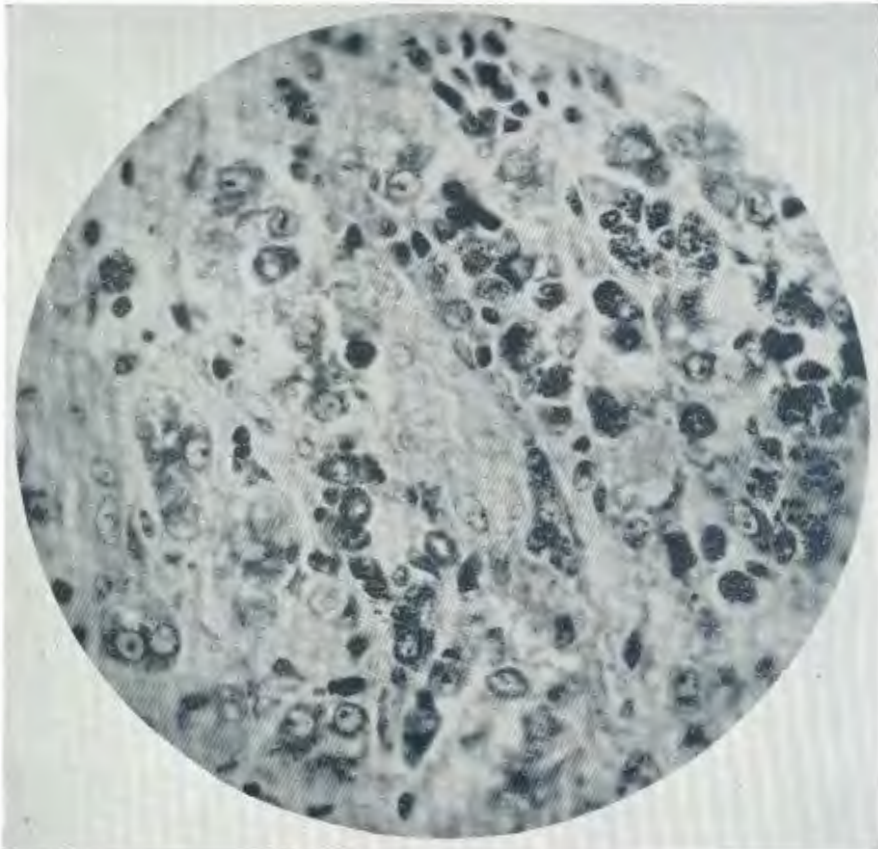


FIG. 79.—From the same tumour as Figs. 77 and 78, but with the myelocytomatous moiety emphasised by technique. Note the rod-shaped specific granules seen in all stages of development among these cells, which are proliferating rapidly by mitosis. The cholangiocellular moiety of the tumour is seen as a pale-staining tubule in the centre and the hepatocellular moiety as transections of cords of finely granular cells with distinct nucleoli (to left and below). Giemsa.) X 1250. (34607.)

In all the above cases, "haemofuscin" pigmentation is demonstrable in the liver tumours (as well as in the brain tumours) and in one case the tumours were macroscopically recorded as having a yellow to orange coloration.

*Discussion of these Cases.*

The mere finding, in a large series of glioma subjects, of three cases of concomitant liver tumours might not excite comment. When taken together with Fox's single case which was also accompanied by liver tumours, it is bound to be of interest. But when in all the present cases it is seen that the liver tumours are of a peculiar and complex type not hitherto described in birds, these findings become of great significance. It should also be added here that mammalian cases of "Adenoma hepatocellulare haemoplasticum", in which proliferation of liver cells is accompanied by "haemopoiesis", as described by Frankel (1929) in sheep and ox, are well worth comparison. Furthermore the "green liver-cell adenoma" of a bovine described by de Kock and Fourie (1928) was notable for a "*proliferation of eosinophils*"<sup>(10)</sup> in the stroma.

I wish to state my suspicion that the described liver lesions in fowls (and probably the liver lesion described by Fox in a parakeet) are related to gliomas in the sense that they have a common aetiology. I think the explanation is that in rare cases in birds the causal factor of glioma operates simultaneously in another organ. where perforce (absence of glia cells) the outcome is a lesion of entirely different nature, but yet showing in certain details (proliferation of lymphocytes, plasma cells and myelocytes) histopathological affinity to the encephalitis-glioma series of lesions. The coloration of the liver tumours and microscopic identification of the same pigment is another link in this connecting chain, but my full reasons for suspicion mentioned cannot be stated until the parasitology of glioma and related lesions has been dealt with (in later articles).

#### VI. THE PIGMENTATION OF AVIAN GLIOMA AND ENCEPHALITIS. (AND RELATED LESIONS).

The characteristic orange yellow coloration of avian glioma is regularly seen also in other lesions, which almost without exception have at post-mortem been suspected of being gliomas, viz. all the forms of encephalitis described above including encephalitis associated with haemangioblastomatosis, lymphocytomas and plasmacytomas of the C.N.S., diffuse encephalitis or gliosis of the brain, and even in the concomitant liver tumours described, where such were received unpreserved. It has already been mentioned that this coloration disappears on fixation.

Microscopically, pigment is demonstrable in all these types of lesions, showing that the fading on fixation is due not to solution, but to chemical changes (presumably reduction by formaldehyde). It varies in quantity in the different brain lesions described, being greatest in amount in cerebral abscess and least in amount in glioma. In glioma it is seen in the infiltrating cells including especially the macrophages (histiocytes) but also in lymphocytes, monocytes, and plasma cells; and in smaller amount associated with the tumour cells themselves. Fig. 80 shows a large amount of such intracellular pigment in infiltrating cells, which have accumulated in a cystic cavity in glioma. It is seen in the same cell types forming perivascular infiltrations in the stroma of and in the marginal reaction zone around gliomas (fig. 81). Fig. 82 shows a still heavier pigmentation of such cells in a focus of perivascular encephalitis. It has also been seen in vessel walls, including the hyperplastic endothelium.

---

<sup>(10)</sup> *Italics mine.*

## GLIOMAS OF THE DOMESTIC FOWL.

In purulent encephalitis and especially in cerebral abscess, pigment is present in still larger amount (fig. 83) and is seen in various of the cell types taking part, but particularly in large quantity in the giant cells which are derived from the infiltrating monocytes. Fig. 84 shows an extremely heavy degree of pigmentation in lesions of diffuse encephalitis. Occasionally it has been seen in neurones lying in the marginal zone around glioma and similarly it was present in surviving nerve cells in a lymphocytoma of the Gasserian ganglion (fig. 85). Details of its distribution in liver tumours concomitant with glioma are mentioned in Appendix II.

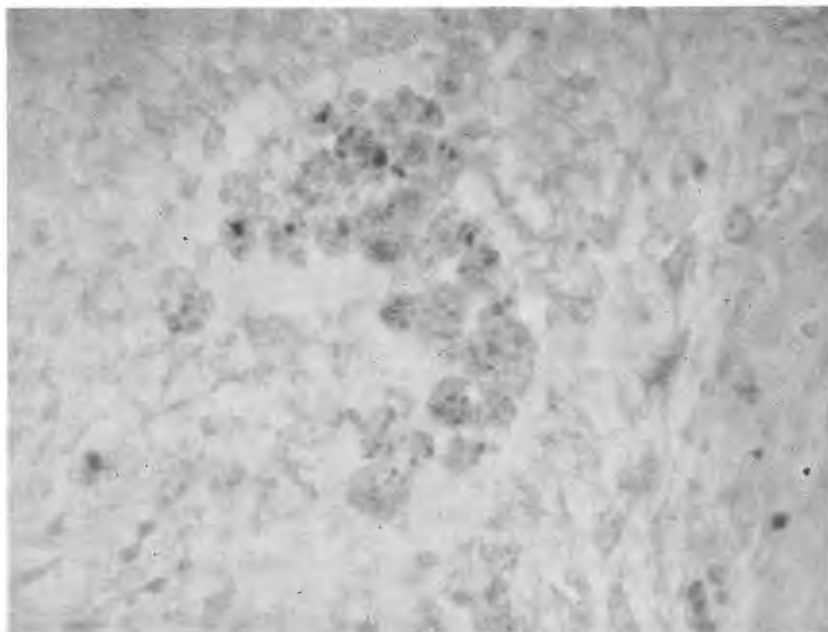


Fig. 80.—Accumulation of “haemofuscin” pigmented infiltrating cells (“macrophages”) in a cystic cavity in glioma. Smaller amounts of the same pigment are seen in the surrounding tumour tissue. (Giemsa.) X 720. (35538.)

This pigment has been identified as belonging to the type known usually as “haemofuscin”. In ordinary sections (H E) it appears in its natural yellow colour. It stains very intensely with basic aniline dyes. Thus with basic fuchsin it responds to Mallory’s “test for haemofuscin” and with Giemsa stain it gives a characteristic intense Prussian blue colour, slightly tinged with green (i.e. it reacts with the methylene blue component)—see fig. 2. It fails to give a positive *Berlinerblau* reaction when tested, as is usual, in the cold. But if the preliminary hydrolysis is carried out at a temperature of 60° C., it is strongly positive.<sup>(11)</sup> This pigment is therefore iron-containing<sup>(12)</sup>, and the iron is more closely bound than in the case of a pigment such as haemosiderin.

<sup>(11)</sup> I am indebted to the Department of Histology of the Medical School, Johannesburg (co-workers of Dr. Joseph Gillman) for advice in regard to the histochemistry of such pigments.

<sup>(12)</sup> A belief inherited from older pathologists seems to persist that pigment described as haemofuscin is iron-free, in contrast to haemosiderin. It seems desirable to state clearly that this impression is quite erroneous and it exists merely because it is customary to test for iron after cold hydrolysis.



Haemorrhage is scarcely ever observed in connection with avian gliomas, even diapedesis of individual red cells. A haematogenous origin of this pigment is therefore not to be thought of.

On the other hand, I believe it to be of *exogenous* origin, representing the residues of various phases of the parasitic agent present in gliomas and related lesions. The evidence for this belief, however, will not be presented in the present communication.

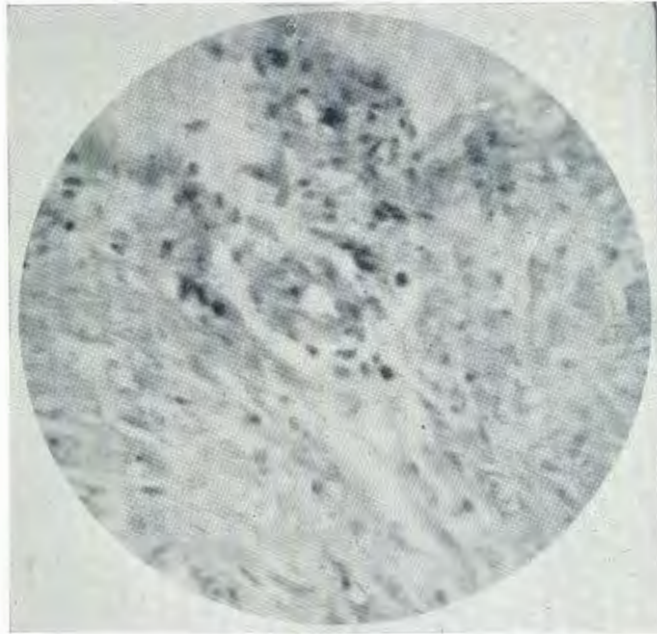


FIG. 81.—Perivascular pigmentation in the marginal reaction zone (above) around glioma (below). (Giemsa.) X 480. (36298.)

## VII. GENERAL DISCUSSION.

### 1. *The Origin of Avian Gliomas from "Adult" Cells, Contrary to the Theory of "Embryonal" Cell Origin of Gliomas.*

The causation of neoplasms in general remains obscure, but there is no class of tumours on which so little light has been shed as in the case of gliomas. For the great majority of tumours a theory of origin from embryonal cell rests has been discarded, but although some criticism has appeared it is still actively entertained in the case of brain tumours. Even so, it sheds no light whatever on why embryonal rests should later be stimulated to activity. It is true that the classificatory scheme of gliomas built up by the efforts of Bailey and Cushing (1926) and based on principles of the normal differentiation of the embryonal cells of the nervous system has brought descriptive order into an otherwise bewildering variety of gliomas and the intricacies of their cytology; yet there is no doubt that it derived encouragement from the theory of embryonal cell origin of the tumours.

#### GLIOMAS OF THE DOMESTIC FOWL.

In these circumstances it should rightly be disconcerting to reflect that no sooner does opportunity occur to investigate thoroughly the foregoing aspects of comparative pathology of gliomas, than certain important principles or theories are found to be false, at least in the case of avian gliomas:—

(1) These avian gliomas do not arise from embryonal cells, but on the other hand from adult glia cells.

(2) Steps in cell changes during neoplasia, hitherto assumed to represent differentiation of immature cells in the direction of maturity, prove to represent in fact the opposite—viz. de-differentiation of adult cells. The stages remain the same, hence it is possible to use the same terminology to describe them, but




FIG. 82.—Pigmentation of the perivascular foci of disseminated encephalitis. (The darkly staining bodies *between* the affected vessels are infiltrating plasma cells.) (Giemsa.) X 600. (35569.)

they occur in reverse order. It seems that the pattern of differentiation imposed on cells by ontogeny cannot be departed from in de-differentiation: there is a developmental pathway which the cells must strictly retrace in de-differentiation. If this is true of avian gliomas, where incomparably better opportunity has occurred to follow the pathogenesis and histogenesis, then the same aspects of human gliomas imperatively need reconsideration, and this reconsideration should be undertaken with an acute suspicion that present conceptions may be false.<sup>(13)</sup>

<sup>(13)</sup> However, I am quite prepared to believe that the aetiological factor in glioma may also operate on embryonal cells, e.g. if it should come into play pre-natally. Further differentiation of such affected cells might well occur.

## 2. *An Hypothesis of the Pathogenesis of Avian Gliomas.*

I believe that the observations presented in this communication provide very weighty evidence that the incidence of glioma in birds—doubtless greatly conditioned by inherited susceptibility or resistance to a hitherto undescribed factor (“X”)—nevertheless is primarily dependent on this factor. What do we know regarding the nature of this X? Tentatively, one should suspect the following:—

- (1) It probably arrives in the brain *via* the bloodstream.
- (2) It or its products are chemotactic for lymphocytes and monocytes; and, presumably when in greater concentration, for granulocytes.

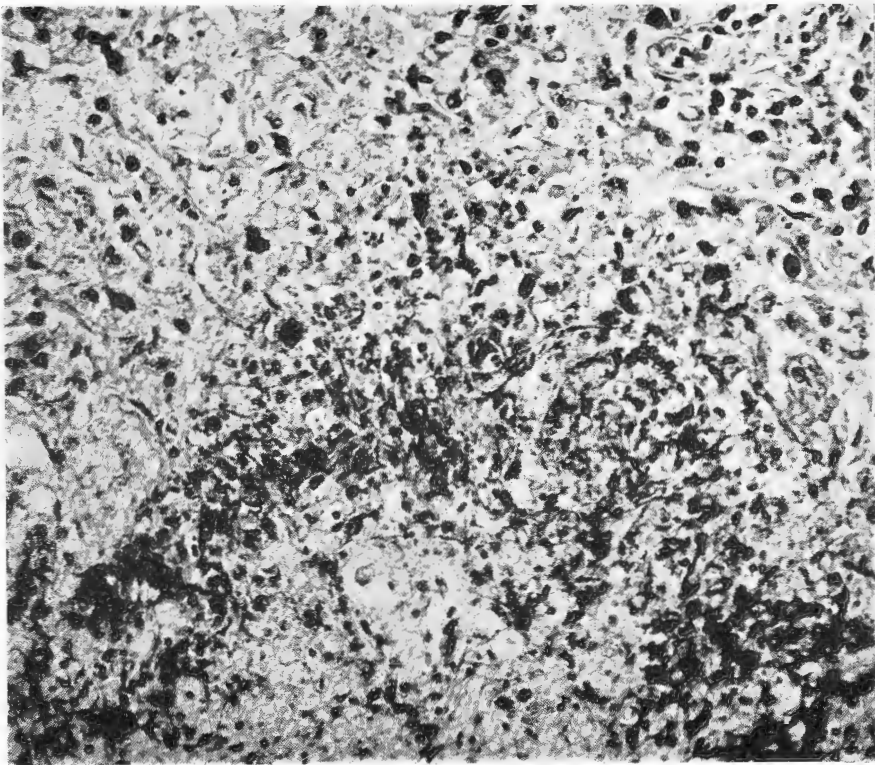


FIG. 83.—Pigmentation of cerebral abscess. Pigment is concentrated in the inner part of the abscess “wall” at the margin of the purulent centre, but is also present in large amount in the latter (below) and in the outer part of the abscess “wall” (above). (Giemsa.) X 480. (36684.)

- (3) It is capable of passing through the bloodvessel walls.
- (4) In so doing it excites changes in these walls—endothelial hypertrophy and hyperplasia, sclerosis, etc. If the progressive changes in the endothelial cells reach sufficient intensity, (multiple) haemangioblastoma may be the outcome.



FIG. 84.—Pigmentation in diffuse gliosis of cerebellum. Extremely heavy deposits of pigment (quite unassociated with haemorrhage). (Giemsa.) X 150. (53875.)

- (5) Reaching the perivascular spaces it continues to exert its chemotactic effect on haematogenous elements, usually on lymphocytes and monocytes, but (presumably if in sufficient concentration) also on granulocytes, in which case purulent encephalitis or cerebral abscess results instead of non-purulent encephalitis (or glioma).
- (6) It (or its products) stimulate proliferation of lymphocytes and monocytes which have emigrated from the vessels and if in sufficient concentration, also myelocytes. If the stimulation of lymphocytic proliferation is sufficiently intense, a lymphocytoma results.

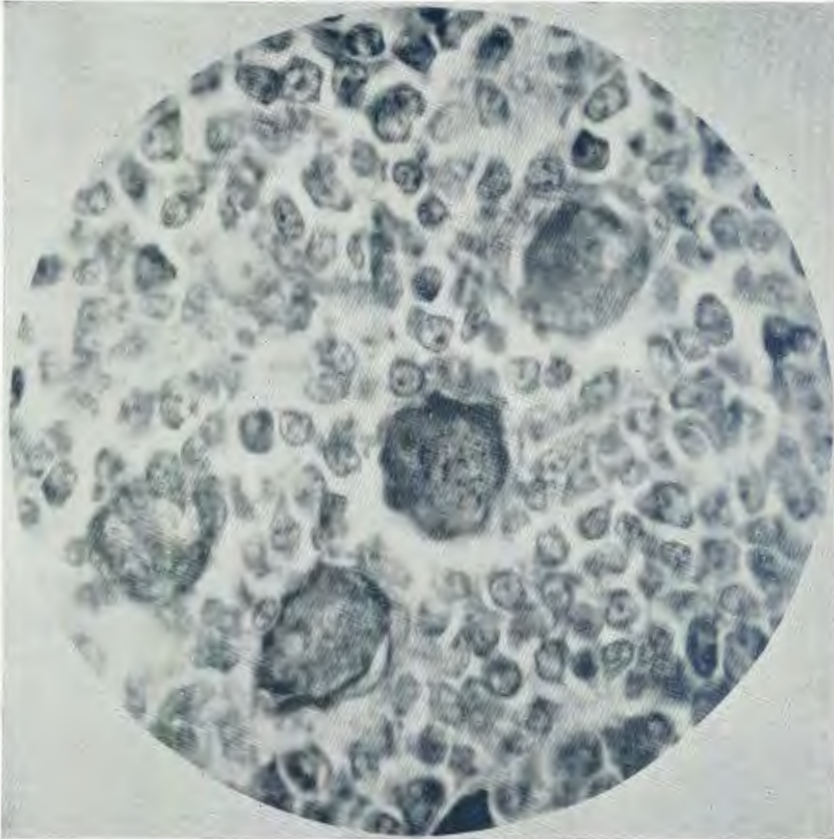


FIG. 85.—Pigmentation of surviving ganglion cell in a case of lymphocytoma of the Gasserian ganglion. (Several other surviving nerve cells are seen among the neoplastic lymphocytes, either unpigmented or with pigment granules not well focussed.) (Giemsa.) X 1320. (35636.)

- (7) It encourages the transformation of lymphocytes into plasma cells. If proliferation and this transformation of lymphocytes is sufficiently intense, the result is a plasmacytoma.
- (8) Especially in purulent encephalitis and cerebral abscess it stimulates the transformation of monocytes into giant cells. In gliomas, especially of the Type II (*b*), it stimulates proliferation of monoblastic cells and plasma cells derived therefrom on a neoplastic grade.

- (9) It stimulates previously normal adult protoplasmic astrocytes to progressive changes. Under this influence astrocytes enlarge, they may tend to develop glia fibrils, their processes tend to be taken up into the general cytoplasmic body, and they multiply. They de-differentiate into cells corresponding by morphological definition (although not by conventional embryogenetic definition) with astroblasts.
- (10) If the events described in (9) (above) are sufficiently pronounced, a glioma results. If de-differentiation should proceed no further than described, this tumour will be an astroblastoma (type I glioma).
- (11) However, if further de-differentiation occurs (perhaps dependent on disjunction of the vascular processes of the astroblasts from the vessels), these astroblasts tend to change further in shape—to become spongioblasts—and to undergo a change in their chemistry which has as a result loss of ability to impregnate (readily or deeply) with gold sublimate and silver carbonate, and in many cases to secrete mucin. The resulting tumour (type II) is morphologically closely related to glioblastoma of man.
- (12) In some cases factor X may operate simultaneously on the liver, producing tumours of the unusual characters described, depending on stimulation to neoplasia of (again adult!) epithelial cells (whether bile-duct epithelium or hepatic cells, or both), and myelocytes; and again lymphocytes, monocytes, and plasma cells participate.
- (13) Whether X operates also at times on other organs, producing lesions which may be well known (but aetiologically obscure) we do not know.
- (14) There is some evidence that, depending perhaps on the individual response and the age of the affected subject, X may be responsible for a diffuse interstitial encephalitis or sclerosis of the brain of the young chicken, characterised again by marked proliferation of cells derived from the astrocytic lineage.
- (15) In all the lesions dealt with in this communication—gliomas, disseminated non-purulent encephalitis, purulent encephalitis, lymphocytoma and plasmacytoma, and haemangioblastoma of the C.N.S., the concomitant liver tumours in some cases of glioma, and the diffuse brain sclerosis described, the presence of X is associated with the deposition of an iron-containing, non-haematogenous pigment of “haemofuscin” type. How close this relationship is between X and pigment will appear in later communications.

It was tentative deductions such as the above which, taken together, suggested to me that *avian glioma is no mere “purposeless proliferation of cells”, but rather a response to the presence of an unknown factor having the characters described above, and continuing to operate in the brain tissue outside the advancing margin of the tumour.* These deductions impelled me to investigate whether X might not be a microscopically visible agent. Useful leads were to concentrate examination on the reaction zone around gliomas, especially those that were most actively spreading by conversion, and not to confine the examination to gliomas but to extend it both to brain neoplasms which conceivably were to be considered as variants of a single fundamental process which produces both gliomas and other intracranial neoplasms; and to extend the survey also to concomitant tumours in other organs, and to all lesions of birds characterised by the presence of the pigmentation described and in the brain showing histological intergrades to glioma.

It will be known (Jackson 1948) that expectations were exceeded. Not only did an exogenous agent prove to be visible, but it was of parasitic nature and its life cycle has since been extensively studied. Further, on applying the above knowledge to intracranial tumours of man, several phases of an indistinguishable agent were demonstrated regularly (Krynauw and Jackson, 1948), somewhat unexpectedly in meningiomas of the various types and in pituitary tumours as well as in gliomas.

Looking back on this work I cannot refrain from remarking on what I feel to be a tragedy for the medical sciences—the disbelief, not to say hostility, which was accorded to observations of the type made by Stroebe (1895) in human gliomas; so that in modern reviews of the aetiology of glioma they are either accorded no mention, or referred to deprecatingly or perhaps as merely of some historical interest. However, one must remember that it is possible that the data accruing from non-comparative pathological studies may in some fields not enable their author to produce complete or convincing evidence of his theories; and essential links in a chain of evidence may sometimes be forged only by widening those studies to include lower species.

#### SUMMARY.

1. Fowl glioma has erroneously been classified as astrocytoma.
2. Two chief variants occur, more rarely astroblastoma and much more commonly a glioma closely related structurally to glioblastoma (spongioblastoma) multiforme of man, but in general more slowly growing. This commoner type must either be identified for purposes of classification with low-grade glioblastoma multiforme or assessed as intermediate between astroblastoma and glioblastoma.
3. "Microcystic degeneration" leading to cystic cavitation of avian gliomas is associated with the secretory ability of neoplastic glia cells. This secretion is often of demonstrably mucinous nature. The question is raised whether this phenomenon may perhaps be merely an exaggeration of the normal physiology of glia.
4. The growth of avian gliomas occurs overwhelmingly by conversion of neighbouring (adult) astrocytes to tumour cells.
5. The histopathology of a non-purulent disseminated perivascular encephalitis of fowls has been closely studied and is identical with that of the brain tissue at the spreading margin of glioma.
6. Very commonly these focal inflammatory lesions exist side by side with glioma in the same brain.
7. All possible gradations occur between these inflammatory foci and glioma. *The earliest gliomas of fowls have been shown to be nothing but encephalitic foci in which glia proliferation becomes exaggerated and predominant over haematogenous cellular infiltrative changes.*
8. The reacting marginal brain tissue around fowl glioma is identical in all details of its histopathology with this chronic perivascular encephalitis. *Thus not only does glioma arise from encephalitis, but its continued growth and spread are similarly due to conversion of chronically inflamed brain tissue at its periphery into tumour tissue.*

#### GLIOMAS OF THE DOMESTIC FOWL.

9. The very common occurrence of multiplicity of avian gliomas is explained as due to the progression of multiple scattered pre-existent encephalitic foci to tumours.
10. The characteristic lobulation of avian glioma is explained as due to an initial concentration of encephalitic foci which fuse as they become converted into gliomas.
11. Multiplicity of avian glioma should not be thought of as a secondary multiplicity. Although gliomas may break into the ventricles, there is no evidence whatever of a spread by transplantation of tumour cells transported by the C.S.F., or by any other means. On the other hand, each of the multiple tumours is primary and has arisen from a pre-existent focus of encephalitis.
12. The protrusion of gliomas into the ventricles is due to prior location in or near the ventricular walls of encephalitic foci which later become converted to gliomas.
13. The ependymal cells lining such stimulated ventricles readily de-differentiate into ependymal spongioblasts, but such cells have not been observed to participate in neoplasia in birds.
14. All gradations exist between the non-purulent encephalitic foci mentioned and purulent encephalitis including cerebral abscess.
15. All gradations occur between non-purulent encephalitic (and especially meningo-encephalitic) foci and lymphocytoma of the C.N.S.—or in cases where it is the plasma cell transformation of lymphocytes which becomes predominant—between encephalitis and plasmacytoma.
16. The occurrence of haemangioblastoma of the brain of the fowl is reported. The idea is entertained that these tumours also are related to glioma in the sense that they too may arise as encephalitic foci.
17. The proliferation of haematogenous infiltrating cells in gliomas as well as in disseminated meningo-encephalitis may reach neoplastic grade. Thus from foci of leptomeningitis, lymphocytoma may arise and invade the brain. Neoplastic proliferation of lymphocytes in glioma leads to a variant designated glioma lymphomatosum. Neoplastic proliferation of the emigrated haematogenous monocytes gives rise to other mixed tumours designated glioma monoblastomatosum.
18. In four cases of avian glioma [three of the present author's and one of Fox (1912)] there have been concomitant liver tumours of a peculiar type. These—as might have been anticipated—are not metastatic gliomas in the liver(!) In my own cases they were cholangiocellular adenocarcinoma, cholangiocellular carcinoma, or mixed hepatocellular and cholangiocellular adenoma or adenocarcinoma; in all cases admixed with myelocytomatous neoplasia. It is suspected that these unusual findings are to be explained by the assumption that an unknown factor causing glioma (or encephalitis) may in some cases operate simultaneously on the liver, and that much more constantly in the liver than has above been mentioned in the C.N.S., this factor tends to evoke simultaneous neoplastic proliferation of emigrated haematogenous cells.
19. The relationship of a spectacular case of diffuse gliosis of the brain to glioma has been discussed.



20. Avian glioma (as well as the related lesions of non-purulent and purulent encephalitis, lymphocytomatous tumours and solid haemangioblastomas of the C.N.S., and the peculiar concomitant liver neoplasms) is characterised by the presence of an iron-containing pigment responsible for a peculiar orange to yellow coloration of all these lesions. The author believes this pigment to be of great significance, indeed that it is derived from a parasitic agent present in these lesions.
21. The theory of origin of gliomas from *embryonal cells* which *recapitulate* their ontogenetic ancestry by *differentiation* towards *adult* types is false in the case of gliomas of birds. These gliomas on the contrary arise from previously *adult cells* which *de-differentiate* into *more primitive cells*—a “*recapitulation in reverse order*” of their embryonic ancestry.
22. A suggested pathogenesis of avian glioma and related lesions has been developed in considerable detail.
23. The histopathological, histogenetic, and pathogenetic observations suggested strongly that avian glioma is a response to some noxa which continues to spread in the brain in advance of the tumour. This led to a search for the presence of a visible agent associated with glioma and related lesions of the fowl and also later in human gliomas. Preliminary accounts of the results of this search have been published and fuller reports are in preparation.

#### ACKNOWLEDGEMENTS.

Most of the material on which this work has been based was supplied by the Poultry Section, Onderstepoort (Prof. D. Coles).

The exacting technical procedures necessary in neurohistology at this Institute are at present carried out with great competence and care by Mr. W. H. Gerneke, B.Sc., with the assistance of Miss M. Barnard and Mr. J. Froneman. Earlier preparations also illustrated in this article were the work of Miss Dorothy Armstrong (since retired).

The formidable task of the microphotography was accomplished chiefly through the services of Mr. N. Johnstone, Technician in the Neurosurgical Department, Johannesburg Hospital. We were also fortunate to have the advice of Mr. Th. Meyer, the retired photographer of this Institute, and later the services of the present photographic staff (Mr. T. Marais).

The coloured plates are from paintings by Miss G. E. Laurence.

This work was made possible by kind permission of both the present Director of Veterinary Services (Dr. G. de Kock, Dr. Med. Vet., D.Sc., M.R.C.V.S.) and his predecessor, Dr. P. J. du Toit, B.A., D.Phil., D.Sc., Dr. Med. Vet.

With humility I acknowledge what I owe to all workers who have laboured in these arduous fields of neuropathology, not least those whose opinions I may have ventured to criticise. Only they will know to what extent I have had to rely on the written guidance of far separated investigators of these difficult problems.

GLIOMAS OF THE DOMESTIC FOWL.

REFERENCES TO LITERATURE.

- BAILEY, P. AND CUSHING, H. (1926). *Tumours of the Glioma Group*. J. B. Lippincot Company, Philadelphia, London and Montreal.
- BELMONTE, V. (1935). Über ein Gliom beim Haushuhn. *Virch. Arch.* Vol. 294 pp. 329-33.
- DE KOCK, G. AND FOURIE, P. J. J. (1929). Green liver cell adenoma in a bovine. *13th and 14th Repts. D.V.R., Un. of S.A., Part II*, pp. 727-729.
- FOX, H. (1921). Observations upon neoplasms in wild animals in the Philadelphia Zoological Gardens. *Jl. Path. and Bact.* Vol. 17, pp. 217-231.
- FRENKEL, H. S. (1929). Über primäre epitheliale blutbildende Lebergewächse bei Schaf und Rind (Adenoma und adenocarcinoma haemoplasticum). Zugleich ein Beitrag zur Blutbildung. *Virch. Arch.* Vol. 273, pp. 611-656.
- FURTH, J. (1934). Lymphomatosis, myelomatosis and endotheliomatosis of chickens caused by a filtrable agent. *J. Exp. Med.* Vol. 59, pp. 501.
- GLOBUS, J. H. AND STRAUSS, I. (1925). Spongioblastoma multiforme. A primary malignant form of brain neoplasm: its clinical and anatomic features. *Arch. Neurol. and Psychiat.* Vol. 14, pp. 139-191.
- HATFIELD, G. AND GARROD, L. P. (1934). *Recent Advances in Pathology*, 2nd Ed., pp. 350-362, P. Blakiston's Son, Philadelphia.
- JACKSON, C. Tumours of Animals in South Africa. *Ond. Jl.*, Vol. 6, No. 1, pp. 6-460 (see pp. 323-328).
- JACKSON, C. (1936). Relationship of Glioma to encephalitis in the domestic fowl, and an associated parasitic agent. *Nature*, Vol. 161, pp. 441-442.
- JACKSON, C. AND DE BOOM, H. P. A. (1951). A contribution to the cytology of the spleen: The Romanovsky-stained bovine spleen smear. *Ond. Jl.* Vol. 25, No. 2, pp. 79-156.
- JOEST, E. (1936). *Handbuch der speziellen pathologische Anatomie der Haustiere*. R. Schoetz., Berlin, Vol. II, pp. 697-721.
- JOEST, E. AND ERNESTI, S. (1916). Untersuchungen über spontane Geschwülste bei Vögeln mit besonderer Berücksichtigung des Haushuhns. *Z.f. Krebsf.*, Vol. 15, pp. 1-75.
- JUNGHERR, E. AND WOLF, A. (1939). Gliomas in animals. A report of two astrocytomas in the common fowl. *Am. Jl. Cancer.* Vol. 37, pp. 393-509.
- KERNOHAN, J. W., SVIEN, H. J. AND ADSON, A. W. (1949). A simplified classification of the gliomas. *Proc. Staff Meet. Mayo Clin.* Vol. 24 (3), pp. 71-75.
- KRYNAUW, R. A. AND JACKSON, C. (1949). Presence of a parasitic agent in various intracranial tumours of man. *Nature*. Vol. 162, pp. 147.
- LIEB, ETHEL (1948). Modified phosphotungstic acid-haematoxylin stain. *Arch. Path.* Vol. 45, pp. 559-560.
- McMENEMY, N. H. (1940). Alzheimer's disease: a report of six cases. *Jl. Neurol. and Psychiat.*, Vol. 2, pp. 211-240.
- SCHERER, H. J. (1940). The pathology of cerebral gliomas. *Jl. Neurol. and Psychiat.*, Vol. 3, pp. 147-177.
- STROEBE, H. (1895). Über Entstehung und Bau der Gehirn-Gliome. *Zeigler's Beitr.*, Vol. 18, pp. 405-486.
- SVIEN, H. J., MABON, R. F., KERNOHAN, J. W. AND ADSON, A. W. (1949). Astrocytoma. (Symposium on a new and Simplified concept of Gliomas.) *Proc. Staff Meet. Mayo Clin.* Vol. 24, pp. 54-68.
- WALSHE, F. M. R. (1931). Intracranial tumours; a critical review. *Quart. Jl. Med.* Vol. 24, pp. 587-640.

APPENDIX I.  
SUMMARY OF CASES STUDIED.

The foregoing study covers 146 cases of fowls suffering from intracranial tumours or inflammatory brain lesions believed by the author to be pathogenetically related to certain brain tumours, or from both types of lesion simultaneously.

In this material there are 120 cases of intracranial tumours, classified as follows: Glioma, 109 cases; Primary Lymphosarcomatous Tumours (of the brain or meninges), 7 cases (6 lymphocytomas and 1 plasmacytoma); Haemangioblastoma (haemangioblastoma), 2 cases; Osteogenic sarcoma (originating in the meninges), 1 case; Secondary (metastatic) lymphocytoma in the brain, 1 case. In addition, in one of the cases of glioma there was also a lesion of the chorioid plexus tentatively classified as chorioid epithelioma.<sup>(14)</sup>

In 94 cases of glioma (85%), lesions of a non-purulent focal perivascular encephalitis (or meningo-encephalitis) could be demonstrated accompanying the tumours, and in no less than 86 of these cases (78% of cases of glioma) actual transitional stages between such foci and gliomatous tumours could be found. In both the cases of haemangioblastoma the neoplasia was also superimposed on an encephalitis, and in 2 of the cases of primary lymphosarcoma it was considered that the origin of the tumours from encephalitic (or meningo-encephalitic) foci could be demonstrated.

The gliomas were classified as follows: Type I (Astroblastoma), 1 case (0.9%). Type II (see text), 91 cases [ca 83%; in 4 cases a tendency towards type II (a), in 2 cases towards type II (b), and in 1 case towards both types II (a) and II (b)]. Type II (a) (Glioma lymphomatosum) 1 case (ca. 0.9%). Type II (b) (Glioma monoblastosum) 16 cases (14.6%); [in 8 cases either pure type II tumours or tumours transitional between types II and II (b) also existed].

In only 3 cases of glioma was a solitary tumour found; in all the remaining cases (97%) multiple tumours existed. Gliomas were distributed as follows in the different divisions of the brain: Cerebrum, affected in 91 cases (both hemispheres involved in 63 cases); Optic lobes(s)—50 cases (bilateral 34); Cerebellum—14 cases; Brain-stem (medulla or cerebral peduncle)—5 cases.

Avian encephalitis was studied in 128 cases, classified as follows: Disseminated focal non-purulent perivascular encephalitis, 110 cases. In 98 of these cases gliomatous tumours were superimposed on the encephalitic lesions, while in 2 cases haemangioblastoma and in 2 cases lymphosarcoma had developed. In 11 cases there was no concomitant neoplasia. Lesions transitional between non-purulent and purulent encephalitis, 5 cases; Purulent encephalitis, 8 cases (including 5 cases of cerebral abscess and 4 cases in which all gradations occurred from non-purulent encephalitis to cerebral abscess); Diffuse encephalitis or gliosis, 2 cases.

*Concomitant Pathological Lesions.*

Apart from the encephalitic lesions mentioned previously the following conditions accompanied gliomas: Mixed epithelial and myelocytomatous liver tumours, 3 cases; Nodular Regenerative Polymyositis, 2 cases; Lymphoid leucosis, 4 cases; Osteopetrosis 2 cases; chorioid epithelioma (see above), 1 case. Osteofibromyxoma (subcutis of wing), 1 case.

*Remarks on Concomitant Lesions.*

Conditions which have so far been encountered solely in birds suffering from glioma (the mixed liver tumours mentioned) or from encephalitis (haemangioblastoma of brain or meninges) and for this as well as other reasons suspected to be aetiologically or pathogenetically connected with glioma or with encephalitis have been dealt with fully in the text. Other concomitant lesions do not show this connection with such clarity. They may either be merely coincidental or at any rate precise evidence of the interdependence with the brain pathology is lacking, as in the case of the nodular polymyositis on which a short note follows.

<sup>(14)</sup> This term is used instead of the more familiar chorioid *papilloma*, because the pattern of this tumour in the bird is not in fact papillomatous as in the case of mammalian chorioid tumours. No such neoplasm has hitherto been described in submammalian species and the whole question of plexus pathology in birds requires further study.

## GLIOMAS OF THE DOMESTIC FOWL.

### *Nodular Regenerative Polymyositis.*

This is a rare condition, poorly understood, and probably has often been erroneously interpreted. It has not been described in birds; but the literature contains cases diagnosed as (multiple) rhabdomyomas or rhabdomyosarcomas and some cases of so-called fibrosarcomas of the musculature which I suspect in reality to have represented this disease. Three cases have been encountered by me in fowls, two of which were the subjects of glioma. In the third case no record of a brain lesion exists. In two cases the breast musculature and in one case the intercostal musculature was involved. It is hoped to study further this very obscure condition.

## APPENDIX II.

### SELECTED CASE REPORTS.

#### *Type I Glioma.*

##### *Case 27562.*

Adult W. L. Hen, P. M.—Right optic lobe greatly enlarged to more than twice its normal size, distorted in shape and showed a pronounced yellow-orange discoloration (fig. 1). *Microscopically*: Right optic lobe contains three larger lobulated tumours and about half-a-dozen smaller ones, occupying at least five-sixths of the substance of the lobe and encroaching extensively on the ventricle. The ventricular ependyma is reactive (reversion to ependymal spongioblasts). There is a stroma of evenly dispersed bloodvessels with hypertrophied walls and hyperplastic endothelium, and showing infiltration by lymphocytes, monocytes, macrophages, and plasma cells, sometimes also pseudo-eosinophil leucocytes. Around these vessels the tumour cells are disposed in pronounced radiating arrangement (figs. 5, 6 and 7). They impregnate heavily and precisely with both Cajal's gold-sublimate and Hortega's silver carbonate. They are for the most part large angular elements with eccentric nuclei and cytoplasmic processes, especially a robust vascular process directed to the vessel wall and ending in a sucker-foot expansion. Between these perivascular masses of cells is a looser arrangement of tumour cells. Multinucleate cells are seen occasionally. The larger tumours show moderate central cavitation developing from microcystic degeneration. Glia fibrils are developed in parts. Nerve cells are seen in process of being overtaken by the tumours and sometimes persisting well inside the tumour tissue. Haemofuscin pigment is seen in the infiltrating cells especially within the cavities. At the margin of the tumours pronounced multiplication and hypertrophy of bloodvessels is seen and these together with surrounding hypertrophied astrocytes are in many places in process of being added to the tumour tissue—growth by conversion. Rare mitoses are present. *Diagnosis*: Multiple Type I Gliomata of optic lobe.

#### *Type II Glioma.*

##### *Case 35538.*

An 18-months-old W.L. Hen, killed for autopsy, showed extensive orange-coloured growths throughout the right cerebral hemisphere and similar lesions were also present in the left hemisphere. A sister of this bird had also suffered from gliomatosis.

*Microscopically*: Multiple tumours are present in both cerebral hemispheres, more in the right than in the left. They vary greatly in size, the larger ones being lobulated. There is an irregular stroma of hypertrophied bloodvessels with surrounding infiltrating cells. The tumour cells are multiform in shape, patternlessly arranged, and do not impregnate with Cajal's gold-sublimate, in contrast to the astrocytes of the surrounding brain tissue (figs. 8 and 9). Around the tumours there is a striking zone of abnormal brain tissue showing vascular multiplication and hypertrophy, perivascular infiltration of "round" cells, and pronounced hypertrophy and hyperplasia of astrocytes (figs. 24 and 30). These astrocytogenous cells become incorporated in the tumour tissue and as they do so their ability to impregnate with Cajal declines and finally ceases (fig. 32). The walls of both lateral ventricles are involved by the tumours and the ependymal cells in many places have been stimulated to revert to ependymal spongioblasts. Haemofuscin pigment is present in the tumour tissue and especially in macrophages lying within cystic cavities in the larger tumours (fig. 80). Glia fibrils are present sparsely in some of the larger tumours. Mitosis was not seen. Apart from the changes in the marginal zone around the tumours, multiple foci of perivascular encephalitis are present and all transitions occur between these foci and early gliomas. Confluence of such transforming foci is seen, leading to the production of the larger lobulated tumours (fig. 43). *Diagnosis*: Multiple Type II Gliomata, with focal perivascular encephalitis and transitions to tumours, affecting both cerebral hemispheres.

*Case 34608.*

A W.L. Pullet aged about 8 months, killed for autopsy, showed orange discoloration and enlargement of both optic lobes. *Microscopically*: Both optic lobes are very severely involved by multiple, in part confluent tumours, replacing about nine-tenths of the nervous tissue (fig. 4). There is a stroma of bloodvessels with hyperplastic endothelium and greatly thickened walls due to increase of elastic and collagen fibres (fig. 26). The neoplastic cells are of the astrocytic series, pleomorphic, and considerably anaplastic—much enlarged nucleoli, nuclei of distorted shapes, markedly eccentric and hyperchromatic and often partly or even wholly occupied by hyaline intranuclear inclusions. Mitoses present. Some of the tumours contain cavities filled with metachromatically staining fluid and infiltrating cells. The ventricles of both lobes are encroached into and ependymal de-differentiation is noted. Haemofuscin pigment is present in considerable amounts both around the blood vessels and in the tumour cells. In a broad zone around the tumours the vascular changes described above are again seen, together with pronounced astrocyte hypertrophy around these vessels. All stages are seen in the transformation of these pre-existing astrocytes to tumour cells and their addition to the edge of the tumours. This growth by conversion is so active that in parts it becomes almost impossible accurately to define the tumour margin. A section of the cerebellum shows multiple disseminated foci of non-purulent perivascular meningo-encephalitis, and transitions are seen between encephalitic foci and early gliomas located within the foliae. *Diagnosis*: Multiple Type II Gliomata affecting both optic lobes, and focal non-purulent meningo-encephalitis of the cerebellum with transitions to early gliomata.

*Type II (a) Glioma.**Case 36200.*

An adult W.L. Hen, killed for post mortem, showed severe suspected gliomatosis of the left cerebral hemisphere especially in its frontal portion. *Microscopically*: Several large lobulated tumours and occasional smaller simple tumours are present in the left cerebral hemisphere. There is a pleomorphic celled gliomatous moiety not impregnating with Cajal at 6 hours and even at 23 hours impregnating far more imperfectly and weakly than the astrocytes of the surrounding brain tissue. Perivascular lymphocytic infiltration in and at the edges of the larger tumours is extreme, culminating in the formation of actual nodules of lymphoid tissue with germ centres (fig. 70). The reaction zone around the margin of the tumours is very exaggerated. The lateral ventricle is involved and pronounced ependymal reactivity is noted. Cavitation is present in the tumours. Rare foci of non-purulent perivascular encephalitis are present in this brain. Haemofuscin pigment is present in the gliomatous tissue, in the lymphomatous tissue, in the marginal conversion zones, and in the encephalitic foci. *Diagnosis*: Multiple Glioma lymphomatosum, with concomitant focal non-purulent encephalitis.

*Type II (b) Glioma (for illustrations of the microscopic structure of similar tumours, see figs. 71–73).**Case 34537.*

A 7-months-old W.L. Pullet suffering from paralysis and persecution by its fellows was destroyed and at post mortem showed orange discoloration and enlargement of both cerebral hemispheres. *Microscopically*: In both hemispheres there are multiple tumours of variable size from lobulated lesions ca. 0.5 cm. in diameter to microscopic lesions. There is a pleomorphic-celled gliomatous moiety impregnating poorly with Globus-Cajal (in contrast to the astrocytes of the surrounding brain tissue) and demonstrated much better by means of Hortega IV and Mallory's phosphotungstic acid haematoxylin. Arranged in columns and groups separated by the processes of these tumour cells are elements identified as of the monocytic series—monoblasts, monocytes, and especially monocytic plasma cells with angular, often triangular outline, intensely basophilic cytoplasm and leptochromatic although trachychromatic nuclei. The cells of this second moiety tend to predominate over the glia cells in the smaller tumours. Mitoses occur among the cells of both moieties, but much more frequently among the cells of the monocytic series. The gliomatous moiety is rich in glia fibrils. Cavity formation with mucinous fluid is present. Both lateral ventricles are extensively encroached upon and show a reactive ependyma. In addition to the tumours there are multiple smaller foci of perivascular encephalitis in which stasis, emigration and multiplication of the cells of the monocytic series is prominent. All gradations occur between these foci and the smaller tumours. Haemofuscin pigment is demonstrable. *Diagnosis*: Multiple Glioma monoblastomatosum of cerebrum, with encephalitic foci and transitions between these foci and tumours.

*Mixed Liver Tumours Concomitant with Glioma.*

## Case 36251.

An adult W.L. Hen which was not laying and appeared stupid, was inclined to veer from side to side when running and to lift its legs abnormally high when walking. It was killed and on post mortem there was a suspected glioma "involving the whole of the right cerebral hemisphere". Two tumours were also present in the liver: On the dorsal border of the right lateral lobe<sup>(15)</sup> a tumour mass 3.5×1.5×1.0 cm. described as pinkish-yellow-orange in colour, unencapsulated, and poorly demarcated from the surrounding liver tissue; on the parietal surface of the right central lobe, a definitely orange-coloured tumour 0.75×0.5 cm., raised above the surface. These tumours were suspected to be lymphocytomas. *Microscopically*: Right cerebral hemisphere—multiple, confluent, well-developed gliomas—type II, showing cavity formation, demonstrable mucin, and prominent perivascular plasma cell infiltration. Left optic lobe—in the deep grey matter there is a single minute focus in structure transitional between an encephalitic focus and a small glioma, which ordinarily would probably be assessed as already having "attained neoplastic grade". Cerebellum—multiple focal non-purulent encephalitis. The liver is not cirrhotic. The larger of the liver tumours (fig. 74) is composed of two tissues: (1) Bile-duct epithelium growing partly in regular tubular or adenomatous pattern and partly in irregular carcinomatous arrangement. There are numerous mitoses. (2) Pseudo-eosinophil myelocytes including pro-myelocytes, and fewer myeloblasts. There are many mitoses. These two tissues are often intimately intermingled, sometimes more separate. Both are growing invasively into the surrounding liver tissue. Haemofuscin pigment is present in both types of tissue and even accumulates in the lumen of the neoplastic bile-ducts. A collagenous stroma is present, in which the bloodvessels show pronounced "round cell" infiltration. The smaller liver tumour (fig. 75) is composed of a much more regular, entirely tubular arrangement of bile-duct epithelium. Nevertheless mitoses are present and there is invasive growth into the liver tissue. Centres of proliferating myelocytes are present but less prominent. Haemofuscin pigment is again seen. There is a collagenous stroma with perivascular lymphocytic infiltrations forming actual lymphoid nodules. There is no encapsulation whatever. *Diagnosis*: (1) Advanced multiple gliomata (type II) of cerebrum. (2) Early glioma (arising from an encephalitic focus) of optic lobe. (3) Mixed liver tumours: (a) Carcinoma cholangiocellulare myelocytomatousum, (b) Adenocarcinoma cholangiocellulare myelocytomatousum. (4) Congenital anomaly of the liver (four-lobed, which is abnormal for the species).

## Case 9805.

This fowl was the subject of the second of the two gliomas reported by Jackson (1936). There was an advanced type II glioma situated in the central white matter of the cerebellum, replacing the deep grey nuclei but also encroaching extensively on the bases of the foliae. There were in addition multiple lesions in the liver, up to the size of 1 cm. in diameter, which at that time remained undiagnosed. Re-examination shows these liver tumours to be thickly encapsulated by collagen (fig. 76). There is a fibroblastic and collagenous stroma in which there is much perivascular infiltration by lymphocytes and plasma cells, in places forming actual lymphoid nodules. The parenchyma is complex: (1) Bile-duct epithelium in regular tubular arrangement. Mitoses can be found but are rare. (2) Cords of cells having the characters of liver cells but not arranged in lobules. But their arrangement in the cords is regular, although the lumen (canaliculus) is larger than is normal for the avian liver. These cells contain many needle-like crystals of bilirubin as well as excessive fat droplets. Mitosis is detectable on prolonged searching, but is extremely rare. (3) Proliferations of myelocytes in all stages of maturity. Mitoses occur. The liver shows no cirrhosis. *Diagnosis*: Central cerebellar type II glioma; concomitant multiple liver tumours of the nature of mixed cholangiocellular and hepatocellular adenomas, admixed with myelocytomatous tissue—terminology: Adenoma cholangiocellulare et hepatocellulare myelocytomatousum.

## Case 34607.

An adult R.I.R. Hen, killed for autopsy, showed suspected gliomatosis of the left optic lobe and of the frontal pole of the right cerebral hemisphere. In addition there was a 1 cm. diameter tumour in the liver. Of the latter tumour it was remarked: "Very peculiarly this turned yellow after a couple of days in formalin. Gliomas are orange coloured but they lose their colour in formalin". *Microscopically*: In the right cerebral

<sup>(15)</sup> The liver was anatomically abnormal for the species, having four distinct lobes separated by well-defined fissures.

hemisphere and left optic are multiple tumours composed of (1) a pleomorphic gliomatous moiety well demonstrated by Hortega IV and not impregnating with Globus-Cajal as do the astrocytes of the surrounding normal brain tissue. (2) Tending to predominate over this are cells of the monocytic series arranged in packets; the angular outlines of the monocytic plasma cells being very striking (figs. 71, 72 and 73). Mitoses occur frequently among the monoblasts and the plasma cells, and also occur among the glia cells. Cavitation is present in the tumours as a result of confluence of "microcysts" and the contained fluid stains metachromatically. The bloodvessels of the stroma and at the margin of the tumours are surrounded by infiltrating cells, largely lymphocytes, but there is also emigration of pseudo-eosinophil leucocytes. Haemofuscin pigment is present. In addition to the actual tumours, perivascular foci of non-purulent encephalitis are present in both optic lobes and all transitions occur between these foci and small tumours. Liver: The tumour described as a single lesion microscopically is seen to consist of two entirely distinct nodules separated by about 2 mm. of intervening liver tissue. They are encapsulated but in parts have broken through the capsule to form outlying lobules of tumour tissue. Although these tend to become re-encapsulated, there is also seen direct invasive spread into the surrounding liver tissue (fig. 77). There is a coarse irregularly lobular collagenous stroma containing the larger bloodvessels and a fine reticular stroma which supports (1) glandular epithelial cells of two types (see figs. 78 and 79): (a) cells with finely granular cytoplasm and indistinct outlines, arranged in cords with an indistinct central lumen. The nuclei are vesicular with prominent nucleoli (neoplastic liver cells); (b) elongated ducts lined by columnar cells with oval nuclei, indistinct nucleoli, clear pale cytoplasm and distinct cell boundaries (neoplastic bile-duct epithelium). (2) Irregular groups of proliferating pseudo-eosinophil myelocytes (immature nuclear characters, all stages in ripening of the specific granules, most of which are still in the rounded and basophilic phase (see fig. 79). Mitoses can be found among all three of the cell types described but are seen chiefly among the myelocytes. Infiltrating lymphocytes, monocytes and plasma cells are seen. Haemofuscin pigment was demonstrated, although with some difficulty. *Diagnosis:* (1) Multiple Type II (b) gliomata of cerebrum and optic lobe, with transitions from foci of non-purulent encephalitis. (2) Adenocarcinoma hepatocellulare et cholangiocellulare of the liver, this tumour showing the gradation of adenoma into adenocarcinoma.