

Intravascular Changes.

Often to be observed is an intravascular stasis, especially of lymphocytes and monocytes, less often of pseudo-eosinophils. These cells are destined to emigrate through the vessel wall, but even before doing so they may commence to multiply by mitosis (fig. 27).

Perivascular Changes.

There is perivascular infiltration especially by lymphocytes and monocytes (fig. 28). Some of these cells (the proportion varies with the severity of the changes) are immature—"lymphoblasts" and "monoblasts". These cells of the lymphocytic and monocytic series are capable of multiplying by mitosis, both after as well as before emigration from the vessels. And both transform freely into plasma cells (fig. 29), many of which on nuclear characteristics can easily be classified as lymphocytic or monocytic plasma cells.⁽⁶⁾ The plasma cells are

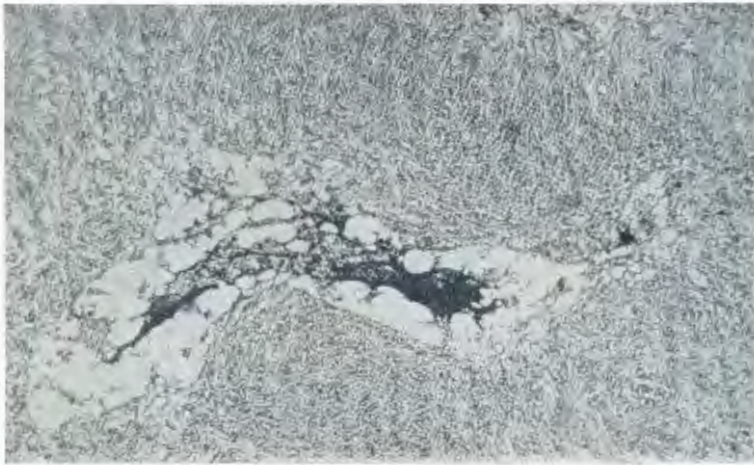


FIG. 23.—Metachromatic reaction of the mucinous contents of a cavity in glioma. (Giemsa.)
X 100. (34538.)

of all sizes and could roughly be classified as small, medium, and large. Their cytoplasm may show chromophobic vacuolations which are the precursors of the Russell bodies which are encountered occasionally. The plasma cells, perhaps even more than the other cell types, continue to increase by mitosis. Many of them are accurately adapted to the tissue spaces formed by the walls of the other cells and this adaptation (triangular or columnar outlines) may be preserved even in smears (fig. 2). Less often pseudo-eosinophils participate. Sometimes the latter are immature (myelocytes) in which case mitoses may be seen among them also. The accumulation of lymphocytes and plasma cells may reach enormous proportions—actual lymphoid nodules containing secondary nodules ("germ centres") may be observed, with gradations to what must be considered

⁽⁶⁾ This dual origin of plasma cells is not peculiar to avian species; on the contrary, it is in full accord with the origin of mammalian plasma cells as recently emphasised by Jackson and de Boom (in press). A review of the literature on this point will be found in the publication cited (see "References").

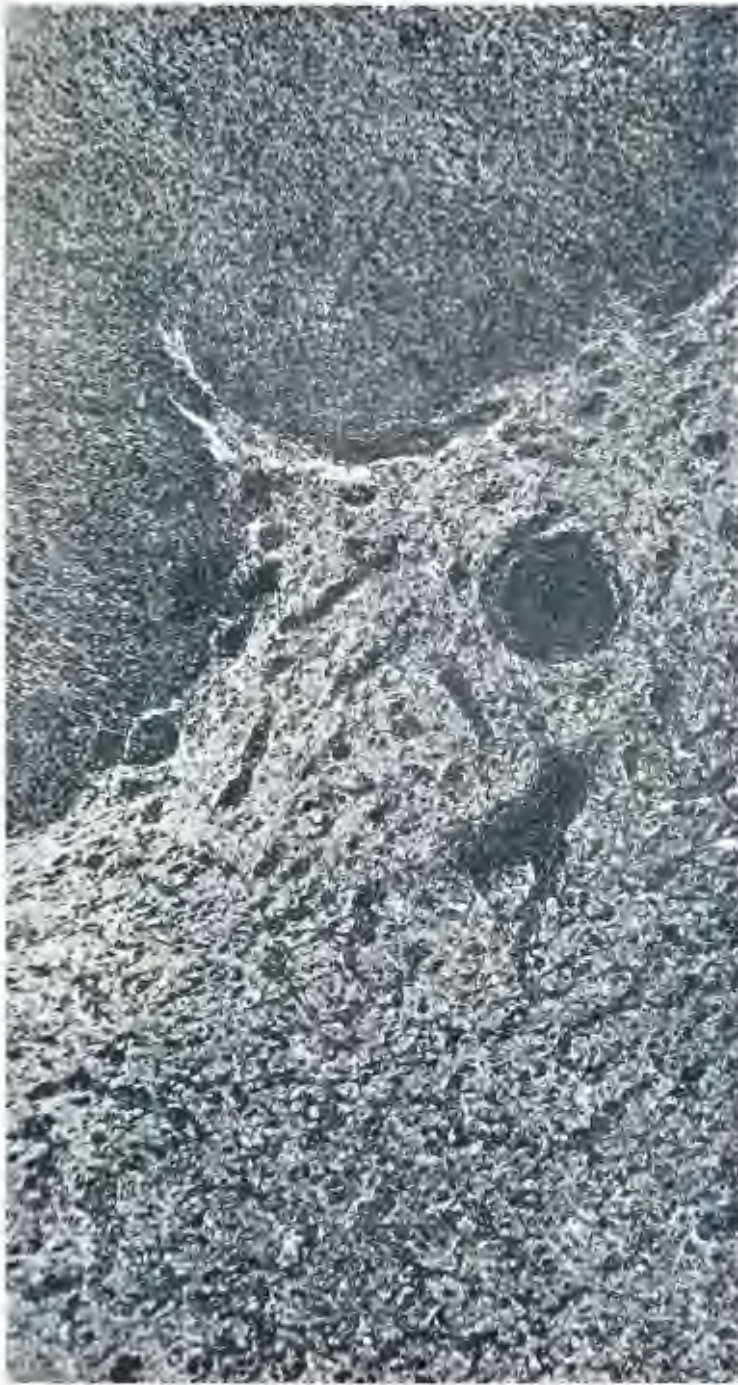

FIG. 24.—General view of the abnormal brain tissue (centre) at the margin of glioma (right). The vascular and perivascular changes described (including vascular hypertrophy, perivascular infiltration, and perivascular gliosis) are prominent, in contrast to the relatively normal brain tissue (left). (Hortega IV.) X 125. (35538.)

as lymphomatous tissue. (See later under "Mixed Gliomatous and Mesenchymal Tumours"). The number of monocytes among the infiltrating "round cells" is perhaps better appreciated in smears (see fig. 2) than in sections. It has already been stated that these monocytic cells are capable of multiplication and some of them are thus presumably to be termed "monoblasts". Perivascular pigmentation is seen and will be dealt with later.

These altered vessels with their surrounding infiltrations later become incorporated in the tumour to form the septa between tumour lobules (fig. 44 and p. 540). The infiltrating cell types are well depicted among the tumour cells in fig. 2.

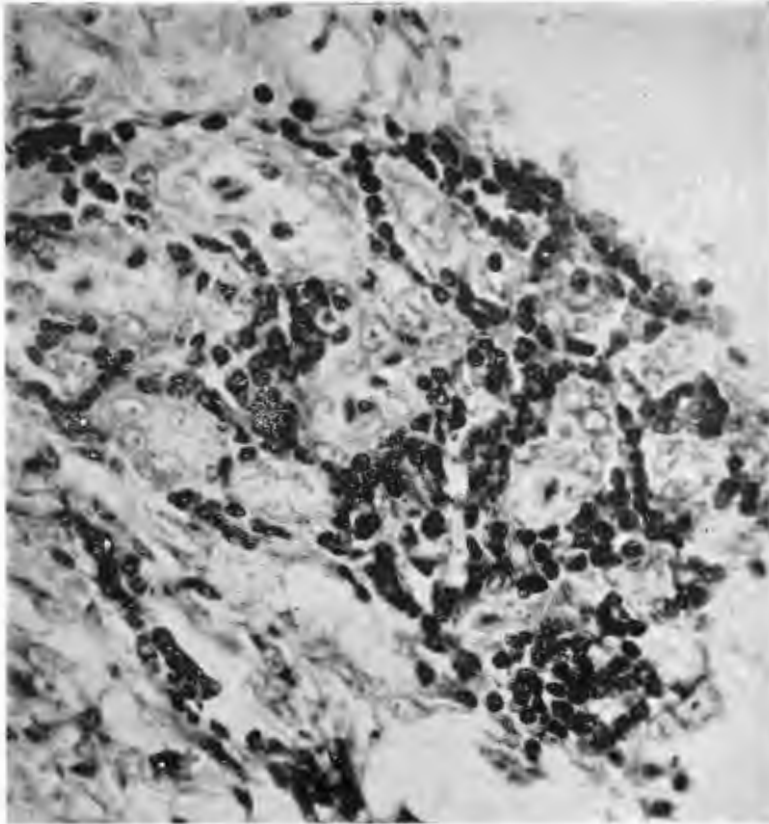


FIG. 25.—Vascular multiplication and endothelial hypertrophy at the margin of glioma. In several vessels the endothelium almost obliterates the lumen. Perivascular cellulation is also seen. (Giemsa.) X 470. (34636.)

(2) *Marginal Gliosis and its Significance in the Growth, Spread and Histogenesis of Gliomas.*

Of perhaps even greater interest, because of its intimate bearing on the histogenesis of the tumours, is the perivascular gliosis which occurs in a zone of variable width around the margin of the tumours. This change varies in severity. When severe it is readily appreciated in sections stained with routine

GLIOMAS OF THE DOMESTIC FOWL.

technique (fig. 31), but with Cajal and Hortega methods it is especially striking (fig. 30) and is more favourably shown up in the less severe cases. The astrocytes of the surrounding brain tissue enlarge and increase in numbers. They are capable of multiplying by mitosis, and often they also become binucleate. These previously "protoplasmic" astrocytes sometimes show a tendency to develop glia fibrils (fig. 31), which usually appear as differentiations of the ectoplasm of the cell. At times this may affect the entire substance of an ectoplasmic process, the whole of which then stains blue (instead of tan) with Mallory's phosphotungstic acid haematoxylin.

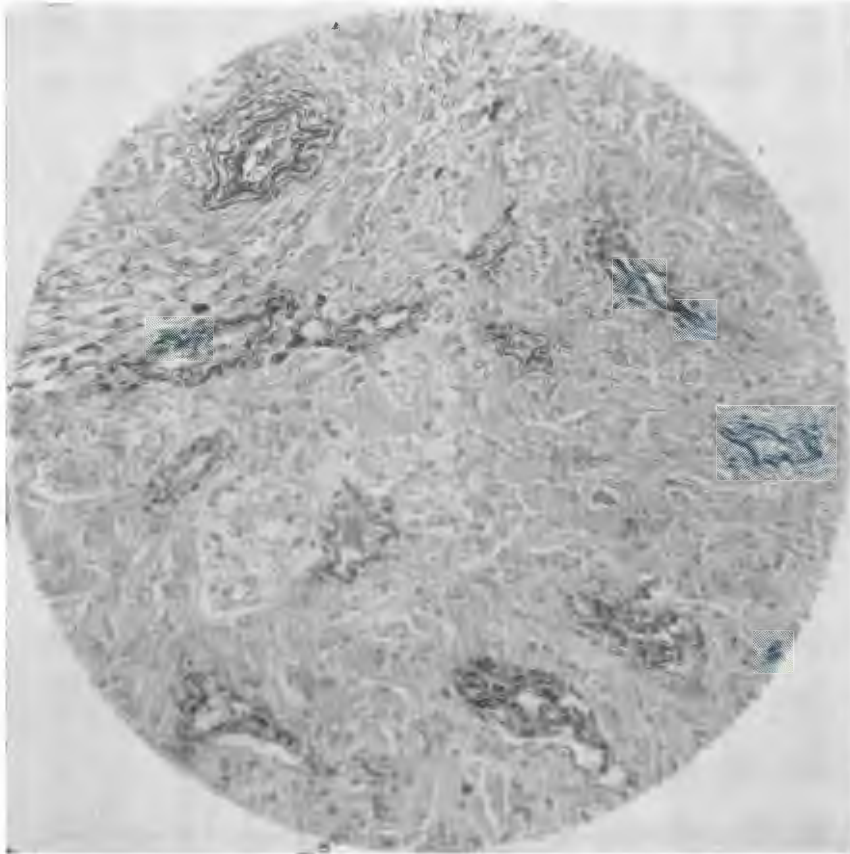


FIG. 26.—Deposition of elastic tissue in the vessel walls at the margin of glioma. Growth by conversion of surrounding astrocytes and bi-nucleation of these cells can also be seen. (Orcein-methylene blue.) X 280. (34608.)

For a variable time these cells take on the character of astroblasts. They tend to become elongated and their processes become less conspicuous (being, as it were, in part taken up into the increased cytoplasmic body of the cell), with the exception of the vascular process which comes to exceed all the other processes in its development. In this stage they continue to impregnate heavily and readily with silver or gold. By morphological definition *they are astroblasts, although derived by a direct reversionary transformation of pre-existent astrocytes.*

Step by step with their incorporation into the tumour tissue the ability of these cells to impregnate declines (fig. 32). A cell process which becomes buried within the tumour margin will cease to impregnate, while processes of the same cell outside the tumour tissue will still impregnate; and the degree of impregnation of a given process declines progressively the deeper it becomes buried in the tumour tissue. These cells have ceased to be astroblasts (by definition): they have become spongioblasts (glioblasts). Ultimately there is complete loss of impregnatability under the conditions in which astrocytes and marginal astroblasts in the same block of tissue become impregnated. However, it is possible, by

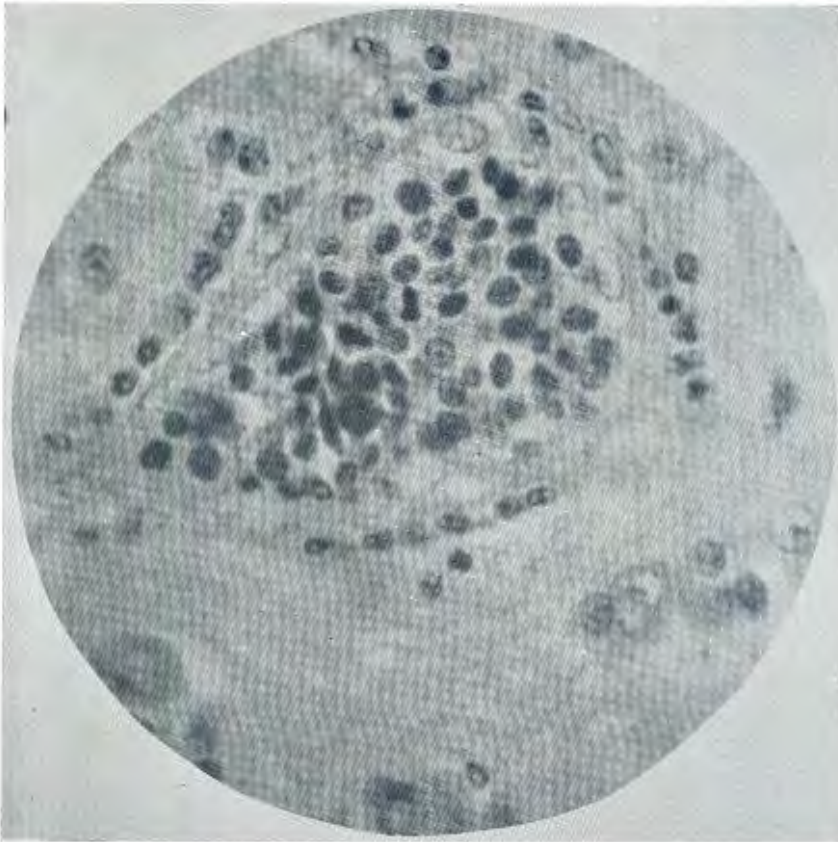


FIG. 27.—Bloodvessel at margin of glioma showing pronounced intravascular stasis of lymphocytes and monocytes, several of which are already undergoing mitosis. These haematogenous cells are also seen migrating through the hypertrophied endothelium into the perivascular space. (H.E.) X 1200. (35048.)

increasing the vigour of impregnation beyond the customary degree for demonstration of astrocytes and astroblasts, to secure impregnation of the newly incorporated elements at the edge of (but already within) the tumour. In fig. 33 the impregnation has been pressed in this way, with the result that the marginal (and youngest) tumour tissue, composed of cells still preserving a perivascular

GLIOMAS OF THE DOMESTIC FOWL.

alignment appears to be almost as deeply impregnated as the astrocytes of the surrounding brain tissue, while the rest of the tumour cells show relative loss of impregnability even under the vigorous conditions of the technique.

The foregoing paragraph, however, applies only to the histogenesis of Type II gliomas. In the rare case of Type I glioma the marginal astroblasts preserve an orderly arrangement around the blood vessels with which they become incorporated to form the tumour tissue, and they remain in the stage as astroblasts and continue to impregnate by Cajal's and Hortega's silver carbonate methods (fig. 5-7).



FIG. 28.—Perivascular infiltrations (chiefly of lymphocytes, plasma cells and monocytes) in the brain tissue at the margin of glioma (below). (Normal brain tissue above.) Giemsa. X 125. (34987.)

In avian gliomas there is thus never evidence of histogenesis from *embryonal* cells, which thereafter tend to differentiate in varying degrees in *recapitulation* of embryonic histogenesis. Instead, there is abundant proof of derivation of these tumours from *adult cells* which *recapitulate their embryonic ancestry in reverse order*—by *de-differentiation*. Where adult astrocytes de-differentiate as far as astroblasts and no further, an astroblastoma results. Where de-differentiation of adult astrocytes proceeds still further to spongioblasts—a spongioblastoma is the outcome. (?) (See footnote on next page.)

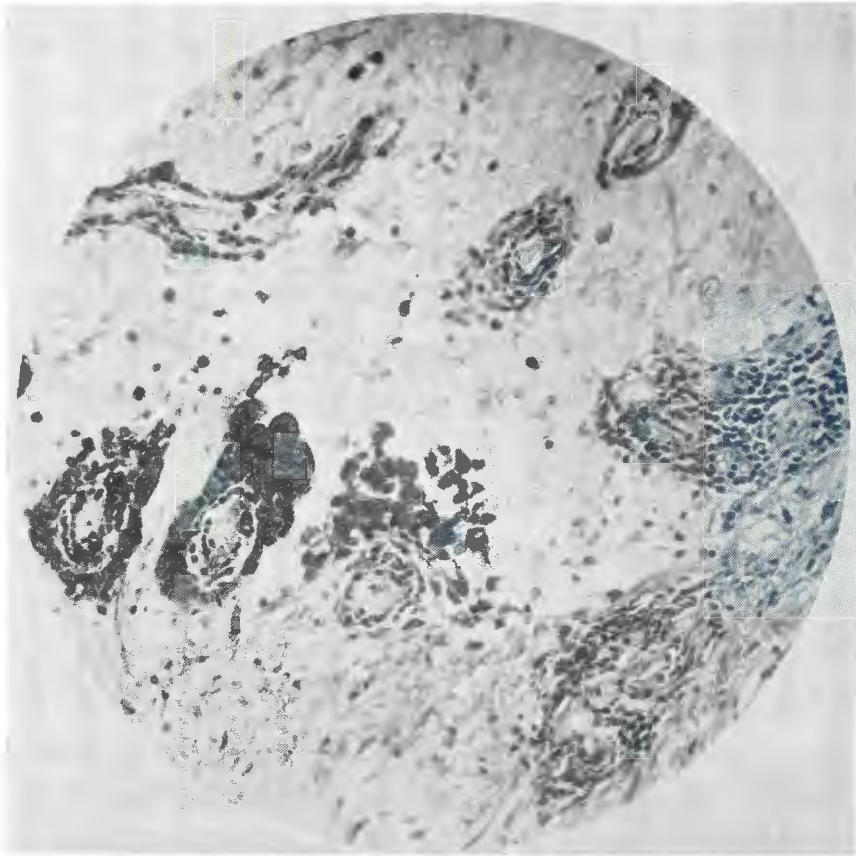


FIG. 29.—Variations in the cell types forming perivascular infiltrations at the margin of glioma (below). Some vessels (left and centre) show great predominance of plasma cells, while others (right) show chiefly lymphocytes and monocytes. The progressive decline in the severity of the changes further from the tumour is also seen. (Giemsa.) X 400. (34636.)

(⁷) Since this was written and as it goes to press, the embryonal theory, criticised by Walshe (1930-1) and by Scherer (1940), and of which doubts were also expressed by Hatfield and Garrod (1934), has been outspokenly condemned by Svien *et al.* (1949), and by Kernohan *et al.* (1949), dealing especially with the astrocytoma-astroblastoma-glioblastoma series of human tumours and also with the ependymoma-ependymoblastoma group. The claims of these authors, although I believe them to be entirely correct, are based merely on observing intergrades both between the different tumours and between the cell types. Such gradations could, of course, still be explained theoretically just as well on the basis of varying degrees of differentiation of embryonal cells as by de-differentiation of adult cells—a reply which proponents of the embryonal theory will doubtless make in defence. Final proof can be obtained only by a study of the actual histogenesis, especially by observing the de-differentiation of adult cells at the time of inception of a glioma, as can be so readily done in the case of the fowl. Such opportunities are extremely restricted in the case of man, but doubtless the importance of looking out for them is insufficiently appreciated. Evidence may also be obtained by observing de-differentiation and “conversion” of previously adult astrocytes at the margin of well-established tumours. This point also will be returned to later in the present article.

GLIOMAS OF THE DOMESTIC FOWL.

It has also been described how adult ependymal cells affected by collateral hyperplasia, in cases of gliomatosis affecting the ventricles, readily retrace their embryonic ancestry by reverting to ependymal spongioblasts. The same process is seen in ependymal tumours of man, where the occurrence of ependymal spongioblasts is worthless as evidence of a derivation from embryonal cells.

The evidence shows clearly that the growth of avian gliomas and their progressive spread into the surrounding brain tissue occurs far less from their own resources than from continued accretion of previously normal and adult cells of the surrounding brain tissue (growth by conversion). The term "invasion" (of surrounding tissues by neoplasms) is scarcely a fortunate one where it is applied to tumours which grow in this manner.

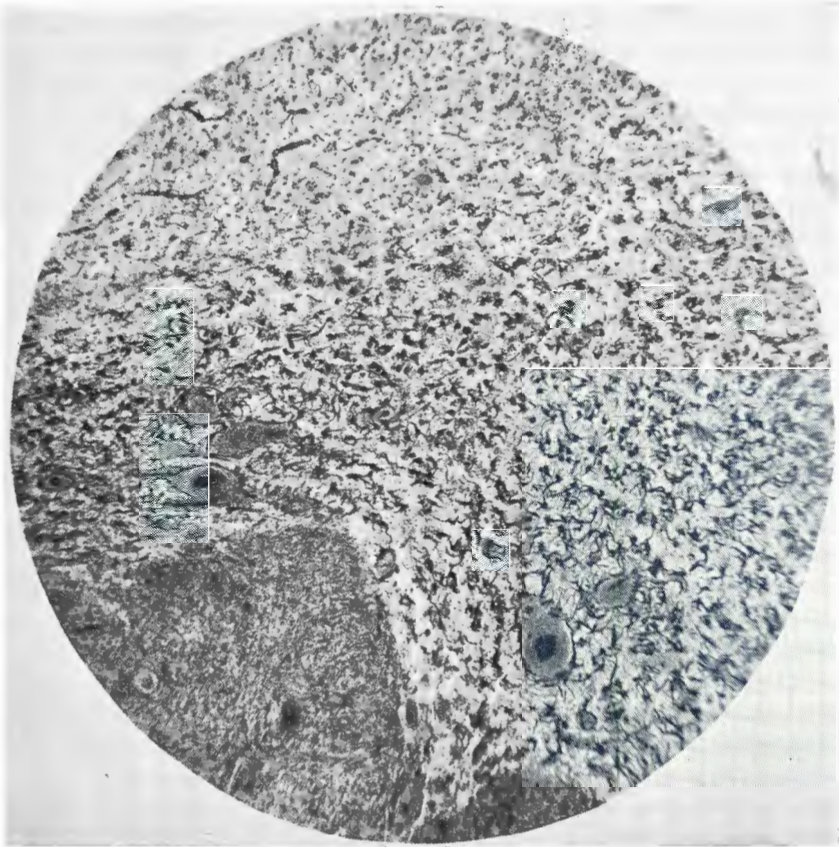


FIG. 30.—Perivascular gliosis in the marginal zone around a glioma (below). The pronounced hypertrophy and hyperplasia of the astrocytes is appreciated when compared with those of the normal brain tissue (above). (Cajal's gold sublimate.) X 75. (35538.)

Lastly, as will be dealt with in more detail later, the youngest of multiple gliomas are seen to arise from pre-existent perivascular astrocytes as independent primary foci, not by any form of cellular metastasis whatever.

3. *The Fate of Brain Tissue "Invaded" by Glioma.*

This question has been largely covered by the foregoing: the astrocytes are destined to be incorporated as a permanent part of the neoplastic "parenchyma", either as astroblasts or as still more de-differentiated cells (spongioblasts). Thus it is largely incorrect to speak of "invasion" of the surrounding tissue by the tumour, when in fact this "invasion" is merely simulated by *conversion* of surrounding cells to tumour tissue. It is scarcely correct to speak even of the "spread" of such tumours in the brain. It would be at least as accurate to say that the brain tissue "spreads into" the tumour. Although the term "growth by conversion" is nowadays well known in its application to neoplasia, pathology is still sadly deficient in detailed terminology whereby to describe the various phenomena and appearances which this involves. It must always be remembered that previously normal elements in process of accretion to the margin of a tumour

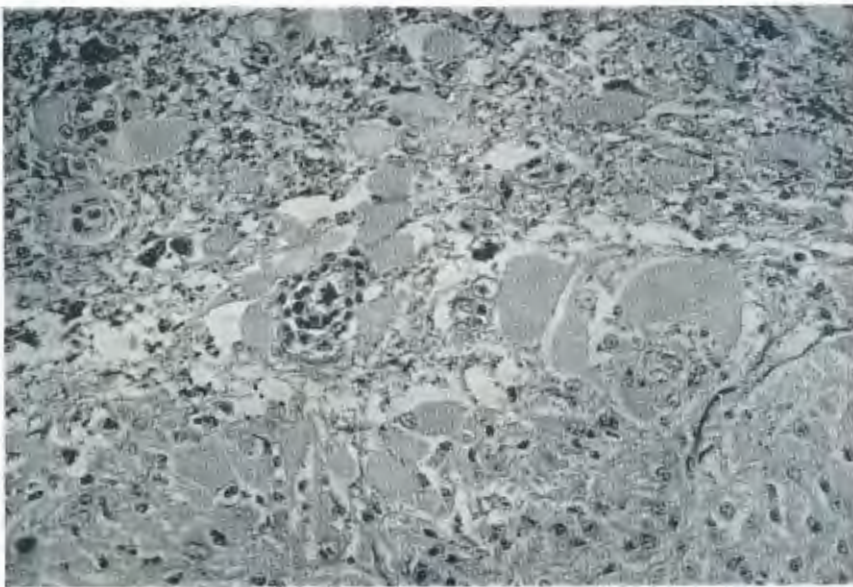


FIG. 31.—Growth of glioma by conversion. The edge of the tumour is seen about one inch from the lower margin of the picture. Outside it (centre) are seen the often enormously hypertrophied perivascular astrocytic glioma cells, which everywhere are being added to the tumour cells at the margin. Above, the changes are less severe and one sees gradations from astrocytes of more normal size. Occasionally gliofibrils are seen in the conversion zone (right). (Phosphotungstic acid haematoxylin.) X 480. (34609.)

are only too likely to be misinterpreted as tumour cells invading the surrounding tissue. Ultimately, as is the case in this study of fowl gliomas, the differentiating test is the demonstration that as the supposed "invading" cells are followed further from the tumour margin, there is a gradual grading over to normal cells—a *decrease* ending in disappearance of, instead of a *maintenance* of, "anaplastic" characters; in other words, a loss of differentiation *from without inwards*.

The hypertrophied bloodvessels also become incorporated, but many become partly or completely obliterated by the progressive sclerosis described. If they do not, then this may well be the reason for the development of astroblastoma

GLIOMAS OF THE DOMESTIC FOWL.

instead of the usual glioblastoma; for I am inclined to believe that the ability to preserve the cytological characteristics of astroblasts may depend on the maintenance of a sucker-foot connection with a vessel carrying an efficient circulation, and that decline of impregnability and subsequent changes in cell form may follow dislocation and atrophy of the vascular process.

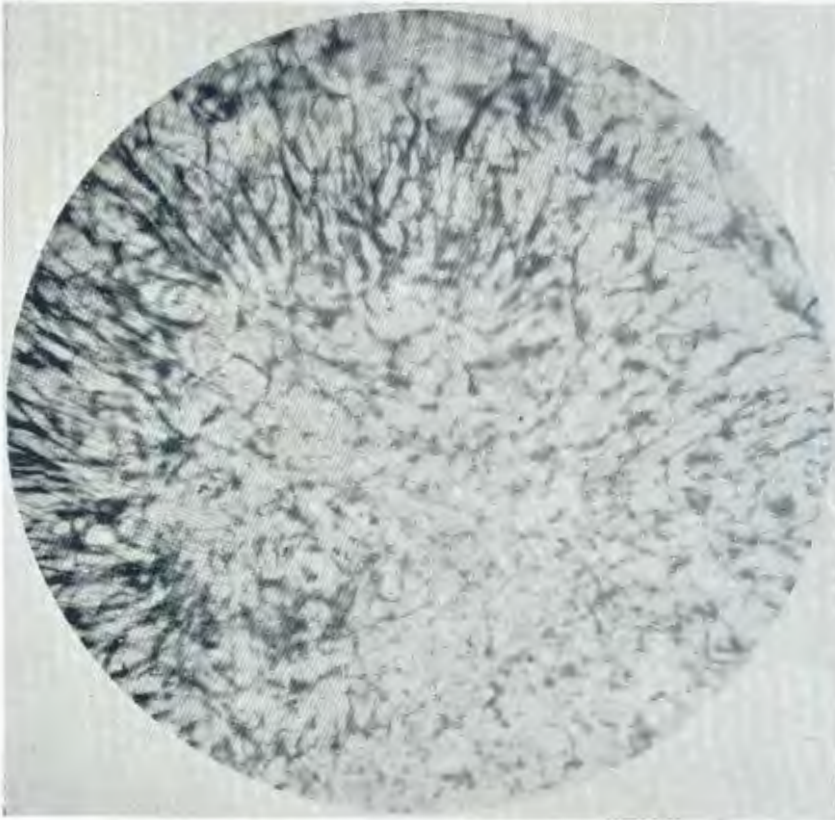


FIG. 32.—Loss of ability of the astrocytic cells of the conversion zone (left and above) to impregnate as they become incorporated in the tumour (below). Margin of Type II glioma. (Cajal's gold sublimate.) X 400. (35538.)

The fate of oligoglia and microglia has not been followed, in the absence of any evidence to suggest that such study would prove of more than academic interest. But it is quite clear that the "round cells" and the monocytes and "histiocytic" elements of the stroma of fowl glioma are haematogenous elements; not mobilised microglia, as might erroneously be anticipated from general knowledge of brain pathology and as was erroneously thought to be the case by Belmonte (*loc. cit.*) in his discussion of reactive changes in the neighbourhood of and far removed from the tumour reported by him.

The fate of nerve cells is often incorporation in the tumour (fig. 34). Usually such incorporated cells undergo a degenerative atrophy, so that they are most often seen near the margin of the tumour rather than deeply in its interior. But

this is not invariable: well-preserved neurones may sometimes be encountered in the depths of the tumour tissue. They have even been seen lying within the central cavities mentioned previously (fig. 35).

This phenomenon of long survival of incorporated neurones in tumours is of some considerable importance in neuropathology, from the viewpoint of distinguishing neoplasms of glia lineage from those of neurone lineage. There are cases in human pathology in which it is necessary to exercise caution and take pains to exclude the danger of mistaking incorporated surviving pre-existent nerve cells for differentiation along neurone lineage of the tumour cells themselves. The same caution in diagnosis is necessary when assessing the significance of nerve fibres in tumours. Care must be taken to demonstrate that they are actual processes of the tumour cells before attaching diagnostic significance to them.

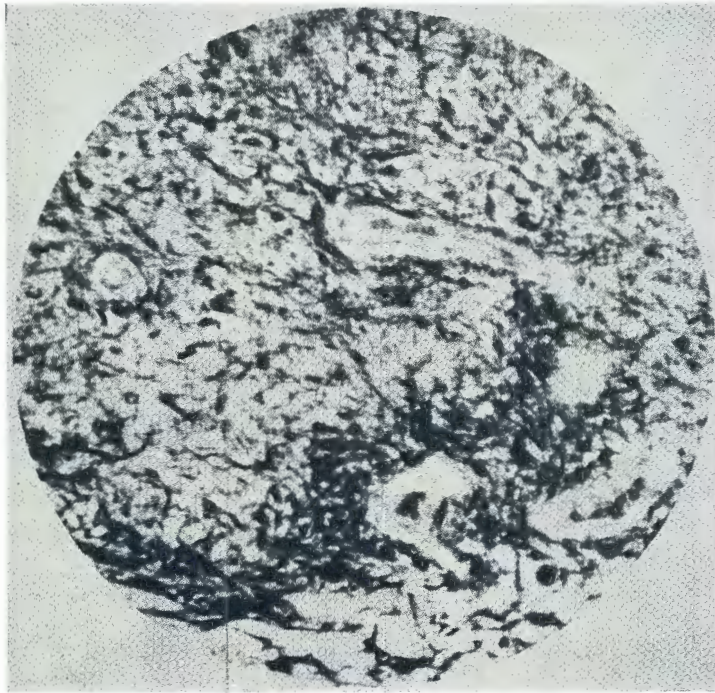


FIG. 33.—Decline of impregnatability of the newly incorporated cells has here been compensated by prolonging the silver impregnation (overnight). Below (at extreme edge)—the marginal tissue showing astrocytes impregnated. Just above this, the edge of the glioma, composed of recently incorporated cells still retaining perivascular alignment and also impregnated under these conditions of technique. But in the rest of the tumour (centre and above) the cells have declined still further in affinity for gold and even under the vigorous conditions of technique are but slightly or not at all impregnated. (Cajal's gold sublimate, over-night.) X 200. (25538.)

V. THE RELATIONSHIP BETWEEN GLIOMA AND OTHER LESIONS.

1. *Concomitant Encephalitis and its Significance.*

The most frequent concomitant lesion of the brain in cases of fowl glioma is a non-purulent disseminated focal perivascular encephalitis. This condition exists (independently of the marginal lesions discussed) in the great majority of cases

GLIOMAS OF THE DOMESTIC FOWL.

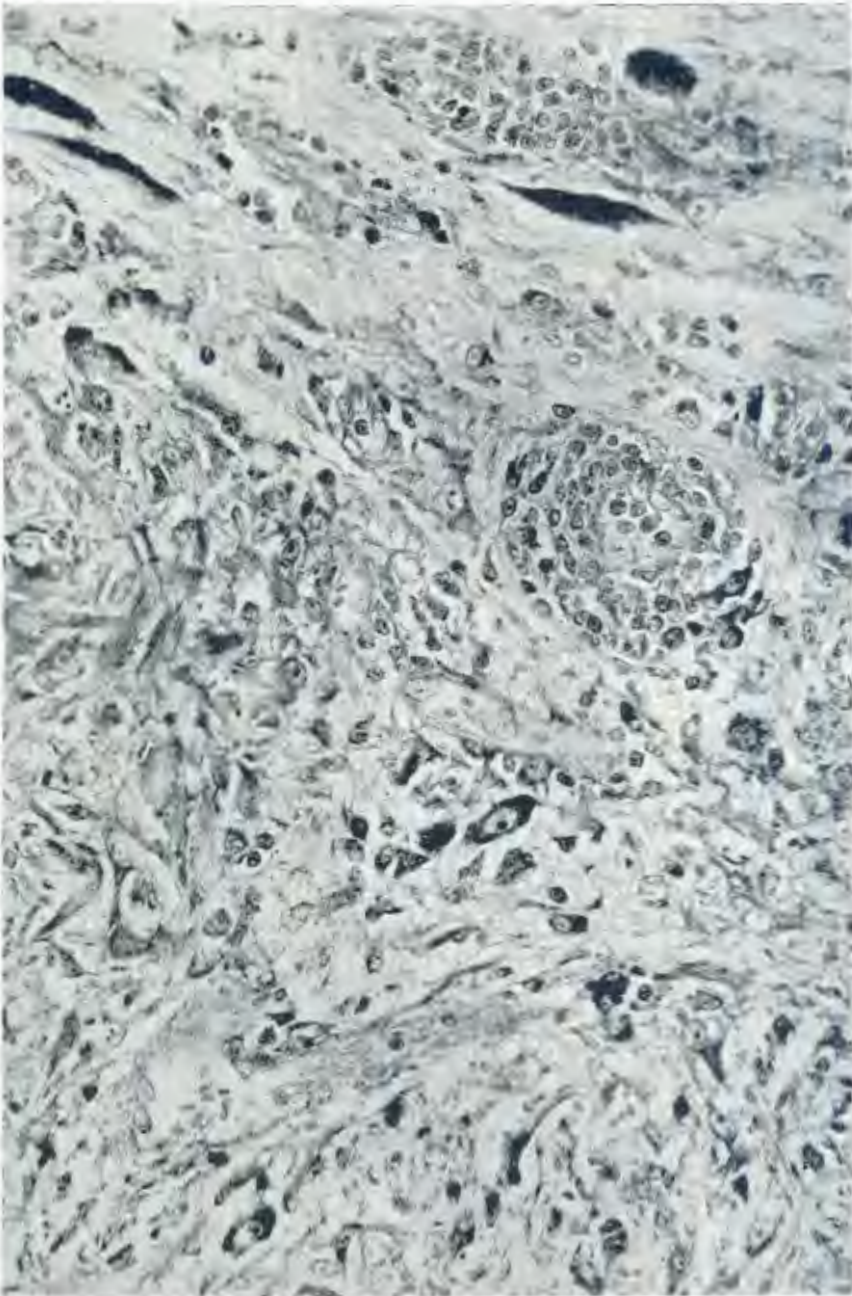


FIG. 34.—Incorporation of nerve cells into a glioma (central cerebellar tumour). The margin of the tumour is seen to left of centre and below. Nerve cells of the surrounding brain tissue (above, with deeply stained Nissl substance and often much compressed across the direction of tumour growth) are seen becoming incorporated into the tumour tissue (centre) and even persisting well within the tumour (below). (Giemsa.) X 510. (35536.)

of multiple gliomatosis (figs. 36 and 37). It could be demonstrated in 85% of the present series of cases. It was doubtless present in Belmonte's (*loc. cit.*) case, but he misinterpreted the nature of changes observed by him in the cerebrum in his case of glioma affecting the cerebellum and medulla. (The infiltrating round cells were mistaken for reactive microglia.)

Histopathology of this Encephalitis.

A description of the histopathology of these disseminated foci must recapitulate in every detail the changes already described in the marginal zone around gliomas (see fig. 38). Again the changes could be classed as intravascular, vascular, and perivascular. There are leucocytic stasis, emigration, and proliferation, the cell types involved being the same as already described: hypertrophy and hyperplasia of the endothelium of the affected vessels; multiplication of capillaries; sclerosis of the vessel walls; and hypertrophy and hyperplasia of perivascular astrocytes with changes in the direction of astroblasts. The same pigment is found in these lesions as in glioma (fig. 82).



FIG. 35.—Nerve cells surviving deep within a glioma, in the walls of and actually in the lumen of a central cystic cavity. (Giemsa.) X 210. (36590.)

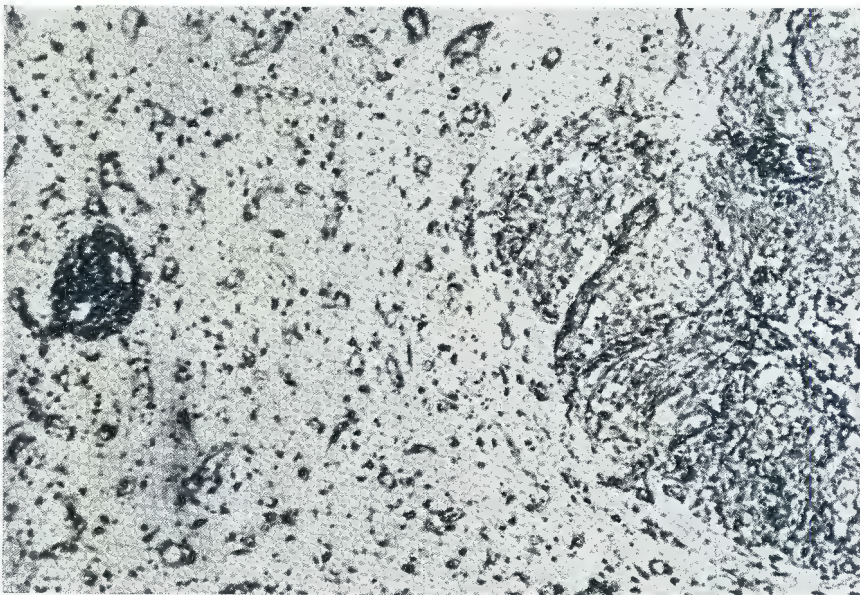
In pure cases of this encephalitis of fowls (i.e. without the co-existence of glioma) the astrocytic mobilisation remains within certain limits and the haematogenous proliferating cells predominate over it (fig. 39). But in the cases of multiple gliomas with co-existing encephalitis, *all possible gradations exist between encephalitic foci and young gliomas*. See figs. 40, 41 and 42.

This enables one to study the histogenesis and pathogenesis of avian glioma in the greatest detail. Fig. 40 shows a lesion which is nothing but a focus of encephalitis in which astrocyte hypertrophy and hyperplasia (together with the phenomenon of transformation of these astrocytes in the direction of astroblasts) have started to predominate over the haematogenous cellular infiltration. The question whether this focus is already a glioma is idle and meaningless. But the lesions shown in figs. 41 and 42 would undoubtedly have to be assessed as small gliomas and are presumably the earliest brain tumours that anyone has had the fortune to observe in any species.

GLIOMAS OF THE DOMESTIC FOWL.



FIG. 36.



FIGS. 36 AND 37.—Two examples of the frequent occurrence of disseminated foci of perivascular encephalitis concomitantly with glioma. In both cases a glioma (right) and a focus of perivascular encephalitis (left) independent of the changes in the immediate marginal zone around the tumour. (Giemsa.) X 100. (35047 and 34784.)

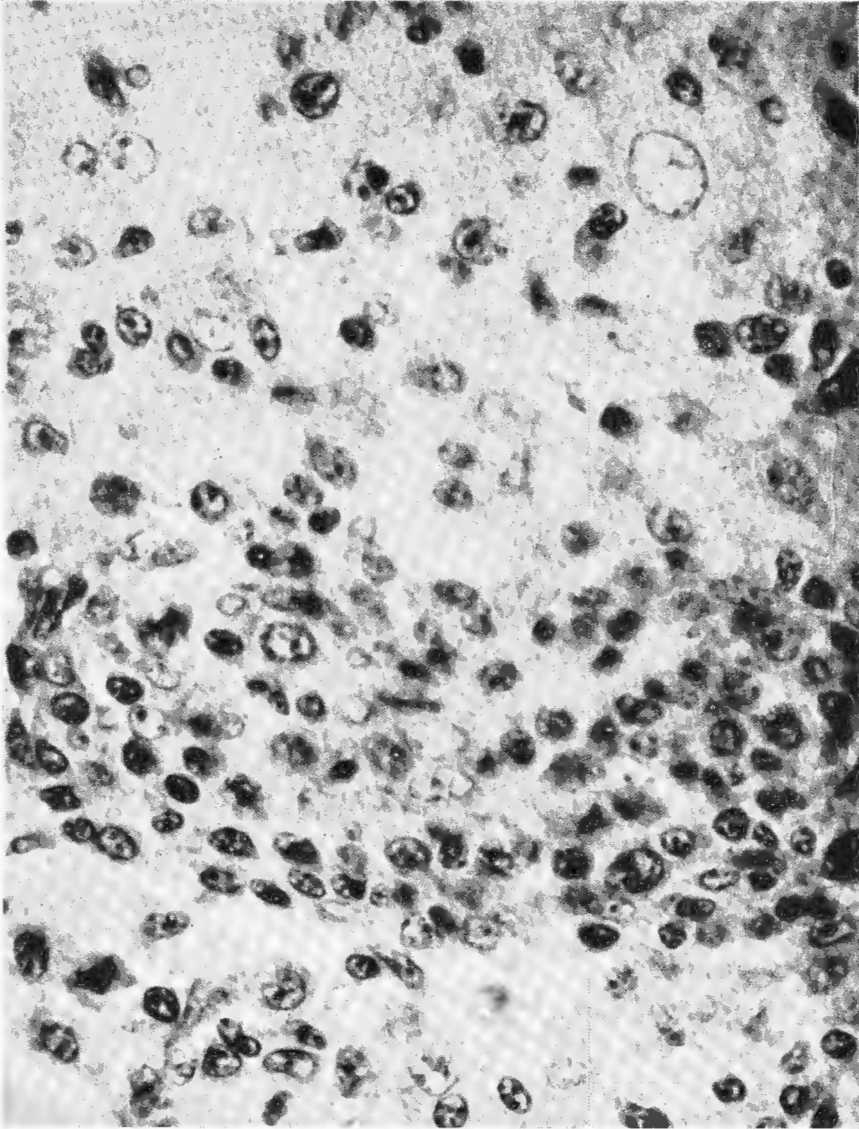


FIG. 38.—Details of the cytolgy of disseminated perivascular encephalitis of rather severe degree. Just below the centre, running horizontally, is seen the greatly hyperplastic endothelium of the affected vessel. The lumen is crowded with haematogenous agranulocytic cells which are everywhere migrating into the surrounding brain substance, and among which infiltrating lymphocytes, plasma cells, and monocytes can be distinguished. Mitoses are seen among these cells. Above, reactive changes in the surrounding astrocytes (very large vesicular nuclei) which show hypertrophy and hyperplasia of limited degree. (H.E.) X 1500. (34605.)

GLIOMAS OF THE DOMESTIC FOWL.

So, in the case of the fowl at least, are gliomas born—from inflammatory foci which so gradually take on the characters of neoplasia that it is futile to debate exactly at what point the lesion has “crossed the borderline” between chronic hyperplastic inflammation and neoplasia. No borderline indeed exists!

Similarly the marginal changes around well-developed gliomas are nothing but such perivascular foci of encephalitis in process of transformation to tumour tissue.

Thus avian glioma arises as a focus of perivascular encephalitis in which astrocytic changes come to preponderate over infiltrative changes and the tumour continues to grow by conversion of marginal encephalitic foci into tumour tissue.

The characteristic lobulation of the larger tumours depends upon the confluence, as they transform into tumour tissue, of encephalitic foci whose original distribution was relatively concentrated (fig. 43). The hypertrophied and infiltrated bloodvessels of the marginal zone of each young tumour later form a prominent stroma between the lobules of the large tumour mass resulting from the fusion (fig. 44). Multiple (separate) tumours are due to more widespread dissemination of the original encephalitic lesions.

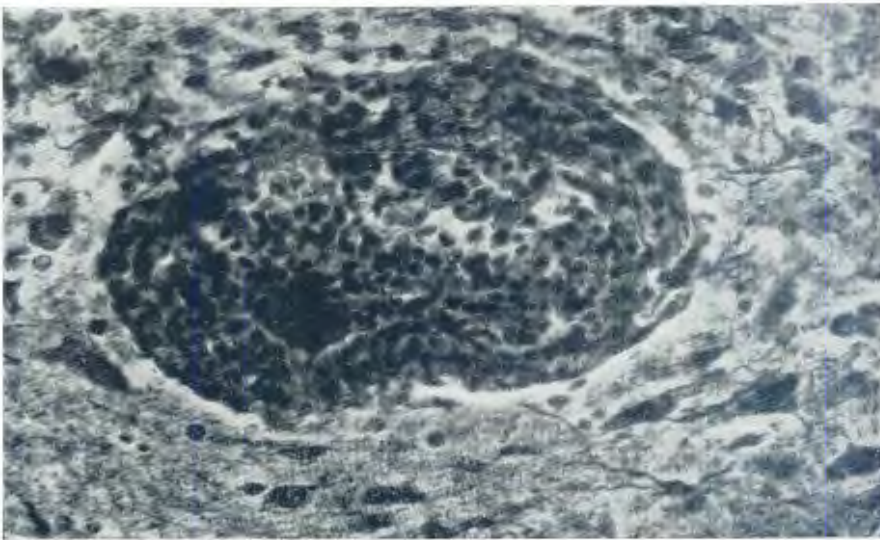


FIG. 39.—Focus of perivascular encephalitis. Although reactive changes in the astrocytes are visible, it is the infiltration of haematogenous cells which predominates in this lesion. (Hortega IV.) X 550. (35669.)

The multiplicity of gliomas in the fowl is primary, each tumour arising as an independent focus of encephalitis, as shown clearly in fig. 45. Thus I disagree with Belmonte's (loc. cit.) interpretation—also accepted by Joest (1937)—of the metastatic nature of the multiple small tumours found in addition to the large tumours in his case. The interpretation should rather have been that suggested for spongioblastoma multiforme of man by Globus and Strauss (1925), who observed in six

of their cases "multiple separate centres of growth at distinct points", not regarded as metastases but as multiple primary centres from the same cause or causes (fig. 45).

Encroachment of gliomas into ventricles is due to prior location of pre-gliomatous encephalitic foci in or near the ventricular wall (fig. 46). As is seen, there may be encroachment on the ventricular lumen by lesions still in the inflammatory stage.

FIGS. 40-42.—Stages in the genesis of glioma (compare Fig. 39).

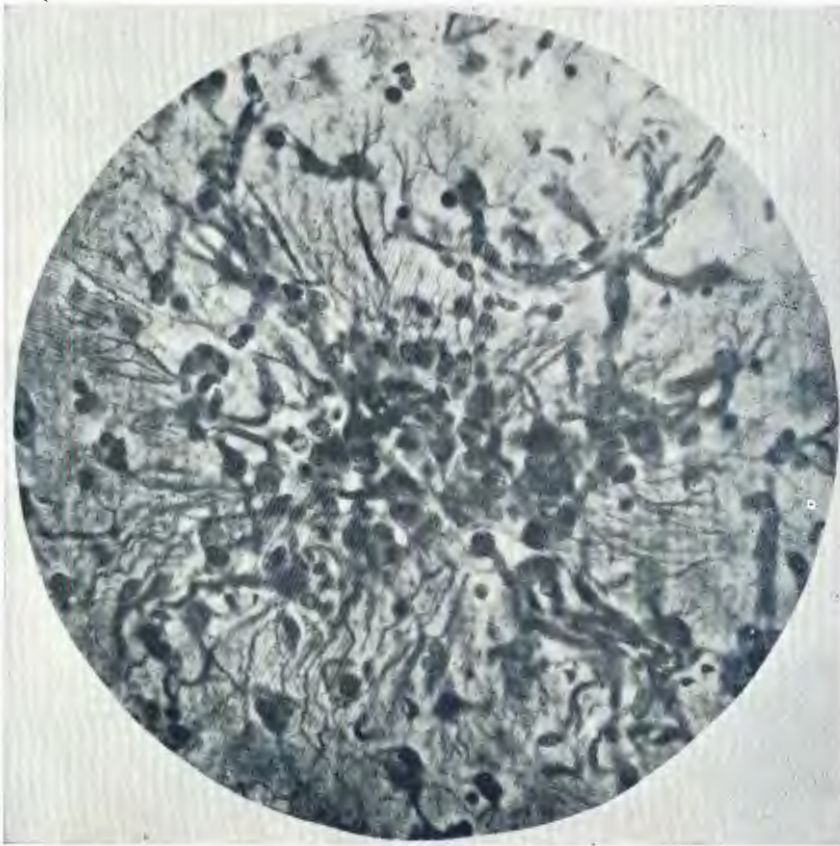


FIG. 40.—Focus of perivascular encephalitis in which astrocyte hypertrophy and hyperplasia are starting to predominate over the haematogenous cellulation—i.e. this focus is transforming to a minute glioma. (Hortega IV.) X 600. (35539.)

In fowl brains affected by gliomatosis and disseminated focal encephalitis, it is often possible by means of Hortega's IVth variant to demonstrate argyrophil plaques of the acellular type, similar to those illustrated in the human cerebellum by McMenemy (1940) in one of his cases of Alzheimer's disease. However, they show no particular relationship to either type of lesion, being scattered haphazardly both near to and remote from other lesions (fig. 47).

2. ENCEPHALITIS INDEPENDENTLY OF GLIOMA.

(a) *Non-Purulent Encephalitis (and Meningo-encephalitis).*

In some cases the above described disseminated perivascular encephalitis exists without progression of the encephalitic foci to glioma formation. In other words, in these individuals the infiltrative changes continue to preponderate over reactive glia changes. Macroscopically there is diffuse enlargement and orange to yellow discoloration of the affected divisions of the brain. Various grades of severity exist (figs. 48 and 49).



FIG. 41.—Later stage in the genesis of glioma. Still greater predominance of the astrocytic cells over the haematogenous elements. This focus is considered beyond all doubt to be actually a glioma although still of microscopic dimensions. Already it is growing by conversion of marginal astrocytes (best seen left and above). (Hortega IV.) X 350. (35539.)

In some cases the leptomeninges are simultaneously affected (leptomeningo-encephalitis—fig. 50) and a few cases have been encountered of lesions confined to the leptomeninges (disseminated focal non-purulent leptomeningitis). In all cases where the meninges are affected, the lesions (as in encephalitis) are primarily perivascular in distribution. The changes are the same as in the brain tissue, except of course that no astrocytes are present.

(b) *Purulent Encephalitis.*

In a few cases, pseudo-eosinophil leucocytes (which in glioma and non-purulent encephalitis are either absent or play but an insignificant part in the infiltration) are prominent in the cellular infiltrate (fig. 51). There is marked intravascular stasis of these elements and emigration through the vessel walls, and this is associated with a certain degree of brain softening. In such severer forms of encephalitis there is still more intense participation of plasma cells and monocytes together with macrophages and even giant cells derived from the

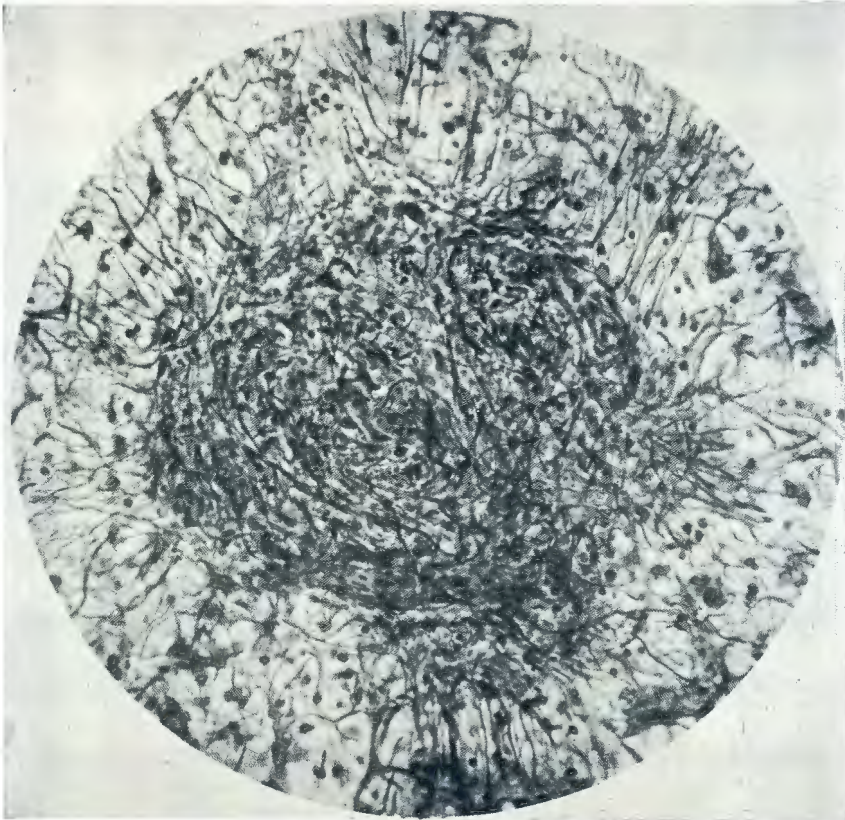


FIG. 42.—Still later stage in the development of a young glioma. A small tumour of coherent astrocyte derivatives has been formed around a bloodvessel. The haematogenous infiltrating elements have now become relatively insignificant. Growth by conversion is seen in progress at all parts of the margin. (Hortega IV.) X 400. (35539.)

latter. Even the plasma cells can multiply quite freely by mitosis. All gradations exist between this purulent encephalitis and the non-purulent encephalitis previously described (fig. 49). Both types of lesions may co-exist in the same brain. Progressive changes in astrocytic glia are as described, and may be pronounced, although no coherent tumour tissue is formed from the latter.

(c) Cerebral Abscess.

All gradations exist between disseminated foci of purulent encephalitis and frank cerebral abscess (not of bacterial origin). This latter condition is rare in fowls. It may be single or multiple. In one case (36684), cerebral abscess in one cerebral hemisphere was accompanied by disseminated non-purulent encephalitis in the same and also in the other hemisphere (fig. 52). In frank cerebral abscess (fig. 53 and 54) the pus formation and softening are still more extensive than in purulent encephalitis, forming the centre of the abscess. This is surrounded by a "wall" formed by cellular infiltrative changes, where again pseudo-eosinophils predominate over lymphocytes, and plasma cells and monocytes are again prominent. The latter very markedly tend to form macrophages and giant cells. There is also reactive proliferation of astrocytes. Immediately outside the abscess "wall" the brain tissue shows the lesions of perivascular encephalitis.

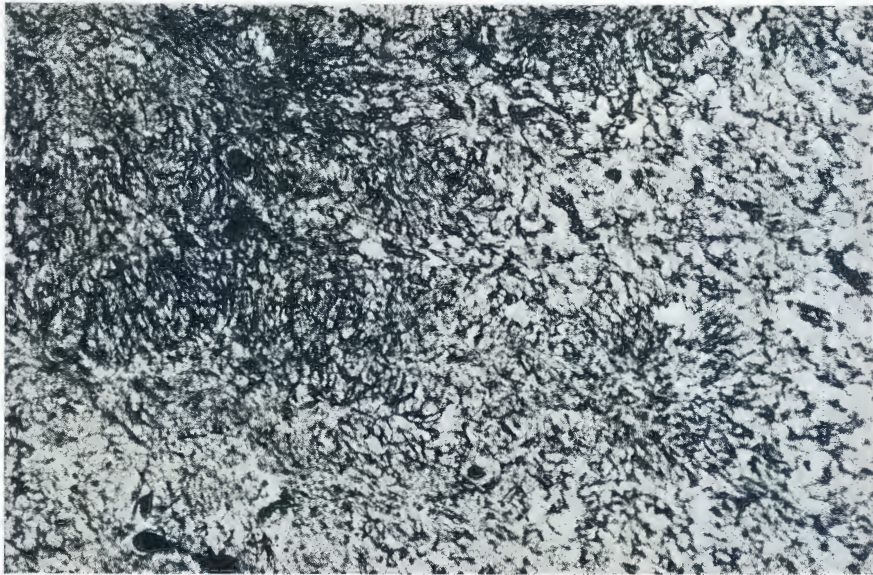


FIG. 43.—Multicentric origin of a lobulated glioma: Confluence of multiple perivascular centres of encephalitis in which astrocytic proliferation predominates. The result will be a lobulated glioma. (Cajal's gold sublimate—prolonged impregnation.) X 100. (35538.)

Remarks.

The occurrence of the gradations referred to between these different lesions and their occurrence in some cases in the same individual, leads to the conclusion that these forms of encephalitis represent merely a single pathological entity in different degrees of severity. All these lesions are associated with the same pigmentation as has been described in gliomas, and this pigment is present in larger quantity the more severe the encephalitis. In all cases, macroscopically the affected brain tissue shows a similar orange to yellow discoloration.

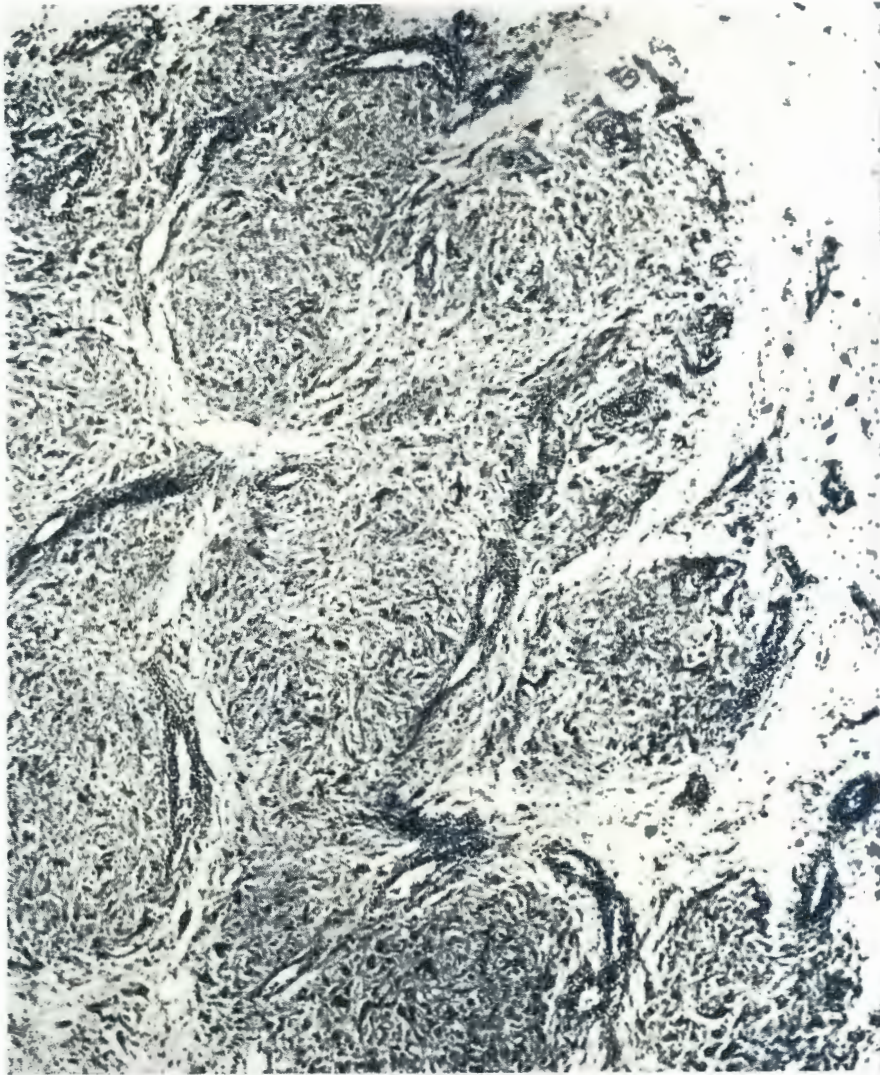


FIG. 44.—A lobulated glioma, which is still growing by the addition of new lobules. Tumour tissue, transforming from marginal perivascular encephalitic foci (below, right), becoming confluent with the main mass, which is built up of lobules having arisen previously in the same manner. The infiltrated and hypertrophied vessels of the reaction zone around the separate tumour centres (right) come to form the stroma between the lobules seen in the main mass (centre and above). (Giemsa.) X 125. (34987.)

3. *Diffuse Encephalitis (Gliosis).*

This condition, at least in its typical form, has been encountered once only.

Case Report (32375).

The subject was a White Leghorn chick 20 days old. "For five days this chick had not grown and had been nervous and backed about the battery. There was a persistent fine muscular tremor. Killed. Whole cerebellum a dark orange colour. Optic lobes normal. Both cerebral hemispheres have a slight orange colour." Gliomatosis was suspected.

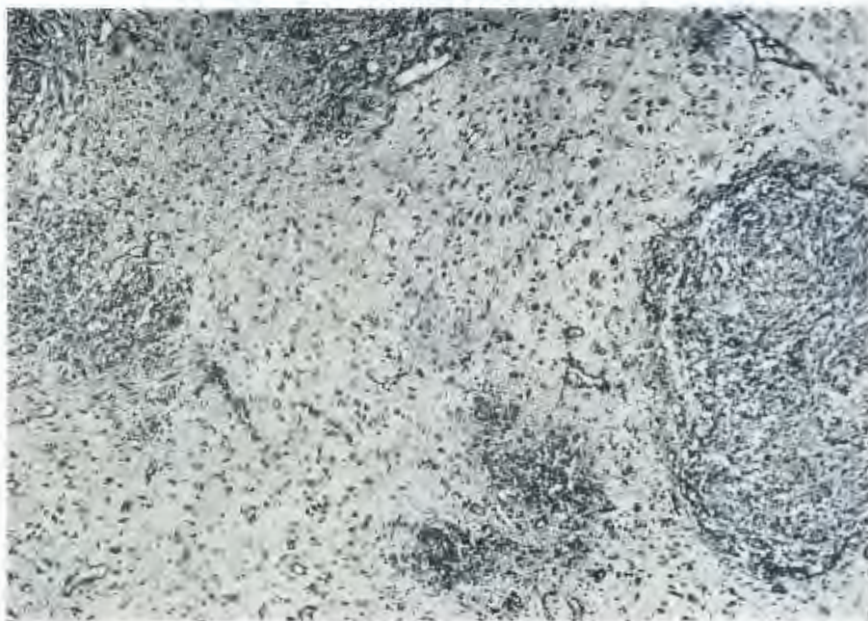


FIG. 45.—Primary multiplicity of avian gliomatosis. The tumours arise as multiple disseminated foci of encephalitis. Transitional stages (left) are seen between encephalitic foci (above and below) and definitive glioma (right). (Giemsa.) X 100. (34784.)

Microscopically the changes in the cerebellum are spectacular (fig. 55). While the general pattern of the organ (foliae, sulci, size and shape) is quite unaltered, so that the section is readily recognisable on naked eye examination, paradoxically it is virtually unrecognisable as cerebellum under the microscope. Two pathologists on whom the test was made failed to recognise the organ under the microscope, and one of them was not even able to suspect what it was. The finer architecture is more or less entirely obliterated by a most striking diffuse proliferation of astrocytic neuroglia cells. The molecular layer for the most part no longer looks molecular on account of this great cellularity. The Purkinje cells have been almost entirely obliterated, it is possible to find a highly degenerate one here and there on searching. The outer part of the granular layer, shows more or less complete replacement of its normal elements by glia cells, in the inner part groups of granule cells remain, but between them are no eosin

bodies but only glia cells. The white substance is reduced to a fraction of its normal thickness and those fibres which remain show evidence of degeneration. The pial septa show "round cell" infiltration (lymphocytes, plasma cells, and monocytes).

In the cerebrum one also sees neurone degeneration and excess of glia cells and slight perivascular round cell infiltration, but here the changes are less striking. Pigment can be demonstrated in the lesions, although in much smaller quantity than might have been expected considering the pronounced coloration recorded macroscopically. This might in part be due to its very diffuse distribution in small particles seen both in association with the proliferating glia cells and the infiltrating cells.

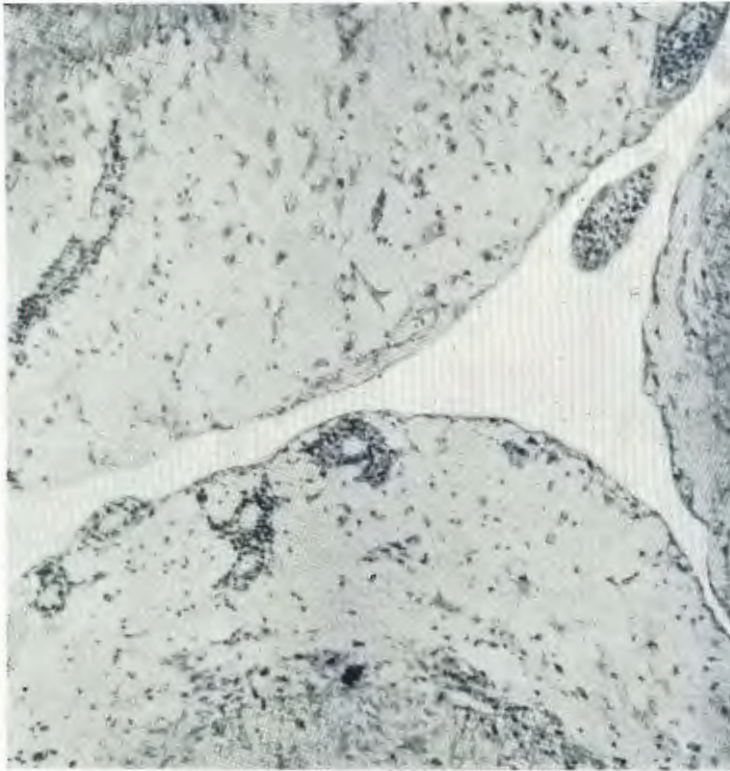


FIG. 46.—Encephalitic foci in ventricular wall, one (left) commencing to bulge into the cavity and another (right) hanging into it. When such foci transform into gliomas, the latter will of course encroach on or even occlude the ventricular lumen (cf. Figs. 16 and 17). (Giemsa.) (43636.)

Diagnosis.

Diffuse interstitial encephalitis (gliosis) especially of the cerebellum.

Discussion.

This condition also is thought possibly to be related aetiologically to glioma and disseminated encephalitis. The reasons cannot be given fully here. In common with the lesions discussed this lesion shows the characteristic orange



FIG. 47.—Argyrophil plaques in the molecular layer of the cerebellum. There was a central glioma in this cerebellum and multiple foci of perivascular encephalitis (some of which are seen in this field) occurred in the foliae. The acellular plaques are seen to be haphazard in distribution, not particularly associated with the cellular encephalitic foci nor even essentially distributed in relationship to the bloodvessels. (The granular layer of the foliae is seen at the right and left margins and the vascular pial septum between two adjacent foliae runs vertically in the centre.) (Hortega IV.) X 150. (35536.)

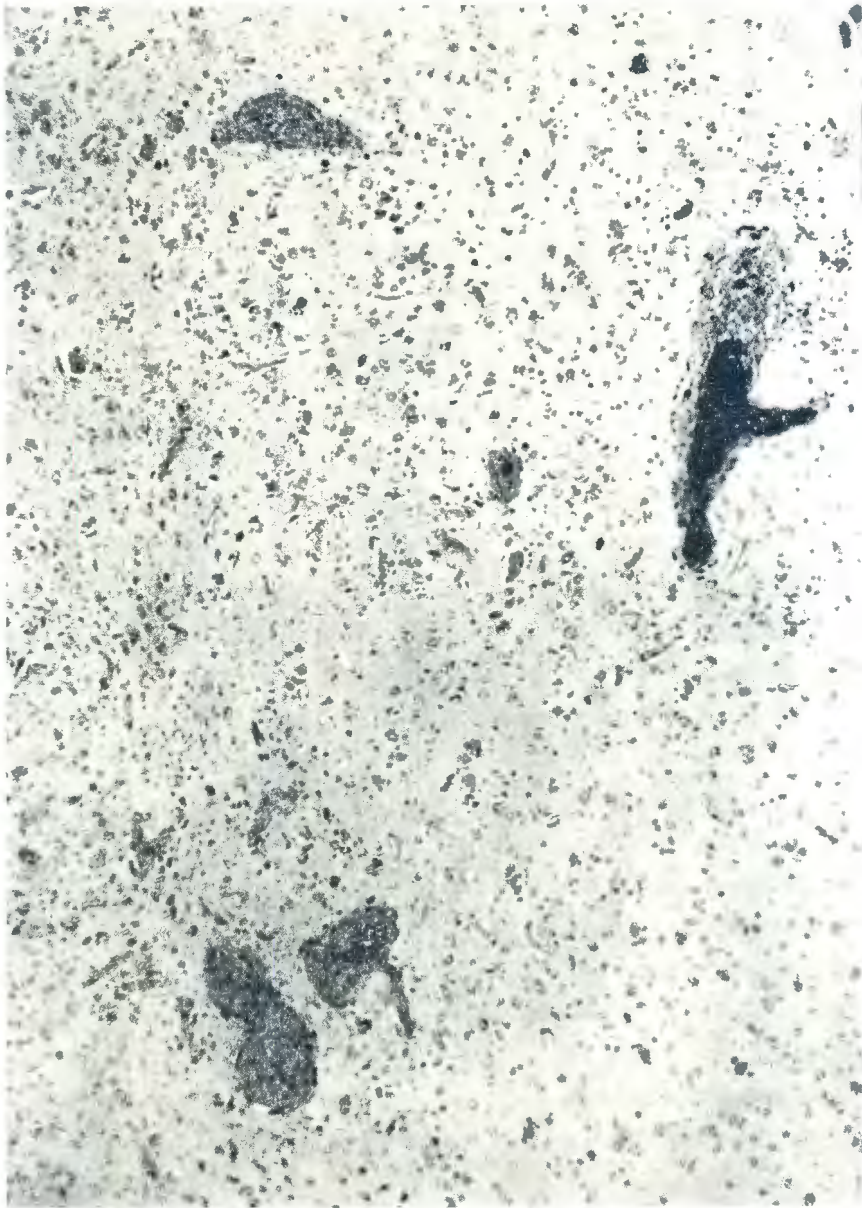


FIG. 48.— Multiple disseminated focal perivascular encephalitis (without glioma formation).
X 120. (35669.)