

## **A Further Case of Congenital Porphyrinuria (Pink Tooth) in a Living Grade Friesland Cow in South Africa. (Cedara Case).**

---

By P. J. J. FOURIE, Section of Hygiene, and C. R. RIMINGTON,  
Section of Toxicological Chemistry, Onderstepoort.

---

DETAILS concerning the occurrence, symptomatology, pathology and haematology of the first and only known living world cases of congenital porphyrinuria in bovines, were recorded by Fourie (1936).

These cases were discussed by Rimington (1936) independently from the chemical point of view. These cases all occurred in a grade short horn herd soon after the introduction of a certain bull as sire. Fairly extensive enquiries were at that time made but no definite evidence was obtained as to the presence of other clinical cases in South Africa. However, one of our Colleagues, Dr. I. P. Marais, whilst examining the cattle of the Cedara School of Agriculture, Natal, for mastitis, found one cow, showing extensive skin lesions and having at the same time discoloured teeth. The urine was not available for examination, but otherwise the clinical picture was that of congenital porphyrinuria. This cow was taken over by the Division of Veterinary Services and is the subject of this communication. She will for the sake of convenience be referred to as the Cedara case.


*History.*—She is a Grade Friesland cow (177, C. Ria 4th, Onderstepoort No. 7354) born at Cedara 20.12.1930. Her dam and granddam (the latter being in 1937 more or less 17 years old, born 25.8.1920) are both alive. Her sire C. Joe is dead. As a calf she had three sores on her body. As far as can be made out these never healed. She was a shy breeder. Her first date of service was 24.3.33. Her first pregnancy resulted in an abortion on the 18th March 1936. Subsequently she was repeatedly served, but eventually held to a service, as a result of which she produced, here at Onderstepoort, a beautiful, normal, high grade Friesland, heifer calf on the 18.5.1937. (Figs. 1 and 2).

Figure 1.



Cedara Case: Cow 7354 with her calf No. 7393.

Figure 2.



Cedara case: early skin lesions between black spots towards the top of the back. Lesions do not show up too well in photograph.

This is the first living calf known to have been delivered by a bovine affected with congenital porphyrinuria.

*Ancestry.*—The hereditary nature of porphyrinuria will not be discussed in this paper. The evidence that the condition is hereditarily transmitted as a recessive character will be presented by one of us at a later date. It will nevertheless be of interest to submit here relevant portions of the ancestry of this Cedara case.

*Ancestry of the Cedara case: Cow 177, Cedara Ria 4th.*

*Angel:*

Ria 136 (*granddam of Cedara case*) by *Elsenburg Rhonda 985*

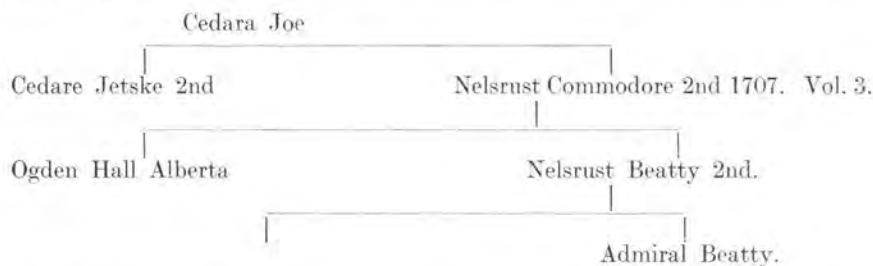
V. 3. F. H. B.

113 *Cedara Ria 2nd (dam of Cedara case)* by *Frederick*

177 *Cedara Ria 4th (Cedara case)* by *Cedara Joe.*

The cow Angel is of the Friesland type, but she was not registered and nothing is known of her ancestry. She was however a poor doer. At the time this was thought to have been due to liver fluke infestation, but Mr. Johnston, Animal Husbandry Officer of the Stellenbosch-Elsenburg College of Agriculture, who kindly gave us the above details, makes the statement that, "it would appear to be possible that if the cow was destroyed as a bad doer, a rare condition such as porphyrinuria may have been overlooked and the entire trouble attributed to the liver fluke." This of course implies that the cow Angel may have been a clinically affected case, whereas she may equally well have been a carrier of the recessive character (Dr.), in which case she would have been to all intents and purposes a clinically normal animal.

Turning now to the bull Cedara Joe, the sire of the Cedara case, this bull is, as far as is known clinically normal, and must therefore have been a carrier of the recessive character (Dr.). The pedigree of C. Joe is:



From this it will be seen that C. Joe is descended from the once famous South African Bull Admiral Beatty, which in turn is descended from the more famous sire Jan 3265 F. R. S. of Holland.

Enquiries were made, but no evidence suggestive of any cases of porphyrinuria in the ancestry of the bull C. Joe could be found

However, one should in this connection bear in mind that the chance of recognising even a suspicious case of porphyrinuria in bygone generations is extremely small.

CLINICAL FEATURES.

*General.*—The respirations are 36 per minute, the pulse 66 per minute and there are 11 ruminal movements in 5 minutes. Her temperament is docile.

*Teeth.*—The teeth are reddish brown in colour but definitely not as deeply pigmented as in the shorthorn cases described by Fourie (1936).

*Urine.*—The urine is of reddish brown colour, having absorption bands at 540·6, 577·6, 497·7, 621·6. On an analysis the urine was found to contain 0·8 mg. of coproporphyrin and 1·4 mg. uroporphyrin per 100 c.c. Porphyrins were also identified in the faeces.

Figure 3.




Cedara case: Old skin lesions on the back.

*Conjunctiva.*—This is markedly reddened and of a bright pink colour, but there is no noticeable discharge from the eyes. When the animal was stabled to protect her against the harmful rays of the sun the reddening of the conjunctiva gradually diminished, until some time after stabling, the conjunctiva became completely normal in colour again.

*Lesions of photosensitization.*—Lesions are present on portions of the unpigmented skin exposed to the direct rays of the sun. The lesions extend along the back, from the withers to the commencement of the tail. See Figs. 3 and 4.

Except for small portions here and there, the lesions are continuous in the skin over the spinous processes. One large lesion extends obliquely from in front and mesial to the external angle of the ilium to about 10 cm. from the tuber ischii. Lesions extend on either side from the top of the back to a distance of 15 cm. down between the last two ribs. These lesions consist of hard, keratinised crusts with horny, fingerlike outgrowths in places. These are old lesions, probably of some years standing, but in some portions of unpigmented skin, young lesions are present. These are in the form of raised wheals, confined to unpigmented parts of the skin, which shows acute reddening, but the black spots on the skin, contiguous to altered unpigmented skin, are completely normal. No lesions are present on the nose or the muzzle.

Figure 4.



Cedara case: Old skin lesions on the back.

#### HAEMATOTOLOGY.

A haematological examination of this animal was made on three occasions. Details are given below.

Date.	R.C.	W.C.	B.P.	L.	N.	M.	E.	B.
24/ 2/37.....	5.3	8.8	—	53	25	4	17	1
20/10/37.....	4.2	6.5	—	54	18	8	19	1
30/11/37.....	4.1	8.2	—	38	40	7	15	0

The red counts are somewhat on the low side, but no well marked morphological changes indicative of anaemia are present. Only occasionally does one see cells showing punctate basophilia.

The eosinophiles are undoubtedly increased in number. In this case bilharzia infection is absent, but unfortunately a liver fluke infestation is present and this may not only be responsible for the low red counts, but also for the eosinophilia. However, haematological observations are being continued in order to see if there is any response to medicinal treatment against liver fluke.

Since writing this article, the cow had an accident as a result of which she sustained a fracture of the external angle of the ilium. The open wound refused to heal and the loose piece of bone was removed and found on analysis (kindly undertaken by Mr. Roets) to contain: Uroporphyrin, the first crop of crystalline methyl ester of which has a melting point of 276°-280°. The spectrum in chloroform shows bands at 626·8, 583·0, 571·5, 537·3, 502·7. For comparison the bands of the uroporphyrin ester are quoted, viz. 626·1, 581·4, 570·5, 537·3, 500·8.

#### SUMMARY.

A further living case of congenital porphyrinuria is described of a cow which gave birth to a clinically normal heifer calf and showing herself discoloured teeth, porphyrin in urine and faeces, and extensive skin lesions of photosensitization.

#### LITERATURE.

- FOURIE, P. J. J. (1936). The occurrence of congenital Porphyrinuria (Pink Tooth) in cattle in South Africa. (Swaziland). *Onderstepoort Jnl. of Vet. Sci. and An. Ind.*, Vol. 7, No. 2, pp. 535-565.
- RIMINGTON, C. (1936). Some cases of congenital porphyrinuria in cattle. Chemical studies upon the living animals and post mortem material. *Onderstepoort Jnl. of Vet. Sci. and An. Ind.*, Vol. 7, No. 2, pp. 567-609.