



UNIVERSITEIT VAN PRETORIA  
UNIVERSITY OF PRETORIA  
YUNIBESITHI YA PRETORIA

**The anatomy and clinical implications of the obturator  
nerve and its branches**

by

**Zithulele Nkosinathi Tshabalala**

Dissertation submitted in full fulfilment of the requirements for the degree

**Master of Science in Anatomy**

In the Faculty of Health Science

University of Pretoria

Supervisor: Dr A-N van Schoor

Co-supervisor: Mrs R Human-Baron

Co-supervisor: Mrs S van der Walt

2015

## DECLARATION OF ORIGINALITY

### UNIVERSITY OF PRETORIA

The Department of Anatomy places great emphasis upon integrity and ethical conduct in the preparation of all written work submitted for academic evaluation.

While academic staff teach you about referencing techniques and how to avoid plagiarism, you too have a responsibility in this regard. If you are at any stage uncertain as to what is required, you should speak to your lecturer before any written work is submitted.

You are guilty of plagiarism if you copy something from another author's work (e.g. a book, an article or a website) without acknowledging the source and pass it off as your own. In effect you are stealing something that belongs to someone else. This is not only the case when you copy work word-for-word (verbatim), but also when you submit someone else's work in a slightly altered form (paraphrase) or use a line of argument without acknowledging it. You are not allowed to use work previously produced by another student. You are also not allowed to let anybody copy your work with the intention of passing it off as his/her work.

Students who commit plagiarism will not be given any credit for plagiarised work. The matter may also be referred to the Disciplinary Committee (Students) for a ruling. Plagiarism is regarded as a serious contravention of the University's rules and can lead to expulsion from the University.

The declaration which follows must accompany all written work submitted while you are a student of the Department of Anatomy. No written work will be accepted unless the declaration has been completed and attached.

Full names of student: Zithulele Nkosinathi Tshabalala

Student number: 27356010

Topic of work: The anatomy and clinical implications of the obturator nerve and its branches

## Declaration

1. I understand what plagiarism is and am aware of the University's policy in this regard.
2. I declare that this dissertation (e.g. essay, report, project, assignment, dissertation, thesis, etc.) is my own original work. Where other people's work has been used (either from a printed source, Internet or any other source), this has been properly acknowledged and referenced in accordance with departmental requirements.
3. I have not used work previously produced by another student or any other person to hand in as my own.
4. I have not allowed, and will not allow, anyone to copy my work with the intention of passing it off as his or her own work.

---

**Zithulele Nkosinathi Tshabalala**

## Acknowledgements

In the name of the Father, of the Son and of the Holy Spirit.

Firstly, I would like to thank my mother for bringing me this far. The love of a mother is one that no instrument can measure. My Ma, you are my Peter and from this rock I have gained all my strength. You deserve it all. Mama, lerato la hao le tswa lehodimong. Morena a o hlonolofatse. The Lord was showing off when he made you. My sisters, Minky and Thulisa, thank you for the love, support and understanding; especially when coming home was only a dream. Your encouragement held me together through this process. I love you all, Thank you.

To the rest of my family, especially Anjeng (My Ouma), Paulina and Malome Morena, thank you for the help in raising me to be the man I am today. Ke motho ka lebaka la lona. From my undergraduate studies to this very day, I could fall in you for support. Ke Leboha Ho Se Menahano.

Ncuthukazi, this has been quite a journey. You became more than a girlfriend; you were my friend, assistant, boss, my biggest fan and a kick in the butt when I needed it. No amount of words can express my gratitude for always having my back.

I would like to thank my supervisors and the staff of the Department of Anatomy and the Department of Statistics of the University of Pretoria for all their help and support.

Lastly, I would like to thank the Research Development Programme (RDP) of the University of Pretoria and the National Research Foundation – Competitive Support for Unrated Researchers (NRF-CSUR) Grant for their financial assistance. Any opinion, finding and conclusion or recommendation expressed in this material is that of the author(s), the RDP and NRF-CSUR do not accept any liability in this regard.

Tshabalala. Mshengu. Ludonga lika Mavuso. Sdwaba siluthuli. Sithi singabancwaba seza nomlandakazi. Wawawa owahlaba inkmo ngameva. Nina benkonkoni enhle ya semavaneni.

Amen

## Table of contents

<b>Heading</b>	<b>Page number</b>
<b>List of figures</b>	I
<b>List of tables</b>	III
<b>List of abbreviations</b>	IV
<b>Abstract</b>	V
<b>Executive summary</b>	VI
<b>Chapter 1 – Introduction</b>	1
<b>Chapter 2 – Literature review</b>	2
<b>2.1. Obturator nerve anatomy</b>	2
2.1.1. Anterior branch	4
2.1.2. Posterior branch	4
2.1.3. Accessory obturator nerve	5
2.1.4. Injury to the obturator nerve	5
<b>2.2. Clinical procedures</b>	6
2.2.1. Obturator nerve block	6
2.2.1.1. Traditional approach	6
2.2.1.2. Interadductor approach	7
2.2.2. Pelvic lymphadenectomy	7
2.2.3. Transobturator procedures	8

2.2.3.1. Tension-free Vaginal Tape-Obturator inside-out technique (TVT-O)	8
2.2.3.2. Transobturator Tape outside-in technique (TOT females)	10
2.2.3.3. Transobturator Tape inside-out technique (TOT males)	11
2.2.3.4. Transobturator Tape outside-in technique (TOT males)	12
2.2.3.5. Previous study on SUI treatment procedures	13
<b>2.3. Aim</b>	<b>14</b>
2.3.1. Research objectives	14
<b>Chapter 3 – Materials and methods</b>	<b>15</b>
<b>3.1. Phase 1: Abdomen dissection for obturator nerve description</b>	<b>15</b>
3.1.1. Exclusion criteria	15
3.1.2. Dissection procedure	15
3.1.3. Statistical analysis	18
<b>3.2. Phase 2 – Location of the obturator nerve in the obturator foramen</b>	<b>18</b>
3.2.1. Exclusion criteria	18
3.2.2. Dissection procedure	18
3.2.3. Statistical analysis	20
<b>3.3. Phase 3: Clinical applications of the results</b>	<b>20</b>
<b>Chapter 4 – Results</b>	<b>21</b>
<b>4.1. Origin and course of the obturator nerve and its branches</b>	<b>21</b>
4.1.1. Root values of the obturator nerve	21

4.1.2. Course through the abdomen	24
4.1.3. Bifurcation of the obturator nerve	25
4.1.4. Muscle innervation in the medial thigh	27
<b>4.2. Phase 2: Location of the obturator nerve within the obturator foramen</b>	<b>29</b>
<b>4.3. Phase 3: Clinical applications of the results</b>	<b>31</b>
<b>Chapter 5 – Discussion</b>	<b>32</b>
<b>5.1. Origin and course of the obturator nerve and its branches</b>	<b>32</b>
5.1.1. Root values of the obturator nerve	32
5.1.2. Nerve roots and the psoas major muscle	33
5.1.3. Obturator neurovascular bundle	34
5.1.4. Bifurcation (termination) of the obturator nerve	34
5.1.5. Anterior branch of the obturator nerve	35
5.1.6. Posterior branch of the obturator nerve	36
<b>5.2. Location of the obturator nerve within the obturator foramen</b>	<b>37</b>
<b>5.3. Clinical applications</b>	<b>38</b>
5.3.1. Obturator nerve block	38
5.3.2. Pelvic lymphadenectomy	40
5.3.3. Transobturator procedures	40
<b>Chapter 6 – Conclusion</b>	<b>42</b>
<b>6.1. Obturator nerve anatomy</b>	<b>42</b>

<b>6.2. Location of the obturator nerve within the obturator foramen</b>	<b>42</b>
<b>6.3. Clinical applications of the results</b>	<b>42</b>
<b>References</b>	<b>44</b>



## List of figures

Figure number	Page number
<b>Figure 1:</b> Root values of the obturator nerve lateral to the lumbar vertebra	2
<b>Figure 2:</b> Medial view of the lateral pelvic wall on the right side	3
<b>Figure 3:</b> View of the perineum of an unembalmed female cadaver placed in the lithotomy position. Incision made for the entry of the needles inferior to the urethral meatus and the exit incisions at the genitofemoral fold	9
<b>Figure 4:</b> View of the perineum of an unembalmed female cadaver placed in the lithotomy position. Incision made for the entry of the needles in the genitofemoral fold and the exit incision made inferior to the urethral meatus	10
<b>Figure 5:</b> View of the perineum of an unembalmed male cadaver placed in the lithotomy position. The scrotum is reflected superiorly to allow insertion of the needles through the obturator foramen from the inside	12
<b>Figure 6:</b> View of the perineum of an unembalmed male cadaver placed in the lithotomy position. The scrotum is reflected superiorly to allow insertion of the needles through the obturator foramen from the outside.	13
<b>Figure 7:</b> Pinning of the intervertebral discs on the left	16
<b>Figure 8:</b> Pinned intervertebral discs (green) and nerve rami of the obturator nerve (blue) and femoral nerve (pink)	17
<b>Figure 9:</b> Landmarks used to locate the obturator nerve within the obturator foramen. Each point is indicated by a similarly coloured letter (right) and circle (left).	19
<b>Figure 10:</b> Nerve roots of the nerves of the lumbar plexus from L2-L4, with an absent obturator nerve L2 contribution.	21

<b>Figure 11:</b> Obturator nerve root value frequencies on the roots in males and females on the left	22
<b>Figure 12:</b> Obturator nerve root value frequencies on the roots in males and females on the right	23
<b>Figure 13:</b> Combined obturator nerve root value frequencies in males and females	24
<b>Figure 14:</b> The low fusion of L3 to L4 obturator nerve (green) roots	25
<b>Figure 15:</b> Left obturator nerve bifurcation location frequencies	26
<b>Figure 16:</b> Right obturator nerve bifurcation location frequencies	26
<b>Figure 17:</b> Combined obturator nerve bifurcation location frequencies	27
<b>Figure 18:</b> View of the innervation patterns of the anterior branch of the obturator nerve (yellow) as it innervates the gracilis (green), adductor longus (orange) and adductor brevis (red). Obturator externus (OE) as it is innervated by the posterior branch (purple)	28
<b>Figure 19:</b> Medial view of the double innervation of the adductor brevis (green) muscle by the anterior (orange) and posterior (blue) branches of the obturator nerve.	29
<b>Figure 20:</b> Anterior branch of the obturator nerve (arrow) as it appears deep to the pectineus muscle, to descend between adductor longus and brevis muscles (left leg)	36

## List of tables

<b>Table number</b>	<b>Page number</b>
<b>Table 1:</b> Prevalence of the varied origins of the obturator nerve	33
<b>Table 2:</b> Prevalence of the accessory obturator nerve	33
<b>Table 3:</b> Comparison of bifurcation location frequencies	35

## List of abbreviations

<b>Abbreviation</b>	<b>Full title</b>
ANOVA	Two-way analysis of variance
GLM	Generalised Linear Models
L2/3/4/5	Lumbar vertebra 2/3/4/5 intervertebral disc/spinal nerve root
L2/3/4/5 vertebra	Lumbar vertebra 2/3/4/5
n	Sample size
p	Probability
SD	Standard Deviation
SUI	Stress Urinary Incontinence
T12	Twelfth thoracic spinal nerve root
TOT	Transobturator tape
TVT	Tension-free vaginal tape
TVT-O	Tension-free vaginal tape-obturator

## Abstract

The obturator nerve sends both motor and sensory fibres to the medial compartment of the thigh. This study aimed to provide a clear description of the anatomy and course of the obturator nerve and its branches to assist surgeons and clinicians in the safe performance of various pelvic procedures

One hundred and one (101) formalin-fixed cadavers 61 males and 40 females ( $68 \pm 17$  years), were dissected at the Department of Anatomy, University of Pretoria. Dissections were performed just lateral to the lumbar vertebra to describe the origin of the obturator nerve. The course of the nerve, with its relations, was observed and recorded until it terminated in the medial thigh. The location of the obturator nerve within the obturator foramen was quantified by measuring the distance from three (3) bony landmarks of the obturator foramen to the nerve; most superior, most medial and most inferior points. The results were used to determine their possible clinical applications.

Variations were observed in the root origins of the obturator nerve, its course in the abdomen, bifurcation patterns and the innervation patterns of its terminal branches. The obturator nerve (B) was found  $6.26 \pm 1.62$  mm from the most superior point (A),  $31.69 \pm 3.41$  mm from the most medial point (C) and  $47.33 \pm 3.94$  mm from most inferior point (D). The measurement from the obturator nerve to the most inferior point (B-D) is the one with a significant difference for sex ( $p = 0.26$ ).

The results may be used in the pre-operative preparation of pelvic lymphadenectomy, stress urinary incontinence (SUI) treatment and obturator nerve blocks. The study has assisted in expanding the knowledge on the anatomy of the obturator nerve and its branches in a South African context. These results should be verified in a clinical setting.

**Keywords:** pelvic cancer; pelvic surgery; pelvic lymphadenectomy; obturator nerve block; obturator nerve roots; obturator foramen, obturator nerve location, TOT, TVT-O; SUI

## Executive summary

Several surgical and clinical procedures are performed in the area of the medial compartment of the thigh. These are performed in attempts to achieve anaesthesia/analgesia or to repair and treat surrounding areas of the medial compartment. The procedures are either performed close to the nerves or directly along them. This places the obturator nerve and its branches in potential danger of injury. The literature reports several instances of obturator nerve damage during these procedures, which can often directly be associated with a lack of anatomical knowledge. The use of instruments calibrated for European or American populations could also account for nerve damage in a South African population as several studies have highlighted the anatomical differences between these populations. The location of anatomical structures may therefore be similar in concept, but their relationships to bony landmarks may be highly variable.

This study aimed to clearly describe the course of the obturator nerve and its branches from their origin at the lumbar vertebrae in the abdominal cavity, to the terminal branches in the medial compartment of the thigh. The location of the obturator nerve within the obturator foramen was also quantified using three (3) bony landmarks of the obturator foramen. The variations of these nerves were also investigated and accurately described.

One hundred and one (101) cadavers were dissected at the Department of Anatomy, School of Medicine, Faculty of Health Sciences, University of Pretoria. The sample comprised of 61 males and 40 females (68 ± 17 years). The study fell under the auspices of the National Health Act 61 of 2003. In the first phase of the study, the observed course and variations of the obturator nerve was recorded. The course was described from its origins at the lumbar vertebra in the abdominal cavity to where it enters the obturator canal, to terminate in the medial compartment of the thigh. The normal anatomy and variations of the branching and innervation patterns of the anterior and posterior branches of the obturator nerve were recorded after exiting the obturator canal and entering the medial compartment. To give a quantitative description of the location of the obturator nerve (B) within the obturator canal,

measurements were taken from the most superior (A), most medial (C) and most inferior (D) points of the obturator foramen.

Variations were found with regard to the origin of the spinal nerve roots. The second lumbar nerve root (L2) was absent in 20% (36/181), with the obturator nerve only originating from the third (L3) and fourth (L4) lumbar spinal nerves. There was significance found for the influence of sex on the origin of the nerve roots of the obturator nerve. For the location of the obturator nerve within the obturator foramen, the distance of A-B was  $6.26 \pm 1.62$  mm,  $31.69 \pm 3.41$  mm for the B-C distance and  $47.33 \pm 3.94$  mm for the B-D distance. A significant difference for sex was found only for the B-D measurement ( $p = 0.26$ ). The distance in the females was found to be  $44.99 \pm 3.55$  mm and the distance in males was  $48.85 \pm 3.42$  mm. The results have clinical applications in obturator nerve blocks, pelvic lymphadenectomy and stress urinary incontinence (SUI) procedures.

The results indicate that there is high variation in terms of the nerve root origins, bifurcation at the obturator foramen and the innervation patterns of the terminal branches. The description of the anatomy and variation of the obturator nerve and its branches in the medial compartment of the thigh will assist anaesthesiologists in performing nerve blocks for knee surgery, amongst others. The description of the course within the pelvis will assist surgeons in performing pelvic lymphadenectomy procedures safely, by avoiding damage to the nerve and surrounding vessels. The location of the obturator nerve within the obturator foramen may be used in gynaecologic and urologic surgery for the treatment of SUI. Using the measurements within the foramen will help avoid the obturator nerve. Using the most medial and most inferior points of the obturator foramen allows for safe performance of these SUI procedures.

The results may be used in a clinical setting to verify their practical usage, possibly allowing refining of procedural guidelines.

## Chapter 1 - Introduction

The obturator nerve and its branches are known to be variable in their branching patterns and innervation (Horwitz, 1939, Kirchmair *et al.*, 2008, Anagnostopoulou *et al.*, 2009, Arora *et al.*, 2014). An extensive review of the available literature indicates that, apart from general anatomical descriptions, few actual studies have been done to provide a detailed description of the exact position, course, branching pattern or possible anatomical variations of the obturator nerve. Furthermore, a thorough description of the position of the obturator nerve within the obturator foramen is lacking. This is especially true for the South African population.

Complications related to damage to the obturator nerve and its branches intra-operatively and post-operatively have previously been reported in the literature (Bradshaw *et al.*, 1997, Possover *et al.*, 1998, Loeb *et al.*, 2010, Ates and Tulandi, 2013, Ball *et al.*, 2013). Symptoms of obturator nerve damage have been observed in pelvic surgery such as radical prostatectomy, cystectomy, pelvic lymphadenectomy for cancer diagnosis and procedures for the treatment of stress urinary incontinence (SUI) in males and females (Spaliviero *et al.*, 2004, Heidenreich *et al.*, 2007, Hazewinkel *et al.*, 2009, Kitagawa *et al.*, 2009, Shah *et al.*, 2013).

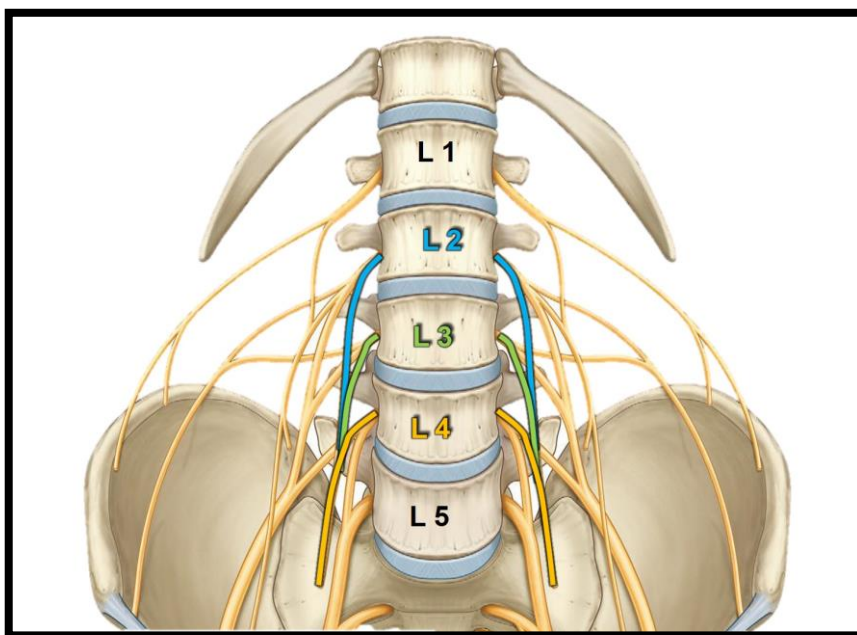
With regard to regional anaesthesia of the obturator nerve and its branches, failed blocks or even nerve damage have been reported when an obturator nerve block for knee and hip surgery is incorrectly performed (Bouaziz *et al.*, 2002, Choquet *et al.*, 2005, Simeoforidou *et al.*, 2013). This further emphasizes the importance of a clear description of the course of the obturator nerve and any possible variations within different population groups.



## Chapter 2 – Literature review

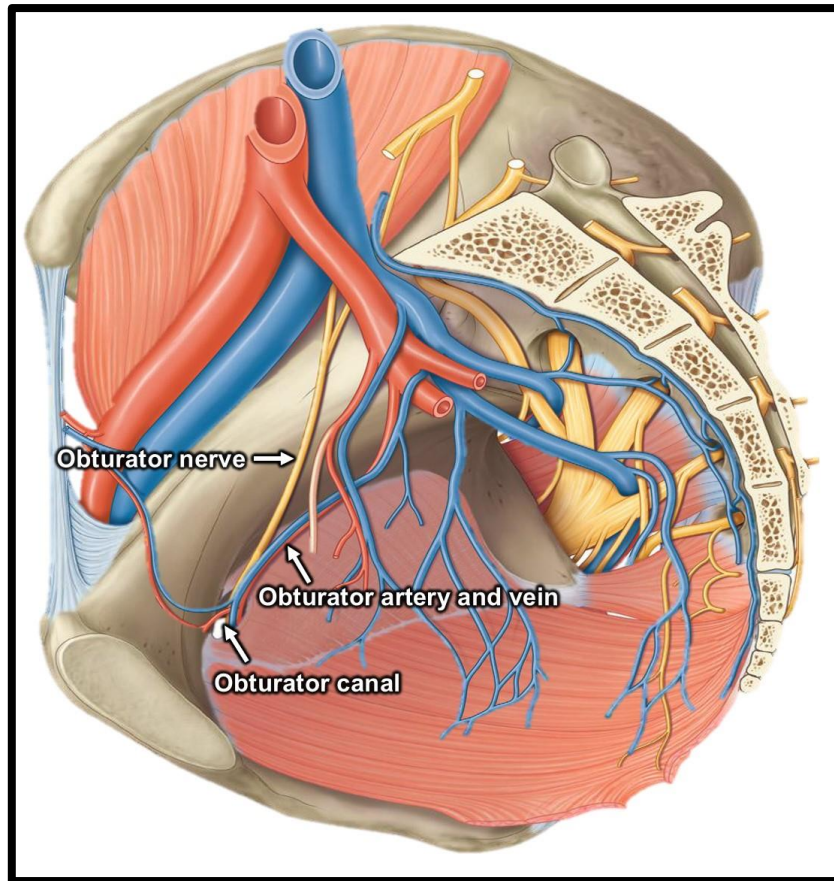
### 2.1. Obturator nerve anatomy

The obturator nerve forms part of the lumbar plexus. It originates from the ventral rami (anterior divisions) of the second (L2), third (L3) and fourth (L4) lumbar spinal nerves. These rami fuse within the psoas major muscle, to then descend and emerge on its medial border; running on the pelvic brim (Figure 1).



**Figure 1:** Root values of the obturator nerve lateral to the lumbar vertebra (Agur and Dalley, 2009)

The nerve then enters the true pelvis at the level of the sacroiliac joint. Here, it is accompanied by the obturator artery and vein. The obturator nerve and artery run antero-inferiorly along the pelvic brim and lateral pelvic wall towards the obturator foramen. At the obturator foramen, the nerve and artery pass through the obturator canal; a fibro-osseous tunnel in the obturator membrane (Figure 2). The obturator canal is the only part of the obturator foramen that is not covered by the obturator membrane and is found supero-laterally within the foramen. The canal is bordered superiorly by the superior pubic ramus and inferiorly by the obturator membrane and the obturator externus muscle.



**Figure 2:** Medial view of the lateral pelvic wall on the right side (Agur and Dalley, 2009)

Once through the obturator canal, the obturator nerve bifurcates into an anterior and posterior branch, as well as a branch to the obturator externus muscle. These branches innervate the muscles of the medial compartment of the thigh and give sensory innervation to the medial thigh and the knee joint. The anterior and posterior branches are separated by the obturator externus muscle as the obturator nerve enters into the medial compartment of the thigh (Wassef, 1993, Bradshaw *et al.*, 1997, Vloka and Hadić, 1999, Ricciardi *et al.*, 2012, Moore *et al.*, 2013). The bifurcation of the nerve has been reported to be variable in its location and have been described to either be intrapelvic, in the canal or extrapelvic (in the medial thigh) (Anagnostopoulou *et al.*, 2009).

### 2.1.1. Anterior branch

The anterior division provides sensory innervation to the distal two-thirds of the skin over the medial thigh and motor innervation to the adductor muscles. It branches off from the obturator nerve to course anterior to the obturator externus muscle and deep to the pectineus muscle. In its course through the medial thigh, the anterior branch runs posterior to the adductor longus and anterior to the adductor brevis muscles. The anterior branch is commonly known to innervate the adductor longus, adductor brevis and gracilis muscles along its course. These muscles, together with the adductor part of the adductor magnus muscle, function as the adductors of the hip (Bradshaw *et al.*, 1997, Tipton, 2008, Anagnostopoulou *et al.*, 2009, Ricciardi *et al.*, 2012).

Variations in the motor innervation of the anterior branch have been reported. The nerve has been observed to also innervate the pectineus muscle, as well as the obturator externus muscle (Bradshaw *et al.*, 1997, Anagnostopoulou *et al.*, 2009). Reports have also shown the anterior branch only innervating the adductor longus and gracilis muscles, while the adductor brevis muscle was innervated by the posterior branch of the obturator nerve. The adductor brevis muscle may also display a double innervation by both the anterior and posterior branches of the obturator nerve (Anagnostopoulou *et al.*, 2009, Vandana *et al.*, 2011).

### 2.1.2. Posterior branch

Within the medial thigh, the posterior branch runs between the adductor brevis muscle posteriorly and the adductor magnus muscle anteriorly. Its primary innervation is to the adductor part of the adductor magnus muscle. As previously mentioned, it may assist the anterior branch in the innervation of the adductor brevis muscle. As it descends, it gives off an articular branch for sensory innervation to the knee joint (Bradshaw *et al.*, 1997, Tubbs *et al.*, 2005, Ahtari *et al.*, 2006, Tipton, 2008).

Further variations were reported in a study by Anagnostopoulou *et al.* (2009), where multiple nerve divisions were observed. Three branches were observed, which innervated the adductor magnus, adductor brevis and obturator externus muscles. In the same study, four branches of the posterior branch were also observed to

innervate the adductor magnus, adductor brevis, obturator externus and adductor longus muscles.

### **2.1.3. Accessory obturator nerve**

The accessory obturator nerve arises from the ventral rami of L3-L4. This nerve is not commonly found and has been reported in 13-40% of people (Katritsis *et al.*, 1979, Bradshaw *et al.*, 1997, Kitagawa *et al.*, 2009). It descends medial to the psoas major muscle, together with the obturator nerve. In its descent, it enters the medial thigh on the superior border of the superior pubic ramus to rest on and innervate the pectineus muscle. If present, it may give articular branches to the hip joint (Bradshaw *et al.*, 1997, Beneš, 1999, Tipton, 2008, Kitagawa *et al.*, 2009).

### **2.1.4. Injury to the obturator nerve**

Damage to the obturator nerve during surgical and clinical procedures may occur if knowledge of the variation in the branching patterns of the nerve is lacking or incorrect. Damage to the obturator nerve may present with motor and/or sensory fallouts such as paraesthesia or loss of sensation to the medial third of the thigh and weakness of the adductor muscles, which may lead to atrophy of the muscles (Beneš, 1999, Spaliviero *et al.*, 2004, Ghaemmaghami *et al.*, 2009). Additionally, compression of the nerve by surgical instruments and inflammation caused by the surgical procedures may cause groin pain. This pain is reversible, although it may persist for some time after repair (Siliski and Scott, 1985, Hazewinkel *et al.*, 2009).

## 2.2. Clinical procedures

### 2.2.1. Obturator nerve block

An obturator nerve block is performed to reduce muscle spasm and sensation to the medial thigh during pelvic and lower limb surgeries. The procedure is also performed to provide anaesthesia for knee surgery. The block is usually performed concurrently with the femoral, sciatic and lateral femoral cutaneous nerve blocks, or a “3-in-1 block”, to ensure full anaesthesia of the lower limb including the knee.

Anaesthesia over the knee may, at times, be obtained without the addition of the obturator nerve block, but studies show that the anaesthetic effects may not be complete. The addition of the obturator nerve block for knee surgery is therefore considered an important component in providing successful anaesthesia intra-operatively (Lang *et al.*, 1993, Morris and Lang, 1999). In addition, the block is performed for pain management around the knee post-operatively (Bouaziz *et al.*, 2002, McNamee *et al.*, 2002). Obturator nerve blocks may also be performed for anaesthesia in transurethral bladder surgical procedures to prevent muscle contraction of the adductor muscles intra-operatively (Augspurger and Donohue, 1980, Gasparich *et al.*, 1984, Akata *et al.*, 1999).

There are two main approaches that could be used to block the obturator nerve; the traditional and interadductor approach.

#### 2.2.1.1. Traditional approach

This method was first described by Labat (1922). In this approach, a needle is inserted perpendicular to the skin at a distance 1.5 - 3 cm lateral and 1.5 – 3 cm inferior to the pubic tubercle. The needle, connected to a nerve stimulator, is inserted until it reaches the inferior border of the superior pubic ramus. It is then slightly retracted from the bone and is angled antero-laterally along the border of the superior pubic ramus. This is continued until the obturator nerve is stimulated resulting in the adductor muscles being in spasm, after which the anaesthetic is injected.

### 2.2.1.2. Interadductor approach

This approach was described by Wassef (1993) as an alternative to the traditional approach. In the study, the author suggested that the traditional approach was difficult to perform as a result of the anatomy of the area in which the needle was inserted. This was supported by Moore (1979) and Kakinohana *et al.* (2002).

In the interadductor approach, the femoral artery is identified and a mark is made 1 - 2 cm medial to it and then inferior to the inguinal ligament to denote the trajectory of the needle. The adductor longus is identified and marked as well. An insulated needle, attached to a nerve stimulator, is inserted posterior to the tendon of the adductor longus muscle and advanced laterally. The spasm of the adductors of the thigh will indicate that the needle is in close proximity to the obturator nerve and the local anaesthetic solution is injected.

In 1993, Wassef compared the two procedures. Each procedure was performed on 10 patients. It was found that the traditional approach was successful in only 60% (n = 6) of the cases, while the interadductor approach was successful in 80% (n = 8) of the cases. These findings were later supported by Kakinohana *et al.* (2002).

### 2.2.2. Pelvic lymphadenectomy

Lymphadenectomy is a surgical procedure performed for diagnosis and staging in cancer patients (Briganti *et al.*, 2006). As a preventative measure, it entails the surgical removal of lymph nodes in the area where the cancer is located. Although damage is said to be rare, injury to the obturator nerve has been reported in the surgical management of gynaecological and urologic cancers (Guillonneau *et al.*, 2002, Kitagawa *et al.*, 2009, Ricciardi *et al.*, 2012, Pavlovich *et al.*, 2015). This is possibly due to a disruption of the normal anatomy from space occupying growths. It may also be due to a lack of knowledge of the normal anatomy in the region; such as the potential variations of the obturator nerve or lack of a clear description of its course in a specific population group.

In a case report by Ricciardi *et al.* (2012), the obturator nerve was transected during a lymphadenectomy of pelvic lymph nodes in a patient with cervical cancer. The nerve was transected intra-operatively and, at a later stage, repaired without any functional loss. In another case of lymphadenectomy performed in a male patient with prostate cancer, the obturator nerve was transected intra-operatively. The injury was identified and repaired laparoscopically (Spaliviero *et al.*, 2004). A similar complication was also reported by Pavlovich *et al.* (2015), where the obturator nerve was damaged during pelvic lymph node dissection with cystectomy for the treatment of bladder cancer in male patients.

### **2.2.3. Transobturator procedures**

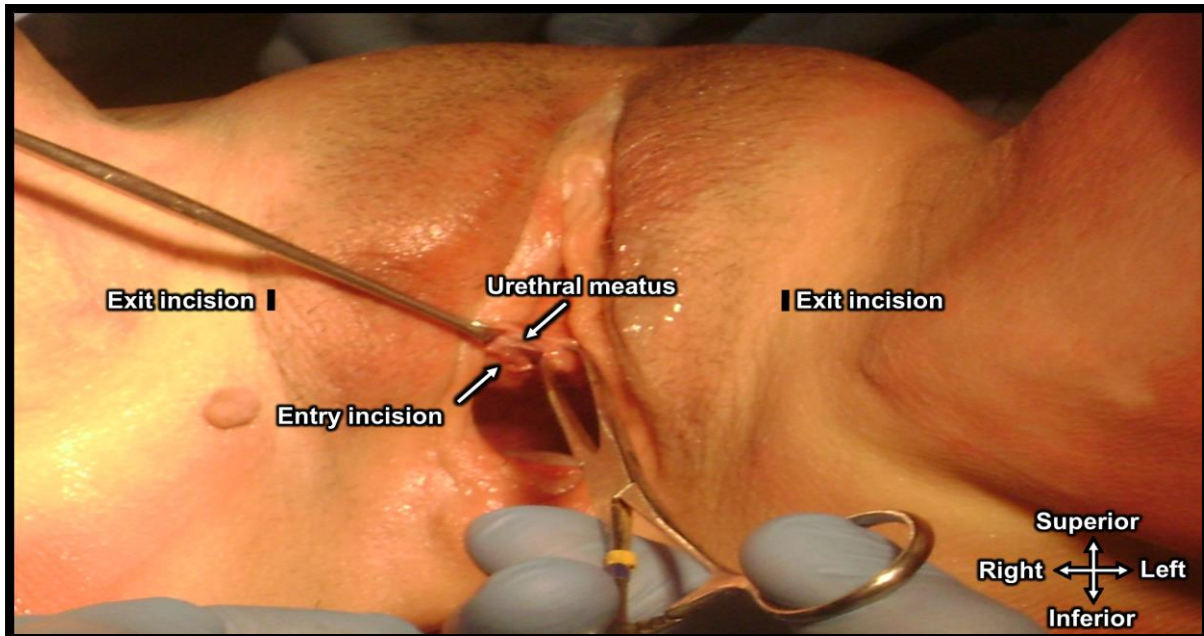
These procedures are performed for the treatment of SUI in both males and females. It requires traversing the left and right obturator foramina, with a surgical needle, in order to secure a transobturator sling under the mid-urethra (Ridgeway *et al.*, 2008). Various types have been developed and are discussed below.

#### **2.2.3.1. Tension-free Vaginal Tape-Obturator inside-out technique (TVT- O)**

The tension-free vaginal tape inside-out technique (TVT-O) was developed in order to overcome the safety issues and complications caused by the previously used tension-free vaginal tape (TVT) procedure for the treatment of SUI in females (de Leval, 2003, Ahtari *et al.*, 2006). The TVT procedure utilises the retropubic space instead of the obturator foramen as a pathway for needle insertion and sling placement. An incision is made inferior to the urethral meatus to allow needle introduction. The needles exited through incisions made superior to the pubis, 5 cm apart.

For the procedure, the patient is placed in the lithotomy position; the legs are placed in stirrups and the thighs are abducted and flexed. The TVT-O procedure shies away from the retropubic space by using the obturator foramen as an area for needle penetration in the placement of the transobturator mid-urethral sling. As in the TVT procedure, it uses an incision made inferior to the urethral meatus as an entry point for the helical needles (entry incision). These are rotated laterally on either side to

pierce through the obturator foramen and exit at horizontal incisions made at the genitofemoral folds, 2 cm superior to the level of the mid-urethra (exit incision) on both legs (Figure 3) (Ulmsten *et al.*, 1996, Ulmsten *et al.*, 1998, Costa and Delmas, 2004, Bonnet *et al.*, 2005).



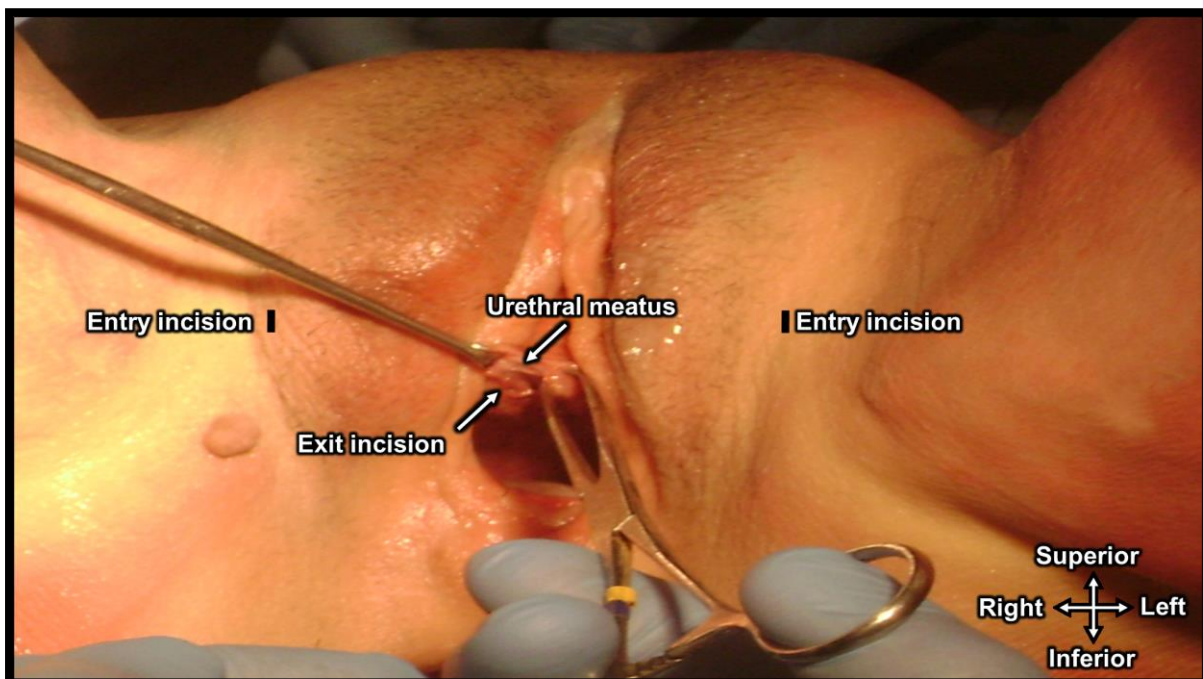
**Figure 3:** View of the perineum of an unembalmed female cadaver placed in the lithotomy position. Incision made for the entry of the needles inferior to the urethral meatus and the exit incisions at the genitofemoral fold (Picture courtesy of Tshabalala *et al.*, 2013).

Complications caused by the placement of the TVT-O have been documented by other studies (Boyles *et al.*, 2007, Juang *et al.*, 2007). These include mesh erosion, as well as bowel, bladder and blood vessel injuries. Cases of groin pain due to obturator nerve injury have also been reported in the literature and was found to be higher in the TVT procedure when compared to the TVT-O procedure (de Leval, 2003, Juang *et al.*, 2007, Wang *et al.*, 2009). Although seemingly safer than the TVT procedure, the TVT-O inside out procedures does seem to have its own associated issues; as mentioned above.



### 2.2.3.2. Transobturator Tape outside-in technique (TOT females)

The TOT outside-in procedure was developed to minimise the complications experienced in the placement of the TVT-O procedure in females. The TOT outside-in procedure similarly uses the obturator foramen as a pathway for the placement of a sling around the urethra. The TOT outside-in procedure differs in technique by inserting the needles through the incisions made at the genitofemoral fold (entry incision), with the patient placed in the lithotomy position. The needles are rotated medially and exit through an incision made inferior to the urethral meatus (exit incision) (Figure 4). The sling is attached to the needles, to be pulled through the pathway created by the needles through the obturator foramen (Costa and Delmas, 2004, Bonnet *et al.*, 2005). This technique allows the surgeon to enter at their preferred angle, choosing the correct angle would thereby avoid damage to the obturator nerve and vessels.

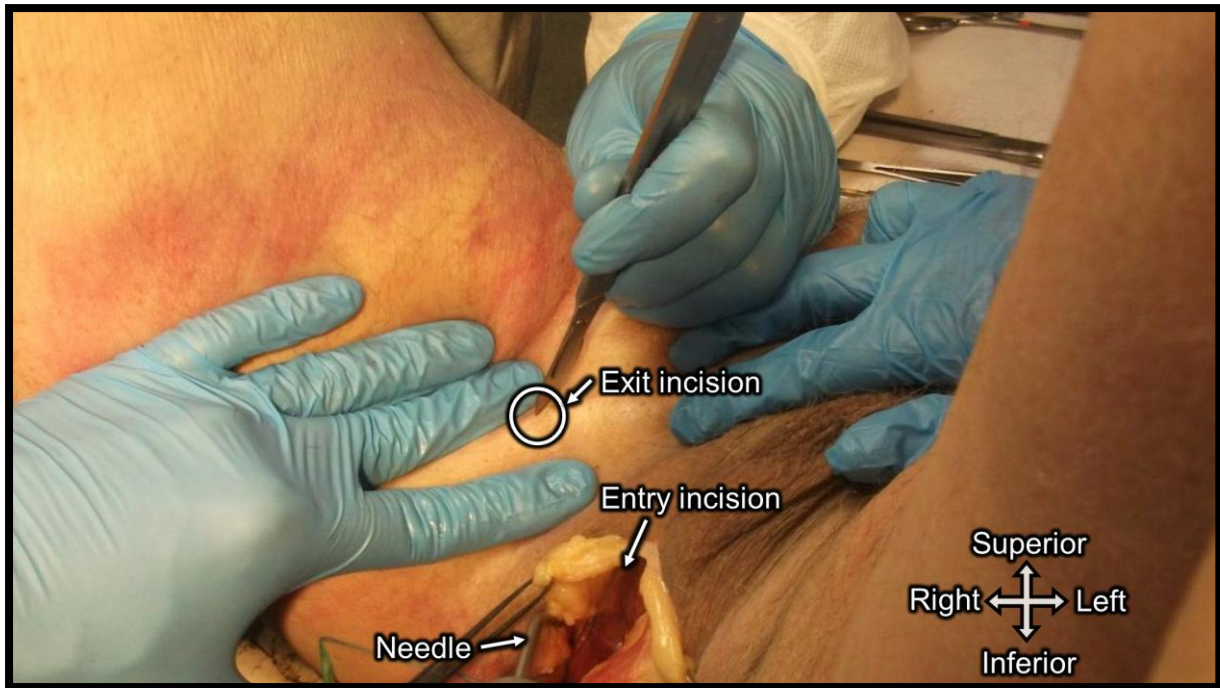


**Figure 4:** View of the perineum of an unembalmed female cadaver placed in the lithotomy position. Incision made for the entry of the needles in the genitofemoral fold and the exit incision made inferior to the urethral meatus (Picture courtesy of Tshabalala *et al.*, 2013).

Although the literature deemed the TOT outside-in safer than the TVT and TVT-O inside-out procedures, the obturator nerve may be injured during the procedure as needles pass near the infero-lateral bladder and bladder neck during placement of the sling; which are in close proximity to the obturator nerve in the pelvis (Hradec *et al.*, 1982, Akata *et al.*, 1999, Khorrami *et al.*, 2010). Injury to the pelvic organs has also been reported, although complications involving the urinary tract are found to be lower in TOT than in the other procedures. Other complications include vaginal erosion, haemorrhaging, dyspareunia and perineal pain (Costa and Delmas, 2004, Kaelin-Gambirasio *et al.*, 2009).

### 2.2.3.3. *Transobturator Tape inside-out technique (TOT males)*

The TOT inside-out procedure is used for the treatment of SUI in males. This procedure uses an incision made between the scrotum and the anal margin to allow a dissection to accommodate the needles (entry incision), with the patient placed in the lithotomy position. Through this incision, the needles enter the perineal space between the base of the penis medially and the ischiocavernosus muscle laterally. The needles are rotated laterally to pierce the obturator foramen. The needles exit through incisions made in the genitofemoral fold (exit incision), lateral to the scrotum at the level of the base of the penis (when it is reflected onto the abdomen), as seen in figure 5 (Rehder and Gozzi, 2007, De Leval and Waltregny, 2008).

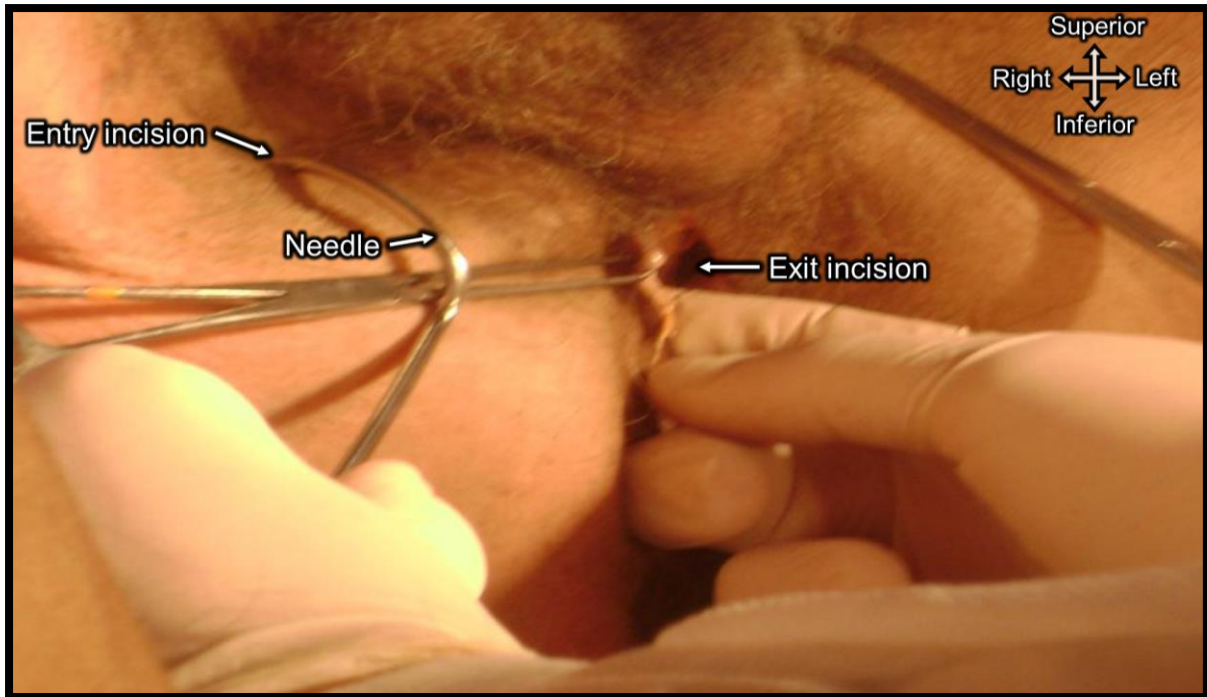


**Figure 5:** View of the perineum of an unembalmed male cadaver placed in the lithotomy position. The scrotum is reflected superiorly to allow insertion of the needles through the obturator foramen from the inside (Picture courtesy of Tshabalala *et al.*, 2013).

Current literature has reported this procedure to be safe, with minimal complications, although the obturator nerve is still located in the area where the tape is inserted (De Leval and Waltregny, 2008, Gozzi *et al.*, 2008).

#### 2.2.3.4. *Transobturator Tape outside-in technique (TOT males)*

Similar to the inside-out technique, this procedure is also performed for the treatment of SUI in males. It uses the same concept as the TOT procedure in females, with the patient placed in the lithotomy position, whereby incisions in the genitofemoral folds are used to insert the needles (entry incision); whereafter the needles are rotated medially. The needles exit lateral to the bulb of the penis between the ischiocavernosus muscle laterally and the bulb of the penis medially (exit incision). The mesh is attached to the needle and pulled through the obturator foramen (Figure 6) (Rehder and Gozzi, 2007, Gozzi *et al.*, 2008).



**Figure 6:** View of the perineum of an unembalmed male cadaver placed in the lithotomy position. The scrotum is reflected superiorly to allow insertion of the needles through the obturator foramen from the outside.

*The procedure was not included in the postgraduate dissertation by Tshabalala et al. (2013), the picture was only used to demonstrate the TOT outside-in procedure.*

Obturator nerve damage is a common complication that may be incurred in all of these procedures. The clinical symptoms of damage to the nerve are weakness of the adductor muscles and loss of sensation of the medial thigh. Groin and perineal pain in males and females respectively may only be a temporary complication of damage to the nerve, but could still radically reduce the quality of life for these individuals (de Leval, 2003, Whiteside and Walters, 2004, Juang *et al.*, 2007, Wang *et al.*, 2009). Therefore, clinical knowledge of the position, course and branching pattern of the obturator nerve is essential to successfully perform these procedures without complications, irrespective of severity.

#### 2.2.3.5. Previous study on SUI treatment procedures

In an unpublished dissertation by Tshabalala *et al.* (2013), the researchers investigated the relations of the obturator nerve to mid-urethral slings placed for the treatment of SUI in males and females. The sample was equally distributed according

to sex (n = 28). The TOT inside-out procedure was performed on 14 males, the TOT outside-in procedure was performed on 7 females and the TVT-O inside-out procedure was performed on the final 7 females in the sample. Measurements were made from the obturator nerve to the mesh in each of these procedures.

The researchers reported that the posterior branch was most in danger in all the procedures. The anterior branch was found to be safe from the trajectory of the needles. These results were supported by a study by Spinosa *et al.* (2007).

## **2.3. Aim**

The aim of this MSc study was to address certain “gaps” that currently exist in the literature regarding the obturator nerve. This study aimed to achieve this by means of detailed qualitative and quantitative descriptions of the anatomy (origin, course, relationship to other structures, branching patterns and variations) of the obturator nerve in a Southern African cadaver population.

### **2.3.1. Research objectives**

1. To expand the knowledge on the anatomy of the obturator nerve and its branches through qualitative observation of its origin, course, branching patterns, muscle innervation and possible variations.
2. To give a quantitative description of the obturator nerve within the obturator foramen using palpable bony landmarks.
3. To find clinical relevance for the knowledge of the anatomy of the obturator nerve and its branches, as well as described variations, by comparing it to the current literature and guidelines to perform surgical/clinical procedures in the area of this nerve.

## **Chapter 3 – Materials and methods**

A total of 101, formalin-fixed, cadavers were used in the study. The sample comprised of 61 males and 40 females ( $68 \pm 17$  years). The cadavers were obtained from the Department of Anatomy, School of Medicine, Faculty of Health Sciences, University of Pretoria in 2014 and 2015. The usage of these cadavers falls under the auspices of the South African National Health Act 61 of 2003. Bilateral dissections were made to the posterior abdominal wall, pelvic cavity and upper medial thigh of each cadaver. The study was conducted in three phases.

### **3.1. Phase 1: Description of the course of the obturator nerve within the abdomen**

#### **3.1.1. Exclusion criteria**

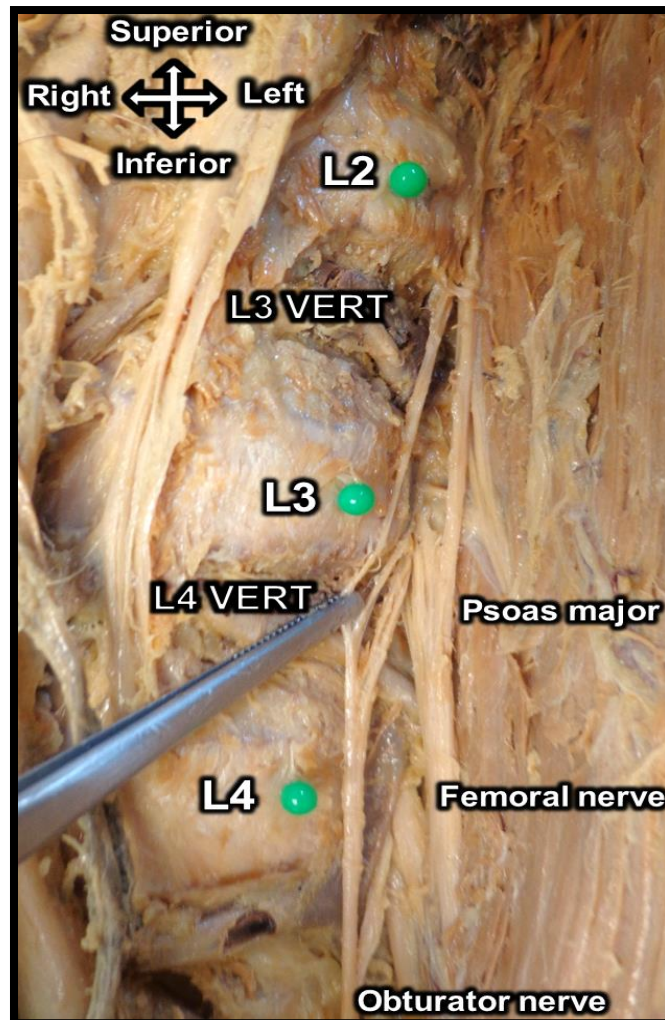
Cadavers with previous surgery, pathology, that have been previously dissected or where the psoas major muscle was not intact at its origin, were excluded. There was no exclusion with regard to age, race or sex.

#### **3.1.2. Dissection procedure**

After the data collection, the sample size for obturator nerve root dissection was reduced to 181 sides (90 left and 91 right sides) as a result of exclusion of a side or both sides of a cadaver. The cadaver sample consisted of 55 males and 36 females. The investigation comprised of the observation of the anatomy of the obturator nerve from its origin (point where the anterior rami of lumbar spinal nerves fused lateral to the vertebral column) and its course throughout the abdominal and pelvic cavity, to its termination in the medial compartment of the thigh.

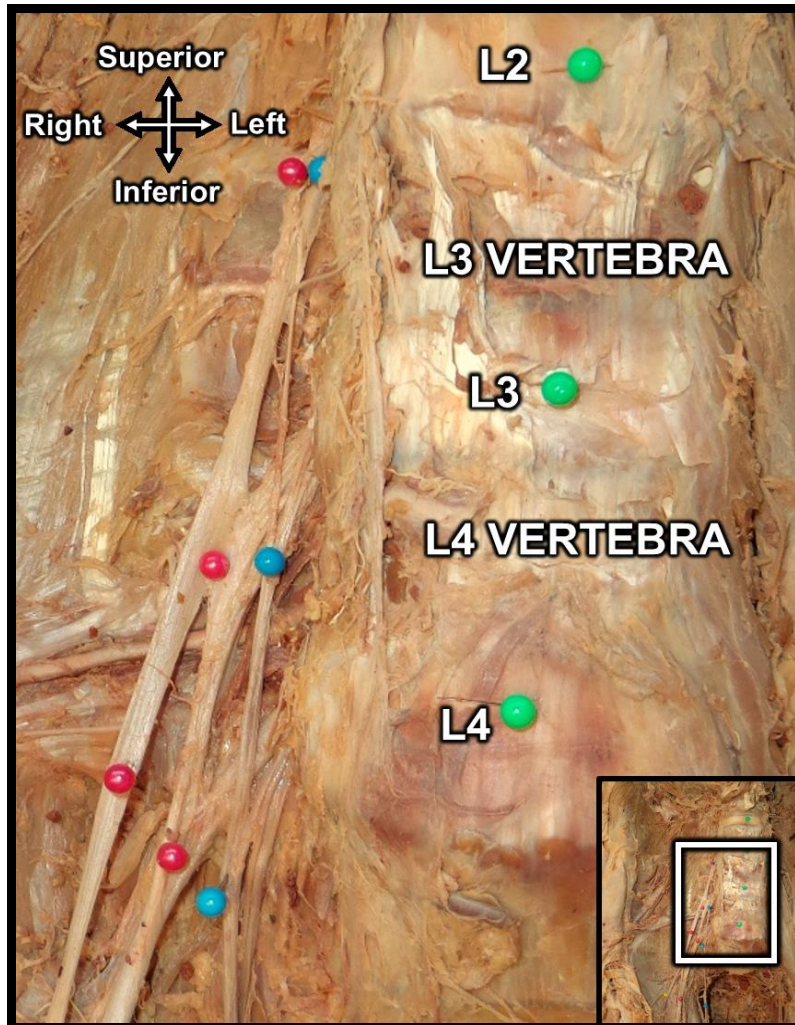
Before the commencement of dissections, the lumbar vertebrae were identified and pins were placed into their respective intervertebral discs. To determine the origin of the nerve from the vertebral column, the relation to the psoas major muscle in the abdomen was firstly noted. The fibres of the psoas major muscle were carefully

reflected from their origins on the vertebral column until the rami of the spinal nerves were visible; thereby ensuring that the nerves were not damaged. The obturator nerve was followed proximally and the rami that formed the nerve were identified. Where necessary, additional blunt dissection was done to isolate the rami (Figure 7).



**Figure 7:** Pinning of the intervertebral discs on the left  
*Vert - Vertebra*

The rami were pinned and any variations found were noted and photographed. The relations of the rami to those of other nerves were also recorded (Figure 8). The course of the obturator nerve, after its rami fused, was then observed. All relations to muscles, vessels and other nerves were noted as it descended towards the true pelvis and travelled to the obturator canal to conclude its course within the abdomen and pelvis.



**Figure 8:** Pinned intervertebral discs (green) and nerve rami of the obturator nerve (blue) and femoral nerve (pink)

The course of the nerve was then followed into the lower limb, as the obturator nerve exited the obturator canal. The obturator nerve was firstly observed as it terminated into its anterior and posterior branches, noting whether it terminated within the pelvis (intrapelvic), the obturator canal (within canal) or the thigh (extrapelvic). Within the canal was defined as a point between the obturator canal and the anterior surface of the obturator externus muscle. This defined a nerve to have bifurcated within the canal if the anterior and posterior branches originated before they emerged from the obturator externus muscle; where the posterior branch pierces the muscles. In turn, extrapelvic bifurcation would be when the anterior and posterior branches originated after the obturator externus muscle, emerging on its superior border, to then innervate the muscles of the medial thigh.



Thereafter, the course of each terminal branch – to their respective areas of muscle innervation – were observed. Finally, the position of the terminal branches, in relation to adductor muscles, and their course to innervate these muscles were observed and accurately described. Any variations observed were also noted.

### **3.1.3. Statistical analysis**

Analyses were firstly done on the different root values of the obturator nerve on the left and right sides of the lumbar vertebrae. A Chi-Square test was performed against sex to determine significance of the influence in the different root values. For cells with an expected count of less than 5, a two-sided Fisher's exact test was performed. For the bifurcation patterns of the obturator nerve at the obturator foramen, a contingency table was made to determine frequencies. Similarly, a contingency table was also made for the innervation patterns of the anterior and posterior branches of the obturator nerve in the medial compartment of the thigh.

## **3.2. Phase 2: Location of the obturator nerve within the obturator foramen**

### **3.2.1. Exclusion criteria**

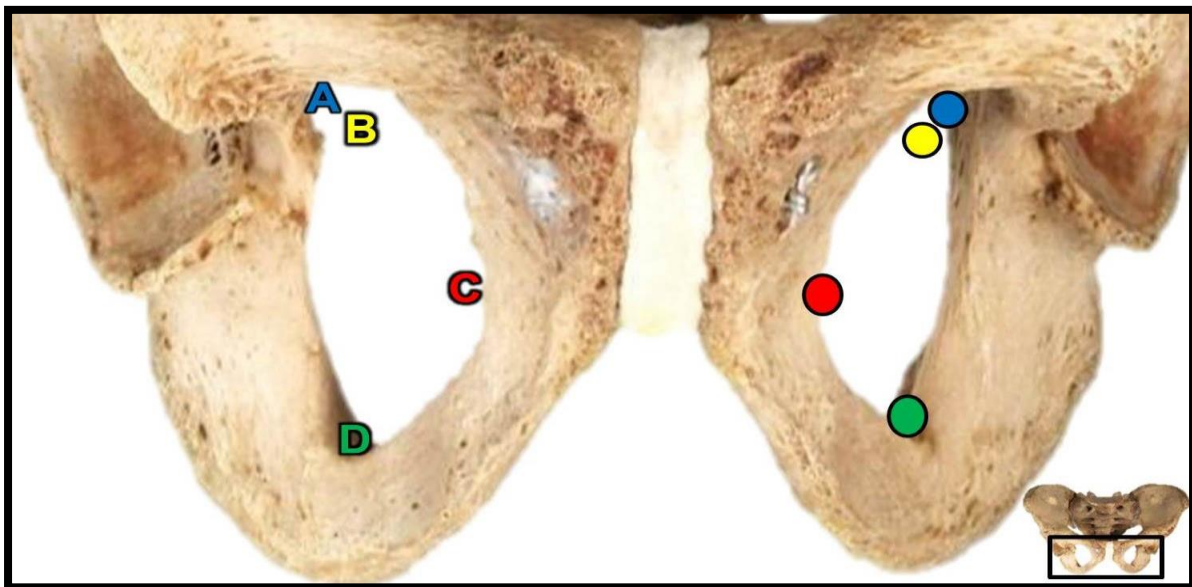
Cadavers were excluded from the sample if the medial thigh was fully dissected, if there was previous surgery performed in the area or if there was visible pathology in the area of the obturator foramen. No cadaver was excluded according to age, race or sex.

### **3.2.2. Dissection procedure**

This phase was the quantitative aspect of the study, quantifying the location of the obturator nerve within the obturator foramen. Measurements were made only after all observations of the obturator nerve and its branches within the abdomen, pelvis and the medial compartment of the thigh were completed. The exclusion of cadavers or

one side of a cadaver reduced the sample size to 186 sides; 95 left and 91 right sides. These sides were from a sample of 99 cadavers; 60 males and 39 females.

For the measurements, three specific bony landmarks of the obturator foramen were used to locate the obturator nerve (B) within the foramen. These were the most superior (A), most medial (C) and most inferior points (D) of the obturator foramen (Figure 9).



**Figure 9:** Landmarks used to locate the obturator nerve within the obturator foramen. Each point is indicated by a similarly coloured letter (right) and circle (left).

The dissection was initiated by placing the cadavers in a supine position, with the hips abducted. This was achieved by placing the lower extremities of the cadaver beside metal stirrups secured to the sides of the dissection tables. To expose the designated landmarks, the adductor muscles of the medial thigh and surrounding muscles were reflected or removed, as necessary. The most superior point of the obturator foramen was exposed by carefully reflecting the pectineus muscle laterally from the pectineal line and the adductor longus muscle inferiorly from the superior pubic ramus.

Once landmark A was exposed, a measurement was taken between the latter and the obturator canal (landmark B). To expose landmark C and D of the foramen, muscles were removed from their origins; parts of the adductor brevis and adductor magnus muscles were removed from their origins to allow stability of the obturator nerve and

to allow space for the calliper. A part of the adductor brevis muscle was removed from the body and inferior ramus of the pubis and a part of the adductor magnus muscle from the ischiopubic ramus. The last muscle to be reflected was the obturator externus muscle, along the margins of the obturator foramen.

The sliding calliper was pressed against landmarks C and D and measurements to landmark B were made from each point. To describe the average position of B within the obturator foramen, descriptive statistics were used.

### **3.2.3. Statistical analysis**

To evaluate the location of B within the obturator foramen, a two-sided t-test was done. The measurements of the left and right sides of A-B, B-C and B-D were compared to test for any significant difference between them ( $p < 0.05$ ). Thereafter, individual Generalised Linear Models (GLM) were performed on the measurements using sex as a defining factor to test if sex has an influence on the measurement.

## **3.3. Phase 3: Clinical applications of the results**

Using the results from the previous phases, selected surgical and clinical procedures performed in areas where the obturator nerve is present were investigated. Comparisons of the results were then made with current guidelines of these procedures through extensive literature searches using the PubMed, Science Direct, Ovid and Google Scholar journal databases, as well as current surgical and anaesthetic textbooks/guidelines. The results were compared to the investigated procedures using similar landmarks, allowing validation or contention of these procedures. Procedures were chosen according to specific criteria:

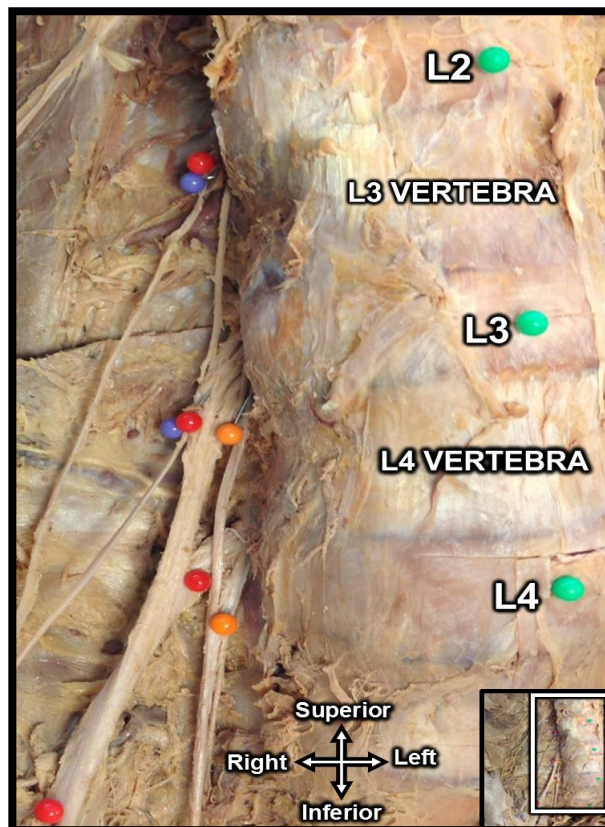
1. Their procedural relationship to the obturator nerve and/or its branches, i.e. Proximity of instruments used and/or the selected procedural landmarks to the nerves
2. Possible damage to the obturator nerve and/or its branches by performance of these procedures.

## Chapter 4 – Results

### 4.1. Origin and course of the obturator nerve and its branches

#### 4.1.1. Root values of the obturator nerve

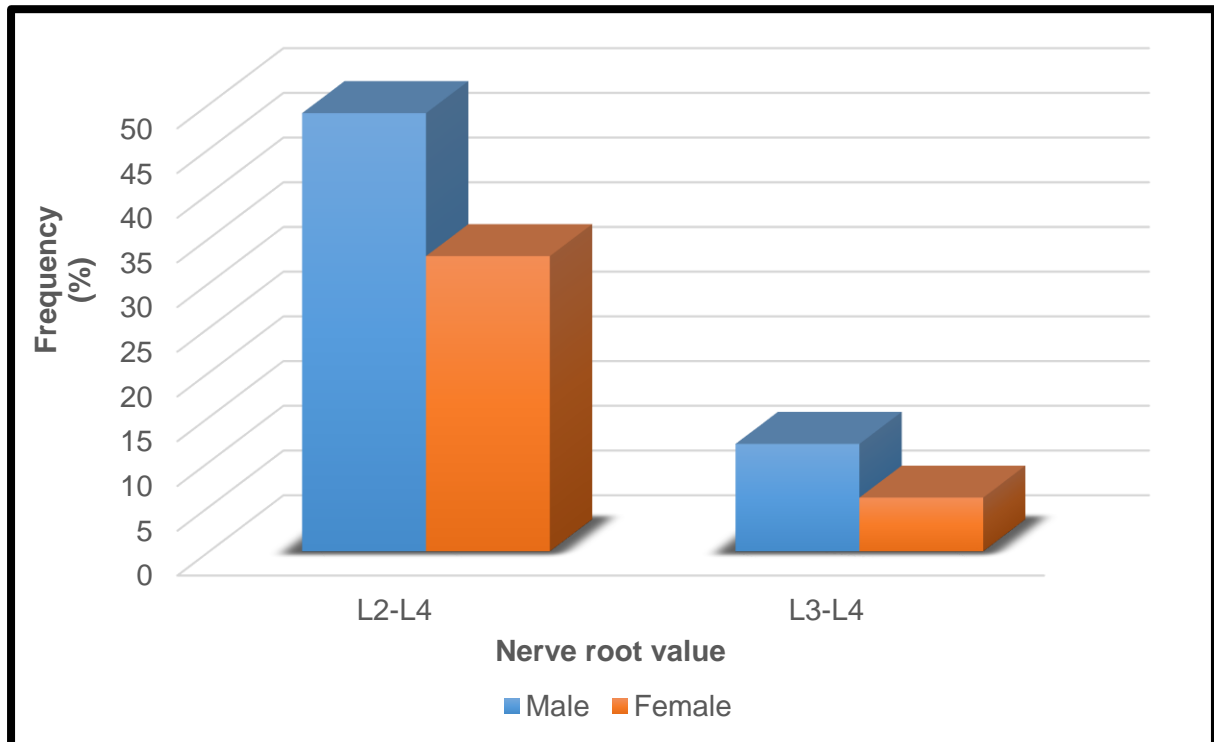
The obturator nerve originates from the L2, L3 and L4 spinal nerves. Variations of this norm are known to be present, as seen in figure 10, where the L2 root is absent. A contingency table was made for the influence of sex on the origins of the obturator nerve on the left side. The sample of left sides (n = 90) consisted of 61% males (n = 55) and 39% females (n = 35).



**Figure 10:** Nerve roots of the nerves of the lumbar plexus from L2-L4, with an absent obturator nerve L2 contribution.

*Green – Intervertebral discs. Orange – Obturator nerve roots. Red – Femoral nerve roots. Blue – Lateral femoral cutaneous nerve roots.*

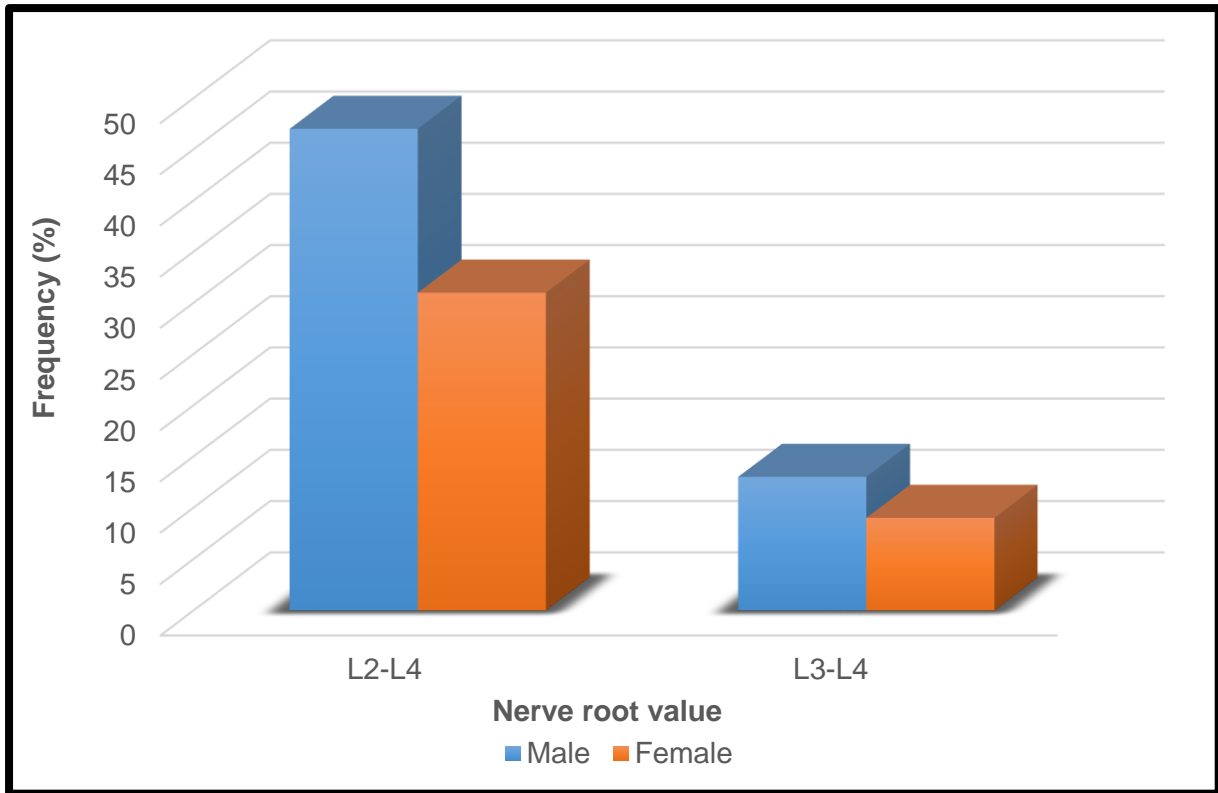
Figure 11 below indicates that 82% (n = 74) of the obturator nerves observed originated from the L2-L4 nerve roots and 18% (n = 16) originated from only the L3 and L4 nerve roots. This is further broken down into the obturator nerve of 49% of the males (n = 44) and 33% of the females (n = 30) originating from the L2-L4 nerve roots. Alternatively, the obturator nerve originated from the ventral rami of only the L3 and L4 nerve roots in 12% of the males (n = 11) and 6% of the females (n = 5).



**Figure 11:** Obturator nerve root value frequencies on the roots in males and females on the left

A Chi-square test revealed that the influence of sex on the root values of the obturator nerve was not significant ( $p = 0.49$ ).

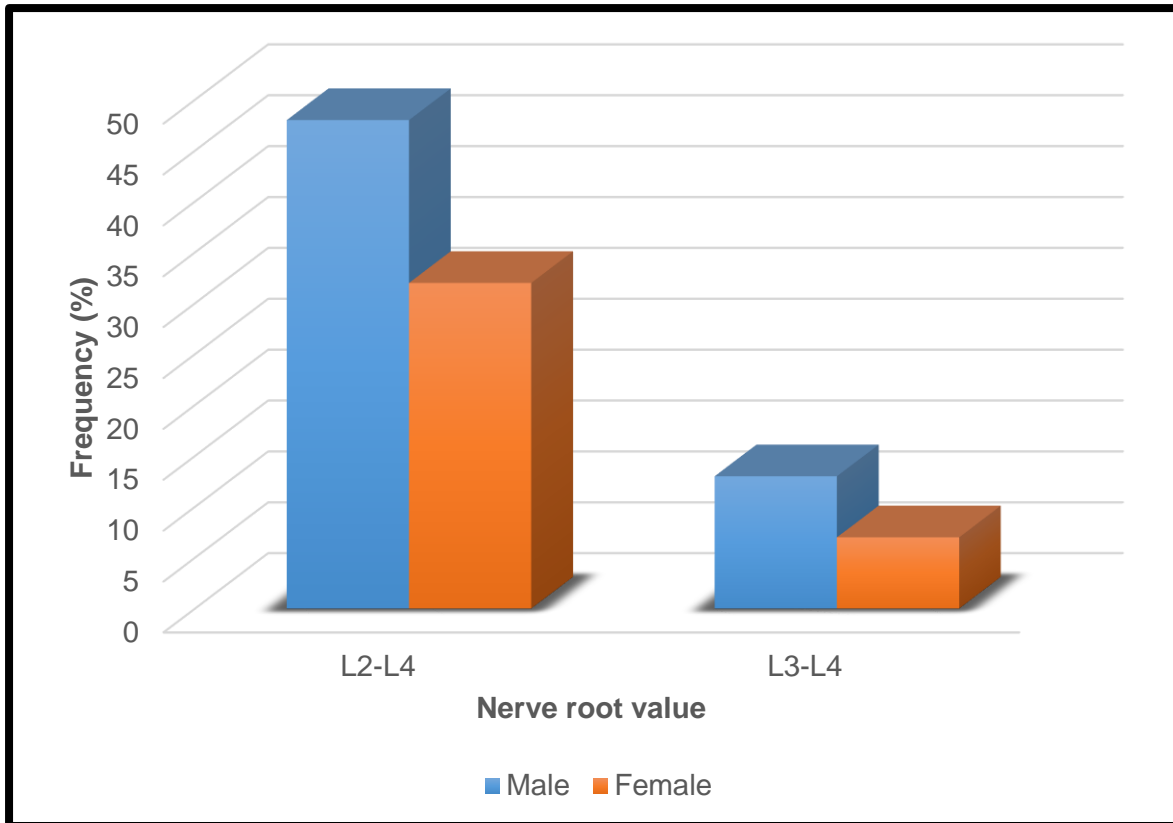
Similar tests were performed on the nerve root on the right (n = 91). The results in figure 12 show that 78% (n = 71) of the cases had the obturator nerve originated from the L2-L4 spinal nerve roots, while 22% (n = 20) originated from L3 and L4. Additionally, 47% of the male cases (n = 43) and 31% of the female cases (n = 28) originated from the L2-L4 nerve roots, with 13% of the male cases (n = 12) and 9% of the female cases (n = 8) originated from L3 and L4 nerve roots.



**Figure 12:** Obturator nerve root value frequencies on the roots in males and females on the right

The Chi-square test determined that sex had no statistically significant influence on the root value of the right obturator nerve ( $p = 0.96$ ).

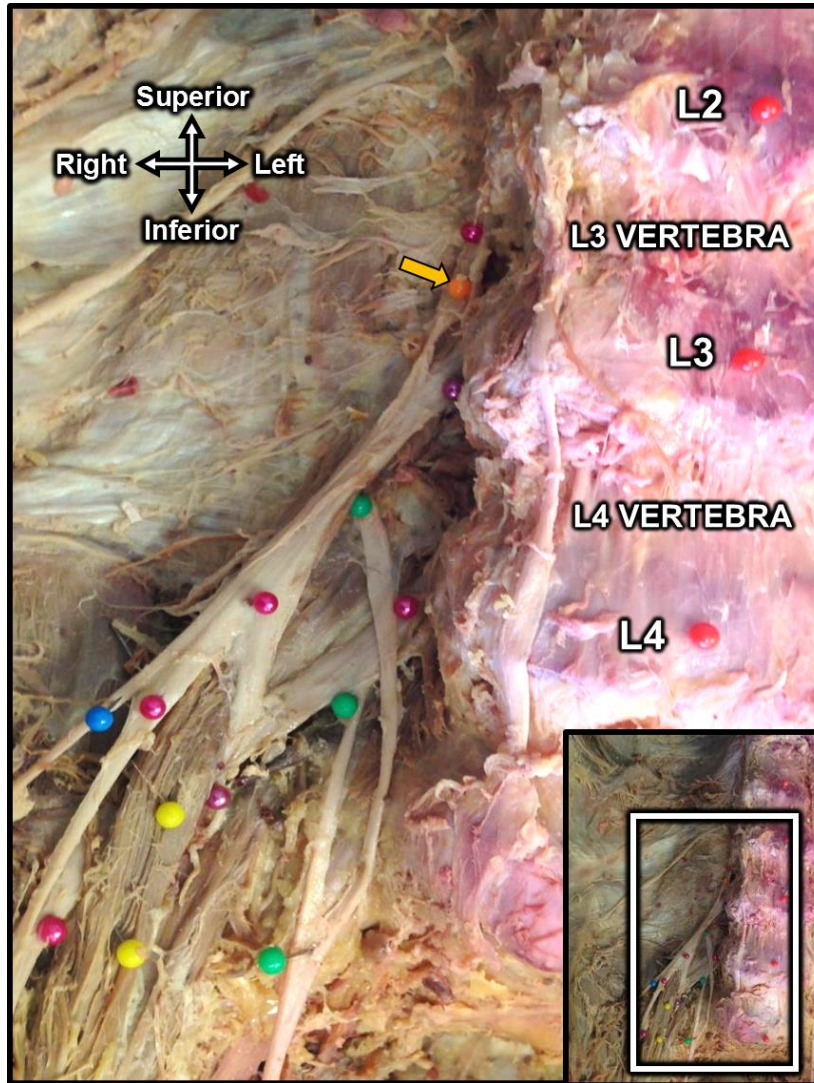
This allowed the sample to be combined into a sample of 181 sides. In the new combined sample, the nerve was observed to originate from L2-L4 in 80% ( $n = 145$ ) of the cases and from L3 and L4 in 20% ( $n = 36$ ) of the cases. Within the new sample, the nerve originated from L2-L4 in 48% of the males ( $n = 87$ ) and in 32% of the females ( $n = 58$ ). Alternatively, the nerve originated from L3 and L4 in 13% of the males ( $n = 23$ ) and 7% of the females ( $n = 13$ ), as seen in figure 13.



**Figure 13:** Combined obturator nerve root value frequencies in males and females

#### 4.1.2. Course through the abdomen

The roots of the obturator nerve generally fused within the fibres of the psoas major muscle. Some instances were recorded where one of the roots only joined the others more distally, after exiting the psoas major muscle on its medial border. This is evident in figure 14, where the L3 nerve root joins the L4 root within the true pelvis. Similar fusions were seen in 2 other cases (n = 3 of 181 cases (1.7%)).

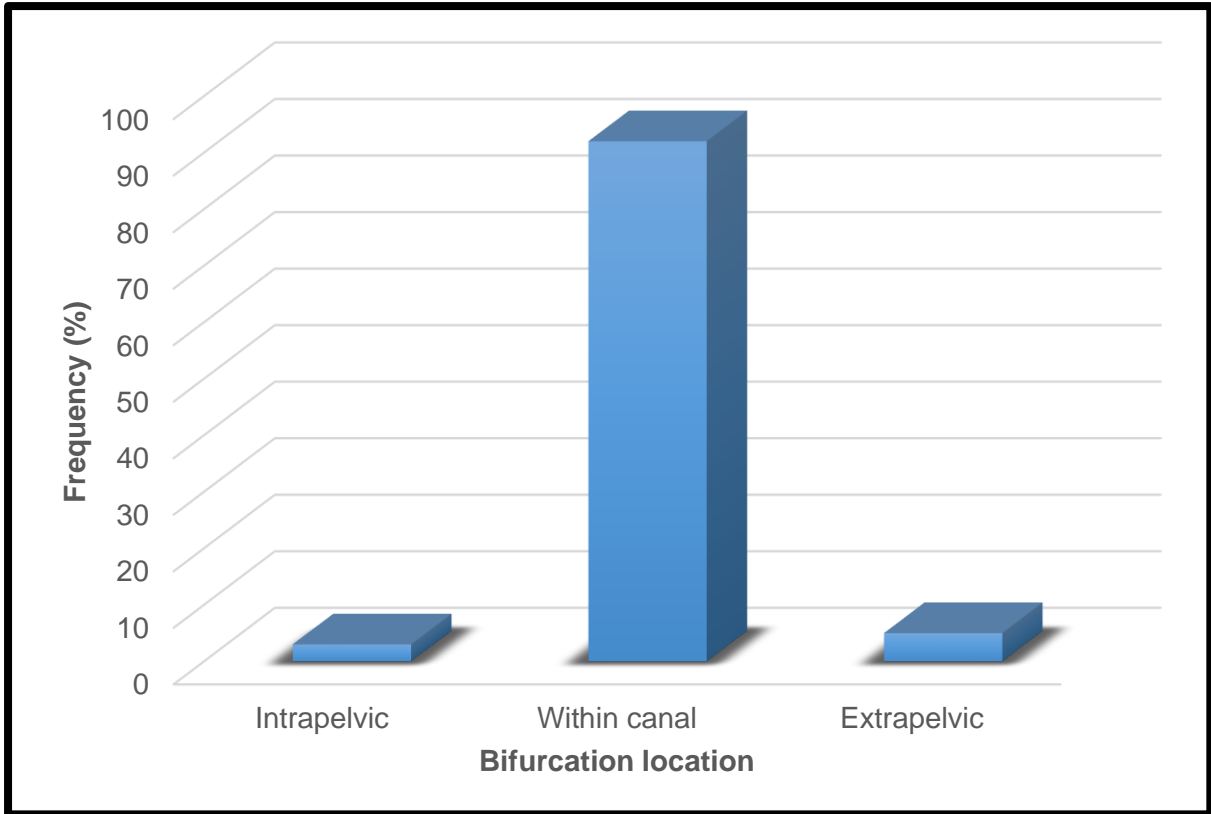


**Figure 14:** The low fusion of L3 to L4 obturator nerve (green) roots  
*Pink – Femoral nerve. Blue – Lateral femoral cutaneous nerve.*  
*Orange (with arrow) – Genitofemoral nerve. Yellow – Remaining fibres of psoas major.*

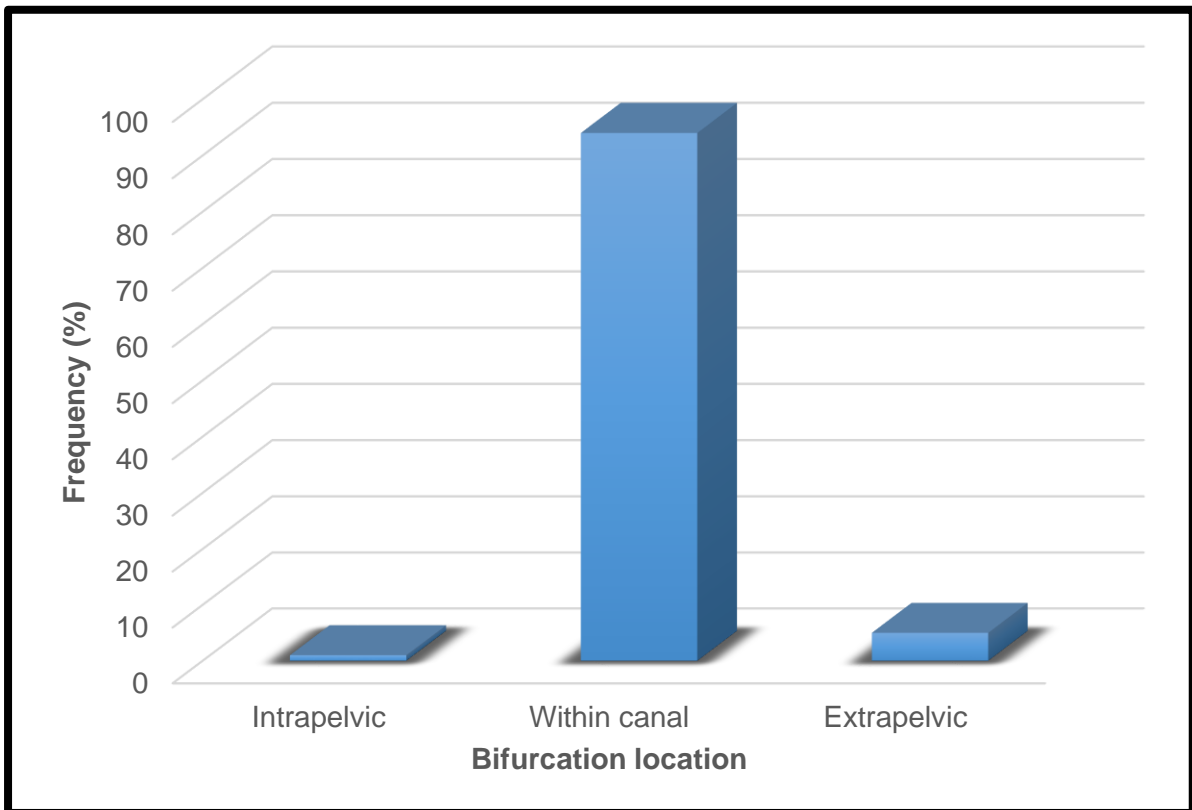
#### 4.1.3. Bifurcation of the obturator nerve

Bifurcation of the obturator nerve occurred at the obturator canal, where it terminated into the anterior and posterior branches of the obturator nerve. The frequencies of the left and right bifurcation patterns are represented in figure 15 and 16, with an overall sample size of 101 on the left and 100 on the right. Intrapelvic bifurcation occurred only in 3% (n = 3) on the left and 1% (n = 1) on the right. Bifurcation was observed mostly frequently within the obturator canal, in 92% (n = 93) of the cases on the left and in 94% (n = 94) on the right. Extrapelvic bifurcation occurred in 5% of the cases on both the left and right (n = 5)



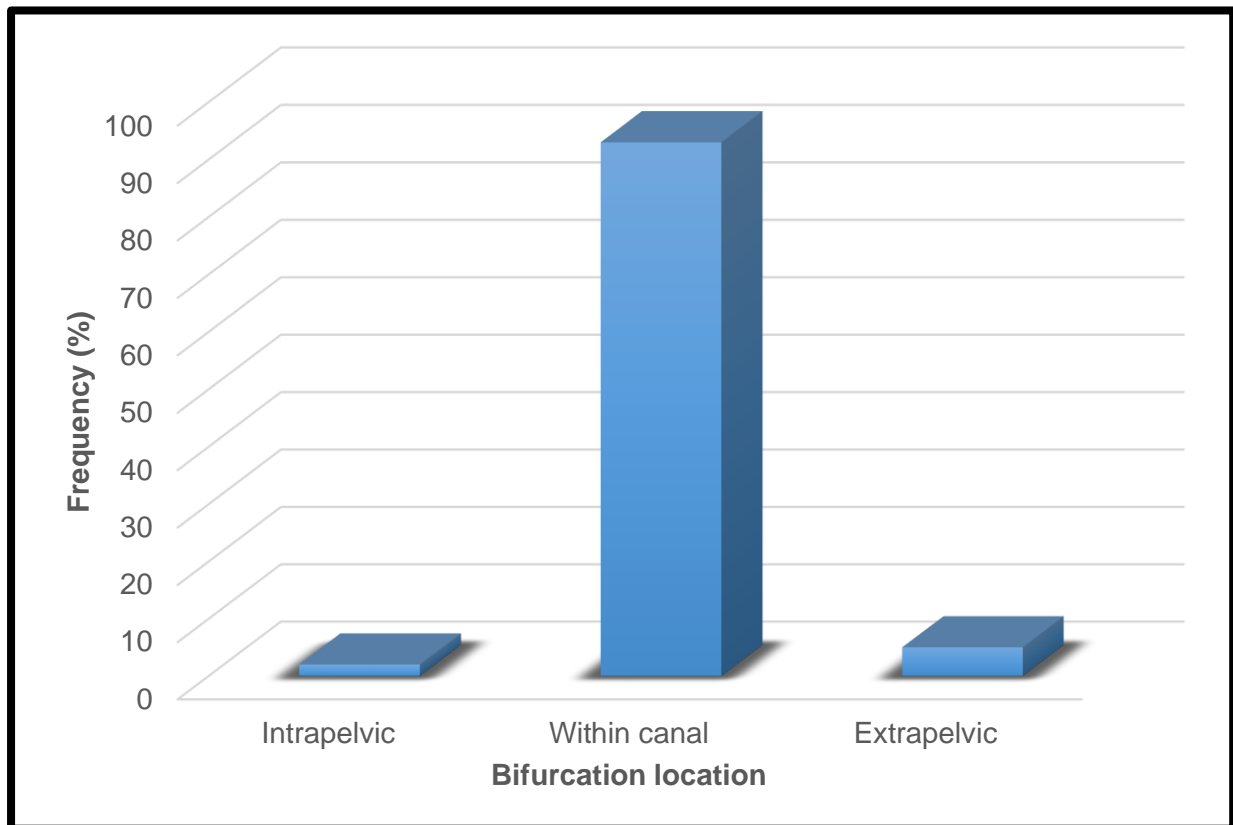


**Figure 15:** Left obturator nerve bifurcation location frequencies



**Figure 16:** Right obturator nerve bifurcation location frequencies

No significant difference was found between left and right sides in terms of sex ( $p > 0.05$ ). The lack of significance allowed the left and right sides to be pooled into one sample size of 201 specimens. In the new sample, intrapelvic bifurcation of the nerve was observed in 2% ( $n = 4$ ) of the cases. Bifurcation within the obturator canal was observed in 93% ( $n = 187$ ) of the sample and extrapelvic bifurcation was observed in 5% ( $n = 10$ ) of the sample. These results are represented by the graph in figure 17.

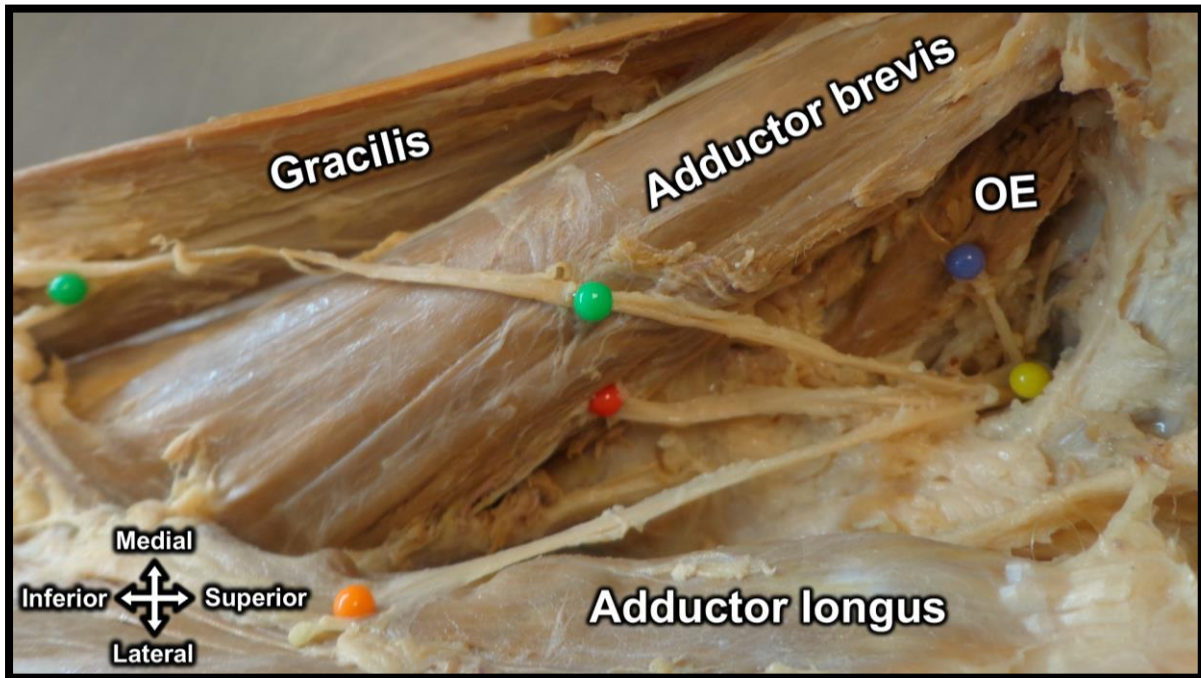


**Figure 17:** Combined obturator nerve bifurcation location frequencies

#### 4.1.4. Muscle innervation in the medial thigh

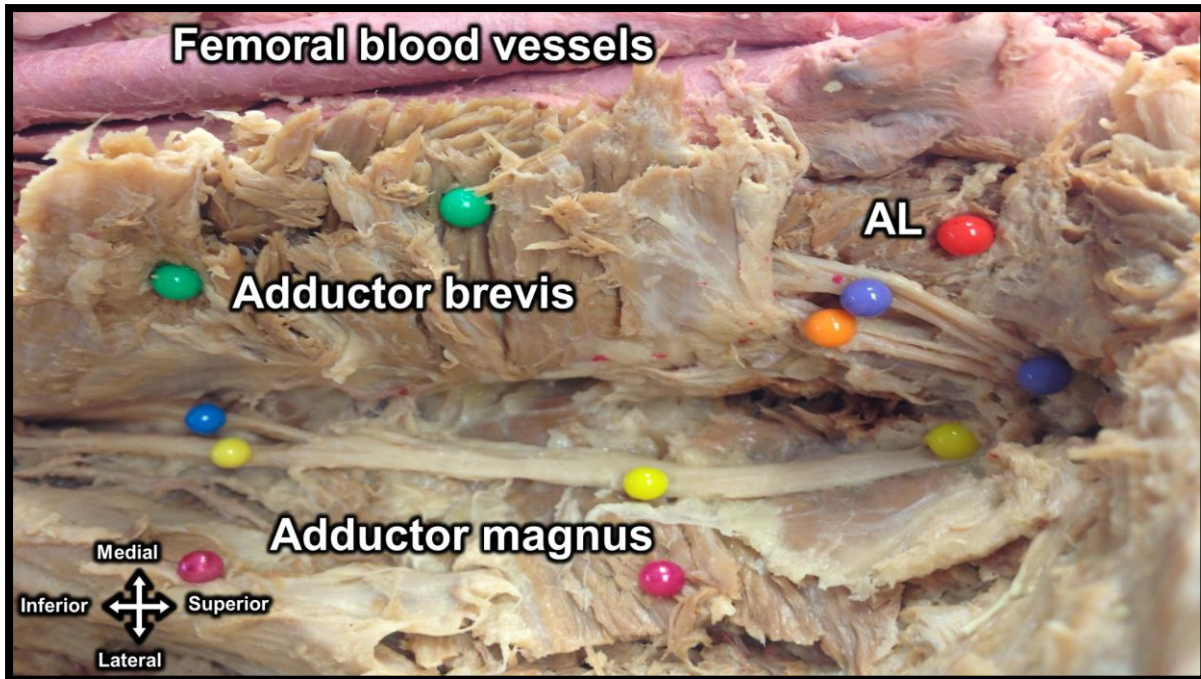
According to anatomical literature, the anterior branch of the obturator nerve commonly innervates the adductor longus, adductor brevis and gracilis muscles. The posterior branch is described to innervate the obturator externus and the adductor part of the adductor magnus muscle (Bradshaw *et al.*, 1997, Anloague and Huijbregts, 2009, Moore *et al.*, 2013). There was some variation with regard to this norm. In all cases on the left ( $n = 97$ ) and 99% on the right ( $n = 98$ ), the anterior branch innervated

the muscles of the medial thigh as commonly described (Figure 18). There was one case on the right, where the anterior branch innervated the pectineus muscle.



**Figure 18:** View of the innervation patterns of the anterior branch of the obturator nerve (yellow) as it innervates the gracilis (green), adductor longus (orange) and adductor brevis (red). Obturator externus (OE) as it is innervated by the posterior branch (purple)

The posterior branch of the obturator nerve is known to innervate the obturator externus and the adductor magnus muscles. In this study, it was the case in 90% (n = 87) on the left of the total cases (n = 97) and in 89% (n = 87) of the cases on the right (n = 98). The posterior branch was also observed to assist the anterior branch in the innervation adductor brevis. This was the case in 10% (n = 10) on the left and 11% (n = 11) on the right sides (Figure 19).



**Figure 19:** Medial view of the double innervation of the adductor brevis (green) muscle by the anterior (orange) and posterior (blue) branches of the obturator nerve. AL - Adductor longus. Purple – Nerve to adductor longus. Posterior branch – Yellow.

#### 4.2. Phase 2: Location of the obturator nerve within the obturator foramen

To quantify the location of the obturator nerve within the obturator foramen, a two-sample t-test was performed to test for significant differences between the left (n = 95) and right (n = 91) measurements. Pooled (equal variance) and Satterthwaite (unequal variance) methods were performed on the A-B measurements to analyse the probability of having either equal or unequal variance between the samples. Both the methods resulted in a p-value of 0.19, showing no significant difference between the measurements, regardless of variance. A test of equality of variance confirmed that the samples have equal variance, resulting in a p-value that is equal to 0.19,

Similar statistics were performed on the B-C measurements. A check for the variance of the sample had a p-value of 0.95 for the Pooled and Satterthwaite methods. The test of equality revealed that the sample had equal variance, with a p-value of 0.34. This indicated equal variance of the sample.

For the B-D measurements, a p-value of 0.26 was observed for both the Pooled and Satterthwaite methods. A p-value of 0.71 was seen for the test of the equality of variances for the measurements. Equal variance of the sample could then be assumed.

GLMs were made for each of the averages of the measurements of the obturator foramen landmarks to the nerve. These models were used to test whether sex had a significant influence on the measurements within the obturator foramen. A p-value of 0.34 for the influence of sex indicated that there was no significant difference with regard to the distance between the most superior point of the foramen (landmark A) and the obturator nerve (landmark B) within the obturator canal. The mean value (mean  $\pm$  SD) of the A-B length averages was found to be  $6.25 \pm 1.76$  mm.

GLM was also performed for the B-C measurement. The mean value for the B-C lengths was  $31.77 \pm 3.74$  mm. No significant difference was found for the influence of sex on the distance between the obturator nerve (B) and the most medial point of the obturator foramen (landmark C) ( $p = 0.61$ ).

The final measurement completed the overall location of the obturator nerve in the obturator foramen. The B-D measurements had a mean value of  $47.48 \pm 4.19$  mm. There was however a significant difference found for the influence of sex on the distance of the obturator nerve (B) to the most inferior point of the obturator foramen (landmark D) ( $p < 0.0001$ ).

The observed mean values for the measurement B-D in the male and female samples are  $48.85 \pm 3.55$  mm and  $44.99 \pm 3.42$  mm respectively. It is important to note that the male sample mean value is larger than of the female sample.

### 4.3. Phase 3 - Clinical applications of the results

A variety of relevant clinical and surgical procedures were identified after an extensive search of the available literature. Keywords used in the database searches mentioned in the materials and methods were: *obturator nerve*, *obturator nerve variation*, *obturator nerve damage*, *obturator nerve blocks*, *lumbar plexus* and *obturator nerve surgery*. As possible procedures were identified after results of the previous keywords, the following additional keywords were used to find the most relevant procedures: *total knee arthroplasty*, *lumbar plexus block*, *obturator lymphadenectomy*, *transurethral transection*, *urinary incontinence surgery*, *knee analgesia*. Although many other clinically relevant procedures were found on the obturator nerve and its branches, not all of them were reviewed. The review resulted in three procedures being selected for investigation; two of which are clinical (obturator nerve block and pelvic lymphadenectomy) and one surgical (SUI treatment in males and females). The applications of the results on these procedures are detailed in chapter 5.

## Chapter 5 – Discussion

### 5.1. Origin and course of the obturator nerve and its branches

Knowledge of the anatomy of the obturator nerve and its branches is important in the successful performance of clinical and surgical procedures. The results indicate that there are variations with regard to the origin, course and branching pattern of the obturator nerve. A clear and concise observational and quantitative analysis of these variations will assist in decreasing complications involving the obturator nerve in procedures performed on or around the area of the obturator nerve and its branches.

#### 5.1.1. Root values of the obturator nerve

In chapter 3, the roots of the obturator nerve were investigated. There was no significant influence found for sex as a defining factor for nerve root values of the obturator nerve. This implies that procedural techniques performed on the obturator nerve or structures within its surrounding area at the lumbar vertebra may be applied to both males and females.

Variations were found with regard to the absence or presence of the L2 spinal root in the formation of the obturator nerve. This is contrary to a study by Anloague and Huijbregts (2009), where no variations were found in the origins of the obturator nerve at the lumbar vertebrae. In a study of 60 lumbar plexuses by Arora *et al.* (2014), the obturator nerve originated from L2-L4 in only a third of the sample. Horwitz (1939) found similar results in a sample of 228 lumbar plexuses, where it was observed that the obturator nerve mostly arose from L3 and L4, with a small percentage originating from the L2 to L4 and the twelfth thoracic lumbar nerve root (T12) to the L5 root values. This was not observed in the current study. Table 1 compares the findings of the above studies to the current study.

**Table 1:** Prevalence of varied origins of the obturator nerve

Study	Country	n	Prevalence (%)		
			L2-L4	L3-L4	T12-L5
Horwitz (1939)	USA	228	10	77	13
Anloague and Huijbregts (2009)	USA	38	100	0	0
Arora <i>et al.</i> (2014)	India	60	33	65	2
Current study (2015)	South Africa	181	80	20	0

The accessory obturator nerve is not commonly found in the lumbar plexus (Tubbs *et al.*, 2005, Akkaya *et al.*, 2008, Anloague and Huijbregts, 2009). Similar to a study by Tubbs *et al.* (2005) where no instance of an accessory nerve was found, the current study did not observe the presence of an accessory obturator nerve in the 181 sides. Several studies that have examined the presence of an accessory obturator nerve are summarised in table 2.

**Table 2:** Prevalence of the accessory obturator nerve

Study	Country	n	Prevalence (%)
Tubbs <i>et al.</i> (2005)	USA	22	0
Akkaya <i>et al.</i> (2008)	Turkey	24	12.5
Anloague and Huijbregts (2009)	USA	38	8.8
Current study (2015)	South Africa	181	0

### 5.1.2. Nerve roots and the psoas major muscle

The roots of the obturator nerve have been documented to fuse within the psoas major muscle, descending within the muscle and emerging on its medial border at the level of the pelvic brim (Bradshaw *et al.*, 1997, Kirchmair *et al.*, 2008, Anagnostopoulou *et al.*, 2009, Shah *et al.*, 2013). This description of the course of the roots of the obturator nerve was observed in this study, with the roots traversing the length of the psoas major muscle until it entered the true pelvis. It entered the true pelvis posterior to the convergence of the internal and external iliac veins, at the level of the sacroiliac joint.



### 5.1.3. Obturator neurovascular bundle

Within the true pelvis, the obturator nerve lies against the lateral pelvic wall, accompanied by the obturator vessels. The neurovascular bundle runs together, from superior to inferior, as the obturator nerve, obturator artery and then the obturator vein. As they accompany each other, the neurovascular bundle enters the obturator canal of the obturator foramen. This correlates with findings by Won *et al.* (2015). After entering the medial compartment of the thigh, the orientation of the neurovascular bundle changes to; from medial to lateral; the obturator vein, obturator artery and then the obturator nerve. This was observed in a study by Kendir *et al.* (2008), where 22 cadaver sides were investigated.

Knowledge of these relationships will allow for the prevention of complications such as haemorrhaging of the obturator artery during surgery (Akata *et al.*, 1999, Soong *et al.*, 2007). In a study of pelvic neuropathies by Cardosi *et al.* (2002) of 23 patients that had undergone pelvic surgery, the incidence of obturator nerve damage was 39% (n = 9). Knowledge of the relationship of the obturator nerve to other structures within the pelvis could allow the incidence rates of complications to decrease.

### 5.1.4. Bifurcation (termination) of the obturator nerve

The obturator nerve terminates into the anterior and posterior branches of the obturator nerve around the area of the obturator canal. This bifurcation of the nerve is known to vary in its location in relation to the obturator canal. In a study by Anagnostopoulou *et al.* (2009), the authors investigated this phenomenon in 168 sides (84 cadavers). The results of this study, as well as the current study, are compared in table 3.

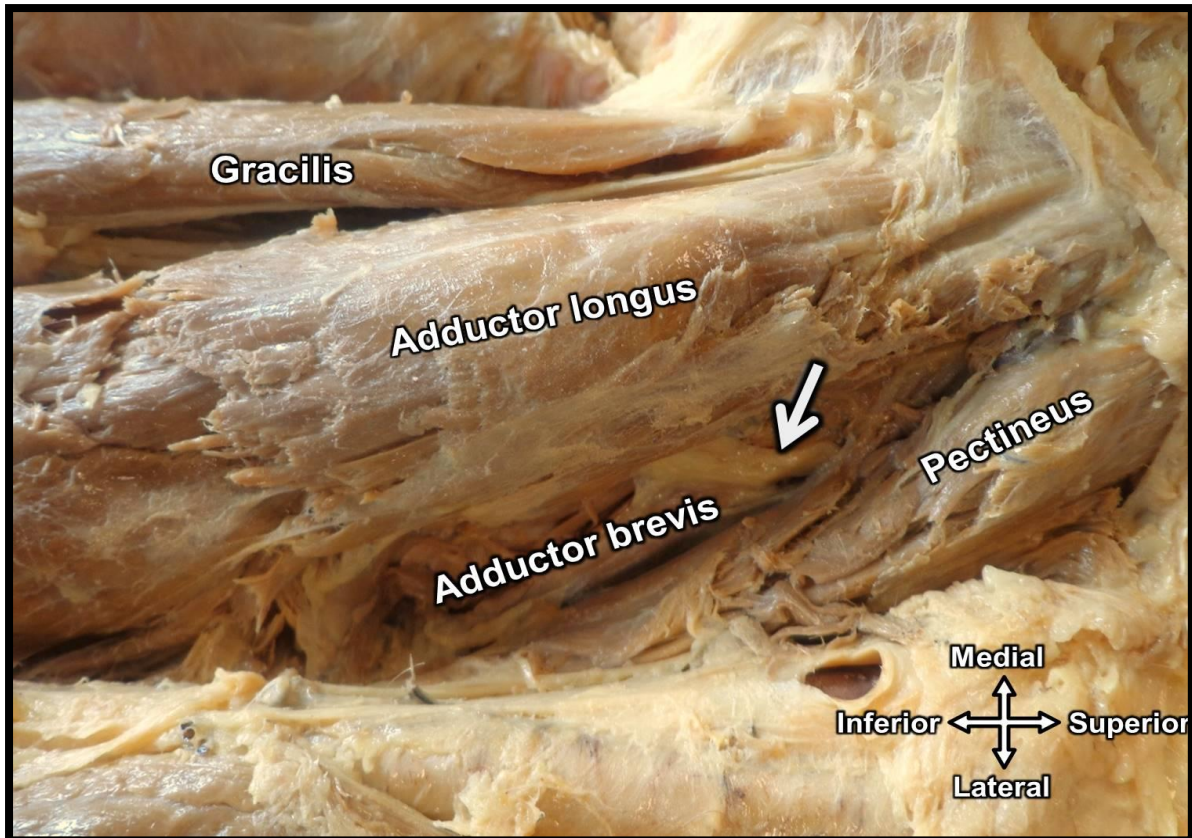
**Table 3:** Comparison of bifurcation location frequencies

	Country	n	Branching frequencies (%) around the obturator canal		
			Intrapelvic	Within canal	Extrapelvic
Anagnostopoulou <i>et al.</i> (2009)	Greece	168	25	23	52
Current study (2015)	South Africa	201	2	93	5

No additional literature investigating the bifurcation patterns of the obturator nerve could be found. This lack of information echoes the previous statements on the need for further research of the anatomy of the obturator nerve. It can be seen in the table that the results between the two studies are very different. This might be as a result of the difference in the definition of each location of bifurcation of the obturator nerve into its anterior and posterior branches, specifically in the definition of extrapelvic and “within canal” bifurcation. Anagnostopoulou *et al.* (2009) defined extrapelvic bifurcation as a point after the obturator canal and then define “within canal” bifurcation as located within the obturator canal. The within canal definition was difficult to adhere to, as it gave little room for clear visualisation, as the obturator membrane that forms the obturator canal is a thin fibrous layer. The current study defined the locations differently, by using the obturator externus muscle as the boundary between within canal and extrapelvic. The definition allows consistency in the allocation of bifurcation location; as the obturator externus muscle is always present in the area.

### 5.1.5. Anterior branch of the obturator nerve

The anterior branch has both motor and sensory fibres. It appears deep to the pectineus muscle to continue between the adductor longus and brevis muscles, innervating them, as can be seen in figure 20. The nerve also innervates the gracilis muscle, medially, to give sensory innervation to the medial side of the thigh. This description was observed in this study. These observations have been documented by other researchers as well (Anagnostopoulou *et al.*, 2009, Sinha *et al.*, 2009)



**Figure 20:** Anterior branch of the obturator nerve (arrow) as it appears deep to the pectineus muscle, to descend between adductor longus and brevis muscles (left leg)

#### 5.1.6. Posterior branch of the obturator nerve

The posterior branch of the obturator nerve emerges through the obturator externus muscle to enter the medial compartment of the thigh, innervating the muscle (Bradshaw *et al.*, 1997). In this study, there was variation with regard to the appearance of the posterior branch in relation to the obturator externus muscle. The nerve either pierced or appeared on the supero-lateral surface of the muscle.

After branching from the obturator nerve, the posterior branch ran between the adductor brevis and adductor magnus muscles, only innervating the latter. This was observed in the current study. It was also observed that the posterior branch assisted the anterior branch in the innervation of the adductor brevis muscle in 11% (n = 21) of the sample (n = 195). This variation was observed at a higher frequency in a study by Anagnostopoulou *et al.* (2009), where the double innervation of the adductor brevis muscle was seen in 70% of the sample (n = 168).

The anatomy and variations are important to note, as blocking of the posterior branch of the obturator nerve, with a local anaesthetic solution, has been reported to assist in post-operative analgesia of patients that have undergone knee surgery; in combination with other blocks (McNamee *et al.*, 2002).

## **5.2. Location of the obturator nerve within the obturator foramen**

Three (3) bony landmarks of the obturator foramen were identified as possible points that may be used to locate the obturator nerve during surgery. To the best of our knowledge, no published literature was found where these landmarks were used to locate the obturator nerve within the obturator foramen.

The current study found that these bony landmarks are viable to use during surgical procedures where a pathway through the obturator foramen is required. The most medial and most inferior points of the obturator foramen are palpable during surgery are all palpable during SUI surgeries. Although the most superior point may not be used in procedures, it was important to use this landmark in order to provide a complete description of the obturator nerve within the obturator foramen. If used concurrently with the quantified location of the obturator nerve within the obturator foramen reported in this study, these landmarks may aid in pre-operative planning, as well as the success of intra- and post-operative procedures or care.

The ability to palpate these landmarks intra-operatively will help surgeons to safely guide their instruments through the foramen without damaging the obturator nerve and its branches. This is opposed to the use of the midpoint of the ischiopubic pubic ramus used during TOT and TVT-O procedures for the treatment of SUI in males and females. Studies suggest that this landmark will guide surgeons in inserting the needles closer to the ischiopubic ramus within the obturator foramen (Whiteside and Walters, 2004, Hinoul *et al.*, 2007). Use of the midpoint of the ischiopubic ramus is subjective, as this point is dependent on the surgeon performing the procedure.

This study aimed to provide a clear location of the obturator nerve within the area using the selected landmarks, to assist in the possibility of using them as landmarks in

clinical and surgical procedures. Knowledge of the location of the obturator nerve within the obturator foramen may assist in the safe performance of surgical procedures performed in the area; such as in the treatment of SUI in males and females (Ulmsten *et al.*, 1996, Juang *et al.*, 2007, Gozzi *et al.*, 2008, Bauer *et al.*, 2010).

Moore *et al.* (2013) describes the obturator foramen to be different in shape between males and females. The authors describe the shape of the obturator foramen as round in males and oval in females. Not much research has been done on the shape of the obturator foramen. In a study by Ridgeway *et al.* (2008), the shape of the obturator foramen between African American and European American females was investigated. The authors reported that there was a difference in the shape of the obturator foramen between the female groups. The study suggested that the differences were as a result of differences in stature and not race.

In a study by Bierry *et al.* (2010), the authors investigated the difference in the shape of the obturator foramen between 52 males and 52 females using three-dimensional computed tomography. The obturator foramen was described to be oval in males and triangular in females, concluding that there is sexual dimorphism in the shape of the foramen.

The results of the current study yielded a significant difference on the influence of sex for the B-D measurement only ( $p < 0.0001$ ), the distance between the obturator nerve and the most inferior point of the obturator nerve. The authors suggest that this may be as a result of sexual dimorphism as a result of the differences found on the shape of the obturator foramen. This finding supports the usage of different instruments in procedures for the treatment of SUI between males and females.

### **5.3. Clinical applications**

#### **5.2.1. Obturator nerve block**

Obturator nerve blocks are used in the performance of knee surgery, hip surgery and in gynaecologic and urologic procedures, such as transurethral resection procedures

(Gasparich *et al.*, 1984, Vloka and Hadić, 1999, Kakinohana *et al.*, 2002, McNamee *et al.*, 2002). The blocks inhibit spasms of the adductor group and sensory innervation to the medial thigh. Kendir *et al.* (2008) emphasise the importance of clear knowledge of the anatomy of the obturator nerve and its branches in the success of obturator nerve blocks. The researchers report that knowledge of the relationship between the obturator nerve and its branches to surrounding structures will assist in the prevention of complications during obturator nerve block.

This is highlighted by several studies that have reported that the nerve blocks may assist in post-operative analgesia in patients that have undergone knee surgery; in combination with other blocks (McNamee *et al.*, 2002, Choquet *et al.*, 2005, Simeoforidou *et al.*, 2013).

The interadductor approach to obturator nerve blocks has been suggested to be easier and have less complications than the traditional approach (Wassef, 1993, Kakinohana *et al.*, 2002). The observations of the anatomy of the obturator area, with regard to the course of the obturator nerve between the muscles and its innervation and branching patterns, validate that the interadductor approach could be a better alternative. The obturator vessels were not observed to accompany the nerve as it coursed in the medial thigh. Instead, the pelvic branch of the obturator artery leaves the pelvis through the obturator canal to remain on the pelvic surface of the pubic bone (Moore *et al.*, 2013). The adductor muscles were observed to be supplied by the femoral blood vessels. Inserting the needles posterior to the adductor longus muscle will assist in avoiding muscular and vascular injury, as the only identified structure coursing in the area was the anterior branch of the obturator nerve.

Using this approach, clinicians may be able to anaesthetise the medial thigh by blocking the anterior branch of the obturator nerve in that plane. Further insertion of the needle would alternatively allow direct blocking of both the anterior and posterior branches of the obturator nerve.

Caution should be taken when advancing the needles in an attempt to block the anterior and posterior branches simultaneously, as the bifurcation location of the obturator nerve is variable and incomplete anaesthesia might be experienced if these

variations are not taken into consideration. The current study found the obturator nerve bifurcating within the obturator canal in 93% of the observations. It is recommended that the needle be angled posteriorly as it nears the obturator canal. According to the results, the likelihood of successfully blocking both branches will then increase.

### **5.2.2. Pelvic lymphadenectomy**

The anatomy of the lateral pelvic wall is important when performing a lymphadenectomy. Several studies have questioned whether the benefits of pelvic lymphadenectomy outweigh the complications associated with it (Kawakami *et al.*, 2006, Loeb *et al.*, 2010). The authors reported that the obturator nerve is the most commonly injured nerve during lymphadenectomy procedures. It was suggested in the studies that the injury was either by resection or crushing of the obturator nerve. The close relationship of the obturator nerve to different vessels in the pelvis places it in danger during pelvic surgery (Cardosi *et al.*, 2002).

### **5.2.3. Transobturator procedures**

SUI is a condition whereby individuals have lost the ability to retain urine within the bladder when the intra-abdominal pressure is increased, e.g. during coughing or climbing stairs. The insertion of slings around the mid-urethra has assisted in the management of this condition. The performance of these procedures invade the area of the obturator foramen through the insertion of standardised helical needles through the foramen. The results of this study for the location of the obturator nerve within the obturator foramen will assist in the safe performance of these procedures, giving surgeons “coordinates” on the approximate location of the nerve in the foramen in a South African population group. Using palpable bony landmarks of the obturator foramen to determine the trajectory of the needles will allow for the safe performance of these procedures.

In a study by Bierry *et al.* (2010), it was found that sexual dimorphism exists in the shape of the obturator foramen. The authors reported that the foramen was more oval in males and triangular in females.

Analysis of the results indicated that the obturator nerve was closest to the superior point of the obturator foramen, followed by the most medial point, with the most inferior point being the furthest away. This description offers a potential safe area of penetration of the needles between the most medial and most inferior points of the obturator foramen. Tshabalala *et al.* (2013) arrived at the same conclusion using the distances from the mid-urethral slings to the branches of the obturator nerve. The researchers found that passing the needles superior to the most medial point of the obturator foramen placed the mesh closer to the obturator nerve and its branches. In one case, it was reported that the mesh went through the obturator canal in a male specimen that received the TOT inside-out procedure.



## **Chapter 6 – Conclusion**

### **6.1. Obturator nerve anatomy**

This study served to assist in the clear description of the obturator nerve from its origin at the lumbar vertebra, its course in the abdomen and pelvis, until its termination in the medial compartment of the thigh. The results show that there are some noteworthy variations with regard to the course of the obturator nerve. These include the prevalence of variation of the root values of the obturator nerve in the lumbar area and the bifurcation of the obturator nerve into its terminal branches at the level of the obturator foramen. This included the variations of the innervation of the anterior and posterior branches of the obturator nerve in the medial compartment of the thigh. This information may be useful in the teaching of the anatomy of the obturator nerve in medical schools. These variations have not been widely studied, especially in a South African context, and the results of this study could provide surgeons and clinicians with a better understanding of the anatomy of this region.

### **6.2. Location of the obturator nerve within the obturator foramen**

The study validates the need to use different methods in the treatment of SUI for males and females. Procedures for the treatment of SUI, for both males and females, performed in the vicinity of the most medial and most inferior points of the obturator foramen will contribute to the success of surgical procedures requiring a pathway through the obturator foramen. The measurements may, also, assist in the description of the position of the obturator nerve of the obturator foramen in a South African population.

### **6.3. Clinical applications of results**

The description of the anatomy of the obturator nerve and the quantification of its location in the obturator foramen will assist surgeons in performing safe procedures in the vicinity of the obturator foramen. This is especially true within a South African

clinical setting. Accurate knowledge of the anatomy and any possible variations that may occur is imperative for clinicians and surgeons.

The understanding of the innervation patterns of the anterior and posterior branches of the obturator nerve in the medial thigh will benefit anaesthesiologists to successfully perform obturator nerve blocks. The results reported in this study on the anatomy of the obturator nerve and its branches will help guide clinicians during pre-operative preparation and decrease the possibility of complications. Clinicians should familiarise themselves with the prevalence of variations of the innervation patterns of the anterior and posterior branches to rule out the possibility of incomplete anaesthesia.

To avoid damage to the obturator nerve in procedures that pass through the obturator foramen, the most medial and most inferior points of the obturator foramen are the safest points to use. These being the furthest points from the nerve. Using the area between the most medial and most inferior points is most ideal.

The results should be verified in a clinical setting to validate their practical use, possibly allowing refinement of procedural guidelines.

## References

- ACHTARI, C., MCKENZIE, B. J., HISCOCK, R., ROSAMILIA, A., SCHIERLITZ, L., BRIGGS, C. A. & DWYER, P. L. 2006. Anatomical study of the obturator foramen and dorsal nerve of the clitoris and their relationship to minimally invasive slings. *International Urogynecology Journal*, 17, 330-334.
- AGUR, A. M. & DALLEY, A. F. 2009. *Grant's atlas of anatomy*, Lippincott Williams & Wilkins.
- AKATA, T., MURAKAMI, J. & YOSHINAGA, A. 1999. Life-threatening haemorrhage following obturator artery injury during transurethral bladder surgery: a sequel of an unsuccessful obturator nerve block. *Acta anaesthesiologica scandinavica*, 43, 784-788.
- AKKAYA, T., COMERT, A., KENDIR, S., ACAR, H., GUMUS, H., TEKDEMIR, I. & ELHAN, A. 2008. Detailed anatomy of accessory obturator nerve blockade. *Minerva anesthesiologica*, 74, 119-122.
- ANAGNOSTOPOULOU, S., KOSTOPANAGIOTOU, G., PARASKEUOPOULOS, T., CHANTZI, C., LOLIS, E. & SARANTEAS, T. 2009. Anatomic variations of the obturator nerve in the inguinal region: implications in conventional and ultrasound regional anesthesia techniques. *Regional anesthesia and pain medicine*, 34, 33-39.
- ANLOAGUE, P. A. & HUIJBREGTS, P. 2009. Anatomical variations of the lumbar plexus: a descriptive anatomy study with proposed clinical implications. *Journal of Manual & Manipulative Therapy*, 17, 107E-114E.
- ARORA, D., KAUSHAL, S. & SINGH, G. 2014. VARIATIONS OF LUMBAR PLEXUS IN 30 ADULT HUMAN CADAVERS-A UNILATERAL PREFIXED PLEXUS.
- ATES, S. & TULANDI, T. 2013. Malpractice claims and avoidance of complications in endoscopic surgery. *Best Practice & Research Clinical Obstetrics & Gynaecology*, 27, 349-361.
- AUGSPURGER, R. & DONOHUE, R. 1980. Prevention of obturator nerve stimulation during transurethral surgery. *The Journal of urology*, 123, 170-172.
- BALL, M. W., GORIN, M. A. & ALLAF, M. E. 2013. Reducing morbidity of pelvic and retroperitoneal lymphadenectomy. *Current urology reports*, 14, 488-495.
- BAUER, R. M., MAYER, M. E., MAY, F., GRATZKE, C., BUCHNER, A., SOLJANIK, I., BASTIAN, P. J., STIEF, C. G. & GOZZI, C. 2010. Complications of the AdVance transobturator male sling in the treatment of male stress urinary incontinence. *Urology*, 75, 1494-1498.
- BENEŠ, J. 1999. Immediate grafting of the damaged obturator nerve by gynaecological surgery. *Acta neurochirurgica*, 141, 435-436.
- BIERRY, G., LE MINOR, J. M. & SCHMITTBUHL, M. 2010. Oval in males and triangular in females? A quantitative evaluation of sexual dimorphism in the human obturator foramen. *American journal of physical anthropology*, 141, 626-631.
- BONNET, P., WALTREGNY, D., REUL, O. & DE LEVAL, J. 2005. Transobturator vaginal tape inside out for the surgical treatment of female stress urinary incontinence: anatomical considerations. *The Journal of urology*, 173, 1223-1228.

- BOUAZIZ, H., VIAL, F., JOCHUM, D., MACALOU, D., HECK, M., MEURET, P., BRAUN, M. & LAXENAIRE, M.-C. 2002. An evaluation of the cutaneous distribution after obturator nerve block. *Anesthesia & Analgesia*, 94, 445-449.
- BOYLES, S. H., EDWARDS, R., GREGORY, W. & CLARK, A. 2007. Complications associated with transobturator sling procedures. *International Urogynecology Journal*, 18, 19-22.
- BRADSHAW, C., MCCRORY, P., BELL, S. & BRUKNER, P. 1997. Obturator Nerve Entrapment A Cause of Groin Pain in Athletes. *The American journal of sports medicine*, 25, 402-408.
- BRIGANTI, A., CHUN, F. K.-H., SALONIA, A., SUARDI, N., GALLINA, A., DA POZZO, L. F., ROSCIGNO, M., ZANNI, G., VALIQUETTE, L. & RIGATTI, P. 2006. Complications and other surgical outcomes associated with extended pelvic lymphadenectomy in men with localized prostate cancer. *European urology*, 50, 1006-1013.
- CARDOSI, R. J., COX, C. S. & HOFFMAN, M. S. 2002. Postoperative neuropathies after major pelvic surgery. *Obstetrics & Gynecology*, 100, 240-244.
- CHOQUET, O., CAPDEVILA, X., BENNOURINE, K., FEUGEAS, J.-L., BRINGUIER-BRANCHEREAU, S. & MANELLI, J.-C. 2005. A New Inguinal Approach for the Obturator Nerve Block Anatomical and Randomized Clinical Studies. *The Journal of the American Society of Anesthesiologists*, 103, 1238-1245-1238-1245.
- COSTA, P. & DELMAS, V. 2004. Trans-obturator-tape procedure-'inside out or outside in': Current concepts and evidence base. *Current opinion in urology*, 14, 313-315.
- DE LEVAL, J. 2003. Novel surgical technique for the treatment of female stress urinary incontinence: transobturator vaginal tape inside-out. *European urology*, 44, 724-730.
- DE LEVAL, J. & WALTREGNY, D. 2008. The inside-out trans-obturator sling: a novel surgical technique for the treatment of male urinary incontinence. *European urology*, 54, 1051-1065.
- GASPARICH, J., MASON, J. & BERGER, R. 1984. Use of nerve stimulator for simple and accurate obturator nerve block before transurethral resection. *The Journal of urology*, 132, 291-293.
- GHAEMMAGHAMI, F., BEHNAMFAR, F. & SABERI, H. 2009. Immediate grafting of transected obturator nerve during radical hysterectomy. *International Journal of Surgery*, 7, 168-169.
- GOZZI, C., BECKER, A. J., BAUER, R. & BASTIAN, P. J. 2008. Early results of transobturator sling suspension for male urinary incontinence following radical prostatectomy. *European urology*, 54, 960-961.
- GUILLONEAU, B., ROZET, F., CATHELIN, X., LAY, F., BARRET, E., DOUBLET, J.-D., BAUMERT, H. & VALLANCIEN, G. 2002. Perioperative complications of laparoscopic radical prostatectomy: the Montsouris 3-year experience. *The Journal of urology*, 167, 51-56.
- HAZEWINKEL, M. H., HINOUL, P. & ROOVERS, J.-P. 2009. Persistent groin pain following a trans-obturator sling procedure for stress urinary incontinence: a diagnostic and therapeutic challenge. *International Urogynecology Journal*, 20, 363-365.
- HEIDENREICH, A., OHLMANN, C. H. & POLYAKOV, S. 2007. Anatomical extent of pelvic lymphadenectomy in patients undergoing radical prostatectomy. *European urology*, 52, 29-37.

- HINOUL, P., VANORMELINGEN, L., ROOVERS, J.-P., DE JONGE, E. & SMAJDA, S. 2007. Anatomical variability in the trajectory of the inside-out transobturator vaginal tape technique (TVT-O). *International Urogynecology Journal*, 18, 1201-1206.
- HORWITZ, M. T. 1939. The anatomy of (a) the lumbosacral nerve plexus—its relation to variations of vertebral segmentation, and (b), the posterior sacral nerve plexus. *The Anatomical Record*, 74, 91-107.
- HRADEC, E., SOUKUP, F., NOVAK, J. & BURES, E. 1982. The obturator nerve block. Preventing damage of the bladder wall during transurethral surgery. *International urology and nephrology*, 15, 149-153.
- JUANG, C.-M., YU, K.-J., CHOU, P., YEN, M.-S., TWU, N.-F., HORNG, H.-C. & HSU, W.-L. 2007. Efficacy analysis of trans-obturator tension-free vaginal tape (TVT-O) plus modified Ingelman-Sundberg procedure versus TVT-O alone in the treatment of mixed urinary incontinence: a randomized study. *European urology*, 51, 1671-1679.
- KAELIN-GAMBIRASIO, I., JACOB, S., BOULVAIN, M., DUBUISSON, J.-B. & DÄLLENBACH, P. 2009. Complications associated with transobturator sling procedures: analysis of 233 consecutive cases with a 27 months follow-up. *BMC women's health*, 9, 28.
- KAKINOHANA, M., TAIRA, Y., SAITOH, T., HASEGAWA, A., GAKIYA, M. & SUGAHARA, K. 2002. Interadductor approach to obturator nerve block for transurethral resection procedure: comparison with traditional approach. *Journal of anesthesia*, 16, 123-126.
- KATRITSIS, E., ANAGNOSTOPOULOU, S. & PAPADOPOULOS, N. 1979. Anatomical observations on the accessory obturator nerve (based on 1000 specimens). *Anatomischer Anzeiger*, 148, 440-445.
- KAWAKAMI, J., MENG, M. V., SADETSKY, N., LATINI, D. M., DUCHANE, J., CARROLL, P. R. & INVESTIGATORS, C. 2006. Changing patterns of pelvic lymphadenectomy for prostate cancer: results from CaPSURE™. *The Journal of urology*, 176, 1382-1386.
- KENDIR, S., AKKAYA, T., COMERT, A., SAYIN, M., TATLISUMAK, E., ELHAN, A. & TEKDEMIR, I. 2008. The location of the obturator nerve: a three-dimensional description of the obturator canal. *Surgical and Radiologic Anatomy*, 30, 495-501.
- KHORRAMI, M. H., JAVID, A., SARYAZDI, H. & JAVID, M. 2010. Transvesical blockade of the obturator nerve to prevent adductor contraction in transurethral bladder surgery. *Journal of Endourology*, 24, 1651-1654.
- KIRCHMAIR, L., LIRK, P., COLVIN, J., MITTERSCHIFFTHALER, G. & MORIGGL, B. 2008. Lumbar plexus and psoas major muscle: not always as expected. *Regional anesthesia and pain medicine*, 33, 109-114.
- KITAGAWA, R., KIM, D., REID, N. & KLINE, D. 2009. Surgical management of obturator nerve lesions. *Neurosurgery*, 65, A24-A28.
- LABAT, G. 1922. *Regional anesthesia: its technic and clinical application*, WB Saunders.
- LANG, S. A., YIP, R. W., CHANG, P. C. & GERARD, M. A. 1993. The femoral 3-in-1 block revisited. *Journal of clinical anesthesia*, 5, 292-296.
- LOEB, S., PARTIN, A. W. & SCHAEFFER, E. M. 2010. Complications of pelvic lymphadenectomy: do the risks outweigh the benefits? *Reviews in urology*, 12, 20.

- MCNAMEE, D., PARKS, L. & MILLIGAN, K. 2002. Post-operative analgesia following total knee replacement: an evaluation of the addition of an obturator nerve block to combined femoral and sciatic nerve block. *Acta anaesthesiologica scandinavica*, 46, 95-99.
- MOORE, D. 1979. Regional anesthesia. Springfield, IL, Charles C. Thomas Publishers.
- MOORE, K. L., DALLEY, A. F. & AGUR, A. M. 2013. *Clinically oriented anatomy*, Wolters Kluwer Health.
- MORRIS, G. F. & LANG, S. A. 1999. Innovations in lower extremity blockade. *Techniques in Regional Anesthesia and Pain Management*, 3, 9-18.
- PAVLOVICH, C. P., GORIN, M. A., PIERORAZIO, P. M. & MULLINS, J. K. 2015. Pelvic Lymphadenectomy for Prostate and Bladder Cancer. *Pelvic Cancer Surgery*. Springer.
- POSSOVER, M., KRAUSE, N., PLAUL, K., KÜHNE-HEID, R. & SCHNEIDER, A. 1998. Laparoscopic para-aortic and pelvic lymphadenectomy: experience with 150 patients and review of the literature. *Gynecologic oncology*, 71, 19-28.
- REHDER, P. & GOZZI, C. 2007. Transobturator sling suspension for male urinary incontinence including post-radical prostatectomy. *European urology*, 52, 860-867.
- RICCIARDI, E., JAKIMOVSKA, M., MANIGLIO, P., SCHIMBERNI, M., FREGA, A., KOBAL, B. & MOSCARINI, M. 2012. Laparoscopic injury of the obturator nerve during fertility-sparing procedure for cervical cancer. *World journal of surgical oncology*, 10, 1-3.
- RIDGEWAY, B. M., ARIAS, B. E. & BARBER, M. D. 2008. Variation of the obturator foramen and pubic arch of the female bony pelvis. *American journal of obstetrics and gynecology*, 198, 546. e1-546. e4.
- SHAH, D. J., ANDI, A. C., RAMESAR, K. & GILLIAN WATSON, M. 2013. Adductor Muscle Atrophy Due to Obturator Nerve Compression by Metastatic Lymph Node Enlargement—A Rare Complication of Recurrent Bladder Cancer. *OMICS Journal of Radiology*.
- SILISKI, J. M. & SCOTT, R. 1985. Obturator-nerve palsy resulting from intrapelvic extrusion of cement during total hip replacement. Report of four cases. *JBJS Case Connector*, 1225-1228.
- SIMEOFORIDOU, M., BAREKA, M., BASDEKIS, G., TSIKA, K., CHANTZI, E. & VRETZAKIS, G. 2013. Peripheral nerve blockade as an exclusive approach to obturator nerve block in anterior cruciate ligament reconstructive surgery. *Korean journal of anesthesiology*, 65, 410-417.
- SINHA, S. K., ABRAMS, J. H., HOULE, T. T. & WELLER, R. S. 2009. Ultrasound-guided obturator nerve block: an interfascial injection approach without nerve stimulation. *Regional anesthesia and pain medicine*, 34, 261-264.
- SOONG, J., SCHAFHALTER-ZOPPOTH, I. & GRAY, A. T. 2007. Sonographic imaging of the obturator nerve for regional block. *Regional anesthesia and pain medicine*, 32, 146-151.
- SPALIVIERO, M., STEINBERG, A. P., KAOUK, J. H., DESAI, M. M., HAMMERT, W. C. & GILL, I. S. 2004. Laparoscopic injury and repair of obturator nerve during radical prostatectomy. *Urology*, 64, 1030.
- SPINOSA, J. P., DUBUIS, P. Y. & RIEDERER, B. M. 2007. Transobturator surgery for female stress incontinence: a comparative anatomical study of outside-in vs inside-out techniques. *BJU international*, 100, 1097-1102.

- TIPTON, J. S. 2008. Obturator neuropathy. *Current reviews in musculoskeletal medicine*, 1, 234-237.
- TSHABALALA, Z., HUMAN-BARON, R. & VAN DER WALT, S. 2013. *Obturator nerve anatomy in relation to selected perineal surgical procedures*. BSc(Honours) dissertation, University of Pretoria, Pretoria, South africa.
- TUBBS, R. S., SALTER, E. G., WELLONS III, J. C., BLOUNT, J. P. & OAKES, W. J. 2005. Anatomical landmarks for the lumbar plexus on the posterior abdominal wall. *Journal of Neurosurgery: Spine*, 2, 335-338.
- ULMSTEN, U., FALCONER, C., JOHNSON, P., JOMAA, M., LANNER, L., NILSSON, C. & OLSSON, I. 1998. A multicenter study of tension-free vaginal tape (TVT) for surgical treatment of stress urinary incontinence. *International Urogynecology Journal*, 9, 210-213.
- ULMSTEN, U., HENRIKSSON, L., JOHNSON, P. & VARHOS, G. 1996. An ambulatory surgical procedure under local anesthesia for treatment of female urinary incontinence. *International Urogynecology Journal*, 7, 81-86.
- VANDANA, M., SURI, R., RAVI, S., VANDANA, D. & GAYATRI, R. 2011. Clinical submission of supernumerary head of adductor brevis muscle. *Journal of Surgical Academia*, 1, 78-81.
- VLOKA, J. D. & HADIĆ, A. 1999. Obturator and genitofemoral nerve blocks. *Techniques in Regional Anesthesia and Pain Management*, 3, 28-32.
- WANG, W., ZHU, L. & LANG, J. 2009. Transobturator tape procedure versus tension-free vaginal tape for treatment of stress urinary incontinence. *International Journal of Gynecology & Obstetrics*, 104, 113-116.
- WASSEF, M. 1993. Interadductor approach to obturator nerve blockade for spastic conditions of adductor thigh muscles. *Regional Anesthesia and Pain Medicine*, 18, 13-17.
- WHITESIDE, J. L. & WALTERS, M. D. 2004. Anatomy of the obturator region: relations to a trans-obturator sling. *International Urogynecology Journal*, 15, 223-226.
- WON, H.-S., KIM, J.-H., LEE, U.-Y., RHA, K. H. & KIM, D. K. 2015. Topographical relationships between the obturator nerve, artery, and vein in the lateral pelvic wall. *International urogynecology journal*, 1-6.