

## STUDIES ON THE PHYSIOPATHOLOGY OF CHRONIC OBSTRUCTIVE PULMONARY DISEASE IN THE HORSE. VIII. MEAN MODAL VECTORS OF THE P WAVE AND THE QRS COMPLEX

A. LITTLEJOHN, C. BUTTON and FELICITY BOWLES, Faculty of Veterinary Science, University of Pretoria, Onderstepoort 0110

### ABSTRACT

LITTLEJOHN, A., BUTTON, C. & BOWLES, FELICITY, 1983. Studies on the physiopathology of chronic obstructive pulmonary disease in the horse. VIII. Mean modal vectors of the P wave and the QRS complex. *Onderstepoort Journal of Veterinary Research*, 50, 119-124 (1983).

Mean modal vectors of P<sub>1</sub>, P<sub>2</sub> and QRS were determined in the 3 planes of a semi-orthogonal EKG lead system in 17 horses and ponies with chronic obstructive pulmonary disease (COPD) and in 17 clinically normal horses and ponies. Subjects were paired so that the heart rates of each pair were not dissimilar by more than 2 cycles per minute.

Probably significant differences were observed between the mean angles of P<sub>1</sub> vectors in the transverse and sagittal planes (T plane, normal = 324° ± 24.6°, COPD = 342° ± 21.0°, t = 2.0, P < 0.05; S plane, normal = 331° ± 22.6°, COPD = 348° ± 16.2°, t = 2.52, P < 0.02).

There were no significant differences between the mean angles of planar modal QRS vectors of normal subjects and those of COPD subjects.

### INTRODUCTION

In the dog, as in man, the salient features of the EKG which are associated with cor pulmonale are well recognized (Ettinger & Suter, 1970). These features are:

- (a) A tall, peaked p wave known as P pulmonale in both canine and human medicine (Ettinger & Suter, 1970).
- (b) Depression of the P-R segment, known as a Ta wave. This wave form is associated with right atrial enlargement and often occurs in association with P pulmonale (Ettinger & Suter, 1970).
- (c) Deviation of the mean QRS electrical axis to the right, in the frontal plane (Hamlin, 1968).

Correlations between heart chamber enlargements and specific features of the EKG in horses do not appear to have been made prior to the studies of Holmes (1976) in 190 horses. There seems little doubt that this was due to the inadequacy of the Einthoven lead system to portray the nature of the changes produced in the equine cardiac electrical field (Holmes & Darke, 1970; Holmes & Else, 1972).

While there was general agreement that the Einthoven lead system was adequate for the diagnosis of cardiac arrhythmias (Holmes, 1974), a number of authors noted the disadvantages of the system for vectorcardiography in horses. The great variations in horizontal plane modal QRS vectors derived from Einthoven limb leads were commented on by Van Zijl (1951), Holmes & Alps (1967) and Holmes & Else (1972). Variations in the configuration of the QRS complex were also caused by minor changes in subject forelimb positioning (Brooimans, 1957; Steel, 1963; Holmes & Darke, 1970).

Evidence that the Einthoven lead system gave an inaccurate orientation of VCG loops in the horizontal plane was provided by Holmes & Darke (1970). The true orientation of vectorcardiographic (VCG) loops for the QRS complex in horizontal and transverse planes was forward, upward and, in most horses, leftward; VCG loops in the horizontal plane derived from Einthoven limb leads, however, were orientated backwards and to the left (Holmes & Darke, 1970). The results of the above authors' investigations were supported by the results of studies of the ventricular activation process in horses by Muylle & Oyaert (1975a). The reason why the Einthoven bipolar limb lead system misrepresented the nature of the cardiac electrical field in the horse was identified by Holmes & Else (1972) as a greater degree of positivity at the root of the hindlimbs than at the root of the forelimbs.

The semi-orthogonal lead system developed by Holmes & Darke (1970) and Holmes & Else (1972) therefore appeared to provide a more accurate portrayal of cardiac electrical forces than did the Einthoven limb lead system. Subsequent studies by Holmes (1976) on a series of 190 horses indicated that the semi-orthogonal system devised by Holmes & Darke (1970) and Holmes & Else (1972) should be of value in the diagnosis of heart chamber enlargement in the horse. Studies by Button (1976) confirmed the validity of conclusions reached by Holmes & Else (1972) and established basic parameters for wave forms and electrocardiographic intervals measured on the X, Y and Z leads of the semi-orthogonal system.

Electrocardiographic features which Holmes (1976) suggested may be indicative of right ventricular hypertrophy were predominantly anteriorly directed QRS vectors in lead Y. In a study of 190 horses, Holmes (1976) was able to show that in horses in which the maximum backward spatial vector was less than 20 per cent of the magnitude of the maximum forward spatial vector, there was a significantly higher incidence of respiratory disorders. The respiratory disorders were not specified. Holmes (1976) suggested that conditions leading to right ventricular enlargement may result in predominance of anteriorly directed resultant vectors (right ventricular) over left ventricular forces. The Y (sagittal plane) lead of the semi-orthogonal system was considered by Holmes (1976) to be particularly important because it measured the backward or forward activation and appeared to have a relationship to left or right ventricular predominance respectively. A prominent R wave in lead Y therefore indicated backwardly directed (left ventricular) vectors, whereas an entirely negative wave form (QS wave) indicated forwardly directed (right ventricular) spatial vectors. No vectorcardiographic studies on horses with COPD confirmed at autopsy have been reported, although Holmes (1976) suggested pulmonary emphysema as a possible cause of S wave predominance.

The objects of the present studies in normal horses, and in horses with chronic obstructive pulmonary disease (COPD) were to determine the mean modal vectors of the P<sub>1</sub> and P<sub>2</sub> phases of the P wave and the mean modal QRS vectors in the 3 planes of the S-O system, and compare the results statistically.

### MATERIALS AND METHODS

#### Subjects

Seventeen normal subjects and seventeen COPD subjects of the series described by Littlejohn (1980) were used for vectorcardiographic studies. The subjects were paired so that heart rates of each pair were not dissimilar by more than two cycles per minute.

### Recording system

The Mingograf-81 Recording System was used for all EKG's. Three of the 5 jet galvanometers of this physiological recording system provided simultaneous ink tracings from 3 EKG leads. The input impedance of the EKG modular system was 100 megohm, the frequency response was from 0–500 hz and the common mode rejection factor was 15 000:1. Paper speeds up to 100 mm per second were available. The above specifications (as published by Elema-Schönander) satisfy the criteria considered by Steel & Stewart (1974) to be necessary for recording equine EKG's of a quality satisfactory for research or clinical purposes.

### Semi-orthogonal (S-O) leads and electrodes

S-O leads were similar to those described by Holmes & Darke (1970) and Holmes & Else (1972). Six lengths of 5 m each of 30 gauge screened flex were used to provide 3 pairs of cables giving positive and negative connections for leads X, Y and Z.

S-O lead electrodes were atraumatic crocodile clips. These were also used for X-lead electrodes instead of the lead-alloy sheets recommended by Holmes & Else (1972). X-lead electrodes were placed on the forelimbs as suggested by Hamlin, Smetzer & Smith (1964).

Most horses tolerated the application of the crocodile clips very well since care was taken to attach them slowly to skin folds. However, 2 subjects required subcutaneous injections of 0.5 ml lignocaine before they tolerated application of the clips.

A drop of Elema-Schönander electrode cream was used to moisten the skin surface at sites of electrode application.

### Procedure

The S-O lead system was connected to the Mingograf-81 and the 6 electrodes of this S-O system were placed in site on the subject at the following points:

- X<sup>+</sup> 1 cm above the point of the left olecranon
- X<sup>-</sup> as above, on the right side
- Y<sup>+</sup> the xiphoid area in the midline
- Y<sup>-</sup> the cariniform cartilage of the sternum area in the midline

Z<sup>+</sup> the withers

Z<sup>-</sup> The medial surface of the left forelimb 3–4 cm below the point of the olecranon

Care was taken to avoid dampness on all equipment and on the subject. Damp or dirty equipment, excessive use or spillage of electrode cream or faulty earthing were the most common causes of 50 cycle A-C current interference during recordings. The rubber mat and hooves of subjects were kept dry, and equipment was carefully cleaned and dried to eliminate 50 cycle A-C interference as much as possible. Tracings of leads X, Y and Z were then recorded.

Three consecutive electrocardiographic complexes of good quality were chosen from those made at a paper speed of 100 mm/sec, and the major deflections of the wave forms were noted according to the terminology of Detweiler & Patterson (1972).

The angles of mean modal vectors were calculated for the P<sub>1</sub> and P<sub>2</sub> waves and for the QRS complex in the horizontal, sagittal and transverse planes of the S-O lead system as described by Holmes & Else (1972).

The backward QRS vector as a percentage of the forward QRS vector on lead Y was calculated. Holmes (1976) proposed that this percentage may be of diagnostic significance in cases of ventricular enlargement in the horse, since the shape and position of the equine heart suggested that forward and backward vectors of the QRS complex represented forces of depolarization in right and left ventricles respectively.

Atrial pressure was measured in all subjects as described by Littlejohn & Bowles (1980).

### RESULTS

Tracings of the semi-orthogonal leads X, Y and Z of the EKG are shown in Fig. 1.

#### The P wave

The P wave was bifid and positive in leads X and Y and bifid negative or isoelectric in lead Z. The 2 components of the P wave were designated P<sub>1</sub> and P<sub>2</sub>, representing respectively the 1st and 2nd P wave deflections (Muyile & Oyaert, 1975b).




FIG. 1 Tracings of the semi-orthogonal leads X, Y and Z of the EKG of subject E5

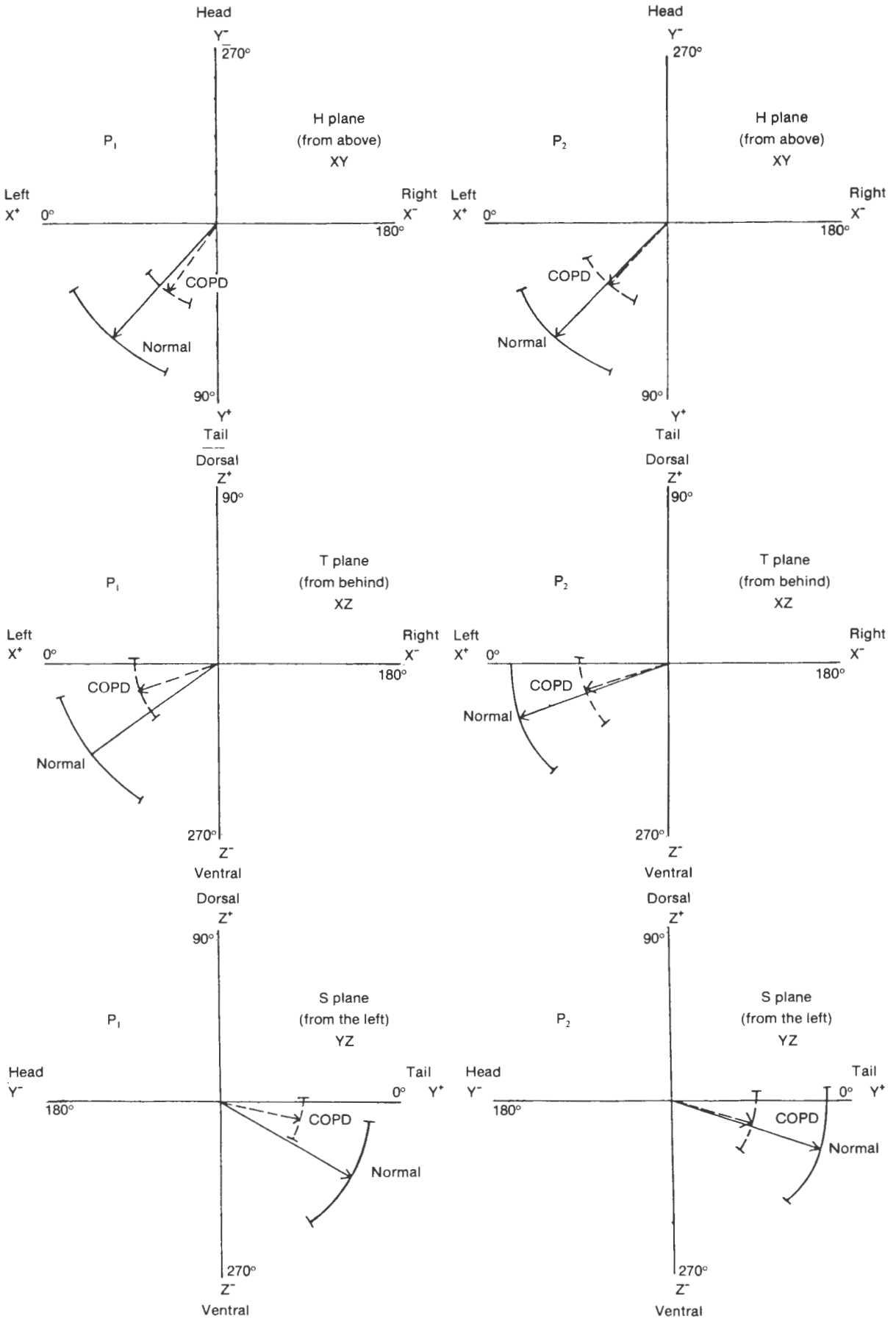


FIG. 2 Directions of  $P_1$  and  $P_2$  vectors in horizontal, transverse and sagittal planes of the S-O lead system. Arcs represent standard deviations.



No significant differences were detected between the mean amplitudes of  $P_1$  and  $P_2$  in normal subjects and those of COPD subjects. The mean amplitudes in millivolts and the standard deviations for  $P_1$  were as follows: X lead, normal =  $+0,12 \pm 0,07$ , COPD =  $+0,14 \pm 0,07$ ; Y lead normal =  $+0,14 \pm 0,07$ . COPD =  $+0,15 \pm 0,05$ ; Z lead, normal =  $-0,08 \pm 0,05$ , COPD =  $-0,05 \pm 0,05$ .

The mean amplitudes and standard deviations for  $P_2$  were as follows: X lead, normal =  $+0,33 \pm 0,15$ , COPD =  $+0,31 \pm 0,12$ ; Y lead, normal =  $+0,36 \pm 0,13$ , COPD =  $+0,33$ ; Z lead, normal =  $-0,12 \pm 0,08$ , COPD =  $-0,10 \pm 0,09$ .

The mean angles of modal  $P_1$  and  $P_2$  vectors in the horizontal, transverse and sagittal planes are illustrated in Fig. 2.

Probably significant differences were observed between the mean angles of  $P_1$  vectors in the transverse and sagittal planes (T plane, normal =  $324^\circ \pm 24,6^\circ$ , COPD =  $342^\circ \pm 21,0^\circ$ ,  $t = 2,0$   $P < 0,05$ ; S plane, normal =  $331^\circ \pm 22,6^\circ$ , COPD =  $348^\circ \pm 16,2^\circ$ ,  $t = 2,52$ ,  $P < 0,02$ ).

The difference between the mean angles of  $P_1$  vectors in the horizontal plane was not significant (normal  $47^\circ \pm 22,0^\circ$ , COPD =  $53^\circ \pm 19,3^\circ$ ,  $t = 0,78$ ).

No significant differences were observed between the mean angles of the  $P_2$  vectors of normal and COPD subjects in any of the 3 planes of the semiorthogonal.

*The QRS complex*

The mean angles of planar modal QRS vectors and the standard deviations thereof are illustrated in Fig. 3 a, b & c. The directions of modal QRS vectors in the horizontal (H), transverse (T) and sagittal (S) planes of the semi-orthogonal lead system were very similar to those published by Holmes & Else (1972) and Button (1976). This was true of both normal and COPD subjects and there were no significant differences between the mean angles of planar modal QRS vectors of normal horses and those of COPD horses.

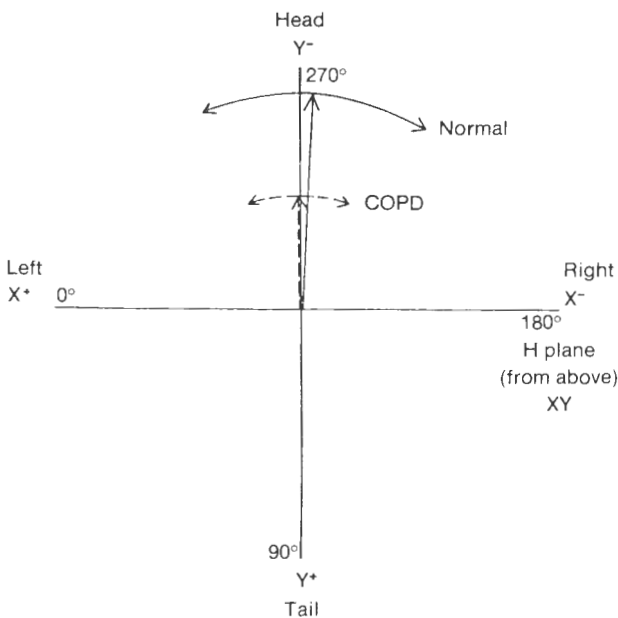


FIG. 3a Mean modal QRS vectors in the semi-orthogonal H plane for 17 normal subjects and 17 COPD subjects. Arcs represent standard deviations.

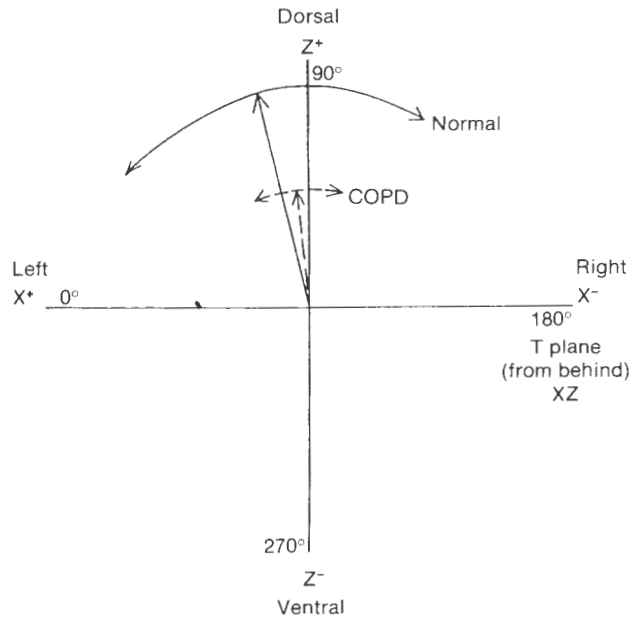


FIG. 3b Mean modal QRS vectors in the semi-orthogonal T plane for 17 normal subjects and 17 COPD subjects. Arcs represent standard deviations.

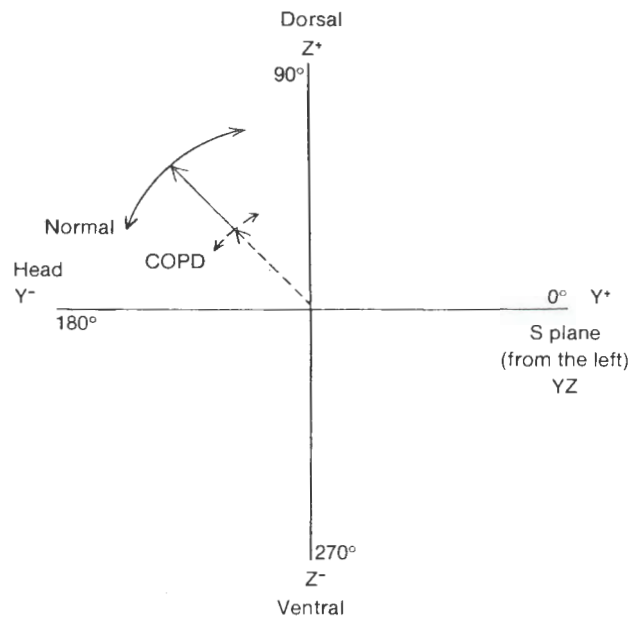


FIG. 3c Mean modal QRS vectors in the semi-orthogonal S plane for 17 normal subjects and 17 COPD subjects. Arcs represent standard deviations.

*The magnitude of the backward QRS vector as a percentage of the magnitude of the forward QRS vector in Y lead tracings*

There was no significant difference in this respect between the mean values calculated for the 2 groups of subjects (Table 1).

DISCUSSION

*The P wave*

Muyllé & Oyaert (1971) reviewed information about the anatomical relationships of the sino-atrial node and the right and left atria of the horse and concluded that the directions of the 2 vectors  $P_1$  and  $P_2$  coincided closely with the anatomical positions of the 2 atria. They noted a definite increase in the amplitude of the  $P_2$  wave in horses with aortic or mitral valve defects. Muyllé & Oyaert (1975b) later investigated atrial activation pathways and body surface EKG's of the Y and Z leads of a semi-orthogonal lead system in horses. They found that

TABLE 1 The magnitude of the backward QRS vector as a percentage of the magnitude of the forward QRS vector in lead Y

	Normal n = 17	COPD n = 17	Difference	Significance
Mean magnitude of the backward QRS vector as a percentage of the magnitude of the forward QRS vector	32,4 ± 32,1	34,7 ± 33,2	2,3	NS

at the moment of the notch between P<sub>1</sub> and P<sub>2</sub> the excitation wave reached the cranial border of the right auricle, the cranioventral border of the right atrium and the cranio-dorsal part of the left atrium. The ascending limb of P<sub>1</sub> was thus the result of cancellation between 3 fronts of activation, viz., a cranially directed front over the right auricle, a caudally directed front over the right atrium and caudally directed activity over the cranial edge of the left atrium.

The directions of vectors P<sub>1</sub> and P<sub>2</sub> in this study were very similar to those ascertained by Muylle & Oyaert (1971) in 180 clinically normal Thoroughbred and Thoroughbred cross horses, and also coincided closely with those illustrated by Button (1976).

In very general terms it can be accepted that P<sub>1</sub> represents mostly right atrial activation, whereas P<sub>2</sub> represents mostly left atrial activation.

The direction of vectors P<sub>1</sub> and P<sub>2</sub> in the present studies as well as in those of Muylle & Oyaert (1971, 1975b) and Button (1976) was backwards, leftwards and downwards.

The probably significant upward rotation of vector P<sub>1</sub> in the transverse and sagittal planes in COPD subjects could possibly be due to dilatation of the right atrium. However, no significant correlations were found between the angle of vectors in T or S planes, and the atrial pressures.

#### The QRS complex

As Holmes (1976) pointed out, electrocardiography in horses has so far failed to provide standards of diagnostic value in heart chamber enlargements. This is not the case in man (Ross, 1962; Schamroth, 1957) or in the dog (Ettinger & Suter, 1970) in which species electrocardiography is accepted as a valuable aid to the diagnosis of ventricular enlargements. The explanation for the failure of equine electrocardiography to provide diagnostic information in this respect lies almost certainly in the very different myocardial activation processes and EKG's in horses compared with those of man and the dog (Hamlin & Smith, 1965; Smith, Hamlin & Crocker, 1965). Insofar as ventricular activation is concerned, Muylle & Oyaert (1975a) concluded that unlike in man and the dog, no regular activation front travelled from the endocardium to the epicardium. According to the above authors who investigated the sequence of activation of the ventricular epicardium, activation of the free ventricular walls of horses starts near the points of insertion of the papillary muscles and is directed from those areas towards the apex and to the base of the heart. The absence of definite fronts of activation, the cancelling effect of receding waves of depolarization and the lack of information regarding the ventricular activation processes in different layers of the equine myocardium (Muylle & Oyaert, 1975a) provide cogent reasons for the difficulties attending the interpretation of equine vectorcardiographic data. The attempt to utilize a semi-orthogonal lead system for this purpose was therefore unproductive in the present series of subjects. However, although the present series failed to provide information of value regarding ventricular depolarization in COPD subjects, the results did suggest that further studies of the P wave may prove rewarding.

#### The magnitude of the backward QRS vector as a percentage of the magnitude of the forward QRS vector in Y lead tracings

Holmes's (1976) data showed that horses in which the maximum backward spatial vector was less than 20% of the maximum forward spatial vector had a significantly higher incidence of respiratory disease than those in which the maximum backward spatial vector was more than 20% of the maximum forward spatial vector. Holmes (1976) suggested that predominantly anteriorly directed vectors may be associated with right ventricular changes, having regard to the predominantly anterior placement of the right ventricle in the thoracic cavity. Holmes (1976), however, did not specify the respiratory problems encountered in his series of 190 horses and they may have included cases other than chronic obstructive pulmonary disease.

The lack of evidence relating anterior vectorial predominance to chronic obstructive pulmonary disease in the present series may be associated with factors such as the small population sample, the altitude at which the EKG examinations were made and the comparatively low grade of pulmonary disability.

#### REFERENCES

- BROOIMANS, A. W. M., 1957. *Electrocardiography in horses and cattle: theoretical and clinical aspects*. Utrecht: Canteleer.
- BUTTON, C., 1976. *Studies on a semi-orthogonal lead system for equine electrocardiography*. M.Med.Vet. Thesis, Pretoria.
- DETWEILER, D. K. & PATTERSON, D. F., 1972. The cardiovascular system. In: CATCOTT, E. J. & SMITHCORS, J. F. (eds). *Equine medicine and surgery*. (2nd edn) Wheaton, Illinois: American Veterinary Publications.
- ETTINGER, S. J. & SUTER, P. F., 1970. *Canine cardiology*. Philadelphia: W. B. Saunders.
- HAMLIN, R. L., SMETZER, D. L. & SMITH, C. R., 1964. Analysis of QRS complex recorded through a semi-orthogonal lead system in the horse. *American Journal of Physiology*, 207, 325-333.
- HAMLIN, R. L. & SMITH, C. R., 1965. Categorization of common domestic mammals based upon their ventricular activation process. *Annals of the New York Academy of Sciences*, 127, 195-203.
- HAMLIN, R. L., 1968. Electrocardiographic detection of ventricular enlargement in the dog. *Journal of the American Veterinary Medical Association*, 153, 1461-1469.
- HOLMES, J. R. & ALPS, B. J., 1967. Studies into equine electrocardiography and vectorcardiography 1. Cardiac electrical forces and the dipole vector theory. *Canadian Journal of Comparative Medicine and Veterinary Science*, 31, 92-102.
- HOLMES, J. R. & DARKE, P. G. G., 1970. Studies on the development of a new lead system for equine electrocardiography. *Equine Veterinary Journal*, 2, 12-21.
- HOLMES, J. R. & ELSE, R. W., 1972. Further studies on a new lead system for equine electrocardiography. *Equine Veterinary Journal*, 4, 81-88.
- HOLMES, J. R., 1974. General discussion on cardiology, haematology and performance. *Journal of the South African Veterinary Association*, 45, p. 302.
- HOLMES, J. R., 1976. Spatial vector changes during ventricular depolarisation using a semi-orthogonal lead system—a study of 190 cases. *Equine Veterinary Journal*, 8, 1-16.
- LITTLEJOHN, A., 1980. Studies on the physiopathology of chronic obstructive pulmonary disease in horses. I. Clinical signs. *Onderstepoort Journal of Veterinary Research*, 47, 159-162.
- LITTLEJOHN, A. & BOWLES, FELICITY, 1980. Studies on the physiopathology of chronic obstructive pulmonary disease in horses. II. Right heart haemodynamics. *Onderstepoort Journal of Veterinary Research*, 47, 187-192.

- MUYLLE, E. & OYAERT, W., 1971. Clinical evaluation of cardiac vectors in the horse. *Equine Veterinary Journal*, 3, 129-138.
- MUYLLE, E. & OYAERT, W., 1975a. Excitation of the ventricular epicardium of the horse. *Zentralblatt für Veterinärmedizin A*, 22, 463-473.
- MUYLLE, E. & OYAERT, W., 1975b. Atrial activation pathways and the P wave in the horse. *Zentralblatt für Veterinärmedizin A*, 22, 474-484.
- ROSS, D. N., 1962. A surgeon's guide to cardiac diagnosis. Part I: The diagnostic approach. p. 60. Berlin: Springer Verlag.
- SCHAMROTH, L., 1957. An introduction to electrocardiography. Oxford: Blackwell.
- SMITH, C. R., HAMLIN, R. L. & CROCKER, H. D., 1965. Comparative electrocardiography. *Annals of the New York Academy of Sciences*, 127, 155-169.
- STEEL, J., 1963. Electrocardiographic studies in horses. Sydney: Australasian Medical Publishing Co.
- STEEL, J. D. & STEWART, G. A., 1974. Electrocardiography of the horse and potential performance ability. *Journal of the South African Veterinary Medical Association*, 45, 263-268.
- VAN ZIJL, W. J., 1951. The electrocardiogram of the normal horse using the techniques of Einthoven and Wilson. *Tijdschrift Diergeneeskunde*, 76, 85-96.