

The anterior loop of the inferior alveolar nerve:  
prevalence and measurement using reformatted  
medical computed tomographic imaging

**Dr G. O. Patterson**

A research report submitted to the University of Pretoria in partial fulfilment of the  
requirements for the degree of

**MChD (Oral Medicine and Periodontics)**

October 2014

## DECLARATION

I, Geoffrey Oswald Patterson, hereby declare that this dissertation is my own work. It is submitted in partial fulfillment of the requirements for the degree of Master of Dentistry in the field of Oral Medicine and Periodontics. It has not been submitted for any other degree at this or any other university.

---

Geoffrey Oswald Patterson

October 2014

## **ACKNOWLEDGEMENTS**

This study was made possible by the Department of Oral Medicine and Periodontics, University of Pretoria.

Professor A W van Zyl, Head of Department Oral Medicine and Periodontics, for his encouragement, guidance and support in the preparation of this dissertation.

## TABLE OF CONTENTS

The anterior loop of the inferior alveolar nerve: prevalence and measurement using reformatted medical computed tomographic imaging.....	i
Declaration.....	ii
Acknowledgements.....	iii
Table of contents.....	iv
Introduction.....	1
Literature Review.....	3
Aim of study.....	8
Research hypothesis.....	9
Materials and Methods.....	10
Measurements.....	12
Statistical analysis.....	15
Results and Discussion.....	16
Conclusions.....	21
References.....	22

## INTRODUCTION

The placement of endosseous dental implants to replace lost teeth has over the decades become an extremely predictable treatment modality, with success rates in excess of 95%<sup>1</sup>. Dental implant placement in the anterior mandible (inter-foraminal area) has become the standard of care for edentulous mandibles<sup>2</sup>. Although it is generally regarded as a safe procedure, there are anatomical risks in the anterior mandible<sup>3</sup>. The most important anatomical risk is the possible damage to the anterior loop of the inferior alveolar nerve (IAN) just before it emerges through the mental foramen<sup>4</sup>.

The terminal portion of the inferior alveolar nerve may pass beyond the anterior rim of the mental foramen, before curving back to exit the mental foramen. The portion of the inferior alveolar nerve anterior to the mental foramen is termed the anterior loop of the inferior alveolar nerve<sup>5</sup>.

Failure to identify the anterior loop of IAN preoperatively may result in iatrogenic damage to the nerve. Damage to the anterior loop will result in mental nerve damage. This may present as anaesthesia, paraesthesia, dyesthesia or even overt pain in the area innervated by the mental nerve<sup>4</sup>. The mental nerve supplies sensation to the labiomental area and gingival tissue up to the mandibular second premolar<sup>6</sup>. Altered sensation in this region may impede the ability to perform routine activities such as eating, speaking, kissing, shaving, applying make-up and even tooth brushing<sup>4</sup>.

The prevalence of the anterior loop varies<sup>7</sup>. In a cadaver study, Bavitz et al<sup>8</sup> found the anterior loop in 11% whereas Rosenquist<sup>9</sup> detected it in 24% of cases. It should be noted that differentiating between the anterior loop and the incisive canal by means of cadaver dissection is extremely challenging<sup>3</sup>. In a study by Kaya et al<sup>10</sup> the anterior loop was detected in 28% of cases using panoramic radiographs. Li et al<sup>11</sup> using spiral CT identified the anterior loop in 83.1% of cases. Parnia et al<sup>3</sup> in a cone beam computed tomographic study identified it in 84% of cases. The large variations in incidence highlight the fact that conventional two dimensional radiological methods are unreliable in identifying the anterior loop.

To avoid injury to the mental nerve, surgeons have advocated varying safety margins from the mental foramen. They have recommended implants be placed 1mm<sup>8</sup>, 4mm<sup>12</sup>, 5mm<sup>13</sup>, 6mm<sup>14</sup> anterior to the mental foramen. Due to these conflicting results, and heterogeneity between studies it was essential to conduct a study of sufficient size and accuracy to formulate recommendations for implant placement in the area of the anterior loop.

## LITERATURE REVIEW

Rehabilitation of an edentulous patient frequently involves the placement of implants in the anterior mandible between the mental foramina (interforaminal). Biomechanical planning often dictates that the most distal implant be placed as close to the mental foramen as possible, in order to reduce the distal cantilever as well as maximising the distance between the anterior and posterior implants. The greater the distance between the anterior and posterior implants, the better the anterior implants can counteract the forces generated on the distal cantilevers of the prosthesis<sup>8</sup>. Dental implant placement in this region may result in various complications. The most significant of which is iatrogenic injury to the third division of the trigeminal nerve. When preparing the osteotomy site, the drill may come into contact with the anterior loop of the inferior alveolar nerve. This will result in a magnitude of events including direct mechanical trauma, neural chemical trauma due to the release of intracellular components and ischemic injury as a result of continued bleeding into the canal. As a result it is likely that injury to the anterior loop of the inferior alveolar nerve incorporates a combination of mechanical, chemical and ischemic events providing a complex therapeutic challenge. In order to avoid such devastating results it is essential that the surgeon have adequate pre-operative planning and a sound knowledge pertaining to the anatomy of the area involved<sup>15</sup>.

To avoid damage to the inferior alveolar neurovascular complex during surgical interventions, various safety margins from the mental foramen have been advocated. Bavitz et al<sup>8</sup>. suggested placing an implant at least 1mm from the anterior rim of the

mental foramen. Kuzmanovic<sup>16</sup> advocated a safety zone of 4mm. The Branemark surgical procedure guide recommends a 5mm safety zone<sup>17</sup>. Even though these general safety margins do exist, the problem relates to the ability of the surgeon to identify the anterior loop preoperatively or even intra-operatively to safely plan his actions, thus avoiding the risk of neurosensory injury.

One way of overcoming this problem is by exposing the mental foramen during implant surgery. This will allow the surgeon to visualise the mental nerve. The safe zone for implant placement is superior to the upper margin of the mental foramen. Placement of implants below this level is however frequently required due to factors such as bone resorption and the demands of the restorative dentist for sufficient vertical space required for the prosthesis. Placing the implant below the level of the mental foramen risks violating the anterior loop. In an attempt to overcome this Greenstein and Tarnow<sup>6</sup> suggested the clinical identification of the anterior loop by means of a periodontal probe. To do this the authors suggested raising a full thickness mucoperiosteal flap to the upper border of the mental foramen. Following which a blunt ended curved probe is used to navigate through the foramen and into the canal. If the distal aspect of the foramen is patent then the authors state that “there is no anterior loop”. Alternatively if only the anterior aspect of the canal is patent then it implies that the nerve entered from mesial and as such the authors conclude that in such cases there must be an anterior loop. The problem persists however as it is not possible to clinically differentiate between the anterior loop and the incisive canal by means of a probe. As such it is not possible to measure the anterior loop, nor be convinced of the true existence in such cases.



The prevalence of an anterior loop varies considerably in the literature, as does the average measurements of its length. The mean length varies from 0.1mm<sup>8</sup> to 6.92mm<sup>18</sup>. The large variance could possibly be the result of numerous factors such as the equipment utilised (cadavers, dry skulls, 2-D radiographs and 3-D technologies), different population groups (races, age, gender and dental status) and different methods of performing the actual measurements (measuring directly with the aid of a probe, callipers and different methods of interpreting the radiographs). The methodologies employed in the literature can be broadly grouped into dry skulls, cadavers, panoramic radiographs, CBCT, spiral CT and conventional multi-slice CT.

Cadaver studies appear to have a few similarities such as small sample size and advanced age of the sample population. Solar et al<sup>14</sup>. found the anterior loop present in 59% of the 37 cadavers dissected, the mean ALL was 1mm and ranged from 0.5 to 5mm. Kumanovic et al.<sup>16</sup> found that the prevalence of the Anterior loop was 37% based on the dissection of 22 cadaveric samples, with a mean length of 1.2mm and a range of 0.11 to 3.31mm. Uchida et al.<sup>7</sup> utilising 75 hemi mandibles found the anterior loop present in 62.7% of cases, with a mean loop length of 1.5mm and a range of 1.0 to 6.6mm. Mardinger et al.<sup>19</sup> dissected 46 cadavers and found the anterior loop present in 28% of cases and a range of 0.4 to 2.19mm. Neiva et al.<sup>20</sup> following the dissection of 22 cadavers reported a prevalence of 88%, mean length of 4.13mm and a range of 1 to 11mm. Kieser et al.<sup>21</sup> was not able to demonstrate a single anterior loop in study involving 56 cadavers. Taken together the studies based on cadaveric samples demonstrate a prevalence of the anterior loop varying from 0 to 88%, mean loop length varying from 0 to 4.13mm, and a range of 0 to 11mm.

Panoramic radiographs have been used in numerous studies relating to the anterior loop of the inferior alveolar nerve. Jacobs et al.<sup>22</sup> studied 545 panoramic images and found an anterior loop present in 11% of cases. They did however not measure the length of anterior loop. Kuzmanovic et al.<sup>16</sup> found the anterior loop to be present in 27% of cases, with a range of 0.5 to 3mm. This was based on a small sample size of 22 panoramic images. Misch and Crawford<sup>13</sup> evaluated 324 panoramic radiographs and reported an average length of 5mm and a prevalence of 12%. They did not provide information regarding their range of findings. Arzouman et al.<sup>23</sup> employed two different panoramic methods on the same 25 dried skulls. Utilising method A the loop was detected in 56% of cases with a mean length of 2.69mm. Method B returned higher values, the prevalence rose to 76% and the mean loop length to 2.75mm. Based on the large range of findings, numerous authors now recommend that panoramic radiographs should not be relied on to identify the anterior loop of the inferior alveolar nerve when planning surgical interventions involving the mandible.<sup>6,16</sup>

Cone beam computed tomography (CBCT) was introduced into implant dentistry at the turn of the millennium.<sup>24</sup> Since then various studies pertaining to the prevalence and measurement of the anterior loop have been conducted. Ritter et al.<sup>25</sup> evaluated 1010 CBCT scans and found the anterior loop to be present in 31% of cases, with a mean length of 1.4mm and a maximum of 4.6mm. Uchida et al.<sup>26</sup> performed a study to compare the accuracy of CBCT to that of direct measurements made on cadavers. Unfortunately the sample size of the CBCT study consisted of only 7 hemi-mandibles. The authors recorded a mean length of 2.2mm, however they did not report on any other data. Rosa et al.<sup>27</sup> evaluated 352 CBCT scans and found the

mean loop length to be 2.4mm, with a range of 0.15 to 6.60mm. Apostololakis and Brown<sup>5</sup> studied 93 CBCT scans and reported the prevalence of the anterior loop to be 48%, with a mean length of 0.89mm and a range of 0 to 5.7mm. In a recent study by Chen et al.<sup>18</sup> the mean length of the anterior loop of the inferior alveolar nerve was compared between an American and Taiwanese cohort. Each cohort consisted of 100 samples. The anterior loop length of the Taiwanese (7.61+- 1.81mm) was significantly longer than that of the Americans (6.22+-1.68mm). The most recent study utilising CBCT to identify the anterior loop was that of Lu et al.<sup>28</sup> The study consisted of 366 CBCT scans, the prevalence of the anterior loop was 85.2% with a mean length of 1.46mm and a maximum length of 6.67mm.

A study is required to determine the prevalence and measurement of the length of the anterior loop of the inferior alveolar nerve in a South African population. This research was focused on using the most advanced diagnostic equipment in determining whether an anterior loop was indeed present in a South African cohort, and if so, determining the prevalence thereof.

## **AIMS AND OBJECTIVES**

This study aims to determine the prevalence and measurement of the length of the anterior loop of the inferior alveolar nerve in a South African population. The main objective will be to make clinical recommendations regarding surgical interventions involving the anterior mandible.

## RESEARCH HYPOTHESIS

Null hypothesis:

There is no difference in the length of the anterior loop of the inferior alveolar nerve between different ages, left and right sides of the mandible, gender and dental status in a South African population.

## MATERIALS AND METHODS

The sample population consisted of 200 patients (400 hemi-mandibles), sent for CT examination and subsequent software reformatting for dental implant planning. (Simplant, Materialise Dental NV, Leuven, Belgium)

The inclusion criteria were:

1. The anterior aspect of the body of the mandible bilaterally and up to 3cm distal to the mental foramen had to be included in the volume.
2. No pathology that could affect the position of the mandibular canal and mental foramen was present.
3. No evidence of any trauma or surgery that could affect the position of the mandibular canal and mental.
4. The images had to be of adequate quality.

The patients were divided into six age groups for the purposes of statistical analysis: (1) 18-30, (2) 31-40 (3) 41-50 (4) 51-60 (5) 61-70 (6) 71-87 years.

The patients were regarded as dentate when there was at least one premolar or canine present in the respected quadrant.

All CT scans were performed by the same radiologist using the same CT unit (Philips 64 slice scanner). The radiologist utilised for the scans has over 20 years' experience in craniofacial radiology. The protocol employed by the radiologist was identical for all patients. This involved positioning the patient in the supine position with the lower border of the mandible parallel to the occlusal line as dictated by the

CT unit, with the teeth slightly separated. The CT unit was set to take 1mm slice thickness with 0.5mm overlap. The kV was standardised at 120, collimation 64 x 0.624, pitch 0.579, rotation time 0.5s, filter set on “detail” and window set to C:200 and W: 2000.

Reformatting with Simplant software consisted of preparing industry-standard DICOM datasets on the CT scanner and importing it into Simplant Master Software. Surface rendering with realistic shading was applied to generate 3D views of the mandibular structures. In all cases, bone reconstruction algorithms and slice thicknesses of 0.5mm and slice increments of 0.5 mm or less were used. All datasets were prepared by a reformatting centre (Simplant SA with Simplant Master Software). The software allows the user to view images in grey scale or full spectrum colour, re-orientate slices to the occlusal plane and adjust the distance between axial, cross-sectional and panoramic images to allow for accurate measurements. Although measurements on the 3D image are possible, all measurements were done in 2D images as 3D images are influenced by various software settings, such as triangle reduction and smoothing factors.

The study sample consisted of 129 female and 71 male patients. There were 188 dentate and 12 edentulous patients.

## MEASUREMENTS

Using the Simplant software the alpha plane was determined as the plane which passes perpendicular to the inferior margin of the mandible (IMM) and connects to the anterior-most aspect of the mental foramen (MF). This was accomplished by first using the 3D reconstruction in full screen mode. Once the plane had been drawn, this was verified on both the axial and panoramic views to ensure absolute accuracy (Fig 1).

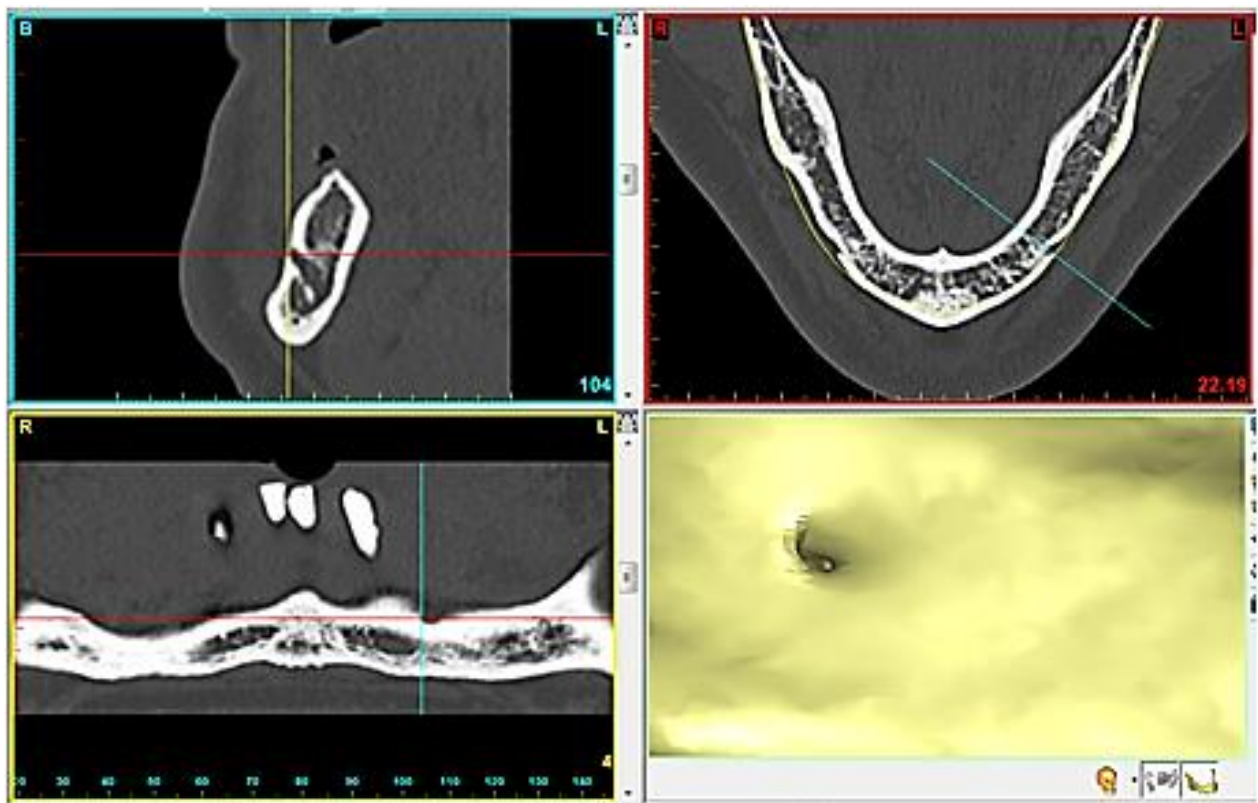
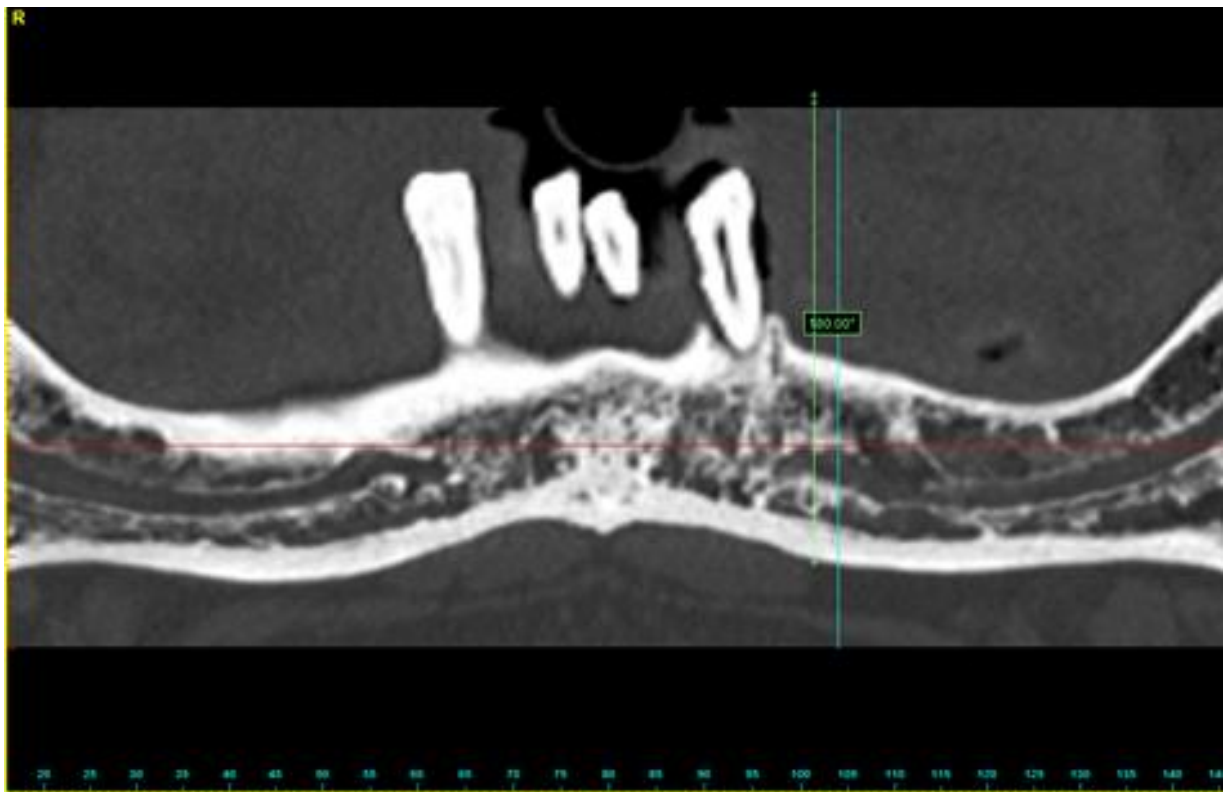


Figure 1: Alpha plane (turquoise line) drawn through the anterior-most aspect of the mental foramen.

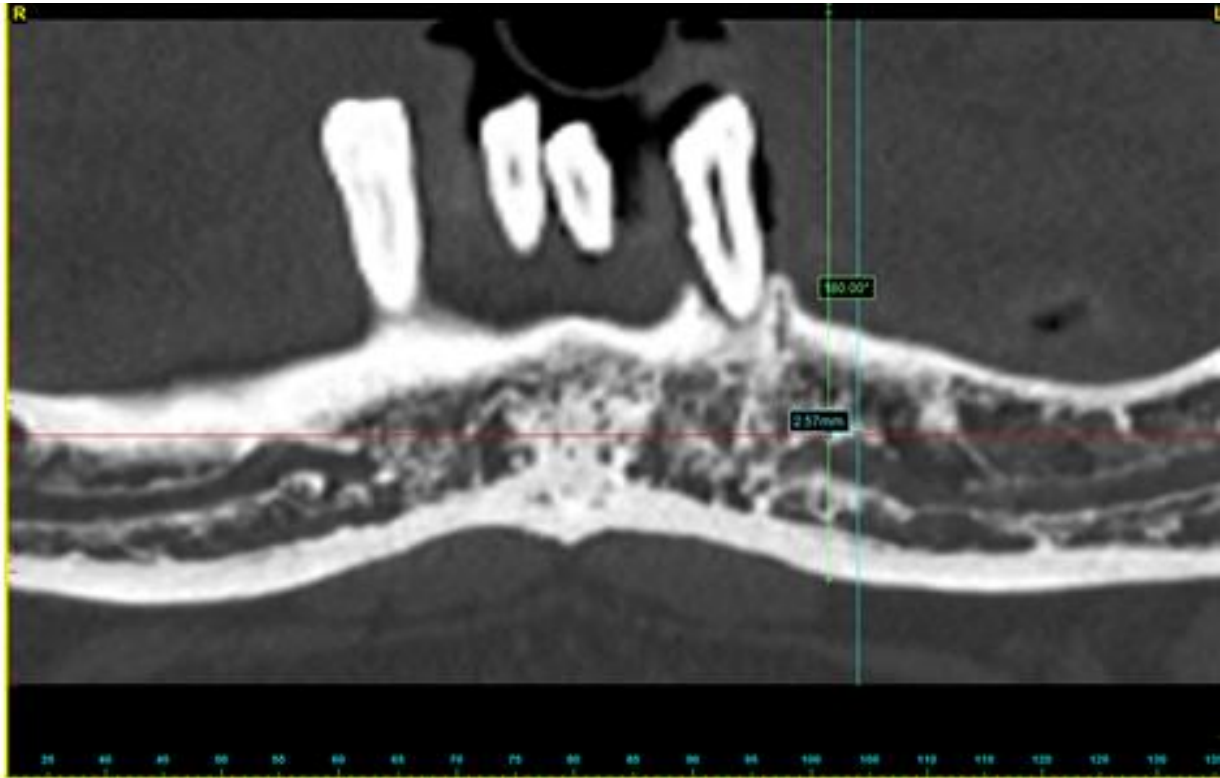


Secondly the beta plane was drawn which again passed perpendicular to the IMM and to the anterior most aspect of the anterior loop of the inferior alveolar nerve. To determine where the anterior most aspect of the anterior loop was, all the available views were utilised by scrolling through the reconstructions. Once satisfied that the anterior most aspect of the anterior loop had been identified, the beta plane was drawn in (Fig 2).



**Fig 2: Beta plane (Green line) drawn through the most anterior aspect of the anterior loop and parallel (180 degrees) to alpha plane**

Measuring the anterior loop length (ALL) was performed by measuring the shortest distance between the alpha and beta planes (Fig 3).



**Figure 3: Measuring the shortest distance between the alpha and beta planes**

To ensure reproducibility 25 scans were evaluated using the above mentioned method. Three weeks later the same examiner re-examined the 20 scans without having access to any of the previous markings or measurements.

## STATISTICS

### Descriptive

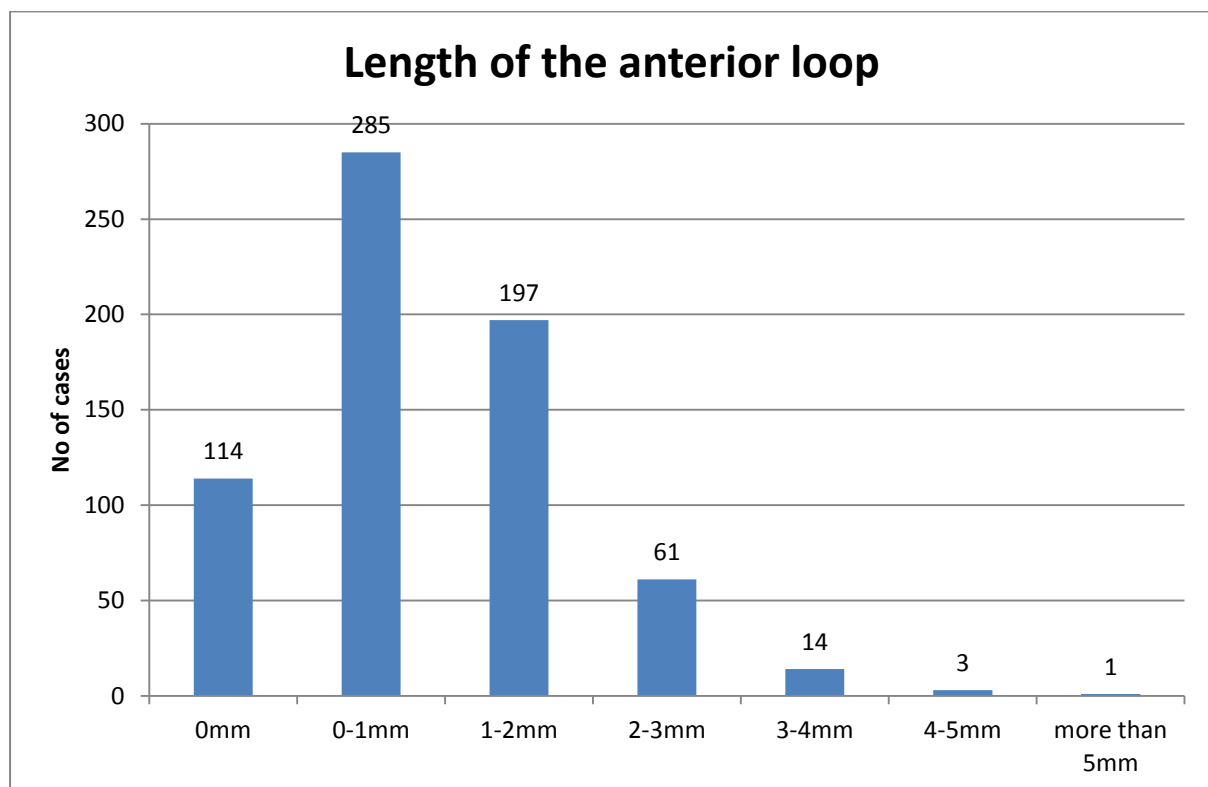
The prevalence of the anterior loop was calculated and a distribution chart for the length of the anterior loop was produced (Fig.4). The mean values, range, standard deviation of the measurements were calculated and categorized by side, gender, age group and dental status. From Fig. 4, it can be seen that our data is severely skewed. As a consequence, median and interquartile values were also calculated to give a better description of our data set (Table 1).

### Comparative

To compare the measured values for differences between gender and dental status, multiple group comparisons were made using Kruskal–Wallis ANOVA, whilst the Wilcoxon rank sum test was used for two group comparisons. These analyses were performed for each side (left or right) separately. Differences between left and right sides were investigated using the Wilcoxon matched pairs, signed-rank test. The results were considered significant where  $P < 0.05$ . Spearman's correlation coefficient was used to estimate the relationship between the length of the anterior loop and age. Twenty cases (40 sides), representing 10% of the total cases were re-examined after 3 weeks by the same examiner. Intraclass correlation was used to provide an estimate of the reliability of the measurements. Also the range of absolute errors between the two measurements and the average absolute mean error of the two measurement attempts were calculated.

## RESULTS

The anterior loop was evaluated in 200 patients (400 hemi-mandibles). In 286 out of 400 sides (71%) the data indicated that an anterior loop was present. The mean length of the loop is 1.054mm for all of the observations combined and the measurements range from 0mm to 5.29mm. The median is 0.96mm, which is the value in the middle of all of the other observations and the interquartile range is from 0mm to 1.58mm.



**Figure 4. Length of the anterior loop for all 400 observations.**

In 29% of cases examined, no anterior loop was identified. In 54% of these cases the loop was absent bilaterally and in 46% an anterior loop could not be identified on one side only (it was visible on the contra-lateral side).

Of those sides that presented an anterior loop, 51% lay between 0 and 1 mm in length, 35% between 1 and 2 mm, 11% between 2 and 3 mm, 2% between 3 and 4 mm and 1% between 4 and 5 mm. The longest loop measured was 5.29mm, and was the only measurement exceeding 5mm. Due to the very likely case that measurements above 4mm are outliers (as confirmed by the Z test) non-parametric tests were used for the purposes of comparison since they are less sensitive to the presence of outliers.

The statistics for each category were examined, see Table 1 below. The data is severely skewed to the right (Skewness=0.9). As a result the shape of the distribution was determined by using the median and interquartile ranges. This means that most of the observations will be of low value (between 0 and 3mm) and only a few of the observations of high value.

Ages were divided into 10 year bands, except for the lowest and highest age bands which are 18 to 30 and 71 to 87 respectively since the number of observations in separate bands over these ranges were too low.

Group	n	Range	Median	IQR	Mean	SD	95% CI
<b>All</b>	400	0 - 5.29	0.96	0 - 1.58	1.05	0.94	0 - 3.27
<b>Side</b>							
<b>Right</b>	200	0 - 5.29	1.14	0 - 1.61	1.12	0.97	0 - 3.27
<b>Left</b>	200	0 - 4.02	0.88	0 - 1.51	0.99	0.90	0 - 3.22
<b>Gender</b>							
<b>Male</b>	142	0 - 5.29	1.26	0.76 - 1.95	1.35	1.04	0 - 3.5
<b>Female</b>	258	0 - 4.02	0.86	0 - 1.3	0.89	0.84	0 - 2.8
<b>Age</b>							
<b>18-30</b>	18	0 - 2.06	1.11	0 - 1.39	0.85	0.69	0 - 1.86
<b>31-40</b>	60	0 - 3.22	0.88	0 - 1.24	0.91	0.77	0 - 2.83
<b>41-50</b>	86	0 - 3.54	1.14	0.3 - 1.82	1.18	0.97	0 - 3.26
<b>51-60</b>	138	0 - 4.36	1.07	0 - 1.58	1.06	0.92	0 - 2.94
<b>61-70</b>	84	0 - 5.29	0.84	0 - 1.42	1.00	1.08	0 - 3.62
<b>71-87</b>	14	0 - 2.4	1.58	0.88 - 2.01	1.41	0.76	0 - 2.38
<b>Dental Status</b>							
<b>Dentate</b>	376	0 - 5.29	0.95	0 - 1.58	1.05	0.95	0 - 3.35
<b>Edentulous</b>	24	0 - 2.8	1.11	0.36 - 1.33	1.05	0.81	0 - 2.65

**Table 1. Summary of the finding regarding the anterior loop of the inferior alveolar nerve**

It is apparent from figure 4 that the data is severely skewed to the right and as result a normal distribution could not be established. For this reason we utilized the Kruskal-Wallis and Wilcoxon Rank Sum tests to establish equality of the underlying distributions in terms of the median and not the mean. We have used the non-parametric Wilcoxon rank sum test, since the test is less sensitive to singular outliers in the data.

The Wilcoxon rank sum test was conducted for the comparison of two groups, where the null hypothesis that the two samples are from identical, continuous distributions with the same median value was tested. P-values less than 0.05 indicate that the null hypothesis is rejected and that the samples are not from identical, continuous distributions with the same median. If the null hypothesis is not rejected we can conclude that there are no statistically significant differences between the groups. Comparisons tabulated in table 2 below.

Groups	p-value	Null hypothesis rejected?
<b>Male vs. Female</b>	0.0000055943	Yes
<b>Dentate vs. Edentulous</b>	0.8755	No

**Table 2. Comparison between the groups**

When we compare several groups (in this case age) we use Spearman's correlation coefficient, that tells us that  $r=0.0196$  and  $p=0.6956$  which means that we can safely conclude that there is no relationship between the anterior loop and age. We can also conclude that there is no difference in age whether the anterior loop is present or not since the Wilcoxon rank sum test yields a p-value of 0.8110 which is significantly higher than 0.05.

Finally, the Wilcoxon matched pairs, signed rank test was used to compare the left and right side measurements. We used this test to compare if the difference between the left and right side measurements have a zero median. The test yields a p-value of 0.0657, which means we cannot reject the null hypothesis at a 5% level of significance. So it is likely that the left and right side measurements are similar,

although it is interesting to note that we can reject the null hypothesis for the test at a 10% level of significance, meaning that the medians are possibly not equal.

From the investigation we can conclude that there is a statistically significant difference between measurements of the anterior loop for males and females. There are no indications of differences in terms of dental status or age between the measurements. It is found that 97% of observed measurements lie between 0mm and 3mm and that the distribution of the measurements is positively skewed, additionally, 99% of all observed measurements lie between 0mm and 4mm. Therefore high values of measurements (i.e. those above 3mm) are unlikely. In terms of the statistics, we can conclude that the loop is prevalent in 71% of the cases investigated and did not exceed 4mm in 99% of these cases. There are no statistically significant differences between the groups investigated such as age and dental status, except for gender, indicating that the loop tends to be larger in males.



## CONCLUSIONS

After evaluating 200 CT scans reformatted with Simplant software (Simplant, Materialise Dental NV, Leuven, Belgium):

(1) 71% of the scans revealed the presence of an anterior loop of the inferior alveolar nerve.

(2) A wide range of measurements existed for the anterior loop length (ALL) ranging from 0 to 5.29mm with a mean of 1.05mm.

(3) No statistically significant differences were found between the left and right side measurements or between the different age groups, but the male group had a significantly larger anterior loop length than the female group.

When placing implants in close proximity to the mental foramen, caution is recommended to avoid injury to the inferior alveolar nerve, or one of its branches. The anterior loop of the inferior alveolar nerve becomes a critically important surgical reference point during treatment planning. Because of the wide range of the anterior loop lengths observed in our study, no fixed distance mesially or anteriorly from the mental foramen should be considered to be a “safe” distance without the use of 3 dimensional imaging. Analysing CT scans using the method described in this paper can be a useful tool in avoiding implant surgical complications in the anterior mandible.

## REFERENCES

1. Buser D, Janner SM, Wittneben J, Bragger U, Salvi G. 10-Year Survival and Success Rates of 511 Titanium Implants with a Sandblasted and Acid-Etched Surface: A Retrospective Study in 303 Partially Edentulous Patients. *Clin Oral Implants Res.* 2012;14:839-851.
2. Malo P, Rangert B, Nobre M. “All-on-Four” Immediate-Function Concept with Brånemark System® Implants for Completely Edentulous Mandibles: A Retrospective Clinical Study. *Clin Implant Dent Rel Res.* 2003;5:2-9.
3. Parnia F, Moslehifard E, Hafezeqoran A, Mahboub F, Mojaver-Kahnamoui H. Characteristics of anatomical landmarks in the mandibular interforaminal region: A cone-beam computed tomography study. *Med Oral Patol Oral Cir Bucal.* 2012;17:420-5.
4. Renton T. Prevention of iatrogenic inferior alveolar nerve injuries in relation to dental procedures. *J Oral Maxillofac Surg.* 2010;37:350-363.
5. Apostolakis D, Brown J. The anterior loop of the inferior alveolar nerve: prevalence, measurement of its length and a recommendation for interforaminal implant installation based on cone beam CT imaging. *Clin Oral Implants Res.* 2012;23:1022-1030.

6. Greenstein G, Tarnow D. The mental foramen and nerve: clinical and anatomical factors related to dental implant placement: a literature review. *J Periodontol.* 2006;77:1933-43.
7. Uchida Y, Yamashita Y, Goto M, Hanihara T. Measurement of anterior loop length for the mandibular canal and diameter of the mandibular incisive canal to avoid nerve damage when installing endosseous implants in the interforaminal region. *J Oral Maxillofac Surg.* 2007;65:1772–1779.
8. Bavitz JB, Harn SD, Hansen CA, Lang M. An anatomical study of mental neurovascular bundle-implant relationships. *Int J Oral Maxillofac Implants.* 1993;8: 563–567.
9. Rosenquist B. Is there an anterior loop of the inferior alveolar nerve? *Int J Periodontics Restorative Dent.* 1996;16:41–45.
10. Kaya Y, Sencimen M, Sahin S. Retrospective radiographic evaluation of the anterior loop of the mental nerve: comparison between panoramic radiology and spiral computerized tomography. *Int J Oral Maxillofac Implants.* 2008;23:919-925.
11. Li X, Jin Z, Zhao H. The prevalence, length and position of the anterior loop of the inferior alveolar nerve in Chinese, assessed by spiral computed tomography. *Surg Radiol Anat* 2013

12. Wismeijer D, van Waas MA, Vermeeren JI, Kalk W. Patient's perception of sensory disturbances of the mental nerve before and after implant surgery: a prospective study of 110 patients. *Br J Oral Maxillofac Surg.* 1997;35:254-259.
13. Misch CE, Crawford EA. Predictable mandibular nerve location – a clinical zone of safety. *Int J Oral Implant.* 1990;7:37-40.
14. Solar P, Ulm C, Frey G, Matejka M. A classification of the intraosseous paths of the mental nerve. *Int J Oral Maxillofac Implants.* 1994;9:339-344.
15. Renton T. Minimising and managing nerve injuries in dental surgical procedures. *Fac Dent.* 2011; 2:164-171.
16. Kuzmanovic DV, Payne AG, Kieser JA, Dias GJ. Anterior loop of the mental nerve: A morphological and radiographic study. *Clin Oral Implants Res.* 2003; 14:464–471.
17. Magnusson, S. *Surgical Procedure Manual*, 1st edition 1992; pD-4, Goteborg: Nobelfarma AB.
18. Chen JC, Lin LM, Geist JR, Chen JY, Chen CH, Chen YK. A retrospective comparison of the location and diameter of the inferior alveolar canal at the mental

foramen and length of the anterior loop between American and Taiwanese cohorts using CBCT. *Surg Radiol Anat.* 2013;35:11-8.

19. Mardinger O, Chaushu G, Arensburg B, Taicher S, Kaffel. Anterior loop of the mental canal: An anatomical-radiologic study. *Implant Dent.* 2000;9:120–123.

20. Neiva RF, Gapski R, Wang HL. Morphometric analysis of implant-related anatomy in Caucasian skulls. *J Periodontol.* 2004;75:1061-7.

21. Kieser J, Kuzmanovic D, Payne A, Dennison J, Herbison P. Patterns of emergence of the human mental nerve. *Arch Oral Biol.* 2002; 47:743-7.

22. Jacobs R, Mraiwa N, Steenberghe DV, Sanderink G, Quirynen M. Appearance of the mandibular incisive canal on panoramic radiographs. *Surg Radiol Anat.* 2004; 26:329–333.

23. Arzouman JM, Otis L, Kipnis V, Levine D. Observation of the anterior loop of the inferior alveolar canal. *Int J Oral Maxillofac Implants.* 1993;8:295–300.

24. Sukovic P. Cone beam computed tomography in craniofacial imaging. *Orthod Craniofac Res.* 2003; 6(Suppl 1):31–6.

25. Ritter L, Neugebauer J, Mischlowski RA, Dreiseidler T, Rothamel D, Richter U. Evaluation of the course of the inferior alveolar nerve in the mental foramen by cone beam computed tomography. *Int J Oral Maxillofac Implants*. 2012;27:1014-1021.
  
26. Uchida Y, Noguchi N, Goto M, Yamashita Y, Hanihara T, Takamori H, Sato I, Kawai T, Yosue T. Measurement of anterior loop length for the mandibular canal and diameter of the mandibular incisive canal to avoid nerve damage when installing endosseous implants in the interforaminal region: a second attempt introducing cone beam computed tomography. *J Oral Maxillofac Surg*. 2009;67:744-50.
  
27. Rosa MB, Sotto-Maior BS, Machado VC, Francischone CE. Retrospective Study of the Anterior Loop of the Inferior Alveolar Nerve and the Incisive Canal Using Cone Beam Computed Tomography. *Int J Oral Maxillofac Implants*. 2013;28:388-92
  
28. Chun-I. Lu, John Won, Aladdin Al-Ardah, Ruben Santana, Dwight Rice, and Jaime Lozada (2014) Assessment of the Anterior Loop of the Mental Nerve Using Cone Beam CT-Scan. *J Oral Implant In-Press*.



UNIVERSITEIT VAN PRETORIA  
UNIVERSITY OF PRETORIA  
YUNIBESITHI YA PRETORIA

Faculty of Health Sciences  
School of Dentistry

2013/06/06

Prof AJ Ligthelm  
Dean  
School of Dentistry

Dear Professor

**PROTOCOL APPROVAL: DENT 2013/04**

Name: Dr GO Patterson  
Title: "The anterior loop of the inferior alveolar nerve: prevalence and measurement using reformatted medical computed tomographic imaging"

The protocol attached hereto was evaluated by the Research Committee of the School of Dentistry. The Research Committee recommends the approval of the title and the protocol.

Your sincerely

**PROF P.J. VAN WYK**  
**CHAIRPERSON: RESEARCH COMMITTEE**

Protocol approved/not approved

**PROF AJ LIGTHELM**  
**DEAN: SCHOOL OF DENTISTRY**

University of Pretoria  
PO Box 1255  
PRETORIA 0001  
Republic of South Africa

Tel: +27 12 319 2419  
Fax: +27 12 323 7616

<http://www.up.ac.za>  
[esme.schoeman@up.ac.za](mailto:esme.schoeman@up.ac.za)

The Research Ethics Committee, Faculty Health Sciences, University of Pretoria complies with ICH-GCP guidelines and has US Federal wide Assurance.

- FWA 00002567, Approved dd 22 May 2002 and Expires 20 Oct 2016.
- IRB 0000 2235 IORG0001762 Approved dd 13/04/2011 and Expires 13/04/2014.



UNIVERSITEIT VAN PRETORIA  
UNIVERSITY OF PRETORIA  
YUNIBESITHI YA PRETORIA

Faculty of Health Sciences Research Ethics Committee

29/08/2013

**Approval Certificate  
New Application**

**Ethics Reference No.:** 341/2013

**Title:** The anterior loop of the inferior alveolar nerve: prevalence and measurement using reformatted medical computed tomographic imaging

Dear Dr Geoff Patterson

The **New Application** as supported by documents specified in your cover letter for your research received on the 7/08/2013, was approved by the Faculty of Health Sciences Research Ethics Committee on the 28/08/2013.

Please note the following about your ethics approval:

- Ethics Approval is valid for 1 year.
- Please remember to use your protocol number (341/2013) on any documents or correspondence with the Research Ethics Committee regarding your research.
- Please note that the Research Ethics Committee may ask further questions, seek additional information, require further modification, or monitor the conduct of your research.

**Ethics approval is subject to the following:**

- The ethics approval is conditional on the receipt of 6 monthly written Progress Reports, and
- The ethics approval is conditional on the research being conducted as stipulated by the details of all documents submitted to the Committee. In the event that a further need arises to change who the investigators are, the methods or any other aspect, such changes must be submitted as an Amendment for approval by the Committee.

We wish you the best with your research.

Yours sincerely

**DR R SOMMERS;** MBChB; MMed(Int); MPharmMed.  
**Deputy Chairperson** of the Faculty of Health Sciences Research Ethics Committee  
University of Pretoria