

Prevalence and pattern of brown adipose tissue distribution of ^{18}F -FDG in patients undergoing PET-CT in a subtropical climatic zone

Alan C. Perkins^a, Dahiru S. Mshelia^c, Michael E. Symonds^b and Mike Sathekge^c

Background The uptake of ^{18}F -FDG in brown adipose tissue (BAT) may have important implications in understanding the pathophysiology of BAT and obesity. Because of the thermal implications of BAT uptake of ^{18}F -FDG, this study aimed to contribute to existing knowledge by assessing patients scanned in a subtropical environment with particular reference to ethnicity.

Patients and methods A retrospective study was carried out to determine the prevalence and pattern of BAT uptake in patients undergoing ^{18}F -FDG PET-CT imaging in a PET facility located in a subtropical climatic zone. Standardized uptake values were obtained for regions of BAT uptake of ^{18}F -FDG, and the distribution pattern was assessed according to anatomical region, sex, age, BMI and ethnicity.

Results Following a review of a total of 386 scans, 38 patients showed BAT uptake of ^{18}F -FDG (9.85%), with the mass and activity of BAT being greater in women than in men (11.95 and 6.88%, respectively). BAT uptake of ^{18}F -FDG in the neck/supraclavicular, axillary and mediastinal regions was greater in adults whose BMI was less than $18\text{kg}/\text{m}^2$. However, perirenal BAT activity was shown to be greater in obese individuals. The frequency of BAT uptake of ^{18}F -FDG was 55% in winter as against

45% during summer ($P < 0.012$). There was no statistical difference in BAT uptake between black and white patients.

Conclusion This study shows the pattern and prevalence of BAT in patients in a subtropical environment. Although the average seasonal temperatures are higher in a subtropical climate, a seasonal variation in BAT expression was observed, although there were no differences with respect to patient ethnicity.

Keywords: brown adipose tissue, brown fat, ^{18}F -FDG imaging, PET imaging, subtropical climate

^aDivision of Radiological and Imaging Sciences, School of Clinical Sciences and Nottingham Digestive Diseases Biomedical Research Unit, ^bThe Early Life Nutrition Research Unit, Academic Division of Child Health and Respiratory Biomedical Research Unit, Queen's Medical Centre, University of Nottingham, Nottingham, UK and ^cDepartment of Nuclear Medicine, Steve Biko Academic Hospital, Pretoria, South Africa

Correspondence to Prof. Alan C. Perkins, PhD, CSci, FIPEM, FRCR, Hon FRCP, Radiological and Imaging Sciences, Medical Physics, Medical School Queen's Medical Centre, University of Nottingham, Nottingham, NG7 2UH, UK Tel: + 44 115 970 9192; fax + 44 115 970 9301; e-mail: alan.perkins@nottingham.ac.uk

Introduction

The adipose tissue pool in mammals is composed of at least two functionally different types of fat: white and brown. White adipose tissue is the primary site of energy storage and the site of release of hormones and cytokines that modulate whole-body metabolism and insulin resistance [1]. Brown adipose tissue (BAT) is highly vascularized, rich in mitochondria organelles and important especially in early life for both basal and inducible energy expenditure in the form of thermogenesis mediated by the expression of tissue-specific uncoupling protein 1 (UCP1) [2,3]. It is well recognized that BAT is present and active in human newborns and is responsible for the successful maintenance of body temperature without shivering [4,5]. However, findings from ^{18}F -FDG PET-CT imaging have shown that BAT is not only present in adults but is also an important factor in tissue energy balance and metabolism [6]. The presence of UCP1 in biopsy samples taken from the supraclavicular

areas corresponding to the sites of ^{18}F -FDG uptake has confirmed the presence of BAT at these sites [7,8]. BAT uptake of ^{18}F -FDG is therefore considered a 'normal' variation [9,10] and studies have found it to be comparable to the uptake in pathologic lymph nodes or soft-tissue masses in supraclavicular areas [11–13]. Consequently, in the context of clinical investigation, the uptake in metabolically active BAT is seen as a disturbing complication.

It is clear that ^{18}F -FDG PET-CT imaging may contribute important information to the understanding of the pathophysiology of BAT and obesity [14]. This retrospective study, which is the first of its kind in Africa, was carried out to determine the prevalence and common sites of BAT visualization in patients undergoing ^{18}F -FDG PET-CT imaging in a subtropical climatic zone as well as to determine whether the frequency of BAT varied with sex, age, BMI and ethnicity.

Patients and methods

This study followed the institutional guidelines for the Steve Biko Academic Hospital, Pretoria, South Africa. As only medical records and images were examined, individual patient consent was not required.

^{18}F -FDG PET-CT scans were reviewed retrospectively to determine the presence and frequency of hypermetabolic BAT uptake at different anatomical sites in patients. We analysed 386 consecutive ^{18}F -FDG PET-CT whole-body images taken for patients referred for a variety of diagnostic reasons from January to November 2010. Scans taken in March, April, the last half of November and December were not included because of technical reasons.

^{18}F -FDG PET-CT scanning

Patients were instructed to take low-carbohydrate meals and avoid strenuous exercise for 24 h before undergoing the scanning procedure. They were also advised to avoid stressful physical activity on the day of the scan. Patients were asked to fast for at least 4 h before the appointment. On arrival at the department, the procedure was thoroughly explained to the patients, their history was taken and clinical examinations were carried out. The patient's blood glucose level was determined using a glucometer. The administered activity of ^{18}F -FDG, given intravenously, was determined using the formula $[(\text{patient's weight}/10) + 1] \times 37 \text{ MBq}$. During the interval between injection and scanning, all patients were kept in a semidarkened quiet room, asked to remain still, covered with a blanket, and deprived of auditory stimuli for at least 60 min to avoid uptake of the radiotracer at physiological sites excited by these stimuli. During this uptake phase, patients were asked to drink at least 1 l of water. The patients voided their urinary bladders immediately before scanning.

Images were acquired using a Biograph 40-3R PET-CT scanner (Siemens Medical Solutions, Malvern, Pennsylvania, USA). Scans were acquired 90 min after ^{18}F -FDG injection for all cases of malignancy and after 60 min in cases of infection/inflammation. Patients were instructed not to move while on the scanner bed and were instructed to breathe normally during acquisition. Scans were acquired in three-dimensional mode for 3 min in each of seven to nine bed positions from mid-thigh to the skull vertex in a 512×512 matrix size of a slice size of 5 mm. Images were reconstructed with and without CT attenuation correction using ordered subset expectation maximization with four iterations and eight subsets, yielding axial, sagittal and coronal slices.

For CT scanning, contrast enhancement was achieved by intravenous administration of 100 ml of nonionic contrast material, Ultravist (Bayer HealthCare Pharmaceuticals, Gauteng, South Africa) at a rate of 2 ml/s. Helical CT images were obtained from the vertex to mid-thigh at

0.8 s/rotation, 80 mA, 120 kVp, 700 mm field of view, noise index 11.91 SD and image size 512, with a section thickness of 5 mm. The CT scan was used for PET attenuation correction and for anatomical localization. The attenuation-corrected PET and CT image data sets were registered on a Syngo MI workplace image platform (Siemens Medical Solutions) and displayed as fused images.

Analysis of BAT uptake

BAT was considered present in the ^{18}F -FDG PET-CT scans if there were areas of tissue with activity greater than background, colocalized with regions of fat identified on the CT images with a density of adipose tissue (-250 to -50 HU). The location of BAT depots was recorded and quantified by the measurement of maximum standardized uptake value (SUV_{max}) over the sites of uptake. The anatomical areas used in the study are the neck/supraclavicular region, the axillary region, the mediastinal region, the paravertebral region, the perirenal region, and the abdomen, the latter excluding the paravertebrae and perirenal regions. SUV_{max} values were obtained for all regions identified by defined regions of interest where the SUV_{max} was measured on the attenuation-corrected images. Regions of interest were overlaid onto the BAT through direct visual assessment of the area on the CT images. The total number of positive depots identified was quantified for correlation with the other variables.

Data pertaining to the month of the scan, patient age, sex, blood glucose level, weight, height, and BMI (in kg/m^2), calculated using the formula $\text{weight (kg)}/\text{height (m)}^2$, were collected.

Statistical analysis

The prevalence and distribution of BAT in all patients, as well as differences between male and female patients and between adult and paediatric patients, were determined. All statistical analyses were performed using the Statistical Package for the Social Sciences (SPSS version 16.0 for windows; SPSS Inc., Chicago, Illinois, USA). Summary descriptive statistics of BAT activity were determined for each of the anatomical depots. A χ^2 -test was conducted to ascertain whether there was a significant relationship between sex, age and the total number of BAT-positive scans and between season and the total number of BAT-positive scans.

Results

A total of 386 whole-body PET-CT scans were reviewed. The patient population comprised 160 male and 226 female patients. Of the 386 patients, 55 were in the paediatric age range (defined as patients who were younger than 18 years of age), whereas 331 patients were adults. Thirty-eight patients were found to have BAT uptake of ^{18}F -FDG. A summary of the prevalence of BAT

uptake of ^{18}F -FDG according to age and sex is shown in Table 1.

Age

The mean \pm SD age of patients who had active BAT uptake of ^{18}F -FDG was 35.5 ± 17.8 years (range 5–63 years). The prevalence of active BAT among all patients was 9.85%. The result showed the prevalence to be higher in female patients (27/226; 11.95%) than in male patients (11/160; 6.88%) ($P < 0.002$), the female : male ratio being 1.74 : 1. It was also shown that visualization was more prevalent among paediatric patients (7/55; 12.73%) than among adults (31/331; 9.37%) ($P < 0.01$) (Table 1). Among the paediatric patients in whom BAT activity was visualized, 71.43% were boys whereas 28.57% were girls. There was significantly higher BAT activity in boys compared with girls in the neck/supraclavicular, paravertebral and perirenal regions with no difference in the axillar region. Neither sex showed BAT activity in the abdomen or mediastinal regions.

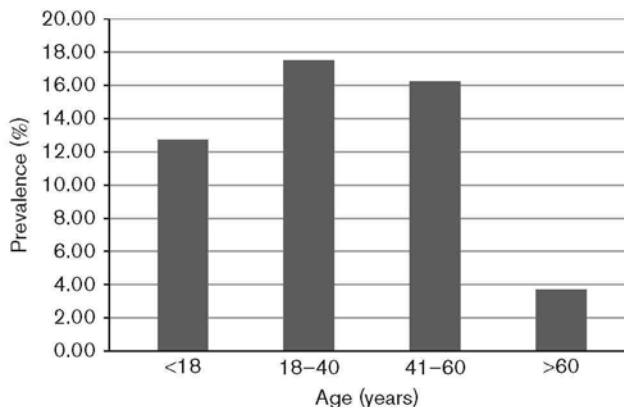
Figure 1 shows a decreasing prevalence of BAT with increasing age of adult patients. The prevalence is higher among patients aged less than 40 years but subsequently decreased with increasing age.

Table 1 Age and sex distributions of the prevalence of BAT among patients

| Variables | Total number of patients | Total number of BAT | Prevalence (%) |
|--------------------------|--------------------------|---------------------|----------------|
| Total number of patients | 386 | 38 | 9.85 |
| Females | 226 | 27 | 11.95 |
| Males | 160 | 11 | 6.88 |
| Adults | 331 | 31 | 9.37 |
| Paediatrics | 55 | 7 | 12.73 |

BAT, brown adipose tissue.

Fig. 1



Prevalence of brown adipose tissue in patients on the basis of age (demonstrating decreasing prevalence with increasing age among adults).

Anatomical site of uptake

Table 2 shows the frequency of distribution of BAT uptake of ^{18}F -FDG at different anatomical sites in patients, whereas Fig. 2 shows the intensity (mean SUV_{max}) of BAT according to age ranges. BAT was visualized more frequently in the neck/supraclavicular region and less frequently in the abdomen. Similarly, ^{18}F -FDG uptake was found to be most intense in the neck/supraclavicular region (6.62 ± 4.21) and less in the paravertebral region (3.96 ± 1.82). Three patients showed the presence of BAT only at other sites and not in the neck/supraclavicular region. In all regions except at the mediastinum and abdomen, BAT was seen to be more intense in the paediatric age group, indicating that BAT not only declined in prevalence with age but also decreased in intensity with age (Fig. 2).

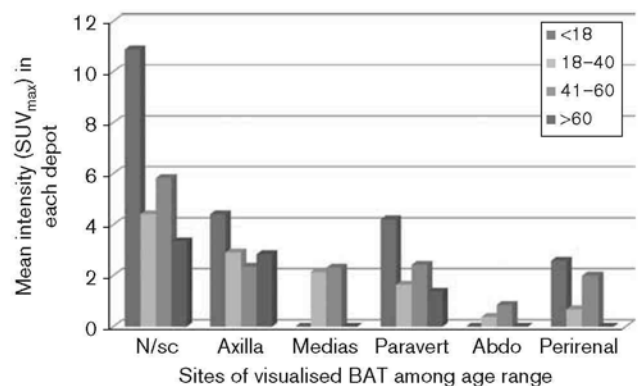
The SUV_{max} of the five different anatomical regions in the study showed wide variation in the intensity of BAT uptake, ranging from 1.78 to 21.94. The mean value in each region, except for the paravertebral and axillar regions, was greater than 5, well into the commonly accepted pathological range (Table 2).

Table 2 Anatomical distributions, frequency and intensity of BAT among the patients

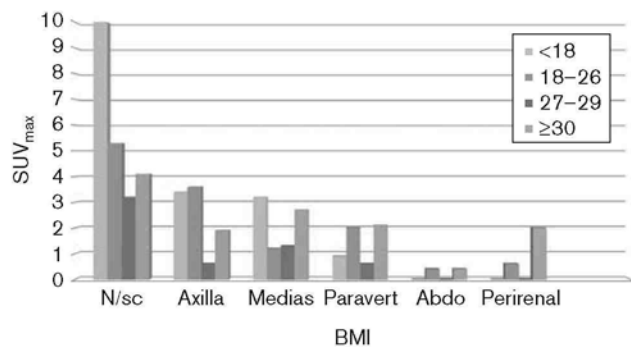
| Regions | Number of patients in whom uptake was visualized (frequency) | Intensity (mean \pm SD SUV_{max}) | Range of SUV_{max} |
|----------------------|--|--|------------------------------------|
| Neck/supraclavicular | 35 | 6.62 ± 4.21 | 2.41–21.94 |
| Axilla | 29 | 4.06 ± 1.66 | 1.64–7.42 |
| Mediastinum | 12 | 5.24 ± 1.87 | 2.48–7.44 |
| Paravertebral | 24 | 3.96 ± 1.82 | 1.78–8.25 |
| Abdomen | 3 | 5.72 ± 2.29 | 3.83–8.27 |
| Perirenal | 10 | 5.68 ± 2.77 | 2.10–11.55 |

BAT, brown adipose tissue; SUV_{max} , maximum standardized uptake value.

Fig. 2



Intensity (SUV_{max}) of BAT uptake in anatomical locations among patients according to age. Abdo, abdominal; BAT, brown adipose tissue; medias, mediastinal; N/sc, neck/supraclavicular; paravert, paravertebral; SUV_{max} , maximum standardized uptake value.

Fig. 3

Relationship between BMI and intensity (SUV_{max}) of BAT in anatomical locations. Abdo, abdominal; BAT, brown adipose tissue; medias, mediastinal; N/sc, neck/supraclavicular; paravert, paravertebral; SUV_{max}, maximum standardized uptake value.

The results showed that BMI was inversely related to BAT activity and intensity on the basis of SUV_{max}. This is shown in Fig. 3 in which the intensity of BAT in the neck/supraclavicular, axillary and mediastinal regions was greater in adults whose BMI was less than 18 kg/m². However, perirenal BAT activity was shown to be greater in obese individuals.

Seasonal variation

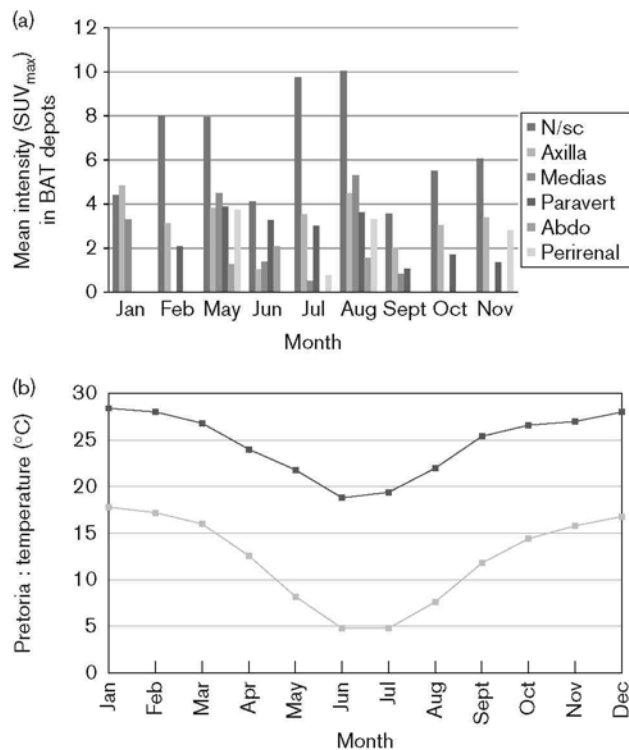
The proportion of patients with BAT activity showed a striking seasonal variation. In South Africa, the coldest period covers the months of May to August and 21 out of 38 positive scans were taken during this period, representing 55% of the BAT-positive images as against 45% taken during summer ($P < 0.012$). The intensity of uptake was especially marked in the neck/supraclavicular region, the regions of the body more likely to be exposed to the external environment. The intensity of uptake shown by month of scan is given in Fig. 4, together with the seasonal temperatures in Pretoria.

Ethnicity

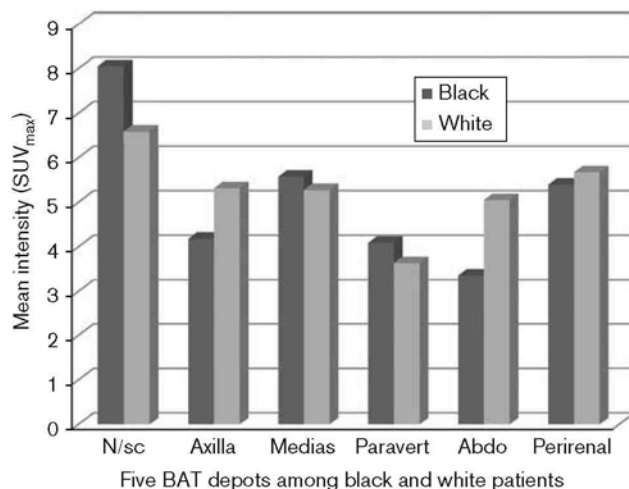
Of the 38 patients in whom BAT uptake of ¹⁸F-FDG was visualized, 78.95% were black, 13.16% were white and 7.89% were Asian. These numbers may simply reflect public hospital attendance among the ethnic groups in South Africa. When the anatomical BAT uptake measured in SUV was compared between black and white patients no significant difference was seen (Fig. 5); 7.89% of Asian patients showed BAT activity only in the neck/supraclavicular region and are therefore not included in Fig. 5.

Discussion

This is the first study to assess the incidence of BAT visualization in different ethnic groups in a subtropical climatic zone. The overall prevalence of active BAT detected on ¹⁸F-FDG PET-CT scans was 9.85%. Previous

Fig. 4

(a) Seasonal incidence of BAT visualization in patients (coldest period covers the months of May to August). (b) Annual average temperature in Pretoria (taken from <http://www.allmetsat.com>). Abdo, abdominal; BAT, brown adipose tissue; medias, mediastinal; N/sc, neck/supraclavicular; paravert, paravertebral; SUV_{max}, maximum standardized uptake value.

Fig. 5

Intensity of ¹⁸F-FDG uptake in black and white patients shown by anatomical site. Abdo, abdominal; BAT, brown adipose tissue; medias, mediastinal; N/sc, neck/supraclavicular; paravert, paravertebral; SUV_{max}, maximum standardized uptake value.

studies have shown varied prevalence, ranging from 2.3% to as high as 80% [12,13,15–18] depending on whether the procedure was with or without intervention.

It has been observed previously that BAT is most prominent in newborns and reduces with age [3,4]. Our observations showing that BAT was seen more frequently in younger patients is in agreement with this trend. The study also demonstrated a decreasing BAT intensity with increasing age. The sites of BAT in humans are largely central and internal, in a distribution likened to a ‘high-collared vest’ arranged such that the heat generated warms the blood supply to vital organs. The five depots noted in our study were in the neck/supraclavicular, axillar, mediastinum, paravertebral, abdominal and perinephric regions, which are the sites previously observed in other studies.

The anatomical sites of highest BAT uptake of ^{18}F -FDG that we observed were in the neck and supraclavicular areas. However, perirenal depots, which are generally considered to be rare [4,6], were found in a large number of our patients, especially in the obese.

The mean SUV_{max} of most depots in the current study was greater than 5, well into the commonly accepted pathological range. Occasionally, this can obscure scan findings, resulting in both false-positive or false-negative interpretations of ^{18}F -FDG PET-CT scans; similarly, the presence of BAT in the perirenal area, found in a number of patients in this study, could easily have been misinterpreted as adrenal metastases [15,19]. However, for areas demonstrating significantly intense BAT uptake with a suspicious pathology, decisions were mainly dependent on CT findings. To add certainty in future studies, particularly for the neck/supraclavicular region, fine needle aspiration cytology may be required. Out of the 38 patients in whom BAT uptake was visualized, only two were imaged 60 min after injection (referred for the investigation of infection/inflammation). This did not exert a significant influence on the overall results of the study.

The use of methods to suppress ^{18}F -FDG uptake by BAT may increase the sensitivity of detection of tumour uptake, allowing a larger pool of ^{18}F -FDG to be available for lesion detection [20,21].

Although the distribution of white adipose tissue displays clear sexual dimorphism [22], the depots of BAT have similar distribution in both sexes, but the mass and activity of BAT are greater in women than in men. In the current study of 386 scans, we found substantial collections of BAT in 11.95% of female patients and 6.88% of male patients, demonstrating significantly increased prevalence of BAT in female patients, a finding that is consistent with that of other studies [8,12,16,19,22,23].

One important finding from our study is that, although the average temperatures are higher in a subtropical

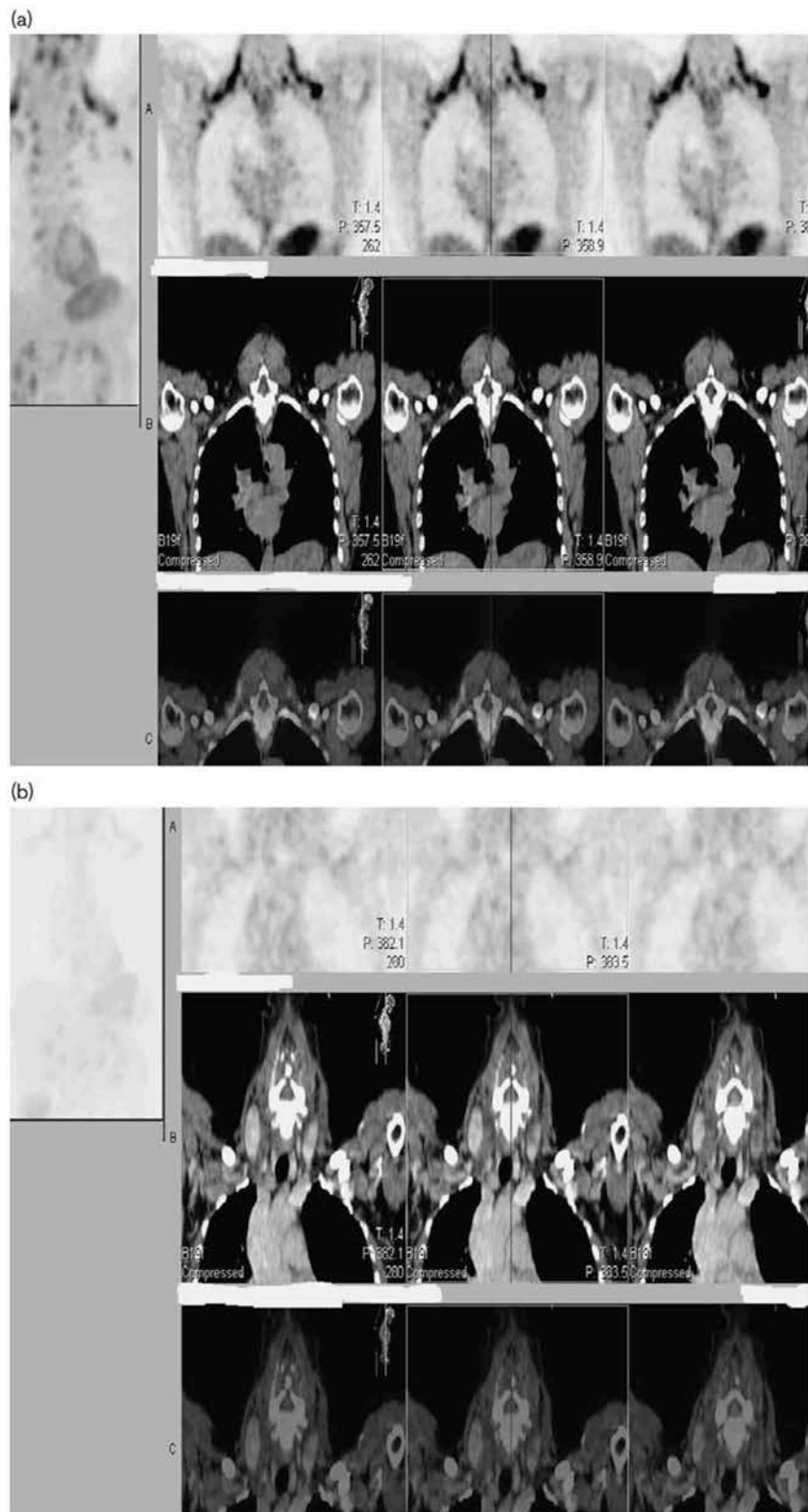
climate, a seasonal variation in BAT expression was observed. The mid-day temperatures in Pretoria range from 18.3°C in June to 27.5°C in January. It is known that the human body acclimatizes to ambient temperatures and therefore it is this change in temperature that may induce BAT activation. An important consideration regarding the observation of BAT in ^{18}F -FDG PET-CT images is whether the findings are reproducible. It is likely that the variation is dependent on the activation of BAT activity; therefore, single measurements may seriously underestimate the true prevalence of BAT in humans, as uptake would occur only if the examination is performed under conditions in which the tissue is physiologically stimulated – that is, if the patient experienced some degree of cold [18,23,24]. Cold exposure is known to promote BAT activity in both rodents and humans [20,23,24]. This would explain why BAT that is inactive in summer shows increased activity and a greater number of depots in winter. The seasonal variation is in agreement with the results by Au-Yong *et al.* [23], in whose study the effects of seasonal change on BAT activity were demonstrated.

An additional aspect of our results is that they demonstrate that the intensity of BAT activity was more pronounced in the neck and supraclavicular regions of the body, these being the sites that are more likely to be influenced by the external ambient temperature [25]. Given what is known about the thermal challenge of patients and the activation of BAT, it is also likely that the ambient room temperature during ^{18}F -FDG injection and scanning is an important factor affecting BAT activation and ^{18}F -FDG uptake. It should be borne in mind that in the present study, although outside temperatures varied throughout the year (Fig. 6), the temperature in the waiting rooms was constant at a nominal 18–20°C. In the scanning department, patients were kept warm by covering them with a blanket during the uptake time and also on the scanner bed throughout the scanning period.

Patients were not given specific instructions on the mode of dress to be worn or on the use of air conditioning in their cars. In Pretoria black patients are more likely to use public transport and hence would have to walk some distance before they can access public transport. They are also more likely to be dropped away from the hospital and would have to make their way to the hospital on foot. These patients may have greater exposure to outside weather conditions before reaching the department. However, although we studied a greater number of black patients than white, in the present study no significance difference in the intensity of ^{18}F -FDG uptake between black and white patients was observed, indicating that there was no ethnic variation.

In this study, it has been shown that BMI was inversely related to BAT ^{18}F -FDG intensity on the basis of a

Fig. 6



PET-CT images of the same patient scanned with ^{18}F -FDG on 12 May 2010 (a) and 24 January 2011 (b) showing seasonal effect on uptake in brown fat in the supraclavicular regions (coldest period covers the months of May to August).

semiquantitative measure (SUV_{max}) and was most intense in adult patients with BMI less than 18 kg/m^2 . This inverse relationship has been demonstrated by some researchers [17,18] but not by others [11,12]. Although there is no direct evidence for any involvement of BAT in physiological weight reduction, there is some evidence from whole-body calorimetric studies that women prone to obesity may have a defect of BAT-type thermogenesis. It has been shown previously in animal models that reduced BAT thermogenesis is aetiologically related to the development of diabetes and obesity [26]. It is also considered that in hypothyroidism the lipid content of BAT is increased, suggesting a reduced thermogenic activity, which seems appropriated on clinical grounds [4]. The current position on the role of BAT in thermogenesis and body-weight control in adult humans is generally becoming clearer and hence BAT has been implicated as an important mediator in the treatment of obesity and diabetes mellitus [14,26]. A better understanding of the role of functional BAT imaging will provide a stronger scientific basis for future treatment strategies, in particular with regard to obesity and diabetes mellitus [27,28].

Acknowledgements

Conflicts of interest

There are no conflicts of interest.

References

- Ronti T, Lupattelli G, Mannarino E. The endocrine function of adipose tissue: an update. *Clin Endocrinol (Oxf)* 2006; **64**:355–365.
- Rosen ED, Spiegelman BM. Adipocytes as regulators of energy balance and glucose homeostasis. *Nature* 2006; **444**:847–853.
- Symonds ME, Budge H, Perkins AC, Lomax MA. Adipose tissue development – impact of the early life environment. *Prog Biophys Mol Biol* 2011; **106**:300–306.
- Lean ME. Brown adipose tissue in humans. *Proc Nutr Soc* 1989; **48**:243–256.
- Lean ME, James WP. Brown adipose tissue in man. In: Trayhurn P, Nivholls DG, editors. *Brown adipose tissue*. London, UK: Edward Arnold; 1986. pp. 339–365.
- Nedergaard J, Bengtsson T, Cannon B. Unexpected evidence of active brown adipose tissue in adult humans. *Am J Physiol Endocrinol Metab* 2007; **293**:E444–E452.
- Virtanen KA, Lidell ME, Orawa J, Heglind M, Westergren R, Niemi T, et al. Functional brown adipose tissue in healthy adults. *N Engl J Med* 2009; **360**:1518–1525.
- Cypess AM, Lehman S, Williams G, Tal I, Rodman D, Allison B, et al. Identification and importance of brown adipose tissue in adult humans. *N Engl J Med* 2009; **360**:1509–1517.
- Chang JM, Lee HJ, Goo JM, Lee HY, Chung JK, Im JG. False-positive and false-negative FDG-PET/scans in various thoracic diseases. *Korean J Radiol* 2006; **7**:57–69.
- Griffiths LK. Use of PET/CT scanning in cancer patients: technical and practical considerations. *Proc (Bayl Univ Med Cent)* 2005; **18**: 321–330.
- Cohade C, Osman M, Pannu HK, Wahl RL. Update in supraclavicular area fat ('USA-Fat'): description on ^{18}F -FDG PET/CT. *J Nucl Med* 2003; **44**:170–171.
- Henry WD, Teung MD, Ravinder K, Grewal MD, Mithat G, Heiko S, Steven ML. Pattern of ^{18}F -FDG uptake in adipose tissue and muscle: a potential source of false-positives for PET. *J Nucl Med* 2003; **44**:1789–1796.
- Tatsumi M, Engles JM, Ishimori T, Nicely O'B, Cohade C, Wahl RL. Intense ^{18}F -FDG uptake in brown adipose fat can be reduced pharmacologically. *J Nucl Med* 2004; **45**:1189–1193.
- Basu S. Functional imaging of brown adipose tissue with PET: can this provide new insights into the pathophysiology of obesity and thereby direct antiobesity strategies. *Nucl Med Commun* 2008; **29**:931–933.
- Lin D, Jacobs M, Percy T, Dowdy Y, Mantil J. High 2-deoxy-2(F-18)fluoro-D-glucose uptake on positron emission tomography in hibernoma originally thought to be myxoid liposarcoma. *Mol Imaging Biol* 2005; **7**:2001–2002.
- Engel H, Steinert H, Buck A, Berthold T, Huch BR, von Schulthess G. Whole-body PET. Physiology and actual fluorodeoxyglucose accumulation. *J Nucl Med* 1996; **37**:441–446.
- Hany T, Gharehpapagh E, Kamel E, Buck A, Himms-Hagen J, von Schulthess G. Brown adipose tissue: a factor to consider in symmetrical tracer uptake in the neck and upper chest region. *Eur J Nucl Med Mol Imaging* 2006; **29**:1393–1398.
- Saito M, Okamatsu-Ogura Y, Matsushita M, Watanabe K, Yoneshiro T, Nio-Kobayashi J, et al. High incidence of metabolically active brown adipose tissue in healthy adult humans. *Diabetes* 2009; **58**:1526–1531.
- Truong MT, Erasmus JJ, Munden RF, Marom EM, Sabloff BS, Gladish GW, et al. Focal FDG uptake in mediastinal brown fat mimicking malignancy: a potential pitfall resolved on PET/CT. *Am J Roentgenol* 2004; **183**: 1127–1132.
- Barrington SF, Maisey MN. Skeletal muscle uptake of fluorine- ^{18}F -FDG: effect of oral diazepam. *J Nucl Med* 1996; **37**:1127–1129.
- Williams G, Kolodny GM. Method for decreasing uptake of ^{18}F -FDG by hypermetabolic brown adipose tissue on PET. *Am J Roentgenol* 2008; **190**:1406–1409.
- Cannon B, Nedergaard J. Brown adipose tissue: function and physiological significance. *Physiol Rev* 2004; **84**:277–359.
- Au-Yong ITH, Thorn N, Ganatra R, Perkins AC, Symonds ME. Brown adipose tissue and seasonal variation in humans. *Diabetes* 2009; **58**:2583–2587.
- Van Marken Lichtenbelt WD, Vanhommerig JW, Smulders NM, Drossaerts JN, Kemerink GJ, Bouvy ND, et al. Cold-activated brown adipose tissue in healthy men. *N Engl J Med* 2009; **360**:1500–1508.
- Hutunen P, Hirvonen J, Kinula V. The occurrence of brown adipose tissue in outdoor workers. *Eur J Appl Physiol Occup Physiol* 1981; **46**:339–345.
- Lowell BB, S-Susulic V, Hatmann A, Lawitts JA, Himms-Hagen J, Boyer BB, et al. Development of obesity in transgenic mice after genetic ablation of brown adipose tissue. *Nature* 1993; **365**:740–742.
- Virtanen KA, Nuutila P. Functional imaging of brown adipose tissue. *Heart Metab* 2010; **48**:15–17.
- Chen YI, Cypess AM, Sass CA, Brownell A-L, Jokivarsi K, Kahn CR, Kwong KK. Anatomical and functional assessment of brown adipose tissue by magnetic resonance imaging. *Obesity (Silver Spring)* 2012; **20**: 1519–1526.