

## RESEARCH COMMUNICATION

# Bovine besnoitiosis: transfer of colostral antibodies with observations possibly relating to natural transmission of the infection

VARDA SHKAP, E. PIPANO, S. MARCUS and Y. KRIGEL

Kimron Veterinary Institute, Beit Dagan, P.O. Box 12, Beit Dagan, 50250 Israel

### ABSTRACT

SHKAP, V., PIPANO, E., MARCUS, S. & KRIGEL, Y. 1994. Bovine besnoitiosis: transfer of colostral antibodies with observations possibly relating to natural transmission of the infection. *Onderstepoort Journal of Veterinary Research*, 61:273–275

Colostral antibodies to *B. besnoiti* were detected by immunofluorescence in four calves born to two *Besnoitia*-infected dams, with titres ranging from 1:64 to 1:1024. A specific antibody titre of 1:1024 was found in colostrum collected from one of the dams. Two of the newborn calves, when sampled immediately after birth, were serologically negative to *B. besnoiti*, but became positive on the next day. In all the calves, antibodies were detectable up to the age of 4 months. Observations concerning passive transfer of antibodies from *Besnoitia*-infected dams to offspring, and transmission of the infection among infected and non-infected closely kept cows, are discussed.

### INTRODUCTION

Bovine besnoitiosis is a protozoan disease that causes serious losses to the cattle industry in some areas of Africa and Asia (Bigalke 1981). The disease is encountered mainly in a chronic form with scleroderma, seborrhea and alopecia as predominant clinical signs, accompanied by poor general condition. The causative agent, *Besnoitia besnoiti*, forms numerous cysts in the fascia of the muscles, the subcutis (Schulz 1960; Basson, McCully & Bigalke 1970), and in various internal organs (Nobel, Neumann, Klopfer & Perl 1977; Bargay, Nobel & Perl 1984). The complete life cycle of this species—in particular the man-

ner of transmission—is not yet clear (Diesing, Heydorn, Matuschka, Bauer, Pipano, De Waal & Potgieter 1988), though in other members of this group (*Toxoplasma gondii*, *Sarcocystis*), intermediate mammalian vectors are involved (Fayer 1980; Tadros & Laarman 1982). Circulating *B. besnoiti* antibodies have been detected in cattle, following natural and artificial infection (Frank, Pipano & Rosenberg 1977; Goldman & Pipano 1983; Shkap, Ungar-Waron, Pipano & Greenblatt 1984).

The present paper concerns passive transfer of antibody, by colostrum, to calves born to dams infected with *B. besnoiti*.

A mixed-breed cow (no. 438) exhibiting symptoms of chronic besnoitiosis, was spotted in a field-grazing beef herd. The animal suffered from an advanced

TABLE 1 Antibody titres in *Besnoitia besnoiti*-infected cows and their offspring

Dams		Calves			
No.	Antibody titre <sup>a</sup> on day of calving	No.	Antibody titre <sup>a</sup> on days after birth		
			0	1	2
438	> 1024	495	Negative	64	64
438	> 1024	581	256	256	256
438	> 1024	751	256	1024	1024
17	256	61	Negative	512	512

<sup>a</sup> Reciprocal antibody titre by indirect fluorescent antibody test

stage of generalized scleroderma accompanied by alopecia on large areas of the body, and numerous cysts were seen on the conjunctival sclera of the eyes. The cow was transferred to the experimental shelter-paddock of the Kimron Veterinary Institute and was found to be positive for *B. besnoiti* antibodies at 1:1024 titre, by the indirect immunofluorescent antibody test (IFA) described by Goldman & Pipano (1983). The cow was about 2 months pregnant at the time. About 3 months after calving (calf 495), the cow was artificially inseminated and she calved again (calf 581). This was repeated once more and a third calf was born (calf 751). After cow 438 had been slaughtered, numerous typical thick-walled *B. besnoiti* cysts (Schulz 1960) were observed in histological preparations of skin tissues and subcutis.

Another cow (cow 17) affected by besnoitiosis was spotted in a different beef herd and was also found to be positive for *B. besnoiti* antibodies at 1:1024 titre. A few months after transfer to the Institute, the cow calved (calf 61). All calves born to the two infected dams were in excellent condition and developed normally. They were kept with their mothers for 2–8 months after birth. By that time the dams had improved dramatically under barn conditions and the alopecia had disappeared, though numerous cysts still remained on the scleral conjunctiva.

The antibody titres of the dams and their calves are shown in Table 1.

Two of the newborn calves (495 and 61) were found to be negative at first sampling right after birth, while the other two (581 and 751) showed IFA titres of 1:256. It can be assumed that the latter had ingested colostrum before the blood was drawn. Colostrum collected from dam 438 immediately after she had given birth, was tested serologically. The fat in the colostrum was removed by centrifugation at 1 500 g at 4 °C, and 1% rennet was added (Cohen & Trainin 1969). An antibody titre of 1:1024 to *B. besnoiti* was found in the colostrum. All calves showed high titres on the second and the third days after birth. In three

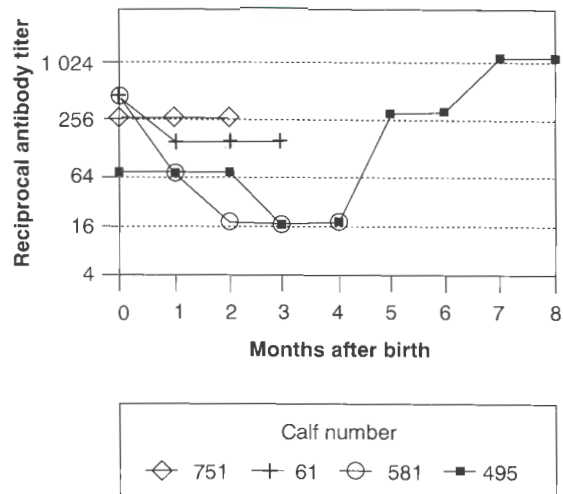


FIG. 1 Fluorescent antibody titres in calves born to *B. besnoiti*-infected dams kept together for 8 months after birth

calves, 581, 751 and 61, antibodies were detectable until at least 2–4 months after birth (Fig. 1).

In calf 495, the antibody titre gradually dropped from 1:512 to 1:16 during the 2–4-month period, and then rose to 1:1024 during the 7–8-month period, the longest length of time tested. The maximum titre was recorded at the beginning of August. No cysts on the sclera, or other signs of besnoitiosis could be detected in this calf.

In a separate observation, two Friesian cows originating from a besnoitiosis-free dairy farm were kept in an enclosure separated from that of a naturally infected cow (cow 438) by a row of iron bars. Under these circumstances, a limited degree of physical contact such as touching, rubbing and licking, was possible. The Friesian cows showed no clinical signs of besnoitiosis for about a year. During the second half of September, cysts were detected on the sclera of one of the cows and serologic examination by IFA revealed a 1:1024 *B. besnoiti* titre.

In a field survey conducted by Goldman & Pipano (1983), a considerable proportion of beef cows possessed antibody titres up to 1:1024 against *B. besnoiti*, despite the fact that only a few of them showed clinical signs of besnoitiosis. In the light of the present observations, it is likely that the dams could have transferred antibodies to their offspring. It is unclear, however, whether such antibodies can protect the calves against natural exposure to *B. besnoiti*. Experience of over 20 years in Israel teaches that the proportion of imported European bulls contracting clinical besnoitiosis is considerably greater than that in the locally born bulls. It seems likely that most of the local animals acquire partial protection by passive immunity, when they are exposed to *B. besnoiti* infection in the field. Antibodies that are transferred through colostrum and confer various degrees of protection have been reported in final and intermediary ruminant hosts of coccidian parasites (Fayer, Andrews, Ungar & Blagburn 1989; Fiege, Klatte, Kollmann, Zahner & Burger 1992; Zu, Fang, Fayer & Guerrant 1992).

It has been reported that besnoitiosis-free cattle have contracted the disease when kept in close contact with infected cattle (Hofmeyer 1945; Bigalke 1968). This might be a possible explanation for the rise of antibody titre in calf 495, accompanied by an asymptomatic infection, and for the spontaneous infection in one of two healthy Friesian cows that were kept close to the naturally infected cow. These observations, together with the well-known activity of biting flies beginning from May to October, reinforce the conclusion (Bigalke 1968) that the summer seasonal incidence of besnoitiosis is associated with mechanical transfer of the disease by blood-sucking arthropods.

Bulls, parasitized with numerous cysts, often suffer testicular degeneration followed by sterility (Pols 1960; Bargay *et al.* 1984). On the other hand, from the very restricted experience reported here, it appears that the fertility of heavily infected cows is not affected, despite the fact that cysts may also develop in tissues of the uterus (Nobel *et al.* 1977).

## REFERENCES

- BARGAY, U., NOBEL, T. & PERL, S. 1984. Radiographic changes in testes of bulls infected with besnoitiosis. *Veterinary Radiology*, 25:235–239.
- BASSON, P., McCULLY, R. & BIGALKE, R. 1970. Observations on the pathogenesis of bovine and antelope strains of *Besnoitia besnoiti* (Marotel, 1912) infection in cattle and rabbits. *Onderstepoort Journal of Veterinary Research*, 2:105–126.
- BIGALKE, R. 1968. New concepts on the epidemiological features of bovine besnoitiosis as determined by laboratory and field investigations. *Onderstepoort Journal of Veterinary Research*, 35:3–139.
- BIGALKE, R. 1981. Besnoitiosis and globidiosis, in *Diseases of cattle in the tropics*, edited by Ristic, M. & McIntyre, I. The Hague, Boston, London: Martinus Nijhoff Publishers: 429–441.
- COHEN, R. & TRAININ, Z. 1969. Serum gamma-globulin levels of newborn calves in two dairy herds and some observations on the effect of prophylactic administration of gamma-globulin preparations. *Refuah Veterinarith*, 26:18–25.
- DIESING, L., HEYDORN, A., MATUSCHKA, F., BAUER, C., PIPANO, E., DE WAAL, D. & POTGIETER, F. 1988. *Besnoitia besnoiti*: studies on the definitive host and experimental infections in cattle. *Parasitology Research*, 75:114–117.
- FAYER, R. 1980. Epidemiology of protozoan infections: the coccidia. *Veterinary Parasitology*, 6:75–103.
- FAYER, R., ANDREWS, C., UNGAR, B. & BLAGBURN, B. 1989. Efficacy of hyperimmune bovine colostrum for prophylaxis of cryptosporidiosis in neonatal calves. *Journal of Parasitology*, 75:393–397.
- FIEGE, N., KLATTE, D., KOLLMANN, D., ZAHNER, H. & BURGER, H.-J. 1992. *Eimeria bovis* in cattle: colostral transfer of antibodies and immune response to experimental infections. *Parasitology Research*, 78:32–38.
- FRANK, M., PIPANO, E. & ROSENBERG, A. 1977. Prevalence of antibodies against *Besnoitia besnoiti*. *Refuah Veterinarith*, 3:83–85.
- GOLDMAN, M. & PIPANO, E. 1983. Serological studies of bovine besnoitiosis in Israel. *Tropical Animal Health and Production*, 15:32–38.
- HOFMEYER, C. 1945. Globidiosis in cattle. *Journal of South African Veterinary Medical Association*, 16:102–109.
- NOBEL, T., NEUMANN, M., KLOPFER, U. & PERL, S. 1977. Kystes de la *Besnoitia besnoiti* dans les organes genitaux de la vache. *Bulletin de L'Academie Veterinaire de France*, 50:569–574.
- POLS, J. 1960. Studies on bovine besnoitiosis with special reference to the aetiology. *Onderstepoort Journal of Veterinary Research*, 28:265–356.
- SCHULZ, K. 1960. A report on naturally acquired besnoitiosis in bovines with special reference to its pathology. *Journal of South African Veterinary Medical Association*, 31:21–35.
- SHKAP, V., UNGAR-WARON, H., PIPANO, E. & GREENBLATT, C. 1984. Enzyme-linked immunosorbent assay for detection of antibodies against *Besnoitia besnoiti* in cattle. *Tropical Animal Health and Production*, 16:233–238.
- TADROS, W. & LAARMAN, J. 1981. Current concept on the biology evolution and taxonomy of tissue cyst-forming eimeriid coccidia. *Advances in Parasitology*, 20:294–468.
- ZU, S.-X., FANG, G.-D., FAYER, R. & GUERRANT, R. 1992. Cryptosporidiosis: pathogenesis and immunology. *Parasitology Today*, 8:24–27.