

THE LEUCOCYTOZOIDAE OF SOUTH AFRICAN BIRDS: PASSERIFORMES

G. F. BENNETT⁽¹⁾, R. A. EARLÉ⁽²⁾ and M. A. PEIRCE⁽³⁾

ABSTRACT

BENNETT, G. F., EARLÉ, R. A. & PEIRCE, M. A., 1992. The Leucocytozoidae of South African birds: Passeriformes. *Onderstepoort Journal of Veterinary Research*, 59, 235–247 (1992)

The leucocytozoids of ten families of Passeriformes—Estrildidae, Fringillidae, Laniidae, Nectariniidae, Passeridae, Ploceidae, Promeropidae, Pycnonotidae, Sturnidae and Zosteropidae—are reviewed. *Leucocytozoon roubaudi* from the Estrildidae, *L. fringillinarum* from the Fringillidae, *L. balmorali* from the Laniidae, *L. gentili* from the Passeridae, *L. bouffardi* from the Ploceidae, *L. brimonti* from the Pycnonotidae and *L. zosteropis* from the Zosteropidae are re-described. *Leucocytozoon dutoiti*, *L. nectariniiae*, *L. deswardti*, *L. pycnonoti* and *L. sturni* are new species described from the Fringillidae (Carduelinae), Nectariniidae, Promeropidae, Pycnonotidae and Sturnidae respectively while *L. monardi* is considered to be a synonym of *L. gentili* and *L. molpastis* is considered to be a synonym of *L. brimonti*.

INTRODUCTION

The order Passeriformes is a vast order containing about two thirds of the modern birds. They occupy virtually every possible terrestrial habitat and show an unequalled diversity of nesting, feeding and other behavioural characteristics. The order has long been the subject of intensive ornithological study and is the mainstay of the large body of amateur naturalists who have studied their every move. The birds are usually relatively easy to trap or net and as a result, their haematozoan parasites are well studied in comparison to other avian groups. Of the 54 passeriform families examined for blood parasites, 44 families harboured leucocytozoids (Bennett, Whiteway & Woodworth-Lynas, 1982). However, of the 96 described species of leucocytozoids, only 27 are from passeriforms (Bennett *et al.* 1982), indicating that even here there is still much study to be carried out on the systematics of the leucocytozoids of this avian order.

In sub-Saharan Africa, passeriforms are a major portion of the avifauna. However, many other avian species have greater economic importance and their haematozoa have received considerably more attention than those of the passeriforms. This is particularly true of the leucocytozoids. Eleven of the 19 species of leucocytozoid originally described from the Phasianidae were from African birds (Bennett, Earlé, Peirce, Huchzermeyer & Squires-Parsons, 1991) but only three passerine leucocytozoids—*Leucocytozoon bouffardi* Leger & Blanchard, 1911 (from the Ploceidae) *L. zosteropis* Peirce, Cheke & Cheke, 1977 (from the Zosteropidae) and *L. balmorali* Peirce, 1984 (from the Laniidae)—have been described from African material. In this present study, these three species are re-described, using the criteria recently established by Bennett *et al.* (1991) for the diagnoses of *Leucocytozoon*. Additionally, *Leucocytozoon brimonti* Mathis & Leger, 1910

from the Pycnonotidae, *L. roubaudi* Mathis & Leger, 1911 from the Estrildidae, *L. gentili* Leger, 1913 from the Passeridae and *L. fringillinarum* Woodcock, 1910 from the Fringillidae are also re-described. New species of *Leucocytozoon* are described from the Fringillidae (Carduelinae), Nectariniidae, Promeropidae, Pycnonotidae and Sturnidae. *Leucocytozoon monardi* of the Passeridae and *L. molpastis* of the Pycnonotidae are considered as synonyms of *L. gentili* and *L. brimonti* respectively.

It is generally accepted that Leucocytozoidae show host familial specificity as Fallis, Desser & Khan (1974) showed that eight of the nine species of *Leucocytozoon* studied were host family specific while the ninth, *Leucocytozoon fringillinarum*, might have a broader host range. This latter assumption was based on morphology rather than experimental transmission. Bennett & Campbell (1975), acting on this suggestion, synonymized all the leucocytozoids of the "sparrows" (Emberizidae, Estrildidae, Fringillidae, Passeridae, Ploceidae) with *L. fringillinarum*. In this they were premature as recent re-evaluations of these ornithological groupings (American Ornithologists' Union, 1983; Edwards, 1986) have clearly delineated them as separate entities with different phylogenetic associations. This is particularly true of the Emberizidae which (i) used to be a sub-family of the Fringillidae but are now a separate family and (ii) have had five New World families included as sub-families. It would seem wise, therefore, to retain the demonstrated concept of host familial specificity until such time as the systematics of the Passeriformes are finalized and experimental evidence proves contrary. Therefore, species synonymized by Bennett & Campbell (1975) with *L. fringillinarum* are herein resurrected from synonymy and re-described. The leucocytozoids of the now primarily New World family Emberizidae will be treated separately.

MATERIALS AND METHODS

Materials used in this study were deposited in the collection of the International Reference Centre for Avian Haematozoa by collaborators around the world or were collected by the authors. The blood smears were initially air-dried and then either fixed with 100% methanol/ethanol or with May-Grünwald-Giemsa. Material was either stained on location with Giemsa's stain or subsequent to receipt at the Centre. The morphological characteristics and

⁽¹⁾ International Reference Centre for Avian Haematozoa, Memorial University of Newfoundland, St. John's, NF, Canada, A1B 3X9 and FRD International Visiting Fellow, Department of Parasitology, Faculty of Veterinary Science, Onderstepoort 0110, Republic of South Africa

⁽²⁾ Department of Parasitology, Faculty of Veterinary Science, Private Bag X04, Onderstepoort 0110, Republic of South Africa, to whom correspondence should be addressed

⁽³⁾ 16 Westmorland Close, Woosehill, Wokingham, Berks. RG11 9AZ, United Kingdom

Received 15 July 1992—Editor

derived ratios (Bennett *et al.*, 1991) were obtained by drawing the appropriate cell with the aid of a camera lucida and determining the lengths and areas with the aid of a Zeiss MOP-3 Digital Analyzer. As initially stated by Bennett *et al.* (1991), microgametocytes were subject to the same scrutiny as were the macrogametocytes. In most cases, the morphology was closely similar and the two sets of measurements were also similar with the exception of the large nucleus of the microgametocyte, so typical of apicomplexan parasites. In the interests of brevity, the measurements of the microgametocytes are not included but if major variation from the macrogametocyte was noted, this is cited in text. Photomicrographs were taken with a Zeiss Photomicroscope III. All hapantotype, parahapantotype and other material used in these descriptions is deposited in the collection of the International Reference Centre for Avian Haematozoa.

TAXONOMIC REVIEW

FAMILY ESTRILIDAE

Leucocytozoon roubaudi Mathis & Leger, 1911

Type host: the spotted munia, *Munia topela* [= *Lonchura punctulata* (L.)]

Type locality: Hanoi (= Haiphong), North Vietnam.

Macrogametocyte (Fig. 1–3; Table 1). Parasite with round morph only. Parasite small, round to broadly ovoid, occupying 77 % of the area of the host cell-parasite complex; parasite nucleus relatively large, round to elliptical, without marked karyosome, occupying 8.5 % of the area of the parasite; cytoplasm with a few small vacuoles, volutin granules uncommon; nucleus of the host cell variable, usually as a band but sometimes as a slight cap, covering 61 % of the periphery of the parasite and occupying 23 % of the area of the host cell-parasite complex.

Microgametocyte (Fig. 4). Morphology of the microgametocyte similar to that of the macrogametocyte but parasite is 10–15 % smaller in most dimensions.

Basis of re-description. Neohapantotype: blood film No. 40844 from the chestnut munia *Lonchura malacca* (L.), collected by McClure, Negros, Philippine Islands, 1 September 1965. Paraneohapantotype: blood film No. 46831 from the green-winged pytilia *Pytilia melba*, collected by Peirce, Ngulia, Kenya, 16 December 1974; blood film No. 92477 from the paradise whydah *Vidua paradisea*, collected by Peirce, Balmoral, Zambia, 15 August 1981.

Additional host records and distribution. All leucocytozoid records attributed to estrilids by Bennett *et al.* (1982) can be considered to be *Leucocytozoon roubaudi*. Presumably the parasite is distributed throughout the range of the Old World family Estrilidae.

Comments. *Leucocytozoon roubaudi* is one of the many small, round leucocytozoids without many distinctive features that occur throughout the passeriform families. The species was described from a south-eastern Asian estrilid when this group was a sub-family of the Ploceidae. Consequently, it was

considered as a possible synonym of *L. bouffardi* of the Ploceidae, and was reduced to a synonym of *L. fringillinarum* by Bennett & Campbell, 1975. It is here resurrected from synonymy and considered to be the valid leucocytozoid of the avian family Estrilidae on the basis of both its morphology (the proportion of the periphery of the parasite covered by the host cell nucleus is 50 % greater than that for *L. fringillinarum* and the parasite nucleus is 25 % larger) and its assumed host family specificity. In as much as these birds are easy to keep and manipulate in captivity, it should be relatively easy to experimentally prove whether this parasite can be transmitted to other "sparrows". The species is relatively abundant in South Africa and ornithophilic blackflies are also abundant and the solution of this problem is presented as a challenge to African parasitologists and ornithologists.

Mathis & Leger (1911) made no comments as to the deposition of their material and it is presumed lost as the Curator of the Protozoological collection of the National Museum of France is unaware if the material is present in the national collection. A neohapantotype has been designated from *Lonchura malacca* from the Philippines, the only lonchurid in the collection of the International Reference Centre that was satisfactory for systematic designation. This estrilid has a widespread distribution throughout eastern Asia and occurs in Vietnam. The measurements of *L. roubaudi* from this bird were well within (i) the measurements presented for the species by Mathis & Leger (1911) and (ii) were within \pm one standard deviation of the measurements of the paraneohapantotypes which were obtained from African material.

FAMILY FRINGILLIDAE

SUBFAMILY CARDUELINAE

Leucocytozoon dutoiti n. sp.

Type host: streaky-headed canary *Serinus gularis* (Smith)

Type locality: Paardeplaats, Transvaal, Republic of South Africa.

Macrogametocyte (Fig. 5–7, Table 1). Parasite with round morph only. Parasite of medium size, occupying about 80 % of the area of the host cell-parasite complex, round to broadly ovoid; parasite nucleus round to broadly ovoid or piriform, occupying almost 7 % of the area of the parasite, karyosome not pronounced; cytoplasm with small vacuoles and volutin granules although few, usually present; nucleus of host cell-parasite complex either as a band (Fig. 6) or as a marked cap (Fig. 5), covering 50 % of the periphery of the parasite and occupying 20 % of the area of the host cell-parasite complex.

Microgametocyte (Fig. 8, 9). Parasite closely similar in morphology to the macrogametocyte but averaging about 5 % smaller in all dimensions. The microgametocyte has a remarkably large parasite nucleus which occupies nearly 40 % of the area of the parasite.

Basis of description. Hapantotype. Blood film No. 118401 from the streaky-headed canary *Serinus*

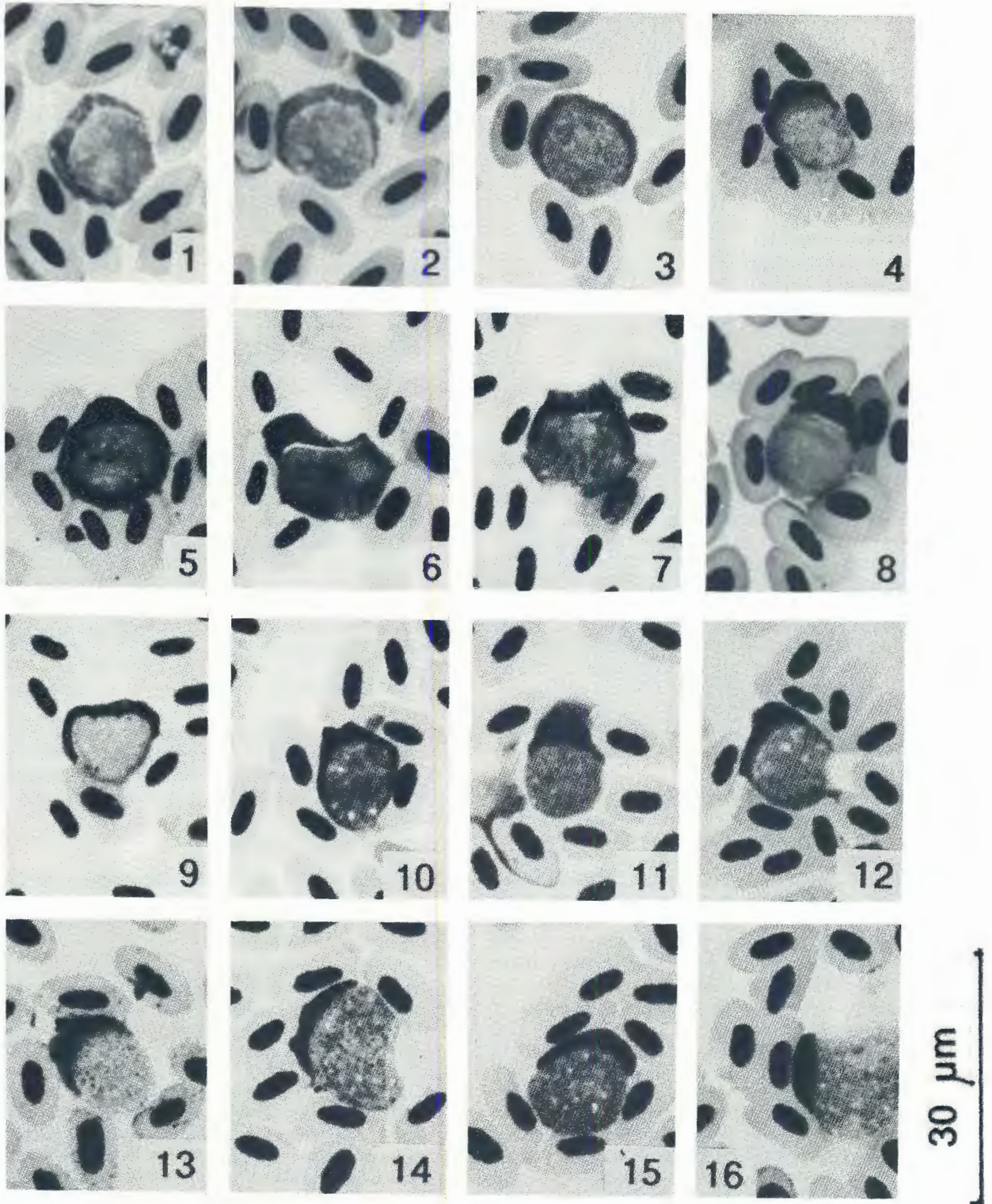


FIG. 1-4 *Leucocytozoon roubaudi*. Fig. 1-3, macrogametocytes; Fig. 4, microgametocyte

FIG. 5-9 *Leucocytozoon dutoiti*. Fig. 5-7, macrogametocytes; Fig. 8-9, microgametocyte

FIG. 10-13 *Leucocytozoon fringillinarum*. Fig. 10-12, macrogametocyte; Fig. 13, microgametocyte

FIG. 14-17 *Leucocytozoon balmorali*. Fig. 14, 15, round macrogametocytes; Fig. 16, fusiform macrogametocyte; Fig. 17, fusiform microgametocyte

TABLE 1 Morphometric parameters (in μm) of the leucocytozoids of the Estrildidae, Fringillidae and Laniidae

N =	<i>roubaudi</i> 45	<i>dutoiti</i> 115	<i>fringillinarum</i> 55	<i>balmorali</i> 30
Parasite and nucleus				
Maximum diameter	14,1 (1,6)	12,2 (1,6)	11,5 (0,9)	14,3 (1,4)
Minimum diameter	10,3 (1,9)	10,6 (1,1)	10,4 (1,0)	11,1 (1,2)
Periphery of parasite	39,7 (4,0)	36,2 (4,0)	34,8 (2,8)	36,4 (6,2)
Area of parasite	117,3 (24,7)	102,3 (20,8)	91,9 (14,2)	134,3 (16,4)
Maximum width nucleus	4,3 (0,9)	3,6 (0,8)	3,2 (0,7)	4,6 (0,8)
Minimum width nucleus	2,9 (0,6)	2,6 (0,6)	2,3 (0,4)	2,8 (0,6)
Area of nucleus	10,3 (3,6)	7,1 (2,8)	5,5 (1,9)	10,0 (2,6)
Host cell-parasite complex				
Maximum diameter or length	15,8 (1,5)	14,4 (1,8)	13,7 (1,0)	20,1 (2,1)
Minimum diameter or length	12,2 (2,2)	11,8 (1,5)	11,1 (1,1)	13,7 (1,5)
Area of complex	152,2 (27,7)	130,3 (27,2)	116,1 (14,9)	184,2 (25,4)
Parasite periphery covered by complex nucleus	24,3 (2,9)	18,4 (3,9)	15,1 (1,5)	12,1 (2,5)
Area of complex nucleus	35,2 (7,1)	28,5 (8,5)	24,2 (4,7)	23,5 (6,0)

N = sample size; means followed by standard deviation in parentheses. Measurements from *L. balmorali* are from fusiform parasites

gularis, collected by De Swardt at Paardeplaats, Transvaal, Republic of South Africa on 4 October 1991. Parahapantotypes: blood film No. 21123 from the house finch *Carpodacus mexicanus* collected by Herman in Kern Co., California on 2 May 1946; blood film No. 68782 from the purple finch *Carpodacus purpureus* collected by Bennett in Algonquin Park, Ontario, Canada on 17 July 1958; blood film No. 92347 from the yellow-eyed canary *Serinus mozambicus* by Peirce at Copper Chalice, Zambia on 16 March 1980; blood film No. 98698 from the Eurasian siskin *Carduelis spinus* collected by Fallis at Rendalen, Norway on 8 July 1968; blood film No. 118702 from the black-throated canary *Serinus atrogularis*, collected by Earlé at Buffelsdrift, Pretoria, Transvaal, Republic of South Africa on 10 January 1992.

Distribution and additional hosts. This parasite is known from a broad holarctic and African distribution of the cardueline finches. Presumably all records of leucocytozoids from cardueline finches (Bennett *et al.*, 1982) can be ascribed to this species and the distribution of the parasite will correspond to the distribution of the hosts. Curiously, few leucocytozoids have been reported from species of the genus *Carduelis* at this time. Most records stem from species of *Acanthis*, *Carpodacus* and *Serinus*.

Comments. *Leucocytozoon dutoiti* is another of the small, round leucocytozoids that occur so frequently in the Passeriformes. It is considered to be distinct from *Leucocytozoon fringillinarum* of the Fringillinae on the basis that it is larger in all dimensions, particularly in area of the parasite and the area of the host cell-parasite complex. Moreover, while sharing a certain number of morphological characters in common, the host complex nucleus cap has a different appearance from that seen *L. fringillinarum*, in that the cap tends to have a less pronounced cap (frequently two small caps as in Fig. 6, 7) or extends more completely around the parasite (Fig. 9).

The cardueline finches are considered by most authors (American Ornithologists' Union, 1983; Campbell & Lack, 1985; Maclean, 1985) to be a

subfamily of the Fringillidae, and this view is adopted here, although Edwards (1986) considers these finches to be a subfamily of the Emberizidae. We are assuming host familial specificity at the subfamilial level (Bennett *et al.*, 1991) and therefore consider *L. dutoiti* separate from *L. fringillinarum*, not only on the basis of its morphology but on the basis that it occurs in a distinct subfamily that may even be associated with a different family. Experimental cross-transmissions are needed to clarify this point. However, the avian species involved are relatively easy to maintain in captivity and such experiential taxonomy should be relatively easy to carry out.

The species is named after Ms. Hester du Toit of the National Museum in Bloemfontein who has contributed greatly to our knowledge of the haematozoa of South African birds through her zeal in collecting material.

SUBFAMILY FRINGILLINAE

Leucocytozoon fringillinarum Woodcock, 1910

Type host: the chaffinch, *Fringilla coelebs* L.

Type locality: England.

Macrogametocyte (Fig. 10, 11, Table 1). Parasite with round morph only. Parasites generally small and typically round, rather than ovoid, occupying 80 % of the area of the host cell-parasite complex; parasite nucleus usually round, but sometimes ovoid to elliptical, without marked karyosome, occupying 6 % of the area of the parasite; cytoplasm with vacuoles, sometimes pronounced and volutin granules occasionally present (when present, numerous); nucleus of host cell as a cap (the most typical feature of this species), covering 43 % of the periphery of the parasite and occupying 21 % of the area of the host cell-parasite complex.

Microgametocyte (Fig. 13). The morphology and measurements virtually identical with the macrogametocytes.

Basis of re-description. Neohapantotype: blood film No. 98636 from the chaffinch *Fringilla coelebs* collected by Fallis, Rendalen, Norway, 7 July 1968.

Paraneohapantotype: blood film No. 98639 from *Fringilla coelebs*, collected by Fallis, Rendalen, Norway, 5 July 1968; blood film No. 98575 the brambling *Fringilla montifringilla*, collected by Fallis, Rendalen, Norway, 11 July 1968.

Additional host records and distribution. All records for *Leucocytozoon* from the Fringillidae *sensu stricto* should be referred to this species. The parasite is distributed over the Old World distribution of the Fringillidae. The many records of *L. fringillinarum* from non-fringillid hosts (as seen in Bennett *et al.* 1982, for example) are in error. These leucocytozoids should be referred to the appropriate species for that avian family.

Sporogony. Presumably in ornithophilic simuliids as demonstrated for all other species of *Leucocytozoon* studied. The comments by Bennett (1960), Fallis & Bennett (1962) and others quoting this work that sporogony was noted in a series of ornithophilic simuliids in Algonquin Park, Ontario are in error as Bennett was not dealing with *L. fringillinarum* but with *L. cambournaci* Franca, 1912 of the Emberizidae.

Comments. *Leucocytozoon fringillinarum* is the classic round leucocytozoid with the host cell nucleus forming a distinct cap that has been quoted throughout the literature. Most round leucocytozoids are compared to it and frequently, any round leucocytozoid with a cap is identified as *L. fringillinarum*, regardless of the avian family to which the host bird belongs. This has engendered considerable confusion in the past and has led to the belief that this species has a broad host spectrum and no specificity (jumping even ordinal boundaries). Unfortunately, there have been no experimental studies to confirm that this species does, in fact, cross familial boundaries routinely. *Leucocytozoon fringillinarum* is one of the smaller leucocytozoids and is a parasite that is usually round. The host cell nearly always forms a prominent cap-like band that covers only 43 % of the periphery of the parasite.

The deposition of Woodcock's material is unknown and a neohapantotype has been designated. Unfortunately, no adequate material from the type host is currently available from the United Kingdom, so a blood film from the type host from Rendalen, Norway has been designated. The chaffinch is widely distributed in the western Palaearctic region.

Recently, the Fringillidae have undergone a major reorganization and the subfamily Fringillinae contains only three species (Edwards, 1986), including the type host, *Fringilla coelebs*, of *Leucocytozoon fringillinarum*. The family Fringillidae also contains the subfamily Carduelinae according to the American Ornithologists' Union (1983) and to Campbell & Lack (1985).

FAMILY LANIIDAE
SUBFAMILY MALACOTINAE

***Leucocytozoon balmorali* Peirce, 1984**

Type host: the black-backed puff back shrike, *Dryoscopus cubla* (Shaw).

Type locality: Balmoral, Zambia.

Macrogametocyte (Fig. 14–16, Table 1). Parasite with round and fusiform morphs. Round morph (Fig. 14, 15). Parasites too few to measure. Description adapted from Peirce (1984). Cytoplasm stains dark blue with purple volutin granules scattered throughout; vacuoles present in some parasites; parasite nucleus often difficult to see; host cell nucleus forms either a cap-like structure or is a band stretching at least 50 % about the periphery of the parasite; the round forms (N=20) averaged 11.99 (10.6–14.1) μm in diameter. Fusiform morph (Fig. 16). Parasites generally large, broadly ovoid, rarely round; occupying 73 % of the area of the host cell-parasite complex; parasite nucleus generally round, sometimes ovoid, rarely with marked karyosome, occupying 7.5 % of the area of the parasite; cytoplasm with small vacuoles and purple volutin granules present; nucleus of host cell as a band, more rarely as a cap-like structure, covering 34 % of the periphery of the parasite and occupying only 13 % of the area of the host cell-parasite complex; cytoplasm horns stout and sharp-pointed.

Microgametocyte (Fig. 17). Microgametocyte closely similar to macrogametocyte in general morphology and measurements. Cytoplasm non-granular and nucleus frequently fails to take up stain and is difficult to see. Peirce (1984) states a sex ratio of 40:1 and there is no apparent explanation for the small number of microgametocytes.

Basis of re-description. Hapantotype: blood film No. 91780b from the black-backed puff back *Dryoscopus cubla*, collected by Peirce, Balmoral, Zambia, 19 September 1981. Parahapantotype: blood film No. 91781, as above, on 10 October 1980.

Additional host records and distribution. *Leucocytozoon balmorali* can be ascribed to all leucocytozoid infections noted in shrikes of the Malaconotinae, a sub-family endemic to sub-Saharan Africa.

Comments. *Leucocytozoon balmorali* is unique among the passeriform leucocytozoids in having a fusiform morph; the fusiform morph is the one normally seen with the round morph being relatively rare. The exact status of the Malacotinidae is in some dispute. Most authorities (Edwards, 1986) consider the Malacotinidae to be a sub-family of the Laniidae, while studies by Benson, Brooke, Dowsett & Irwin (1973) suggest that the group is distinct and should be placed in its own family, the Malaconotidae. The issue is far from resolved at this time but all shrikes will be considered to be sub-families of the Laniidae *sensu lato*. The importance of the final resolution to this present study lies in the fact that leucocytozoids are host family specific and probably specific at the sub-familial level as well (Bennett *et al.*, 1991). A similar point was raised by Bennett, Peirce & Earlé (1990) concerning the haemoprotozooids of the same group.

Peirce (1984) gives an excellent discussion of *Leucocytozoon balmorali*. The present description of the fusiform morph, based on the type and parahapantotype material, was made to extend the 1984 description with reference to the new criteria recently established by Bennett *et al.* (1991).

TABLE 2 Morphometric parameters (in μm) of the leucocytozoids of the Nectariniidae, Passeridae, Ploceidae and Promeropidae

N =	<i>nectariniae</i> 35	<i>gentili</i> 50	<i>bouffardi</i> 70	<i>deswardti</i> 62
Parasite and nucleus				
Maximum diameter	12,4 (1,6)	14,4 (1,4)	12,9 (1,2)	12,4 (1,4)
Minimum diameter	10,2 (1,2)	10,7 (1,6)	10,9 (1,0)	10,2 (1,2)
Periphery of parasite	38,0 (5,7)	40,9 (2,8)	37,9 (3,0)	36,9 (3,2)
Area of parasite	99,4 (19,2)	122,3 (17,5)	110,1 (16,0)	99,8 (15,5)
Maximum width nucleus	3,8 (1,0)	5,3 (0,9)	4,2 (0,7)	4,2 (1,0)
Minimum width nucleus	2,6 (0,6)	3,0 (0,8)	2,9 (0,6)	2,5 (0,5)
Area of nucleus	7,4 (3,1)	12,3 (3,8)	9,5 (3,1)	8,1 (2,0)
Host cell-parasite complex				
Maximum diameter	15,4 (1,8)	16,0 (1,5)	14,6 (1,4)	14,2 (1,8)
Minimum diameter	11,9 (1,6)	12,5 (1,8)	12,5 (1,2)	11,9 (1,3)
Area of complex	134,3 (24,9)	158,0 (21,4)	139,8 (19,1)	130,1 (19,1)
Parasite periphery covered by complex nucleus	27,9 (6,0)	26,6 (3,5)	23,2 (3,4)	59,1 (13,0)
Area of complex nucleus	34,9 (7,8)	35,6 (6,6)	29,8 (7,8)	30,2 (6,9)

N = sample size; means followed by standard deviation in parentheses

FAMILY NECTARINIIDAE

***Leucocytozoon nectarinae* n. sp.**

Type host: the malachite sunbird, *Nectarinia famosa* (Smith)

Type locality: Paardeplaats, Republic of South Africa.

Macrogametocyte (Fig. 18–20, Table 1). Parasite with round morph only. Parasites generally small, round to broadly ovoid, occupying 75 % of the area of the host cell-parasite complex; parasite nucleus round to broadly ovoid, sometimes with marked karyosome, occupying 7 % of the area of the parasite; cytoplasm with a few vacuoles, volutin granules uncommon; nucleus of host cell as a thin band with two bulbous terminal portions (similar to *Leucocytozoon dubreuilii* of the Turdinidae, Khan & Fallis, 1970), the thin portion of the nucleus sometimes barely visible and the nucleus appears divided into two sections (Fig. 19) as in *Leucocytozoon smithi* (Bennett *et al.*, 1991), nucleus covering 75 % of the periphery of the parasite and occupying 26 % of the area of the host cell-parasite complex.

Microgametocyte (Fig. 21, 22). Morphology of microgametocyte similar to that of macrogametocyte and dimensions closely similar, with the microgametocyte averaging 5 % smaller in area.

Basis of description. Hapantotype: blood film No. 108272 from *Nectarinia famosa*, collected by De Swardt, Paardeplaats, Republic of South Africa, 25 November 1989. Parahapantotype: blood film No. 108291 from the black sunbird *Nectarinia amethystina*, collected by De Swardt, Paardeplaats, Republic of South Africa, 28 November 1989; blood film No. 24469, collected by White, Amani, Tanzania, 6 June 1971.

Additional hosts and distribution. All leucocytozoid infections recorded for sunbirds by Bennett *et al.* (1982) can be referred to this species. The identification by Bennett & Herman (1976) of *Leucocytozoon fringillinarum* and *L. majoris* in *Nectarinia amethystina* and *N. kilimensis* was in error.

Comments. *Leucocytozoon nectarinae* is only

similar to *L. dubreuilii* of the leucocytozoids of the passeriforms. The double-capped host cell nucleus that covers nearly three quarters of the periphery of the parasite distinguishes it from most other *Leucocytozoon* species of this avian order. *Leucocytozoon* infections in sunbirds of south-eastern Asia (McClure, Poonswad, Greiner & Laird, 1978) were extremely light and did not present material suitable for taxonomic studies. However, the parasites were the same as those seen from African sunbirds, where the intensity of infection was far higher.

FAMILY PASSERIDAE

***Leucocytozoon gentili* Leger, 1913**

Type host: the rock sparrow, *Petronia petronia* (L.)

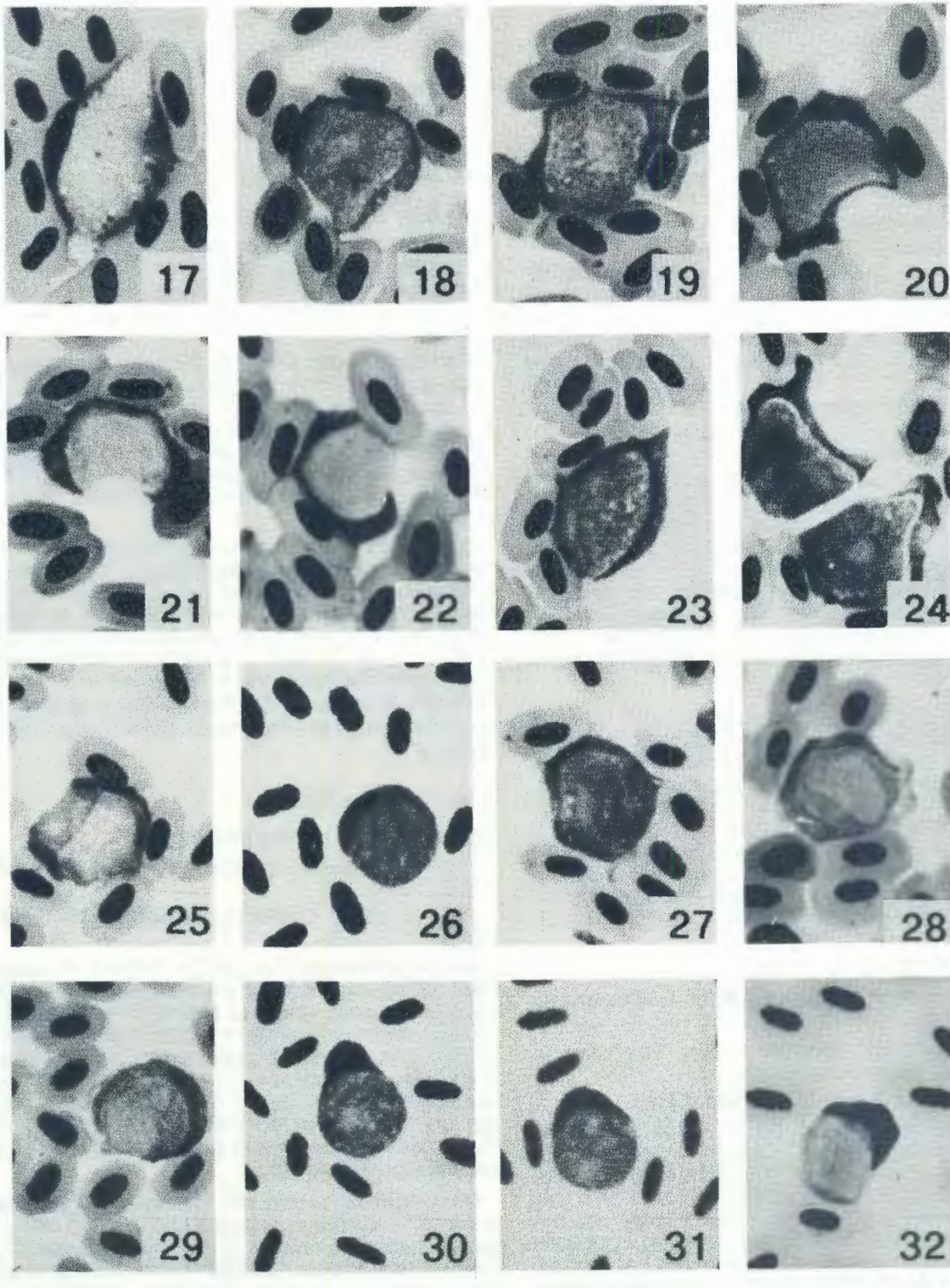
Type locality: Bastia, Corsica.

Synonym: *Leucocytozoon monardi* Rodhain, 1931.

Macrogametocyte (Fig. 23, 24, Table 2). Parasite with round morph only. Parasite of medium size, sometimes round but usually broadly ovoid, occupying 77 % of the area of the host cell-parasite complex; parasite nucleus ranging from round to elliptical and occasionally with a marked karyosome, nucleus proportionally large, occupying nearly 10 % of the area of the parasite; cytoplasm generally granular with small vacuoles but volutin granules not common; nucleus of host cell as a band, sometimes with a single terminal bulb and with a small cap-like extension on occasion, host cell nucleus covering 65 % of the periphery of the parasite and occupying 23 % of the area of the host cell-parasite complex.

Microgametocyte (Fig. 25). Morphologically closely similar to macrogametocyte but 10–15 % smaller in most dimensions.

Basis of re-description. Neohapantotype: blood film No. 106655 from the Cape sparrow *Passer melanurus*, collected by Earlé, Bloemfontein,



30 μm

FIG. 18–22 *Leucocytozoon nectarinis*. Fig. 18–20, macrogametocytes; Fig. 21, 22, microgametocytes. Note that Fig. 22 also shows the male has the host cell complex nucleus as a thin band without cap

FIG. 23–25 *Leucocytozoon gentili*. Fig. 23–24, macrogametocyte; Fig. 25, microgametocyte

FIG. 26–29 *Leucocytozoon bouffardi*. Fig. 26, 27, macrogametocyte; Fig. 28, 29, microgametocytes

FIG. 30–32 *Leucocytozoon deswardti*. Fig. 30, 31, macrogametocyte; Fig. 32, microgametocyte

Republic of South Africa, 3 August 1989. Paraneohapantotype: blood film No. 106657 from *Passer melanurus*, collected by Earlé, Bloemfontein, Republic of South Africa, 3 August 1989; blood film No. 106646 from the house sparrow *Passer domesticus*, collected by Earlé, Bloemfontein, Republic of South Africa, 2 August 1989.

Additional host records and distribution. All leucocytozoids reported for the Passeridae can be referred to *Leucocytozoon gentili* and presumably this parasite is distributed across the Old World range of the passerids.

Comments. *Leucocytozoon gentili* is another small, non-descript leucocytozoid that used to be confused with, and was synonymized with, *L. fringillinarum*. However, it lacks the distinctive cap-like deformation of the host cell nucleus, and the deformed host cell nucleus covers considerably more of the periphery of the parasite than it does for *L. fringillinarum*. In addition, this parasite is considerably larger in most dimensions.

In 1931, Rodhain described *Leucocytozoon monardi* from the grey sparrow *Passer griseus*, in Katanga, apparently unaware of Leger's description of *L. gentili*. Rodhain's description and one sketch show a parasite that is clearly the same as *L. gentili*, and the measurements he presents are within the mean and standard deviation of this study (Table 2). Therefore, *Leucocytozoon monardi* Rodhain, 1931 falls as a synonym of *Leucocytozoon gentili* Leger, 1913.

The deposition of Leger's material is not reported and is presumed lost and the Curator of the protozoological specimens of the National Museum of France is unaware that it is deposited in that institution (Landau, 1992, *in littoris*). In the absence of suitable material from both the type host and the type locality, a neohapantotype has been designated from *Passer melanurus*, a passerid conspecific with *Passer griseus* in southern Africa, which was the type host of Rodhain's (1931) *L. monardi*.

FAMILY PLOCEIDAE

***Leucocytozoon bouffardi* Leger & Blanchard, 1911**

Type host: yellow-backed weaver, *Hyphantornis* (= *Ploceus*) *melanocephalus* (L.).

Type locality: Bamako, Republic of Mali.

Macrogametocyte (Fig. 26, 27, Table 2). Parasite with round morph only. Parasite small, round to broadly ovoid, occupying 79 % of the host cell-parasite complex; parasite nucleus round to elliptical, without marked karyosome, relatively large, occupying 8,5 % of the area of the parasite; cytoplasm with few vacuoles and volutin granules uncommon; nucleus of host cell as band around the parasite, sometimes thickened in the centre but not as a cap, covering 60 % of the periphery of the parasite and occupying 21 % of the area of the host cell-parasite complex.

Microgametocyte (Fig. 28, 29). Similar in morphology to the macrogametocyte but 10–15 % smaller in most dimensions.

Basis of re-description. Neohapantotype: blood film No. 103821 from the Cape weaver *Ploceus capensis*, collected by De Swardt, Lydenburg, Republic of South Africa, 24 December 1988. Paraneohapantotype: blood film No. 106868 from the vitelline masked weaver *Ploceus velatus*, collected by Earlé, Bloekombos, Republic of South Africa, 15 August 1989; blood film 19211 from the baglafaecht weaver *Ploceus baglafaecht*, collected by Crans, Amani, Tanzania, 22 November 1970; blood film No. 16921 from the Madagascar fody *Foudia madagascariensis*, collected by Uilenberg, Madagascar, 3 January 1965; blood film No. 94989 from the blue-faced parrot finch *Erythrura trichroa*, collected by Jones, Mt. Kaindi, Papua New Guinea, 19 January 1982.

Additional hosts and distribution. All leucocytozoids reported for the Ploceidae can be referred to this species. The reports of *Leucocytozoon fringillinarum* in the Ploceidae (summarized in Bennett *et al.*, 1982) are in error and should be termed *Leucocytozoon bouffardi*. The parasite appears to occur throughout the Old World distribution of the Ploceidae.

Comments. *Leucocytozoon bouffardi* is similar to the other small, round leucocytozoids of the Passeriformes. It is distinguished from *L. fringillinarum* by the fact that the host cell nucleus forms a ribbon rather than a cap-like structure. Assuming host family specificity, this is a distinct species but experimental cross-transmissions must be carried out to establish this point. In as much that these birds are easily kept in captivity, such studies should be relatively easy to carry out.

FAMILY PROMEROPIDAE

***Leucocytozoon deswardti* n. sp.**

Type host: Gurney's sugarbird, *Promerops gurneyi* Verreaux

Type locality: Lydenburg, Republic of South Africa.

Macrogametocyte (Fig. 30, 31, Table 2). Parasite small, occupying 75 % of the area of the host cell-parasite complex, round to broadly ovoid; parasite nucleus moderately large, round to elliptical, without a marked karyosome, occupying 8,1 % of the area of the parasite; vacuoles not prominent; nucleus of host-cell parasite complex ranging from a distinct cap to a thin band, covering 60 % of the periphery of the parasite and occupying 23 % of the area of the host cell-parasite complex.

Microgametocyte (Fig. 32). Microgametocytes are about 10 % smaller in all characters than the macrogametocyte; the nucleus of the host cell-parasite complex tends to be band-like in the microgametocytes where a cap-like formation occurs more frequently in the macrogametocytes.

Basis of description. Hapantotype: blood film No. 104897 from Gurney's sugarbird *Promerops gurneyi* collected by De Swardt at Lydenburg, Republic of South Africa on 19 June 1989. Parahapantotype: blood film No. 104907 from Gurney's sugarbird, collected by De Swardt as above on 22 June 1989.

TABLE 3 Morphometric parameters (in μm) of the leucocytozoids of the Pycnonotidae, Sturnidae and Zosteropidae

N =	<i>brimonti</i> 45	<i>pycnonoti</i> 45	<i>sturni</i> 50	<i>zosteropis</i> 40
Parasite and nucleus				
Maximum diameter	12,8 (1,9)	12,8 (2,1)	13,0 (1,0)	12,8 (1,6)
Minimum diameter	10,3 (1,1)	10,0 (1,2)	11,1 (0,9)	10,2 (1,0)
Periphery of parasite	38,3 (4,4)	37,2 (3,8)	37,5 (2,6)	38,8 (2,5)
Area of parasite	103,7 (19,7)	95,8 (14,2)	109,3 (10,6)	104,5 (11,7)
Maximum diameter nucleus	3,9 (0,7)	3,6 (1,0)	4,5 (0,6)	4,6 (0,7)
Minimum diameter nucleus	2,3 (0,4)	2,3 (0,4)	3,0 (0,5)	2,6 (0,4)
Area of nucleus	7,5 (1,7)	6,3 (1,7)	10,3 (2,2)	9,3 (2,0)
Host cell-parasite complex				
Maximum diameter	14,2 (1,8)	15,0 (2,0)	14,4 (1,0)	17,9 (2,2)
Minimum diameter	12,4 (1,4)	11,5 (1,3)	12,5 (1,0)	12,4 (1,4)
Area of complex	127,9 (22,3)	130,9 (19,5)	136,8 (13,4)	155,6 (16,7)
Parasite periphery covered by complex nucleus	13,7 (2,2)	31,6 (3,6)	18,0 (2,7)	30,8 (3,6)
Area of complex nucleus	24,2 (7,0)	35,2 (7,6)	27,5 (6,0)	51,1 (13,4)

N = sample size; means followed by standard deviation in parentheses

Additional host records and distribution. Presumably *Leucocytozoon deswardti* also occurs in the Cape sugarbird *Promerops cafer*, but no specimens have been examined. The parasite presumably occurs over the range of the endemic family Promeropidae in South Africa.

Comments. The two species of sugarbirds endemic to South Africa have long been considered members of the Australian family of honey-eaters (Meliphagidae). There is some controversy as to the correct systematic relationships of these two species, but Sibley & Ahlquist (1974), using recombinant DNA techniques, indicated that these birds were more closely related to the starlings (Sturnidae) than the Meliphagidae, forming an unique endemic group in South Africa. The latest edition of Robert's Birds of South Africa (Maclean, 1985) accepts this separation and they are considered to be in a separate family by Edwards (1986) and by Campbell & Lack (1985).

Bennett & De Swardt (1989) reported the first occurrence of *Leucocytozoon anellobiae* Johnston, 1912 in the Gurney's sugarbird in South Africa. In view of the presumed host familial specificity of leucocytozoids (Fallis *et al.*, 1974; Bennett *et al.*, 1991), it is unwise to consider that *Leucocytozoon anellobiae* of the Australian Meliphagidae also occurs in the South African Promeropidae. Hence, we are designating the leucocytozoid of the South African Promeropidae as *Leucocytozoon deswardti*, named after Dawid de Swardt who not only collected the material but has extensively studied the life cycle and behaviour of Gurney's sugarbird, particularly in the Lydenburg area. It must be noted, however, that the morphometric parameters of both species are essentially identical and the separation of the two species is essentially based on host family differences. *Leucocytozoon deswardti* is another small leucocytozoid of the passeriforms with little to distinguish it from the others.

FAMILY PYCNONOTIDAE

Leucocytozoon brimonti Mathis & Leger, 1910

Type host: the light-vented bulbul, *Ixus hainanus*

[=*Pycnonotus sinensis* (Gmelin)]

Type locality: Hanoi, Vietnam.

Synonym: *Leucocytozoon molpastis* de Mello, 1937

Macrogametocyte (Fig. 33–35, Table 2). Parasite with round morph only. Parasites small, round to broadly ovoid, occupying 80 % of the area of the host cell-parasite complex; parasite nucleus round to ovoid, sometimes elliptical, without marked karyosome, occupying 7,5 % of the area of the parasite; cytoplasm granular with some vacuoles, volutin granules not common; host cell nucleus as a short band about the parasite, sometimes forming a small cap but cap not pronounced, host cell nucleus covering only 35 % of the periphery of the parasite and occupying 19 % of the area of the host cell-parasite complex.

Microgametocyte (Fig. 36). Morphologically, the microgametocyte closely similar to the macrogametocyte but is 15–20 % smaller in most dimensions.

Basis of re-description. Blood film No. 92316 from the black-eyed bulbul *Pycnonotus barbatus*, collected by Peirce, Balmoral, Zambia, 25 October 1980; blood film No. 98027 from *P. barbatus*, collected by Cassidy, Pretoria, Republic of South Africa, 16 May 1987.

Additional hosts and distribution. *Criniger bres*, *C. ochraceus*, *C. pallidus*, *Hypsipetes criniger*, *H. flavala*, *H. maclellandii*, *H. philippinus*, *H. thompsoni*, *Phyllastrephus terrestris*, *Pycnonotus atriceps*, *P. blandfordi*, *P. brunneus*, *P. cafer*, *P. erythroptalmus*, *P. eutilotus*, *P. finlaysoni*, *P. flavescens*, *P. goiaver*, *P. importunus*, *P. jocosus*, *P. luteolus*, *P. melanicterus*, *P. nigricans*, *P. plumosus*, *P. xanthopygus*. *Leucocytozoon brimonti* is distributed over the range of the Old World family Pycnonotidae.

Comments. *Leucocytozoon brimonti* is a small, round leucocytozoid which on first appearance resembles *L. fringillinarum*. However, the host cell nucleus forms a band rather than a pronounced cap on the parasite and this band covers only 36 % of

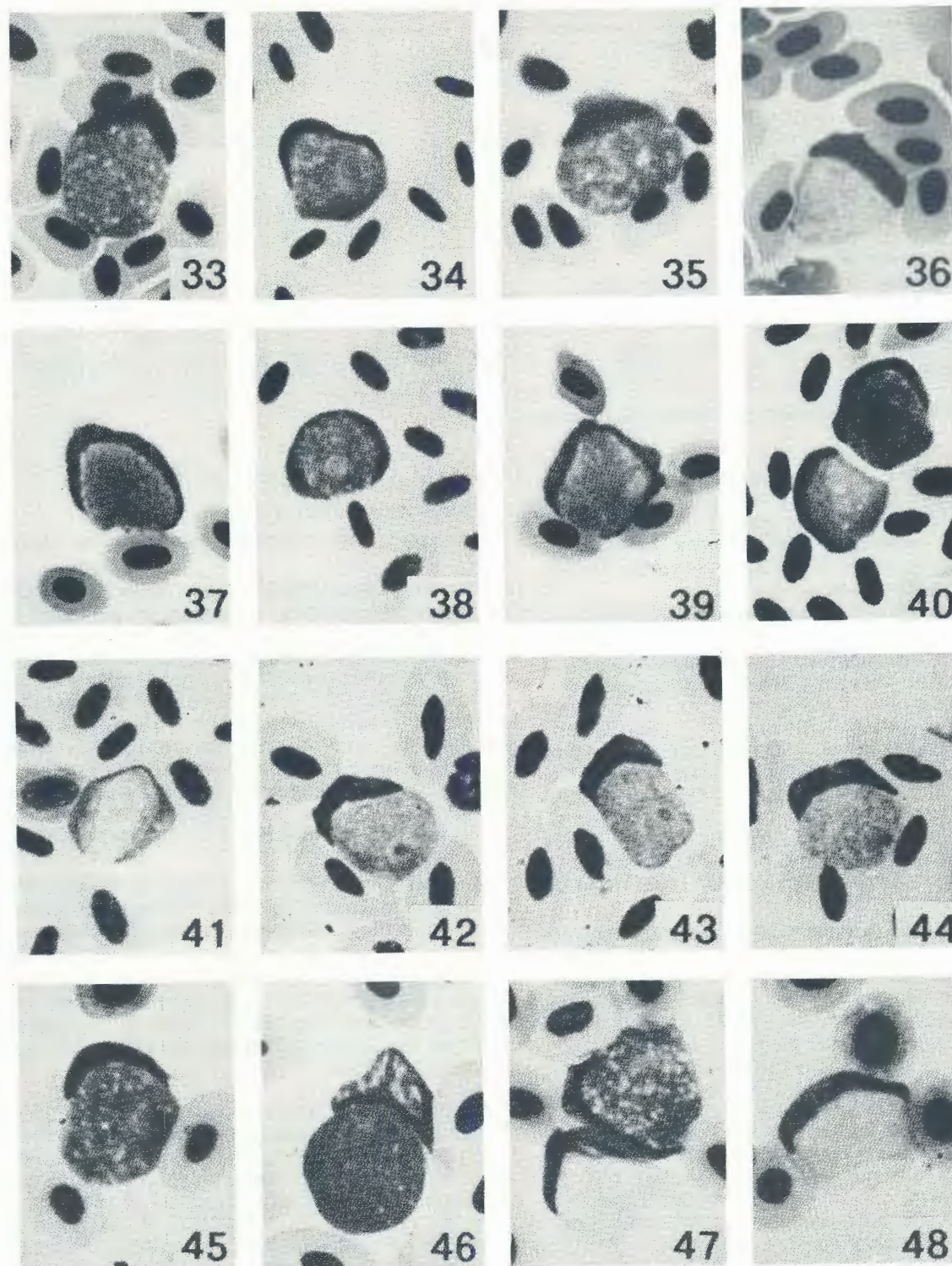


FIG. 33-36 *Leucocytozoon brimonti*. Fig. 33-35, macrogametocytes; Fig. 36, microgametocyte

FIG. 37-41 *Leucocytozoon pycnonotis*. Fig. 37-39, macrogametocytes; Fig. 40, macrogametocyte and microgametocyte; Fig. 41, microgametocyte

FIG. 42-44 *Leucocytozoon sturnis*. Fig. 42-44, macrogametocyte

FIG. 45-48 *Leucocytozoon zosteropis*. Fig. 45-46, macrogametocyte; Fig. 47, macrogametocyte and microgametocyte; Fig. 48, microgametocyte

the periphery of the parasite on average, somewhat less than that seen in *L. fringillinarum*. The parasite occurs in most species of bulbuls, and is distributed through the distributional range of the bulbuls, particularly in south-eastern Asia.

De Mello (1937) described and illustrated a round leucocytozoid from *Molpastes* (= *Pycnonotus*) *cafer* shot in Goa, India. The description and illustrations are clearly those of *L. brimonti*, and De Mello was apparently unaware of the 1910 work of Mathis & Leger. *Leucocytozoon molpastis* is herein declared a synonym of *L. brimonti*.

***Leucocytozoon pycnonoti* n. sp.**

Type host: black-eyed bulbul, *Pycnonotus barbatus* (Desfontaines)

Type locality: Pretoria, Republic of South Africa.

Macrogametocyte (Fig. 37–40, Table 3). Parasite with round morph only. Parasite small, round to broadly ovoid, occupying 73 % of the area of the host cell-parasite complex; parasite nucleus round to ovoid without marked karyosome, occupying 6.5 % of the area of the parasite; cytoplasm granular with some vacuoles, volutin granules present on occasion; host cell nucleus as a thin band, rarely cap-like or thickened, that covers 85 % of the periphery of the parasite and occupying 27 % of the area of the host cell-parasite complex.

Microgametocyte (Fig. 40, 41). Morphology closely similar to that of the macrogametocyte but parasite is about 10 % smaller in most dimensions.

Basis of description. Hapantotype: blood film No. 96949 from the black-eyed bulbul, *Pycnonotus barbatus*, collected by Cassidy, Pretoria, Republic of South Africa, 15 March 1986. Parahapantotype: blood film No. 11209 from the red-whiskered bulbul, *Pycnonotus jocusus*, collected by McClure, Chiang-mai, Thailand, 3 December 1964.

Additional host records and distribution. *Criniger ochraceus*, *C. pallidus*, *C. phaeocephalus*, *Hypsipetes charlottae*, *H. flavala*, *H. madagascariensis*, *H. maclellandii*, *H. philippinus*, *H. virescens*, *Pycnonotus atriceps*, *P. aurigaster*, *P. blandfordi*, *P. brunneus*, *P. cafer*, *P. finlaysoni*, *P. flavescens*, *P. goiaver*, *P. melanicterus*, *P. plumosus*, *P. simplex*, *P. xanthopygus*. *Leucocytozoon pycnonotis* is widely distributed throughout the range of the Pycnonotidae, completely overlapping both the spatial and host range of *L. brimonti*.

Comments. *Leucocytozoon pycnonoti* is a readily recognized parasite and easily separated from *L. brimonti* by the marked deformation of the host cell nucleus which nearly surrounds the periphery of the parasite. With the exception of *L. majoris* of the Paridae and *L. zosteropsis* of the Zosteropidae, no other round morph leucocytozoid has a host cell nucleus that covers so much of the periphery of the parasite. *Leucocytozoon pycnonotis* can occur as a double infection with *L. brimonti* in the same host.

FAMILY STURNIDAE

***Leucocytozoon sturni* n.sp.**

Type host: African pied starling, *Spreo bicolor* (Gmelin).

Type locality: Harrismith, Republic of South Africa.

Macrogametocyte (Fig. 42, 43, Table 3). Parasite with round morph only. Parasite small, usually round but ranges to broadly ovoid, occupying 80 % of the area of the host cell-parasite complex; parasite nucleus proportionally large, round to ovoid without marked karyosome, occupying 9.5 % of the area of the parasite; cytoplasm finely granular with large vacuoles but volutin granules absent; host cell nucleus as a band, thin at both ends but thick in the centre but not cap-like, covering 48 % of the periphery of the parasite and occupying 20 % of the area of the host cell-parasite complex.

Microgametocyte (Fig. 40). Microgametocyte closely similar to macrogametocytes in morphology and dimensions.

Basis of description. Hapantotype: blood film No. 115806 from the African pied starling, *Spreo bicolor*, collected by Earlé, Harrismith, Republic of South Africa, 16 January 1990. Parahapantotype: blood film No. 38777 from the Philippine glossy starling *Aplonis panayensis*, collected by McClure, Palawan, Philippine islands, 8 February 1966.

Additional host records and distribution. All leucocytozoids in the Sturnidae can be ascribed to this species. Reports in the literature using the terminology *Leucocytozoon fringillinarum*, *L. majoris* and *L. dubreuilii* (summarized in Bennet *et al.* 1982) are in error. The parasite is distributed throughout the Old World distribution of the Sturnidae but does not occur in the introduced common starling (*Sturnus vulgaris*) and common myna (*Acridotheres tristis*) introduced into North America.

Comments. *Leucocytozoon sturni* is a small, round leucocytozoid that bears some resemblance to *L. fringillinarum* but the host cell nucleus does not form a distinct cap on the parasite; the host cell nucleus also covers slightly more of the periphery. Surprisingly, although sturnids are frequently parasitized by haemoproteids (35 of 48 species examined), relatively few (14 out of 48 species examined) have been shown to be parasitized by *Leucocytozoon sturni*. Two starling species, *Sturnus vulgaris* (common starling) and *Acridotheres tristis* (common myna) were introduced into North America where the former has reached pest proportions in many areas. The original introduced stock were apparently parasite free as neither species, in North America, has been reported infected with either *Leucocytozoon* or *Haemoproteus*, although North American birds are heavily parasitized by both of these genera. While it might be said that the vectors in North America have not yet adapted to these exotic hosts, it can also be argued that as there are no sturnids in this continent, their blood parasites are also absent, and the local species will not develop in these birds. If this is indeed the fact, there is additional support for the concept that species of *Leucocytozoon* are host family specific.

Zeniev (1975) referred to *Leucocytozoon vulgaris* as a leucocytozoid he saw in *Sturnus vulgaris*. However, as this name was used in a table without further description or illustration, thus contravening the

International Code for Zoological Nomenclature (1985), Peirce & Bennett (1979) declared it a *nomen nudum*. Similarly, Yakunin (1976) employed the name *Leucocytozoon zasukhini* without description or illustration, for a leucocytozoid he found in 39 species of birds, including the starling, *Sturnus vulgaris*. This name, without description or illustration, appears at the start of a paragraph; it is herein declared a *nomen nudum*.

FAMILY ZOSTEROPIDAE

***Leucocytozoon zosteropis* Peirce, Cheke & Cheke, 1977**

Type host: the Mascarene white-eye, *Zosterops borbonica* (Gmelin)

Type locality: Alexandra Falls, Mauritius.

Macrogametocyte (Fig. 45–47, Table 3). Parasite with round morph only. Parasites small, round to broadly ovoid, occupying 67 % of the area of the host cell-parasite complex; parasite nucleus relatively large, usually ovoid to elliptical, occasionally with a marked karyosome, nucleus occupying 9 % of the area of the parasite; cytoplasm granular with small vacuoles but volutin granules absent; nucleus of host cell as a thin band ending in a pronounced mass at each end (somewhat reminiscent of *Leucocytozoon dubreuilii* of the Turdinae) and giving the host cell-parasite complex the appearance of a fusiform morph, host cell nucleus covering 80 % of the periphery of the parasite.

Microgametocyte (Fig. 47, 48). Parasite morphology closely similar to that of the macrogametocyte but measurements 5–10 % smaller.

Basis of re-description. Blood film No. 103458 and 106518 from the pale white-eye, *Zosterops pallidus*, collected by Earlé, Bloemfontein, Republic of South Africa, 8 October 1988 and 11 July 1989 respectively.

Additional hosts and distribution. All leucocytozoids of the Zosteropidae can be assigned to this species. The parasite appears to be distributed throughout the range of the family Zosteropidae.

Comments. *Leucocytozoon zosteropis* is a unique leucocytozoid of the passeriforms as it appears to be a fusiform parasite, a distinctive morphological form in the passeriforms that permits ready identification. Peirce *et al.* (1977) have given a good discussion of the species. However, they suggest that perhaps the parasite is endemic to the Mascarene Islands, but its occurrence in zosteropids from Japan, the Philippine islands and throughout south-eastern Asia to Africa indicates that this surmise is not true.

ACKNOWLEDGEMENTS

The financial support of the Natural Sciences and Engineering Research Council of Canada to the first author is gratefully acknowledged. The appointment of the first author as an International Visiting Fellow to the Department of Parasitology, Faculty of Veterinary Science, University of Pretoria by the Foundation for Research Development of the Republic of South Africa permitted the first author to visit the

country and examine much of the material at first hand.

REFERENCES

- AMERICAN ORNITHOLOGISTS' UNION, 1983. Check-list of North American Birds. 6th edition. American Ornithologists' Union, Lawrence, Kansas, 877 pp.
- BENNETT, G. F., 1960. On some ornithophilic bloodsucking Diptera in Algonquin Park, Ontario, Canada. *Canadian Journal of Zoology*, 38, 377–389.
- BENNETT, G. F. & CAMPBELL, A. GILLIAN, 1975. Avian Leucocytozoidae. I. Morphometric variation in three species of *Leucocytozoon* and some taxonomic implications. *Canadian Journal of Zoology*, 53, 800–812.
- BENNETT, G. F. & HERMAN, C. M., 1976. Blood parasites of some birds from Kenya, Tanzania and Zaire. *Journal of Wildlife Diseases*, 12, 59–65.
- BENNETT, G. F., WHITEWAY, MADONNA A. & WOODWORTH-LYNAS, CARLA B., 1982. Host-parasite catalogue of the avian haematzoa. *Memorial University of Newfoundland Occasional Papers in Zoology* No. 5, 243 + ix pp.
- BENNETT, G. F. & DE SWARDT, D. H., 1989. First African record of *Leucocytozoon anellobiae* (Apicomplexa: Leucocytozoidae) in Gurney's sugarbird, *Promerops gurneyi*. *Ostrich* 60, 171.
- BENNETT, G. F., PEIRCE, M. A. & EARLÉ, R. A., 1990. The haemoproteids of the shrikes of the avian family Laniidae (Passeriformes). *South African Journal of Zoology*, 25, 194–198.
- BENNETT, G. F., EARLÉ, R. A., PEIRCE, M. A., HUCHZERMAYER F. W. & SQUIRES-PARSONS, DEBORAH, 1991. Avian Leucocytozoidae: the leucocytozoids of the Phasianidae *sensu lato*. *Journal of Natural History*, 25, 1407–1428.
- BENSON, C. W. BROOKE, R. K., DOWSETT, R. J. & IRWIN, M. P. S., 1973. The birds of Zambia. Second Edition, Collins, London. 414 pp.
- CAMPBELL, B. & LACK, ELIZABETH, 1985. A dictionary of birds. The British Ornithologists' Union. T. & A. D. Poyser Ltd., Staffordshire, United Kingdom. 670 pp.
- EDWARDS, E. P., 1986. A coded workbook of birds of the world. Volume 2. Passerines. Second edition. E. P. Edwards, Box AQ, Sweet Briar, VA, USA, 24595, 170 pp.
- FALLIS, A. M. & BENNETT, G. F., 1962. Observations on the sporogony of *Leucocytozoon mirandae*, *L. bonasae* and *L. fringillinarum* (Sporozoa: Leucocytozoidae). *Canadian Journal of Zoology*, 40, 395–400.
- FALLIS, A. M., DESSER, S. S. & KHAN, R. A., 1974. On species of *Leucocytozoon*. In: DAWE, B. (ed.). Advances in parasitology. Academic Press, New York, 12, 1–67.
- FRANÇA, C., 1912. Contribution à l'étude des *Leucocytozoon* des oiseaux du Portugal. Troisième note. *Bulletin de la Société de Pathologie Exotique*, 5, 82–86.
- INTERNATIONAL CODE FOR ZOOLOGICAL NOMENCLATURE, 1985. International Trust for Zoological Nomenclature, British Museum of Natural History, London, England, 338 pp.
- JOHNSTON, T. H., 1912. Internal parasites recorded from Australian birds. *Emu*, 12, 105–112.
- KHAN, R. A. & FALLIS, A. M., 1970. Life cycles of *Leucocytozoon dubreuilii* Mathis & Leger, 1911 and *Leucocytozoon fringillinarum* Woodcock, 1910 (Haemosporidia: Leucocytozoidae). *Journal of Protozoology*, 17, 642–658.
- LEGER, A. & BLANCHARD, M., 1911. Hématozoaires d'un passereau du Haute-Sénégal et Niger (*Hypantornis melanocephala* Linné). *Bulletin de la Société de Pathologie Exotique*, 4, 526–527.
- LEGER, M., 1913. Hématozoaires d'oiseaux de la Corse. *Bulletin de la Société de Pathologie Exotique*, 6, 515–523.
- MACLEAN, G. L., 1985. Roberts' Birds of southern Africa. John Voelcker Bird Book Fund, Cape Town. 848 pp.
- MATHIS, C. & LEGER, M., 1910. Parasites sanguicoles d'un passereau du Tonkin (*Ixus hainanus*), boulboul de l'Isle de Hainan). *Comptes Rendus des Séances de la Société de Biologie et de ses filiales*, 69, 330–332.
- MATHIS, C. & LEGER, M., 1911. *Leucocytozoon* d'un paon, d'un crabier et d'un bengali du Tonkin. *Comptes rendus des Séances de la Société de Biologie et de ses filiales*, 70, 211–212.
- MCCLURE, H. E., POONSWAD, P., GREINER, E. C. & LAIRD, M., 1978. Haematzoa in the birds of eastern and southern Asia. Memorial University of Newfoundland. 296 + x pp.
- MELLO, I. F., DE. 1937. On haemoprotezoa of Indian birds. *Compte Rendu 12th Congress Internationale de Zoologie (Lisbon)*, 2, 1391–1445.

- PEIRCE, M. A., CHEKE, A. S. & CHEKE, R. A., 1977. A survey of blood parasites of birds in the Mascarene Islands, Indian Ocean. With descriptions of two new species and taxonomic discussion (by M. A. Peirce). *Ibis*, 119, 451–461.
- PEIRCE, M. A. & BENNETT, G. F., 1979. Avian Haematozoa: some taxonomic and nomenclatural problems arising from the Russian literature. *Journal of Protozoology*, 26, 357–359.
- PEIRCE, M. A., 1984. Haematozoa of Zambian birds. IV. Description of *Leucocytozoon balmorali* sp. nov. from Malaconotidae. *Journal of Natural History*, 18, 223–226.
- RODHAIN, J., 1931. Deux *Leucocytozoon* d'oiseaux du Congo belge. *Comptes Rendus des Séances de la Société de Biologie et de ses filiales*, 107, 273–276.
- SIBLEY, C. G. & AHLQUIST, J. E., 1974. The relationships of the African sugarbirds (*Promerops*). *Ostrich*, 45, 22–30.
- WOODCOCK, H. M., 1910. Studies on avian haemoprotozoa. I. On certain parasites of the chaffinch (*Fringilla coelebs*) and the redpoll (*Linota rufescens*). *Quarterly Journal of Microscopical Science*, 55, 641–740.
- YAKUNIN, M. P., 1976. Paraziticheskie prosteishie krovi dikikh ptits Kazakhstana. [In Russian]. (Parasitic protozoa in the blood of wild birds from Kazakhstan). *Materialy 11 vsesoyuz.s'ezda protozoologov. Naukova Dumka, Kiev* 1, 166–167.
- ZEINIEV, N. R., 1975. Paraziticheskie krovi ptits severo-vostochnogo Azerbaidzhana. [In Russian]. (Parasitic protozoa in the blood of birds from north-eastern Azerbaidzhan). *Izvestiya Akademii nauk Azerbaidzhanskoi SSR, seriya biologicheskikh i meditsinskikh nauk*, 4, 86–89.