

## A COMPARATIVE STUDY OF THE THICKNESS OF THE TUNICA MUSCULARIS IN THE FORESTOMACH AND ABOMASUM OF GREY, WHITE AND BLACK KARAKUL LAMBS

H. B. GROENEWALD<sup>(1)</sup> and K. K. BOOTH<sup>(2)</sup>

### ABSTRACT

GROENEWALD, H. B. & BOOTH, K. K., 1992. A comparative study of the thickness of the tunica muscularis in the fore-stomach and abomasum of grey, white and black Karakul lambs. *Onderstepoort Journal of Veterinary Research*, 59, 225–227 (1992)

Homozygous grey Karakul lambs are born with a lethal genetic factor responsible for death and weaning age. When put on a high roughage diet under field conditions they develop distended, thin-walled rumens and sand impacted abomasa. Homozygous white Karakul lambs have a similar factor but survive for a longer period. Black Karakul lambs are not affected. The present study was undertaken to compare by image analysis the thickness of the tunica muscularis of the forestomach and abomasum of 24-hour old grey, white and black Karakul lambs. One square centimetre samples were taken from equivalent areas in each case of the rumen, reticulum, omasum and abomasum of 38 embalmed Karakul lambs. Haematoxylin and eosin stained histological sections of each sample were studied with a Vids 2 Image Analyzer and the thickness of the circular and longitudinal muscle layers was measured. An analysis of variance indicated a significant difference between the groups in the thickness of the tunica muscularis of the rumen, reticulum and abomasum; the grey group displaying the thinnest and the black group the thickest. The omasa were not affected. The study indicates a reduction in thickness of the tunica muscularis of the homozygous grey and white lambs when compared to normal black lambs.

### INTRODUCTION

Homozygous grey Karakul lambs are born with a lethal genetic factor responsible for death at weaning age (Nel & Louw, 1953). When put on a high roughage diet under field conditions they develop distended thin-walled rumens and sand impacted abomasa (Nel, 1965). These lambs have a potbellied appearance, become emaciated and die. Homozygous white Karakul lambs are born with the same genetic factor and they show the same clinical signs as the homozygous grey lambs, but they survive for a longer period. Black Karakul lambs are unaffected. The homozygous grey lambs die before they reach sexual maturity, resulting in a scarcity of grey lambs and consequently a scarcity in grey pelts. Homozygous grey and white Karakul lambs can be identified at birth by the lack of pigmentation of the tongue, palate and ears (Nel & Louw, 1953). Previous studies in 24-hour-old grey, white and black Karakul lambs (Groenewald & Booth, 1989), showed a significant difference ( $P < 0,05$ ) in the length and width of the rumen and in the volume of the rumino-reticulum between the three groups, the grey group displaying the largest organ and the black group the smallest. The walls of the rumen appeared thinner in the grey and white lambs. Milk filled rumens were observed in the homozygous grey and white lambs.

The present study was undertaken to determine whether the apparent thinning of the walls of the fore-stomach and abomasum of the grey and white lambs was due to a decrease in the thickness of the tunica muscularis.

The results showed a significant decrease in the thickness of the tunica muscularis in the grey and white lambs when compared to the black lambs.

<sup>(1)</sup> Department of Anatomy, Faculty of Veterinary Science, University of Pretoria, Private Bag X04, Onderstepoort, 0110

<sup>(2)</sup> Department of Veterinary Anatomy, Faculty of Veterinary Science, Medical University of Southern Africa, Medunsa, 0204

Received 23 April 1992—Editor

### MATERIALS AND METHODS

Thirteen grey, fifteen white, and ten black 24-hour-old Karakul lambs were embalmed with 10 % formalin via the left common carotid artery immediately after they had been slaughtered and skinned. Grey and white lambs with unpigmented tongues, palates, and ears were selected. Black lambs were randomly selected and served as the control group.

A 1 cm<sup>2</sup> sample was taken from an equivalent area of the rumen, reticulum, omasum and abomasum in each of the 38 embalmed lambs. The samples of the rumen were taken from the middle of the left and right side of the dorsal sac, and the left and right side of the ventral sac. The other samples were taken from the right surface of the reticulum, the parietal surface of the omasum and the greater curvature of the abomasum. Histological sections were prepared from each sample and stained with the standard haematoxylin and eosin technique. All measurements of the tunica muscularis were performed using a Vids 2 Image analyzer.

The thickness of the circular and longitudinal layers of the tunica muscularis was measured on the left, middle and right third of each section and the mean thickness of each layer for the rumen, reticulum, omasum and abomasum as well as the total thickness of the tunica muscularis was calculated. The thickness of the tunica muscularis in the rumen was calculated from the mean of the left and right side of the dorsal sac and the left and right side of the ventral sac measured.

One way analysis of variance was implemented to determine whether significant differences exist in the thickness of the tunica muscularis between the three groups of lambs.

### RESULTS

There was a significant difference between the groups in the total thickness of the tunica muscularis of the rumen (F ratio = 2,19) (Fig. 1), reticulum (F ratio = 7,25) (Fig. 2), and abomasum (F ratio = 5,75)



A COMPARATIVE STUDY OF THE THICKNESS OF THE TUNICA MUSCULARIS

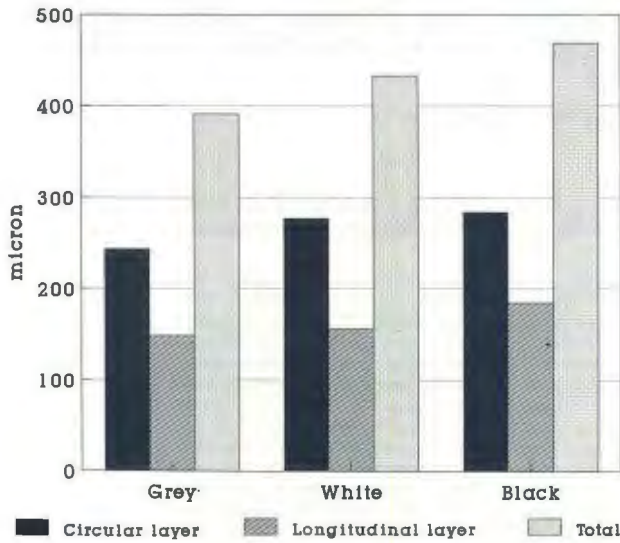


FIG. 1 Thickness of the tunica muscularis of the rumen

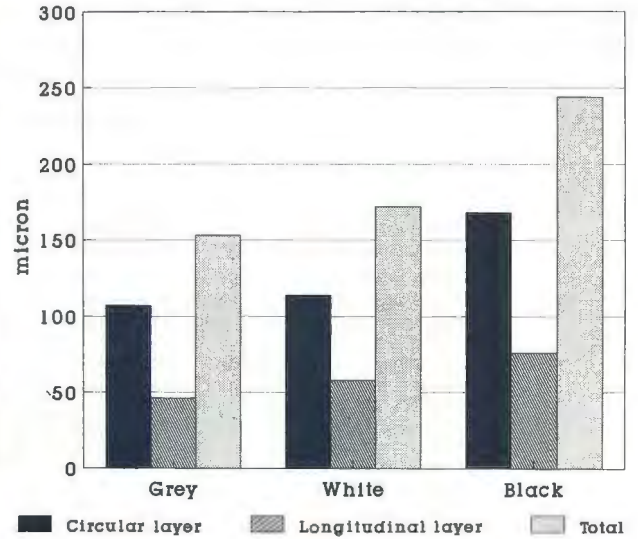


FIG. 3 Thickness of the tunica muscularis of the abomasum

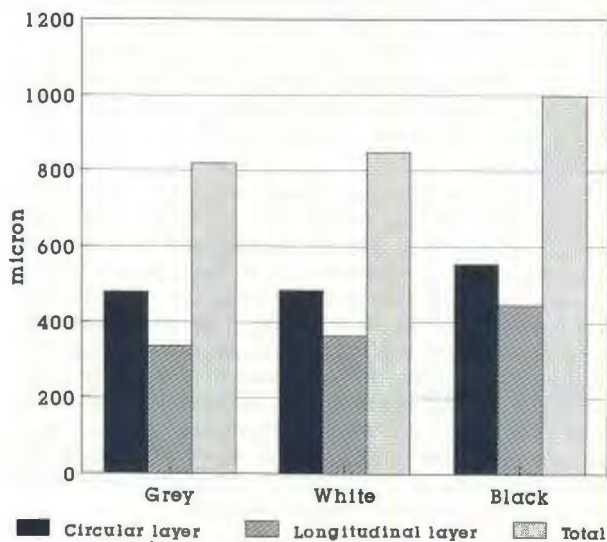


FIG. 2 Thickness of the tunica muscularis of the reticulum

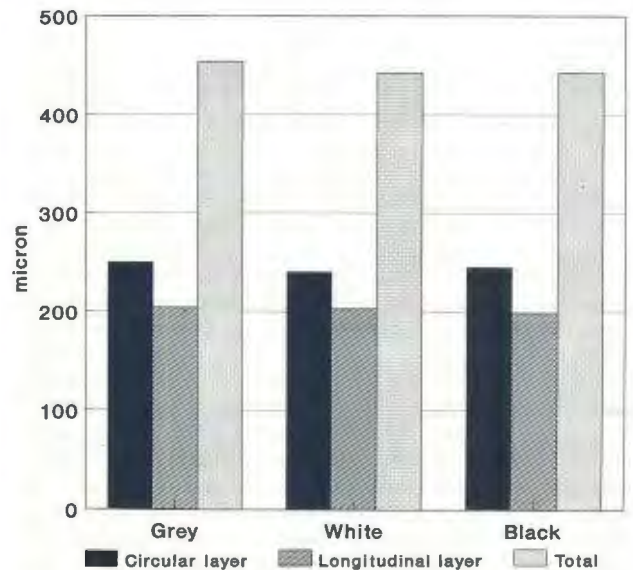


FIG. 4 Thickness of the tunica muscularis of the omasum

(Fig. 3); the grey group displaying the thinnest and the black group the thickest layer. No significant differences were found in the thickness of the tunica muscularis of the omasum ( $F$  ratio = 0,74) (Fig. 4). It would seem that the outer longitudinal layer was more affected than the inner circular layer.

DISCUSSION

Nel (1965) observed that homozygous grey Karakul lambs had a distended rumen with thinner walls at weaning age when compared to normal black lambs. The present study indicated that the walls of the rumen, reticulum and abomasum of homozygous grey and to a lesser extend homozygous white lambs are thinner than those of normal black

Karakul lambs at 24 hours of age, and that this is due to reduction in thickness of the tunica muscularis. These results indicate that the thinner walls observed by Nel (1965) were not due to ruminal distension alone, although distension with milk might result in further thinning.

It appears that only structures which develop from the greater curvature of the foetal stomach are affected. The omasum, which had walls of normal thickness in all the lambs measured, develops from the lesser curvature, whereas the rumen and reticulum develop from the greater curvature, and the abomasum from both (Bryden, Evans & Binns, 1972).

Embryologically the inner circular layer of the tunica muscularis develops first (Bryden *et al.*, 1972; Duncan & Phillipson, 1951), followed by the nervous layer and finally the outer longitudinal layer (Duncan & Phillipson, 1951). Duncan & Phillipson (1951) observed contractions of the smooth muscle of the inner circular layer of the tunica muscularis before the development of the nervous layer. The smooth muscle therefore has an intrinsic ability to contract. The reduction in the thickness of the tunica muscularis in the affected lambs could thus lead to an abatement of the movement of the rumen, reticulum and abomasum causing insufficient digestion and absorption of nutrients. This could lead to starvation and death.

Nerve supply plays a major role in the movement of the forestomachs and abomasum of ruminants (Habel, 1956). Vagal stimulation in the foetus causes movement of all the stomachs (Duncan & Phillipson, 1951). Both the intrinsic ability of the smooth muscle to contract and a functional nerve supply are thus essential for the movement of the stomachs, and there is a possibility that a defective nerve supply may play a role in the lethal condition described. This would be supported by the fact that the outer longitudinal muscle layer appeared to be

more affected than the inner layer, possibly due to defective nerve supply causing atrophy. It also seems possible that the distension of the rumen with milk described by Groenewald & Booth (1989) is due to failure of the oesophageal reflex caused by inadequate nerve supply.

It is concluded that the reduction in the thickness of the tunica muscularis is one of the factors causing the lethal condition in homozygous grey lambs.

#### REFERENCES

- BRYDEN, M. M., EVANS, H. E. & BINNS, W., 1972. Embryology of the sheep. *Journal of Morphology*, 138, 187-206.
- DUNCAN, D. L. & PHILLIPSON, A. T., 1951. The development of motor responses in the stomach of foetal sheep. *Journal of Experimental Biology*, 28, 32-40.
- GROENEWALD, H. B. & BOOTH, K. K., 1989. An anatomical comparison of the rumen of grey, white and black Karakul lambs. *South African Journal of Science*, 85, p. 446 (Abstract).
- HABEL, R. E., 1956. A study of the innervation of the ruminant stomach. *Cornell Veterinarian*, 46, 555-633.
- NEL, J. A., 1965. The effects of the sub-lethal factor on the internal organs of the grey Karakul. *Proceedings of the South African Society of Animal Production*, 1965, 282-285.
- NEL, J. A. & LOUW, D. J., 1953. The lethal factor in grey Karakul lambs. *Farming in South Africa*, 5, 169-172.