

# Genetic testing of canine degenerative myelopathy in the South African Boxer dog population

**Authors:**

Gareth E. Zeiler<sup>1</sup>  
Henriette van der Zwan<sup>2</sup>  
Marinda C. Oosthuizen<sup>3</sup>

**Affiliations:**

<sup>1</sup>Department of Companion Animal Clinical Studies, University of Pretoria, South Africa

<sup>2</sup>Inqaba Biotec, Pretoria, South Africa

<sup>3</sup>Department of Veterinary Tropical Diseases, University of Pretoria, South Africa

**Correspondence to:**

Gareth Zeiler

**Email:**

gareth.zeiler@up.ac.za

**Postal address:**

Private Bag X04,  
Onderstepoort 0110,  
South Africa

**Dates:**

Received: 18 Feb. 2013  
Accepted: 10 May 2013  
Published: 27 Sept. 2013

**How to cite this article:**

Zeiler, G.E., Van der Zwan, H. & Oosthuizen, M.C., 2013, 'Genetic testing of canine degenerative myelopathy in the South African Boxer dog population', *Journal of the South African Veterinary Association* 84(1), Art. #1005, 5 pages. <http://dx.doi.org/10.4102/jsava.v84i1.1005>

**Copyright:**

© 2013. The Authors.  
Licensee: AOSIS  
OpenJournals. This work is licensed under the Creative Commons Attribution License.

**Read online:**

Scan this QR code with your smart phone or mobile device to read online.

Canine degenerative myelopathy (DM) is a progressive disease process that is diagnosed late in life and mainly affects the pelvic limbs. Factors that make an ante-mortem definitive diagnosis of DM include: an insidious onset and clinical manifestation that mimics other disease processes of the pelvic limbs (hip dysplasia, cranial cruciate ligament rupture, etc.) or there may even be concurrent disease processes, old-age onset and lack of reliable diagnostic methods. Until recently, South African dog owners had to submit samples to laboratories overseas for genetic testing in order to confirm an affected dog (homozygous A/A) and to aid in the ante-mortem diagnosis of DM. Only affected dogs have been confirmed to manifest the clinical signs of DM. This study aimed to verify whether genetic testing by a local genetic laboratory was possible in order to detect a missense mutation of the superoxide dismutase gene (SOD1) that is implicated in causing the clinical signs of DM. The study also aimed to detect and map the inheritance of this disease process in a local Boxer dog population where the pedigree of the sampled population was known. Venous blood collected from Boxer dogs using a simple random sampling technique. The samples were genotyped for the SOD1:c.118G>A polymorphism. Carrier and affected Boxer dogs were detected. A pedigree that demonstrated the significance of inheriting a carrier or affected state in the population was mapped. The present study concludes that genotyping of the missense mutation in Boxer dogs is possible in South Africa. There are carrier and affected Boxer dogs in the local population, making DM a plausible diagnosis in aged dogs presenting with pelvic limb pathology.

## Introduction

Clinical and pathological findings of degenerative myelopathy (DM) were first described in the German Shepherd dog by Averill (1973). In the earlier descriptions of this disease process, canine DM has also been called chronic degenerative radiculomyelopathy (Griffiths & Duncan 1975), German Shepherd dog myelopathy (Braund & Vandeveld 1978) and progressive myelopathy (Waxman, Clemmons & Hinrichs 1980). Early investigation of the clinical manifestations of DM, which were most often recognised in the German Shepherd dog, suggested an inherent breed genetic predisposition (Braund & Vandeveld 1978). Investigation into leukocyte behaviour suggested an autoimmune-based aetiology (Waxman, Clemmons & Hinrichs 1980). Hereditary factors were suspected when DM was described in closely related Siberian Husky dogs (Bichsel *et al.* 1983). To date, DM has been diagnosed in many different dog breeds (Coates & Winger 2010). The five most frequently diagnosed dog breeds with DM are German Shepherd dogs, Pembroke Welsh corgis, Boxer dogs, Rhodesian ridgebacks and Chesapeake Bay retrievers (Awano *et al.* 2009; Coates *et al.* 2007).

Characteristic clinical presentation of DM includes: an insidious, progressive onset of asymmetric upper motor neuron (UMN) paraparesis; general proprioceptive pelvic limb ataxia; and lack of paraspinal hyperaesthesia (Awano *et al.* 2009; Coates *et al.* 2007; Coates & Winger 2010). These clinical signs are typical of the early stages of DM and may also include worn nails, spinal reflexes consistent with UMN paresis localised in the T3 to L3 spinal cord segment (Averill 1973), inconsistent patella reflex (normal, hyporeflexia, hyperreflexia) and normal withdrawal reflexes that may demonstrate crossed extension, which is suggestive of a chronic UMN dysfunction.

Owners often elect euthanasia when the clinical signs progress to a non-ambulatory paraparesis (Awano *et al.* 2009; Coates & Winger 2010). Clinical signs will progress in the late stage of DM and include lower motor neuron paraplegia that may ascend to the thoracic limbs (Averill 1973; Awano *et al.* 2009; Coates *et al.* 2007; Coates & Winger 2010). Flaccid tetraplegia, possible involvement of the cranial nerves presenting as swallowing difficulties and inability to bark, urinary and faecal incontinence, and muscle mass loss may occur in the very advanced stages (Averill 1973; Awano *et al.* 2009; Coates *et al.* 2007; Coates & Winger 2010). The mean age of onset and mean duration of clinical signs in the Boxer dog are 9.3 years and 11.2 months respectively (Coates & Winger 2010). Mean age of death in the Boxer dog is 10.3 years (Coates & Winger 2010).

Advances in molecular genetics have progressed to genome-wide association mapping of DM using the Canine Genome (GeneChip Canine Genome 2.0 Array; Affymetrix, USA) (Awano *et al.* 2009). The strongest association was detected in the chromosome of *Canis familiaris* 31 (CFA31), where a mutation of the gene encoding superoxide dismutase 1 (SOD1) was mapped and localised to a 5-SNP (single nucleotide polymorphism) haplotype. The area of the genome contains the E40K missense mutation that predicts a G to A transition in exon 2, corresponding to nucleotide 118 of the complementary DNA (cDNA). This area is thought to be responsible for encoding a defect in the SOD1 amino acid chain (Awano *et al.* 2009). The defect is where a glutamic acid to lysine missense mutation at amino acid 40 (Coates & Wininger 2010) is predicted. Dogs may be genotyped into three different categories, based on the genotypic expression of the SOD1:c.118 allele, namely: unaffected, carrier, or at-risk or affected (Awano *et al.* 2009; Coates *et al.* 2007; Coates & Wininger 2010).

The present study was aimed at detecting carrier and/or affected Boxer dogs of DM in the South African population using a SOD1:c.118G>A genetic test that had recently been developed in South Africa. This article also discusses the potential clinical relevance within a South African context.

## Materials and Methods

The prospective, owner-consented, blind, observational study was approved by the Animal Use and Care Committee of the University of Pretoria (Protocol V005-13).

### Animals

A targeted sample size of 50 Boxer dogs was genotyped for the SOD1:c.118G>A polymorphism. No exclusion criteria on age, sex or pedigree were enforced. A history of prior hind limb pathology and gait abnormalities was obtained to determine possible phenotypic expression of DM. A simple random sampling technique was used where the owners were made aware of the study 2 weeks prior to the sample collection and were allowed to enrol their dog or dogs at their own will on the day of sample collection. It was prohibited to encourage, promote or entice the owners to participate in the study.

### Sample collection and storage

Boxer dogs were sampled at two dog show days hosted by clubs affiliated with the Federation of Boxer Clubs of Southern Africa (FBCSA). An owner-signed consent form and dog pedigree registration certificate showing the last three generations was required before sampling. Venous blood (2 mL) was aseptically collected from either the left or right cephalic vein using a syringe and needle. The collected sample was transferred to a vacuumed Ethylenediaminetetraacetic acid (EDTA) collection tube and stored on ice in a cooler box. Upon return to the University, the samples were stored overnight in a refrigerator before being transported on ice in

a cooler box to the genetic testing laboratory. The number of dogs participating in the two shows and an estimated Boxer dog population size based on the FBCSA database were determined.

### Genotyping of the superoxide dismutase gene:c.118 allele

The genetic testing laboratory (Inqaba Biotec, South Africa) developed an in-house DM test, which was based on literature published on the canine SOD1 gene (Awano *et al.* 2009). The genetic testing laboratory synthesised their own oligonucleotides used for testing, based on the sequences published by Awano *et al.* (2009). DNA was extracted and purified using a kit (Zymo Research Quick-gDNA MicroPrep kit, Zymo Research Corporation [USA] 17062 Murphy Ave. Irvine, CA 92614). A polymerase chain reaction (PCR) amplification was carried out on a cyclor (ABI GeneAmp PCR system 9700 thermal cyclor; Applied Biosystems) to amplify the gene of interest. The cycle conditions are given in Table 1. Thereafter, the amplicons were sequenced on an analyser (ABI PRIS 3130 Genetic Analyzer; Applied Biosystems) to determine the nucleotide sequence of the gene. Boxer dogs were genotyped into three different categories, namely: clear or unaffected (homozygous G/G), carrier (heterozygous A/G), and at-risk or affected (homozygous A/A) based on the genotypic expression of the SOD1:c.118 allele. Where applicable, the registration certificate information of the pedigree was used to describe the hereditary nature of the mutation in the SOD1 gene in the sampled population.

### Statistical analysis

The age of the sampled Boxer dog population was described as median (maximum-minimum) in years. A spreadsheet software package (Microsoft Office Excel 2007; Microsoft Corporation USA) was used to organise and calculate information from the data collected. Point prevalence of dogs genotyped as affected for the SOD1 mutation in the FBCSA Boxer dog population was calculated as follows: number of dogs genotyped as being affected when sampled on the show day divided by the total number of dogs participating in the show on the sample day; this number was then converted into a percentage. Overall prevalence of affected genotyped dogs was calculated as follows: known number of affected genotyped Boxer dogs divided by the estimated FBCSA dog population. This number was then converted into a percentage.

## Results

A total of 52 (29 female, 23 male) Boxer dogs were tested. The sample population had a median median age of 2.7

**TABLE 1:** PCR Cycle conditions.

Phase of complete cycle	Temperature	Time
Phase 1 (1 cycle)	98 °C	3 min
Phase 2 (30 cycles)	98 °C	15 s
	59 °C	75 s
	72 °C	30 s
Phase 3 (1 cycle)	72 °C	5 min

(maximum of 9.7; minimum of 0.53) years. The numbers of clear, carrier and affected Boxer dogs are summarised in Table 2. The percentages of dogs sampled per show were 72.7% and 68.3% for show day 1 and show day 2 respectively.

The hereditary nature of DM was detected in one line of Boxer dogs that were sampled (Figure 1). The progeny of the only affected dog genotyped during the data collection were subsequently tested and an additional five affected dogs were detected. The owner of the affected dog did indicate a history of pelvic limb abnormalities that had not been definitively diagnosed as DM, instead cranial cruciate ligament injury was suspected on cursory clinical examination.

Point prevalence of Boxer dogs genotyped as affected were 3.03% and 0.00% for show day 1 and show day 2 respectively. Based on current database information, the estimated FBCSA population is 2650 Boxer dogs. Current overall prevalence of affected Boxer dogs within the FBCSA dog population is estimated  $([1 \text{ affected} + 5 \text{ affected progeny}/2650] \times 100)$  at 0.23%.

## Discussion

The present study determined that the recently available genetic test for canine DM in South Africa was able to

genotype the SOD1:c.118 allele in a Boxer dog population. Clear, carrier and affected Boxer dogs were identified despite none of them demonstrating typical clinical signs of DM on examination. Enquiring about past pelvic limb or gait abnormalities suggested acute injuries to the stifle joint, with cranial cruciate ligament injury as the most common historical finding.

The DM associated SOD1:c.118A homozygous (affected) allele has been identified in no less than 91 different dog breeds (Coates & Wininger 2010). Despite identifying the genotypic variation that causes a missense mutation in the gene coding for SOD1, it remains unclear as to whether affected animals will express phenotypic traits of DM during their lifetime (Awano *et al.* 2009; Coates *et al.* 2007). Previous studies have found that affected dogs may not exhibit clinical signs of DM, which suggests an incomplete penetrance. The incomplete penetrance may be due to modifier loci, environmental factors, and/or death of affected dogs due to other causes before the clinical signs of DM manifest (Awano *et al.* 2009). Thus, the current literature suggests that an affected dog is at risk of developing clinical signs of DM and not that the dog will develop clinical signs of DM owing to incomplete penetrance (Awano *et al.* 2009; Coates *et al.* 2007; Coates & Wininger 2010).

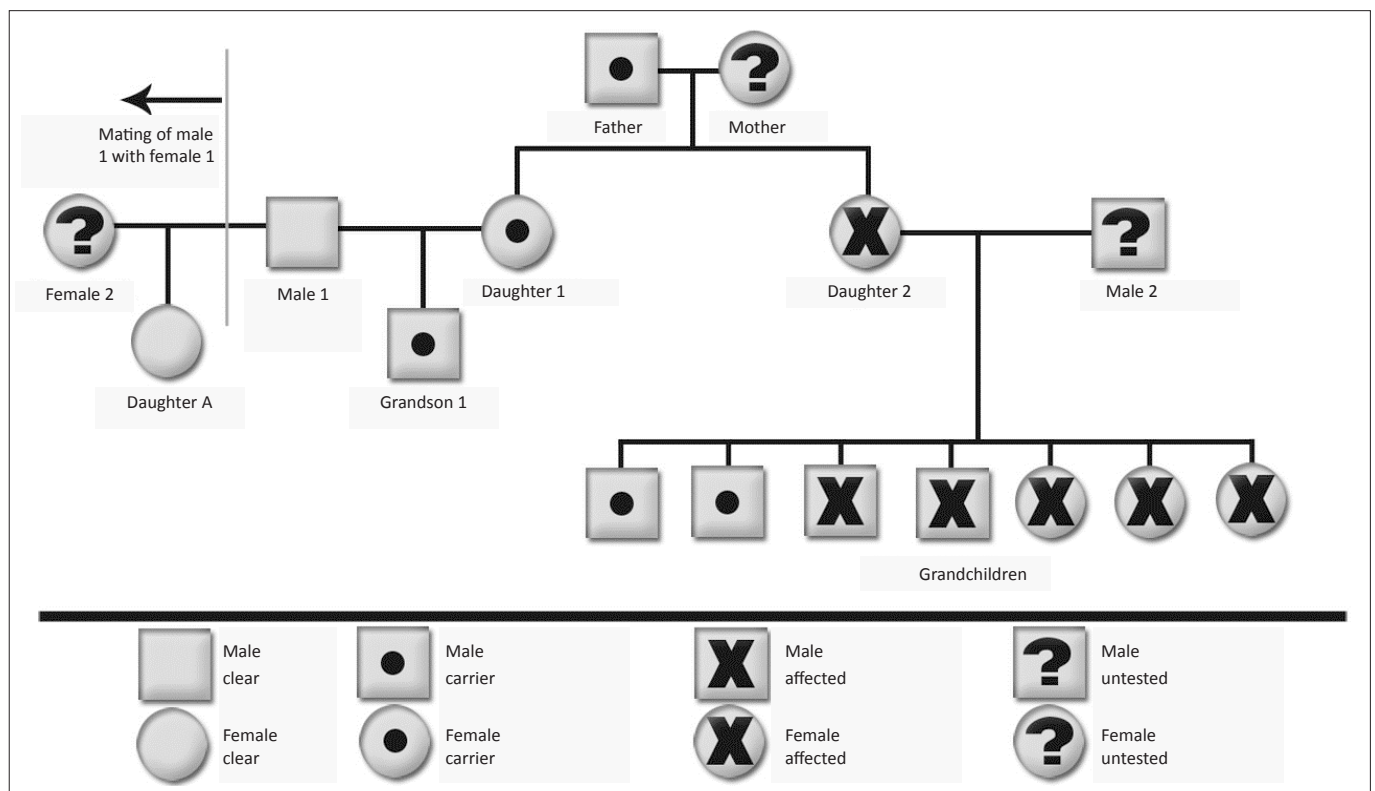


FIGURE 1: A graphical demonstration of canine degenerative myelopathy heritage in a South African Boxer dog family.

TABLE 2: Summary of Boxer dogs genotyped for canine degenerative myelopathy.

Show Day	Number of dogs at show	Number of dogs tested	Clear	Carrier	Affected
Day 1	33	24	15	8	1
Day 2	41	28	22	6	0
<b>Total</b>	<b>74</b>	<b>52</b>	<b>37</b>	<b>14</b>	<b>1</b>

Note: Clear is homozygous G/G, Carrier is heterozygous A/G and Affected is homozygous A/A.

The characteristic clinical signs associated with DM are attributed to the histopathological changes in the spinal cord thought to be due to the malformation of the SOD1 protein (Awano *et al.* 2009; Barclay & Haines 1994; Clemmons 1992; Coates *et al.* 2007; Coates & Winingering 2010; Cork *et al.* 1987; Johnston *et al.* 2000; Miller *et al.* 2009; Ogawa *et al.* 2011; Shelton *et al.* 2012; Tsai *et al.* 2012; Winingering *et al.* 2011). The SOD1 protein functions as a free radical scavenger within the central nervous system (Awano *et al.* 2009; Coates & Winingering 2010). The missense mutation causes the SOD1 protein to fold incorrectly, which reduces its net negative charge. This is thought to be the cause of increased intracellular accumulation and aggregation of this protein due to either reduced repulsive Coulombic forces or increased anionic membrane surface interaction (Coates & Winingering 2010). These insoluble intracellular SOD1 aggregates are thought to either alter intracellular function or alter the enzyme substrate specificity, leading to toxic by-product production that causes the neurodegenerative changes associated with the disease (Coates & Winingering 2010). These characteristic histopathological lesions are considered diagnostic for DM, but samples are only taken during post-mortem examination (Awano *et al.* 2009; Coates & Winingering 2010; Johnston *et al.* 2000; Miller *et al.* 2009). A tentative ante-mortem diagnosis may be made on characteristic clinical presentation in the absence of other thoracolumbar myelopathy aetiologies (Awano *et al.* 2009; Coates *et al.* 2007; Coates & Winingering 2010).

Other disease processes may coexist or even mimic and confound a definitive diagnosis of DM, including degenerative lumbosacral syndrome, intervertebral disc disease, spinal cord neoplasia and degenerative joint diseases such as hip dysplasia or cranial cruciate ligament rupture (Coates & Winingering 2010). The historical finding of cranial cruciate ligament injury of the affected Boxer dog (3 years old) in the present study could indicate that there may be a link between these coexisting disease processes and DM. An affected genotyped dog will greatly increase the suspicion of DM as being the definitive diagnosis only in patients presenting with the characteristic clinical signs. Other ante-mortem diagnostic tests have included magnetic resonance imaging (Coates & Winingering 2010), computer tomography (Jones *et al.* 2005), cerebrospinal fluid examination (Kamishina *et al.* 2008; Oji *et al.* 2007), electrodiagnostic testing (Coates *et al.* 2007; Shelton *et al.* 2012) and neuromuscular biopsies (Awano *et al.* 2009; Coates & Winingering 2010; Shelton *et al.* 2012), which may assist in definitively diagnosing DM; however, these diagnostic tests are not always positive (Awano *et al.* 2009; Coates & Winingering 2010; Okada *et al.* 2009; Oliver 1993). A definitive diagnosis of DM in the ante-mortem stage remains a challenge (Coates & Winingering 2010). The link between the genotypic expression of the SOD1 mutation, the histopathological findings and the clinical manifestation cannot be ignored.

Previous studies have indicated that both normal and carrier dogs present with clinical signs of DM; however, these

findings were not definitively diagnosed on histopathology and thus other possible aetiological causes cannot be excluded (Awano *et al.* 2009; Coates & Winingering 2010). Carrier dogs do have characteristic immuno-histopathological lesions that react with antibodies against the faulty SOD1 protein as in affected dogs, but are not associated with clinical manifestation of the disease (Awano *et al.* 2009; Barclay & Haines 1994; Coates & Winingering 2010), perhaps due to incomplete penetrance.

Degenerative myelopathy was not definitively diagnosed in any of the participating Boxer dogs in the present study and thus disease prevalence could not be calculated or estimated. The calculated point prevalence and overall prevalence were therefore based on detecting affected genotyped Boxer dogs in the FBCSA population. The overall prevalence of affected genotyped Boxer dogs was determined to be 0.23%, which is close to the current overall estimated prevalence of diagnosed DM of 0.19% (Coates *et al.* 2007; Shelton *et al.* 2012). These results indicate that DM should not be ignored as a possible differential diagnosis in aged Boxer dogs presenting with pelvic limb abnormalities. The clinical significance of this finding is difficult to appreciate at present as the affected dog did have a history of pelvic limb pathology characteristic of cranial cruciate ligament injury and not of DM. Due to the old age onset and progressive nature of the disease, the genotyping may become clinically significant in the future.

## Conclusion

The present study concludes that genotyping of the missense mutation in Boxer dogs is possible in South Africa and that there are carrier and affected Boxer dogs in the South African population. This makes degenerative myelopathy a plausible diagnosis in aged dogs presenting with pelvic limb pathology. Owing to the late onset and insidious nature of the disease process, owners of Boxer dogs (and other commonly affected breeds) should consider genotyping prior to breeding.

## Acknowledgements

The authors would like to thank the FBCSA and owners of the Boxer dogs for participating in this study. Publication of this article was sponsored by the Wildlife Group (<http://www.vets4wildlife.co.za>) of the South African Veterinary Association.

## Competing interests

The authors declare that they have no financial or personal relationship(s) that may have inappropriately influenced them in writing this article.

## Authors' contributions

M.C.O. (University of Pretoria) liaison between the Federation of Boxer Clubs of Southern Africa and other investigators, and organiser of sample collection days. H.v.d.Z. (Inqaba Biotec) genetic testing of Boxer dogs samples. G.E.Z. (University of Pretoria) collection of samples from Boxer dogs and publication writing.



## References

- Averill, D.R. (Jr), 1973, 'Degenerative myelopathy in the aging German Shepherd dog: clinical and pathologic findings', *Journal of the American Veterinary Medical Association* 162, 1045–1051. PMID:4196853
- Awano, T., Johnson, G.S., Wade, C.M., Katz, M.L., Johnson, G.C., Taylor, J.F. *et al.*, 2009, 'Genome-wide association analysis reveals a SOD1 mutation in canine degenerative myelopathy that resembles amyotrophic lateral sclerosis', *Proceedings of the National Academy of Sciences of the United States of America* 106, 2794–2799. PMID:19188595, PMCID:2634802
- Barclay, K.B. & Haines, D.M., 1994, 'Immunohistochemical evidence for immunoglobulin and complement deposition in spinal cord lesions in degenerative myelopathy in German shepherd dogs', *Canadian Journal of Veterinary Research* 58, 20–24. PMID:8143248, PMCID:1263654
- Bichsel, P., Vandeveld, M., Lang, J. & Kull-Hachler, S., 1983, 'Degenerative myelopathy in a family of Siberian Husky dogs', *Journal of the American Veterinary Medical Association* 183, 998–1000, 965.
- Braund, K.G. & Vandeveld, M., 1978, 'German Shepherd dog myelopathy – a morphologic and morphometric study', *American Journal of Veterinary Research* 39, 1309–1315. PMID:697138
- Clemmons, R.M., 1992, 'Degenerative myelopathy', *Veterinary Clinics of North America: Small Animal Practice* 22, 965–971. PMID:1641928
- Coates, J.R., March, P.A., Oglesbee, M., Ruaux, C.G., Olby, N.J., Berghaus, R.D. *et al.*, 2007, 'Clinical characterization of a familial degenerative myelopathy in Pembroke Welsh Corgi dogs', *Journal of Veterinary Internal Medicine* 21, 1323–1331. <http://dx.doi.org/10.1111/j.1939-1676.2007.tb01955.x>, PMID:18196743
- Coates, J.R. & Wininger, F.A., 2010, 'Canine degenerative myelopathy', *Veterinary Clinics of North America: Small Animal Practice* 40, 929–950. <http://dx.doi.org/10.1016/j.cvsm.2010.05.001>, PMID:20732599
- Cork, L.C., Kitt, C.A., Struble, R.G., Griffin, J.W. & Price, D.L., 1987, 'Animal models of degenerative neurological disease', *Progress in Clinical and Biological Research* 229, 241–269. PMID:3601987
- Griffiths, I.R. & Duncan, I.D., 1975, 'Chronic degenerative radiculomyelopathy in the dog', *Journal of Small Animal Practice* 16, 461–471. <http://dx.doi.org/10.1111/j.1748-5827.1975.tb05773.x>, PMID:1195675
- Johnston, P.E., Barrie, J.A., McCulloch, M.C., Anderson, T.J. & Griffiths, I.R., 2000, 'Central nervous system pathology in 25 dogs with chronic degenerative radiculomyelopathy', *Veterinary Record* 146, 629–633. <http://dx.doi.org/10.1136/vr.146.22.629>, PMID:10872782
- Jones, J.C., Inzana, K.D., Rossmeis, J.H., Bergman, R.L., Wells, T. & Butler, K., 2005, 'CT myelography of the thoraco-lumbar spine in eight dogs with degenerative myelopathy', *Journal of Veterinary Science* 6, 341–348. PMID:16293999
- Kamishina, H., Oji, T., Cheeseman, J.A. & Clemmons, R.M., 2008, 'Detection of oligoclonal bands in cerebrospinal fluid from German Shepherd dogs with degenerative myelopathy by isoelectric focusing and immunofixation', *Veterinary Clinical Pathology* 37, 217–220. <http://dx.doi.org/10.1111/j.1939-165X.2008.00020.x>, PMID:18533922
- Miller, A.D., Barber, R., Porter, B.F., Peters, R.M., Kent, M., Platt, S.R. *et al.*, 2009, 'Degenerative myelopathy in two Boxer dogs', *Veterinary Pathology* 46, 684–687. <http://dx.doi.org/10.1354/vp.08-VP-0270-M-BC>, PMID:19276068
- Ogawa, M., Uchida, K., Park, E.S., Kamishina, H., Sasaki, J., Chang, H.S. *et al.* 2011, 'Immunohistochemical observation of canine degenerative myelopathy in two Pembroke Welsh Corgi dogs', *Journal of Veterinary Medical Science* 73, 1275–1279. <http://dx.doi.org/10.1292/jvms.11-0097>, PMID:21628865
- Oji, T., Kamishina, H., Cheeseman, J.A. & Clemmons, R.M., 2007, 'Measurement of myelin basic protein in the cerebrospinal fluid of dogs with degenerative myelopathy', *Veterinary Clinical Pathology* 36, 281–284. <http://dx.doi.org/10.1111/j.1939-165X.2007.tb00225.x>, PMID:17806078
- Okada, M., Kitagawa, M., Kanayama, K., Yamamura, H. & Sakai, T., 2009, 'Negative MRI findings in a case of degenerative myelopathy in a dog', *Journal of the South African Veterinary Association* 80, 254–256. <http://dx.doi.org/10.4102/jsava.v80i4.222>, PMID:20458868
- Oliver, J.E., 1993, 'What is your neurologic diagnosis? Degenerative myelopathy in a dog, based on negative results of all diagnostic tests', *Journal of the American Veterinary Medical Association* 203, 647–648. PMID:8407528
- Shelton, G.D., Johnson, G.C., O'Brien, D.P., Katz, M.L., Pesayco, J.P., Chang, B.J. *et al.*, 2012, 'Degenerative myelopathy associated with a missense mutation in the superoxide dismutase 1 (SOD1) gene progresses to peripheral neuropathy in Pembroke Welsh Corgis and Boxers', *Journal of the Neurological Sciences* 318, 55–64. <http://dx.doi.org/10.1016/j.jns.2012.04.003>, PMID:22542607
- Tsai, K.L., Noorai, R.E., Starr-Moss, A.N., Quignon, P., Rinz, C.J., Ostrander, E.A., *et al.*, 2012, 'Genome-wide association studies for multiple diseases of the German Shepherd Dog', *Mammalian Genome* 23, 203–211. <http://dx.doi.org/10.1007/s00335-011-9376-9>, PMID:22105877, PMCID:3509149
- Waxman, F.J., Clemmons, R.M. & Hinrichs, D.J., 1980, 'Progressive myelopathy in older German shepherd dogs. II. Presence of circulating suppressor cells', *Journal of Immunology* 124, 1216–1222. PMID:6444648
- Wininger, F.A., Zeng, R., Johnson, G.S., Katz, M.L., Johnson, G.C., Bush, W.W. *et al.*, 2011, 'Degenerative myelopathy in a Bernese Mountain Dog with a novel SOD1 missense mutation', *Journal of Veterinary Internal Medicine* 25, 1166–1170. <http://dx.doi.org/10.1111/j.1939-1676.2011.0760.x>, PMID:21848967