

Oligodontia – treatment planning of a case

SADJ October 2012, Vol 67 no 9 p502 - p506

NN Desai¹, SM Dawjee²

"The Journal recognises the celebration of the Department of Orthodontics, University of Pretoria - a fiftieth birthday this year! Over the years so many developments, so many achievements, so wonderful a service to the profession and, importantly, to the country. This paper is part of those celebrations. Every congratulation!" - Editor



INTRODUCTION

The numerous abnormalities of teeth can be divided into those that are primary, idiopathic and appear hereditary in nature¹ and those influenced by environmental forces (e.g., concrescence, hypercementosis, and dilacerations).

Variation in the number of teeth that develop is a common abnormality, described by terms specific to the extent of the problem. **Anodontia** refers to a total lack of tooth development. **Hypodontia**, on the other hand, denotes the lack of development of one or more teeth; and **oligodontia** (which is a subdivision of hypodontia) indicates the lack of development of six or more teeth, excluding the third molars.² These definitions do not of themselves indicate the complexity of the required management as the number of missing teeth determines how extensive treatment will have to be.

Hypodontia in the permanent dentition has been reported as having an incidence of between 1.6% to 9.6%, when the absence of third molars is excluded, the prevalence increasing to 20% if third molars are considered.¹ The relative frequency of the missing teeth or tooth varies between different ethnic groups³ but those most commonly absent are:⁴

- mandibular second premolars;
- maxillary lateral incisors;
- maxillary second premolars; and
- mandibular central incisors.

Patients with congenitally missing teeth suffer aesthetic, functional and psychological disability to varying degrees through childhood, adolescence and in adulthood. Therefore the aim of the dental rehabilitation of patients who are congenitally missing teeth is to achieve and maintain a functional, healthy and aesthetically acceptable dentition throughout the life of the individual.⁵ The restorative dentist must be involved in the treatment planning of these patient groups from the outset. In

patients presenting with only one or two teeth that have failed to develop, for example where only a single premolar is missing, it may be appropriate for the orthodontist to make decisions without the advice of, or consultation with, other dental specialties. However, in the more severe cases, where there are multiple teeth missing or where the absence has obvious aesthetic or functional implications, the patient should be examined as part of a multi-disciplinary team.⁵

The main options in treating patients with hypodontia and the resulting edentulous space are orthodontic space closure, adhesive bridgework, conventional bridgework, removable prostheses or implants.⁶ Alternatively, the space could be accepted or, occasionally, an autotransplantation may be effective.

FACTORS INFLUENCING TREATMENT PLANNING

Treatment planning will involve several factors.

Severity of hypodontia

The majority of patients with hypodontia present with one or two congenitally missing teeth.⁶ As the number of missing teeth increases there will be a greater need to involve a multidisciplinary team.

Underlying skeletal and incisor relationship

When rendering treatment, the orthodontist aims to provide the patient with a Class I incisor relationship. Therefore, in Class I malocclusion, when teeth are missing in the maxillary arch and the mandibular arch requires extractions, space closure may be the best option.⁷ Similarly in Class II, division 1 malocclusion, when teeth are missing in the maxillary arch, space closure may be a better option as the spaces related to the missing teeth can be used to reduce the overjet.⁷ However, in patients with a Class III relationship, it may be prudent to replace missing maxillary teeth to maintain a positive overjet.⁸

Facial profile

As with any malocclusion, facial profile at the start of treatment plays an important role in the treatment approach to the case. In patients with bimaxillary protrusion, the spaces at the sites of the missing teeth can facilitate retraction if the patient desires a less prognathic profile. However, in patients with a retrusive profile, the retraction of anterior teeth to close space may have a detrimental effect on his or her lip posture and could further "dish-in" the profile.⁷

1. **NN Desai:** BChD (UWC), PDD(Ortho)(UWC), MChD (Ortho)(UP). Consultant: Department of Orthodontics, University of Pretoria.

2. **SM Dawjee:** BChD, BChDHons, MSc(Odont), MDent(Ortho), PGDipIRE, PhD. Head of Department: Department of Orthodontics, University of Pretoria.

Corresponding author

NN Desai:

P.O. Box 1266, Pretoria, 0001. Tel: 012 319 2306/2510, Cell: 082 777 0045, Fax: 012 328 6697/ 086 622 4420
E-mail: Nitinkumar.Desai@up.ac.za / desainn@hotmail.com

Tooth size

Patients with hypodontia often have associated microdontia.¹ In patients with mild hypodontia, where one maxillary lateral incisor is missing, the other lateral incisor is usually small, and if it is decided to close spaces then extraction of the small incisor is indicated to preserve the dental midline and symmetry.⁹

In patients presenting with hypodontia and associated microdontia, the chance of space opening subsequent to treatment is great, and therefore these cases are destined for prolonged retention or the placement of crowns.¹⁰

Colour and shape of adjacent teeth

This is an important consideration when space closure is undertaken in the maxillary arch where lateral incisors are missing and the aim is to move the canines mesially. Modification in shape and size of the canines is required to mimic the lateral incisors. Veneering may be necessary, as the canines are generally yellower and less translucent than incisors and are also wider labiolaterally and mesiodistally.¹⁰ Vital bleaching can also be performed on the canine to achieve a better colour match with the central incisors.¹⁰ If these factors are not favourable, the bias will be away from the space closure option, on an aesthetic basis, even though other factors may support space closure.⁷

Age, motivation and expectation

Early detection of the absence of teeth may influence a decision toward closure of space.⁷ Timely extraction of primary teeth will facilitate eruption and, most favourably, natural space closure may occur by mesial migration of permanent teeth.¹¹ More commonly, however, residual spaces remain which will require treatment.

Lip line

If a patient has a high lip line, anterior space closure in the maxillary arch may leave a less-than-desirable aesthetic result, the more so if the canine has an unfavourable morphology and is relatively darker in colour. Furthermore, the height differences of the respective gingival margins of a canine next to a central incisor will produce a less than ideal aesthetic result.

Orthodontics can treat many but not all of these factors and it is important to decide on the most appropriate options after consulting with the multidisciplinary dental team.

MANAGEMENT

Caries-prevention with adequate oral hygiene care is first priority. One of the aims of treatment may be the preservation of deciduous teeth, which in turn will ensure the maintenance of alveolar bone.¹² However, any that hamper orthodontic or prosthodontic therapy and are infra-occluded may have to be removed. In the implementation of these regimens the general dental practitioner becomes the primary role player. At an early stage of the child's development, referral to the orthodontist and the prosthodontist is imperative, to seek further insight on the treatment options.

Replacement of the missing teeth can be effected by either a removable or fixed prosthesis. A partial denture or overdenture may have a place in providing temporary tooth replacements and ensuring space-maintenance following completion of orthodontic treatment.¹³ This is particularly true for patients with oligodontia. The prosthesis provides important diagnostic information concerning the position of replacement teeth and the possible need for an increased occlusal face height, together with the opportunity for gauging compliance with re-

movable appliances. The instability of dentures, however, is functionally and socially unacceptable to many patients and fixed prostheses can be employed when growth is complete. Consideration must also be given as to whether the edentate saddle is of favourable contour and span.¹² Adhesive bridges are particularly suited to the restoration of one or two tooth spaces for teenagers and young adults, and are commonly used as an interim replacement for teeth following finalization of orthodontic treatment and until completion of craniofacial growth allows for implant placement.¹³ For both these options of removable and fixed prostheses, the condition of the abutment teeth is crucial to the life of the restoration.

Tooth transplantation can be useful in some hypodontia patients, offering options to:

- Reposition an ectopic tooth into a natural position; and
- Transfer a tooth into another position in either arch, for example where only one jaw is deficient in tooth number and the other jaw exhibits crowding.¹³

Dental implants are also an option in the restorative cycle. Their use is dictated by factors such as age, bone type, width and depth of available bone.¹² Equally important is the state of the static and dynamic occlusion. Consideration must also be given to the concerns, compliance and habits of the patient.

CASE REPORT

A 19-year-old female patient presented to the Orthodontic Department, Oral and Dental Hospital, University of Pretoria. Her main complaint was, "My tande. Hulle is skeef en hulle het nie uitgekom nie", translated, "My teeth. They are skew and they never came out". The patient desired that the dental spaces be closed to improve her appearance. Medically, the patient was confirmed to be in good health.

The family history indicated that no other member had the condition and the patient therefore presented as an isolated case of hypodontia.

EXAMINATION

An extra-oral examination revealed a reduced occlusal-vertical dimension with a flattened nasolabial angle and a slightly protrusive chin point (Figure 1a, b and c).

Intra-orally, the patient had a deep bite while the soft-tissue examination showed healthy gingiva (Figure 2) with good oral hygiene control.

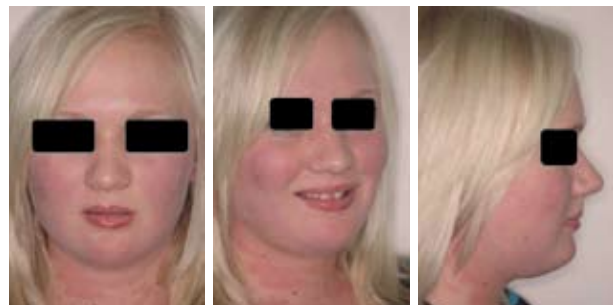

Figure 1a: Frontal view

Figure 1b: 45° view

Figure 1c: Lateral view

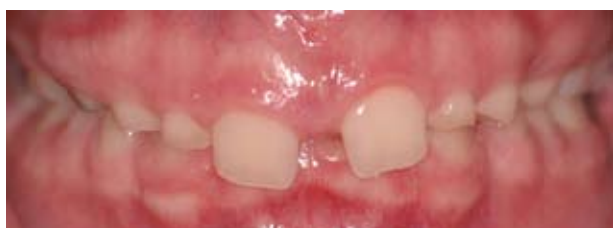

Figure 2: Pre-Orthodontic treatment: frontal

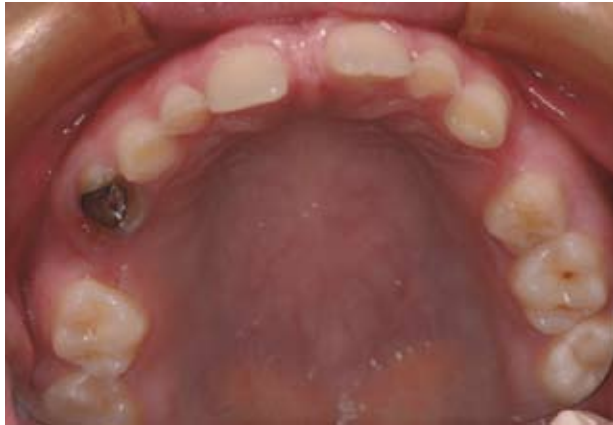

Figure 3: Pre-Orthodontic Treatment: Maxillary arch

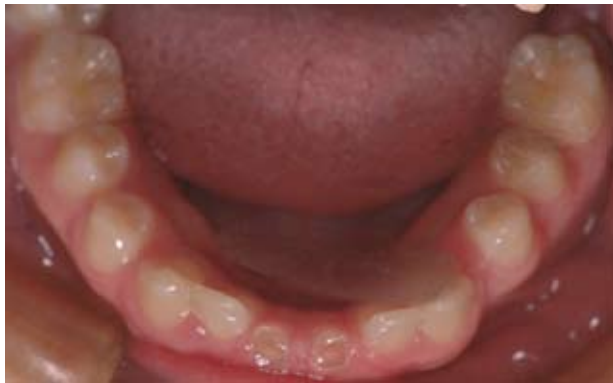

Figure 4: Pre-Orthodontic Treatment: Mandibular arch

The patient suffered severe oligodontia. In the maxillary arch the following teeth had failed to develop: Permanent third molars, permanent first and second premolars, permanent canines and permanent lateral incisors.

The following teeth were present: Permanent first and second molars, permanent central incisors, over-retained left deciduous second molar and root remnants of the right deciduous second molar, right deciduous first molar, deciduous canines and lateral incisors (Figure 3).

In the mandibular arch the following teeth had failed to develop: Permanent third molars and permanent central incisors.

The following teeth were present: Right permanent second molar, permanent first molars, permanent first and second premolars, permanent canines and lateral incisors and over-retained root rests of the deciduous central incisors (Figure 4).

The patient had a disto-occlusal amalgam restoration on the right maxillary first deciduous molar and the lower left second molar had been extracted. Discoloured fissures were visible on tooth 26.

The patient had a cusp-to-cusp molar relationship on the right and a Class II molar relationship on the left. The lower arch demonstrated a deep curve of Spee.

The genetics of tooth agenesis are diverse and vague, and in the endeavour to establish the cause of the missing teeth, the patient was referred to the geneticist, who confirmed there were no associated syndromes such as ectodermal dysplasia or Down's syndrome. Besides the oligodontia and slight scoliosis, no other associated defects could be found.



Cape Town
Cape Town International Convention Centre

Exciting, developmental, unifying
Scientific programme

Cutting edge, state of the art
Traders exhibition

Well-known local and international speakers:

KEYNOTE OPENING ADDRESS

Mr. Clem Sunter: "The World and South Africa beyond 2012: the latest scenarios, flags, probabilities and implications for healthcare".

INTERNATIONAL SPEAKERS

Dr. Mauro Fredeani • Dr. Cathy Jameson • Prof. Michael MacEntee • Dr. Carlo Tinti • Dr. Hugh Harvie • Prof. Fridus van der Weijden • Dr. Alasdair McKelvie
• Dr. Carlos Araújo • Prof. Daniel Wismeijer • Dr. Justin Kolnick • Mr. Jose Da Sousa • Mr. Dieter Grübel.

LOCAL SPEAKERS

Prof. Andre van Zyl • Dr. Howard Gluckman • Prof. Peet van der Vyver • Prof. Peter Owen • Dr. Lekan Ayo-Yusuf • Dr. Desi Moodley • Dr. Ottie van Zyl
• Mr. Athol Gordon • Prof. Jean Morkel • Dr. Nic van Rheede van Outshoorn • Dr. Sybrand van Rheede van Outshoorn • Dr. Andrew Ackermann • Dr. John Bronner.

FOR DETAILS ABOUT SPEAKERS AND TOPICS GO TO www.sada.co.za/E_SADA2012.asp

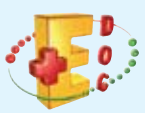Contact SADA for more Congress Enquiries:

Tel: 011 484 5288

Fax: 011 642 5718

E-mail: congress@sada.co.za

Website: www.sada.co.za/E_SADA2012.asp



SEE YOU THERE !

Table 1: Cephalometric analysis

Parameter	Normal value	Patient values	Diagnoses
ANB.	0 – 4°	5°	Mild skeletal Class II
Wits appraisal.	-1 – +1 mm.	2 mm.	Mild skeletal Class II
Mandibular plane angle.	32°	29°	Horizontal growth tendency
Maxillary incisor inclination.	22°	11°	Retroclined
Mandibular incisor inclination.	25°	25°	Normal
Growth direction.	66°	63°	Horizontal growth tendency

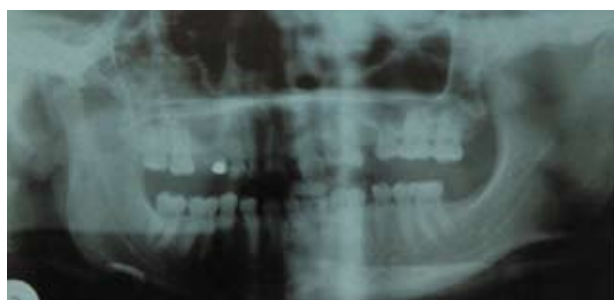

Figure 5: Panoramic radiograph

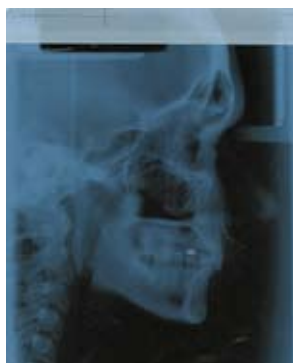

Figure 6a: Lateral Cephalogram radiograph.



Figure 6b: Analysis of lateral Cephalogram radiograph.

SPECIAL DIAGNOSTIC INVESTIGATIONS

Examination of the panoramic radiograph indicated several congenitally missing/absent teeth as follows: 18, 15, 14, 13, 12, 22, 23, 24, 25, 28, 38, 31, 41 and 48. Tooth 37 could have been mistaken to be congenitally missing but, as recorded above, the patient had provided the information that it had been extracted (Figure 5).

Cephalometric analysis indicated a mild Class II skeletal relationship with a horizontal growth tendency. The patient has a straight profile with a decreased lower anterior facial height. The maxillary incisors appeared retroclined and retrusive and the mandibular incisors were seen to be upright (Table 1, Figure 6).

TREATMENT PLAN

Due to the severity of the oligodontia, a multidisciplinary consultation meeting was arranged to plan the treatment, with the objective of achieving a functional, healthy and aesthetically acceptable result for this individual.

Consolidate the buccal segments, approximating molars, premolars and canines but leaving space in the 32/42 region for possible implant placement.

Periodontically, it was decided that in order to maintain the alveolar bone, the maxillary deciduous teeth should be

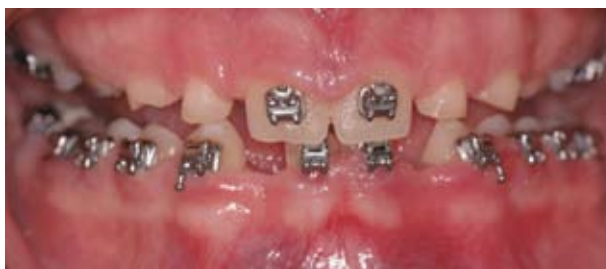

Figure 7: Post-Orthodontic treatment: frontal.

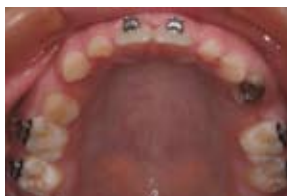

Figure 8: Post-Orthodontic treatment: Maxillary arch.

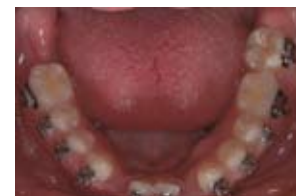

Figure 9: Post-Orthodontic treatment: Mandibular arch.

retained as far as possible. It was also decided that after the orthodontic treatment and prior to beginning prosthodontic treatment, the patient will be examined again in order to assess the sites for implant placement, and to discuss the need for possible gingivoplasty and crown lengthening.

Prosthodontically, it was decided that the patient requires full mouth rehabilitation with the placement of up to six implants in the maxillary arch and two in the mandibular arch with subsequent fixed prostheses for the replacement of the missing teeth.

Orthodontically the treatment plan was directed to accommodate and facilitate the intentions of the periodontic and restorative components and therefore entailed:

- In the maxillary arch, closure of the diastema between the 11 and 21, leaving 1–2mm of space for placement of the planned crowns.
- In the mandibular arch, extraction of the deciduous central incisors (7 1& 81), then reposition the mandibular permanent lateral incisors (32 & 42) into the central incisor sites, leaving 1–2mm of space to allow for crowns on these teeth.
- Consolidate the buccal segments, approximating molars, premolars and canines but leaving space in the 32/42 region for implant placement.

A pre-orthodontic diagnostic wax-up was done by the prosthodontic team to provide guidance as to where the natural teeth should be positioned orthodontically and to evaluate the possible outcome of treatment. (Figures 7, 8 and 9).

Fixed appliance orthodontic treatment was commenced, the spaces being consolidated with sliding mechanics. Levelling the curve of Spee in the mandibular arch resulted in an opening of the bite.

With the conclusion of 15 months of orthodontic treatment (Figures 10, 11 and 12) the patient has been referred to the Prosthodontic Department to receive the restorative phase of treatment. The orthodontic outcome is being retained in the interim with rectangular stainless steel arch wires and “figure eight” interlinking ligatures to prevent relapse. The dictates of the diagnostic set up have been satisfied orthodontically, providing a sound basis on which the restorative treatment can be delivered (Figures 10, 11 and 12).

CONCLUSION

This case highlights the typical features and challenges that may be encountered in a patient presenting with oligodontia. The number of absent teeth can vary considerably in these patients. Management options can be wide-ranging and com-

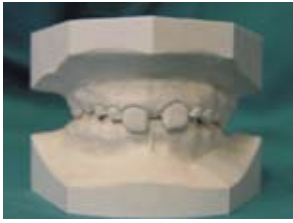

Figure 10a: Pre-treatment study cast: frontal in occlusion

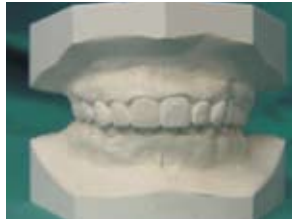

Figure 10b: Diagnostic set-up: frontal in occlusion.



Figure 11a: Pre-treatment study cast: Maxillary arch.

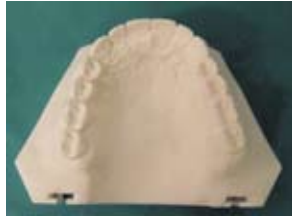

Figure 11b: Diagnostic set-up: Maxillary arch.



Figure 12a: Pre-treatment study cast: Mandibular arch.



Figure 12b: Diagnostic set-up: Mandibular arch.



plex for both the patient and the clinician. Whilst current treatment modalities can offer acceptable outcomes for patients with oligodontia, the need for input from a multidisciplinary team is essential to ensure the appropriate treatment and the correct timing of interventions to achieve maximum benefit. Whatever options are considered, careful planning is essential with collaboration between the restorative team, periodontist, orthodontist and the patient.

Individuals with congenitally missing teeth actively seek treatment to improve their appearance. Their motivation results in conspicuous compliance, a marked positive in these challenging cases.

Declaration: No conflict of interest declared.

References

1. Neville BW, Damm DD, Allen CM and Bouquet JE. eds Oral and Maxillofacial Pathology. Third edition. Saunders Elsevier, 2009.
2. Hobkirk JA, King PA, Goodman JR and Jones SP. Hypodontia: 2. The management of severe hypodontia. Dent Update 1995; 22(1):8 – 11.
3. Harris EF and Clark LL. Hypodontia: An epidemiologic study of American black and white people. Am J Orthod Dentofacial Orthop 2008; 134(6): 761 –7.
4. Gahan MJ, Lewis BR, Moore DH and Hodge TM. The orthodontic-restorative interface: 1. Patient assessment. Dent Update 2010; 37(2): 74 –6, 78 – 80.
5. Bishop K, Addy L and Knox J. Modern restorative management of patients with congenitally missing teeth: 1. Introduction, terminology and epidemiology. Dent Update 2006; 33(9): 531 –4, 537.
6. Addy L, Bishop K and Knox J. Modern restorative management of patients with congenitally missing teeth: 2. Orthodontic and restorative considerations. Dent Update 2006; 33(10): 592 –5.
7. Thind BS, Stirrups DR, Larmour CJ and Mossey PA. Management of hypodontia: Orthodontic considerations (II). Quintessence Int 2005; 36(5): 345 –53.
8. Miller BJ and Taylor NG. Lateral thinking: The management of missing upper lateral incisors. Br Dent J 1995; 179(3): 99 – 106.
9. Bowden DEJ and Harrison JE. Missing anterior teeth: Treatment options and their orthodontic implications. Dent Update 1994; 21(10): 428 –34.
10. Rosa M and Zachrisson BU. Integrating esthetic dentistry and space closure in patients with missing maxillary lateral incisors. J Clin Orthod 2001; 35(4): 221 –34.
11. Proffit WR, Fields HW Jr. and Sarver DM. eds Contemporary Orthodontics. Fourth edition. Mosby Year Book, 2007.
12. Sundram F and Walmsley AD. The management of severe hypodontia in a young adult patient: A case report. Dent Update 2003; 30(6):326 –30.
13. Nohl F, Cole B, Hobson R, Jepson N, Meechan J and Wright M. The management of hypodontia: Present and future. Dent Update 2008; 35(2): 79 – 80, 82 –4 and 86 - 8.

University of Pretoria:  Department of Orthodontics  50th Anniversary

