

Characterization of mucus glycoproteins in the intestinal mucosa of the African elephant (*Loxodonta africana*) following lectin histochemistry

H.L. COETZEE, S.H. KOTZÉ and N. LOURENS

Department of Anatomy, Faculty of Medicine, University of Pretoria
P.O. Box 667, Pretoria, 0001 South Africa

ABSTRACT

COETZEE, H.L., KOTZÉ, S.H. & LOURENS, N. 1995. Characterization of mucus glycoproteins in the intestinal mucosa of the African elephant (*Loxodonta africana*) following lectin histochemistry. *Onderstepoort Journal of Veterinary Research*, 62:187–192

The glycoproteins of the small intestines, caecum and colon of three adult elephants and one recently weaned elephant calf were examined by means of lectin histochemistry. Tissue sections were histochemically stained with peroxidase-labelled concanavalin A (Con A), asparagus-pea (TPA), peanut (PNA) and wheat-germ (WGA) lectins. Con A and TPA showed no binding activity in the intestinal tract of the adult elephants or the duodenum and ileum of the elephant calf, but did show a small amount of binding activity in the caecum and colon of the calf. WGA bound very intensely throughout the intestinal tracts of the adults and of the calf—especially with the goblet cells located in the crypts of Lieberkuhn and the glands of Brunner—decreasing in intensity towards the luminal surface of the intestinal tract. PNA stained the glands of Brunner of the duodenum faintly and the goblet cells of the ileum moderately, with no staining of the caecum and faint staining of the colon. These results show the distribution of Con A-, WGA-, PNA- and TPA-binding sites, and the changes that take place in the type of glycoprotein secreted after a change in the diet of the animal.

Keywords: African elephant, glycoproteins, histochemistry, intestinal mucosa, lectin, *Loxodonta africana*, peroxidase-labelled lectins, staining

INTRODUCTION

The mucus that covers the intestinal mucosa of animals plays an important role in many of the gastrointestinal-tract functions, such as chemoreception, protection and lubrication, and acts as a substrate for certain enzymes and as a selective physical barrier between the plasma membrane and the environment of the gastrointestinal tract (Smith & Butler 1974; Filipe & Branfoot 1976; Neutra & Forstner 1987).

These mucins have been intensively studied biochemically and histochemically and have been demonstrated to possess distinctive chemical structures in diverse sites of highly specialized biological activity. This interassociation between the chemical structure and site implies a connection between the chemical nature of the glycoproteins and the function at the site of occurrence (Spicer & Schulte 1992).

Plant lectins have been successfully applied in the histochemical distribution and characterization of glycoproteins (Watanabe, Muramatsu, Shirane & Ugai 1981; Sato & Spicer 1982; Colony & Steely 1987; Fischer, Klein, Vierbuchen, Skutta, Uhlenbruck &

Fischer 1984; Jacobs & Huber 1985; Madrid, Ballesta, Castells, Marin & Pastor 1989; Ferri & Liquori 1992). Of the different available lectins, wheat-germ (WGA) agglutinin was shown to bind preferentially to N-acetylglucosamine and/or sialic-acid residues on glycoproteins (Allen, Neuberger & Sharon 1973; Nagata & Burger 1974), while the specificity of peanut (PNA) lectins to terminal galactose and N-acetylgalactosamine residues was determined by Lotan, Skutelsky, Danon & Sharon (1975). Concanavalin A (Con A) was found to have a selective binding to mannose, glucose and fructose (Goldstein & Hayes 1978) and *Tetragonolobus purpureas* (TPA) is strongly specific for chains containing α (1-2)-linked fucose residues on the terminal galactose (Debray, Decout, Strecker, Spik & Montreuil 1981).

Histochemically, lectins can be used to analyse modifications or changes in glycoprotein content (Spicer & Schulte 1992). Jacobs & Huber (1985), using lectin probes, reported that the mucus synthesized by jejunal and colonic mucosae is altered by dietary change, and Vahouny, Le, Ifrim, Satchithanandam & Cassidy (1985) found that dietary fibre increases the turnover of jejunal mucins. The aim of this study was to characterize the types of glycoproteins present in the adult and calf of the African elephant (*Loxodonta africana*) and to determine whether a difference could be demonstrated in the type of glycoprotein present in the small and large intestines of the herbivorous adult and calf during weaning.

MATERIALS AND METHODS

Specimens of the intestinal tract (duodenum, ileum, caecum and colon) of three adult African elephants and one recently weaned elephant calf were obtained during a culling expedition in the Kruger National Park. The specimens were fixed in Bouin's solution for 24 h, routinely processed, embedded in paraffin wax and sectioned. Sections were trypsinated [2% (w/v) trypsin and 2% (w/v) CaCl₂, pH 7.0] for 1 h at 37° C to expose hidden epitopes, and endogenous peroxidase was blocked by incubating the slides with 3% H₂O₂ in methanol for 10 min (Leathem & Atkins 1983). Sections were then incubated with diluted peroxidase-labelled lectins (0.05 mg/ml) for 1 h at room temperature. Between incubation steps the sections were washed for 30 min in 0.05 M Tris-buffered saline (pH 7.4). Staining was accomplished with diaminobenzidine solution (DAB) for 8 min (Vacca, Hewett & Woodson 1978).

The peroxidase-labelled lectins used are indicated in Table 1.

The controls implemented were the following:

- Labelled lectins were substituted with lectins pre-adsorbed to the appropriate haptenic sugar (nega-

tive control) or inappropriate sugar (positive control).

- Pre-incubation of lectins with haptenic sugars was carried out 1 h prior to incubation of sections at room temperature.
- Control slides were also incubated with DAB without H₂O₂, to assess endogenous peroxidase activity of the tissue.
- Sections of rat kidney containing distal convoluted tubules, were used as a positive-control tissue.

Stained preparations were photographed with an Olympus photomicroscope, and the Normaski system of differential interference contrast was used.

RESULTS

The results are presented in Table 2. The intensity of the reactions observed was subjectively assessed and graded as follows:

- +++ intense
- ++ moderate
- + faint
- no reaction

Con A lectin

Adult elephant

No staining of the intestinal tract occurred in any of the different regions used.

Calf elephant

No staining was observed in the duodenum and ileum, but goblet cells in the middle and base regions of the caecal crypts of Lieberkuhn (Fig. 1a) stained moderately, while faint staining occurred throughout the length of the colonic crypts (Fig. 1b).

WGA lectin

Adult elephant

In the duodenum the glands of Brunner as well as the goblet cells in the bases of the crypts of Lieberkuhn in the duodenum, ileum, caecum and colon showed intense staining (Fig. 1c). Some goblet cells located on the villi also showed staining, although less intensely.

Calf elephant

Intense staining of the glands of Brunner in the duodenum (Fig. 1d) and bases of the crypts of Lieberkuhn in the duodenum and ileum occurred, while in the caecum and colon, goblet cells (Fig. 1e) located in the base and middle regions of the crypts stained well.

TABLE 1 Peroxidase-labelled lectins (Sigma) used for the examination of glycoproteins in the intestinal tract of the African elephant

Lectin	Abbreviation	Specificity	Inhibiting sugar
<i>Canavalia ensiformis</i> <i>Tetragonolobus purpureas</i> <i>Triticum vulgare</i> <i>Arachis hypogaea</i>	Con A TPA WGA PNA	α -D-mannose, α -D-glucose α -L-fucose GlcNAc(β 1,4GlcNAc) ₁₋₂ > β GlcNAc>NeuAc Terminal Gal β 1,3GalNAc	D-mannose L-fucose N-acetyl-D-glucosamine D-galactose

PNA lectin

Adult elephant

The faint to moderate staining reaction observed in the duodenum was mainly in the Brunner's glands of the duodenum as well as in the goblet cells in the base to middle regions of the crypts of Lieberkuhn of the duodenum, ileum and colon (Fig. 1f).

Calf elephant

Faint staining occurred in the crypts of Lieberkuhn from the ileum through to the colon, except for the caecum (Fig. 1g), where more moderate staining was observed.

TPA lectin

Adult elephant

No staining whatsoever was observed in the intestinal tract.

Calf elephant

Only the caecum (Fig. 1h) showed moderate staining of the goblet cells throughout the crypts of Lieberkuhn with a faint staining reaction occurring in the colon. The duodenum and ileum showed no staining at all.

DISCUSSION

In this study the distribution of sugar residues in the herbivorous adult African elephant and a young, recently weaned, elephant calf was examined. WGA agglutinin was shown to bind preferentially to N-acetylglucosamine and/or sialic-acid residues on glycoproteins (Allen *et al.* 1973; Nagata & Burger 1974). The intense WGA binding throughout the small and large intestines of the adult African elephant demonstrated the presence of N-acetylglucosamine and/or sialic-acid residues. This is in agreement with results recorded previously by a number of researchers (Fischer *et al.* 1984; Madrid *et al.* 1989; Ferri & Li-quori 1992) who identified WGA lectin in goblet cells of both the small and large intestines of animals belonging to at least five different classes of vertebrates studied, i.e. sea bream, frog, tortoise, chicken, rat, hamster, monkey and human. These findings are al-

TABLE 2 The distribution of the different types of glycoproteins demonstrated by lectin histochemistry of the intestinal tract of the African elephant—adult and calf

African elephant	Con A ^a	WGA ^b	PNA ^c	TPA ^d
Adult				
Duodenum	—	+++ ^e	+ ^g	— ^h
Ileum	—	+++	++	—
Caecum	—	++ ^f	—	—
Colon	—	+++	-/+	—
Calf				
Duodenum	—	+++	—	—
Ileum	—	+	-/+	—
Caecum	++	+++	++	+
Colon	+	++	-/+	-/+

^a Con A (*Canavalia ensiformis*)

^b WGA (*Triticum vulgare*)

^c PNA (*Arachis hypogaea*)

^d TPA (*Tetragonolobus purpureas*)

^e +++ = Intense staining

^f ++ = Moderate staining

^g + = Faint staining

^h — = No staining

so in keeping with those obtained by previous histochemical staining of the small and large intestines of the African elephant (Kotzé & Coetzee 1994), when sulphomucins and sialomucins occurred in more or less equal amounts throughout the intestinal tract. The strong presence of especially sialomucins with their long, rod-like structure and high negative charge (Slayter & Codington 1973) would give excellent protection against the possible harmful effect of the protozoal and bacterial flora in the colon.

The specificity of PNA lectins to terminal galactose and N-acetylgalactosamine residues was determined by Lotan *et al.* (1975). The binding of the PNA lectin in the small intestines and colon of the adult, and in the ileum, caecum and colon of the calf elephants, shows the presence of terminal galactose and N-acetylgalactosamine residues. Watanabe *et al.* (1981) found that PNA-binding sites can be considered to be a marker of cell differentiation in a given system. Sato & Spicer (1982) also demonstrated selective binding of PNA to the intermediate lamellae, but not to the *cis* and *trans* faces of the Golgi-complex. Fischer *et al.* (1984) described the variations in lectin distribution between the different cells types of their

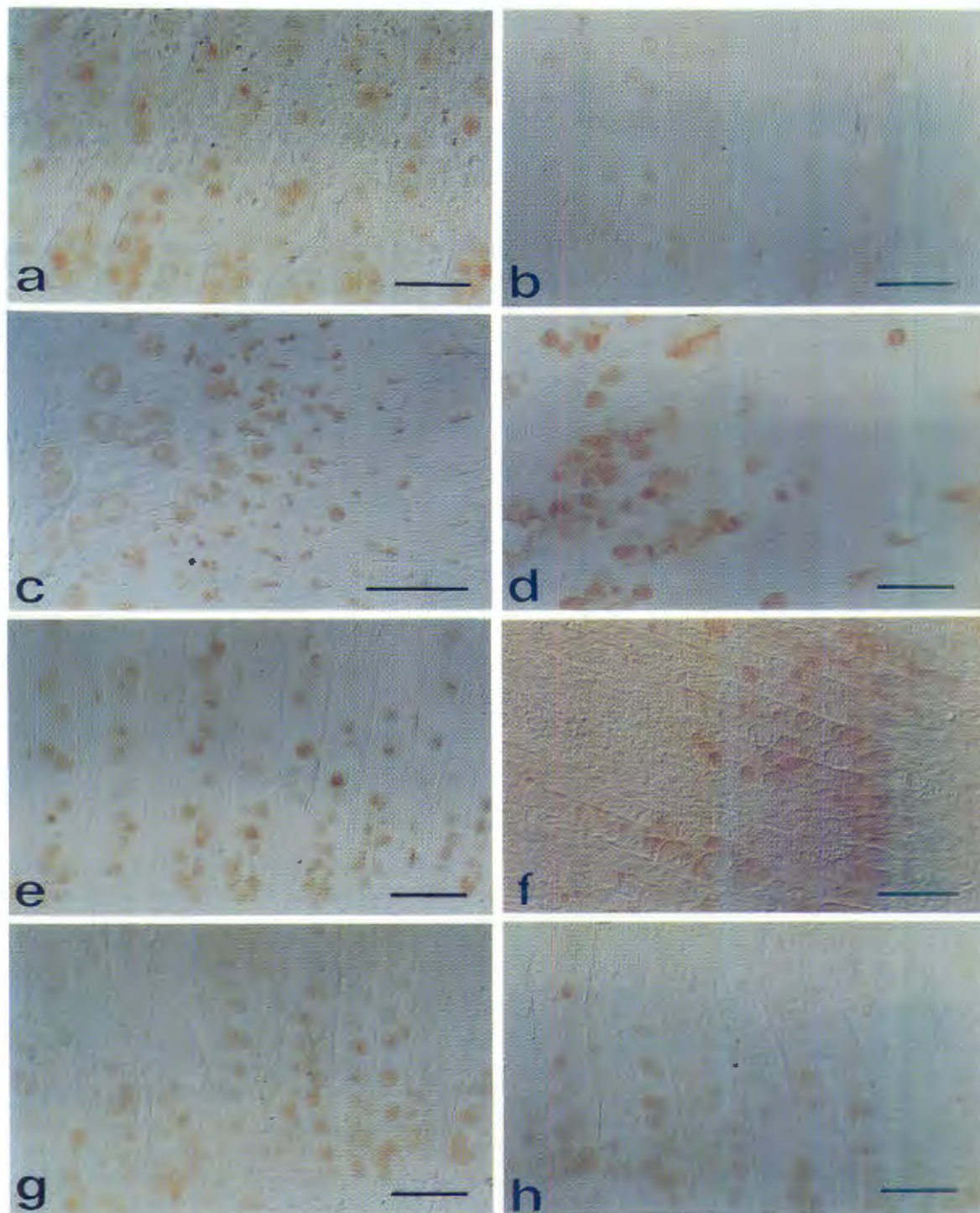


FIG. 1 Lectin histochemistry of the intestinal tract of the adult and calf African elephant
a. Moderate reaction with Con A of goblet cells of the calf caecal crypts of Lieberkuhn
b. Weak reaction with Con A of goblet cells of the calf colonic crypts
c. Intense reaction with WGA lectin of Brunner's glands and goblet cells of the adult intestinal crypts
d. Intense reaction with WGA lectin of goblet cells of the calf duodenum
e. Moderate reaction with WGA lectin of the calf colonic goblet cells
f. Moderate reaction with PNA lectin of the goblet cells of the adult ileum
g. Moderate reaction with PNA lectin of the calf caecal goblet cells
h. Weak reaction with TPA lectin of the caecal goblet cells of the calf
Scale bars = 100 μ m and 150 μ m

research to be indicative of a higher affinity of PNA lectins for the incomplete glycosylated glycoprotein components within the cells. Therefore, at the base of the crypt, immature cells produce incomplete glycoproteins and, as they mature with the elaboration of organelles, their glycosyltransferase activities change, to secrete a complete glycoprotein. The type of complete glycoprotein finally secreted depends on genetic, physiological and environmental factors (Filipe & Fenger 1979).

Goldstein & Hayes (1978) determined the specificity of Con A to be for mannose, glucose and fructose, while Hotta, Goso & Kato (1982) described the main reactive sites of Con A to be on the cytoplasmic membrane, where mannose residues were expected to have the terminal position. The absence of Con A binding in the intestinal tract of the adult elephant is in contrast to the findings of Fischer *et al.* (1984) in the human, and those of Madrid *et al.* (1989) in the hamster, chicken, Greek tortoise, lake frog and gilt-head sea bream. The young elephant calf, however, showed Con A binding to the goblet cells in the large bowel. The lack of affinity for Con A suggests the absence of mannose residues in the mucins involved in the small intestines, caecum and colon of the adult elephant. According to Goldstein & Hayes (1978), the structural organization of the carbohydrates and the position of the individual sugars in the oligosaccharide chains primarily influence their accessibility for interaction with lectins. An inconstant reaction or lack of Con A staining might be interpreted as that an addition of other sugars, such as N-acetyl glucosamine, galactose or sialic acid, leads to a "masking" of the mannosyl residues (Pavelka & Ellinger 1985).

TPA is strongly specific for chains containing $\alpha(1\rightarrow2)$ -linked fucose residues on the terminal galactose (Debray *et al.* 1981). The fact that TPA did not stain in the small intestines, caecum and colon of the adult animal, may be an indication of a lack of this type of binding site in the adult elephant. The elephant calf, however, did show the presence of such binding in the caecum and colon. This may be due to a change in function of the mucus of the colon. Colony & Steely (1987), evaluating the lectin-binding patterns in the developing-rat colon, found that in all cases the adult binding pattern was established by weaning and that the changes started late in the suckling period. The changes they found applied, amongst others, to a significant loss of fucose-labelled goblet cells, distally, in the colon and a restriction of labelled cells to the base of the crypts, proximally.

The difference between the binding patterns of Con A, WGA, PNA lectin and TPA in the colon of the calf, and the patterns of these lectins in that of the adult elephant, may be due to the change in diet. Moré, Fioramonti, Bénazet & Buéno (1987) showed that the nature of the mucin synthesized in the jejunum and

colon of pigs is altered by dietary changes, and Vahouny *et al.* (1985) reported that dietary fibre modifies the nature of the mucins secreted. The adult elephant, being a herbivorous hindgut fermenter with a high fibre intake, has a diet that differs from that of the calf which, until weaned, is on a low-fibre milk diet.

ACKNOWLEDGEMENTS

The authors would like to thank Dr G. van Aswegen and the National Parks Board for providing the specimens and Mr F.O. Waldeck for technical assistance.

REFERENCES

- ALLEN, A.K., NEUBERGER, A. & SHARON, N. 1973. The purification, composition and specificity of wheat-germ agglutinin. *Biochemical Journal*, 131:155–162.
- COLONY, P.C. & STEELY, J. 1987. Lectin binding patterns in developing rat colon. *Gastroenterology*, 92:1116–1126.
- DEBRAY, H., DECOUT, D., STRECKER, G., SPIK, G. & MONTREUIL, J. 1981. Specificity of twelve lectins towards oligosaccharides and glycopeptides related to N-glycosylproteins. *European Journal of Biochemistry*, 117:41–55.
- FERRI, D. & LIQUORI, G.E. 1992. Characterization of secretory cell glycoconjugates in the alimentary tract of the ruin lizard (*Podarcis sicula campestris* De Betta) by means of lectin histochemistry. *Acta Histochemica*, 93:341–349.
- FILIFE, M.I. & BRANFOOT, A.C. 1976. Mucin histochemistry of the colon. *Current Topics in Pathology*, 63:143–178.
- FILIFE, M.I. & FENGER, C. 1979. Histochemical characteristics of mucins in the small intestines. A comparative study of normal mucosa, benign epithelial tumours and carcinoma. *Histochemical Journal*, 11:277–287.
- FISCHER, J., KLEIN, P.J., VIERBUCHEN, M., SKUTTA, B., UHLENBRUCK, G. & FISCHER, R. 1984. Characterization of glycoconjugates of human gastrointestinal mucosa by lectins. I. Histochemical distribution of lectin binding sites in normal alimentary tract as well as in benign and malignant gastric neoplasms. *Journal of Histochemistry and Cytochemistry*, 32:681–689.
- GOLDSTEIN, I.J. & HAYES, C.E. 1978. The lectins: Carbohydrate-binding proteins of plants and animals. *Advances in Carbohydrate Chemistry and Biochemistry*, 35:127–340.
- HOTTA, K., GOSO, K. & KATO, Y. 1982. Human gastric glycoproteins corresponding to paradoxical concanavalin A staining. *Histochemistry*, 76:107–112.
- JACOBS, L.R. & HUBER, P.W. 1985. Regional distribution and alterations of lectin binding to colorectal mucin in mucosal biopsies from controls and subjects with inflammatory bowel disease. *Journal of Clinical Investigation*, 75:112–118.
- KOTZÉ, S.H. & COETZEE, H.L. 1994. A histochemical study of mucus glycoproteins or mucins in the intestinal tract of the African elephant (*Loxodonta africana*). *Onderstepoort Journal of Veterinary Research*, 61:177–181.
- LEATHEM, A.J.C. & ATKINS, N.J. 1983. Lectin binding to paraffin sections, in *Techniques in immunocytochemistry*, edited by G.R. Bullock & P. Petrusz. London: Academic Press, 2:39–70.
- LOTAN, R., SKUTELSKY, E., DANON, D. & SHARON, N. 1975. The purification, composition and specificity of the anti-T lectin

- from peanut (*Arachis hypogaea*). *Journal of Biological Chemistry*, 250:8518–8523.
- MADRID, J.F., BALLESTA, J., CASTELLS, M.T., MARIN, J.A. & PASTOR, L.M. 1989. Characterization of glycoconjugates in the intestinal mucosa of vertebrates by means of lectin histochemistry. *Acta histochemica et cytochemica*, 22:1–14.
- MORÉ, J., FIORAMONTI, J., BÉNAZET, F. & BUÉNO, L. 1987. Histochemical characterization of glycoproteins present in jejunal and colonic goblet cells of pigs on different diets. A biopsy study using chemical methods and peroxidase-labelled lectins. *Histochemistry*, 87:189–194.
- NAGATA, Y. & BURGER, M.M. 1974. Wheat germ agglutinin. Molecular characteristics and specificity for sugar binding. *Journal of Biological Chemistry*, 249:3116–3122.
- NEUTRA, M.R. & FORSTNER, J.F. 1987. Gastrointestinal mucus: Synthesis, secretion, and function, in *Physiology of the gastrointestinal tract*, edited by L.R. Johnson. New York: Raven Press: 975–1009.
- PAVELKA, M. & ELLINGER, A. 1985. Localization of binding sites for concanavalin A, *Ricinus communis* I and *Helix pomatia* lectin in the golgi apparatus of rat small intestine absorptive cells. *Journal of Histochemistry and Cytochemistry*, 33:905–914.
- SATO, A. & SPICER, S.S. 1982. Ultrastructural visualization of galactosyl residues in various alimentary epithelial cells with peanut lectin-horseradish peroxidase procedure. *Histochemistry*, 73:607–624.
- SLAYTER, H.S. & CODINGTON, J.F. 1973. Size and configuration of glycoprotein fragments cleaved from tumor cells by proteolysis. *Journal of Biological Chemistry*, 248:3405–3410.
- SMITH, B. & BUTLER, M. 1974. The autonomic control of colonic mucin secretion in the mouse. *British Journal of Experimental Pathology*, 55:615–621.
- SPICER, S.S. & SCHULTE, B.A. 1992. Diversity of cell glycoconjugates shown histochemically: A perspective. *Journal of Histochemistry and Cytochemistry*, 40:1–38.
- VACCA, L.L., HEWETT, D. & WOODSON, G. 1978. A comparison of methods using diaminobenzidine (DAB) to localize peroxidases in erythrocytes, neutrophils, and peroxidase-antiperoxidase complex. *Stain Technology*, 53:331–337.
- VAHOUNY, G.V., LE, T., IFRIM, I., SATCHITHANANDAM, S. & CASSIDY, M.M. 1985. Stimulation of intestinal cytochromes and mucin turnover in rats fed wheat bran or cellulose¹⁻³. *American Journal of Clinical Nutrition*, 41:895–900.
- WATANABE, M., MURAMATSU, T., SHIRANE, H. & UGAI, K. 1981. Discrete distribution of binding sites for *Dolichos biflorus* agglutinin (DBA) and for peanut agglutinin (PNA) in mouse organ tissues. *Journal of Histochemistry and Cytochemistry*, 29: 779–790.