

CHAPTER IV

DISCUSSION

4.1 Clinicopathological features of plasmablastic lymphoma

The current study represents the largest series of PBL affecting the oral cavity to date. The second largest series was published by Kane *et al.*, in 2009 and included 25 cases affecting mostly the gingiva⁷². The results of this study were in line with others who reported the gingiva and the palatal mucosa as the most common anatomical locations for PBL affecting the oral cavity^{8, 25}. The majority of patients in this series presented with a rapidly growing mass, some clinically reminiscent of Kaposi sarcoma, that affected mostly the gingiva, palatal mucosa, buccal sulcus and extraction sockets (Table 2). One patient presented with a swelling of the face due to diffuse infiltration of the facial soft tissues.

The mean patient age was 41 years (29-58 years) with a male predominance. This correlated with the results of previous studies which reported a median age of 39 years²². The high median age of 50 years reported by the 2008 WHO classification is difficult to explain but may reflect a lower percentage of HIV-positive compared to HIV-negative patients diagnosed with PBL in WHO source data. In my study the only known HIV-negative patient was 36 years old correlating with the median age found in the rest of the group.

The male to female ratio of 2.6:1 in this study was less than the 5.7:1 reported previously by some authors²⁴⁶. This discrepancy might be explained in part by the fact that females represent a larger proportion of the HIV population in South Africa than in other parts of the world. This is likely to be due to HIV transmission being heterosexual rather than homosexual in South Africa²⁴⁷. The number of females affected by HIV has either being stable or increased in certain parts of the world⁶. Due to the strong association of PBL with HIV infection in our South African sample, we concurred with others who proposed the diagnosis of PBL to suggest immunosuppression in an individual with otherwise unknown immune status²⁵. Recently a large study of 42 PBL's was

published by Valera and co-workers¹³. The 42 cases included only eight cases affecting the mucosa of the oral cavity. Twenty of their 35 patients (57%) with known HIV status and PBL in locations other than the oral cavity were HIV-positive but interestingly seven of the eight patients (88%) with oral PBL were immunosuppressed due to HIV-infection. PBL of the oral cavity therefore seem to have a stronger association with HIV-infection than those occurring in other anatomical locations. As a result of this we proposed that PBL should be included as a group 1 lesion in the EC-Clearinghouse and WHO Collaborating Centre on Oral Manifestations of the Immunodeficiency Virus classification of oral problems related to HIV infection²⁴⁸ as a specific entity. This is especially relevant to parts of the world with high incidences of HIV infection such as sub-Saharan Africa.

A limitation of my study was the shortage of clinical information with regard to the CD4 counts, HIV viral loads, extent of the disease beyond the oral cavity, the possible presence of other plasma cell dyscrasias or any further follow-up before or after treatment. Others have shown a strong association of PBL with advanced immunosuppression as reflected by low CD4+ counts and high viral loads^{21, 56, 93}. The correlation between the diagnosis of PBL, state of immunosuppression as measured by the CD4 counts of the patient and prognosis should be confirmed in large series of PBL such as the current one.

In general, the histomorphologic features of all cases included in this study were similar. The tumour infiltrates consisted mostly of monomorphic, large blastic cells with abundant cytoplasm and a cohesive, sheet-like growth pattern in an extra nodal and extra-medullary location (Fig.2 and Fig.3). In some cases tumour cells exhibited a more discohesive appearance (Fig.4), a feature that eventually made single cell FISH analysis easier, as will be discussed later. This phenomenon may be explained by the inherent character of the tumour cells, being a lymphoproliferative neoplasm, cells are not cohesive by nature or it may be artifactual in some instances with tissue shrinkage and artificial discohesion. An interesting finding not previously described in the literature was the pronounced cell pleomorphism noted in a percentage of the tumour cells of some cases with large nuclei, either slightly indented, binucleate or even multinucleated in some instances. These were

always intermingled with the more monomorphic plasmablasts of the tumour bulk (Fig.5). There was no specific correlation between the presence of cell pleomorphism and specific immunohistochemical or genetic features. Due to the fact that all cases except one were EBV positive, the association between pleomorphism and EBV status was difficult to exclude in this study.

All blastic tumour cells displayed eccentrically placed, slightly irregular round to oval nuclei with little chromatin. Nucleoli were always prominently visible in the cell nucleus. A mixture of tumour cells with a single, centrally located nucleolus and therefore immunoblastic appearance (Fig.2) and others with several peripherally located nucleoli (Fig.3) was always seen in all cases. Occasionally one or the other cell type predominated but this did not have any diagnostic implication in this study. These results suggest that PBL can be defined as having a mixture of blastic tumour cells with either a single prominent nucleolus or several smaller nucleoli distributed throughout the cell nucleus. The results of this study confirmed that these features did not warrant separate classifications.

The degree of plasmacytic differentiation within each case was evaluated and noted. Plasmacytic differentiation was defined as tumour cells exhibiting more mature plasma cell morphology. This was done to evaluate the theories of previous authors who classified PBL morphologically according to the amount of plasmacytic differentiation. These categories included '*PBL of the oral mucosa type*' where the tumour consisted mostly of blastic cells, '*PBL with plasmacytic differentiation*' where the tumour consisted of a higher percentage of mature plasma cells and '*PBL secondary to plasma cell neoplasms*' when the presence of another plasma cell neoplasia such as MM or plasmacytoma was confirmed^{13, 21, 43, 56}. The latter group poses diagnostic difficulty and imply a thorough clinical work-up to exclude MM or plasmacytoma before a diagnosis of PBL can be accepted. All 45 cases of PBL in this study showed the presence of mature plasma cells in the tumour cell infiltrate (Fig.7). It was impossible to differentiate reactive plasma cells from true plasmacytic differentiation unless the 'plasmacytic cells' showed features of neoplasia such as being much larger than reactive cells or exhibited at least some degree of atypia or pleomorphism. Atypia and pleomorphism might be absent

in plasma cell neoplasias such as MM and plasmablastic morphology might be present in aggressive forms of MM as well as various other lymphoproliferative entities. This poses a major diagnostic dilemma²⁴⁹. Whether PBL represents a group of plasma cell neoplasias with plasmablastic 'dedifferentiation' or whether one should rather consider them as plasmablastic neoplasms with some plasmacytic 'differentiation' should be considered. Maybe it would be possible to evaluate these plasmablastic and plasmacytic cells through single cell laser microdissection and subsequent comparative genetic analysis thereof in order to determine their relationship with one another. Until such time however, the conclusion of this study was that morphologic classifications based on the amount of plasmacytic differentiation currently has no diagnostic advantage. It would be interesting to determine whether the percentage of blastic cells versus plasmacytic cells has any prognostic implication for a patient with PBL and this should be further investigated.

A prominent feature of PBL was the presence of numerous tingible body macrophages with a prominent starry sky appearance on lower magnifications (Fig.6). This was ascribed to the high proliferation index of more than 75% confirmed in most cases using Ki-67 (MIB1) antibody. Two of the 45 cases (Case 17 and 24) initially only showed focal Ki-67 positivity (Fig.12). The stains were repeated in both cases but similar results were obtained the second time. The reason for this was uncertain but likely related to poor immunoreactivity due to the age of the stored FFPE specimen for case 24. This ten year old paraffin block also showed lower MUM-1 positivity compared to the other cases and negative or focal positivity with other stains. Case 17, a 3 year old paraffin block, showed strong and diffuse reactivity for CD138, MUM and κ light chain and general low immunoreactivity was therefore an unlikely explanation. Case 17 was the only EBV negative case in this series of PBL's. Whether this might aid in explaining the lower proliferation index in this case was uncertain.

Ki-67 on cases 17 and 24 was repeated a third time using a rabbit monoclonal antibody (RabMAbs) against Ki-67 antigen [clone SP6 (Spring Biosciences M3060, 6920 Koll Centre Parkway, Suite 211, Pleasanton, CA 94566)]. In

both cases intermediate positivity, defined in this study as positive staining in 20 to 70% of cells, was found. This might be explained by the superior nature of RabMAbs²⁵⁰. They are known to provide the combined benefits of superior antigen recognition of the rabbit immune system with the specificity and consistency of a monoclonal antibody^{251, 252}. Rabbit monoclonal antibodies also have more diverse epitope recognition and bind with greater affinity to their target antigen²⁵².

4.2 Immunoprofile of plasmablastic lymphomas

The diagnosis of PBL as an entity has been controversial. Many lymphoma entities display plasmablastic features which results in difficulty when trying to diagnose PBL's using morphologic criteria. However, PBL can be distinguished from most of these entities through immunohistochemical examination with pan B-cell markers such as CD19, CD20, CD22 and CD79a. Immunohistochemically all cases of PBL included in this study were negative for CD20 although reactive B-cells served as positive internal control in all cases (Fig.8). It was concluded that the absence of CD20 immunoreactivity should be regarded as one of the main diagnostic criteria for PBL.

It was previously shown that CD56, frequently expressed in plasma cell neoplasms^{249, 253}, might also be expressed in PBL⁹². CD56 is known to be negative in reactive plasmacytosis and monoclonal gammopathy of undetermined significance (MGUS), up-regulated substantially in MM and down-regulated again during evolution of MM to aggressive plasmablastic, anaplastic or extra-medullary forms of the disease²⁵⁴. CD56 negative MM is characterised by poor prognosis, plasmablastic morphology, lack of osteolysis and extra-medullary disease²⁴⁹ all features of PBL. Although the presence of CD56 positivity in PBL's with overt plasmacytic differentiation is postulated to be suggestive of MM with plasmablastic morphology²¹ it will not assist in distinguishing between PBL or MM with plasmablastic morphology and was therefore not performed in this study.

The CD79a molecule is present on the cell membrane of B-cells for longer than CD20 during B-cell to plasma cell development and maturation²⁵⁵ and

also during the terminal stages of plasma cells differentiation which is why this marker is frequently used to estimate the fraction of plasma cells in the bone marrow²⁵⁶. CD79a forms a complex with CD79b to enable B-cell antigen signal transduction²⁵⁷. During the plasma cell stages however, the CD79a molecule is found as an intracellular component and therefore visualised as a cytoplasmic stain. CD79a also plays a significant role in B-cell development, stabilisation and function²⁵⁸ and plasma cells without membranous or cytoplasmic CD79a expression are therefore seen as abnormal B-cells. Apart from one case that showed ontermediary positivity, focal CD79a staining was seen in the tumour cells of 27/45 (60%) cases but not more than 20% of the cells stained positive in any of the 27 cases (Fig.16). This was in agreement with the aberrant loss of CD79a expression reported in various other malignancies including MM²⁵⁶, ALK-positive large B-cell lymphoma⁹⁷ and HHV-8-positive PBL associated with Castleman's disease^{21, 98}. The molecular mechanism responsible for the loss of CD79a expression in neoplastic plasma cell infiltrates is unknown. Tanaka and co-workers indicated that, when CD79a is used in conjunction with other antibodies such as CD138 (usually positive in plasma cells) and cyclin D1 (often over expressed in MM), it may serve as a diagnostic tool in favour of plasma cells²⁵⁶. The low expression of CD79a in 60% and complete loss of this molecule in 38% of our cases of PBL were in line with what has been described for PBL in the literature^{13, 22, 71}. This was mainly ascribed to the aberration of neoplastic cells found in these neoplasms but does not seem to reflect any lineage specificity of the tumour cells. It was the conclusion of this study that CD79a did not play any role in the diagnostic panel of PBL.

CD3 positivity was reported in cases of PBL by one group⁷¹. None of our cases showed CD3 positivity in any cells other than reactive T-cells. It is interesting to note that aberrant T-cell expression has been reported in cases of PEL⁹⁹ and DLBCL associated with chronic inflammation⁹⁶, both morphologically and immunophenotypically similar to PBL. CD3 expression in this study varied from only a few cells (Fig.9) to dense infiltrates of reactive T-cells. The possibility that the number of reactive T-cells amongst the tumour cells could have represented the T-cell count of the patient should be considered. It was postulated that PBL in patients with higher T-cell counts

might have denser infiltrates of reactive T-cells which decreased as the CD4+ counts did, a hypothesis that should be tested in future studies.

MUM-1 plays an important role in the development of normal lymphoid cells²²⁰ and is primarily expressed in B-cells committed to plasmacytic or memory cell differentiation, plasma cells²⁵⁹ but also in activated T-cells²⁶⁰. This marker is not specific for either plasmablasts or plasma cells and is expressed in a wide variety of hematolymphoid neoplasms and even in malignant melanoma^{96, 97, 220}. The 2008 WHO classification does not include MUM-1 as useful immunohistochemical marker for PBL and also does not mention the degree of positivity that might be expected with this marker. All but one of the PBL cases in the current study showed MUM-1 positivity in more than 20% of the cells (Fig.13) with 87% showing strong and diffuse positivity. This was also reported by others¹³. There might be several reasons for this association of PBL with MUM-1 expression. Firstly, MUM-1 is a strong marker of plasma cells^{259, 261} and MUM-1 expression has been shown in 100% of MM cases^{259, 261} which further substantiate the plasma cell nature and possible biological relationship of PBL with other plasma cell dyscrasias. Secondly, a relationship between MUM expression and HIV-infection was demonstrated by Carbone and co-workers in 2001¹⁵. Based on the expression of MUM1, BCL6, and CD138 the authors separated HIV-related lymphoproliferative neoplasms into three groups: (a) the BCL6+ /MUM1- /CD138- pattern, seen in certain cases of AIDS-associated DLBCL; (b) the BCL6- /MUM1+ /CD138- pattern, associated with a fraction of AIDS-immunoblastic lymphoma; and (c) the BCL6- /MUM1+ /CD138+ pattern, associated with systemic and primary central nervous system immunoblastic lymphoma, PEL, PBL of the oral cavity (7 of 7), and HIV-associated Hodgkin's lymphoma¹⁵. BCL6 expression was not evaluated in this study. The true relationship between MUM-1 expression and HIV infection should be investigated in future studies. A third explanation for the high MUM-1 expression in our cases of PBL might be related to the presence of EBV which was found in all but one (case 43) of our cases. The expression of EBV-encoded latent membrane protein-1 (LMP-1) has previously been shown to be associated with the BCL6-/MUM1+/CD138+ expression pattern¹⁵. Increased MUM-1 expression was also proven to be associated with EBV-related transformation of human B-cells in *in vitro*

studies. Xu and co-workers demonstrated that EBV-related LMP-1 stimulates MUM-1 expression in B lymphocytes and suggested that MUM-1 may be a critical factor in EBV transformation and therefore a useful target in the therapy of EBV-mediated neoplasia²⁶². This could not be confirmed by others²²⁰. The single EBV negative case (case 17) in this study displayed diffuse MUM-1 positivity and the results of our study did also not support the proposed hypothesis of Xu and co-workers that EBV might play some role in MUM-1 expression.

Syndecan-1/CD138 is a transmembrane proteoglycan seen in the late stages of B-cell maturation and this marker is generally accepted as a hallmark of mature plasma cells^{263, 264}. Apart from its use in haematopoietic neoplasms, it should be noted that CD138 antibody also stains other forms of mature tissue such as stratified squamous epithelium, which served as a positive internal control in all PBL cases in the current study (Fig.22). Only 9/45 cases (20%) of PBL's showed diffuse positive staining for this marker (Fig.20) although 38/45 (84%) of cases showed some degree of positivity in some of the tumour cells.

CD38 (cyclic ADP ribose hydrolase) is a multifunctional ectoenzyme essential for cell adhesion and signalling as well as the regulation of intracellular calcium²⁶⁵. For the purpose of this study, CD38 served as another marker of post-germinal B-cell development usually strongly expressed in both normal and myelomatous plasma cells²⁶⁶. CD38 proved positive in only 29/45 (65%) of PBL's in this study. Only 7/45 (16%) showed diffuse positivity with this marker (Fig.18).

The exact time of CD138 and CD38 expression during B-cell development into plasmablasts and into plasma cells is still uncertain. Recently Caraux and co-workers reported that circulating plasma cells can be subdivided in CD138⁺CD20⁻CD38⁺⁺ and CD138⁻CD20⁻CD38⁺⁺ cells using flow cytometry²⁶³. I interpreted negative staining for either or both of these markers in two ways. Either the plasmablasts were in an earlier stage of development and have not yet gained the CD38 and/ or CD138 receptors on their cell surfaces²⁶³ or alternatively, it might have been due to some form of cellular dedifferentiation

with loss of the normal plasma cell markers. This should be clarified by future genetic and flow-cytometric studies.

There is currently no clarity on the precise antigen expression profile of neoplastic cells in PBL or the interpretation of immunohistochemical markers for post-germinal B-cell development in these neoplasms. It was clear from this study that the expression of MUM-1, CD38 and/or CD138 or the lack thereof played a very small role in confirmation or exclusion of the diagnosis of PBL, unless interpreted in conjunction with the expression of other cell antigens. In other words CD20 negativity in conjunction with a positive CD38 and/ or CD138 might for instance be helpful to confirm the diagnosis of PBL. However this combination may also be encountered in other plasma cell neoplasias such as MM and plasmacytomas, other HIV-related lymphomas such as PEL⁹⁹ and the rare ALK-positive DLBCL⁹⁷.

An interesting finding in this study was the two cases (Cases 4 and 30) which stained negative for CD79a, CD38 and CD138 although both cases showed diffuse and strong positivity for MUM-1. It would be very interesting to see if the ratios of CD79a, CD38, CD138 and MUM1 positivity might be reflective of a certain stage of maturity in the tumour cells of PBL and therefore have any prognostic implications.

CD45, initially characterised as a leukocyte common antigen, can be found on all hematopoietic cells except platelets and red blood cells²⁶⁷. CD45 is a key regulator of antigen-mediated signalling and activation in B- and T-lymphocytes²⁶⁸. CD45 expression is seen in plasma cells in the early stages of development but then disappears during normal maturation of plasma cells²⁶⁹. The ratio of CD45 positive versus CD45 negative plasma cells in the normal bone marrow seems to be stable but changes in the course of plasma cell disease such as MM. MM was recently classified according to its CD45 expression with the evidence that loss of CD45 expression indicates disease progression with a more immature cell morphology and a less favourable prognosis^{266, 269}. In line with many reports in the literature, 44/45 (98%) of the PBL cases in this study showed some degree of CD45 positivity in at least some of the tumour cells. Seventeen of 45 cases (38%) showed diffuse CD45

staining in more than 70% of the tumour cells (Fig.15). But, due to the exceptionally high numbers of reactive T-cells in some cases, the percentage of CD45 positivity was often difficult to interpret. Other PBL studies in the literature reported CD45 positivity to be minimal or absent in all their cases^{43, 270}. Although a quantitative analysis was not done by all authors, our CD45 positivity seemed to be one of the highest ever reported. Although I tried to evaluate only tumour cells, reactive lymphoid cells might appear bigger than normal with false positive interpretation of the CD45 stain in at least some cells. The laboratory techniques and antibodies used may also have played a role in the variety of results published by various authors. Even so, CD45 immunoreactivity in PBL did not play any diagnostic role in PBL's. Instead CD45 positivity might be indicative of a plasma cell neoplasm with immature morphology (plasma cells in early stages of development) in line with the low CD38 and CD138 positivity observed in many cases in this study. CD45 negative cases could also be reflective of neoplastic plasma cells that have lost their normal CD45 expression.

No PBL case in this study stained positive for the ALK protein which excluded the rare ALK-positive DLBCL, also known as ALK-positive plasmablastic B-cell lymphoma in the WHO classification⁹⁷. These rare lymphomas show remarkable similarities to PBL. They have been described in less than 50 cases of adult males with a median age of 36 years involving the lymph nodes as well as extra-nodal sites such as the nasopharynx²⁷¹. The median survival is less than 11 months and the tumour cells have the exact immunophenotypic and cytomorphologic features as described for PBL's, with the exception of the ALK-positivity (Fig.23). PBL involving the oral cavity in HIV-positive patients are listed as a very specific differential diagnosis. Genetically, these neoplasms are most frequently associated with the t(2;17) translocation responsible for the Clathrin-ALK fusion protein. Future studies might have to be done on ALK-positive DLBCL's in order to determine if they do not possibly represent a subtype of PBL.

Immunohistochemical analysis for κ and λ light chains was performed in all cases of PBL in this study. Light-chain restriction is used as a diagnostic feature of B-cell lymphomas. Although many authors have previously

reported evaluation of monoclonality in PBL's by analysis of immunoglobulin light chains through immunohistochemistry, none described how they actually did this. Kappa: lambda ratios accepted as 'normal' on flow cytometric examinations varies substantially²⁷². To simplify interpretation of the results of the immunohistochemical evaluation used in my study, I did not use ratios to determine the presence or absence of light chain restriction. Only cases completely negative for one of the light chains but positive for the other was accepted and subsequently noted as having light chain restriction. Twenty one of 45 cases (49%) showed clear light chain restriction in the current study, a percentage that would in all probability be higher should I have used ratios (Table 3). Seventeen of the 21 cases (81%) showed κ light chain restriction (Fig.24) and four of these 21 (19%) cases showed λ light chain restriction. The role of light chain restriction in the context of PBL is uncertain at this stage. Although light chain restriction is one of the diagnostic features of MM and was also confirmed as a valuable aid in the diagnostic armamentarium of plasmacytomas^{273, 274}, the lack thereof is seen in approximately 10% of extra-medullary plasmacytomas and 15% of MM¹⁰⁹. This lack of light chain restriction has tentatively been explained by acquired mutations of the *Ig* genes resulting in dedifferentiation of the tumours cells to the extent that they no longer secrete Ig²⁷⁵. The determination of κ and λ light chain restriction by immunohistochemical methods proved to be very difficult with high background staining in many cases. This was recently explained to be due to non-specific adsorption of the antibodies by collagen, resulting in high background staining and difficulty when interpreting the immunohistochemical results²⁵⁶. The presence or absence of light chains in the cell cytoplasm with or without restriction played no significant role in the diagnosis of PBL. There were no correlations between light chain restriction and any other morphological or immunophenotypic features of these neoplasms. The exact incidence of light chain restriction in PBL's should be determined with better methods such as flow cytometry and the implications with regards to prognosis or classification of these neoplasms should be investigated further.

The results of the immunohistochemical investigations of PBL's in this study supported PBL's to either represent a unique form of B- or plasma cell malignancy or an aggressive variant of an existing plasma cell neoplasia such

as MM or plasmacytoma. Neither of these hypotheses has yet been demonstrated. None of the immunohistochemical markers played a major role in the diagnosis of PBL. The combination of immunoblastic or plasmablastic morphology, loss of CD20 expression and simultaneous expression of one or more plasma cell markers such as CD138, CD38 and/ or MUM-1 may be indicative of a diagnosis of PBL. This is further supported by a relevant clinical history such as an aggressive oral tumour in an HIV/AIDS patient without any history of other plasma cell diseases such as MM or plasmacytoma. This study therefore supports the WHO decision to remove PBL as a variant of DLBCL as it was previously classified and to reclassify it as a separate entity²². The classification of PBL might change again as soon as its true biological nature is unravelled through genetic studies.

4.3 Viral status of plasmablastic lymphomas

HHV-8, a gamma herpes virus is the oncogenic virus associated with Kaposi's sarcoma and certain lymphoproliferative diseases such as PEL⁹⁹ and large B-cell lymphoma arising in HHV-8-associated multicentric Castleman's disease⁹⁸. Its presence is necessary for confirmation of these diagnoses. Africa is the continent with the highest prevalence of HHV-8 which increases with the presence of HIV-1 infection²⁷⁶. The genome of HHV-8 harbours an analog of the *Il-6* gene which is responsible for B-cell and plasma cell proliferation and may sometimes result in a lymphoproliferative disorder¹³⁹.

The methods used for HHV-8 detection as well as the use of strict positive and negative internal controls are very important when considering the results obtained by any study. When the role of HHV-8 in the pathogenesis of a tumour is in question, detection techniques where cell morphology remains intact are preferred. This ensures confirmation of the intracellular presence of the virus in the tumour cells examined. The HHV-8 virus may be harboured in B-lymphocytes of immunocompromised patients and signals detected on PCR may be from a source different to the tumour cells, therefore a false positive result caused by the presence of 'bystander' virus contamination²⁷⁷. Due to the high HHV-8 and HIV-1 infection rates in Africa²⁷⁸, PCR is not a good choice as detection method. Techniques for HHV-8 detection that fit the

prerequisite of intact cell morphology include immunohistochemistry and *in situ* hybridisation. The latter has been confirmed as a more sensitive method for detection of HHV-8²⁷⁹ and was therefore the detection method of choice in the current study.

The recommended guidelines from the manufacturer in the protocol of the HHV-8 virus probe and Novocastra detection kit were not followed in this study. Following their guidelines resulted in false positive results in the brain section utilised as negative control (Fig.42). The protocol was adjusted to rectify this, supported by internal control evaluations. Although digestion with Proteinase K according to the procedural notes of the manufacturer was sufficient for the probe to hybridise HHV-8, it was found that a combination of HIER in citric acid buffer (pH6) and pepsin digestion gave superior results. The latter method was in the protocol. False positivity was however seen in the negative control section with both protocols of enzyme digestion. Various test runs were performed to rectify this. The following steps were adjusted: the digestion time of pepsin was decreased in increments as well as the incubation with the probe and enzyme substrate. The incubation time of the probe was increased and that of the enzyme substrate decreased. The dilution of the rabbit F(ab') anti FITC/AP and enzyme substrate was increased. The wash times in buffer were also increased and the use of a shaker included. The post hybridisation wash was increased from nine minutes up to 30 minutes. The temperature was increased from room temperature to 45°C. Only after adjusting the temperature of the post hybridisation wash, however did the positivity in the negative control section disappear. The stringency of the wash buffer in the protocol of the manufacturer [Tris-buffered saline (TBS), 50mM Tris-HCl, 150mM NaCl, pH 7.6 /0.1% Tween] was found insufficient to remove the false positivity in the negative control where after the post hybridisation wash was done using Dako stringent wash concentrate ([saline sodium citrate(SCC), 75mM sodium citrate, 750mM NaCl₂ pH7.6] (Dako Corporation, Carpinteria, CA 93013 USA) at a temperature of 55°C for 20 minutes. This resulted in strong positivity in the nuclei of the vascular endothelial cells in the control Kaposi Sarcoma section (Fig.26) whilst the cells in the negative brain control block did not stain (Fig.43).

Figure 42: *The micrograph shows an example of a false positive HHV-8 (arrows) in the brain section utilised as negative control for HHV-8 ISH (Original magnification: 400x).*

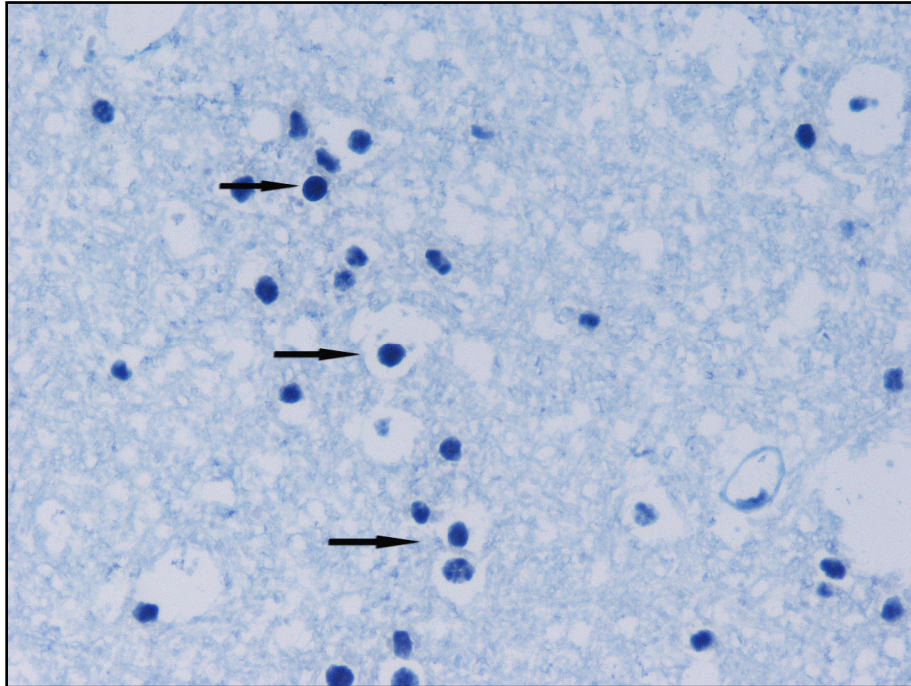
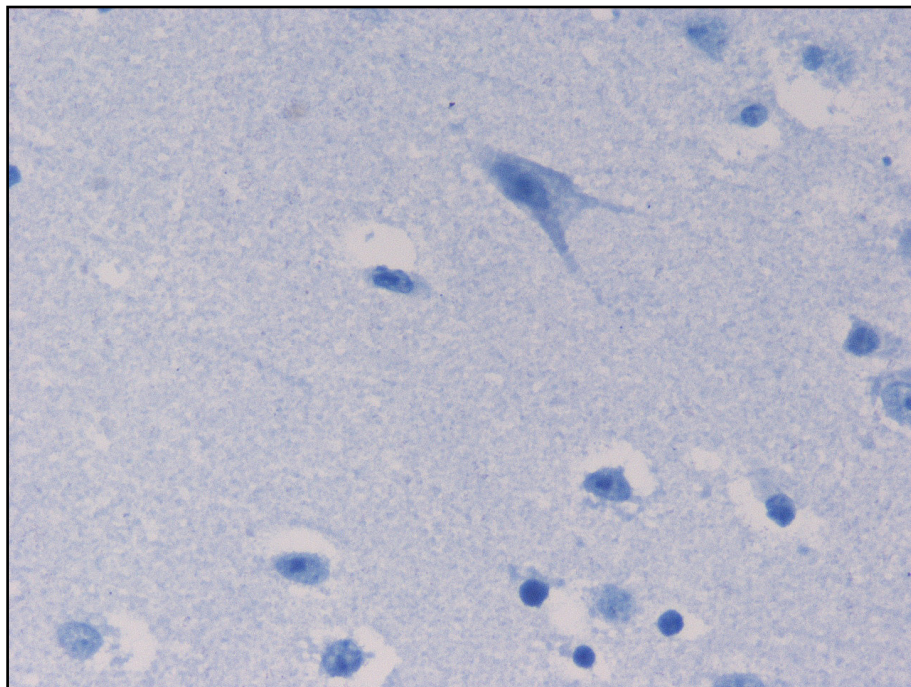


Figure 43: *The micrograph shows the absence of HHV-8 staining in all of the neural cells of this brain section utilised as negative control for HHV-8 ISH (Original magnification: 400x).*



Several authors reported the presence of HHV-8 in their PBL cases¹⁵⁻²⁰. The presence of HHV-8 is however currently widely accepted by most, including the WHO, not to form part of the diagnostic criteria for PBL^{21, 22}. ISH confirmed the absence of HHV-8 in all cases of PBL in this study. HHV-8 positivity is therefore proposed to be a contraindication for the diagnosis of PBL and should warrant a different diagnosis such as solid extracavitary PEL.

EBV is a lymphotropic gamma herpes virus implicated in the pathogenesis of various B-cell lymphoproliferative diseases including HIV/AIDS associated NHL such as DLBCL with immunoblastic morphology, primary central nervous system lymphoma and PEL and its solid variants^{2, 134}. Two main methods can be used to test for the presence of EBV. These include ISH with probes for EBER's, which represent the most widely used technique, and antibody staining for the LMP1⁸. EBER's 1 and 2 are small, non-coding RNA's expressed in all known forms of EBV latency, although their biological function is only speculative at this stage²⁸⁰. We used ISH with probes for EBER-1 and -2 for EBV detection in this study and strict positive and negative internal controls were included in the protocol to ensure optimal results.

The role of EBV in the pathogenesis of PBL is still unclear but it is reported to be associated with 60-100% of these neoplasms^{5, 11, 13, 14}. All but one (98%) case of PBL (case 17) in this South African-based series was EBV positive (Fig.27). As stated earlier, 31 of 32 patients in this study with known HIV-status was HIV-positive (Table 2). The only patient with a known HIV-negative status (case 17) was also EBV-negative. The reason for the high EBV positivity in this study is uncertain but speculated to be the results of the high incidence of HIV-infection.

EBV alone is insufficient to induce malignant change²⁸⁰ and its pathogenetic role in AIDS-related lymphomas, although speculative, has been linked to several mechanisms. LMP-1 is a transforming EBV protein that plays a crucial role in the transformation of B-lymphocytes into immortal B-cells²⁸¹. LMP-1 is frequently expressed in DLBCL and might play a pathogenetic role in these lymphomas²⁸². EBNA-1, a viral protein required for replication and maintenance of latency is found at a high frequency in BL²⁸⁰. EBNA-1 has

strong anti-apoptotic properties and therefore promote malignant proliferation²⁸⁰. A decrease of EBV EBNA1-specific memory CD4+ and CD8+ T-cell responses has been shown in HIV infection²⁸³. The decline in specific immunity in a deregulated and permissive immunological environment of HIV/AIDS as well as the EBV-driven cell proliferation potentially result in the accumulation of genetic alterations with malignant transformation of the lymphocytes as a consequence¹²³.

Apart from the proliferation induced genetic aberrations, latent EBV infection *per se* has been shown to promote genetic instability²⁸⁴. This further enhances the neoplastic drive of EBV infection. Cooperation between the EBV oncoviral proteins such as EBNA-2 and the host *MYC* gene was revealed as a pathogenetic event for lymphoma development^{285, 286}. EBNA-2, the key EBV transactivator protein critical for B-cell activation induces *MYC* expression²⁸⁷. The possibility that EBV may even protect lymphoma cells from the normally apoptotic effects of over expressed *MYC*, especially secondary to a *MYC* translocation such as the BL translocation t(8;14) has been postulated^{134, 280}. Further to this is the possibility that EBV may, through various mechanisms, even re-program B-cells into becoming neoplastic cells with an increased ability to survive oncogenic stress and genomic instability²⁸⁰.

It is not known which of the above pathogenic mechanisms of EBV-related lymphomagenesis is applicable to PBL and this should be investigated in the future. The plasmacytoid differentiation seen in EBV positive lymphomas, especially in the context of HIV infection in which case it is predominant or almost exclusive^{109, 134} does however emphasize the possibility of a role in the pathogenesis of PBL. EBV negative PBL's are occasionally reported in HIV-negative patients in the literature but this should be evaluated carefully. Firstly, the techniques used to demonstrate the presence of the virus should be evaluated. This could furthermore mean that PBL's may be subdivided into PBL associated with HIV/AIDS and PBL not associated with HIV/AIDS, therefore reflecting different pathogenic mechanisms. It may also imply that PBL's diagnosed in an HIV-positive patient may actually represent an atypical presentation of one the plasma cell dyscrasias or that PBL's diagnosed in an

immunocompetent patient actually represent a novel group of malignant lymphoproliferative neoplasms, yet to be defined more clearly. The diagnostic criteria for MM and plasmacytomas with plasmablastic morphology, especially in the setting of HIV/AIDS should be revisited since many neoplasms diagnosed as PBL have clinical features overlapping with the diagnostic criteria for MM.

4.4 Genetic features of plasmablastic lymphoma

Genetic features are an important component of the diagnostic algorithms of lymphomas in the 2008 WHO classification of lymphoid tumours⁹ and additional genetic data continue to inform on the pathogenesis of lymphomas. However, there is a significant shortage of genetic studies on PBL apart from single case reports and small series. Recently a large study of 42 PBL's by Valera et al., highlighted the important frequency of gene rearrangements in these neoplasms¹³. The 42 reported cases only included eight PBL affecting the mucosa of the oral cavity. This paper nevertheless confirmed previous reports suggesting an important role for *MYC* rearrangements in the pathogenesis of PBL especially with *IGH* as a partner^{11, 13, 24-28}. Valera and co-workers described frequent gains of *MYC*, *IGH* and other loci commonly involved in B-cell lymphoma further suggesting an association with complex karyotypes¹³. It was decided to evaluate all of our cases of PBL by FISH analysis for genes commonly described in lymphoma.

Advantages of FISH are that non-dividing (interphase) nuclei can be evaluated and FISH can be done on archived FFPE specimens^{243, 288}, allowing retrospective analysis of archival tissue. The technique can also be applied to small biopsies as FISH analysis can be performed effectively on as few as 40 cells²⁴³.

Recurrent translocations of the *IGH* gene (14q32) are found in approximately 50% of B-cell NHL and as such recognised as a hallmark^{167, 289}. There is a wide diversity of possible partners for the *IGH* gene in lymphomas. The incidence of *IGH* rearrangements in PBL was evaluated in 43 cases of PBL in this study using the *IGH* BA probe (14q32.3 LSI IGH) which is not dependent

on a specific translocation partner. *IGH* rearrangement were observed in 27/43 (63%) of PBL's in this series. The frequency of *IGH* rearrangement seen in our study was in line with what was expected in a B-cell NHL and other plasma cell neoplasia such as MM, known to have *IGH* rearrangements in more than half of non-hyperdiploid cases²⁹⁰.

Substantial evidence has accumulated recently supporting the idea that *MYC* rearrangements do not only characterise BL^{213, 291}, but also occur in approximately 10% of DLBCL²⁹² as well as in the new category of B-cell lymphoma, unclassifiable, with features intermediate between DLBCL and BL^{213, 291}, follicular lymphoma, mantle cell lymphoma, T-cell lymphoma and chronic lymphocytic leukaemia²⁹³. In 22 of the 27 cases (81%) of PBL with *IGH* rearrangement in this series, *MYC* was shown to be the partner of the translocation involving the *IGH* gene. This was seen using the *IGH/MYC* CEP8 tri-colour, dual fusion translocation probe, t(8;14)(q24;q32). Four cases negative for t(8;14) also showed rearrangement of the *MYC* locus on the *MYC* BA rearrangement probe (8q24 LSI *MYC*) with partners other than *IGH*. *MYC* was therefore rearranged in 26/42 (62%) of PBL's affecting the oral cavity in this study.

The incidence of *MYC* rearrangements in PBL has received some attention over the past four years. Reports on the median survival of patients with PBL vary from a few months to 3 years but this seems to be reduced substantially when *MYC* rearrangements, especially t(8;14) are present²⁴⁻²⁶. Recent, case reports on *MYC* rearrangements in PBL include single case reports from different study groups, only some of which were specified to be positive for t(8;14)²⁴⁻²⁷. In some of these reported cases, the patients had a CD4 count of less than 200 cells/mm³ with an associated median survival of three months, further demonstrating the association of poor survival in PBL cases with *MYC* rearrangements and HIV/AIDS disease. Recently, the largest genetic study on PBL of various anatomical sites was reported by Valera *et al.* *MYC* gene rearrangement was seen in 7 of 8 cases (88%) of PBL affecting the oral cavity but this genetic alteration was shown in only 13 of 33 (39%) of their cases affecting other anatomical locations. It was previously discussed in this document that PBL affecting the oral cavity mucosa seems to be more

common in the setting of HIV/AIDS than those of other anatomical sites. This present study reinforced the idea that *MYC*-rearrangements seem to be more common in PBL affecting the oral cavity than PBL affecting any other anatomical site.

The mechanism through which *MYC* aberrations in lymphomas other than BL cause clinical aggressiveness is uncertain. Smith and co-workers recently postulated that *MYC* may modulate a completely different set of target genes in BL than in non-BL²⁹³. The role of *MYC* in tumour cell growth and survival is a complex process as *MYC* regulates proliferation, apoptosis and cell differentiation in normal as well as in tumour cells²⁹⁴. Tumour cells, just like normal cells, respond to the microenvironment which includes cellular stressors such as hypoxia. *MYC* dysregulation, through a variety of mechanisms, provide tumour cells with enhanced growth abilities, even in a microenvironment of hypoxia and other extrinsic stressors. This is achieved by modulating several internal metabolic pathways and by promoting angiogenesis^{293, 295-297}.

The high incidence of *MYC* rearrangement in PBL affecting the oral cavity in HIV/AIDS patients may tentatively be explained. The cooperation of EBV oncoviral proteins such as EBNA-2 with the products of *MYC* gene aberrations could be the main pathogenic event for the development of PBL and should be investigated further^{285-287, 298}. One hypothesis is that EBV may protect the tumour cells from the apoptotic effects of *MYC* over expression driven by a translocation such as the t(8;14)^{134, 280}. In the large PBL series reported by Valera *et al.*, the incidence of *MYC* rearrangement were described as frequent among EBV-positive cases although no specific correlation was made between the anatomical sites, EBV-positive cases and *MYC* rearrangement¹³. Forty-four of 45 (98%) of PBL's of the oral cavity in our study were EBV positive on ISH. The only EBV negative case (case 17) was also the only patient known to be negative for HIV amongst the 32 patients with known HIV statuses in this study. *MYC* rearrangements were therefore seen only in EBV-positive tumours and might play a critical role in the initiation of PBL of the oral cavity, especially if one considers the role of the Waldeyer ring lymphoid tissue and posterior oro-pharyngeal and naso-pharyngeal

epithelial cells as possible EBV reservoirs^{299, 300}. This HIV and EBV negative case in the current series also showed no rearrangement of *MYC* or *IGH* but did however have an increased gene copy number of *CCND1*. This underlines the possibility that PBL outside of HIV-infection might have a different pathogenesis.

Another new and interesting finding from the results of this study was the increased *CCND1* gene copy number discovered in 17/41 (41%) and increased *IGH* gene copy numbers in 6/41 (15%) cases of PBL cases. More than six *CCND1* gene copies per cell nucleus were seen in seven of these cases and more than six *IGH* gene copies in four of them. While increased gene copy number previously described in PBL tend to be attributed to complex karyotypes¹¹, cases with multiple copies suggest true amplification of the *CCND1* and less frequently the *IGH* genes in some oral PBL's in our series. *CCND1* gene amplification has been described in aggressive B-cell NHL's³⁰¹ as well as MM in which case various mechanisms seems to be responsible for increased *CCND1* amplification and over-expression^{302, 303}. Cyclin D1 is a key cell cycle regulatory protein³⁰⁴ and its increased gene copy number might lead to over expression and contribute to the high proliferation index and aggressive clinical course of PBL.

MYC gene rearrangements in non-BL lymphomas are often associated with additional cytogenetic abnormalities which may further contribute to the aggressive behaviour of the disease and to the poor response to therapy seen in these patients^{13, 27}. Patients diagnosed with *MYC* rearranged DLBCL combined with deregulation of *BCL6* or *BCL2*, so-called double-hit lymphomas, have an even worse prognosis^{292, 293}. Karyotypic abnormalities in addition to *MYC* rearrangements are currently integrated into the 2008 WHO classification system. Seven PBL's cases in our series demonstrated rearrangement of both *IGH* alleles demonstrating a possible 'double hit' for the *IGH* locus (Figs 32 & 33). The *MYC* and *CCND1* genes were both translocation partners of *IGH* in one case, demonstrated by positive *IGH/CCND1* dual colour, dual fusion translocation probe, t(11:14)(q13q32) (Fig.37). Both *MYC* and *BCL2* genes were discovered to be partners of the *IGH* gene represented by positive t(8;14) and t(14:18) probes in one case

respectively. *MYC* was one of the *IGH* translocation partners in five cases with the other partner unidentified in three of these cases. In two additional cases both *IGH* chromosome partners remained uncharacterised. Double hits have been reported in several DLBCL and particularly in large B cell lymphoma with intermediate features between DLBCL and BL. To the best of our knowledge, the finding of rearrangement of both *IGH* alleles, although of low frequency (16%), was a new observation in PBL.

The findings of various genetic rearrangements in both simple and complex karyotypes may eventually all have an influence on the choice of treatment strategy for the patient diagnosed with PBL, especially those with *MYC* rearrangements^{293, 297}. Although we currently lack specific therapeutic approaches for patients with *MYC*-associated lymphomas, it has been proven that bortezomib down regulate *MYC*²⁹⁷. This might explain the recent publication by Bose and co-workers who reported dramatic and early response to bortezomib, a proteasome inhibitor widely used in treatment of MM, in a patient diagnose with PBL of the stomach¹². The authors hypothesised the efficacy of this treatment by suggesting PBL to be related more closely to plasma cell neoplasms than to B-cell lymphomas and therefore the poor performance on other oncotherapy regimes such as CHOP (cyclophosphamide, doxorubicin, vincristine and prednisone) and CHOP-like regimens.

Through the results of this study and others, it is recommended that routine genetic analysis for *MYC* rearrangements and others, especially to identify complex karyotypes, should be done and reported in order to identify these aggressive subtypes to the managing clinician^{25, 305, 306}. The spectrum of genetic analysis specific for PBL as well as the FISH probes used to determine the scope of genetic rearrangements should still be evaluated by future studies. Currently however, it is advised that a panel of FISH probes including t(8;14), *IGH* BA and investigations of *CCND1* be performed and if double hit rearrangement of both alleles is found on *IGH* BA, *BCL2* and *BCL6* should also be evaluated as possible translocation partners.

It may be important at this point to take note of a recent publication where the authors described *IGH/MYC* rearrangements in three cases of high-grade lymphoma, detectable on *IGH/MYC* dual-fusion FISH probes but which could not be detected using *MYC* BA FISH probes³⁰⁷. This highlighted certain limitations of using *MYC* BA probes as a stand-alone test. Explanations why some *MYC* rearrangements escape detection by *MYC* BA probe sets include the position of the breakpoints which varies and sometimes include areas that may leave the BA fusion signal intact³⁰⁷. The wide variation of *MYC* breakpoints are well described³⁰⁸, and breakpoints several hundreds of kilobases upstream of *MYC*³⁰⁹ or the extreme centromeric region³¹⁰ have been reported. Other explanations offered by May and co-workers is that an insertion, rather than a translocation, occurred which makes the translocation partner 'invisible' to the analyst. This may involve insertion of a small *IGH* sequence into the *MYC* gene, which may not be large enough to physically separate the two signals flanking the insertion breakpoints, or insertion of part or the entire *MYC* probe into the *IGH* locus with no disruption of the *MYC* probe. Consequently the presence of *MYC/IGH* may be overlooked³⁰⁷.

Cytogenetic studies are expensive and not always available. Less expensive and specialised techniques to identify these *MYC*-aberrations are therefore sought after. A novel monoclonal antibody recognizing the c-MYC protein in FFPE tissue by standard immunohistochemistry was recently described³¹¹. It has been shown that *MYC* expression was exclusively in the nucleus of 88% of BL cases and in both the cytoplasm and nucleus in the other 12% of BL. In cases of DLBCL without *MYC* translocation, the staining with this antibody was cytoplasmic. Nuclear or evenly distributed staining between the nucleus and the cytoplasm were described in 80% of DLBCL that harboured *MYC* rearrangements³¹¹. It is currently proposed that this monoclonal antibody may be used as a screening tool for a *MYC* rearrangements²⁹³, which would be useful in the light of the clinical implications. It would be interesting to test this antibody in PBL cases in a prospective clinico-pathological study.

BCL6 abnormalities are commonly described in DLBCL and are present in up to 30% of cases^{180, 312, 313}. We found no *BCL6* rearrangement in any of the 40 PBL cases screened for this abnormality. Gains in copy number seen as

increased fusion signals per cell nucleus (Fig.41) were however seen in 11/40 (28%) cases screened with the *BCL6* BA probe. Loss of one fusion signal was seen in three cases screened with the same probe.

As discussed throughout this document, it has previously been hypothesised by various groups that PBL may actually represent a plasmablastic form of MM or plasmacytoma¹¹. It was shown by this study as well as many others that there is no specific immunophenotypic or morphological feature to differentiate these diseases. Even clinical aspects seem to overlap to the extent that it makes differentiation between these neoplasms impossible. Genetic aberrations in MM include chromosomal gains and losses as well as specific chromosomal translocations affecting the *Ig* gene loci, most commonly *IGH* at 14q32.3^{225, 230}. Translocations which result in protooncogenes being misplaced into the *Ig* loci results in the powerful *IGH* enhancers to drive abnormal expression of translocated oncogenes including *cyclin D1*, on chromosome 11q13 leading to dysregulation of its expression²²⁷. Recurrent translocations are seen in approximately 40% of MM cases and include t(11;14)(q13;q32) encountered in 15-20% of MM patients^{228, 229}. *IgH* translocation and hyperdiploidy are unified by downstream up regulation of *cyclin D1*, *D2* or *D3*²³¹ which are eventually followed by further instability that often includes genetic alterations of chromosome 8 (*MYC*)²³³. Plasmablastic transformation in MM and other malignancies are frequently associated with *MYC* translocations and EBV-positivity¹¹. Several reports describe the presence of *MYC* translocations in MM to be associated with tumour progression to high-grade plasmablastic morphology and aggressive clinical behaviour^{215, 216, 290, 314}. Very little information on the genetic features of plasmacytomas is available in the literature in order to compare with genetic features of PBL. Bink *et al* recently did the largest study on cytogenetic alterations in 38 cases of extra-medullary plasmacytomas which showed *IGH* breaks in 37%, t(4;14) translocation in 16%, loss of 13q in 40% with chromosomal gains in 82%. No t(11;14) was present in any of their cases³¹⁵.

Only the high incidence of *IGH* rearrangements in this study are in line with what is seen in MM²²⁷. Whereas 15-20% of patients with MM exhibit the t(11;14)^{228, 229} only one of 41 (2%) of our cases evaluated was positive for this

translocation. The t(11;14) translocation juxtaposes the *CCND1* gene to the *IGH* locus and is, together with the over expression of *CCND1*, the genetic hallmark of mantle cell lymphomas, considered as the primary genetic event thereof³¹⁶. The role of the increased *CCND1* and *IGH* gene copy numbers in the pathogenesis of PBL's should be investigated. The true role of key genes in the pathogenesis and biology of PBL will be necessary before further comparison with MM and plasmacytomas with plasmablastic morphology will be possible. This should include evaluating rearrangements of chromosome 1, deletions of 13q and 17p together with possible gains in odd-numbered chromosomes in a large cohort of PBL cases.

The application of FISH to FFPE tissue sections are technique sensitive²⁸⁸. Storage conditions and the age of the tissue blocks have shown to influence the rate of successful FISH analysis on paraffin sections³¹⁷. Some of the archival blocks used in this study dated back to the 1990's which could have played a significant role in the loss of certain cases (see tables) for genetic analysis. Tissue fixed in neutral buffered formalin, a cross-linking fixative, is preferred for FISH on FFPE tissue³¹⁸. Fixation of the tissue prior to embedding it into paraffin blocks is known to play a major role in the quality of results obtained. In some PBL cases the overlying epithelial cells as well as those tumour cells present at the periphery of the sample were better exposed to formalin with better fixation and therefore presented with good morphology and sharp signals on FISH analysis. This was in contrast to tumour cells located towards the centre of especially the larger specimens and for which results were at times sub optimal. This was most probably due to suboptimal fixation in the central regions of a larger tissue sample.

Thickness of the histology section for FISH analysis played a major role in the interpretation of the results. Tissue section thickness should be determined by the type of tissue or cells to be analysed. The ratio of cell diameter versus thickness of the tissue section would either result in or prevent truncation artifact, one of the biggest problems encountered in the interpretation of FISH results^{241, 245}. In the same regard, overlay or directly adjacent nuclei was also problematic because two overlying cells might be regarded as a single cell and the signals present in these two cells be interpreted as signals from a

single cell. I discovered that the overlying mucosal epithelial cell nuclei of the lower third of the epithelial layer were a good indication of the diameter of the tumour cell nuclei in the PBL cases. The epithelial cells therefore served as internal control for all cases in our study. Due to the fact that all cases of PBL in this study affected the oral mucosa, some overlying epithelial cells were always present on every section. Initially we performed FISH on three micrometer sections. This resulted in truncation of tumour and epithelial cell nuclei and subsequent loss of signals in both the epithelium and the tumour cells. Increase of section thickness to four micrometer resulted in an increased number of signals in both cell types and 4 micrometer sections were therefore performed. To prevent misinterpretation of signals, analysis should strictly be performed on the correct thickness of section determined by the type of cells to be analysed. Analysis should also only be performed in areas where tumour cells are single or loose-lying from other tumour cells with no overlapping between nuclei. When dealing with a small cell neoplasm, thinner sections should be used as too much overlapping of nuclei will be present on thicker sections making interpretation of signal patterns impossible. In the case of larger cells, such as is the case with PBL, a thicker section will be needed as too much truncation artefact will result from thin sections.

Experience in histopathology and tissue morphology in FFPE tissue sections aided the author to distinguish between tumour cells of PBL, reactive T- and B-cells with normal morphology, epithelial cells as well as other bystanders such as fibroblasts. This might be a challenge to the inexperienced interpreter which may wrongly interpret normal bystander tissue as tumour and therefore skew the results when evaluating 100 or 200 nuclei for instance. In some slides, arcades of skewly cut covering epithelium intermingled extensively with the cohesive sheets of similar-sized tumour cells in the underlying lamina propria. Due to the non-discriminating nature of the DAPI stain, it was sometimes almost impossible to distinguish the epithelial cells from the tumour cells. Careful evaluation of the morphological features and intercellular bridging seen between most of the epithelial cells were important to ensure that the FISH analysis was performed on the tumour cells only.

Analysis was always done on tumour cells with well defined borders and cells with ghost-like features were excluded.

Optimal tissue fixation, a clear understanding of the principles of the technique and probe construction as well as thorough knowledge on the morphological features of the tumour cells dealt with in a specific assay is crucial in order identify artefacts, aiding in the successful interpretation of the results.

CHAPTER V

CONCLUSION AND FUTURE DIRECTIONS

This study represented the largest cohort of PBL affecting the oral mucosa published to date. The most important findings of this study were the genetic features, some of which confirmed the findings of others and some of which had never been described before. This study confirmed PBL to be a genetically complex, high-grade lymphoproliferative malignancy for which its current position in the 2008 WHO classification as a separate entity, rather than a subtype of DLBCL is supported.

Rearrangements of the *IGH* gene were found in 27/43 (63%) of cases screened with the *IGH*-BA probe set whilst *MYC*-rearrangements were discovered in 26/42 (62%) of PBL's. *MYC* rearrangements in this study consisted of the t(8;14) translocation which was present in 22/27 (81%) of PBL cases with *IGH* rearrangements but four other cases of PBL, negative for *IGH* BA, showed BA of the *MYC* gene with the *MYC*-BA probe set.

The presence of *MYC* rearrangements is currently accepted as an adverse prognostic factor in cases of DLBCL. *MYC*-rearrangements are more commonly associated with complex genetic karyotypes. In this study, seven of the 43 cases showed rearrangement of both alleles of the *IGH* gene, a finding never described before (Table 5). The *MYC* gene was shown to be one partner in five of these cases, all of which was t(8;14) positive, *CCND1* was one of the partners in one case shown to be t(11;14) and t(8;14) positive and *BCL2* was the one partner in one case shown to be t(14;18) and t(8;14) positive. These two lymphomas were therefore proven to be double hit lymphomas. Both partners of *IGH* remained unknown in two of the seven cases that showed rearrangement of both *IGH* alleles.

Increased *CCND1* gene copy numbers were found in 17/41 (41%) of cases screened with the *CCND1*/*MYC* dual fusion translocation probe. Seven cases showed more than six copies of *CCND1* per cell nucleus. Six of the cases (15%) screened with the same probe also showed increased copy numbers of

the *IGH* gene, four of which had more than six copies per cell nucleus. These findings, associated with the high incidence of *MYC*-rearrangements, with or without complex karyotypes might all play a significant role in the aggressive clinical behaviour and poor prognosis of patients diagnosed with PBL.

Valera and co-workers recently published a large genetic study on PBL's affecting various anatomical locations. Only eight cases of the oral mucosa were included in their study. Taking their study into consideration, it was interesting that *MYC* gene rearrangements were more common in PBL of the oral cavity than in PBL of different anatomical locations, especially for patients with HIV/AIDS. Fifty-eight percent of PBL in confirmed HIV-positive patients of my study had *MYC* rearrangements and all but one of the patients with known HIV-status in this study was positive for HIV-infection. The only patient known to be HIV-negative in our cohort of patients also showed no *IGH* or *MYC*-rearrangements in the tumour cells although a low level increase in *CCND1* copy number was obvious in the tumour cells of this case.

The exact role of *MYC*-rearrangement in lymphomagenesis is unclear. Factors responsible for the deregulation of *MYC* are numerous but in the case of PBL of the oral cavity the possible role of EBV infection should be considered. All but one of the tumours in the current study was positive for EBV. This was the same PBL case which showed no *IGH* or *MYC* rearrangements on FISH analysis. This supports the findings from other studies that EBV is more commonly associated with PBL of the oral cavity than those occurring in other anatomical locations, and again, more so in the setting of HIV/AIDS.

The association between EBV and HIV/AIDS might be explained by several reasons such as the reduced specific immunity against EBV oncoviral proteins in the setting of HIV/AIDS. The Waldeyer ring lymphoid tissue and oro- and nasopharyngeal epithelium, commonly infected by EBV in HIV/AIDS patients, should also be considered as an explanation for the frequent association between EBV and PBL of the oral mucosa. It is possible that these infected cells play a significant role in the homing of plasmablasts to the oral mucosa. This, in the background of reduced specific and general immunity, and in the

context of EBV associated neoplastic effects on infected B-cells or plasmablasts, might result in the preferred development of these neoplasms in the oral cavity mucosa.

EBV and *MYC* deregulation, either as a consequence of the EBV infection or as consecutive occurring are the most important pathogenetic factors for PBL affecting the oral cavity in HIV-positive individuals. The results from my study further concurred with previous proposals that the diagnosis of PBL should serve as a sign of immunodeficiency, either as diagnostic thereof or as a predictor of a progressive state of immunodeficiency in patients with known HIV/AIDS status. I suggested PBL to be included as a group 1 lesion in the EC Clearinghouse and WHO Collaborating Centre classification of oral problems related to HIV infection, especially in countries with high incidences of HIV such as South Africa.

The absence of *MYC*-rearrangement in some cases of oral PBL in HIV-positive patients warranted a different explanation. This can only be examined in future prospective studies with a wide panel of genetic probes. Through the results gained from the genetic evaluation of PBL cases in this study, I proposed the routine genetic evaluation of tumours diagnosed as PBL, as this may have prognostic and treatment implications in the future. Follow-up studies in order to confirm the clinical impact of the genetic evaluations have become mandatory.

Clinically, the gingiva and palatal mucosa was shown to be the preferred intra-oral location for PBL. Patients in our cohort, just as in most of the published cases, were around 40 years of age.

This study proved that PBL is not a histomorphologic or immunohistochemical diagnosis by any means. The current histomorphologic classifications of PBL according to the degree of plasmacytic differentiation do not have any diagnostic value although plasmacytic features may have prognostic significance and should be evaluated in future studies. Any lymphoproliferative neoplasm that exhibits plasmablastic features with various degrees of plasmacytic differentiation in an extra-medullary location should encourage histopathologists to do a panel of immunohistochemical and

genetic investigations, including viral studies for EBV and HHV-8. This study supported the WHO and other authors that accept HHV-8 to be negative in all cases of PBL. Should a neoplasm with morphological and immunohistochemical features of PBL be HHV-8 positive, a diagnosis of extracavitary PEL should rather be considered. The results of the immunophenotypic investigations performed in this study supported PBL to be negative for the CD20 receptor. Should an extra-medullary neoplasm of this nature be CD20 positive, another diagnosis such as the immunoblastic variant of DLBCL NOS should rather be considered. The role of plasma cell lineage markers such as CD38, CD138 and MUM as well as light chain restriction in the diagnosis of PBL is uncertain at this stage but proposed not to be diagnostic as stand-alone markers or criteria. The results of immunohistochemical investigations with these molecular markers should be interpreted in the context of extensive clinical, pathological and genetic investigations.

From the results of this study and intensive investigation of the literature, I proposed that PBL, as defined by the WHO, should be a single, extramedullary tumour that conforms to all the morphological and immunophenotypic criteria for the diagnosis of PBL as set by the 2008 WHO classification and described above. I proposed that the possibility should be investigated that some of these tumours might actually represent plasmablastic, extramedullary plasmacytomas with aggressive biological nature and poor prognosis. This was underlined by the high percentage of these tumours confirmed to have immunoglobulin light chain restriction. When multiple tumours or disseminated disease with similar criteria in association with multiple radiolytic bone lesions, bone marrow involvement by neoplastic plasmablasts or serological changes are found during the clinical work-up of such a patient, the diagnosis of atypical presentation of MM should rather be considered. The diagnostic criteria of plasma cell neoplasia such as MM should be re-evaluated and validated, especially in the setting of HIV/AIDS. It is well known that HIV/AIDS may influence the clinical presentation, immunophenotype and genetic features of plasma cell neoplasms, pathology commonly associated with immune deficiency.

It became clear that PBL should never be diagnosed without thorough clinical, systemic, pathological and genetic investigations especially in the backdrop of HIV/AIDS. No pathologist should make the diagnosis of PBL and no clinician should accept such a diagnosis or decide on the treatment modality for the patient involved unless all other possibilities of systemic plasma cell disease have been excluded. The role of genetic features in the diagnosis and management of PBL should be investigated further as it might eventually play an important role in the choice of treatment.

Key future research areas that evolved from this study

The true relationship between HIV/AIDS, EBV infection and PBL of the oral cavity should be considered in detailed molecular pathology, genetic and virology studies. It should be investigated if PBL's do not consist of two types of neoplasms, those associated with HIV/AIDS and those not associated with HIV-related immunosuppression, therefore reflecting different pathogenic mechanisms. Further to this, it should be determined if PBL in an HIV-positive patient does not represent an atypical presentation of another plasma cell dyscrasia for which the diagnostic criteria of MM and plasmacytomas in the setting of HIV/AIDS should be revisited.

The spectrum of genetic analysis specific for PBL as well as the FISH probes used to determine the scope of genetic rearrangements should be evaluated. The true role of key genes in the pathogenesis and biology of PBL will be necessary before further comparison with MM and plasmacytomas with plasmablastic morphology will be possible. This should include evaluating rearrangements of chromosome 1, deletions of 13q and 17p together with possible gains in odd-numbered chromosomes in a large cohort of PBL cases.

Future studies on large cohorts of PBL should evaluate the correlation between the diagnosis of PBL and the clinical state of immunosuppression as measured by the CD4 counts of the patient. From my current study it would also be interesting to see if any correlation exists between the degree of the T-cell infiltrate in the tumour and the CD4 count. The prognostic implications of the CD4 counts at the time of diagnosis should at the same time also be

evaluated through meticulous clinical follow-up of patients diagnosed with this neoplasm. Should there be a correlation between the CD4 count and the degree of T-cell infiltrates in the tumour and eventually between the CD4 count and the prognosis of such a patient, it could serve as a histological prognostic marker for these patients.

The possible prognostic implications of the following microscopic, immunohistochemical and genetic features in PBL should be investigated as part of the prospective clinico-pathologic study of PBL:

- Cellular pleomorphism in the tumour
- The percentage of blasts versus plasmacytic cells in the tumour infiltrate
- Positive versus negative staining for plasma cell markers such as CD38 and CD138
- The ratios of CD79a, CD38, CD138 and MUM1 positivity in the tumour cells
- The presence of specific genetic features such as aberrations of the *MYC*, *CCND1* and *IGH* genes as well as the influence of complex versus simple karyotypes

The biological nature of PBL as either plasma cell neoplasias with plasmablastic 'dedifferentiation' or as plasmablastic neoplasms with some plasmacytic 'differentiation' should be evaluated through molecular pathology techniques such as single cell laser microdissection and subsequent comparative genetic analysis of the cells in order to determine their relationship with one another.