

the male was introduced into the female's enclosure. In cases where a male was not available for introduction in the female he was random from a group of adult cheetahs. The mean age of this group was  $6,9 \pm 1,6$  years. Each of the animals was anaesthetized, and restrained for the 3 h period with CT1341. On day 1 of the trial Harry received the equivalent of 2,5 mg LH in the form of an intramuscular injection of HCG (APL, Ayerst Labs), m46 was given 5 mg, Gouws 10 mg and Boytjie 20 mg. At two weekly intervals thereafter animals were rotated each receiving a different dose of HCG so that at the completion of the experiment each had received at random the equivalent of 2,5 mg, 5 mg, 10 mg or 20 LH. Blood was collected prior to HCG injection, one hour later and thereafter at 30 min intervals until 300 min after HCG.

Conception rate (Ratio of number of pregnancies/total number of females available) of 32%.

The frequency distribution of cheetah births at the Centre during the period 1975 - 1980 is shown in Figure 2.

## RESULTS & DISCUSSION

### Management

Females came into oestrus soon after males were introduced into the passage between their enclosures for the second time. This became apparent when males congregated at a particular female's enclosure. The female was seen close by on the other side of the fence, chirping at the males, submissive and rolling. The males were excited, several developed an erection and short fights broke out amongst them. It was not uncommon to find two or three females in oestrus at the same time. When overt signs of oestrus were observed the animals were often seen to copulate soon after

the male was introduced into the female's enclosure. In cases where the male showed little interest in the female he was replaced by another animal after 30 min.

Indications of oestrus were less overt in some females. Subtle changes in the female's behaviour were noticed by Miss van Dyk who would then introduce a male cheetah into the particular enclosure.

Cheetah males kept in large groups were often aggressive and attacked females despite the fact that they were in oestrus. These animals were of no use for breeding purposes but were kept as part of the group outside the female's enclosure.

Seventy one litters were born during the study period with a mean conception rate ( Ratio of number of pregnancies/total number of females available) of 52%.

The frequency distribution of cheetah births at the Centre during the period 1975 - 1984 is summarized in Figure 2.

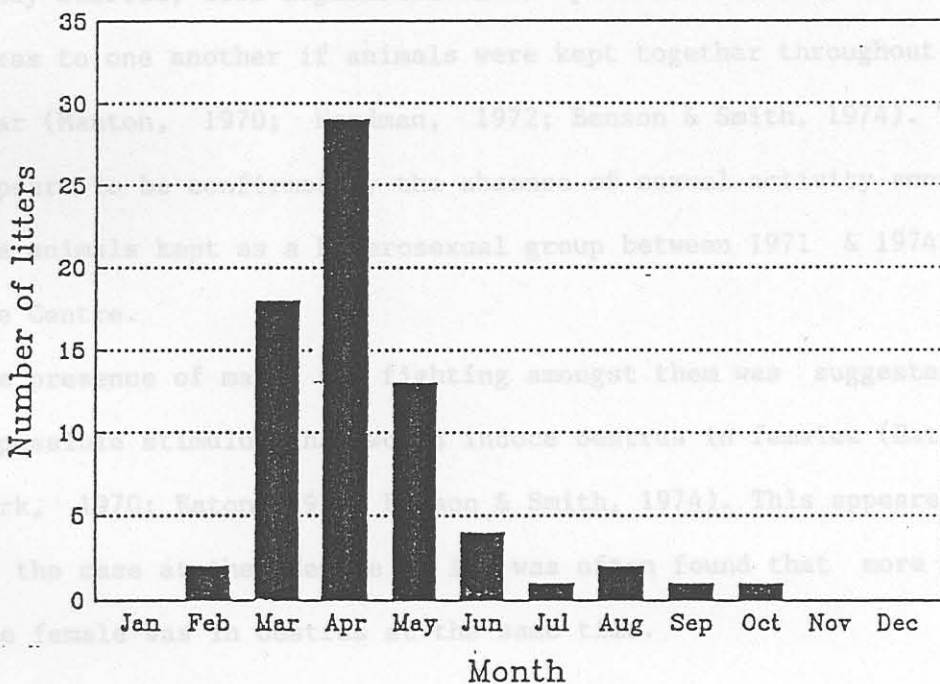


Figure 2 : Frequency distribution of cheetah births at the Centre during the period 1975 - 1984

### Immobilization

Males were allowed into the female area for the first time between November and December and left there until the end of March. *Animals required to enable capture.*

This apparent seasonal distribution is a consequence of the management approach adopted at the centre. Births were planned for the late summer, the end of the rainy season. This also fitted in with other activities during the year. No conclusion as to the possible seasonality of breeding in cheetahs is therefore possible from these results. Eaton (1974) suggested that cheetahs were seasonal breeders. This was contradicted by birth records reported by Wrogemann (1975) and Wildt, O'Brien, Howard, Caro, Roelke, Brown & Bush (1986).

The breeding strategy adopted at the Centre, when the present study started, took cognizance of the possible habituation of the sexes to one another if animals were kept together throughout the year (Manton, 1970; Herdman, 1972; Benson & Smith, 1974). This appears to be confirmed by the absence of sexual activity amongst the animals kept as a heterosexual group between 1971 & 1974, at the Centre.

The presence of males and fighting amongst them was suggested as a possible stimulus that would induce oestrus in females (Eaton & York, 1970; Eaton, 1974; Benson & Smith, 1974). This appeared to be the case at the Centre as it was often found that more than one female was in oestrus at the same time.

Immobilization

Table 2. Induction, recovery times and drug dosages in cheetah

The dosage rate of the drugs used was intentionally reduced to the minimum required to enable capture. presented as mean (n = 23)

After two out of the first three animals captured with ketamine hydrochloride, at a dosage rate of 8 mg/kg, developed epilepti-

form convulsions xylazine hydrochloride was added to the drug mixture darted.

The results of 23 immobilizations of male cheetahs performed at the beginning of the study using a mixture of ketamine and xylazine are recorded in Table 2.

kg	mg/kg	mg/kg	(min)	(min)
4,75	10,82	10,20	14,3	161,4

Induction time is the time between darting and safe handling of the animal. The first signs of drug action, head shaking, were seen 3-5 min after darting. Ataxia developed followed by posterior paralysis, then the animal lay down on its side. The head was held erect, the eyes were open in a fixed stare and mydriasis was present. Palpebral reflexes were absent.

Animals approached at this stage reacted violently to sound or touch and attempted to get away. They were however unable to right themselves and their sight appeared to be impaired. As the effects of the drugs progressed cheetahs lay down on their side with their heads on the ground and could be handled. Muscular

Table 2. Induction, recovery times and drug dosages in cheetah males captured with a drug combination of ketamine hydrochloride and xylazine hydrochloride. Data are presented as mean (n = 23) and standard deviation ( $\pm$ )

MASS kg	KETAMINE mg/kg	XYLAZINE mg/kg	INDUCTION TIME (min)	RECOVERY TIME (min)
48,9	6,45	0,64	12,3	128,8
$\pm 4,75$	$\pm 0,82$	$\pm 0,20$	$\pm 4,9$	$\pm 61,4$

Induction time is the time between darting and safe handling of the animal. The first signs of drug action, head shaking, were seen 3-5 min after darting. Ataxia developed followed by posterior paresis, then the animal lay down on its side. The head was held erect, the eyes were open in a fixed stare and mydriasis was present. Palpebral reflexes were absent.

Animals approached at this stage reacted violently to sound or touch and attempted to get away. They were however unable to right themselves and their sight appeared to be impaired. As the effects of the drugs progressed cheetahs lay down on their side with their heads on the ground and could be handled. Muscular

hypertonicity was present with sporadic myoclonic contractions which developed into typical epileptiform convulsions in some animals particularly when higher doses of ketamine were given.

During this stage of anaesthesia a number of the animals showed a characteristic posture. The upper fore paw was placed on the side of the nose and spasmodic movements were made in which the animals rubbed their eye and the side of the face.

As consciousness returned the symptoms described above were reversed in chronological order. Animals were kept isolated, during the recovery period, to avoid the excitement following reaction to sounds or touch that resulted in an ataxic animal falling heavily when trying to escape. Recovery time was recorded when cheetahs were able to walk without signs of ataxia or incoordination.

Higher doses of either ketamine hydrochloride or xylazine hydrochloride resulted in increased recovery time and had little practical effect on the induction period.

Failure to immobilize cheetahs effectively following darting was recorded in over 15% of cases. Dart misfires, blocked needles, subcutaneous injection of the drugs and darts that bounced off the animal before the complete drug volume had been delivered caused these failures. After initial dosage studies had been completed a standard dart containing 300 mg Ketamine and 20 mg xylazine was used. Endotracheal intubation was possible in most animals at this dosage level. Larger males were on occasion given halothane with a facial mask to enable intubation to be performed. Hyperthermia (temperatures  $> 41^{\circ}\text{C}$ ) was seen in animals

that were chased for some time prior to darting or that developed convulsions. These animals were cooled by douching with cold water.

Convulsions were seen in approximately 5% of the cheetah males immobilized.

#### CT1341 Anaesthesia

Induction with intravenous CT1341 took place within 5-15 sec. Anaesthesia using 2 mg/kg was characterized by a relaxed state in which the animal could be handled safely but nevertheless responded to electroejaculation with muscular contractions of the hind quarters and occasional cries. Recovery was uneventful with the animal gradually regaining consciousness, attempting to stand and eventually able to walk away. Spasmodic pawing of the side of the face was also seen in these animals at the beginning of the recovery period.

Mean recovery time (n = 27) was  $139,4 \pm 48,7$  min which does not differ significantly from that of cheetahs anaesthetized with the ketamine/xylazine mixture (t = -0,42).

Repeated administration of CT1341 required to keep the animal down for long periods during hormone studies resulted in a prolonged recovery time (6-18 h), which was nevertheless uneventful.

The safety of CT1341 was tested when a cheetah intended for euthanasia because of chronic nephritis (Blood urea 24,6 mmol/l, plasma creatinine 323  $\mu$ mol/l) was given 40 ml of the drug, 16 mg/kg.

A state of deep surgical anaesthesia followed and the animal was still alive 2 h later when it was killed with pentobarbitone sodium (Euthabarb, Centaur Labs, Johannesburg).

One cheetah immobilized with ketamine/ xylazine was given an intravenous injection of 3,5 ml of CT1341, approximately 1 mg/kg, in an attempt to control epileptiform convulsions that had developed. Apnoea followed immediately. Intubation and artificial respiration were successful in keeping the animal alive until spontaneous respiration returned but the animal died 30 min later as a result of hyperthermia. This was the only fatality recorded as a result of drug immobilization during the study.

Thiopentone sodium was used in a small number of animals. The drug is known to cause apnoea in cats (Felis catus) (Booth 1982) and was not used on a routine basis as a result. Recovery after a single injection of 400 mg (10 mg/kg) is rapid and one animal escaped after recovering abruptly. An intravenous injection of 100 mg thiopentone sodium proved useful in controlling epileptiform convulsions in animals immobilized with ketamine and xylazine.

Campbell & Harthoorn (1963) stated the requirements for an effective drug for the capture and control of large wild felids as potency, rapid induction, wide therapeutic index and lack of excitatory effects.

A safe and effective method of chemical restraint with a short recovery period was needed to collect semen by electroejaculation from cheetah males. The animals were confined in enclosures and could not move far after darting. It was possible therefore to



reduce the quantity of capture drug used. As the study progressed it became important to be able to handle a greater number of animals in the time available and later it was necessary to keep cheetah males restrained for periods of up to five hours for serial blood collections. These changing requirements together with the erection of smaller enclosures and the construction of capture crushes resulted in changes in the drugs used for restraining cheetahs. of drug required.

Phencyclidine hydrochloride has been used in combination with various neuroleptic drugs for the capture and anaesthesia of cheetahs (Griffiths, Haigh & Susan Harthorn 1968; Pienaar, le Riche & le Roux 1969; Ebedes 1970; Seal, Erickson & Mayo 1970; Holmes & Ngethe 1973; Smuts, Bryden, De Vos & Young 1973). There are disadvantages however that ruled out its use in these animals. Anaesthesia is prolonged (Griffiths et al. 1968; Ebedes 1970; Seal et al. 1970; Holmes & Ngethe 1973; Smuts et al. 1973). Severe epileptiform convulsions were described by Delfs (in Ebedes 1970), Ebedes (1970) and Seal et al. (1970) these were often complicated by hyperthermia (Ebedes 1970; Seal et al. 1970) and one animal died as a result of heat stroke (Seal et al. 1970). Smuts et al. (1973) compared the effects of phencyclidine and ketamine using these drugs, in combination with azaperone, in lions, leopards and cheetahs and concluded that ketamine had the following advantages over its more potent congener: muscular hypertonicity was less severe, no convulsions were seen and the recovery period was shorter. A temperature of 38,4 °C was recorded in an immobilized cheetah and it was

concluded that the drug combination used did not interfere with thermoregulation. Smuts et al. (1970) reported the death of a cheetah immobilized with phencyclidine from asphyxiation following regurgitation and aspiration. They suggested that ketamine would be a safer drug to use when animals had eaten as it did not suppress pharyngeal and laryngeal reflexes. The disadvantage in using ketamine as reported by Smuts et al. (1973) was the larger volume of drug required.

Both phencyclidine and ketamine disrupt central nervous system function by interfering with monoamine neurotransmission (Roberts 1968, in Booth 1982) as a result the thalamoneocortical system is depressed and the limbic system activated (Booth 1982). This produces a state characterized as dissociative anaesthesia by Corssen & Domino (1966, in Smuts et al. 1973). The catalepsy, muscular hypertonicity and epileptic seizures that result from these effects (Chen, Ensor, Russel & Bohner 1959) can be suppressed by the simultaneous administration of various neuroleptic drugs. Acetyl promazine was used by Young (1966) and Seager (1976), azaperone (Pienaar et al. 1969; Smuts et al. 1973) chlorpromazine (Campbell & Harthoorn 1963), diazepam (Reid & Frank, in Booth 1982), promazine (Chen et al. 1959; Seal et al. 1970), triflupromazine (Ebedes 1970) and xylazine (Amend, Klavano & Stone 1972; Sanford & Colby 1980; Clark, Martin & Short 1982; Bush, Custer, Smeller, Bush, Seal & Barton 1978; Watermann 1984).

Seager (1976) blamed acetyl promazine for his failure to collect semen from a cheetah by electroejaculation.

Smuts et al. (1973) reported using 10,6 mg/kg ketamine hydrochloride together with 20 mg azaperone in a cheetah. The same animal was immobilized later with 6,3 mg/kg ketamine on its own. Induction times did not differ appreciably on each of the two occasions but the animal recovered in less time when the lower dosage was used (90 min compared to 270 min). The drug was effective for the capture and handling of cheetahs at this dosage. Higher dosages are used in cats (F.catus): Commons (1970) 20-40 mg/kg; Amend et al. (1972) 11-22 mg/kg (after premedication with 0,25-2,0 mg/kg xylazine); Haskins, Peiffer & Stowe (1975) 35 mg/kg; De Young et al. (in Booth, 1982) 11-33 mg/kg.

The three cheetahs immobilized at the beginning of this study went through all the stages of induction as described by Smuts et al. (1973) confirming their description of the changes that occur. However the muscular hypertonicity together with epileptic convulsions that took place in two of the animals were regarded as unacceptable and the inclusion of a tranquilizer was indicated. Insufficient evidence was available to show whether the hyperthermia reported in cheetahs by Ebedes (1970) and Seal et al. (1970) resulted as a direct effect of phencyclidine itself or as a result of the convulsions, which were severe. Both authors used neuroleptics derived from phenothiazine, triflupromazine (Ebedes 1970) and promazine (Seal et al., 1970) which have been reported to cause hyperthermia in other animals (Booth 1982). Seager (1976) blamed acetyl promazine for his failure to collect semen from a cheetah by electroejaculation.

Xylazine hydrochloride was included in the drug mixture darted. It was reported to reduce muscular hypertonicity when used in combination with ketamine hydrochloride in (F. catus) (Amend et al. 1972; Haskins et al. 1975; Sanford & Colby 1980; Clark et al. 1982), it lowers the dose of ketamine hydrochloride and is miscible with it in the same syringe (Amend et al. 1972).

The dosage of ketamine hydrochloride used by Smuts et al. (1973) was used as a guideline in this study. The availability of fluothane anaesthesia made it possible to reduce the dosages of both drugs used and thus the recovery time. 6-8 mg/kg of ketamine hydrochloride together with 0,5-0,8 xylazine hydrochloride was sufficient for the purpose. Increasing the quantity of either of the two drugs lengthened the time taken for the animals to recover. The capture of cheetah males free in their enclosures was time consuming. Animals soon became aware of the routine and were often difficult to dart. Despite the conclusion by Smuts et al. (1973) that ketamine could be used with relative safety in animals that had eaten, aspiration pneumonia following ketamine anaesthesia has been reported in man (Sears, 1971, Penrose 1972, and Sussman 1974, in Haskins et al. 1975). It was therefore considered necessary to starve the cheetahs for 12 h prior to anaesthesia. Small holding enclosures were erected adjoining the male enclosures. Animals were coaxed or chased into these where they could be starved and were darted with ease. The capture of cheetah males in crushes attached to these enclosures made it possible to use intravenous anaesthesia.

Young (1966) used pentobarbitone sodium for anaesthesia in cheetahs but reported recovery periods in excess of 12 h. Thiopentone sodium has a shorter acting anaesthetic effect (Booth 1982) but has to a large extent been replaced by CT1341 for the anaesthesia of cats (F. catus). It is safer, does not cause perivenous tissue damage when injected subcutaneously and apnoea, commonly seen when thiopentone is used in cats, does not occur (Child, Currie, Davis, Dodds, Pearce & Twissell, 1971; Davis & Pearce 1972; Evans, Aspinall & Hendy 1972). CT1341 consists of two pregnanedione steroids: alphaxalone and alphadolone in solution in polyethylated castor oil (Child et al. 1971). The concentration of alphaxalone is 9 mg/ml and that of alphadolone 3 mg/ml in the product supplied. Alphadolone a 21-acetoxy derivative of alphaxalone:  $3\alpha$ -hydroxy- $5\alpha$ -pregnane-11,20-dione, has half the activity of alphaxalone but is included in the mixture as it increases the solubility of the latter in the vehicle used (Davis & Pearce, 1972). Dosages reported refer to the two drugs which together make up 12 mg/ml in the anaesthetic solution. An intravenous injection of 1,2 mg/kg CT1341 results in the immediate loss of consciousness in a cat (Child et al. 1971) The drug has no analgesic effect but anaesthesia results from a general depression of the central nervous system (Haskins et al. 1975; Booth 1982). Recovery is rapid. Animals given 1,2 mg/kg were able to right themselves after 6-9 min, after 19,2 mg/kg recovery took two hours (Child et al. 1971). Evans, Krahwinkel & Sawyer (1972, in Booth 1982) recommend 7,5-9 mg/kg for minor ation, and the eyelids were closed.

surgical procedures. Additional injections of CT1341 may be given as it does not have a cumulative effect (Child et al. 1971; Davis & Pearce 1972; Hall 1976).

CT1341 has a high therapeutic index calculated in mice to be 30,6 by Child et al. (1971) who report indices for thiopentone and ketamine of 6,9 and 8,5 respectively in mice. These indices were however not regarded by Davis & Pearce 1972 as applicable to larger animals. Dodds (1972 in Gordh, 1972) stated that five 'doubling doses' of the minimum anaesthetic dose of both CT1341 and ketamine were needed to cause fatalities in cats (F.catus).

CT1341 is compatible with neuroleptic drugs and gas anaesthetic agents. It should not however be used in conjunction with barbiturates (Tavernor 1977, in Booth 1982). The polyethylated castor oil vehicle causes histamine release in dogs (Canis familiaris) (Child et al. 1971, Stocks 1973) and the drug is not recommended for use in these animals. Child et al. (1972) and Haskins et al. (1975) describe sneezing, pawing at the face and ears and hyperaemia of the skin of the nose in some cats anaesthetized with CT1341. They ascribe these reactions to histamine release. Marshall (1972) and Edmonds (1973) reported finding atrial and coronary artery thrombi in two cats that died while anaesthetized with CT1341.

Haskins et al. (1975) reviewed the literature dealing with the use of ketamine, xylazine and CT1341 and compared the effects of these drugs in cats. They reported that CT1341 anaesthetized animals made a faster recovery, had better muscular relaxation, and the eyelids were closed.

Both methods of immobilization proved effective and safe in cheetahs. Anaesthesia was not produced at the dosage levels used but animals could be handled and electroejaculated. Recovery time was relatively short.

CT1341 was used in preference to the ketamine xylazine mixture. The induction period was shorter, immobilized animals were relaxed, the eyes were closed and less excitement was seen during recovery as reported by Haskins et al. (1975) in cats. The danger of eye injury was high in animals immobilized with ketamine and xylazine because of the loss of palpebral reflexes and the open mydriatic eyes could conceivably be injured by direct sunlight. It was not possible to protect the eyes effectively as the animals shook off any shielding that was applied during the recovery stage. The rapid induction, when CT1341 was administered, reduced the time taken to examine each animal and, as a result, it was possible to immobilize and electroejaculate a male cheetah within 15 minutes. In contrast induction after the intramuscular administration of ketamine and xylazine was prolonged.

Greater quantities of either of the two drug combinations produce anaesthesia in cheetahs. The inclusion of xylazine hydrochloride together with ketamine reduced muscular hypertonicity and the incidence of epileptiform convulsions but the recovery time was increased as a result of its inclusion in the drug mixture administered. Thiopentone sodium in small quantities is more effective for this purpose and does not have effects on the recovery period when used in this way. The results of this study

indicate that recovery following the use of CT1341 is longer in cheetahs than times recorded in cats ( Child et al. 1971; Davis & Pearce 1972). The repeated administration of small quantities of the drug needed to prolong immobilization during hormone studies resulted in a protracted recovery which was characterized by a state akin to a relaxed sleep. No deleterious side effects were seen using CT1341 in cheetahs. Pawing of the face described in cats by Child et al. (1972) and Haskins et al. (1975) was seen when either ketamine/xylazine or CT1341 was used. Hyperaemia of the skin as described by these authors did not occur. This response seen during the recovery stage in cheetahs appears to originate in the central nervous system and no evidence of a histamine release was present. No fatalities were recorded after an estimated > 750 immobilizations performed using CT1341 alone. This drug should not however be used together with ketamine hydrochloride.

#### Semen collection & evaluation

The voltage, current form and frequency delivered by the electroejaculator was measured galvanometrically during the electroejaculation of three cheetah males and is illustrated in Figure 3.



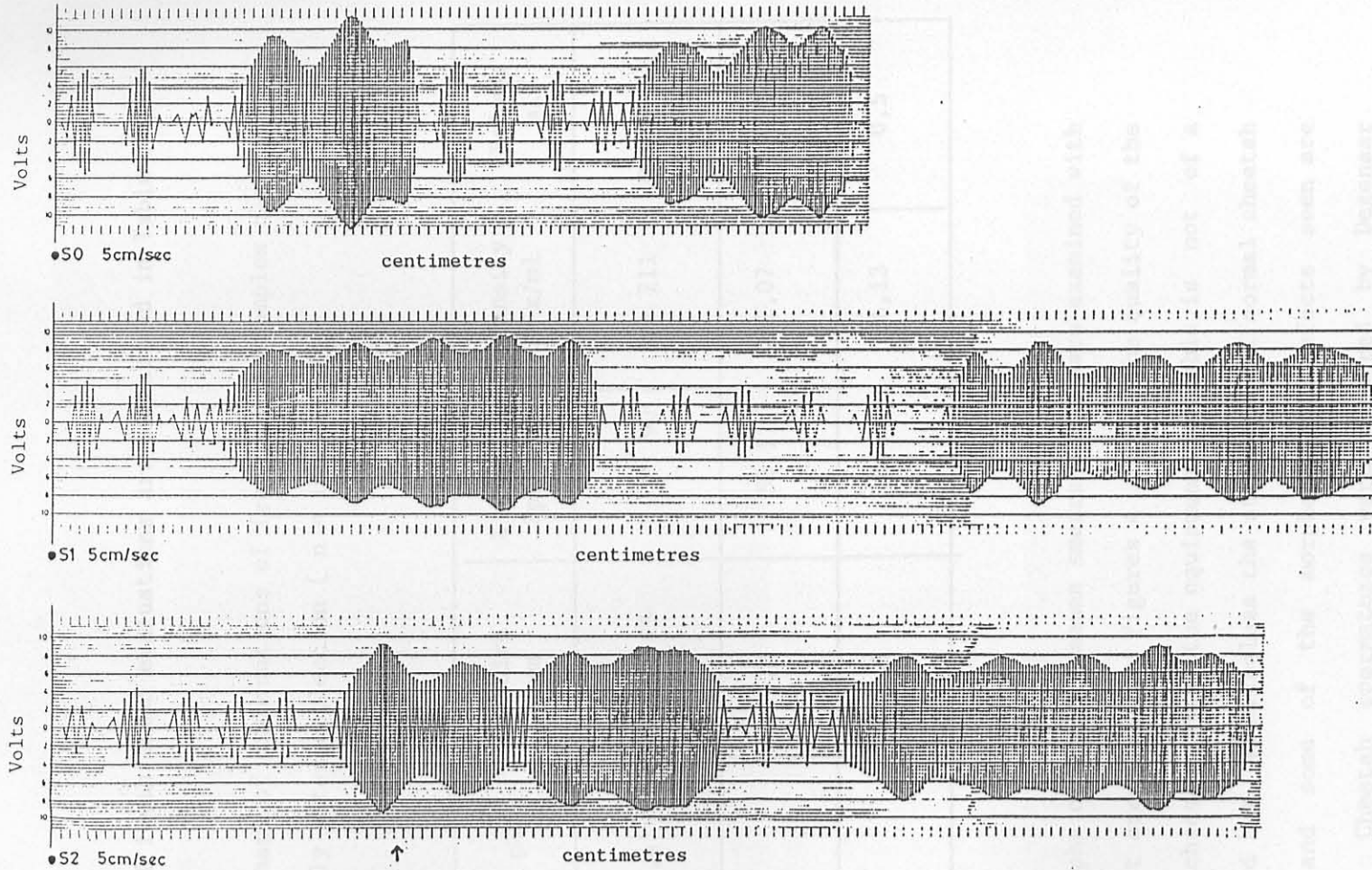


Figure 3: Ejaculatory stimulus.  
A series of three stimuli are shown (S0, S1 & S2). Ejaculation at (↑)

The current measured at the output electrodes of the dynamo was 1 - 1,5 amps. Current was not recorded during electroejaculation as it varied considerably within and between animals.

The results of fresh semen evaluations are summarized in Table 3.

Table 3: Summary of examinations of fresh semen samples carried out immediately after collection ( n = 160).

	pH	% Live Sperm	% Motile Sperm	Density $10^6$ x/ml	Volume ml
Range	6,4 - 8	10 - 95	8 - 90	1 - 211	0,3 - 2,1
Mean		65,2	58,1	32,07	0,7
Std		18,5	18,6	36,13	0,5

Photomicrographs of stained semen smears and smears examined with phase contrast are shown in Figures 4 to 9. The quality of the photographs achieved with the equipment available is not of a high standard but nevertheless the structure of normal cheetah spermatozoa and some of the morphological defects seen are demonstrated. Cheetah spermatozoa were measured by Degenaar (1977).

Figure 6. 'Bag' defects with an abnormal head (a) and a normal head (b).

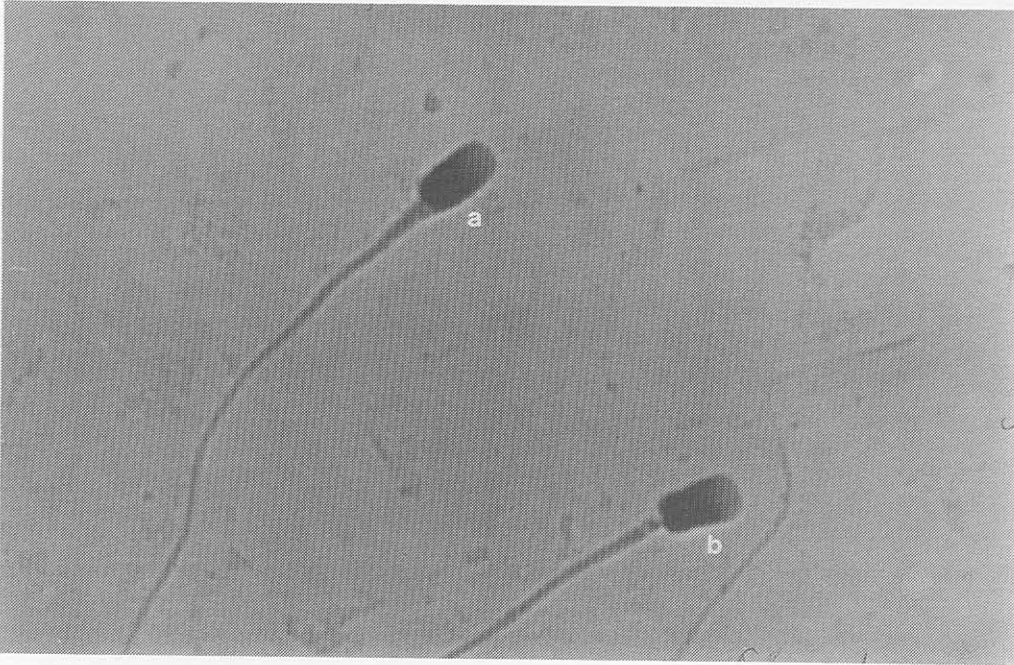


Figure 4. Normal spermatozoa (a); abnormal head and midpiece (B).

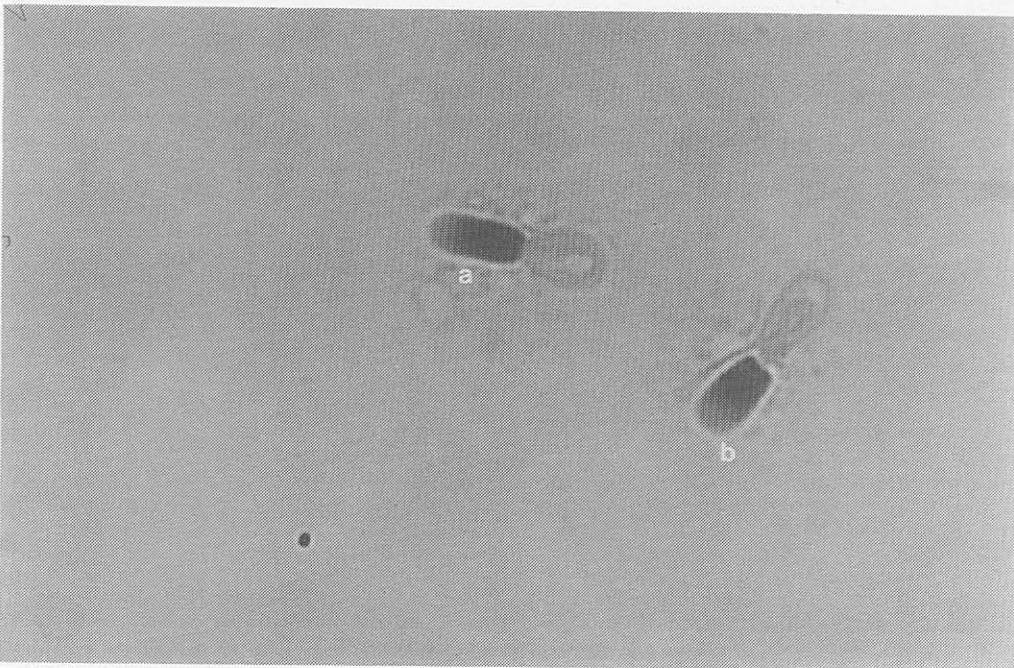


Figure 5. 'Dag' defects with an abnormal head (a) and a normal head (b).

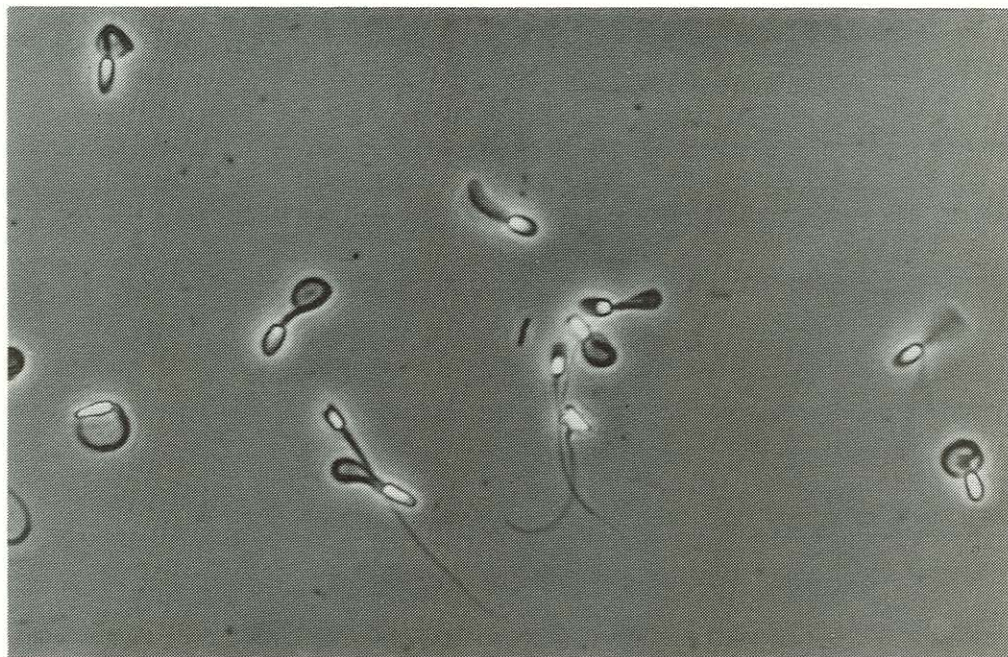

Figure 8

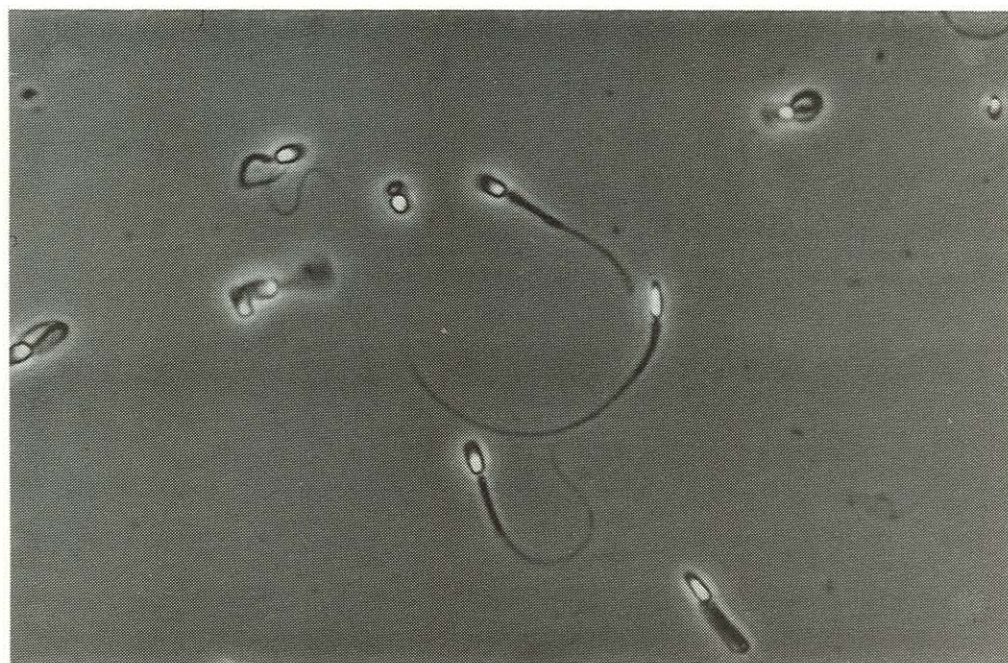

Figure 9

Figures 8/9. Phase contrasts showing 'Dag' defects and coiled tails.

The results of spermograms performed on stained smears or smears examined using phase contrast are summarized in Table 4.

Table 4: Summary of spermogram results ( n = 160)

	% Normal Spermatozoa	% Major Abnormalities
Range	0 - 86	4 - 90
Mean	40,3	26,2
Std	17,5	18,0

A summary of spermogram results from males that sired cubs is presented in Table 5 and shown in Figure 10.




Figure 10. Frequency distribution of the percentage normal sperm counts from seven males that sired 28 litters.

Table 5: Summary of spermograms from seven cheetah males that sired 28 litters between 1975 and 1980. ( n = 63)

	% Normal Spermatozoa	% Major Abnormalities
Range	18 - 80	8 - 42
Mean	47,6	23,6
Std	16,9	8,8

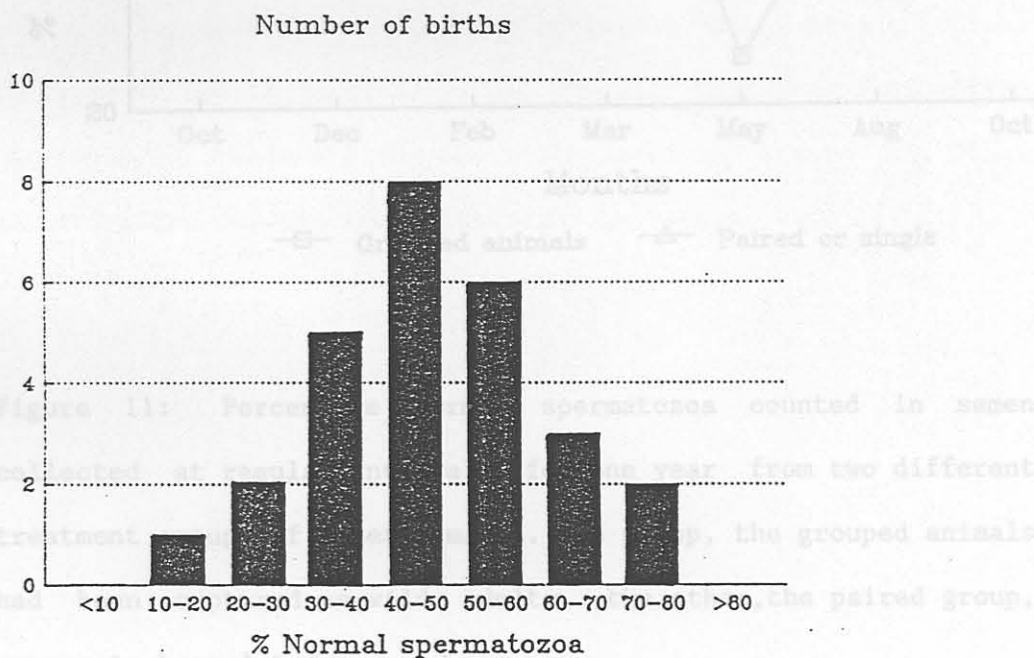


Figure 10. Frequency distribution of the percentage normal sperm counts from seven males that sired 28 litters.

(1976). The head of cheetah spermatozoa in planar view has a compressed elliptical outline while in sagittal section the head is distinctly pear-shaped being considerably broader at the basal

The percentage normal spermatozoa counted in semen samples from 16 cheetah males at regular intervals for one year are shown in Figure 11.

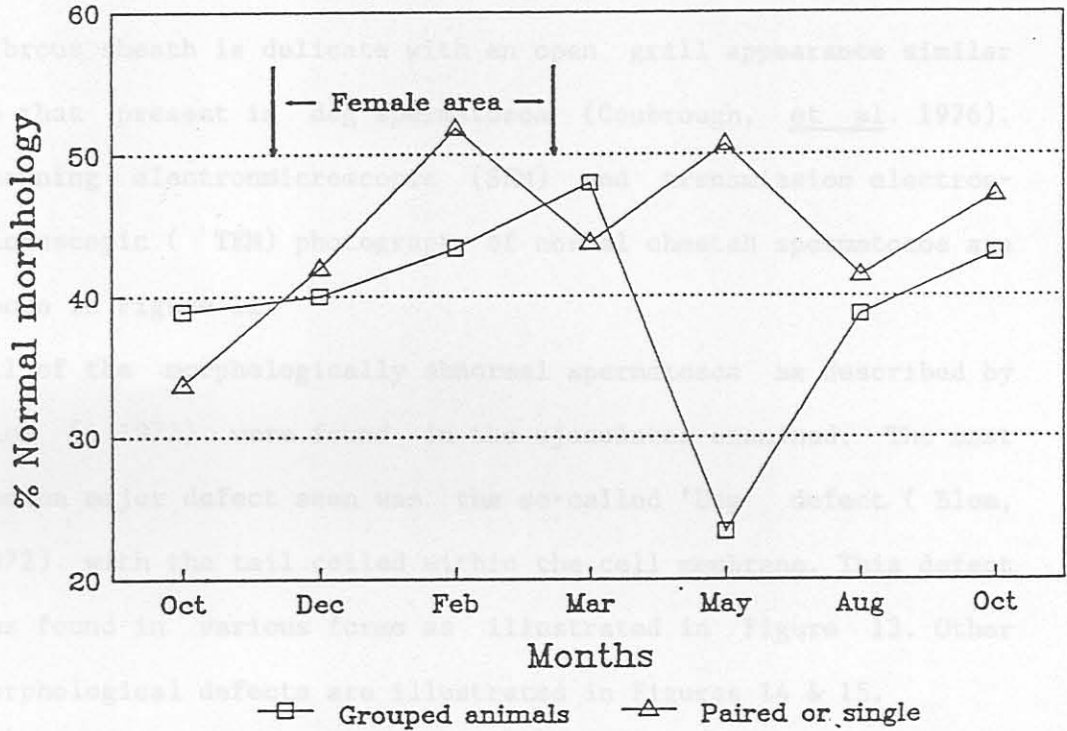


Figure 11: Percentage normal spermatozoa counted in semen collected at regular intervals for one year from two different treatment groups of cheetah males. One group, the grouped animals had been captured as wild adults, the other, the paired group, appear to be related.

The ultrastructural characteristics of normal cheetah spermatozoa were described by Coubrough, Bertschinger, Soley & Meltzer (1976). The head of cheetah spermatozoa in planar view has a compressed elliptical outline while in sagittal section the head is distinctly pear-shaped being considerably broader at the basal

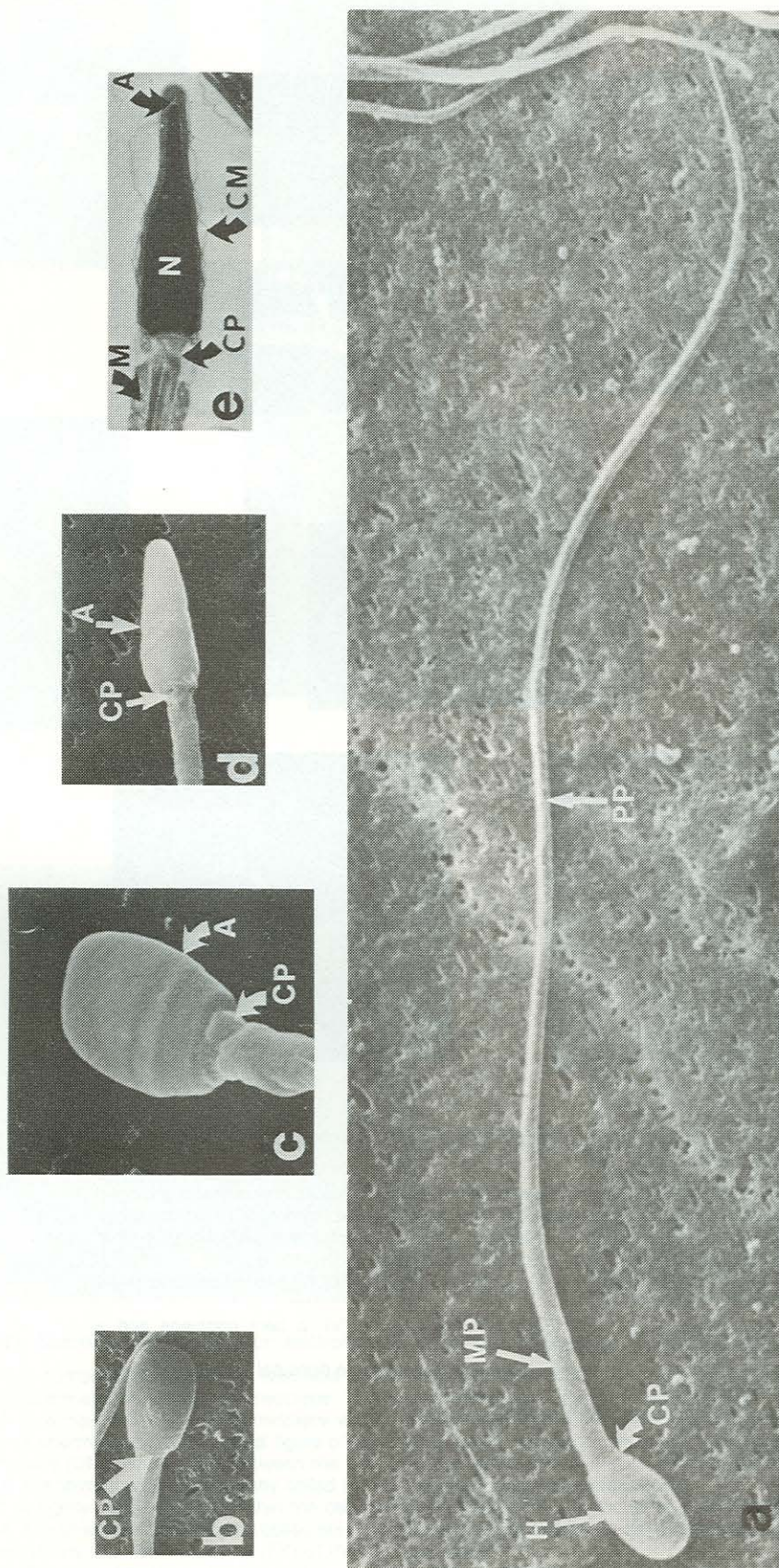
plate. The mitochondrial sheath has a pars spiralis as well as a pars ascendens which almost extends up to the redundant nuclear membrane folds. Capetulum and connecting piece are similar to those seen in other species. No distinct annulus was seen. The fibrous sheath is delicate with an open grill appearance similar to that present in dog spermatozoa (Coubrough, et al. 1976). Scanning electronmicroscopic (SEM) and transmission electronmicroscopic (TEM) photographs of normal cheetah spermatozoa are shown in Figure 12.

All of the morphologically abnormal spermatozoa as described by Blom (1972) were found in the ejaculates examined. The most common major defect seen was the so-called 'Dag' defect (Blom, 1972) with the tail coiled within the cell membrane. This defect was found in various forms as illustrated in Figure 13. Other morphological defects are illustrated in Figures 14 & 15.



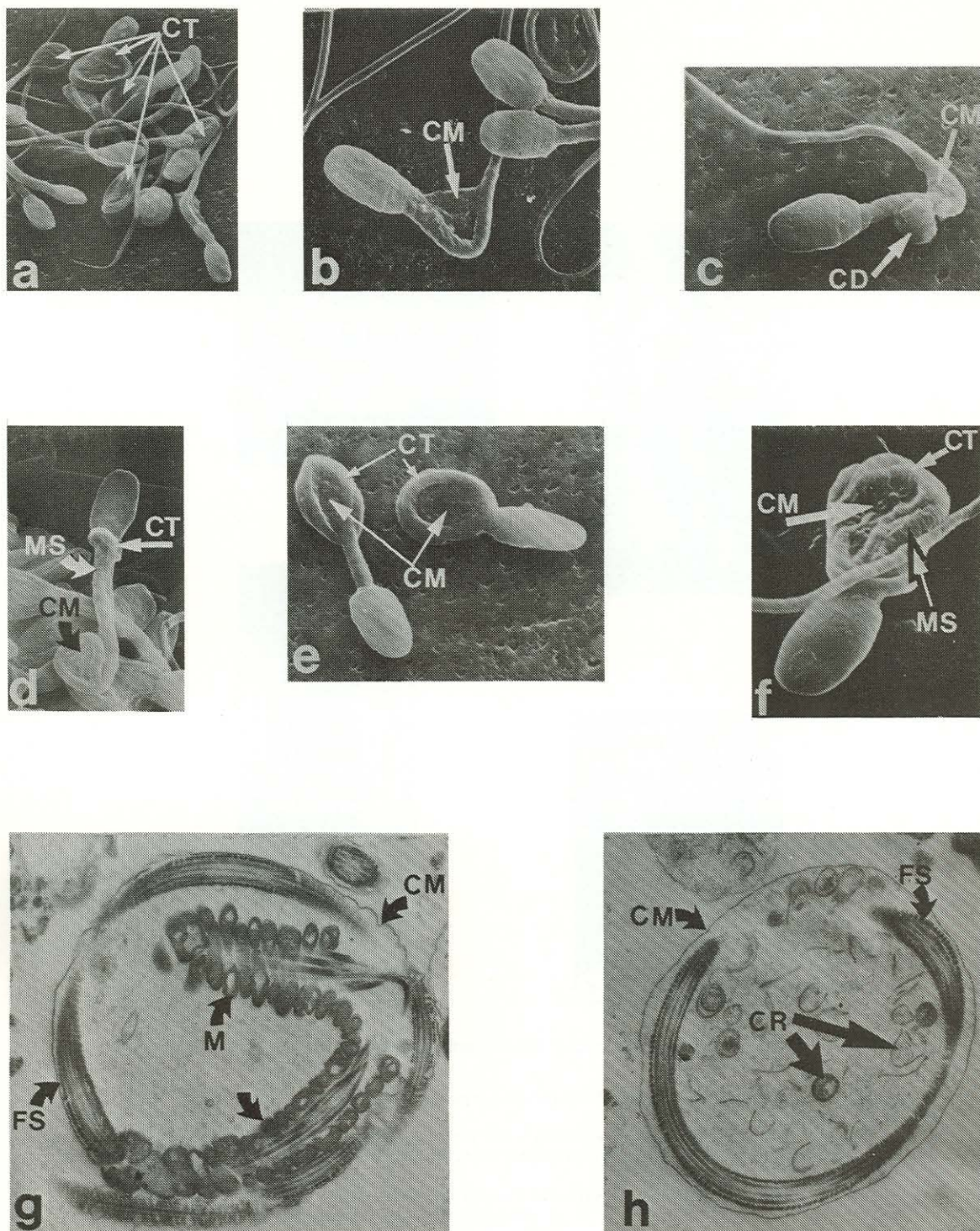
FIGURE 12. (a) SEM. A frontal view of the spermatozoon showing the capetulum (CA) and the connecting piece (CP). (b) SEM. A side view of a spermatozoon showing the capetulum (CA) and the connecting piece (CP). (c) TEM. A longitudinal section of a spermatozoon showing the nucleus (N), nucleolus (NU), connecting piece (CP) and mitochondria (M).





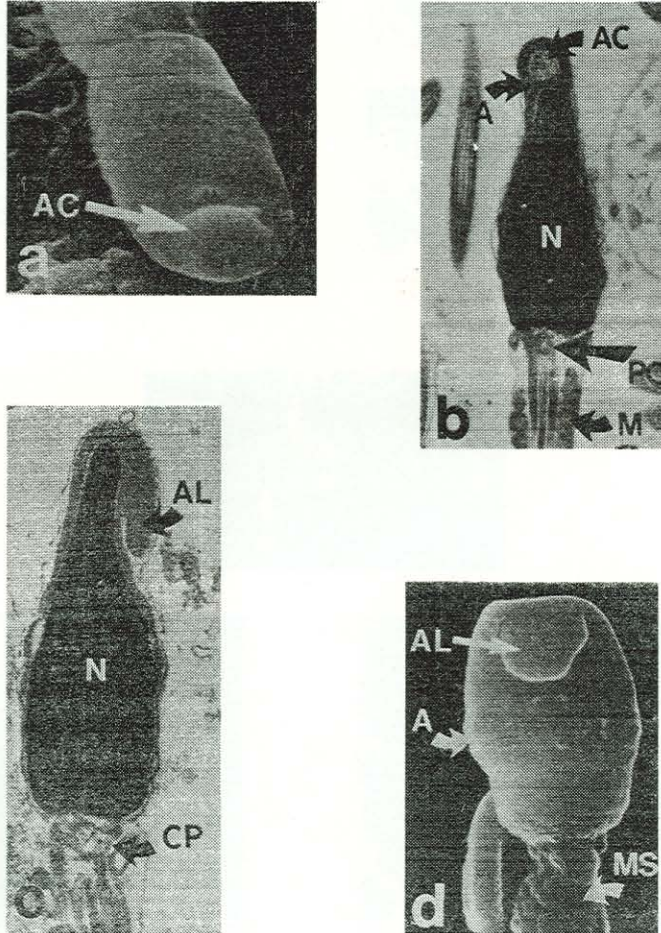
**Figure 12.** Scanning and transmission electronmicroscopy of a normal spermatozoa.

- (a) SEM. A normal spermatozoa showing the head (H), mid-piece (MP) and principal piece (PP).
- (b) SEM. A planar view of a normal head. The connecting piece (CP) is seen.
- (c) SEM. A planar view of the head with the posterior border of the acrosome (A) and the connecting piece (CP) identified.
- (d) SEM. A side view of a sperm head with the posterior border of the acrosome (A) and the connecting piece (CP).
- (e) TEM. A sagittal section of a spermatozoa showing the nucleus (N), acrosome (A), cell membrane (CM), connecting piece (CP) and mitochondria (M).



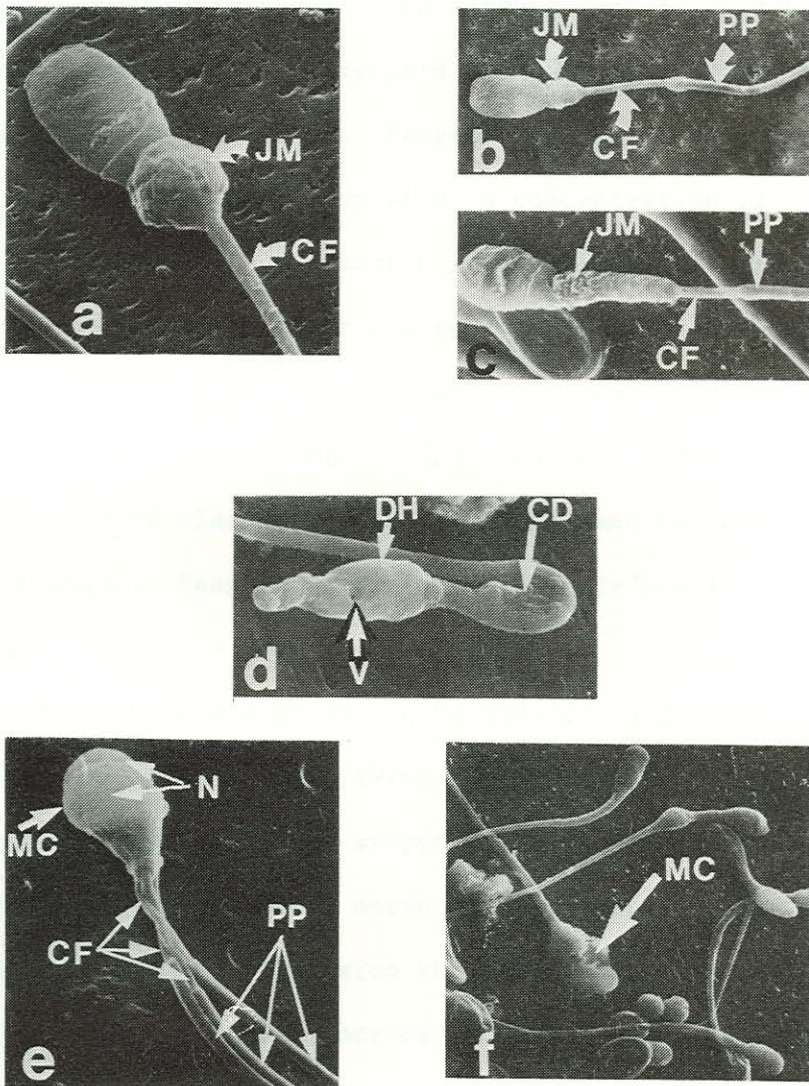
**Figure 13.** Scanning and transmission electromicroscopy of various forms of the 'DAG' defect.

- (a) SEM. A number of spermatozoa with tails coiled within the cell membrane.
- (b) SEM. Spermatozoa with a bent midpiece. The cell membrane is visible in the bend (CM).
- (c) SEM. Spermatozoa with a bent midpiece within the cell membrane (CM) and a persistent cytoplasmic droplet (CB).
- (d) SEM. A spermatozoa with a typical figure of eight 'DAG' defect. Coiling of the tail (CT) around the connecting piece, the cell membrane (CM) can be seen between the coils and the mitochondrial sheath (MS) is visible.
- (e) SEM. A spermatozoa with a tightly coiled tail (CT) within the cell membrane (CM).
- (f) SEM. A tightly coiled tail (CT) within the cell membrane (CM). The mitochondrial sheath (MS) is visible.
- (g) TEM. A cranial section through a coiled tail (CT) showing coiling within the cell membrane (CM), mitochondria of the mid-piece (M) and the fibrous sheath (FS) of the principal piece.
- (h) TEM. Caudal section through a coiled tail showing the cell membrane (CM), fibrous sheath of the principal piece (FS) and cytoplasmic remnants (CR).



**Figure 14.** Scanning and transmission electromicroscopy of acrosomal defects.

- (a) SEM. An acrosomal cyst (AC) also referred to as 'Knobbed sperm'.
- (b) TEM. A sagittal view of a spermatozoa with an acrosomal cyst (AC). The nucleus (N), proximal centriole (PC) and mitochondria (M) are identified.
- (c) TEM. Acrosomal lipping (AL), with the nucleus (N) and the connecting piece (CP) identified.
- (d) SEM. Acrosomal lipping (AL), the acrosome (A) and the mitochondrial sheath (MS).



**Figure 15.** Scanning electronmicroscopy various major defects seen in cheetah spermatozoa.

- (a) Midpiece abnormality in which the mitochondria are displaced cranially and arranged in a jumbled manner at the neck (JM). The bared central filament (CF) can be seen.
- (b) A defect similar to that shown in (a) with jumbled mitochondria (JM), bared central filament (CF) and the principal piece (PP) identified.
- (c) Partially bared central filament (CF), jumbled mitochondria (JM) and the principal piece (PP).
- (d) View of a degenerated head (DH) with vacuolation (V), a bent midpiece and a persistent cytoplasmic droplet (CD).
- (e) Macrocephalic multinucleate (N) spermatozoa with three principal pieces (PP) and a bared midpiece (CF).
- (f) Macrocephalic multinucleate head (MC).

Sadleir (1966) attempted semen collection using electroejaculation in a male leopard (Panthera pardus) which was later found to be infertile due to epididymal occlusion. A semen sample was obtained from a snow leopard (Panthera uncia) by Mayo (1967) using electroejaculation. Seager (1976) electroejaculated two cheetahs and obtained semen with a concentration of < 1 million spermatozoa per ml. Degenaar (1977) electroejaculated 3 cheetah males on several occasions and reported obtaining semen volumes of 0 - 1 ml with spermatozoal concentrations too low to be accurately counted. Ball (1976) reviewed the history and the development of electroejaculation as a means of collecting semen from animals. Seager (1976) described its use in cats and wild felids.

The process of ejaculation can be divided into an emission and an ejaculation phase (Ball, 1976; Benson & McConnell, 1983). The former as the result of sympathetic nerve stimuli reaching the tract via the hypogastric nerve and the latter under the control of the parasympathetic system through innervation from the pelvic and internal pudendal nerves (Gomes, 1978). Emission, the deposition of seminal fluid in the posterior urethra, is accompanied by bladder neck closure which is also a response to adrenergic stimuli. Ejaculation takes place as a result of rhythmic contractions of the periurethral and anal sphincter muscles (Benson & McConnell, 1983).

Adrenergic drugs facilitate emission and bladder neck closure (Benson & McConnell, 1983). Seager (1976) found that cats anaesthetized with a drug combination of ketamine and acetyl promazine

urinated when electroejaculation was attempted. Phenothiazine derivatives used as neuroleptics have been reported to result in a decreased volume of ejaculate or to suppress ejaculation (Martin, 1978). Meltzer, Van Vuuren & Bornman (1987) were unable to obtain semen from chacma baboons (Papio ursinus) immobilized with ketamine and azaperone. Derivatives of both phenothiazine (acetyl promazine) and butyrophenone (azaperone), produce their effects through an adrenergic blockade (Booth, 1982) and thus appear to interfere with emission and bladder neck closure. The initial use of ketamine and xylazine for the immobilization of cheetah males in this study was fortuitous. Xylazine is an alpha-adrenergic agonist (Booth, 1982) and is thus more likely to facilitate effective ejaculation than to hinder it. CT1341 did not appear to influence the ejaculatory response of cheetah males to electrical stimulation in any way.

The characteristics of the electrical stimulus that results in ejaculation have been described (Furman, Ball & Seidel, 1975; Ball, 1976). A sine wave alternating current is the most effective. While the current flow produced by the equipment used is the critical factor in producing ejaculation, sufficient voltage is needed to ensure that tissue resistance is overcome and current flow occurs (Dalziel & Phillips, 1948 in Ball 1976). Furman et al. (1975) found that there was a considerable variation in the resistance to current flow within and amongst bulls (Bos taurus) that they examined and therefore did not measure the current required to elicit electroejaculation. The frequency of the current applied influences the degree of

muscular contraction and discomfort that follow as a side effect of the electrical stimulation. Frequencies of 50-80 Hz caused less unwanted responses than those evinced by lower frequencies (Furman et al. 1975). Muscular contractions are less severe when longitudinal electrodes are used (Ball & Furman 1972, in Ball 1976).

Most investigators use equipment that produces a voltage of up to 40 V for the electroejaculation of domestic animals (Furman et al. 1975). Mayo (1967) used equipment that could produce a voltage of up to 12 V, but did not measure the voltage used to obtain semen from the snow leopard (P. uncia) he examined. Domestic cats (F. catus) were electroejaculated by Platz & Seager (1978) using 2-8 V.

Standard equipment used for the electroejaculation of rams (Ovis aries) (Van Tonder et al. 1973) was used during this study as no external power source was required. The voltage produced was within the range used by Mayo (1967), Platz & Seager (1978) and, in a concurrent study, by Wildt, Bush, Howard, O'Brien, Meltzer, Van Dyk, Ebedes & Brand (1983). Changes in the type of electrode resulted in less muscular stimulation. The use of ring electrodes resulted in seminal fractions being ejaculated at different times as the electrode was moved within the rectum. This observation is similar to that of Furman et al. (1975) who reported obtaining different seminal fractions from bulls when ring electrodes were used. As these fractions were not of consequence to the

purpose of the study they were not evaluated separately. However fractionation of semen could influence the density of semen samples obtained from individual animals.

The quality of semen collected by electroejaculation has been found to be variable ( Lawson, Krise & Sorenson 1967, in Watson, 1978; Roth & Smidt 1970, in Watson 1978). The concentration of spermatozoa in bull semen collected by electroejaculation has been shown to be lower than that of samples obtained using an artificial vagina (Dziuk, Graham, Donker, Marion & Peterson 1954; Austin, Hupp & Murphee, 1961). The volume collected by electroejaculation, however, was greater and thus no significant difference in the total number of sperm per ejaculate was obtained when the two methods were compared ( Austin et al. 1961). Platz & Seager (1978) reported similar observations in cats.

Fresh semen samples evaluated immediately after collection were classified as good, fair or poor after assessing the sperm concentration, % live, % motile, the rate of forward progression and spermatozoal morphology. Accurate counts to determine sperm concentration and the percentage morphologically normal spermatozoa were performed later in the laboratory. All of these parameters were taken into account in arriving at the assessed quality of the semen sample. However, because of the possible of variability in sperm concentration in semen collected by electroejaculation semen motility and spermatozoal morphology were weighted higher in the final assessment of the quality of semen obtained.



There is lack of agreement in the literature as to the correlation between semen evaluation methods and fertility (Watson, 1978; Bartoov, Eltes, Weissenberg & Lunenfeld, 1980; Wildt et al. 1983). Blom (1972) reported six major sperm defects that had been shown to be associated with either decreased fertility or sterility in bulls.

Conception rates after artificial insemination, in cattle, were found to decrease as the proportion of spermatozoal abnormalities rose or when the percentage of live sperm fell below 70 % in the semen used (Munro, 1961). The motility score, a measure of individual sperm activity, was reported as a more reliable estimate of fertility by some (Clarke, O'Neill, Hewetson & Thompson 1973; Linford, Glover, Bishop & Stewart 1976). Carroll, Ball & Scott (1973) rated sperm motility higher than morphology in assessing the fertility of over ten thousand bulls. The proportion of abnormal sperm in ejaculates has been related to infertility in man (Chandley, Edmond, Christie, Gowans, Fletcher, Frankiewicz & Newton, 1975), the bull (B. taurus) (Blom, 1972; Chenoweth & Ball, 1980), the ram (O. aries) (Rhodes, 1980), the boar (Sus scrofa) (Gibson & Johnson, 1980), and the dog (Canis familiaris) (Larson, 1980).

Wildt et al. (1983) proposed chronic stress or the markedly low genetic variation found in cheetahs (O'Brien, Wildt, Goldman, Merrill & Bush, 1983) as possible causes for the large proportion of abnormal spermatozoa found in semen from cheetah males and cited several authors who had shown that inbreeding adversely affected semen morphology. Wildt et al. (1986) found no difference

in the proportion of abnormal spermatozoa in semen from captive North American cheetahs and semen collected from wild cheetahs in the Serengeti National Park. The captive population, comprising 23 animals in zoos had a mean of 70,6 % morphologically abnormal spermatozoa as opposed to the 75,9 % found in 8 wild cheetahs. The percentage abnormal spermatozoa reported by Wildt et al. (1983) and Wildt et al. (1986) cannot be compared with those of the present study. Wildt et al. (1983 & 1986) classified spermatozoal abnormalities as primary and secondary. The former as the result of defective spermatogenesis and the latter as a result of defective maturation of spermatozoa in the duct system. The justification for this approach was questioned by Blom (1972) who had originally proposed it (Blom, 1948, in Blom 1972). He pointed out that new evidence indicated that some so-called secondary abnormalities in fact originated during spermatogenesis and also that secondary abnormalities could be of significance in their influence on fertility when their incidence was in excess of 10 - 15 %. He proposed a new approach in which morphological abnormalities that had been shown to affect fertility were classified as major and were counted together. Minor abnormalities were counted separately and only considered as significant when they exceeded 10-15 % of the total count. The abnormality counts of Wildt et al. (1983, 1986) tend to be misleading as all abnormalities are considered together in their conclusions. This practice has resulted in high abnormality counts even in fertile bulls (Blom, 1972). Further confusion results from their classification of 'coiled flagellum' as a

primary defect. This defect has been shown to develop during passage through the caput epididymis (Blom, 1972).

The breeding results achieved at the De Wildt centre and the cheetah population explosion that was seen at the Suikerbosrand Nature Reserve (Pettifer, De Wet & Muller, 1979 & 1980) appear to belie suggestions, made by Wildt et al. (1983, 1986), that the cheetah is endangered as a result of poor reproductive ability. Low proportions of normal spermatozoa and relatively high numbers of morphologically abnormal spermatozoal were found in some of the nevertheless successful cheetah males at the Centre.

Priority was given to the production of cheetahs in large numbers at the Centre and only males with the best semen quality were used for breeding purposes. This precluded the use of males regarded as sub-fertile in the breeding program as a possible further means of assessing the relevance of the methods applied in evaluating fertility.

The temporal characteristics of spermograms from cheetah males that had either been kept as small groups from 4-6 months of age or had been captured as pairs differed from those of the group of 12 animals. The latter had been removed from the enclosure, where they spent most of the year, and used in the passage between cheetah female enclosures from November to March 1975 - 1976. Fighting amongst them was not uncommon during that time and after their return to their holding enclosure. The former animals were kept, relatively undisturbed, out of the area until required for breeding, and being habituated to one another they did not compete with their companions.

There is evidence that indicates that adult male cheetahs found in their natural environment, in small groups, are related (Eaton, 1974). The presence of females has been shown to affect semen quality (Furman et al. 1975). A seasonal variation in semen quality has been described in many species (Lincoln, 1981). It is possible that stress, as a result of the changed environment and aggression (Wildt et al. 1983), together with the fact that they were removed from the presence of the females, could have influenced spermatogenesis in the grouped cheetah males. The duration of spermatogenesis has been estimated at 54 - 63 days in bulls (B. taurus) and 40-49 days in rams (O. aries) (Courot, Houchereau-de & Ortravant, in Gomes 1978). Evidence as to the duration of spermatogenesis in carnivores is not available but likely to be of a similar order. The decline in semen quality seen in these animals 40 - 60 days after their removal to their enclosure away from the females appears to indicate that spermatogenesis may have been affected by this change. This observation is however not unequivocal and the influence of stress and the presence of the females should be investigated in controlled manner before conclusions in this regard can be made. Cheetahs are not seasonal breeders (Wrogemann, 1975 ; Wildt et al. 1986) and the fact that semen quality did not vary beyond the usual limits amongst the animals kept relatively undisturbed appears to indicate that semen quality in cheetah males does not change with the season. All of the samples collected over the 24 h period.