

Case Report

Isolated left ventricular non-compaction as a cause of thrombo-embolic stroke: a case report and review

J KER, C VAN DER MERWE

Summary

Isolated left ventricular non-compaction is the result of incomplete myocardial morphogenesis, leading to persistence of the embryonic myocardium. The condition is recognised by an excessively prominent trabecular meshwork and deep intertrabecular recesses of the left ventricle. These intertrabecular recesses are prone to thrombus formation, with resultant embolic sequelae. We describe a case of cerebral thrombo-embolism in a young woman due to isolated left ventricular non-compaction.

Cardiovasc J South Afr 2006; 17: 146–147

www.cvjsa.co.za

Case report

A 42-year-old woman was referred for a cardiac evaluation after a second episode of cerebral thrombo-embolism, involving the left mid-cerebral artery distribution. The patient had a history of ulcerative colitis, which was in remission due to 5-aminosalicylic acid use. The clinical examination, electrocardiography, biochemical profile and chest roentgenography were all within normal limits.

Two-dimensional echocardiography was then performed. This revealed the presence of numerous, excessively prominent trabeculations and deep intertrabecular recesses in the mid- and apical segments of the left ventricle (Fig. 1). During systole, the ratio of the non-compacted to compacted layer was above two, a characteristic finding in isolated left ventricular non-compaction (Fig. 2).

The diagnosis of isolated left ventricular non-compaction

was made, based on fulfillment of four echocardiographic criteria, as described by Jenni *et al.* (see Discussion): (1) co-existing cardiac abnormalities were absent, (2) a trabecular meshwork with deep, endomyocardial spaces was present, (3) an end-systolic ratio of more than two of non-compacted to compacted layer was present, and (4) colour Doppler demonstrated deep, perfused intertrabecular recesses. Systolic function was normal with a left ventricular ejection fraction of 64% and a normal pro-BNP level. No electrocardiographic manifestations of dysrhythmia were present.

It was decided that the patient needed long-term anticoagulation with warfarin in order to prevent any thrombo-embolic recurrences. Echocardiography of first-degree relatives did not reveal any other cases of non-compaction.

Discussion

Isolated left ventricular non-compaction is a rare congenital condition that is the result of an intrauterine developmental arrest, which stops the compaction of the loose, myocardial fibre meshwork of the left ventricle.¹ The resultant non-compacted myocardium has a spongy appearance with prominent trabeculations and deep, intertrabecular recesses that communicate with the ventricular cavity, predisposing to local thrombus formation.² The condition is currently listed by the World Health Organisation as an unclassified cardiomyopathy,³ with only a few case reports in the literature.¹

A non-isolated form associated with other congenital heart defects, and an isolated form, often undetected, have been described.¹ The risk for thrombo-embolic episodes is high.^{1,4} Severe heart failure and life-threatening ventricular arrhythmias can also complicate this condition² and it has been advocated that cardiac transplantation should be aggressively pursued once heart failure occurs.¹ It is therefore clear that a diagnosis of isolated left ventricular non-compaction is associated with a high morbidity and mortality and the diagnosis should be made with care, as prominent ventricular trabeculation can be found in healthy hearts as well as in hypertrophied hearts, due to dilated, hypertrophic, valvular

Department of Physiology, University of Pretoria and Pretoria Heart Hospital, Pretoria

J. KER, MB ChB (Pret), MMed (Pret), MRCP (Edinburgh)

Department of Radiology, Pretoria Heart Hospital, Pretoria

C VAN DER MERWE, MB ChB (Pret), MMED (Pret)

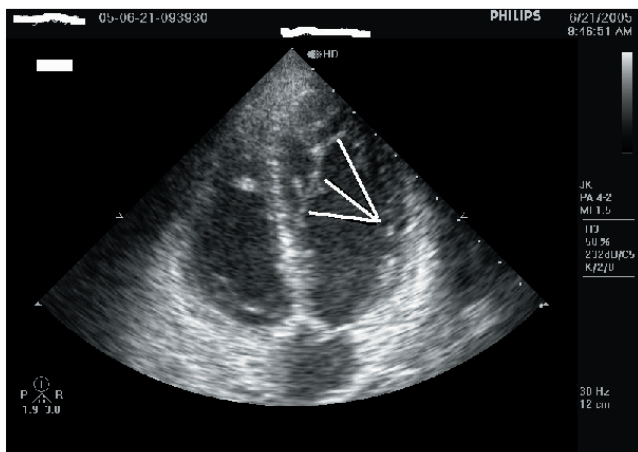


Fig. 1. Two-dimensional echocardiography. Note the excessively prominent trabeculations (white lines) and deep intratrabecular recesses in the mid- and apical segments of the left ventricle.

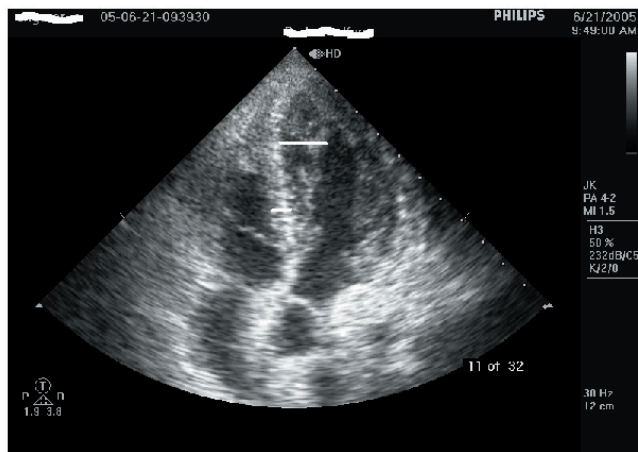


Fig. 2. Two-dimensional echocardiography. Note the characteristic ratio of non-compacted (long white line) to compacted layer (short white line) > 2 during systole.

or hypertensive cardiomyopathy.² However, in a recent study by Murphy *et al.*,⁵ it was found that isolated left ventricular non-compaction is associated with a better prognosis than previously thought.

Since our patient did not have heart failure, which was shown by normal LVEF and a normal pro-BNP level as well as the absence of any dysrhythmias, one tends to think that the prognosis might not be so grave as that reported in the literature. Because this is such a rare condition with few documented case reports, it is fair to speculate that there might be a continuum of severity, with not all patients progressing to heart failure. Only time will tell, as more case reports will undoubtedly appear in future.

Echocardiographic criteria have been established² and include the following: the characteristic appearance of numerous, excessively prominent trabeculations and deep, intertrabecular recesses; intertrabecular spaces filled by blood from the ventricular cavity; and an end-systolic ratio of more than two of non-compacted to compacted layers. This last criterion differentiates isolated left ventricular non-compaction from the trabeculations seen in left ventricular hypertrophy, hypertrophic cardiomyopathy and dilated car-

diomyopathy. In summary, we describe an unusual cause of thrombo-embolic stroke and this case should highlight the importance of meticulous echocardiography in patients with thrombo-embolic stroke.

References

1. Ivan D, Flamm SD, Abrams J. Isolated ventricular non-compaction in adults with idiopathic cardiomyopathy: cardiac magnetic resonance and pathologic characterization of the anomaly. *J Heart Lung Transpl* 2005; **24**: 781–786.
2. Jenni R, Oeschlin E, Schneider J. Echocardiographic and pathoanatomical characteristics of isolated left ventricular non-compaction: a step towards classification as a distinct cardiomyopathy. *Heart* 2001; **86**: 666–671.
3. Richardson P, McKenna W, Bristow M. Report of the 1995 World Health Organization/International Society and Federation of Cardiology Task Force on the definition and classification of cardiomyopathies. *Circulation* 1996; **93**: 841–842.
4. Tufekcioglu O, Aras D, Cagli K. Imaging of isolated ventricular non-compaction with dynamic cardiomyoplasty. *Eur J Echocardiogr* 2005; **6**: 219–220.
5. Murphy RT, Thaman R, Blanes JG. Natural history and familial characteristics of isolated left ventricular non-compaction. *Eur Heart J* 2005; **26**: 187–192.