

**Catastrophic musculoskeletal injuries associated
with four racetracks in Gauteng, South Africa
during 1998-2004**

by

Ingrid Cilliers

Submitted to the Faculty of Veterinary Science, University of
Pretoria, in partial fulfilment of the requirements for the degree
MMedVet (Equine Surgery)

Pretoria, July 2009



UNIVERSITEIT VAN PRETORIA
UNIVERSITY OF PRETORIA
YUNIBESITHI YA PRETORIA

SUPERVISOR:

Prof Ann Carstens

Department of Companion Animal Clinical Studies

Faculty of Veterinary Science

University of Pretoria

to my father who supported me through all my endeavours

TABLE OF CONTENTS

Acknowledgements	v
List of Appendices	vi
List of Tables	vii
List of Figures	viii
List of Abbreviations	ix
Summary	1
CHAPTER 1 INTRODUCTION	3
1.1 Hypotheses	3
1.2 Objectives	3
1.3 Benefits	4
CHAPTER 2 LITERATURE REVIEW	5
2.1. Introduction	5
2.1.1 Definition	5
2.1.2 Incidence of catastrophic musculoskeletal injuries	6
2.1.3 Track surface	8
2.1.4 Race distance	10
2.1.5 Surface condition (going)	11
2.1.6 Class of race / stakes	12
2.1.7 Position on track where catastrophic musculoskeletal injury occurs	13
2.1.8 Pre-race inspection	14
2.1.9 Limb predilection	16
2.1.10 Specific location of injuries	17
2.1.11 Age	20
2.1.12 Gender	22



2.1.13	Race interval (number of starts per year)	22
2.1.14	Number of seasons raced	23
2.1.15	Number of starts per racing season	23
2.1.16	Time of race	24
2.1.17	Position in bunch	24
2.1.18	Barrier position	24
2.1.19	Change in distance	24
2.1.20	Racetrack	25
2.1.21	Cumulative high speed exercise pre-race	26
CHAPTER 3 MATERIALS AND METHODS		27
3.1	Study design	27
3.2	Experimental design	27
3.2.1	Case selection	27
3.2.2	Inclusion criteria	29
3.3	Experimental procedures	29
3.3.1	Radiographic procedure	29
3.3.2	Ultrasonographic examination	30
3.3.3	Magnetic resonance imaging	30
3.3.4	Dissection	31
3.3.5	Deoxyribonucleicacid (DNA) analysis	31
3.3.6	Racing data	31
3.3.7	Statistical analysis	32
CHAPTER 4 RESULTS		34
4.1	Study population	34
4.2	Anatomical study of catastrophic musculoskeletal injuries	34
4.2.1	Anatomical location of catastrophic musculoskeletal injuries during the 1998-2004 racing period	34



4.2.2	Distribution of left versus right forelimb involvement	35
4.2.3	Classification and distribution of fractures	36
4.2.3.1	Open versus closed fractures	36
4.2.3.2	Condylar fractures	36
4.2.3.3	Luxation and subluxation of metacarpophalangeal joint	36
4.2.3.4	Proximal sesamoid bone fractures	37
4.2.4	Tendon, ligament and cartilaginous damage associated catastrophic musculoskeletal injuries	38
4.3	Incidence of catastrophic musculoskeletal injuries	43
4.3.1	Number of starts	43
4.3.2	Number of catastrophic musculoskeletal injuries per racetrack per racing season	45
4.3.3	Incidence of catastrophic musculoskeletal injuries per 1000 starts per racing season	46
4.4	Statistical analysis of potential risk factors for catastrophic musculoskeletal injuries	47
4.4.1	Racetrack	47
4.4.2	Racing year	48
4.4.3	Draw	49
4.4.4	Weight carried by horse	49
4.4.5	Distance raced	50
4.4.6	Going	50
4.4.7	Age	50
4.4.8	Gender	51
4.4.9	Racing interval	52
4.4.10	Size of field	52
4.4.11	Multiple logistic regression model	53



CHAPTER 5	DISCUSSION	56
5.1	Incidence of catastrophic musculoskeletal injuries	56
5.2	Racetrack	57
5.3	Anatomical areas affected	58
5.4	Risk factors for catastrophic musculoskeletal injuries	61
5.5	Limitations identified in this study	64
5.6	Future use of study	66
CHAPTER 6	CONCLUSION	67
REFERENCES		69
APPENDICES		73

Acknowledgements

Without the help of the following people this dissertation would not have been possible. Thank you to:

Dr David Sutton for diligently assisting me with my first protocol and helping breathe life into this study.

Prof Ann Carstens for stepping in when needed and being an inspiration to anyone entering the field of equine science be it surgery or diagnostic imaging. Thanks for your continued enthusiasm and friendship.

Dr Peter Thompson for helping me with all the statistics.

Srs Liani Kitshoff and Melanie McLean for their help in acquiring the radiographic images and their positive criticism of the radiographic quality of these images.

Dr Dale Wheeler for allowing me access to his little black book of Catastrophic musculoskeletal injuries and for all the e-mailing.

Mrs Petro Bester, who without any hesitation was willing to help with the outlay, formatting and printing of the final product.

To my bother-in-law, Andre that helped me tie up the loose ends.

To my husband Nico for allowing me to work until late and supplying endless dinners.

And most importantly thanks to God for granting me the ability and endurance to continue and complete my MMedVet (Equine Surgery).

List of Appendices

Appendix A	Structuring of the different classes or grades of races	73
Appendix B	Schematic representation of the typical outlay of the North American racetrack	74
Appendix C	Horse identification and relevant racing history and injury details for 22 horses	75
Appendix D	Horse identification and relevant racing history for 55 horses	76
Appendix E	Equine distal limb fracture radiology report	77
Appendix F	Equine tendon ultrasound report	109

List of Tables

Table 2.1	Reported incidence of catastrophic musculoskeletal injuries in different international locations.	7
Table 2.2	Risk of injuries per 1000 starts on different track surfaces.	9
Table 2.3	Percentage of occurrence of catastrophic musculoskeletal injuries relative to the different positions on the racetrack.	14
Table 2.4	Reported percentage of musculoskeletal injuries indicating predilection of limb involvement in different international locations.	17
Table 4.1	Number of starts per race season for all four Gauteng racetracks during the racing period 1998-2004.	44
Table 4.2	Incidence of catastrophic musculoskeletal injuries at each track.	48
Table 4.3	Incidence of catastrophic musculoskeletal injuries per race year.	48
Table 4.4	Incidence of catastrophic musculoskeletal injuries related to draw.	49
Table 4.5	Incidence of catastrophic musculoskeletal injuries as related to weight carried by the horse.	49
Table 4.6	Incidence of catastrophic musculoskeletal injuries related to going.	50
Table 4.7	Incidence of catastrophic musculoskeletal injuries related to age.	51
Table 4.8	Incidence of catastrophic musculoskeletal injuries related to gender.	51
Table 4.9	Incidence of catastrophic musculoskeletal injuries related to racing interval.	52
Table 4.10	Incidence of catastrophic musculoskeletal injuries related to size of field.	52
Table 4.11	Results of mixed-effects multiple logistic regression model for risk factors: draw, gender, racing interval and weight carried by horse.	53

List of Figures

Fig. 4.1	Bar chart depicting the anatomical location of the 55 catastrophic musculoskeletal injuries during the racing period 1998-2004.	35
Fig. 4.2	Line graph depicting the number of starts per race season for all four Gauteng racetracks during the racing period 1998-2004.	44
Fig. 4.3	Line graph depicting the number of catastrophic musculoskeletal injuries per racetrack per racing season during the racing period 1998-2004.	46
Fig. 4.4	Incidence of catastrophic musculoskeletal injuries per 1000 starts per racetrack per racing season during the racing period 1998-2004.	47

List of Abbreviations

<i>a.r.o</i>	as result of
AWT	All Weather Track
CI	Confidence interval
CMI	catastrophic musculoskeletal injury
DDFT	deep digital flexor tendon
DSL	distal sesamoid ligaments
<i>e.g.</i>	for example
ERC	Equine Research Centre, Onderstepoort
FL	forelimb
<i>i.e.</i>	that is
IOM	interosseus medius muscle (also referred to as the suspensory ligament)
KRC	Kentucky Racing Commission
lat	lateral
LF	left forelimb
MC3	metacarpus 3 / cannon
MCP	metacarpophalangeal joint
med	medial
MRI	magnetic resonance imaging
MS	musculoskeletal
MSI	musculoskeletal injury
MT3	metatarsus 3
NH	National Hunt
NHRA	National Horse Racing Authority
ODSL	oblique distal sesamoidean ligament
PSB	proximal sesamoid bone
QH	Quarter Horse
RF	right forelimb
RSA	Republic of South Africa
SA	suspensory apparatus
SDFT	superficial digital flexor tendon
SDSL	straight distal sesamoidean ligament



TB Thoroughbred
UK United Kingdom
USA United States of America
US\$ United States dollar
vs versus

Summary

Catastrophic musculoskeletal injuries associated with four racetracks in Gauteng, South Africa during 1998-2004

Cilliers, I. University of Pretoria, 2009

A retrospective investigation of Thoroughbred racehorses euthanized as result of catastrophic musculoskeletal injury (CMI) at four racetracks in Gauteng, South Africa during the period of 1998-2004 was performed. Fifty-five cases of CMI from 103 603 starts were evaluated. The incidence of CMI per 1000 starts was 0.53, similar to the incidence reported worldwide. The affected limb of 32 of 55 horses with a CMI was evaluated radiographically, ultrasonographically and dissected.

CMI occurred unilaterally and predominantly in the forelimbs, the left forelimb (LF) being most commonly affected. The suspensory apparatus, particularly the proximal sesamoid bones (PSB) was predominantly affected, mostly in the LF. Sixty-nine percent of the PSB fractures occurred biaxially, the medial PSB most commonly affected. PSB fractures were often associated with extensive damage to the flexor tendons and ligaments of the metacarpophalangeal joint. Lateral condylar fractures were more common than medial, and the right forelimb predominantly affected.

Significant risk factors for CMI in this study were gender, racing interval, and weight carried. Gender relative to the number of starts had the highest statistical significance (intact males $P < 0.001$ and geldings $P = 0.010$). Intact males were 14.8 times more at risk than females and 5.3 times more so than geldings.

Horses carrying more than 59kg were 3.3 times more at risk of breakdown than horses carrying 54-59kg of weight ($P = 0.006$). Horses with a racing interval of less than one week were approximately three times more at risk than those with longer intervals ($P = 0.025$ and $P = 0.029$ respectively).

Statistically insignificant risk factors were racing year, going, distance, racetrack, age, size of field and draw.

It is of paramount importance that CMI is strictly monitored and risk factors identified to implement preventative measures to circumvent occurrence of CMI, which may



have a negative impact on this important spectator sport. This study provides benchmarks for the racing industry to monitor racetrack fatalities in Gauteng and to evaluate intervention strategies.

Chapter 1: Introduction

1.1 Hypotheses

1. The overall incidence of catastrophic racing injuries involving the musculoskeletal system of Thoroughbred horses (TB) at four racetracks in Gauteng, South Africa is similar to that reported elsewhere in the world.
2. The left forelimb (LF) is the limb most frequently involved in catastrophic musculoskeletal injuries (CMI) at tracks in Gauteng.
3. Damage to the forelimb suspensory apparatus (SA) is the predominant catastrophic musculoskeletal injury observed at the racetracks in Gauteng.
4. Lateral condylar metacarpus III (MC3) fractures are more common than medial condylar fractures at racetracks in Gauteng.
5. Most injuries occur in horses sprinting over short distances
6. The incidence of catastrophic racing injuries involving the musculoskeletal system of Thoroughbred horses differs depending on the specific racetrack.

1.2 Objectives

1. To determine the overall and individual incidence of catastrophic racing injuries involving the musculoskeletal system of horses at four racetracks in Gauteng over the period 1998-2004 and to determine how this compares to that already reported in other countries (USA, Canada, Australia, and UK).
2. To investigate the specific site of the musculoskeletal lesion by means of radiographic and ultrasonographic evaluation and a detailed post-mortem dissection.
3. To anatomically categorize the injuries into different sites (carpus, diaphysis of MC3, metacarpophalangeal joint (MCP), suspensory apparatus, proximal sesamoid bones (PSB), phalanx 1, interosseous medius (IOM), etc.).
4. To investigate the incidence of left forelimb versus right forelimb (RF) involvement.

5. To determine if there is an association between the factors such as age, gender, race distance, racing year, draw, weight carried by horse, going, racing interval, size of field and track, and specific musculoskeletal injury.
6. To compare the relative incidence of catastrophic musculoskeletal injuries at the four racetracks under study, as well as the relative incidence of injuries in successive years.

1.3 Benefits

1. The study will identify the anatomical structures involved in musculoskeletal injuries (MSI) acquired at selected South African racetracks.
2. The study will identify and describe the specific site and location of the musculoskeletal injury. This has not been reported previously in South Africa.
3. The incidence of catastrophic musculoskeletal racing injuries sustained at selected South African racetracks will be reported.
4. The results of this study may have welfare implications for horses being trained and raced in South Africa.
5. The research conducted serves as partial fulfilment of the principal investigator's MMedVet(Equine Surgery) degree.
6. The results of this study will be written in article form and published in a refereed journal.
7. Results may reveal information about the relative safety of the different racetracks in Gauteng.

Chapter 2: Literature Review

2.1 Introduction

Musculoskeletal injury is the major cause of wastage of Thoroughbred racehorses^{15,22,32} and is a major cause of racetrack fatality³⁷. Various studies have been conducted pertaining to breakdowns occurring on North American, Australian and British racetracks. Only one survey conducted over a five-year period (1988-1993) in South Africa has been published pertaining to incidence of catastrophic racetrack injuries in the Transvaal district (currently known as Gauteng)¹⁸.

Some of the reports describing racehorse injuries have yielded conflicting results regarding the importance of various horse and racetrack related risk factors for injury. Musculoskeletal injuries in Thoroughbred racehorses have been associated with sex, age, age at first race, horseshoe characteristics, racing frequency, duration of racing career, number of starts per year, weather, season, pre-existing osseous lesions, experience of trainer, class of race, physical interactions among horses during racing, racetrack, results of pre-race physical inspection, and intensity of racing and training schedules. Lower quality horses may be raced more often to maximize their opportunity to earn winnings and may have more conformational defects that limit their ability to move up in class, and that predispose them to catastrophic musculoskeletal injuries (CMI). In addition these horses may be more likely to race on poorer quality racing surfaces. Different factors may influence the outcome of fractures that are catastrophic to a racing career. Racehorse owners would probably be more likely to attempt to save sexually intact, high quality colts / fillies for breeding purposes.

2.1.1 Definition

The definition of a “breakdown” has varied according to different studies conducted in the past. “Breakdown” was defined in three studies when a horse had not raced within six months following a muscular or skeletal injury on the racetrack^{2,3,21}. This

case definition was chosen in order to include only serious musculoskeletal injuries. Injury was categorized as catastrophic if the horse was euthanized on the day of injury when an obvious onset of lameness became apparent during racing, when initial examination or follow-up monitoring indicated that the horse could not ambulate, and that the likelihood of any treatment resulting in a horse that could exist comfortably at pasture was negligible^{2,3,7,9,12,18,24} or when the horse was euthanized within one month of the injury^{7,9,13}.

Discrepancy in the incidence of “breakdown” reported in different articles can likely be attributed to variability in the definition of a breakdown injury among reports. A standardized definition of a breakdown injury is needed to facilitate the study of MSI because of its severity and importance to the racing industry and its impact on public perception of the racing industry.

2.1.2 Incidence of catastrophic musculoskeletal injuries

CMI or breakdowns have been expressed as the number occurring per 1000 starts. Bailey *et al.* calculated the incidence of serious MSI in each race type by dividing the number of cases (which included fatal MSI) by the total number of race starts³. The incidence of CMI per 1000 starts varies between studies and ranges from 0.3 to 2.3 for flat racing^{2-8,10-13,16,18,20,21,23-24,27,37}. Florida, USA (2.3) has the highest incidence of CMI in flat racing with Sydney, Australia (0.3) the lowest. South African racetracks in the old Transvaal province (currently known as Gauteng) showed an incidence of CMI/1000 starts of 1.4¹⁸ for flat racing. Table 1.1 summarizes reported studies with their respective results. The incidence of CMI reported for racing over hurdles or fences is considerably higher than that for flat racing (6.3)²⁷.



Table 2.1: Reported incidence of catastrophic musculoskeletal injuries in different international locations.

Location	Study period	Ref	Number of starts	Number of CMI Cases	Incidence of CMI/1000 starts
Melbourne Australia	Aug 1988 – July 1995	3	68 014	196	0.6
Sydney Australia	1Aug 1985 – 28 Feb 1995	2	57831	137	0.3
Victoria Australia	1Aug 1989 – 31July 2004	4	719 695	316	0.44
Ontario Canada	2004-2005	10	38 097	76	1.69
Transvaal RSA	1988-1993	18	70 753	102	1.4
UK	1Jan 1987 – 31Dec 1993	20	475 000 (starts included flat races, national hunt flat races, hurdles and steeplechases)	1422	turf =0.8 (all types of racing) AWT=0.6 (all types of racing)
Mainland Britain only	1996-1998	37	133 416	657	3.97 (all injuries including fatalities)
UK	2000-2001	27	2879	83	6.3 (steeplechasing and hurdling)
UK	Feb 1999- Jan 2001	23	77 059	29	AWT=0.72 (all types of racing) turf=0.38 (flat racing)
California USA	20Feb 1990- 1Mar 1992	16	-	358 (MSI and not CMI)	-
California USA	Jan-Jun + Oct-Dec 1991	12	-	83	1.7
California USA	1992	11	47 092	78	1.7
Florida, USA	1995-1998	13	79 416	97	1.2 turf =2.3 dirt =0.9
Kentucky USA	1Jan 1992 – 31May 1993	24	35 484	51	1.4
Kentucky USA	1Mar 1994 – 28Feb 1996	7	-	93	-
Kentucky USA	1Mar 1994 – 28Feb 1996	9	-	206	-
Kentucky USA	1Jan 1996 – 25Oct 1997	8	43 865	11	-
New York USA	Jan 1985 – Jun 1988	21	-	56	-

CMI = catastrophic musculoskeletal injuries
AWT = all weather track
MSI = musculoskeletal injuries
Ref = reference number

2.1.3 Track surface

Currently racing is conducted on ten racecourses in South Africa (two in Gauteng, three in Kwazulu Natal, two in the Western Cape, two in the Eastern Cape, and one in the Northern Cape). Racing takes place in a clockwise direction on the majority of the racecourses. Two racecourses in the Western Cape and one racecourse in Kwazulu Natal are raced in a counter-clockwise direction. In South Africa the majority of races are run on turf. The larger provinces have their own racing season which lasts approximately three to four months of the year. The majority of the horses are trained and stabled at a specific training centre and are transported to participate at the different racetracks. Some trainers will often take an entire string of horses to another province for that province's entire racing season.

The racing industry in Australia exclusively uses turf throughout the year². In Melbourne horses race in an anti-clockwise direction³.

In the United Kingdom (UK), professional horse racing is conducted on 59 racecourses, comprising of many turf racetracks and three All Weather Tracks (AWT). Some turf tracks in Europe are natural surfaces, sown with special grass mixes¹⁷. In Europe each turf track is different, and horses race both anti-clockwise and clockwise¹⁷. The AWTs in Europe are more consistent in design. The AWT surface is constructed of a sand, fibre and polymer binder combination designed not to freeze at subzero temperatures³⁵. The depth of cushion is greater than the turf tracks. All have a standard oval shaped track.

Racetracks in North America are oval shaped and similar in size, with horses consistently racing in the same direction, mainly anti-clockwise¹⁷. In the United States of America (USA) racing on dirt surfaces represents 90% of all TB races¹⁷. The dirt track in North America comprises a roadbed covered with crushed stone and sand, with an overlying cushion of fine sand and organic matter. Turf tracks in North America consist of grass grown on a sandy soil base covering a crushed stone layer and the roadbed. In the USA, field size rarely exceeds 12 horses, because the dirt racetracks are relatively narrow and have tight turns, and turf courses, usually inside of the main track, are even narrower with tighter turns¹.

In flat racing in the UK the risk of injury on AWT was higher than that on turf^{23,37}. The relative risk of injury on AWT compared with turf tracks was 1.9²³. A study in the UK found that the level of prize money and therefore the quality of horses running on AWT in the UK was generally lower than that in turf races²³. This is potentially a confounding factor because one of the reasons for poor performance may be a subclinical or previous injury, and horses in all-weather flat races may therefore be inherently more likely to sustain an injury²³. In contrast to this, another study found that the overall fatality rates on AWT was less than that on turf²⁰. This study reported fatalities between 1987 and 1993, when AWT were relatively new. It is possible that these surfaces were at first safer than the turf and have become associated with a greater risk of injury as the quality of the AWT tracks had deteriorated²⁰.

Studies conducted in the USA, where races are more often run on dirt tracks, have consistently recorded a higher fatality rate^{12,24,38}(see Table 1.2). Horses racing on turf had a lower risk (one third) of serious MSI compared with horses racing on dirt²¹. The risk of injury was the highest for dirt tracks in most of the studies conducted^{12,24}. Turf tracks showed the least risk of injuries per 1000 starts^{20,23,38}, except for a study conducted by Hernandez *et al.* that showed the greatest risk of injury per 1000 starts on turf¹³. The risk on AWT lay in between that of turf and dirt tracks^{20,23}. Table 2.2 highlights some of the reported findings of risk of injuries on different track surfaces.

Table 2.2: Risk of injuries per 1000 starts on different track surfaces.

Study	Ref	AWT	Turf	Dirt
UK Feb 1999- Jan 2001	23	0.72	0.38	-
UK 1Jan 1987- 31Dec1993	20	0.6	0.8	-
California Jan-Jun + Oct-Dec 1991	12	-	-	1.2
Kentucky 1Jan 1992 – 31May 1993	24	-	-	1.04
USA 1992	38	-	0.13 (per 760 starts)	0.16- (per 619 starts)
Florida 1995-1998	13	-	2.3	0.9

AWT= all weather track
Ref = reference number

These results generally suggest that turf courses are safer than dirt or all-weather tracks. However directly inferring that turf is inherently safer may be over-simplistic as there is a need to examine the role of potential confounding factors associated with the country (Australia, UK) in which the study was conducted^{3,23}. Possible confounding factors may include frequency of racing, rules of governing medications, climatic variability, training regimes, class of horse, and even the level of prize money. Horses running on turf surfaces were more likely to participate in more competitive events (large fields, handicap races, long races, high purse values) than horses running on other surfaces¹³. Compared to dirt races, turf races were 5 times as likely to have a large field of horses (9-13), 7 times as likely to be a handicapped race, 66 times more likely to be a long race (1.6-2.4km / 8-12 furlongs), and median purse value was significantly higher (US\$23 000 vs US\$1300 for dirt)¹³.

Although general risk of CMI may be lower on turf, specific injuries may occur more frequently. Parkins *et al.* in their flat racing study showed that fractures of the proximal phalanx were more common on turf, while fractures of the PSBs were more common on AWT²³. Likelihood of sustaining a biaxial proximal sesamoid bone fracture on AWT was 10 times that of turf flat racing²³. The rate of PSB / MCP and tendon / IOM injuries during flat and National Hunt racing was two times greater on AWT³⁷ (see 2.1.10).

2.1.4 Race distance

A furlong is a racing term used to measure a certain distance *i.e.* 1 furlong = 201.16m = 0.125 miles = 220yards; 1 mile = 1609.3m. In the UK, the shortest flat race distance is 1000m (5 furlongs or 0.625 miles), and the longest distance is 4 400m (2.75 miles)³⁵. Race distances in California were recorded between 5.0 and 8.5 furlongs (1000 - 1 700m)¹¹; in Kentucky between 4.5 and 16 furlongs (900 - 3 200m)⁷; and in New York the dirt tracks measured 1 to 1.125 mile (1 600 - 1 800m) and the turf tracks 1 400 - 1 600m¹⁴. Flat racing distances in Melbourne were between 900 – 3 200m³.

Studies in Kentucky, USA have shown that the distance of the race was significantly shorter and the number of turns less among horses with catastrophic injuries than among horses with non-catastrophic injuries^{8,24}. The proportion of horses racing less

than or equal to 1307m (6.5 furlongs) was greater in the catastrophic group (59.8%) than among horses in the career ending group (40%)²⁵. British flat racing places greater emphasis on racing over long distances (greater than 2 414m / 1.5 miles) than North America³⁷.

Cohen *et al.* also detected an increased risk of injury of the suspensory apparatus of the forelimb for horses in races of shorter distance (less than 1408m / 7 furlongs)⁸.

Flat racing risks seem to be different to hurdling races with respect to injury. Pinchbeck *et al.* included all types of racing (hurdling included) in their study and showed that longer distances increased the risk of injury²⁷. Horses are more likely to incur an injury due to increased exposure time and increased number of fences and hurdles. Horses are more likely to be fatigued in longer distance races. Risk of falling also increases with increased distance²⁷.

2.1.5 Surface condition (going)

Official surface conditions are approximate indicators of race track moisture content and usually range from fast, good, muddy to sloppy for dirt, and from firm, good soft to yielding for turf^{11,14}. Fast (hardest and driest), good, dead, slow, and heavy (most moist) are used to describe going on dirt tracks². Turf racing conditions are classified as: hard, firm, good to firm, good, good to soft, soft, and heavy (most moist). AWT surfaces described as: standard and slow³⁷.

Racing surface was associated with risk of injury in some studies^{21,27}. For turf racetracks in Britain the aim is to provide racing surfaces which can be described as good-to-firm for flat racing. The racing authorities ruled that racing should not take place on hard ground³⁷. Horses racing on fast or good tracks had a greater risk of suffering musculoskeletal breakdown compared to heavy surfaces. Harder, drier, turf track surfaces were associated with greater risk than rain affected soft tracks. This may be due to harder turf tracks having less cushioning effect, as horses' limbs have greater forces exerted on them than on tracks with a higher moisture content. Fast tracks positively correlated with occurrence of tendon strain. Overall the frequency of MSI was lowest from racing on turf that was soft and the rate of problems increased as surfaces became firmer (all types of racing)³⁷. Overall racing fatality also tended

to decrease as racing surfaces became softer (all types of racing)³⁷. This trend was only marginally significant for flat racing. There was a clear trend for a decrease in overall rate of MSI as racing conditions became softer^{27,37}.

A study conducted in New York found a significant association between track composition / condition and risk of breakdown²¹. However, when evaluating the interaction between racetrack and track condition in the multivariate analysis a significant effect of this interaction on the risk of breakdown was not found. Horses running on muddy dirt tracks (high moisture content) were at a significantly lower risk of breakdown in comparison to normal dry dirt²¹. No difference was found in risk of breakdown between horses racing on sloppy dirt (very high moisture content) when compared with normal or muddy dirt (high moisture content)²¹. A possible explanation given for this lack of association between the risk of breakdown and racing sloppy dirt tracks is that few healthy fit horses race under these conditions²¹.

In several studies no significant association was found between track condition and composition and racing injuries^{14,25,38}. A difference was not found in risk of CMI between dirt and turf for various official conditions and race distance in a study by Estberg in California, USA¹¹. Interaction between several factors such as racing surface type, race length, horse's age and likelihood to voluntarily withdraw high quality horses from races under poor weather conditions, most likely complicate the relationship between racing surface and risk of CMI.

2.1.6 Class of race / stakes

Races are made to be competitive by restricting which horses are eligible to run in any particular race and Appendix A outlines the structuring of these races.^{1,26}

Bailey *et al.* showed that horses in a stakes race in Sydney were 2.3 times more likely to suffer a MSI than those in non-stakes races.²

Cohen *et al.* showed that more horses were injured in allowance races (32.4%) or races where claiming prizes were US\$5 000 - 10 000 (30.6%) and US\$10 000 - 25 000 (18.5%)⁷. Prize money of greater than US\$15 000 / race was significantly associated with increased risk of CMI. In this study the number of career races was

not significantly associated with any category of injury. However, in a later contradictory study, Cohen *et al.* showed that horses in races in Kentucky with prize monies below US\$25 000 were at increased risk of injury⁸. It is possible that these horses may be raced more often in claiming races to maximize their career earnings. They may represent lower quality horses with anatomic / physiologic characteristics that predispose them to increased risk of injury.

By contrast, Bailey *et al.* found class of race or stakes not to be a significant risk factor for CMI³.

2.1.7 Position on track where catastrophic musculoskeletal injury occurs

The typical outlay of a North American racetrack is illustrated in Appendix B. A study conducted in Kentucky by Peloso *et al.* gave an indication of where on the track specific injuries were more likely to occur²⁴. The proportion of horses with injuries of the diaphysis of MC3 was significantly greater among injuries that developed in the backstretch and club house turn than that of horses injured at other locations on the track. Injuries to the PSB were significantly more common in the stretch turn than at other locations on the track. Injury of the third metacarpal condyle was significantly more likely to be detected after the race than at other locations on track.

The proportion of horses injured on the backstretch and stretch turn in the catastrophic group (55/86, 64%) was significantly greater than that in the career ending group (20/50, 40%)²⁵. In a further study conducted in Kentucky by Cohen *et al.* the location where an injury was sustained on the racetrack was determined for 210 horses⁷. Table 2.3 shows the findings of two studies in which the backstretch turn and stretch turn showed a higher incidence of injuries for those horses suffering a CMI only.

Table 2.3: Percentage of occurrence of catastrophic musculoskeletal injuries relative to the different position on the racetrack.

Study	Ref	Backstretch/ clubhouse turn	Stretch turn	Stretch	After the wire
Kentucky 1Mar 1994 – 28Feb 1996	7	(30CMI/210*) 56.6%	(29CMI/210*) 60.4%	(20CMI/210*) 42.6%	(13CMI/210*) 21%
Kentucky 1Jan 1992 – 31May 1993	24	(18/51) 35.9%	(12/51) 23.5%	-	-

Ref = reference number 210* represents all injuries and not only CMI

2.1.8 Pre-race inspection

An increasing amount of evidence suggests that pre-existing pathologic conditions may play a role in the development of racing injuries in horses²⁵. A screening programme to detect pre-existing pathologic conditions could prevent the development of injuries during racing²⁵.

Pre-race inspection at the Kentucky tracks consists of^{7,8}:

- positive identification of the horse
- assessment of general physical condition
- palpation of distal portion of limbs
- inspection of horses the morning of the race (if stabled at the track)
OR inspection of horses on arrival (if transported to the track)
- inspection of selected horses (at the discretion of the veterinarian) whilst being jogged in the pre-parade (shed) area
- observation of all horses on the racing surface during the pre-race warm-up
- assessment of previous race history
- inspection of previous pre-race inspection results (using a standardised code, including summary assessment score of risk of MSI)

Summary assessment score was the Kentucky Racing Commission (KRC) official veterinarian's overall clinical impression of whether a horse was at increased risk of injury. Horses were considered to be at increased risk of injury on the basis of any of the following criteria: observation of marked changes (increase by > 2 units of severity score) from previous inspection (0 = marked changes not observed since the

last physical examination; or 4 = marked changes observed since the last physical examination); results of examination of KRC veterinary database records for a specific anatomic structure; clinical experience with a particular horse (*i.e.* history of a KRC official veterinary event in the horse's record); or identification during pre-race physical inspection of a specific anatomic structure that had substantial palpable abnormalities, including swelling, joint capsule hypertrophy, decreased range of joint motion, sensitivity to digital pressure, and heat (Scale of 0 to 5: 0 = normal, 1 = mild swelling or joint effusion, 2 = moderate swelling or joint effusion, 3 = severe swelling or joint effusion, 4 = severe swelling or joint effusion in combination with decreased range of joint motion, and 5 = classified as severity score of 1 to 4 in combination with signs of pain elicited during palpation or flexion)⁷. Any horse that does not meet the criteria for racing fitness at any stage of the inspection process is not permitted to race⁸.

Although the assessment of increased risk of injury or findings of abnormalities of the IOM detected pre-race lacked the sensitivity / specificity needed to be useful as a single test to identify horses that will sustain injuries, these findings were considered important risk factors for injury⁸.

Results of pre-race inspection were significantly associated with musculoskeletal injuries (including CMI) in studies conducted in Kentucky^{7,8,25}. The odds of a musculoskeletal injury, injury of the suspensory apparatus of the forelimb and injury to the superficial digital flexor tendon (SDFT) of the forelimb were 5.5 to 13.5 times greater among horses assessed to be at risk of injury on the basis of the results of the pre-race inspection. Odds of an abnormal finding in the IOM during pre-race inspection were 3.4 times greater among horses that injured the suspensory apparatus than among control horses. Injury to the suspensory apparatus of the frontlimb was defined as any injury involving the IOM, proximal sesamoid bones or distal sesamoid ligaments. Odds of an abnormal finding in the SDFT during pre-race inspection were 15 times greater among horses that had injured the tendon than among control horses. These studies therefore highlight the value of pro-active pre-racing inspections, which could potentially lead to reduced rates of CMI during racing.



2.1.9 Limb predilection

The forelimb MSI was most predominant^{7,12,16,18,24,37}. Most of the studies showed greater than 80% involvement of the forelimb and authors suggested that the forelimbs are more prone to injury due to greater relative forces at higher speeds^{7,16,18,24,37}. Williams' *et al.* study showed that injuries to the front legs were 4 or 5 times more common than injuries to the hind legs³⁷. The left forelimb was predominantly affected in most studies except in one study conducted in Kentucky during the 1992-1993 racing period²⁴. Simultaneous front and hind limb injuries were not common (<0.5%). Table 1.4 shows reported study results for predilection of limb involvement.

Table 2.4: Reported percentage of musculoskeletal injuries indicating predilection of limb involvement in different international locations.

Location	Study period	Ref	% FL involvement All injuries	% LF of CMI	% RF of CMI	Total % simultaneous front and hind limb injuries
UK	1996-1998	37	81 (all types of limb injuries)	-	-	<0.5
Transvaal (currently Gauteng)	1988-1993	18	90.2 (representing CMI cases only)	50.98	37.26	1.96
California	1992	11		35.89	30.77	
California	20Feb 1990- 1Mar 1992	16	90 (any fracture sustained by the forelimbs during TB racing)	57 (pertains to all injuries sustained by racing TB)	42 (pertains to all injuries sustained by racing TB)	-
Kentucky	1Jan 1992 – 31May 1993	24	90.2 (all MSI)	36.8 (all MSI)	45 (all MSI)	-
Kentucky	1Mar 1994 – 28Feb 1996	7	94.4 (all MSI)	22	16	-

Ref = reference number FL = forelimb LF = left forelimb RF = right forelimb
CMI = catastrophic musculoskeletal injury TB = Thoroughbred
MSI = musculoskeletal injury

Peloso *et al.* showed that, of the injuries involving the forelimbs, 81.8% occurred unilaterally²⁴. Right forelimb injuries were significantly more common near or after the finish. Left forelimb injuries were significantly more common on the stretch turn (final turn before final straight to finish line. (See Appendix B). This may have been attributable to increased load on the lead limb at the gallop. When racing counter-clockwise (most USA racetracks and some UK tracks) horses are usually on the left lead in the turns and on the right lead during the straight²⁴.

2.1.10 Specific location of injuries

The majority of all racing injuries were located in the metacarpal and the MCP region: 73%¹¹, 93.5%¹⁸, 85.8%²⁴, 90.4%²⁵.

In a study pertaining to flat racing injuries in Britain, the most common limb injury involved the flexor tendons or the IOM (25.37%), followed by the MCP / PSB (11.46%) and then the carpal area (8.29%)³⁷. British flat racing places greater emphasis on racing over longer distances (>2.41kilometres / 1.5 miles) than in North America. This may contribute to the preponderance of injuries to the SDFT³⁷. These structures are at the greatest risk of being damaged when the horses become fatigued, especially if pre-existing pathology exists³⁷. Increased age was also

associated with an increased risk of tendon / IOM injuries. Racing on the flat was associated with much lower age-specific rates of tendon / IOM injuries when compared to other race types (National Hunt (NH) races consisting of racing over hurdles (hurdling) and fences (steeplechasing / chasing / hunter chasing) or over hurdle courses when the hurdles have been removed (NH flat racing)³⁷. The incidence of tendon / IOM injury steadily increased with increase in age with the majority of the injuries being recorded in the ≥ 5 year age group.

In a flat racing study in the UK it was shown that fractures of the proximal phalanx were more common on turf and fractures of the PSB were more common on all-weather tracks²³. Likelihood of sustaining a biaxial sesamoid fracture on AWT is 10 times that of turf flat racing. Proximal sesamoid / MCP and tendon / IOM injuries are two times more likely on AWT³⁷. These results suggest that factors associated with the way the hoof interacts with the ground during racing are crucial to understanding this particular type of fracture. Deceleration on sand and dirt courses has been shown to be less than that on turf courses. Thus, when impacting on a non-turf track, the hoof slides further before stopping, increasing the degree of MCP extension as that leg becomes the predominant weight-bearing limb, and placing greater strain on the suspensory apparatus²³. One excessive hyperextension may be sufficient to produce an acute failure of the sesamoid bone. Alternatively, the repeated higher strain may cause cumulative damage to the suspensory apparatus, and make the proximal sesamoid bones more susceptible to failure²³.

The study conducted in California in 1991 showed that multiple sites were affected in 27% of the horses that incurred a CMI while racing¹². The PSB and MC3 were the most common racing and training injuries, and these injuries occurred more often in the LF while racing. Ligament ruptures unaccompanied by skeletal injury accounted for 16% of the CMI during racing. The distal sesamoidean ligaments (DSL) (54%) and the IOM (31%) were most commonly involved. The DSL most commonly rupture near their origin or insertion. In an earlier study it was found that the PSB commonly fractures in actively training horses, whereas in rested horses the IOM was more likely to fail.⁶

In a second study performed in 1992 in California, they found the MC3 and PSB to be the most common sites of primary injury with multiple sites injured in 42% of the

cases¹¹. Injuries to the RF more commonly involved carpal fractures (8%) and ligament ruptures (6%). The LF injuries more commonly involved the PSB (21%). Overall injury to the limb distal to the carpus in 73% horses was similar in right and left forelimbs.

Osteochondral chip fractures of the carpus are common in racehorses. The most common location of chip fragmentation is the distal-dorsal radial carpal bone¹⁹. This is followed by the proximal dorsal intermediate and disto dorsal-lateral radial aspect of the radius. Fractures are significantly more frequent in the right carpus of Thoroughbreds. Significantly more fractures occur in the right middle carpal joint compared with the left middle carpal joint, but no significant differences occur between the left and right antebrachiocarpal joints¹⁹. Chip fractures are generally a secondary complication affecting joint margins altered by degenerative joint disease. Chip fractures of the dorsal joint margin have been proposed to arise from at least two different processes. Firstly, they can arise from fragmentation of the original tissue of the joint margin. This lesion starts as progressive subchondral bone sclerosis induced by the repetitive trauma of training and racing, with eventual damage of articular cartilage because of noncompliant subchondral bone. Eventually the sclerotic bone undergoes ischaemic necrosis. Secondly, fragments can arise within the base of periarticular osteophytes that form during degenerative joint disease¹⁹.

Slab fractures refer to fractures through an entire carpal or tarsal bone (the proximal joint surface to the distal joint surface). They may occur in a frontal or a sagittal plane, most commonly in the third carpal bone. The radial, intermediate, and fourth carpal bones are less commonly affected. The radial facet is the most common location for frontal slab fractures of the third carpal bone and is also the usual location for sagittal slab fractures. The incidence in this location is related to the hinge-like function in the middle carpal joint, which causes the radial carpal bone to impact the radial facet of the third carpal bone during loading of the limb in the close-packed extended position. It has been suggested that the medial location of the radial facet exposes it to larger forces during exercise and that the intermediate facet is protected by expansion of the articulation between the third and the fourth carpal bones when the intermediate carpal bone is loaded against the distal row of carpal bones¹⁹.

Two independent studies showed that the majority of distal metacarpal condylar fractures occurred on the lateral aspect compared with those occurring on the medial aspect^{16,23}. Fractures of the third metacarpal or metatarsal condyles occur almost exclusively in racehorses whilst the horse is exercising at high speed and are rarely attributed to a specific incident. These fractures are more common in Thoroughbreds than other racing breeds, and the fracture predominantly involves the lateral condyle of the left forelimb. A previous study has shown that significant variations in bone density exist between different regions of the distal condyles of MC3 and metatarsus III (MT3).³⁰ It is hypothesised that these differences in bone density results in stress concentration at the palmar / plantar aspect of the condylar grooves, which may predispose to fracture. It is suggested that condylar fractures in horses are pathologic fatigue or stress fractures that arise from a pre-existing, branching array of cracks in the condylar groove of the distal end of MC3 or MT3²⁸. It is theorized that the high incidence of this fracture results from unbalanced loading of the left forelimb that peaks during counter-clockwise turns. However an unbalanced step can result in a concentration of force on one of the condyles, causing acute failure of the bone³⁴.

2.1.11 Age

In studies conducted in six different areas, including Kentucky^{7,8,9,24}, California^{11,12,16}, South Africa¹⁸, Melbourne³, Sydney² and in Britain^{20,23,27,37}, it was generally concluded that an increase in age was associated with an increased risk of injury. The Californian study indicated that 4-year-old TB horses were approximately 2 times more likely to be injured than 3-year-old TBs¹². Two-year-old TBs were not at a greater risk, compared with that of other age groups. The study conducted in South Africa found that the incidence of breakdowns in 2-year-old TBs was significantly lower than that for more mature horses (≥ 3 -year old TBs)¹⁸. The Australian studies identified that 4- to 5- year-old TB horses were 1.5 times more likely to suffer injury compared to 2- to 3-year-old TBs³. Horses older than 6 years of age were two times more likely to suffer injuries compared to 2- to 3-year-old TBs³. The accumulation of repetitive micro trauma from a long racing career would be expected to place older horses at greater risk of injury^{2,3}.

Johnson *et al.* found that the 2-year-old TBs sustained more injuries during training than when being raced. Two-year-olds (TB and Quarter Horses (QH)) had the highest number of non-exercise related injuries which probably reflects the stress of change in environment for 2-year-old horses when they begin training at a racetrack¹⁶.

In contrast, 3 studies conducted in Florida¹³, New York²¹ and Kentucky⁸ showed no significant association of age with risk of CMI in TBs.

Two studies conducted in Kentucky categorized TB horses into two age groups *i.e.* those younger than 5 years of age and those 5 years of age and older^{7,8}. Proportion of starts made by 5 years of age and older in a high risk group (risk determined by a pre-race inspection discussed in 2.1.8) was significantly higher than that of horses making race starts in a low risk group. This indicated that age might be a potential confounder when analyzing the association of injury with a horse being classified in the high risk group^{7,8}.

The study conducted in California on TBs determined that sustaining only a ligamentous rupture while racing was significantly associated with increased age¹². The 13 TB horses which sustained only ligamentous injuries were older than the 66 horses that had a skeletal fracture (with or without soft tissue injury.) Median age of TB horses sustaining a tendinous / ligamentous injury alone was 5 years (range 3-7 years)¹². Median age of TB horses sustaining a skeletal fracture (with or without soft tissue injury) was 4 years (range 2-9 years). In a study performed a year later it showed that the influence of age on risk, depended on race type (maiden \leq US\$25 000, maiden $>$ US\$25 000, claiming $<$ US\$10 000, claiming US\$10 000 - US\$25 000, claiming $>$ US\$25 000, allowance, stakes and handicap (See Appendix A))¹¹. Risk of injury for TB horses 2- to 5-years of age was two times greater for claiming horses than for maiden horses. A study conducted on mainland Britain also showed that an increase in age was associated positively with flexor tendon and IOM injuries in all race types (flat racing and National Hunt racing)³⁷. Racing on the flat was associated with much lower age-specific rates of tendon / IOM injuries³⁷.

2.1.12 Gender

The male horse was shown to be significantly associated with increased risk of CMI in four studies. The study in South Africa showed that 75.5% of breakdowns occurred in male TBs and 24.5% in females TBs out of 70 753 starts¹⁸. Californian studies showed that age and sex distributions of the race entrants were not independent and varied among race meets^{11,12}. The studies showed that the risk of racing CMI in male horses was about two-fold that in female horses, and in 4-year-old TBs was two-fold that in 3-year-olds.^{11,12} (female race entrants were younger than male entrants). A study performed in Florida associated geldings with a higher risk of injury¹³. Because of their potential for breeding or sale purposes, fillies, mares, and colts are likely to run less frequently or be retired from racing sooner than are geldings^{11,12}.

Conversely, another study conducted in Kentucky found that the male sex was not significantly associated with risk of injury⁸. Sex was not identified as risk factor for CMI in this study. In this study geldings and colts were grouped together and classified as males. The association of injury with sex, may have been very small, and the study may have lacked sufficient power to detect small differences. The proportion of race starts made by males in which an injury was incurred was 25 of 2110 (1.2%), compared with 11 of 1117 (1.0%) for race starts made by female. The conditions of a race often result in horses being matched closely for age and sex, which may explain why age and male sex, previously described as risk factors for injury were not observed as consistent risk factors by the Kentucky study⁸.

2.1.13 Race interval (number of starts per year)

Number of days since last raced was associated with risk of injury^{7,13,24}. A positive association with CMI was found when an interval of greater than 60 days had elapsed between the race in which horse was injured and previous race date⁷. In another study, horses raced greater than 33 days previously, were 2.5 times more likely to sustain a CMI during racing as were horses that raced less than 13 days before¹³.

The number of days since the last race may serve as a useful indicator of previous health and lameness problems. Horses that had a pre-existing injury particularly in the SDFT of the forelimb had an extended interval between races because of the injury⁷. It has been hypothesized that horses that return to training or racing after an extended period of reduced exercise may have insufficient bone mass to prevent micro-damage with exercise; stress fractures may develop as result of continued repetitive loading¹³.

A 3-4 week interval between races has been recommended to decrease the occurrence of injury by diluting physical demands²⁴. However, inter-race interval is likely to be just one of the several factors involved in sustaining a CMI. Peloso *et al.* found that the number of days between previous races was not significantly different than between the last race and the race during which the injury occurred²⁴.

2.1.14 Number of seasons raced

A negative association between number of seasons raced and risk of breakdown was found in the study conducted in New York²¹ *i.e.*: 36% of horses broke down in their 1st season. (2 times decreased risk of breakdown); 34% of horses broke down in their 2nd season (3 times decreased risk of breakdown); 5% of horses broke down after the 4th season (4 times decreased risk of breakdown); and 0% of horses broke down in their 5th season (100 times decreased risk of breakdown compared to horses in their first season). This may indicate that initially the horse has to adapt to not only a stressful new environment in which it is expected to live and work, but also that its body, particularly the limbs have to adapt to the repetitive stresses to which they are exposed to on a daily basis, for example dorsal metacarpal disease.

2.1.15 Number of starts per racing season

Few studies have reported on the number of starts per racing season being a risk factor for CMI. One study conducted in New York by Mohammed *et al.* found a negative association between risk of breakdown and number of starts per season, attributing it to healthier horses being more likely to race often during a season²¹. Horses which raced 7 - 12 times per year were three times less likely to breakdown compared to horses which raced ≤ 6 times per year²¹.

2.1.16 Time of race

Bizarrely, Mohammed *et al.* also reported that horses entered in races earlier in the day (< race 6) were at increased risk of breakdown²¹. This observation was probably confounded by class of race or distance²¹. A possible other explanation is that horses in later races generally are of better quality and are raced more selectively, and feature races usually occur later in the day.

2.1.17 Position in bunch

Peloso *et al.* study in Kentucky found that a significantly greater number of horses with racing injuries were positioned in the fourth (last) quartile of the group of horses competing in the race (field) and in the third and fourth quartiles (last half) of the field at a point 402m (one quarter of a mile) from the start (first quarter fraction)²⁴. Pathologic conditions present prior to the race may have caused the horses to settle to the back of the field early in the race²⁴. Horses with a high pre-race physical examination score (4) (see 2.1.8), injured flexor tendons or suspensory apparatus, and which were in the last 25% of the racing pack at the first quarter mark, were significantly more likely to be injured (catastrophic or career ending)²⁶

2.1.18 Barrier position

Horses closest to the rail were nearly half as likely to suffer a MSI as those starting in outer two thirds of the track². This may be due to the extra effort and competition encountered by these horses attempting to move to the inner rail from a greater distance. In addition, the banking of the track on the outer circumference may also play a role in the increased breakdown rate².

2.1.19 Change in distance

Various outcomes have been found with change in race distance between the race in which the horse was injured and the previous race. An increase in race distance between the race in which the horse was injured and the previous race was

associated with a decreased risk of injury for the suspensory apparatus⁷. A possible explanation given for this was that a horse with a pre-existing condition might have been entered in a race of lesser distance⁷.

Bailey *et al.* showed that horses running at a greater or decreased distance were at less than half the risk of injury than those running at the same distance as the previous race². A proportion of horses that were included as racing at an increased distance were running in their first race, and if these horses were removed from the analysis the significance associated with increased distance was reduced. A further study conducted by Bailey *et al.* found change in race distance not to be a significant risk factor for CMI³. The reason for this was stated to be unknown.

2.1.20 Racetrack

Cohen *et al.* found the specific racetrack to be significantly associated with injury⁸. Three racetracks in Kentucky were significantly more likely to have injuries than others. Coincidentally all the horses with suspensory apparatus injury of the forelimb had acquired the insult at those racetracks with the highest odds ratio for injury. In this study, differences in risk among racetracks did not appear to be attributable either to: track surface conditions, season, meet, class of race, or distance of race. There were significant differences among the racetracks with regard to odds of injury, even after adjusting for the effects of age and sex..

A North American study found one of the New York tracks, Seratoga to be associated with a lower risk of breakdown *i.e.* eleven fold decrease in risk when compared to Aquaduct Main²¹. This may not have been due to the track directly but to other factors associated with the track. It may also have been attributed to a selective population of horses.

The Australian study showed that horses running at Flemington were twice at risk of injury compared to Moonee Valley³. This was surprising because Moonee Valley is a smaller course with tighter turns. It was speculated that it may have been due to different track designs or structural features, such as, the number and positions of “crossings” that may have represented areas of increased soil compaction³.

Several studies indicated the need for further evaluation to establish the reasons for differences amongst racetracks in risk of injury^{3,8}.

Other studies conducted in different parts of the world found that the different racetracks showed no significant differences in proportion of injuries reported
14,18,20,25,38

Studies have not been performed in South Africa to determine whether or not specific tracks are associated with an increased incidence of CMI.

2.1.9 Cumulative high speed exercise pre-race

In Kentucky, injured horses had significantly less cumulative high-speed exercise than did control horses during the one to two month period prior to the race in which the injury occurred⁹. High speed exercise referred only to officially timed workouts and races. Decreased cumulative high speed exercise among injured horses may have been attributable to pre-existing conditions or lesions that limited the horse's ability to perform high speed exercise or efforts of trainers to restrict the frequency of high speed exercise.

Chapter 3: Materials and methods

3.1 Study design

This study is an observational retrospective investigation of horses euthanized as a result of sustaining a CMI on a racetrack in Gauteng, during the period of 1998-2004. These horses were humanely euthanized at the track immediately after the race in which they sustained their CMI, and provide the case material for this study. The racing season in South Africa starts on the 1st August and ends on the 31st July of the following year. Strictly the Vaal Turf racetrack does not lie within the Gauteng boundaries, however due to its close proximity it was included in this study.

3.2 Experimental design

3.2.1 Case Selection

By definition, only horses that sustained severe musculoskeletal injuries that were examined by an appointed official racetrack veterinarian and that necessitated immediate euthanasia on a racetrack in Gauteng during the racing period 1998-2004 form the case material for this study.

The affected limb from each horse was then amputated just proximal to the carpus or tarsus and transported to the Equine Research Centre (ERC), Onderstepoort. The limbs were identified in such a manner that they were traceable. The limbs were frozen and stored at the ERC, Onderstepoort.

According to the National Horse Racing Authorities (NHRA) database a total number of 55 CMI occurred during the six year period of 1998-2004 which fitted the true definition of a CMI (NHRA, P.O. Box 74439, Turfontein, 2140, South Africa). Prior to conducting the study it was presumed that all the affected limbs of all horses euthanized as a result of a CMI during this period had been collected for further investigation. However, once the study had commenced it was realized that only those CMI limbs which were assumed to be attributed to the suspensory apparatus

or due to fetlock pathology by the track veterinarian on duty at the time of the incident had been collected for further investigation and stored at the ERC, Onderstepoort, thereby precluding the inclusion of horses that were euthanized a.r.o. injuries that were sustained further proximally. A total of 32 limbs from 32 horses that had sustained a CMI were thus available for further investigation. Of these 32 limbs only 23 were identifiable. Nine limbs remained unidentifiable. The primary investigator was unable to determine whether the 9 unidentifiable limbs met the inclusion criteria *i.e.* whether they fell within the prescribed racing period and whether the injuries were sustained on one of the Gauteng racetracks.

The post mortal study was thus conducted with the limbs being allocated to one of two groups, namely:

- Group 1 consisted of 22 identifiable limbs from 22 horses that had sustained a CMI. Twenty of the identifiable limbs met the inclusion criteria. One identifiable limb (MHL2) was discarded from the study as the horse had sustained a CMI in 1996. Because of the small number of CMI an additional two identifiable limbs (EG and 2HL) were included in the study. They strictly did not fit into the study as the CMI had occurred in the earlier part of 1998 (prior to 1 August) but were considered to be of relevance as they occurred within 6 months of the 1998 racing period.
- Group 2 consisted of the total 32 limbs from 32 horses that had sustained a CMI and that were dissected. Due to the small number of identifiable limbs and overall number of CMI the primary investigator did not discard the information pertaining to these limbs, as valuable anatomical information could be gained from the injuries sustained.

The identification and relevant race history of each of the 22 horses that suffered a CMI was obtained from the NHRA database. Other information such as name, gender, date of birth, number of previous starts, age at first start, number of seasons raced, racing interval, career wins, date of CMI, name of racetrack, surface type, surface condition, class of race, race distance, race direction, gate position, jockey, jockey weight, and trainer was also collated and assessed in each case (Appendix C. Some of the information has been omitted due to confidentiality reasons imposed by the NHRA). Additional information included: limb affected, structure affected,

relevant pre-race and race history immediately prior to crisis, location on track where injury occurred, raced around a bend / straight, and injury details.

3.2.2 Inclusion criteria

To be included in this study, horses must have:

- sustained a CMI whilst racing
- been euthanized at the track shortly after sustaining a CMI
- raced at one of the four racetracks in Gauteng, namely Turfontein, Gosforth Park, Newmarket and Vaal Turf racetracks.
- sustained a CMI during the period of 1998-2004 (excluding the cases mentioned in 3.2.1).

3.3 Experimental procedures

3.3.1 Radiographic procedure

A stationary Siemens X-Ray unit was used for all radiographs (Siemens, Private bag X071, Halfway House, 1685, South Africa). This machine's output is capable of 800mA, 150kV and 0.1 to 10 second settings. Fuji medical x-ray film (HR-GB), 24 x30 cm Trimax-3M cassettes with T6 Rarex green light emitting screens (300ASA) were used (Axim, P.O. Box X169, Halfway House, 1685, South Africa). Four standard views (lateromedial, dorsopalmar, dorsolatero-palmaromedial, and dorsomedial-palmarolateral oblique views) were taken at preset optimum settings for each forelimb. The radiographic beam was centred on the specific area described by the Jockey Club veterinarian as being the suspected primary site of injury or palpable / visible area of pathology e.g. MCP if distal condylar fractures or proximal sesamoid bone fractures were suspected. The constant source to image distance was kept at 90cm. The film was developed by an automatic processor in the Section Diagnostic Imaging, Department Companion Animal Clinical Studies, Faculty of Veterinary Science, University of Pretoria, Onderstepoort.

A complete radiographic description of each fracture was reported: fractures were classified as open vs closed, displaced vs non-displaced and articular vs non-articular; according to bone(s) affected, and fractures of the third metacarpus were

further classified by site of fracture within the bone; lateral and medial condylar fractures were further defined as fractures that included a fracture line within the lateral (lat) / medial (med) condyle, respectively, of the distal articular surface; and fractures of the PSB were identified as lateral or medial, and classified according to the different types of PSB fractures namely: basilar, body, apical, abaxial, axial, and comminuted. (Appendix E)

3.3.2 Ultrasonographic examination

Each limb was prepared for ultrasonographic evaluation by shaving the palmar surface of the limb from just distal to the carpus to just proximal to the coronary band and abaxially to include the branches of the IOM. An Aloka (4000) ultrasound machine with a 7.5MHz multifrequency linear array transducer was used to scan each limb in longitudinal and transverse planes (Axim, P.O. Box X169, Halfway House, 1685, South Africa). The idea was to use ultrasonography to help to identify precise location, extent, size of lesions, fibre alignment and echogenicity (Appendix F). Ultrasonographic images were difficult to obtain in certain instances as a result of the following factors:

- Life-like weight-bearing of the amputated limb was not attained therefore leading to poor definition of linearity and echogenicity of the tendon fibres.
- Severe gas penetration through open wounds or distal dissection from amputation site
- Poor contact of probe as a result of severe deformity of the distal limb caused by injuries.

This led to the investigator performing less extensive ultrasonographic examinations and concentrating on the areas where images could be acquired. Where possible each flexor region was evaluated in its entirety and linearity, echogenicity, size and extent of lesion was evaluated.

3.3.3 Magnetic resonance imaging (MRI)

Further diagnostics using MRI at Montana Hospital, Pretoria anticipated in preparation for the study, was not required as a diagnosis was made using the previous diagnostic imaging modalities.

3.3.4 Dissection

Each limb was carefully dissected to determine the extent of articular and soft tissue involvement in particular the digital flexor tendons, distal sesamoidean ligaments, collateral ligaments, annular ligament, *manicum flexorum* and *scutum proximale*.

3.3.5 Deoxyribonucleicacid (DNA) analysis

DNA analysis was attempted to identify nine unidentified limbs. The unidentifiable limbs had been labelled during storage as MHL1, MHL2, MHL2/2, MHL3, MHL4, MHL5, MHL6, MHL8, and 2HL. The letters used to identify the limbs had no other meaning other than arbitrary labelling. The DNA was able to obtain profiles from all the tissue samples provided. However these profiles did not match any of the samples in the database of Thoroughbred horses already tested by the Veterinary Genetics Laboratory, Onderstepoort. The laboratory was also not able to identify any parents of these profiles using the statistical program (Cervus) to find the most likely stallion and mare for which profiles were available on the database. Thus the DNA was unsuccessful in identifying any of the limbs. One of the reasons for the disappointing results may have been that in the past, parentage in South Africa was ascertained using blood typing and that DNA analysis was only introduced with the 2001 foal crop, thereafter providing a database representing only those foals, including their respective parents, born from 2001 onwards. DNA from all Thoroughbreds imported into South Africa from 2001 was also added to this database.

3.3.6 Racing Data

Data were obtained from the NHRA pertaining to:

- Total number of starts for each racetrack in Gauteng per racing season during the racing period 1998-2004.
- Number of CMI for each racetrack per racing season for the racing period 1998 – 2004.
- Complete racing history for each of the 55 horses having sustained a CMI during the period 1998-2004 (Appendix D).
- Total number of runners (field) in each race in which a CMI occurred during the racing period 1998-2004.

- Complete racing history of every horse that participated in a race during the racing period 1998-2004 on the Gauteng racetracks.

Due to confidentiality constraints relevant racing data from the NHRA data base were forwarded electronically to Prof Peter Thompson, Faculty of Veterinary Science, University of Pretoria, Onderstepoort, for statistical analysis. All data were managed confidentially. The primary author did not have direct access to the NHRA data base.

The data were compared descriptively with that of other studies performed in other parts of the world.

3.3.7 Statistical analysis

Potential risk factors for catastrophic musculoskeletal injuries during racing that were studied were the following:

Horse factors

- Age was categorised into four groups i.e. < 3 years of age; between 3 - 4 years of age; between 4 - 5 years of age; and greater than 5 years of age. Calendar age, *i.e.* subtracting each horse's actual birth date from the date of the start was used in this study.
- Gender was divided into 3 groups namely: mares / fillies, colts / stallions, and geldings.
- Racing interval was defined as the period between the last race run by the horse and the current race. The racing interval was divided into 3 categories, namely: interval less than 1 week, interval between one and three weeks, and interval greater than 3 weeks.

Race and track factors

- Racetrack (four categories).
- Racetrack condition: The going was initially divided into 5 categories namely hard, firm, good, soft and yielding. No incidents of CMI were recorded in the hard or yielding categories. These two categories were thus merged with the firm and soft categories respectively.
- Race distance (continuous variable).

- Draw (gate position) was divided into three categories, i.e. draw 1-5, draw 6-10, and draw > 10.
- Size of the field was divided into three categories, *i.e.* less than 10 horses in race, 10-14 horses in a race, and more than 14 horses in a race.
- Weight carried by horse was divided into three categories, *i.e.* those horses carrying less than 54kg, those horses carrying 54-59kg, and those horses carrying greater than 59kg.
- Racing year (seven categories).

The collective incidence pertaining to all four tracks represented in Gauteng was calculated for each racing year. Incidence = (number CMI x 1000) / number of starts. Incidence of CMI / 1000 starts was therefore calculated for each of the above categories. Because the data represented a complete record for the four tracks during the period and not a sample from a wider population (*i.e.* it was census data) confidence intervals (CIs) were not calculated. Univariable screening was done for categorical risk factors using Fisher's exact test and for continuous risk factors using simple logistic regression. A P value ≤ 0.25 was used as criterion for entry of a variable into the multiple logistic regression model. A mixed-effects multiple logistic regression model was then developed to adjust for confounding. Race was modelled as a random effect to account for clustering of starts within races. P values of < 0.05 were regarded as significant.

All statistical analyses were performed using Stata 10.1 statistical software (Statacorp, College Station, Texas, USA).

Chapter 4: Results

4.1 Study population

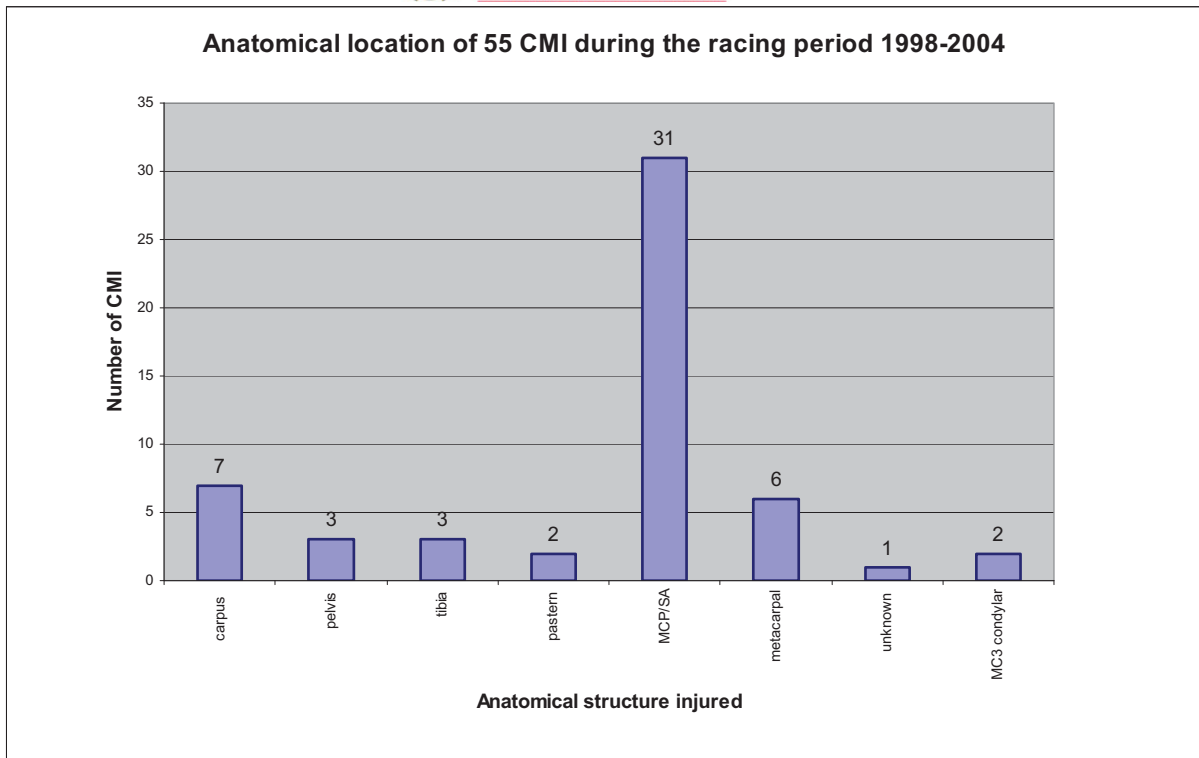
A total number of fifty five CMI occurred over the six year period from 1998-2004 on Gauteng's racetracks as recorded by the NHRA. Thirty two forelimbs that had sustained a CMI to the distal forelimb, assumed to be attributed to the suspensory apparatus by the official track veterinarian on duty at the time of the incidents, were removed after each horse was humanely euthanized, and the limbs sent for storage at the ERC, Onderstepoort until further investigations were performed. Only 22 of the total of 32 cases were identifiable and were known to have sustained the CMI at one of the Gauteng racetracks within the study period. These 22 forelimbs were assigned to Group 1 for further detailed studies including statistical analyses. The total number of 32 forelimbs were assigned to Group 2 on which detailed anatomical studies were performed. (See 3.2.1)

4.2 Anatomical study of catastrophic musculoskeletal injuries

Data was acquired after performing detailed radiographic (Appendix E), ultrasonographic (Appendix F), and dissection studies of the injured limbs.

4.2.1 Anatomical location of catastrophic musculoskeletal injuries during the 1998-2004 racing period

NHRA records showed that the most common location for the CMI was the suspensory apparatus and fetlock region and was represented by 56.36% of the cases. Condylar metacarpal or metatarsal fractures were excluded from this category. The second most common location for CMI was represented equally by the carpal and metacarpal region and was respectively represented by 12.72% of the cases. Fractures affecting the pelvis and tibia were equally represented by 5.45% of the cases. The pastern and MC3 condylar fractures were equally represented by 3.64%. Fig. 4.1 shows the distribution of CMI according to the anatomical location where the injury occurred.



SA = suspensory apparatus CMI = catastrophic musculoskeletal injuries
 MCP = metacarpophalangeal joint MC3 = metacarpus 3

Fig. 4.1: Bar chart depicting the anatomical location of the 55 catastrophic musculoskeletal injuries during the racing period 1998-2004.

4.2.2 Distribution of left versus right forelimb involvement.

In both study groups the CMI occurred unilaterally. In Group 1, seventeen of the twenty two cases of CMI occurred in the left forelimb (77.27%). Only five cases were represented by the right forelimb (22.73%). In Group 2, the proportion of left forelimb involvement in the study of 32 limbs dissected was 71.87%, compared to 28.13% involving the right forelimb.

4.2.3 Classification and distribution of fractures

4.2.3.1 Open versus closed fractures

In both study groups the majority of the fractures were closed (72.72% and 65.63% for Group 1 and Group 2, respectively) and the closed fractures predominantly involved the left forelimb (54.54% and 46.88%, respectively). A total number of 6 forelimbs (27.27%) sustained open fractures in Group 1 vs 11 forelimbs (34.38%) in Group 2. In both groups the left forelimb was predominantly affected in both the open and closed fractures.

4.2.3.2 Condylar fractures

In the CMI Group 1, only 2 cases of MC3 condylar fracture occurred, both of which involved the lateral condyle. The lateral condylar fractures exited approximately 8cm proximally on the lateral cortex of the metacarpus. A left and a right forelimb were represented. Both were open fractures and both were accompanied by a medial proximal sesamoid bone fracture, and flexor tendon pathology involving the SDFT, DDFT and branches of the IOM.

In the CMI Group 2, three condylar fractures occurred, with the lateral condyle being involved twice. Two right forelimbs (a medial and a lateral condylar fracture) and a single left forelimb (lateral condylar fracture) was represented. All three of the fractures were open, with two of the cases (LF and RF) accompanied with flexor tendon pathology involving the SDFT, DDFT and branches of the IOM. The one right forelimb showed no SDFT pathology but did show pathology of the DDFT and a branch of the IOM. The two cases that had sustained a lateral condylar fracture showed signs of desmitis of the medial branch of the IOM. Fractures of the medial proximal sesamoid bones accompanied the lateral condylar fracture, whereas a fracture of the lateral proximal sesamoid bone accompanied the medial condylar fracture.

4.2.3.3 Luxation and subluxation of the metacarpophalangeal joint

In CMI Group 1, the metacarpophalangeal joint was luxated in only one of the 22 CMI cases and involved the right forelimb. The luxation was complete and open with both collateral ligaments ruptured. In CMI Group 2, the metacarpophalangeal joint was

completely luxated with both the collateral ligaments ruptured in three of the four cases reported. The fifth case represented a subluxation of the metacarpophalangeal joint with both collateral ligaments remaining partially intact. The right forelimb was represented in 60% of the cases and the left forelimb was involved in 40% of the cases. All of the luxations and subluxations were accompanied by additional fractures of the PSBs.

4.2.3.4 Proximal sesamoid bone fractures

The following results pertaining to the proximal sesamoid bones were derived from both CMI Groups 1 and 2:

- PSB fractures represent the most common CMI injury and fracture type and was represented in all of the CMI cases except one case.
- The majority of the PSB fractures occurred in the LF
 - Group 1: 16 (72.73%) LF vs 5 (22.73%) RF
 - Group 2: 22 (68.75%) LF vs 9 (28.13%) RF
- Approximately 59% of the PSB fractures were biaxial in Group 1; whereas approximately 69% were biaxial in Group 2
 - Group 1: 13 biaxial(LF 11 (50.00%) : RF 2 (9.09%)) vs 8 uniaxial (LF 5 (22.73%) : RF 3 (13.64%))
 - Group 2: 22 biaxial(LF 17 (53.13%) : RF 5 (15.63%)) vs 10 uniaxial (LF 5 (15.63%) : RF 5 (15.63%))
- The medial PSB was most commonly fractured
 - Group 1: 19 (86.36%) med vs 16 (72.73%) lat (P=0.46)
 - Group 2: 28 (87.5%) med vs 25 (78.13%) lat (P=0.51)

Group 1: PSB fracture configuration and distribution

- The most common configuration of PSB fracture gap was a comminuted fracture represented in 18 (81.81%) cases (LF 12 (54.54%): RF 6 (27.27%)). The lateral PSB was most commonly comminuted (lat 10 (45.45%) : med 8 (36.36%))
- The second most common configuration of PSB fracture was a midbody transverse fracture represented in 16 (72.72%) forelimbs (LF 13 (59.09%) : RF 3 (13.64%))

- Apical fractures were represented in a total of 6 (27.27%) forelimbs (LF 4 (18.18%) : RF 2 (9.09%)).
- Basilar fractures were represented in a total of 5 (22.72%) forelimbs (LF 4 (18.18%) : RF 1 (4.55%))
- Abaxial fractures were represented in 2 (9.09%) forelimbs (LF 1 (4.55%) : RF 1 (4.55%))
- An axial fracture was represented in 1 left forelimb (4.55%).

Group 2: PSB fracture configuration and distribution

- The most common configuration of PSB fracture was the midbody fracture represented in 26 (81.2%) cases (LF 19 (59.38%) : RF 7 (21.88%)).
- The second most common configuration of PSB fracture was a comminuted fracture 22 (68.75%) forelimbs (LF 13 (40.63%) : RF 9 (28.13%). The lateral PSB was most commonly comminuted (lat 14 (43.75%) : med 11 (34.38%)).
- Basilar fractures were represented in a total of 8 (25%) forelimbs (LF 7 (21.88%) : RF 1 (3.13%)).
- Apical fractures were represented in a total of 5 (15.63%) forelimbs (LF 5 (15.63%) : RF 1 (3.13%))
- Abaxial fractures were represented in 3 (9.38%) forelimbs (LF 1 (3.13%) : RF 2 (6.25%))
- An axial fracture was represented in 1 (3.13%) left forelimb.

4.2.4 Tendon, ligament and cartilaginous damage associated catastrophic musculoskeletal injuries

Group 1: Tendon, ligament and cartilaginous damage

Detailed description of the various soft tissue pathology specific to each study group was as follows:

- Pathology pertaining to the interosseous medius muscle:
 - 95.45% (21/22) of the horses suffered IOM pathology, mainly affecting the branches and areas of insertion. The medial branch of the IOM was affected in 45.45% (10/22) of the cases compared to the lateral branch which was affected in 68.18% (15/22) of the cases. Concurrent medial and lateral branch pathology of the IOM was found in 18.18%

(4/22) of the cases. The branch injuries were often missed on ultrasound examination as the branches were severely stretched, frayed and then folded into the PSB fracture gap hiding them from view. Ultrasonography was a poor diagnostic tool in diagnosing these specific injuries in these amputated limbs.

- 13.64 % (3/22) of horses suffered complete rupture / severance of one or more branches of the IOM. Only 1 horse suffered a complete rupture of both branches of the IOM.
 - Damage to the body of the IOM was sustained in two cases (9.09%).
 - Avulsion of the IOM branch from the abaxial surface of the PSB was diagnosed in 2 cases (9.09%).
 - Only one case (4.54%) showed no evidence of IOM branch / body involvement (7HL)
 - 50.00% (11/22) of horses suffered concurrent SDFT, DDFT and IOM pathology.
- Pathology pertaining to the deep digital flexor tendon:
 - 86.36% (19/22) of the horses which had sustained a CMI had DDFT injuries in the region of the MCP.
 - 9/22 (40.90%) of the cases sustained tears to the medial aspect of the DDFT.
 - The majority of the lesions of the DDFT occurred on its dorsal surface 55.55% (12/22) cases in comparison to the palmar surface 9.09% (2/22).
 - Pathology pertaining to the superficial digital flexor tendon:
 - 55.55% (12/22) of the horses which had sustained a CMI had SDFT injuries in the region of the MCP.
 - 36.36% (8/22) of the cases sustained medial tears to the SDFT in the region of the PSB. These were mostly associated with concomitant medial tears in the DDFT (6/8).
 - The lesions on the SDFT occurred equally on the dorsal and palmar surface.
 - 55.55% (12/22) of the horses suffered concurrent SDFT and DDFT pathology.

- Only one case had sustained complete rupture of both the SDFT and DDFT. This same horse had suffered a uniaxial medial PSB fracture and the lateral branch of the IOM was severely stretched with the fibres shredded apart, yet still remained intact.

- Pathology pertaining to the distal sesamoidean ligaments:
 - 72.73% (16/22) of the distal sesamoidean ligaments sustained some degree of pathology.
 - The straight distal sesamoidean ligament was the most common ligament to be injured in 54.54% (12/22) of the cases. The oblique distal sesamoidean ligament was involved in 36.36% (8/22) of the cases.
 - Only one horse suffered no fractures and was euthanased as a result of complete distal sesamoidean ligament rupture (16/1 HL).

- Pathology pertaining to other ligaments and structures:
 - The annular ligament was damaged in 50.00% (11/22) of the cases.
 - The *manicum flexorum* was torn or damaged in 36.36% (8/22) of the cases.
 - The intersesamoidean (palmar) ligament was ruptured in 45.45% (10/22) of the cases.
 - The *scutum proximale* was ruptured in 68.18% (15/22) of the cases.
 - Both the collateral ligaments of the metacarpophalangeal joint were completely ruptured in one case. This same horse had sustained biaxial PSB fractures.
 - The cartilage of the majority of the metacarpophalangeal joints suffered significant cartilage damage (77.27%). Wear lines, cartilage erosions and articular margin osteochondral fragmentation were commonly seen. The other 22.73% of cases showed mild signs of cartilage damage.

Group 2: Tendon, ligament and cartilaginous damage

- Pathology pertaining to the interosseous medius muscle:
 - 93.75% (30/32) of the horses suffered IOM pathology, mainly affecting the branches and areas of insertion. The medial branch of the IOM was affected in 50.00% (16/32) of the cases compared to the lateral branch which was affected 75.00% (24/32) of the cases. Concurrent medial and lateral branch pathology of the IOM was found in 31.25% (10/32) of the cases.
 - 18.75% (6/32) of horses suffered from complete rupture of one or more branches of the IOM. Only 1 horse suffered a complete rupture of both branches of the IOM.
 - The branch injuries were often missed on ultrasound examination as the branches were severely stretched, frayed and then folded into the PSB fracture gap hiding them from view as in group 1. Ultrasonography was a poor diagnostic tool in diagnosing these specific injuries.
 - With the medial condylar fracture a severe strain of the lateral branch of the IOM occurred.
 - Damage to the body IOM was only sustained in three cases.
 - Avulsion of the IOM branch on the abaxial surface of the PSB was diagnosed in only 2 cases.
 - 56.25% (18/32) of horses suffered concurrent SDFT, DDFT and IOM pathology
 - Two cases showed no evidence of IOM branch / body involvement.

- Pathology pertaining to the deep digital flexor tendon:
 - 87.50% (28/32) of the horses which had sustained a CMI had concurrent DDFT injuries in the region of the MCP.
 - 43.75% (14/32) of the cases sustained tears to the medial aspect of the DDFT.
 - The majority of the lesions of the DDFT occurred on its dorsal surface: 40.63% (13/32) cases in comparison to the palmar surface 6.25% (2/32).

- Pathology pertaining to the superficial digital flexor tendon:
 - 59.37% (19/32) of the horses which had sustained a CMI also had concurrent SDFT injuries in the region of the MCP.

- 59.37% (19/32) of the horses suffered concurrent SDFT and DDFT pathology.
- 40.63% (13/32) of the cases sustained medial tears to the SDFT in the region of the PSB. These were also mostly associated with concomitant medial tears in the DDFT in 34.38% (11/13) of the cases.
- Only one case sustained a complete rupture of both the SDFT and DDFT. This same horse had suffered a uniaxial medial PSB fracture. The lateral branch of the IOM was severely stretched with the fibres shredded apart, yet it still remained intact.
- The lesions on the SDFT occurred more often on the dorsal than the palmar surface.

- Pathology pertaining to the distal sesamoidean ligaments
 - 78.13% (25/32) of the distal sesamoidean ligaments (straight and / or oblique) sustained some degree of pathology.

- Pathology pertaining to other ligaments and structures:
 - The annular ligament was damaged in 59.37% (19/32) of the cases.
 - The *manicum flexorum* was torn or damaged in 40.63% (13/32) of the cases.
 - 75% of the cases showed significant cartilage damage of the metacarpophalangeal joints. Wear lines, cartilage erosions and articular margin osteochondral fragmentation were commonly seen. The other 25% of cases showed mild signs of cartilage damage.
 - The intersesamoidean (palmar) ligament was ruptured in (56.25% (18/32) of the cases and the *scutum proximale* in 71.88% (23/32) of the cases.
 - Both the collateral ligaments of the metacarpophalangeal joint were completely ruptured in three cases of complete metacarpophalangeal luxation. All three of these horses also sustained biaxial PSB fractures. The collateral ligaments were partially intact in the one case represented by subluxation of the metacarpophalangeal joint.

4.3 Incidence of catastrophic musculoskeletal injuries

4.3.1 Number of starts

Data pertaining to the total number of starts per race season for all four Gauteng racetracks during the racing period 1998-2004 were obtained from the NHRA database (Table 4.1). Gosforth Park racecourse was closed down at the end of the 2001 racing period and therefore no starts were recorded during the racing period 2002-2004. Fig 4.2 depicts the number of starts per racing season for all four Gauteng racetracks during this six year period.

The following results were obtained from the NHRA data:

- A total number of 103 603 starts for the six year racing period from 1998-2004 for all four racecourses was recorded.
- The greatest annual total amount of starts for all four racetracks was during the 2000 racing period with 16 174 starts.
- The lowest annual total starts for all four racetracks was during the 2003 racing period with 13 624 starts.
- The greatest amount of individual annual starts was during the 2004 racing period at Turfontein with 5960 starts.
- The least amount of individual annual starts was during the 2001 racing period at Gosforth Park with 1968 starts.
- Turfontein had the greatest amount of starts for the period 1998-2004 totalling 32 046 starts.
- Gosforth Park had the least amount of starts for the period 1998-2004 totalling 11 768 starts. The number of lower starts represented by Gosforth Park was as a result of closure of the course at the end of the 2001 racing season. Prior to closure Gosforth Park had the least amount of annual starts during the racing periods 1998-2001.
- From 2002-2004 Turfontein had the largest amount of annual starts, followed by the Vaal Turf and Newmarket racecourses.

Table 4.1: Number of starts per race season for all four Gauteng racetracks during the racing period 1998-2004.

Number of starts per race season								
	1998	1999	2000	2001	2002	2003	2004	Total
Gosforth Park	3219	2876	3704	1968	0	0	0	11 768
Newmarket	4207	3703	4189	4636	3949	3815	3555	28 060
Turfontein	3653	4009	3704	4181	5509	5275	5960	32 046
Vaal Turf	3516	4564	4817	4528	5168	4534	4601	31 729
Total	14 595	15155	16 174	15 313	14 626	13 624	14 116	103 603

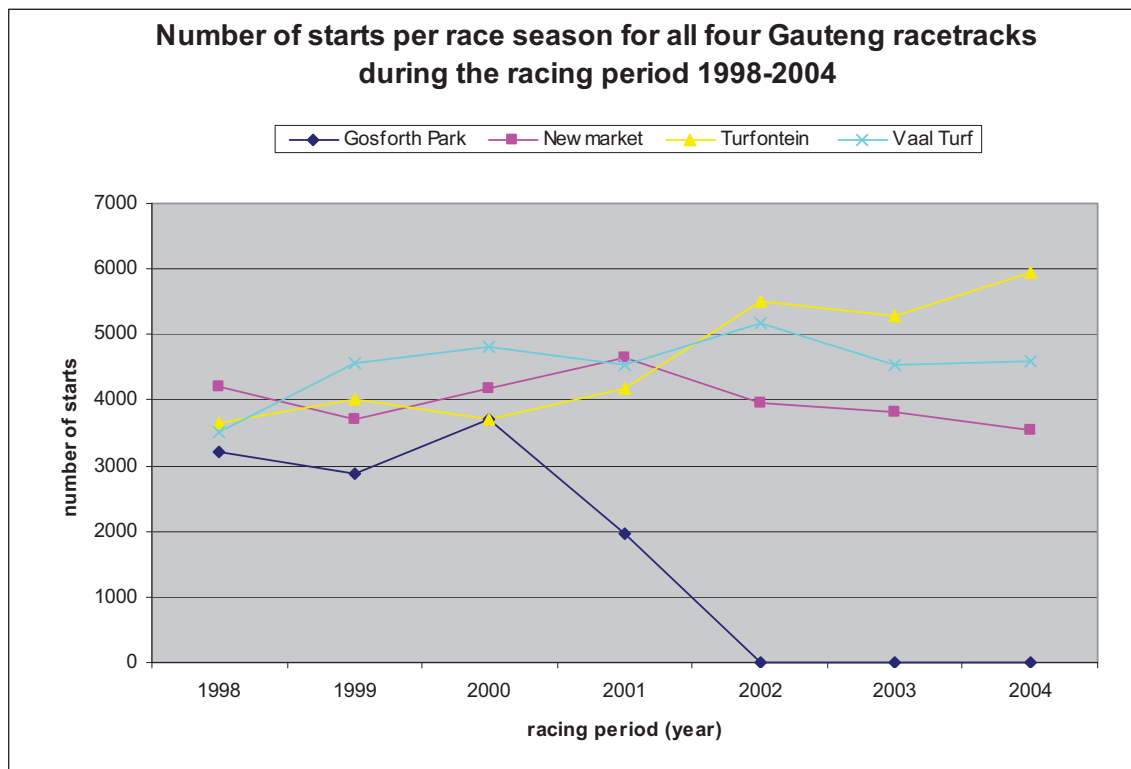
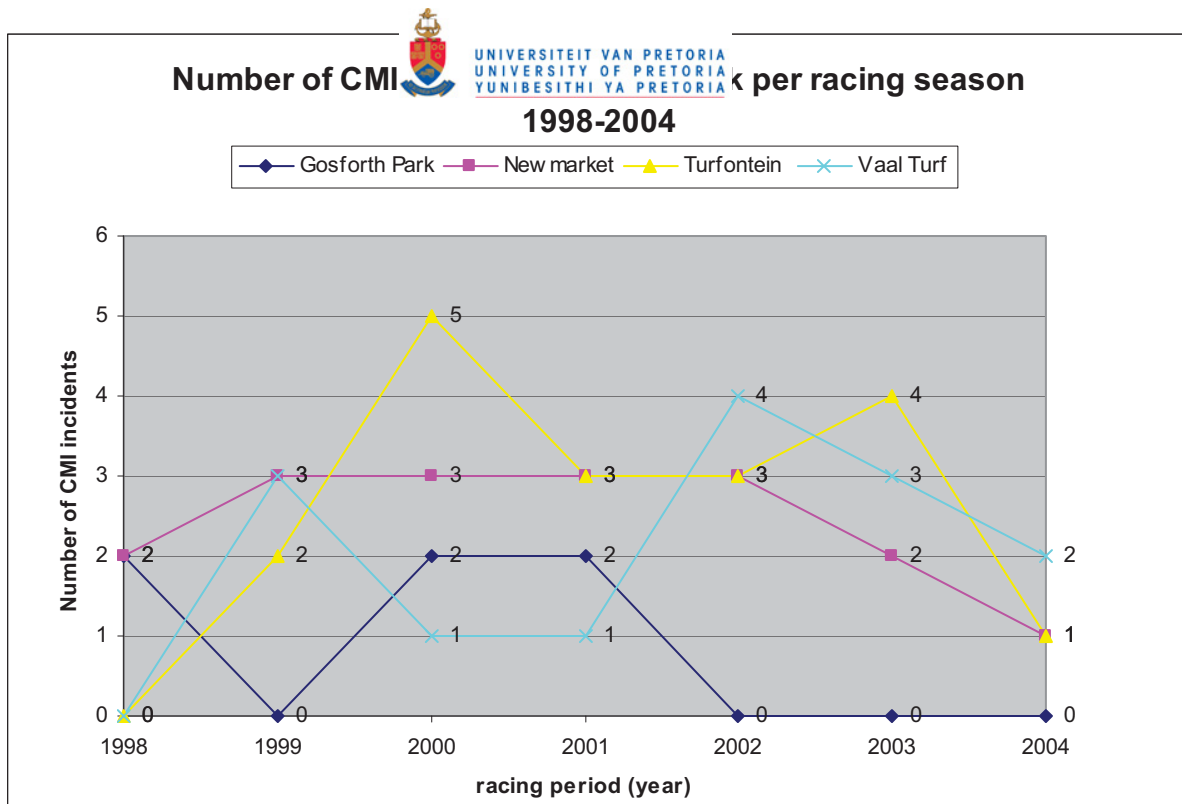


Fig. 4.2: Line graph depicting the number of starts per race season for all four Gauteng racetracks during the racing period 1998-2004.

4.3.2 Number of catastrophic musculoskeletal injuries per racetrack per racing season

The number of CMI per racetrack per racing season was determined from records made available by the NHRA. A line graph depicts the number of CMI per racing season per racetrack during the six year study period in Fig. 4.3. Turfontein race course had the highest recorded number of the CMI (18) during the six year period, followed by Newmarket (17), Vaal Turf (14) and finally Gosforth Park (6). The low number of CMI at Gosforth Park was not a true reflection for the period 1998-2004 as this racecourse was closed down and thus had no starts recorded during the racing period 2002-2004.

- The total annual number of CMI for all racecourses combined was the highest in 2000 (11), followed by 2001 (9) and 2003 (9) and the lowest amount of CMI sustained in 1998 (4) and 2004 (4).
- 2004 represented the second lowest total amount of starts for all four racetracks within the 6 year period (14 116) as well as having the largest number of annual starts being recorded at Turfontein (5960).
- 1998 had the third lowest amount of starts for all four racetracks within the 6 year period (15 147)
- 2003 had the lowest amount of total starts for all four racetracks within the 6 year period (13 624).



CMI = catastrophic musculoskeletal injuries

Fig. 4.3: Line graph depicting the number of catastrophic musculoskeletal injuries per racetrack per racing season during the racing period 1998-2004.

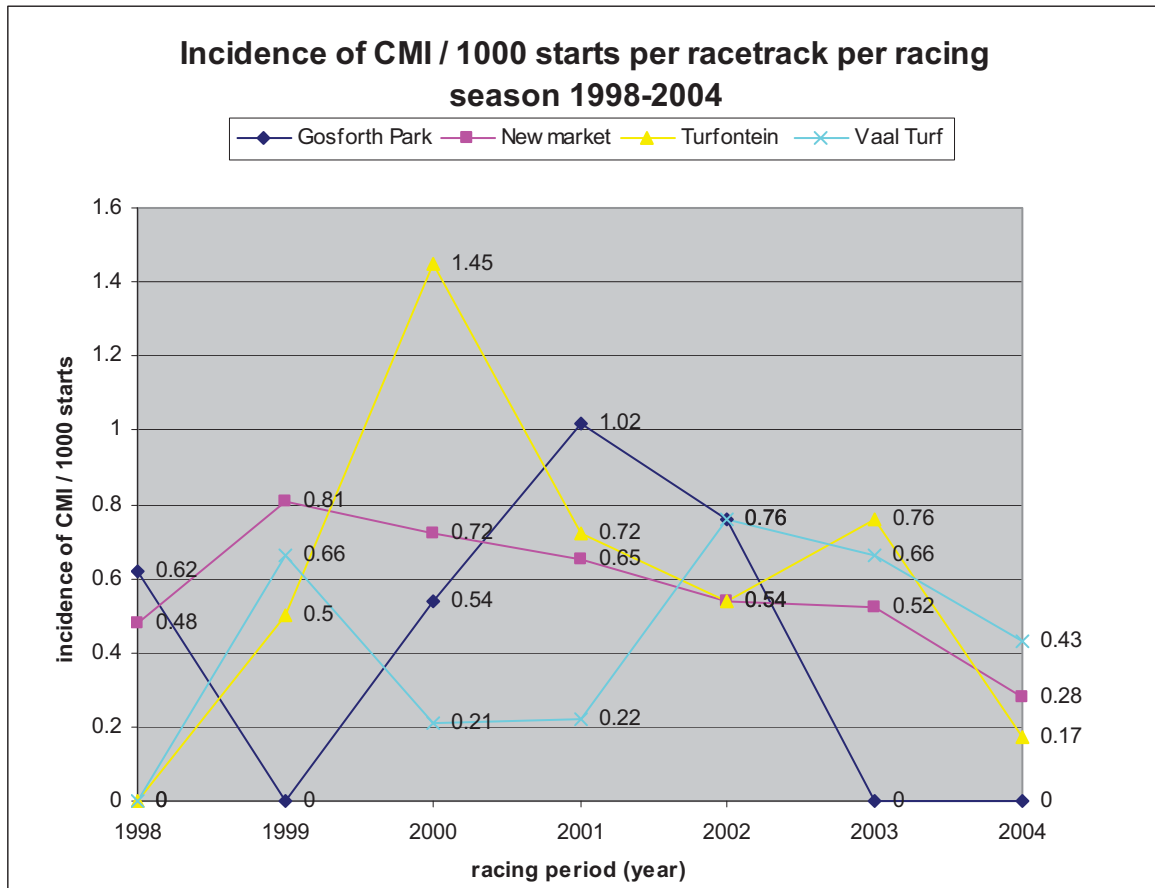
4.3.3 Incidence of catastrophic musculoskeletal injuries per 1000 starts per racing season

The collective incidence pertaining to all four tracks represented in Gauteng was calculated for each racing year. $\text{Incidence} = (\text{number CMI} \times 1000) / \text{number of starts}$. A line graph depicts the incidence of CMI per 1000 starts per racing season per racetrack during the six year study period in Fig. 4.4.

The following information was deduced from this study:

- The highest individual incidence occurred at Turfontein racetrack in 2000 with an incidence of 1.45 / 1000 starts (number of starts = 3459)
- No incidences (0.0 / 1000 starts) occurred at Vaal Turf and Turfontein in 1998 (number of starts = 3653, 3516 respectively) and at Gosforth Park in 1999 (number of starts = 2876).
- The lowest individual incidence (0.21 / 1000 starts) occurred at Vaal Turf in 2000 (number. of starts = 4818).

- The highest collective annual incidence (0.68 / 1000 starts) occurred in 2000 and 2002 (number of starts = 16 174 and 14 626 respectively).
- The lowest collective annual incidence (0.27 / 1000 starts) occurred in 1998 (number of starts = 15 155).



CMI = catastrophic musculoskeletal injuries

Fig. 4.4: Incidence of catastrophic musculoskeletal injuries per 1000 starts per racetrack per racing season during the racing period 1998-2004.

4.4 Statistical analysis of potential risk factors for catastrophic musculoskeletal injuries

4.4.1 Racetrack

The number of starts, number of CMI and incidence of CMI for the different racetracks are given in Table 4.2. Statistically there were no significant differences in incidence of CMI between tracks ($P=0.84$).

Table 4.2: Incidence of catastrophic musculoskeletal injuries at each track.

Racetrack	No. of starts	No. of CMI	Incidence per 1000 starts
Gosforth Park	11 768	6	0.5
Newmarket	28 060	17	0.6
Turfontein	32 046	18	0.6
Vaal Turf	31 729	14	0.4

CMI = catastrophic musculoskeletal injuries

4.4.2 Racing year

Table 4.3: Incidence of catastrophic musculoskeletal injuries per race year.

Race year	No. of starts	No. of CMI	Incidence per 1000 starts
1998	14 595	4	0.3
1999	15 155	8	0.5
2000	16 174	11	0.7
2001	15 313	9	0.6
2002	14 626	10	0.7
2003	13 624	9	0.7
2004	14 116	4	0.3

CMI = catastrophic musculoskeletal injuries

The number of starts, number of CMI and incidence of CMI for the different race years are given in Table 4.3. In this study it was shown that statistically there were no significant differences in the incidence of CMI between the different race years (P=0.463)

4.4.3 Draw

Table 4.4 depicts the distribution of the draw categories in relation to the 55 CMI that occurred over the study period.

Table 4.4: Incidence of catastrophic musculoskeletal injuries related to draw.

Draw	No. of starts	No. of CMI	Incidence per 1000 starts
1 to 5	42 483	17	0.4
6 to 10	38 196	20	0.5
> 10	22 924	18	0.8

CMI= catastrophic musculoskeletal injuries

Although draw was not a statistically significant factor in CMI ($P=0.13$), it was selected in the multiple logistic regression model.

4.4.4 Weight carried by horse

Table 4.5: Incidence of catastrophic musculoskeletal injuries as related to weight carried by the horse.

Weight (kg)	No of starts	No of CMI	Incidence per 1000 starts
<54	16 662	5	0.3
54-59	84 121	44	0.5
>59	2 820	6	2.1

CMI= catastrophic musculoskeletal injuries

Table 4.5 depicts the weight carried by the horse and was shown to be a statistically significant risk factor of CMI in the univariable analysis ($P=0.005$), with horses carrying >59kg having a significantly greater risk of CMI.

4.4.5 Distance raced

Distance run by horse was shown to be of no significance when simple logistic regression was performed ($P=0.925$). It was thus discarded and not used in the multiple logistic regression model.

4.4.6 Going

The distribution of CMI in relation to going is depicted in Table 4.6 which shows the majority of CMI occurred on the good going surface, which also had the greatest number of starts. However, no significant differences between these three categories were detected with the simple logistic regression model ($P=1.00$).

Table 4.6: Incidence of catastrophic musculoskeletal injuries related to going.

Going	No. of starts	No. of CMI	Incidence per 1000 starts
Hard / Firm	5 348	2	0.4
Good	85 631	47	0.5
Soft / Yielding	12 624	6	0.5

CMI= catastrophic musculoskeletal injuries

4.4.7 Age

The distribution of CMI in relation to going is depicted in Table 4.7. The largest number of CMI i.e. 24, were encountered in the age category between 3 - 4 years of age which also had the highest number of starts. No significant differences were found in CMI incidence between the age categories ($P=0.635$). (The univariate analysis was calculated using a total number of 103 546 horses, as data showed that the 2 horses that had been excluded from this particular race had raced at an age of greater than 20 years. This was most likely the result of a typing error or data input error, since a twenty year old horse will not be an active racehorse).

Table 4.7: Incidence of catastrophic musculoskeletal injuries related to age.

Age in years	No. of starts	No. of CMI	Incidence per 1000 starts
<3	18 123	8	0.4
Between 3-4	43 206	24	0.6
Between 4-5	25 277	11	0.4
>5	16 984	12	0.7

CMI= catastrophic musculoskeletal injuries

4.4.8 Gender

Table 4.8 shows the distribution of CMI according to the different gender categories. In the univariate analysis gender proved to be highly significant ($P < 0.001$), with colts / stallions having an increased risk of CMI. The number of colts / stallions that raced in the six year racing period was only 5 410 which was much less than the number of geldings or fillies / mares *i.e.* 55 317 and 42 876, respectively.

Table 4.8: Incidence of catastrophic musculoskeletal injuries related to gender.

Gender	No. of starts	No. of CMI	Incidence per 1000 starts
Fillies/mares	42 876	8	0.2
Colts/stallions	5 410	16	3.0
Geldings	55 317	31	0.6

CMI= catastrophic musculoskeletal injuries

4.4.9 Racing interval

Table 4.9 depicts the relationship of racing interval and CMI over the study period. In the univariate analysis racing interval was shown to be a marginally significant risk factor for CMI ($P=0.054$), with less than 7 days having an increased risk of CMI.

Table 4.9: Incidence of catastrophic musculoskeletal injuries related to racing interval.

Racing interval (weeks)	No. of starts	No. of CMI	Incidence per 1000 starts
<1	3 846	6	1.6
1-3	42 713	22	0.5
>3	46 721	26	0.6

CMI= catastrophic musculoskeletal injuries

4.4.10 Size of field

The number of starts and the number of CMI that occurred within each field size category is depicted in Table 4.10.

Table 4.10: Incidence of catastrophic musculoskeletal injuries related to size of field.

Size of field (No. Of horses)	No. of starts	No. of CMI	Incidence per 1000 starts
<10	15 589	5	0.3
10-14	51 374	33	0.6
>14	36 640	17	0.5

CMI= catastrophic musculoskeletal injuries

Differences between size of field categories were not statistically significant ($P=0.277$).

4.4.11 Multiple logistic regression model

Using $P < 0.25$ as cutoff, four factors were shown to be potentially significant risk factors for CMI in the univariable analyses. These factors were used as predictors in the multiple logistic regression model and included: gender, weight, draw and racing interval. There was insufficient evidence to show that racetrack, age, distance run and going were significant risk factors and these were therefore not included. The results of the mixed-effects multiple logistic regression model are shown in Table 4.11.

Table 4.11: Results of mixed-effects multiple logistic regression model for risk factors: draw, gender, racing interval and weight carried by horse.

Variable	Level	Odds ratio	95% CI	P-value
Draw	1-5	1*	–	–
	6-10	1.29	0.67, 2.47	0.443
	>10	1.83	0.93, 3.61	0.080
Gender	Fillies/mares	1*	–	–
	Colts/stallions	14.83	6.21, 35.40	<0.001
	Geldings	2.81	1.28, 6.16	0.010
Racing interval (weeks)	<1	1*	–	–
	1-3	0.35	0.14, 0.88	0.025
	>3	0.37	0.15, 0.90	0.029
Weight carried (kg)	<54	1*	–	–
	54-59	1.74	0.68, 4.42	0.246
	>59	5.85	1.74, 19.70	0.004

CI= confidence interval * = category to which comparison is made

Gender proved to be a statistically significant risk factor for developing a CMI. Colts / stallions were 14.8 times more likely to suffer a CMI than mares / fillies ($P < 0.001$)

and 5.3 times more likely than geldings ($P < 0.001$). Geldings were 2.8 times more likely to develop a CMI when compared to mares / fillies ($P = 0.01$).

There were significant differences in risk of CMI between categories of weight carried by the horse. Horses carrying $> 59\text{kg}$ of weight were 3.3 times more at risk when compared to those horses carrying 54-59kg of weight ($P = 0.006$) and 5.9 times more at risk than those horses carrying less than 54kg of weight ($P = 0.004$).

A racing interval of less than 1 week also proved to be a significant risk factor for developing a CMI. Horses racing with less than a week since their last race, were 2.8 times more at risk of developing a CMI when compared to horses racing with an interval of greater than 1-3 weeks ($P = 0.025$) and 2.7 times more at risk when compared to horses racing with an interval of greater than 3 weeks ($P = 0.029$). There was no significant difference in risk when comparing the 1-3 week and greater than 3 week interval ($P = 0.881$).

Draw was not quite statistically significant in the multiple regression model, however the risk of CMI appeared to show an increasing trend with increasing draw number. Horses drawn > 10 tended to be at increased risk of CMI when compared to those drawn between 1-5 ($OR = 1.8$; $P = 0.080$). The risk for draw category 5-10 did not differ significantly from either of the two categories.

The outcome of the hypotheses in this study was as follows:

- The hypothesis that the overall incidence of catastrophic racing injuries involving the musculoskeletal system in Thoroughbred horses at four racetracks in Gauteng, South Africa is similar to that reported elsewhere in the world, was supported by previous studies.
- The hypothesis that the incidence of catastrophic racing injuries involving the musculoskeletal system of Thoroughbred horses differs depending on the specific racetrack, was proven false.
- The hypothesis that the left forelimb is the limb most frequently involved in CMI at tracks in Gauteng, was proven true.
- The hypothesis that damage to the forelimb suspensory apparatus is the predominant CMI observed at the racetracks in Gauteng during the racing period 1998-2004, was proven true.



- The study was too small to reject or accept the hypotheses that lateral metacarpal condylar fractures were more common than medial metacarpal condylar fractures at racetracks in Gauteng.
- The hypothesis that most injuries occur in horses sprinting over short distances, was proven false.

Chapter 5: Discussion

5.1 Incidence of catastrophic musculoskeletal injuries

The incidence of CMI in this study falls well within the ranges reported worldwide. The overall incidence of CMI for the racing period 1998-2004 was 0.53. The only three studies that have reported a lower incidence than this was a study in the UK reporting on the 1999-2001 racing period (0.38)²³, a study in Sydney reporting on the 1985-1995 racing period (0.3)², and a study in Victoria reporting on the 1989-2004 racing period (0.44)⁴. This incidence of CMI is also lower than that reported previously in the Transvaal province (currently named Gauteng), RSA during the racing period 1988-1993 (1.4)¹⁸ (see Table 2.1). The annual collective incidences calculated in South Africa from 1998-2004 (0.68 and 0.27, highest and lowest respectively) are lower than that calculated anywhere else in the world except for the two studies done in Sydney (0.3)² and Melbourne (0.6)³, Australia and two studies done in the UK (0.6²⁰; 0.38²³). The highest individual incidence in South Africa occurred at Turfontein racetrack in 2000 with an incidence of 1.45 (number of starts = 3459). This incidence is only exceeded by a couple of studies performed in North America in California (1.7)¹², and Ontario (1.99)¹⁰ and in the UK (6.3²⁷; 3.97³⁷). The high incidences reported in the UK were confounded by the fact that these results pertained to all race types including steeplechasing and hurdling in the first study and in the second reported on all injuries that had occurred and not just the fatalities.

The following factors may have contributed to the relatively low incidence of CMI in Gauteng in this study:

- Stringent rules governing the use of medications which may have precluded horses with musculoskeletal injuries from participating;
- The majority of racing in Gauteng takes place on turf which has shown to have a lower risk than dirt tracks. The Vaal Turf racetrack is the only track at which racing takes place on either a turf or a dirt surface. Horses train on both turf and dirt surfaces in Gauteng;

- The track surfaces at the four Gauteng tracks appear to be of equal quality and are likely to be managed very similarly;
- The climate is very similar for all four of the Gauteng racetracks;
- With modern training practices the horses' limbs are better conditioned and can withstand the repetitive mechanical stresses of racing;
- The generally lower incidence of CMI on the other racetracks still cannot be explained

5.2 Racetrack

No significant differences in incidence of CMI were found between the four different racetracks ($P=0.840$) and six individual racing periods ($P=0.463$). 2003 had the lowest amount of total starts for all four racetracks within the 6 year period (13 624). It is still open to speculation why in 2003 the least number of starts were reported as no outbreaks of disease occurred during this period, and no other plausible cause could be established³⁶. These results most likely were not confounded by the fact that Gosforth Park had closed and no meetings were held from 2002, onwards, as most of these horses were now stabled and trained at Turfontein or the training centre at Randjiesfontein, thereby not precluding them from racing at the other three racetracks. Turfontein and Vaal racetracks showed a trend to increase in number of starts after the closure of Gosforth Park in 2002. This trend was not seen at Newmarket racetrack. Gosforth Park had the least amount of starts due to closure of the track after the 2001 racing period. Newmarket and Turfontein equally showed the highest tendency or risk of CMI (Incidence per 1000 starts = 0.6; odds ratio = 0.06) but were not shown to be significantly greater than the other racetracks. The Vaal Turf is the only racetrack at which racing takes place on a turf or a dirt surface. No incidences of CMI were reported to have occurred on this dirt racetrack. All of the reported CMI occurred on turf. Horses train on both dirt and turf surfaces in Gauteng. Possible explanations for no significant differences in incidence of CMI found between the four different racetracks and six individual racing periods may be that:

- the condition and going at the four Gauteng racetracks is similar;
- the Gauteng tracks are managed similarly;
- similar track standards are set by the NHRA throughout Gauteng;

- the risk of racing on the dirt track at the Vaal Turf racetrack is not greater than the risk of racing on turf;
- the horses are rotated and raced on different racetracks in South Africa.

5.3 Anatomical areas affected

In this study CMI involved primarily the forelimbs. This correlates well with previous studies that showed that the forelimb was involved in more than 80% of the cases^{7,12,16,18,24,25,,37}. Forelimbs are more prone to injury due to greater relative forces at higher speeds. Forelimb lameness is more common than hindlimb lameness due to the horse's centre of gravity being positioned closer to the forelimbs. The weight distribution between the forelimbs and hindlimbs is approximately 60%:40%³³. Higher loads are experienced by the forelimbs, approximately 30% carried on the individual forelimb. Also during certain stages of a particular gait (canter and gallop) a single forelimb is weight-bearing at a point in time and may predispose this limb to injury. The rider's weight may shift the distribution further towards the forelimbs, increasing the ratio to 70%:30%³³. Concurrent front and hindlimb injuries are not common.

All of the CMI in this study occurred unilaterally and predominantly involved the left forelimb. Previous studies have shown the left forelimb to be the most predominantly affected limb^{7,11,16,18}. This may have been attributable to increased load on the lead limb at the gallop, *i.e.* when racing counter-clockwise horses are usually on the left lead in the turns and on the right lead during the straight²⁴. Racing and training in Gauteng however, takes place in a clockwise direction. The horses are most likely to lead with the right forelimb on the turns and lead with the left forelimb on the straight. A horse will naturally lead with the inside limb when rounding a corner or bend as it is more balanced. This inside leading limb is loaded to a greater degree than the outside limb when in a bend or turn especially at a gallop since it is a four-beat gait. There is a period where the inside leading limb will be the only limb actually making contact with the ground and bearing weight whilst the other limbs are still in the air (flight arc). A racehorse will usually change leg (leading limb) once it hits the straight as the inside leading limb starts becomes fatigued due to the excess strain. One would surmise that most of the CMI in this study would therefore affect the right forelimb as this would be the loaded leading limb on the turn or bend. However,

even in this study the left forelimb remains the predominantly affected limb. We cannot explain this, but most CMI are not as a result of a single inciting event, and most likely arise as a result of cumulative injuries that have been incurred during the training sessions. Racehorses' limbs adapt in response to repetitive mechanical stresses placed on the limbs during training by a process of remodelling. This remodelling phase comprises a phase of bone resorption which is followed by a slower remodelling phase whereby new bone is deposited in specific areas to enable the limb to withstand the stresses and strains of racing. The delay between the resorption and remodelling phase places these racehorses at risk as the bone is weaker and is less likely to withstand the cumulative stresses of racing and may lead to a CMI³¹.

The most common location for the CMI in this study was the suspensory apparatus and the metacarpophalangeal region and was represented by 56.36% of the cases. This is similar to findings in other studies conducted in California, which found the PSB and MC3 (42% of cases) to be the most common racing and training injury^{11,12}, and a study conducted in Britain which found the flexor tendons or the IOM (25.37%), followed by the MCP and PSB (11.46%) to be the most common limb injuries³⁷. Suspensory apparatus disruption almost exclusively occurs in the forelimbs of Thoroughbred racehorses working at high speed²⁸. Speed and fatigue of the flexor muscles supporting the metacarpophalangeal joint lead to higher stresses in each component of the suspensory apparatus. The metacarpophalangeal joint is a high motion joint which can become intensely loaded and is particularly at high risk in horses performing at maximal speed. The suspensory apparatus acts by counteracting the high load experienced by the joint and maintains the range of extension²⁸. The PSBs, are an integral part of the suspensory apparatus and the metacarpophalangeal joint articulation, and are also particularly susceptible to injury in horses performing at high speed²⁸. It has been shown that when the hoof impacts with the ground, it slides slightly further forward before stopping (more so on dirt and AWT²³), increasing the degree of fetlock extension as that leg becomes the predominant weight-bearing limb, and placing greater strain on the the SA. The effect of training on the strength of the suspensory apparatus has been investigated and it appears that training strengthens the suspensory ligament so that the weakest component of the apparatus becomes the proximal sesamoid bones⁶. One excessive hyperextension may be sufficient to produce an acute failure of the PSB.

Alternatively, the repeated higher strain may cause accumulative damage to the SA, and make the PSB more susceptible to failure²³.

PSB fractures represented the most common CMI fracture in this study. PSB fractures were also found to be one of the most common sites of primary injury in a study performed in California¹⁶, and represented the second most common injury in a study pertaining to flat racing injuries in Britain³⁷. In this study the majority of the PSB fractures occurred in the LF. This correlates well with the previous Californian study in which the LF injuries more commonly involved the PSB¹⁶. Due to the resulting over-extension and collapse of the metacarpophalangeal joint these fractures were commonly associated with extensive damage of the flexor tendons and ligaments in close proximity to the metacarpophalangeal joint.

Fractures of the third metacarpal or metatarsal condyles occur almost exclusively in racehorses whilst the horse is exercising at high speed and are rarely attributed to a specific incident. These fractures are more common in Thoroughbreds than other racing breeds, and the fracture predominantly involves the lateral condyle of the left forelimb. It has been shown that in racing Thoroughbreds linear defects in mineralised articular cartilage and subchondral bone occur in the palmar / plantar aspects of the condylar grooves adjacent to the sagittal ridge and are associated with intense focal remodelling of the immediately adjacent and subadjacent bone³¹ in response to cyclic loading associated with training and racing which is detectable at as little as four months of training^{28,31}. In the one study, results suggest that condylar fractures in horses are pathologic fatigue or stress fractures that arise from a pre-existing, branching array of cracks in the condylar groove of the distal end of MC3 or MT3²⁸. It is theorized that the high incidence of this fracture results from unbalanced loading of the left forelimb that peaks during counter-clockwise turns. In this study two of the three condylar fractures involved the lateral condyle and were represented by a RF and LF respectively. Only one medial condylar fracture involving the RF was represented. The RF was the predominantly affected limb when taking only condylar fractures into consideration. Previous studies that showed that condylar fractures predominantly involve the lateral condyle of the left forelimb (76% lateral vs 8% medial¹⁶ and 0.97 lateral / 1000 starts vs 0.24 medial /1000 starts in all race types²³). With racing and training in Gauteng occurring in a clockwise direction thereby placing more strain on the inside RF, one would have expected the majority of the condylar

fractures to involve the lateral condyle of the RF. The reason for this is as yet unclear.

5.4 Risk factors for catastrophic musculoskeletal injuries

Factors found to be statistically significant risk factors for CMI in this study using univariable analysis were: gender, weight carried by the horse, racing interval and draw. Factors found to have no statistical significant evidence of being potential risk factors of CMI in this study using univariable analysis were: racetrack, racing year, age, distance, and going.

Gender, relative to the number of starts was shown to be of statistical significance (colts $P < 0.001$ (starts = 5 410) and geldings $P = 0.010$ (starts = 42 876)). Colts / stallions were 14.8 times more at risk of developing a CMI when compared to the fillies / mares and 5.3 times more at risk when compared to the geldings. The previous study performed in Transvaal showed that the majority of CMI occurred in males when compared to females (75.5% vs 24.5%). A study performed in Florida associated geldings with a higher risk of injury¹³. It was found that because of their potential for breeding or sale purposes, fillies, mares, and colts are likely to run less frequently or be retired from racing sooner than are geldings^{11,12}. Conversely another study conducted in Kentucky did not identify gender as a risk factor for CMI⁸. In this study fillies and mares are likely to be withdrawn from racing sooner than their male counterparts due to their breeding value. Geldings represent the largest population of horses on the racetrack (55 317 starts). This may inherently be due to the fact that they do not have any breeding value and are thus more likely to be kept in racing longer. No obvious reason could be found why colts are more at risk of developing a CMI than geldings. Colts represent a very small number of the population of horses racing (5 410 starts). This is likely an indication that colts are castrated quite early in their racing career, contributing to the population of geldings racing.

Greater than 59kg weight carried by the horse was also identified as a significant risk factor identified in this study. Horses carrying > 59kg of weight were 3.3 times more at risk when compared to those horses carrying 54-59kg of weight ($P = 0.006$) and 5.8 times more at risk than those horses carrying less than 54kg of weight ($P = 0.004$).

The more weight that is carried by the horse, the more weight is distributed onto the forelimbs at fast speed thereby putting the horse at greater risk of injury when compared to a horse carrying less weight. It should also be borne in mind that weight on its own may not be the only determining factor especially when referring to the art of riding. In other disciplines of riding it has been shown that an unbalanced, inexperienced rider can interfere with the horses movement and performance to a larger degree than a relatively over-weight but experienced rider. It is however unlikely that a jockey would be grossly inexperienced.

Racing interval was also identified as a significant risk factor for CMI in this study. Horses with a racing interval of less than 1 week are almost three times more likely to develop a CMI when compared to horses with a racing interval of greater than 1 week. This may be attributed to the fact that with a short racing interval these horses have not had sufficient time to recuperate from the previous race's stress and strains and thus more prone to fatigue and injury. A 3-4 week interval between races has been recommended to decrease the occurrence of injury by diluting physical demands²⁴. Conversely, a too long race interval may also serve as a useful indicator of previous health and lameness problems. It has been shown that horses that had a pre-existing injury particularly in the SDFT of the forelimb had an extended interval between races because of the injury⁷. In a previous study a positive association with CMI was found when an interval of greater than 60 days had elapsed between the race in which horse was injured and previous race date⁷. In another study horses raced greater than 33 days previously were 2.5 times more likely to sustain a CMI during racing as were horses that raced less than 13 days before¹³. It has been hypothesized that horses that return to training or racing after an extended period of reduced exercise may have insufficient bone mass to prevent micro-damage with exercise; stress fractures may develop as result of continued repetitive loading¹³.

There was a tendency toward increased risk of CMI when the horse was drawn and raced in a position greater than 10 ($P=0.08$). A possible reason for this may be as a result of the camber of the racetrack on the turns or bends which may lead to a greater portion of stress being placed on the inside limb as the horse has to maintain its balance at high speed. The horses that have been drawn wide also have to jostle

their way through the rest of the field to gain access to the inner rail so as to ultimately keep the distance raced to a minimum.

Worldwide racing is clearly dominated by younger horses. However, no significant differences in risk of CMI were found between the different age categories ($P=0.635$) Most horses being raced are matched closely for age and sex, as shown in the study performed in California where age and sex distributions of the race entrants were not independent¹². The studies showed that the risk of a CMI in male horses was about two-fold that in female horses, and in 4-year-old TBs was two-fold that in 3-year-olds.^{11,12}.

The horses that sustained a CMI in this study raced over a distance ranging from 800m to 2400m. Statistically, race distance was found not to be significant risk factor for CMI in this study and this correlates with a study performed in New York which also did not identify race distance as a risk factor for CMI²¹. Studies in Kentucky, USA have shown that the distance of the race was significantly shorter and the number of turns less among horses with catastrophic injuries than among horses with non-catastrophic injuries^{8,24}. The proportion of horses racing less than or equal to 1307m (6.5 furlongs) was greater in the catastrophic group (59.8%) than among horses in the career ending group (40%)²⁵. Pinchbeck *et al.* included all types of racing (hurdling included) in their study and showed that longer distances increased the risk of injury²⁷. Horses are more likely to incur an injury due to increased exposure time and increased number of fences and hurdles. Horses are more likely to be fatigued in longer distance races. Risk of falling also increases with increased distance²⁷.

Even though going was found not to be a significant risk factor for CMI in this study the majority of the CMI occurred on the good going surface. Hard / firm going is generally correlated with greater speed. The majority of starts in Gauteng occurred on good going (85 631 vs 5 348 and 12 624 for hard and soft going, respectively). In Britain and in Gauteng, RSA the aim is to provide racing surfaces which can be described as good-to-firm (not firm) for flat racing. Overall, the frequency of MSI was lowest from racing on turf that was soft and the rate of problems increased as surfaces became firmer (all types of racing)³⁷. This may be due to harder turf tracks having less cushioning effect, as horses have greater forces exerted on them than on

tracks with a higher moisture content. Overall racing fatality also tended to decrease as racing surfaces became softer (all types of racing)³⁷. The overall race speed decreases on the softer surface leading to a decrease risk of injury. This trend was only marginally significant for flat racing. There was a clear trend for a decrease in overall rate of MSI as racing conditions became softer^{27,37}.

5.5 Limitations identified in this study

Identification of limbs:

Current means of identifying the amputated limbs are not ideal. It was found that after extended periods of storage and during the process of defrosting and repacking the freezers the identification tags had become dislodged leading to nine of the limbs being unidentifiable. It is recommended that a waterproof tag (hospital arm band) be attached directly to the limb on which the full details of the horse be noted, *i.e.* name, date of race, date on which CMI occurred and specific racetrack on which the CMI occurred. It is also recommended that the limbs be analysed as soon as possible after a CMI has occurred so that problems with identification are ruled out completely and results made available for further scrutiny.

CMI database:

The horses which had sustained a CMI were not easily identified when searching through the NHRA database. It is recommended that these horses be clearly identified by means of a special code, which is then recorded in the NHRA database. A standardised form for CMI should be drawn up on which all the details of the horse, particular injury sustained, limb involved, date of race, racetrack and location on track where injury occurred can be noted by the official NHRA track veterinarian. These details should then be added to the horse's normal racing history in the NHRA database.

The NHRA database is the single available resource pertaining to records kept of South African racing. These records are thus not comparable to any other database and should a reporting error occur it may most likely go unnoticed.

DNA analysis:

A further limitation in this study was that the DNA analysis was unable to identify the nine limbs, from which the identifying tags had become dislodged. DNA parentage was initiated in South Africa with the 2001 Thoroughbred foal crop. DNA from all the breeding sires and dams of these foals was collated during 2001. DNA on all imported Thoroughbred horses has been routinely performed since 2001. A probable cause may be that the CMI in these nine horses had occurred before 1998 and that these horses may have been born prior to 1996 thus creating a gap of 5 years before DNA analysis was introduced.

Method of evaluating limbs:

Ultrasonographic evaluation of the distal limbs after amputation was not found to be ideal for several reasons already mentioned in section 3.3.2. The major cause or result of a CMI in this study was easily identified by means of radiographs. The post mortal dissection delivered detailed macroscopic pathological lesions that were sometimes missed whilst performing the ultrasonography. Currently with the advent of portable digital radiography a rapid diagnosis can now be made at the racetrack thereby providing owners with a prognosis of the injuries so that realistic decisions can be made whether to opt for therapy or euthanasia. Breeding potential of the individual will sometimes be the deciding factor. The horses that are referred to surgical institutions should still be included in the study even though they may not return to racing. This can easily be monitored as there are only a few specialist facilities in Gauteng that have the ability to perform this orthopaedic surgery.

Post mortem investigations:

A further limitation of this study was that post mortal investigations were not performed on all the horses that had sustained a CMI on the four Gauteng racetracks. The official NHRA track veterinarians only forwarded those limbs that they suspected had sustained a CMI pertaining to the suspensory apparatus. It is important that all CMI be investigated so that risk factors can be identified to minimise the incidence of CMI. Limited post mortems focusing on the region of pathology are sufficient for those injuries involving the distal limbs, which are easily identifiable. Those CMI positioned further proximally, e.g. the pelvis, may require a more extensive post-mortem examination to establish the extent of pathology. Through previous studies it is evident that most CMI are not of an acute nature but

are the result of remodelling of the bone which takes place so that the horse can adapt to different strains and stresses which are placed on the limbs that are very specific for racing.^{6,29-31}

Pre-race inspection:

Pre-race inspection in Gauteng is far more conservative when compared to that performed in Kentucky, USA. In Gauteng, each horse's identification is checked and the racing history is scrutinised before each race. Any horse can be withdrawn from racing should the official racetrack veterinarian notice any signs of lameness or anything untoward from the time the horse arrives at the track up to the point where the horse enters the starting gates³⁶. Horses are assessed whilst moving towards and within the parade ring as well as when they canter down towards the start. The horses are not specifically trotted out for the veterinarian and the distal limbs are not palpated or manipulated to assess decreased joint flexion or resistance to flexion, and soft tissue swelling or pain pertaining to the joints or tendons is not assessed. Studies have shown that by performing the palpations and manipulations pre-race, horses at risk can be identified and timeously withdrawn from a race thereby circumventing serious musculoskeletal injuries from occurring^{7,8,26}. To implement these inspections more veterinarians may be needed to be employed by the NHRA on racedays.

5.6 Future use of study

The numbers of CMI in this study are low and fall well within the incidence reported throughout the world. However, each and every CMI should be avoided wherever possible as it is not just devastating for the horse but has a negative impact on the spectator value of the sport. The numbers of spectators attending the race events have clearly dwindled over the last few years with the inception of the South African National Lotto and legalisation and accessibility of other gambling institutions. This study provides benchmarks for the racing industry to monitor racetrack CMI in Gauteng and evaluate intervention strategies.

Chapter 6: Conclusion

The following conclusions were deduced from this study:

- The overall incidence of CMI is similar to that reported elsewhere in the world.
- The incidence of CMI at the four different Gauteng racetracks does not differ significantly.
- The incidence of CMI during the six individual racing periods does not differ significantly.
- The left forelimb is the limb most frequently involved in CMI.
- The CMI occurred unilaterally.
- Damage to the forelimb suspensory apparatus is the predominant CMI observed.
- Fractures of the proximal sesamoid bones represent the most common CMI fracture.
- Most CMI do not occur over short distances.
- Statistically proven significant risk factors of CMI are:
 - Gender: colts / stallions were the most significant risk factor with geldings being the third most significant risk factor for CMI.
 - Weight carried by horse: horses carrying more than 59kg of weight are more at risk of developing a CMI.
 - Racing interval: Horses with a racing interval of less than 1 week followed by those with a racing interval between 1-3 weeks are more at risk of developing a CMI, than greater than 3 weeks.

- Factors proven to be non-significant risk factors of CMI are:
 - Going
 - Distance
 - Racetrack
 - Age
 - Racing year
 - Size of field
 - Draw
- Ultrasonography is not a useful modality in assessing the pathology post mortally, regardless of whether the limbs are fresh or frozen.
- Identification of amputated limbs at the racetrack needs to be improved.
- Lack of DNA identification of case limbs needs to be explored further.
- Post mortal investigations focusing on the region of injury need to be performed on all horses sustaining a CMI.
- Standardized reporting needs to be introduced regarding incidences of CMI.
- A more detailed pre-race inspection needs to be introduced to identify potential horses which are at risk of developing a CMI.
- Further studies are required to assess incidence of CMI at other racetracks in RSA.

References

1. Arthur R M, Ross M W, Moloney P J, Cheney M W 2003 North American Thoroughbred. In Ross M W, Dyson S J (eds) *Diagnosis and management of lameness in the horse*. Saunders Company, Philadelphia: 868-879
2. Bailey C J, Reid S W, Hodgson D R, Suann C J, Rose R J 1997 Risk factors associated with musculoskeletal injuries in Australian Thoroughbred racehorses. *Preventative Veterinary Medicine* 32:47-55
3. Bailey C J, Reid S W, Hodgson D R, Bourke J M, Rose R J 1998 Flat, hurdle and steeple racing: risk factors for musculoskeletal injury. *Equine Veterinary Journal* 30(6):498-5031
4. Boden L A, Anderson G A, Charles J A, Morgan K L, Morton J M, Parkin T D H, Slocombe R F, Clarke A F 2006 Risk of fatality and causes of death of Thoroughbred horses associated with racing in Victoria Australia: 1989-2004. *Equine Veterinary Journal* 38(4):312-318
5. Boden L A, Anderson G A, Charles J A, Morgan K L, Morton J M, Parkin T D H, Slocombe R F, Clarke A F 2007 Risk factors for Thoroughbred racehorse fatality in flat starts in Victoria Australia: (1989-2004). *Equine Veterinary Journal* 39(5):430-437
6. Bukowiecki C F, Bramlage L R, Gabel A A 1987 *In vitro* strength of the suspensory apparatus in training and resting horses. *Veterinary Surgery* 16:126-130
7. Cohen N D, Peloso J G, Mundy G D, Fisher M, Holland R E, Little T V et al. 1997 Racing-related factors and results of pre-race physical inspection and their association with musculoskeletal injuries incurred in Thoroughbreds during races. *Journal of the American Veterinary Medical Association* 211(4):454-463
8. Cohen N D, Mundy G D, Peloso J G, Carey V J, Amend N K 1999 Results of physical inspection before races and race-related characteristics and their association with musculoskeletal injuries in Thoroughbreds during races. *Journal of the American Veterinary Medical Association* 215(5):654-661
9. Cohen N D, Berry S M, Peloso J G, Mundy G D, Howard I C 2000 Association of high-speed exercise with racing injury in Thoroughbreds. *Journal American Veterinary Medical Association* 216(8):1273-1278

10. Cruz A M, Poljak Z, Filejski C, Lowerison M L, Goldie K, Martin W, Hurtig M B 2007 Epidemiologic characteristics of catastrophic musculoskeletal injuries. *American Journal of Veterinary Research* 68(12):1370-1375
11. Estberg L, Stover S M, Gardner I A, Johnson B J, Jack R A, Case J T *et al.* 1998 Relationship between race start characteristics and risk of catastrophic injury in Thoroughbreds: 78 cases (1992). *Journal American Veterinary Medical Association* 212(4):544-549
12. Estberg L, Stover S M, Gardner I A, Johnson B J, Case J T, Ardans A *et al.* 1996 Fatal musculoskeletal injuries incurred during racing and training in Thoroughbreds. *Journal American Veterinary Medical Association* 208(1):92-96
13. Hernandez J, Hawkins D L, Scollay M C 2001 Race-start characteristics and risk of catastrophic musculoskeletal injury in Thoroughbred racehorses. *Journal American Veterinary Medical Association* 218(1):83-86
14. Hill T, Carmichael D, Maylin G, Krook L 1986. Track condition and racing injuries in Thoroughbred horses. *Cornell Veterinary Journal* (76):361-379
15. Jeffcott L B, Rosedale P D, Freestone J, Frank C J, Towers-Clark P F 1982 An assessment of wastage in Thoroughbred racing from conception to 4 years of age. *Equine Veterinary Journal* 14(3):185-198
16. Johnson B J, Stover S M, Daft B M, Kinde H, Read D H, Barr BC *et al.* 1994 Causes of death in racehorses over a 2 year period. *Equine Veterinary Journal* 26(4):327-330
17. Kobluk C N 2003 Epidemiology of Racehorse Injuries. In Ross MW, Dyson SJ (eds) *Diagnosis and management of lameness in the horse*. Saunders Company, Philadelphia: 861-867
18. Macdonald D M, Toms T S 1994 Survey into the incidence of race track injuries in Transvaal racing district of Southern Africa. *Proceedings of the 10th International Conference of Racing Analysts and Veterinarians*. 262-264
19. McIlwraith C W 1996 Fractures of the Carpus. In Nixon A J (ed) *Equine Fracture Repair* 1st edition. W B Saunders Company, Philadelphia: 208-221
20. McKee S 1995 An update on racing facilities in the UK. *Equine Veterinary Education* 7(4):202-204
21. Mohammed H O, Hill T, Lowe J 1991 Risk factors associated with injuries in Thoroughbred horses. *Equine Veterinary Journal* 23(6):445-448

22. Olivier A, Nurton J P, Guthrie A J 1997 An epizootological study of wastage in Thoroughbred racehorses in Gauteng, South Africa. *Journal of the South African Veterinary Association* 68(4):125-129
23. Parkin T D H, Clegg P D, French N P, Proudman C J, Riggs C M, Singer E R *et al.* 2004 Risk of fatal distal limb fractures among Thoroughbreds involved in the five types of racing in the United Kingdom. *Veterinary Record* 154:493-497
24. Peloso J G, Mundy G D, Cohen N D 1994 Prevalence of, and factors associated with, musculoskeletal racing injuries of Thoroughbreds. *Journal of the American Veterinary Medical Association* 204(4):620-626
25. Peloso J G, Cohen N D, Mundy G D, Watkins J P, Honnas C M, Moyer W 1996 Epidemiologic study of musculoskeletal injuries in racing Thoroughbred horses in Kentucky. *Proceedings of the 42nd American Association of Equine Practitioners* 42:284-285
26. Pilsworth R C 2003 The European Thoroughbred. In Ross M W, Dyson S J (eds) *Diagnosis and management of lameness in the horse*. Saunders Company, Philadelphia: 879-894
27. Pinchbeck G L, Clegg P D, Proudman C J, Stirk A, French N P 2004 Horse injuries and racing practices in National Hunt racehorses in the UK: the results of a prospective cohort study. *The Veterinary Journal* 167(1):45-52
28. Radtke C L, Danova N A, Scollay M C, Santschi E M, Markel M D, Da Costa Gomez T, Muir P 2003 Macroscopic changes in the distal ends of the third metacarpal and metatarsal bones of Thoroughbred racehorses with condylar fractures. *American Journal of veterinary Research* 64(9):1110-1116
29. Richardson D W 2003 The metacarpophalangeal joint. In Ross M W, Dyson S J (eds) *Diagnosis and management of lameness in the horse*. Saunders Company, Philadelphia: 348-362
30. Riggs C M, Whitehouse G H, Boyde A 1999 Structural variation of the distal condyles of the third metacarpal and third metatarsal bones in the horse. *Equine Veterinary Journal* 31(2):130-139
31. Riggs C M, Whitehouse G H, Boyde A 1999 Pathology of the distal condyles of the third metacarpal and third metatarsal bones of the horse. *Equine Veterinary Journal* 31(2):140-148
32. Rossdale P D, Hopes R, Digby N J, Offord K 1985 Epidemiological study of wastage among racehorses 1982 and 1983. *Veterinary Record* 116(3):66-69

33. Ross M W 2003 Lameness in Horses: Basic facts before starting. In Ross MW, Dyson SJ (eds) *Diagnosis and management of lameness in the horse*. Saunders Company, Philadelphia: 3-8
34. Schneider R K, Jackman B R 1996 Fractures of the third metacarpus and metatarsus. In Nixon A J (ed) *Equine Fracture Repair* 1st edition. W B Saunders Company, Philadelphia: 179-194
35. Turner M, McCrory P, Halley W 2002 Injuries in professional horse racing in Great Britain and the Republic of Ireland during 1992-2000. *British Journal of Sports Medicine* 36(6):403-409
36. Wheeler D NHRA, PO Box 74439, Turfontein, 2410, South Africa, personal communication, 2004-2009
37. Williams R B, Harkins L S, Hammond C J, Wood J L 2001 Racehorse injuries, clinical problems and fatalities recorded on British racecourses from flat racing and National Hunt racing during 1996, 1997 and 1998. *Equine Veterinary Journal* 33(5):478-486
38. Wilson J H, Robinson R A 2005 Risk factors for equine racing injuries. *The Compendium: Continuing Education for Veterinarians* 18(6):682-690

APPENDIX A

Structuring of the different classes or grades of races^{1,26}

(This information was quoted directly from Arthur R M, Ross M W, Moloney P J, Cheney M W 2003 *North American Thoroughbred*, in Ross MW, Dyson SJ (eds) *Diagnosis and management of lameness in the horse*. Saunders Company, Philadelphia: 869¹ and Pilsworth R C 2003 *The European Thoroughbred*, in Ross MW, Dyson SJ (eds) *Diagnosis and management of lameness in the horse*. Saunders Company, Philadelphia: 879-894²⁶)

North America¹

Handicap and allowance races are set up to even the race by varying the weight carried by the horse. Weight variation is a subjective value, determined by racing officials for handicap races. In allowance races, weight variation is determined by a set of published criteria. For example 3-year-olds carry less weight than older horses, fillies less than colts, and non-winners may get additional weight off.

Most races in the United States are claiming races. In claiming races, horses of similar ability are pitted together. Because of the risk of losing a horse by claim, owners and trainers are discouraged from running more valuable horses to steal a purse.

Stakes are the highest level of competition and are entered by the best horses. Stakes races are raced according to sex, age, distance, and surface. Stakes races are graded, listed or restricted. Restricted stakes races restrict eligibility to the state of foaling or to conditions similar to allowance races. Stakes can be handicaps, allowances, or weight for age races. In weight for age races all horses carry the same weight, except for the well-established allowances for age and sex. The best stakes races are graded by a national committee and classified as Grade 1, Grade 2, and Grade 3, Grade 1 races are the top races. Graded stakes races are similar to the group or pattern race classification in Europe.

Non-stakes races fall into several categories. Maiden races are for horses that have never won a race and can be allowance or claiming races. Races can be restricted to horses that have not won a certain number of lifetime starts. Other specific conditions for races can include eligibility for horses that have not won a race in a certain time period or over a certain distance. Claiming races also are restricted by age, sex, distance, and surface.

Stakes races are predominantly for horses 2 and 3 years of age, whereas horses may continue to race in claiming races up to 10 to 12 years of age. Claiming horses may drop progressively in class and value, and the lowest level of Thoroughbred racing in the United States is considerably below that of the UK.

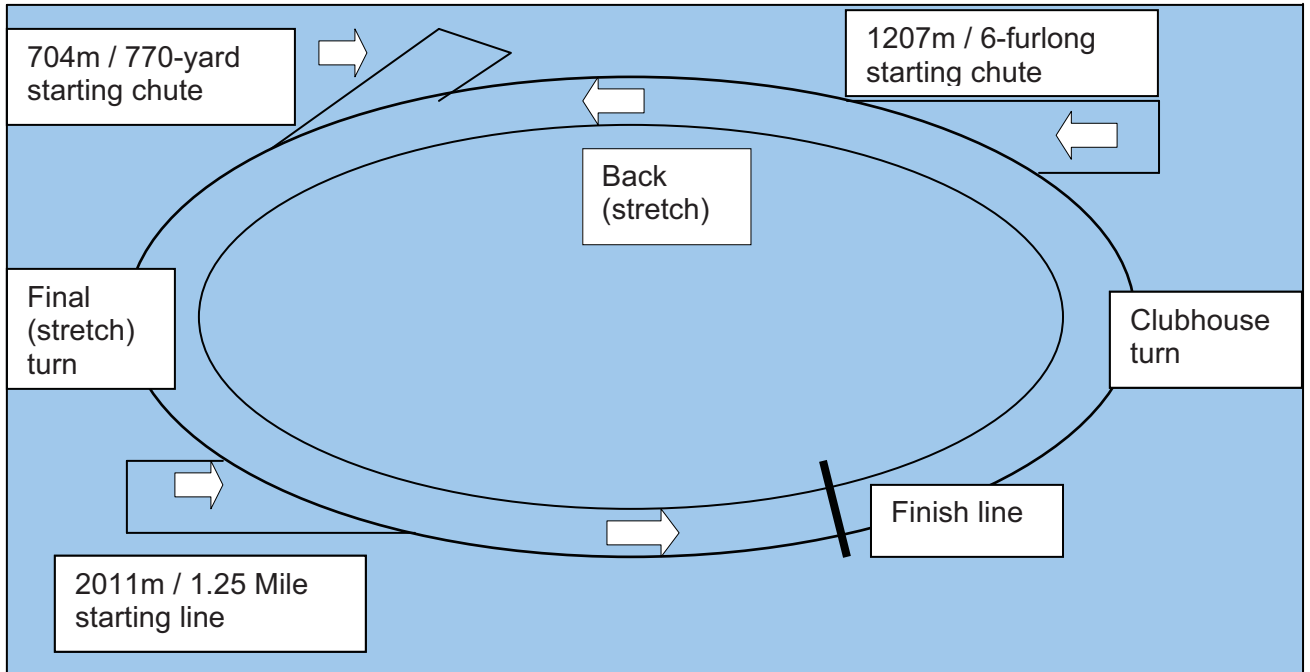
Europe²⁶

The best horses competing at top level meet each other in a group of internationally acknowledged races known as Group 1. This group includes all of the classics in the UK and the most prestigious races throughout Europe and North America. Group 2 and Group 3 races are for horses that have excellent ability but are not up to the extreme rigors of Group 1 racing. Competitors in these races face a weight for performance penalty system. A group 1 winner running in a group 2 race will carry a weight penalty in an attempt to equalize the competition.

The next tier down from group races are Listed races. Again the International Pattern Committee decides which races are of sufficient stature to belong to this list. Usually horses enter a Listed race when they have already won a maiden and possibly another race with specific conditions. Such horses have few other realistic options, because after two wins a horse carries a lot of weight in an open handicap.

APPENDIX B

Schematic representation of the typical outlay of a North American racetrack





APPENDIX C

Horse identification and relevant racing history for 22 horses

No of CHI	Horse details			Racing History					Injury details										Racetrack details					Race details									
	ID Horse	Gender	Date of birth	Age (years)	Total no. of previous starts	No. of seasons raced	Age at first start (months)	Racing frequency	Career wins	Date of CHI	Limb affected	unaxial psb #	bisaxial psb #	midbody#	apical #	abaxial #	axial #	basal #	distal sesamoidan ligament	luxated MCPJ	open #	closed #	contused #	condylar #	Location on track where injury occurred	Name of track	Race direction	Surface type	Surface condition	Race distance (m)	Gate position	Raced around bend / straight	Jockey weight (kg)
1	EG gelding	08/10/1994	3	7	2	29	14d; 2m; 1.5m scratched; 20d 14d; 18m prior to last race.	0	31/03/1998 RF																1800m	Newmarket	clockwise	turf	firm	2400	2	1.5	57
2	2HL colt	10/11/1994	3	2	3	25		0	30/06/1998 LF																1200m	Gosforth	clockwise	turf	good	1600	2	2	54.5
3	11C filly	11/12/1995	2	12	3	22	4d; 7d	0	05/08/1998 LF																450m	Vaal Turf	clockwise	turf	good	1000	14	straight	57
4	17HL colt	1/11/1996	3	1	1	34	17d.	0	12/09/1998 LF																500m	Vaal Turf	clockwise	turf	firm	1700	6	1	57
5	3HL colt	07/09/1997	2	0	1	25	never raced before	0	12/10/1998 LF																400m	Newmarket	clockwise	turf	good	800	6	straight	57
6	18HL filly	18/11/1995	4	64	3	29	2d; 7d; 2d; 5d... 7d; 12d;	1	07/03/2000 LF																1400m	Newmarket	clockwise	turf	soft	2000	8	1	54.5
7	16HL gelding	27/10/1993	6	29	5	32	Scratched; 29d	5	07/03/2000 RF																100m	Newmarket	clockwise	turf	soft	1300	8	Dog's leg	56.5
8	4HL gelding	08/11/1991	9	70	7	31	23d; 21d	8	28/09/2000 RF																1400m	Turfontein	clockwise	turf	good	2000	2	1	55.5
9	5HL gelding	12/10/1997	3	2	2	32	93d; 25d	0	30/09/2000 LF																FINISH	Turfontein	clockwise	turf	firm	1200	straight	59.5	
10	6HL colt	25/09/1998	2	3	1	23	13d; 10d; 21d	0	06/01/2001 LF																300m	Gosforth	clockwise	turf	good	1000	1	straight	57
11	7HL gelding	22/08/2000	3	4	2	31	42d; 7d; 6.5m	0	24/02/2001 LF																700m	Turfontein	clockwise	turf	soft	1000	12	straight	59.5
12	8HL gelding	04/09/1997	3	7	2	3	23d; 23d; 16d	1	15/03/2001 LF																250m	Turfontein	clockwise	turf	good	1400	11	1	55.5
13	9HL mare	26/09/1997	3	17	2	27	18d; 12d; 21d; 30d;	3	16/04/2001 RF																500m	Turfontein	clockwise	turf	good	2450	9	2	57
14	10HL gelding	19/08/1997	3	10	1	39	20d; 17d; 9d...	1	12/05/2001 LF																Pullup	Gosforth	clockwise	turf	good	1000	8	straight	59.5
15	11HL gelding	29/09/1998	3	5	2	29	34d; 58d; 30d	2	18/08/2001 LF																Pullup	Turfontein	clockwise	turf	good	1200	14	straight	56
16	13HL gelding	15/08/1998	3	2	1	40	19d; 13d	0	19/01/2002 LF																Pullup	Gosforth	clockwise	turf	good	1600	16	2	54
17	FBB gelding	12/10/1998	3	13	2	32	18d; 10d; 7d; 21d.	0	30/03/2002 LF																400m	Turfontein	clockwise	turf	good	1400	3	1	60
18	13/1HL gelding	12/09/1997	4	45	3	31	12d; 14d; 8d	1	28/05/2002 RF																900m	Newmarket	clockwise	turf	good	1600	6	1	60
19	15/2HL mare	22/11/1996	6	53	4	35	7d ; 20d; 3d; 11d	0	07/09/2002 LF																300m	Turfontein	clockwise	turf	good	1600	6	1	58
20	15/1 HL colt	09/09/1999	3	10	2	2	21d; 41d; 25d	5	29/03/2003 LF																450m	Turfontein	clockwise	turf	good	1800	11	1	57
21	15/3HL gelding	10/10/2000	3	1	2	38	4m	0	08/04/2004 LF																150m	Vaal Turf	clockwise	turf	good	1300	16	1	58
22	16-1HL gelding	02/11/1999	6	7	2	44	51d; 53 prior; 7m prior	0	01/08/2004 LF																400m	Turfontein	clockwise	turf	good	1600	6	1	56.5

L = lateral M = medial d = day m = month # = fracture LF = left forelimb RF = right forelimb Hx = history



APPENDIX D

Horse identification and relevant racing history for 55 horses

	date of CMI	size of field	draw	weight (kg)	racetrack	distance (m)	date of birth	age (years)	total starts	age at first start	gender	going	racing interval (days)
1	31/10/1998	16	9	57	Gosforth Park	1300	31/10/1995	3	7	3	G	good	32
2	15/11/1998	15	6	57	Gosforth Park	1700	03/10/1995	3	7	3	C	good	40
3	17/11/1998	15	13	57	Newmarket	1300	16/09/1995	3	21	3	C	good	4
4	15/12/1998	16	14	57	Newmarket	1000	12/09/1995	3	16	3	C	good	23
5	05/08/1999	14	14	57	Vaal	1000	11/12/1995	3	12	2	C	good	4
6	12/09/1999	9	6	57	Vaal	1700	17/11/1996	2	1	3	C	firm	17
7	16/09/1999	11	3	57	Vaal	1600	31/08/1995	4	24	3	M	good	11
8	26/09/1999	18	11	57	Turffontein	1100	16/11/1996	2	0	3	C	good	
9	01/02/2000	16	16	54.5	Newmarket	1300	26/09/1996	3	13	3	C	good	3
10	07/03/2000	15	8	54.5	Newmarket	2000	18/11/1995	4	64	3	C	soft	2
11	07/03/2000	14	8	56.5	Newmarket	1300	27/10/1993	5	29	3	G	soft	7
12	01/04/2000	8	1	55.5	Turffontein	2000	20/11/1995	4	14	3	G	soft	21
13	25/09/2000	9	2	55.5	Turffontein	2000	09/11/1991	5	70	3	H	good	23
14	30/09/2000	10	10	59.5	Turffontein	1200	12/10/1997	2	2	3	G	firm	93
15	12/10/2000	14	10	58	Newmarket	1300	12/10/1995	5	29	3	G	good	5
16	19/10/2000	15	6	57	Newmarket	1300	09/09/1997	3	4	3	H	good	12
17	19/10/2000	13	3	57	Newmarket	2400	12/09/1996	4	30	3	G	good	5
18	06/01/2001	6	1	57	Gosforth Park	1000	25/09/1998	2	3	2	H	good	13
19	24/02/2001	13	12	59.5	Turffontein	1000	22/08/1997	3	5	3	G	soft	42
20	11/03/2001	14	11	55.5	Turffontein	1400	04/09/1997	3	7	3	G	good	45
21	16/04/2001	14	9	57	Turffontein	2450	26/09/1997	3	17	2	C	good	18
22	12/05/2001	13	8	59.5	Gosforth Park	1000	19/08/1997	3	10	3	G	good	37
23	19/07/2001	20	2	56	Vaal	1400	09/09/1993	5	23	3	G	good	18
24	18/08/2001	14	14	56	Turffontein	1200	29/09/1998	2	6	3	G	good	35
25	29/11/2001	12	7	53	Gosforth Park	1900	11/11/1996	5	24	3	G	soft	42
26	19/01/2002	16	16	54	Gosforth Park	1600	15/08/1998	3	3	3	G	good	20
27	09/02/2002	14	1	58	Newmarket	1000	18/10/1997	4	22	2	G	good	7
28	30/03/2002	11	3	60	Turffontein	1400	12/10/1998	3	13	3	G	good	18
29	02/04/2002	15	13	58	Vaal	1200	09/10/1998	3	5	3	G	good	35
30	25/05/2002	15	14	55.5	Newmarket	1200	26/08/1997	4	6	4	M	good	24
31	28/05/2002	14	6	60	Newmarket	1600	12/09/1997	4	45	3	G	good	26
32	09/06/2002	16	7	58	Turffontein	1200	13/10/1998	3	6	3	H	good	43
33	07/09/2002	10	6	58	Turffontein	1600	22/11/1996	5	53	3	M	good	7
34	26/09/2002	12	3	55	Vaal	1600	30/11/1998	3	20	3	G	good	9
35	29/10/2002	14	12	50	Newmarket	1200	09/10/1997	5	13	3	G	good	37
36	28/11/2002	13	4	52.5	Vaal	2000	13/11/1996	5	28	3	G	good	14
37	14/01/2003	13	3	58	Newmarket	1000	21/10/1999	3	2	3	M	good	35
38	23/01/2003	12	10	58	Vaal	1000	15/09/1999	3	19	3	M	good	12
39	06/03/2003	11	6	58	Vaal	1000	26/09/1999	3	6	3	G	good	10
40	08/03/2003	10	2	54	Turffontein	1400	13/11/1998	4	17	3	G	good	32
41	29/03/2003	14	11	57	Turffontein	1800	09/09/1999	3	10	3	C	good	21
42	27/07/2003	12	11	58	Newmarket	1200	07/09/1998	4	5	3	M	good	173
43	03/08/2003	11	3	58	Newmarket	1000	28/08/2000	2	10	3	M	good	15
44	14/08/2003	10	1	58	Vaal	1400	18/09/2000	2	1	3	G	good	75
45	27/11/2003	11	4	57	Newmarket	800	16/10/2001	2	1	2	H	soft	9
46	01/04/2004	19	7	54	Vaal	1400	03/10/1999	4	5	3	G	good	9
47	08/04/2004	20	16	58	Vaal	1300	10/10/2000	3	1	3	G	good	123
48	12/04/2004	13	13	48	Turffontein	3000	20/08/1998	5	39	3	G	good	198
49	16/05/2004	8	6	60	Turffontein	1800	02/11/1998	5	27	3	M	good	10
50	29/05/2004	13	13	58	Turffontein	1200	03/10/2000	3	6	2	G	good	13
51	29/05/2004	13	5	58	Turffontein	1200	29/08/2000	3	3	4	G	good	80
52	01/08/2004	10	6	56.5	Turffontein	1600	02/11/1999	4	7	4	G	good	52
53	09/09/2004	15	10	53.5	Vaal	1600	01/10/2000	3	2	4	C	good	42
54	20/09/2004	10	5	58	Vaal	1000	18/10/1998	5	46	2	G	good	25
55	30/10/2004	15	11	58	Newmarket	3200	11/09/1996	5	46	3	G	good	23



APPENDIX E

Equine distal limb fracture radiology report

Patient: *EG*

Limb: LF *RF* LH RH

Clinician: Dr I Cilliers

Date: 30/05/2006

- Articular fracture*
- Non-articular

- Open fracture
- Closed fracture*
- Displaced*
- Non-displaced

- Distal radius
- Proximal row of carpal bones
- Distal row of carpal bones
- Proximal metacarpus
- Mid metacarpus
- Distal metacarpus
- Proximal sesamoid bones*
- Proximal phalanx 1*
- Distal phalanx 1
- Phalanx 2
- Phalanx 3
- Distal sesamoid bone
- Other

- Medial proximal sesamoid bone*
- Lateral proximal sesamoid bone*
- Base
- Body - medial*
 - Transverse
 - Sagittal
- Apex - lateral*
- Abaxial
- Axial
- Comminuted

- Medial MCIII condyle
- Lateral MCIII condyle

Report:

DPa view: Medial psb: Complete transverse displaced mid-body #. Apical fragment displaced proximally. Fracture gap = 4mm.

Lateral psb: Apical fracture. The apical fragment is less radiodense and hardly displaced. The axial surface of the lat psb is irregular and less radiodense (likely due to intersesamoidean ligament rupture)

LM view: Mid-body of medial psb (ascertained on DPa view). Apical # of lat psb. Both sesamoids apices are club-shaped (DJD)

Osteochondral fragment dorsally in fetlock joint. Fracture bed most likely dorso-proximal Ph1.

DLPaM Oblique view: Basal abaxial surface of lateral psb has a small osteophyte. Rest same as above.

DMPaL Oblique view: At abaxial surface of basal fragment of medial psb a possible additional small fragment seen. Within the fracture gap of the med psb a small osteochondral fragment also visible.

Dx:

LF biaxial psb fracture. Medial psb mid body fracture with comminution. Lateral psb apical fracture. Both psb's show signs of moderate DJD. Osteochondral fragment dorsally in joint.



APPENDIX E

Equine distal limb fracture radiology report

Patient: *FBB*

Limb: *LF RF LH RH*

Clinician: Dr I Cilliers

Date: 30/05/2006

- Articular fracture*
- Non-articular

- Open fracture*
- Closed fracture
- Displaced*
- Non-displaced

- Distal radius
- Proximal row of carpal bones
- Distal row of carpal bones
- Proximal metacarpus
- Mid metacarpus
- Distal metacarpus
- Proximal sesamoid bones*
- Proximal phalanx 1*
- Distal phalanx 1
- Phalanx 2
- Phalanx 3
- Distal sesamoid bone
- Other

- Medial proximal sesamoid bone*
- Lateral proximal sesamoid bone*
- Base
- Body (medial)*
 - *Oblique transverse*
 - Sagittal
- Apex - (lateral)*
- Abaxial
- Axial
- Comminuted

- Medial MCIII condyle
- Lateral MCIII condyle

Report:

DPa view: LF biaxial psb #.

Medial psb: mid-body complete displaced comminuted oblique fracture. Proximal fragment displaced abaxially and distally superimposing partially over basal fragment.

Lateral psb: Suspected apical fracture likely as the proximal abaxial border is very irregular.

Small bony fragment visible laterally at level of epicondyle. Fragment measures 5 x 2mm

Joint space widened laterally possibly as a result of collateral ligament disruption/stretching.

Irregular circumscribed squarish mineralized opacities dorsal to both psb's in region of IOM branches.

LM view: biaxial psb #. Apical fragment displaced 10mm proximally. Palmar aspect of one psb with apical # is irregular. The Palmar aspect of the condyle is also very irregular. The other psb's fracture fragments are overlapping and superimposed over each other. A small chip fragment is visible within the joint dorso-proximal to Ph1.

DLPaM Oblique view: Lat psb apical border very irregular. Medial psb positioned almost horizontally.

DMPaL Oblique view: Lat psb irregular surface apically. Fracture gap of medial psb =11mm. Apical fragment displaced abaxially. An additional two bony opacities visualized palmaro-medially and rectangular in shape (7 x 20mm). The proximal opacity seems to flow into or envelope the mineralized opacities in region of medial branch of IOM.

Dx:

LF Biaxial psb #. Displaced mid-body medial psb fracture. Apical fracture of lateral psb. Small osteochondral fragment off dorso-lateral proximal Ph1. Possible mineralization of branches of IOM?



APPENDIX E

Equine distal limb fracture radiology report

Patient: 1IC

Limb: *LF* RF LH RH

Clinician: Dr I Cilliers

Date: 12/05/2006

- Articular fracture*
- Non-articular

- Open fracture*
- Closed fracture
- Displaced*
- Non-displaced

- Distal radius
- Proximal row of carpal bones
- Distal row of carpal bones
- Proximal metacarpus
- Mid metacarpus
- Distal metacarpus
- Proximal sesamoid bones*
- Proximal phalanx 1*
- Distal phalanx 1
- Phalanx 2
- Phalanx 3
- Distal sesamoid bone
- Other

- Medial proximal sesamoid bone*
- Lateral proximal sesamoid bone*
- Base -medial and lateral*
- Body
 - Transverse
 - Sagittal
- Apex
- Abaxial
- Axial
- Comminuted - lateral*
- Comminuted*
- Comminuted

- Medial MCIII condyle
- Lateral MCIII condyle

Report:

DPa view: Both psb's positioned further abaxially indicating rupture of intersesamoidean ligament
Med psb basilar fracture with basilar fracture fragment positioned more axially; fracture gap = 5mm
Lat psb basilar fracture and comminuted; three different fragments visible:

- 11 fragment 5 x 5mm positioned within fracture gap
- 12 fragment 10 x 10mm distal to first fragment (1)
- 13 fragment 10 x 6mm distal to second fragment (2) and displaced more axially

LM view: Biaxial psb fracture: transverse basilar fracture. The lat psb (identified in DPa view) shows comminution of the basilar fragment as a less dense bony opacity is seen further distal to the base of the opposite psb. A small bony chip fragment is visible dorsally to the dorso-proximal aspect of Ph1. Small radiolucent areas over the proximal dorsal condyle is also seen.

DLPaM Oblique view: Lat psb comminuted basilar fracture - all three fragments aligned vertically one above the other.
Med psb - complete basal fracture

DMPaL Oblique view: same fractures noted

Dx:

Biaxial basilar psb fractures with lat psb basilar fragment being comminuted (3 fragments). Small osteochondral fragment (chip fracture) visible dorsal to dorso-proximal Ph1.



APPENDIX E

Equine distal limb fracture radiology report

Patient: <i>ZHL</i> Limb: <i>LF RF LH RH</i>	Clinician: Dr I Cilliers Date: 25/05/2006
<input type="checkbox"/> <i>Articular fracture</i> <input type="checkbox"/> Non-articular	<input type="checkbox"/> Open fracture <input type="checkbox"/> <i>Closed fracture</i> <input type="checkbox"/> <i>Displaced</i> <input type="checkbox"/> Non-displaced
<input type="checkbox"/> Distal radius <input type="checkbox"/> Proximal row of carpal bones <input type="checkbox"/> Distal row of carpal bones <input type="checkbox"/> Proximal metacarpus <input type="checkbox"/> Mid metacarpus <input type="checkbox"/> Distal metacarpus <input type="checkbox"/> <i>Proximal sesamoid bones</i> <input type="checkbox"/> <i>Proximal phalanx 1</i> <input type="checkbox"/> Distal phalanx 1 <input type="checkbox"/> Phalanx 2 <input type="checkbox"/> Phalanx 3 <input type="checkbox"/> Distal sesamoid bone <input type="checkbox"/> Other	<input type="checkbox"/> <i>Medial proximal sesamoid bone</i> <input type="checkbox"/> <i>Lateral proximal sesamoid bone</i> <input type="checkbox"/> Base <input type="checkbox"/> <i>Body - medial</i> <ul style="list-style-type: none"> ▪ Transverse ▪ Sagittal <input type="checkbox"/> <i>Apex - lateral</i> <input type="checkbox"/> Abaxial <input type="checkbox"/> Axial <input type="checkbox"/> Comminuted
	<input type="checkbox"/> <i>Medial MCIII condyle</i> <input type="checkbox"/> <i>Lateral MCIII condyle</i>

<p>Report:</p> <p>DPa view: Medial psb: Complete transverse displaced mid-body #. Apical fragment displaced proximally. Fracture gap = 4mm. Lateral psb: Apical fracture. The apical fragment is less radiodense and hardly displaced. The axial surface of the lat psb is irregular and less radiodense (likely due to intersesamoidean ligament rupture)</p> <p>LM view: Mid-body of medial psb (ascertained on DPa view). Apical # of lat psb. Both sesamoids apices are club – shaped (DJD) Osteochondral fragment dorsally in fetlock joint. Fracture bed most likely dorso-proximal Ph1.</p> <p>DLPaM Oblique view: Basal abaxial surface of lateral psb has a small osteophyte. Rest same as above.</p> <p>DMPaL Oblique view: At abaxial surface of basal fragment of medial psb a possible additional small fragment seen. Within the fracture gap of the med psb a small osteochondral fragment also visible.</p> <p>Dx: LF biaxial psb fracture. Medial psb mid body fracture with comminution. Lateral psb apical fracture. Both psb's show signs of moderate DJD. Osteochondral fragment dorsally in joint.</p>
--



APPENDIX E

Equine distal limb fracture radiology report

Patient: *3HL*

Limb: *LF RF LH RH*

Clinician: Dr I Cilliers

Date: 17/08/2005

- Articular fracture*
- Non-articular

- Open fracture
- Closed fracture*
- Displaced*
- Non-displaced

- Distal radius
- Proximal row of carpal bones
- Distal row of carpal bones
- Proximal metacarpus
- Mid metacarpus
- Distal metacarpus
- Proximal sesamoid bones*
- Proximal phalanx 1
- Distal phalanx 1
- Phalanx 2
- Phalanx 3
- Distal sesamoid bone
- Other

- Medial proximal sesamoid bone*
- Lateral proximal sesamoid bone*
- Base
- Body*
 - *Transverse*
 - Sagittal
- Apex
- Abaxial Axial
- Comminuted

- Medial MCIII condyle*
- Lateral MCIII condyle*

Report:

DPa view:

Biaxial midbody fractures of psb. Medial psb's fracture further distal than that of the lateral psb. Fracture gap medial = 6mm; lateral = 7mm.

LM view:

Transverse midbody fracture visible. On dorsal aspect of one psb a sliver like fragment visible (12x4mm).

DLPaM Oblique view:

Lat psb: Midbody fracture. Thin linear vascular channels visible in proximal fragment.

The medial psb midbody fracture. Fracture gap larger (12mm) axially than abaxially (3mm).

DMPaL Oblique view:

Same fractures as described above. The distal fragment of the medial psb has a pitted pyramidal shape. The lateral psb has an additional dorsal fragment which is displaced proximally.

Dx:

LF biaxial midbody psb fracture



APPENDIX E

Equine distal limb fracture radiology report

Patient: **4HL**

Limb: LF **RF** LH RH

Clinician: Dr I Cilliers

Date: 31/05/2006

- Articular fracture**
- Non-articular

- Open fracture
- Closed fracture**
- Displaced**
- Non-displaced

- Distal radius
- Proximal row of carpal bones
- Distal row of carpal bones
- Proximal metacarpus
- Mid metacarpus
- Distal metacarpus
- Proximal sesamoid bones**
- Proximal phalanx 1**
- Distal phalanx 1
- Phalanx 2
- Phalanx 3
- Distal sesamoid bone
- Other

- Medial proximal sesamoid bone
- Lateral proximal sesamoid bone**
- Base**
- Body
 - Transverse
 - Sagittal
- Apex
- Abaxial
- Axial
- Comminuted**

- Medial MCIII condyle
- Lateral MCIII condyle

Report:

DPa view: RF Lat psb basilar# and comminuted; fracture gap at its widest 7mm; three different fragments visible:

1. large apical fragment displaced proximally
2. axial basilar fragment 19 x 7mm
3. more abaxial positioned basilar fragment 10 x 7mm

LM view: uniaxial psb # : transverse basilar #; fracture gap = 7mm.

The lat psb (identified in DPa view) shows comminution of the basilar fragment: 2 fragments seen:

1. Large basilar fracture lies below displaced proximal fragment
 2. Smaller less dense mineralized opacity viewed caudal to the distal fragment
- A small osteophyte is visible dorsally to the dorso-proximal aspect of Ph1

DLPaM Oblique view: Lat psb comminuted basilar # - two distal fragments. The largest fragment is triangular in shape 25 x 7mm. A smaller less dense fragment is superimposed over the distal fragment and also lies within the fracture gap.

DMPaL Oblique view: same fractures noted
Medial psb NAD

Dx:

Uniaxial displaced comminuted basilar psb fracture of the lat psb of the RF (2 distal fragments). Small osteophyte visible dorso-proximal Ph1.



APPENDIX E

Equine distal limb fracture radiology report

Patient: **5HL**

Limb: **LF RF LH RH**

Clinician: Dr I Cilliers

Date: 09/05/2005

- Articular fracture**
- Non-articular

- Open fracture
- Closed fracture**
- Displaced**
- Non-displaced

- Distal radius
- Proximal row of carpal bones
- Distal row of carpal bones
- Proximal metacarpus
- Mid metacarpus
- Distal metacarpus
- Proximal sesamoid bones**
- Proximal phalanx 1**
- Distal phalanx 1
- Phalanx 2
- Phalanx 3
- Distal sesamoid bone
- Other

- Medial proximal sesamoid bone**
- Lateral proximal sesamoid bone**
- Base
- Body - medial**
 - **Transverse**
 - Sagittal
- Apex
- Abaxial
- Axial - lateral psb**
- Comminuted

- Medial MCIII condyle
- Lateral MCIII condyle

Report:

DPa view:

Medial psb midbody complete transverse fracture. Fracture gap = 1cm. The lateral condyle has an attached sliver distally approx 1-2mm in width (not seen on any other views). The distal fragment of the med psb is displaced distally over the jt surface. The lateral psb shows a crescent defect on its axial border.

LM view:

Psb transverse midbody fracture. Gap 1cm. The basal fragment is displaced distally. On the most palmar aspect of the distal fragment 4 x radiopacities 1-2mm in diameter.

DLPaM Oblique view: same as above

DMPaL Oblique view: 2-3 small radiopacities visible between fracture gap on its most caudal border. Rest same as above

Dx:

Mid-body fracture of med psb with comminution of its basal fragment. Axial fracture of lateral psb.



APPENDIX E

Equine distal limb fracture radiology report

Patient: *6HL*

Limb: *LF RF LH RH*

Clinician: Dr I Cilliers

Date: 01/06/2005

- Articular fracture*
- Non-articular

- Open fracture*
- Closed fracture
- Displaced*
- Non-displaced

- Distal radius
- Proximal row of carpal bones
- Distal row of carpal bones
- Proximal metacarpus
- Mid metacarpus
- Distal metacarpus*
- Proximal sesamoid bones*
- Proximal phalanx 1*
- Distal phalanx 1
- Phalanx 2
- Phalanx 3
- Distal sesamoid bone
- Other

- Medial proximal sesamoid bone*
- Lateral proximal sesamoid bone*
- Base
- Body*
 - Transverse
 - Sagittal
- Apex
- Abaxial
- Axial
- Comminuted*

- Medial MCIII condyle*
- Lateral MCIII condyle*

Report:

DPa view: MCIII luxated laterally and overriding phalanx 1. Condyles intact. Medial psb midbody fracture.

LM view: Psb mid-body fractures with displacement of fragments (some proximally; another palmaro-distally). Distal aspect of MCIII mottled most likely aro gas accumulation. Complete luxation of fetlock joint with MCIII displaced palmaro-distally.

DLPaM Oblique view: same

DMPaL Oblique view: same

Dx:

LF complete open luxation of fetlock joint with biaxial psb fractures.



APPENDIX E

Equine distal limb fracture radiology report

Patient: *7HL*

Limb: *LF RF LH RH*

Clinician: Dr I Cilliers

Date: 19/08/2005

- Articular fracture*
- Non-articular

- Open fracture
- Closed fracture*
- Displaced*
- Non-displaced

- Distal radius
- Proximal row of carpal bones
- Distal row of carpal bones
- Proximal metacarpus
- Mid metacarpus
- Distal metacarpus
- Proximal sesamoid bones*
- Proximal phalanx 1*
- Distal phalanx 1
- Phalanx 2
- Phalanx 3
- Distal sesamoid bone
- Other

- Medial proximal sesamoid bone*
- Lateral proximal sesamoid bone*
- Base
 - Body*
 - Transverse
 - Sagittal
- Apex
- Abaxial
- Axial
- Comminuted*

- Medial MCIII condyle
- Lateral MCIII condyle

Report:

DPa view:

Medial psb midbody fracture. The basal fragment has further fragmentation of its proximo-abaxial surface – this fragment is displaced proximo-abaxially. The apical fragment is also comminuted with a large axial fragment and a smaller abaxial fragment. The large axial fragment has an oblique less radiodense running over its surface (further fragmentation?)

Lateral psb also mid body fracture. Larger apical fragment with smaller basal fragment. The basal fragments abaxial surface is fractured further (comminuted) – small rectangular fragment situated abaxially and displaced a minimally. Basal fragment has also sustained an axial fracture – small fragment displaced axially.

LM view: psb mid-body comminuted fractures with displacement of apical fragment proximally.
A row of mineralized specks seen on distal aspect of MCIII in region of sagittal ridge.

DLPaM Oblique view: Lateral psb midbody fracture. Large apical fragment displaced proximally – basal fragment comminuted (2 fragments).
Medial psb midbody fracture. Comminution of apical fragment (3 fragments). Comminution of basal fragment (2 fragments)

DMPaL Oblique view: same fractures viewed as above

Dx:

LF biaxial midbody comminuted psb fractures.



APPENDIX E

Equine distal limb fracture radiology report

Patient: *BHL*

Limb: *LF RF LH RH*

Clinician: Dr I Cilliers

Date: 10/05/2006

- Articular fracture
- Non-articular*

- Open fracture
- Closed fracture*
- Displaced*
- Non-displaced

- Distal radius
- Proximal row of carpal bones
- Distal row of carpal bones
- Proximal metacarpus
- Mid metacarpus
- Distal metacarpus
- Proximal sesamoid bones*
- Proximal phalanx 1*
- Distal phalanx 1
- Phalanx 2
- Phalanx 3
- Distal sesamoid bone
- Other

- Medial proximal sesamoid bone*
- Lateral proximal sesamoid bone
- Base
 - Transverse
 - Sagittal
- Body
- Apex
- Abaxial*
- Axial
- Comminuted

- Medial MCIII condyle
- Lateral MCIII condyle

Report:

DPa view: Medial psb has a crescent shaped defect on its abaxial surface. Proximally and in mid med psb there is a linear rod shaped bony opacity visible. Just above the crescent defect a larger abaxial fragment is visible superimposed over the abaxial surface (20 x 6mm).
Lateral psb: NAD

LM view: Not a true LM view. Proximal to psb see:
1 x linear rod shaped fragment
1 x larger triangular fragment
1 x small round fragment

DLPaM Oblique view: Clubbing visible on apex of lat psb
4 x bony fragments of med psb superimposed over distal MCIII

DMPaL Oblique view: Triangular bony fragment displaced proximal to med psb.
Decreased opacity of abaxial surface with tunnel extending proximally in med psb.
Additional 2 x smaller fragments abaxio-dorsal of med psb.

Dx:

LF medial psb comminuted abaxial avulsion fracture. Early DJD of fetlock joint.



APPENDIX E

Equine distal limb fracture radiology report

Patient: *9HL*

Limb: LF *RF* LH RH

Clinician: Dr I Cilliers

Date: 10/05/2006

- Articular fracture*
- Non-articular

- Open fracture
- Closed fracture*
- Displaced*
- Non-displaced

- Distal radius
- Proximal row of carpal bones
- Distal row of carpal bones
- Proximal metacarpus
- Mid metacarpus
- Distal metacarpus
- Proximal sesamoid bones*
- Proximal phalanx 1*
- Distal phalanx 1
- Phalanx 2
- Phalanx 3
- Distal sesamoid bone
- Other

- Medial proximal sesamoid bone*
- Lateral proximal sesamoid bone
- Base
 - Transverse
 - Sagittal
- Apex*
- Abaxial
- Axial
- Comminuted*

- Medial MCIII condyle
- Lateral MCIII condyle

Report:

DPa view: Medial psb: Severely comminuted apical #. Comminuted fragments positioned abaxially. Apical fragment displaced

proximally. Fracture gap = 1mm.

Lateral psb: Axial surface slight decreased bone density.

LM view: Comminuted apical # of medial psb (ascertained on DPa view).

Dorsally at proximal aspect of sagittal ridge the MCIII has a moderate concavity (possible synovial pad hyperplasia)

DLPaM Oblique view: same as above

DMPaL Oblique view: same as above

Dx:

RF medial psb apical comminuted fracture. Possible signs of synovial pad hyperplasia



APPENDIX E

Equine distal limb fracture radiology report

Patient: **1OHL**

Limb: **LF RF LH RH**

Clinician: Dr I Cilliers

Date: 30/05/2005

- Articular fracture**
- Non-articular

- Open fracture
- Closed fracture**
- Displaced**
- Non-displaced

- Distal radius
- Proximal row of carpal bones
- Distal row of carpal bones
- Proximal metacarpus
- Mid metacarpus
- Distal metacarpus
- Proximal sesamoid bones**
- Proximal phalanx 1**
- Distal phalanx 1
- Phalanx 2
- Phalanx 3
- Distal sesamoid bone
- Other

- Medial proximal sesamoid bone**
- Lateral proximal sesamoid bone**
- Base
- Body**
 - **Transverse**
 - Sagittal
- Apex
- Abaxial
- Axial
- Comminuted**

- Medial MCIII condyle
- Lateral MCIII condyle**

Report:

DPa view:

Medial psb midbody complete transverse fracture. Fracture gap = 3mm. The proximal fragment of the med psb is displaced proximally. The lateral psb also has a midbody fracture slightly more oblique. The fracture gap is = 7m. The apical fragment of the lateral psb has a comminuted fracture off its abaxial distal surface. This fragment is displaced slightly distal.

LM view:

Psb mid body fracture. Fracture gap = 4mm. The proximal fragment is displaced proximally.

DLPaM Oblique view: same as above

DMPaL Oblique view: same as above

Dx:

Biaxial mid-body fracture of psb with comminution of the lateral psb apical fragment.



APPENDIX E

Equine distal limb fracture radiology report

Patient: **11HL**

Limb: **LF RF LH RH**

Clinician: Dr I Cilliers

Date: 10/05/2006

- Articular fracture**
- Non-articular

- Open fracture
- Closed fracture**
- Displaced**
- Non-displaced

- Distal radius
- Proximal row of carpal bones
- Distal row of carpal bones
- Proximal metacarpus
- Mid metacarpus
- Distal metacarpus**
- Proximal sesamoid bones**
- Proximal phalanx 1**
- Distal phalanx 1
- Phalanx 2
- Phalanx 3
- Distal sesamoid bone
- Other

- Medial proximal sesamoid bone**
- Lateral proximal sesamoid bone**
- Base
- Body**
 - Transverse
 - Sagittal
- Apex
- Abaxial
- Axial
- Comminuted - lateral**

- Medial MCIII condyle
- Lateral MCIII condyle

Report:

DPa view:

Medial psb complete mid-body transverse fracture near base. Fracture gap = 4mm.

Lateral psb comminuted midbody fracture. Fracture line runs obliquely starting axially about midbody. Large distal fragment.

On axial aspect of apical fragment a vertical parasagittal fracture line present. The axial fragment is 4mm wide. A small fragment 5 x 3mm present on proximo-abaxial surface of distal fragment and is triangular shape. A fragment 1.3 x 1cm seen abaxial to distal fragment and has rounded edges.

LM view:

2 oblique fracture lines visible over psb's.; one proximal and one further distal. Fracture gaps = approx 4mm.

DLPaM Oblique view:

Lateral psb midbody fracture fracture, fracture line transverse. Fracture gap = 8mm at its widest point. Small roundish fragment overlapping distal aspect of apical fragment.

Medial psb oblique fracture line through base of psb. Fracture gap = 4mm.

DMPaL Oblique view:

Basilar transverse fracture of medial psb. Fracture gap= 4mm. Vascular channels visible on abaxial surface of medial psb.

Dx:

LF closed displaced biaxial psb fractures. Midbody fracture of medial psb. Basilar fracture of lateral psb with comminution.



APPENDIX E

Equine distal limb fracture radiology report

Patient: **13HL**

Limb: **LF RF LH RH**

Clinician: Dr I Cilliers

Date: 18/08/2005

- Articular fracture**
- Non-articular

- Open fracture
- Closed fracture**
- Displaced**
- Non-displaced

- Distal radius
- Proximal row of carpal bones
- Distal row of carpal bones
- Proximal metacarpus
- Mid metacarpus
- Distal metacarpus
- Proximal sesamoid bones**
- Proximal phalanx 1
- Distal phalanx 1
- Phalanx 2
- Phalanx 3
- Distal sesamoid bone
- Other

- Medial proximal sesamoid bone**
- Lateral proximal sesamoid bone**
- Base
- Body**
 - Transverse
 - Sagittal
- Apex
- Abaxial
- Axial
- Comminuted**

- Medial MCIII condyle**
- Lateral MCIII condyle**

Report:

DPa view:

Multiple fractures of the medial psb. The largest fragment being at the base of the psb;triangular in shape with a fragment broken off axially and abaxially. Two axial fragments of proximal portion of psb. A larger abaxial fragment with a diagonal radiolucent line through the middle of the fragment. A moderately radiodensity proximal to psb on palmar aspect of MCIII. (chip# or mineralization within the IOM?? Or within palmar proximal pouch of fetlock?)

LM view:

Multiple linear radiolucent lines (3) dividing proximal aspect of psb into several fragments (4 fragments). The most distal fragment appears to be at approximately midbody level and appears to be approximately the same size to the fragment just above it (22 x 15mm). A triangular sliver fragment is just above this. Finally a semi-circular fragment with a flat base is also seen.

DLPaM Oblique view:

Lateral psb shows mild radiolucent lines on its abaxial surface.

Medial psb shows an oblique radiolucent line through its proximal third. Dorso-medially a small linear (4x2mm) radiodense fragment visualized just proximal to Ph1.

DMPaL Oblique view:

Large fragment at base of medial psb. A large distracted fragment approx 1cm at prox edge displaced abaxially. A large triangular fragment mid body region is displaced axially and proximally.

The apical fragment of the med psb (10x 11mm) has been displaced slightly proximally. Just above this 2 small linear fragments can be visualized.

Dorsolaterally a small linear radiodense fragment (4 x 2mm) can be visualized just proximal to Ph1.

Dx:

LF closed displaced comminuted midbody medial psb fracture.



APPENDIX E

Equine distal limb fracture radiology report

Patient: **13/1HL**

Limb: **LF RF LH RH**

Clinician: Dr I Cilliers

Date: 22/05/2006

- Articular fracture**
- Non-articular

- Open fracture**
- Closed fracture
- Displaced**
- Non-displaced

- Distal radius
- Proximal row of carpal bones
- Distal row of carpal bones
- Proximal metacarpus
- Mid metacarpus
- Distal metacarpus**
- Proximal sesamoid bones**
- Proximal phalanx 1**
- Distal phalanx 1
- Phalanx 2
- Phalanx 3
- Distal sesamoid bone
- Other

- Medial proximal sesamoid bone**
- Base
- Body**
 - **Transverse**
 - Sagittal
- Apex
- Abaxial
- Axial
- Comminuted**

- Medial MCIII condyle**
- Lateral MCIII condyle**

Report:

DPa view:

Open complete oblique displaced lateral condylar fracture involving the distal MCIII RF. The fracture arises just parasagittal to the sagittal ridge on its lateral side. The fracture line continues proximally and exits the lateral cortex at a height of about 67mm. Lateral condylar fragment is triangular in shape with a very sharp proximal point. The fragment is 67mm in length and displaced abaxially by 3mm. An additional vertical fracture line can be seen running 2mm lateral and parallel to the major fracture line. (possibly dorsal fracture line visible on a different plane). The fracture bed on the remaining cortex has an irregular but sharp border. The lateral psb is superimposed over its distal aspect and appears to be intact. The medial psb has sustained a midbody comminuted fracture with displacement of the apical fragment proximally (fracture gap = 12mm). 3 fragments visible: large basal and apical fragment with a smaller axial fragment positioned vertically and 5 x 18mm in size. This fragment is also displaced axially by 3mm.

LM view:

Triangular like mottled appearance to distal MCIII mainly over central and palmar aspect of MCIII = fracture bed. Comminuted displaced fracture of psb's. The basal fragment of one psb is more radiodense than the rest and displaced slightly distally. The proximal fragments are less radiodense. Unfortunately the most proximo-dorsal aspect of Ph1 is positioned outside the collimated area and an osteochondral fragment may be present in the joint space arising from Ph1.

DLPaM Oblique view:

Same oblique lateral condylar fracture seen. Displacement of fracture fragment greater proximally than closer to condyles. Medial psb midbody fracture: 3 fragments: axial and basal + rectangular vertically positioned additional fragment axial to basal fragment.

DMPaL Oblique view:

Same fractures as described above. Large displacement between apical and basal fragment of medial psb. Smaller fragment of medial psb now displaced proximally and closer to apical fragment than basal fragment.

Dx:

Complete open subluxated lateral condylar fracture of RF MCIII. Comminuted mid-body fracture of med psb (3 fragments).



APPENDIX E

Equine distal limb fracture radiology report

Patient: <i>15/1HL</i> Limb: <i>LF RF LH RH</i>	Clinician: Dr I Cilliers Date: 18/08/2005
<input type="checkbox"/> <i>Articular fracture</i> <input type="checkbox"/> Non-articular	<input type="checkbox"/> <i>Open fracture</i> <input type="checkbox"/> Closed fracture <input type="checkbox"/> <i>Displaced</i> <input type="checkbox"/> Non-displaced
<input type="checkbox"/> Distal radius <input type="checkbox"/> Proximal row of carpal bones <input type="checkbox"/> Distal row of carpal bones <input type="checkbox"/> Proximal metacarpus <input type="checkbox"/> Mid metacarpus <input type="checkbox"/> <i>Distal metacarpus</i> <input type="checkbox"/> <i>Proximal sesamoid bones</i> <input type="checkbox"/> <i>Proximal phalanx 1</i> <input type="checkbox"/> Distal phalanx 1 <input type="checkbox"/> Phalanx 2 <input type="checkbox"/> Phalanx 3 <input type="checkbox"/> Distal sesamoid bone <input type="checkbox"/> Other	<input type="checkbox"/> <i>Medial proximal sesamoid bone</i> <input type="checkbox"/> Base <input type="checkbox"/> <i>Body</i> <ul style="list-style-type: none"> ▪ <i>Transverse</i> ▪ Sagittal <input type="checkbox"/> Apex <input type="checkbox"/> Abaxial <input type="checkbox"/> Axial <input type="checkbox"/> <i>Comminuted</i>
Report:	<input type="checkbox"/> <i>Medial MCIII condyle</i> <input type="checkbox"/> <i>Lateral MCIII condyle</i>
<p><i>DPa view:</i> Complete open oblique displaced lateral condylar fracture of LF. The fracture line through the lateral condyle is parasagittal to the sagittal ridge towards the lateral aspect. The fractured fragment of the distal lateral condyle is triangular shape and approximately 8cm in length. The lateral condyle is in contact with proximo-lateral Ph1. The medial condyle is luxated medially. The distal aspect of the MCIII just above the condyle has a mottled appearance (gas accumulation aro open #). Superimposed over the distal MCIII are 4 fragments that make up the medial psb. There is a large basal fragment (26 x 14mm); a large apical fragment with a vertical radiolucent line running from its base proximally – the gap being +/- 1mm. Distal to this apical fragment is an irregular rectangular fragment 5 x 10mm. The lateral psb is rotated medially. On the lateral aspect of Ph1 there is a vertical radiolucent line with a small bony protuberance osteophyte arising from the proximal lateral aspct.</p> <p><i>LM view:</i> The medial condyle and distal MCII is completely disarticulated and displaced dorsally (by 5mm) and distally by 4 cm. The distal aspect of MCIII is mottled and has several vertical radiolucent lines running down it. The fracture bed can be determined on its lateral aspect as it appears triangular in shape and is more radiolucent. The lateral fragment haas a mottled appearance just proximal to the condyle (probably gas) and is aligned with Ph1. The fragment is approx 7.5cm in engh. On the palmar aspect of the lateral distal MCIII the psb's are visualized. The medial psb has 4 visible fragments. The basal fracture is large and radiodense. On this fragments proximo-palmar border a very radiodense oblong fragment can be seen (9 x 4mm). The large apical fragment has an irregular outline. On the palmar aspect of the lateral psb a triangular fragment 8x14x10mm is superimposed.</p> <p><i>DLPaM Oblique view:</i> Luxated medial condyle displaced dorso-medially and distally. Lateral psb: abaxial surface mildly irregular with a horizontal radiolucent line through the midbody area. Med psb: is superimposed over lateral condylar fragment. 4 fragments visible. Between large basal and apical fragments a radiodense rectangular fragment visible in # gap. Dorso-medial to this a triangular less radiodense fragment visualized. The lateral condylar fragment makes contact with the Ph1.</p> <p><i>DMPaL Oblique view:</i> Mottled appearance of distal MCIII. A curvilinear defect on dorso-lateral cortex of MCIII approx 7cm from joint surface. MCIII displaced distally. The large fragment of the med psb is displaced palmarly, smaller rectangular-like fragment seen just distal to it. The large basal fragment is superimposed over the distal MCIII.</p> <p>The tendinous structures can be seen palmarly – slightly radiodense.</p> <p><u>Dx:</u> Complete luxated lateral condylar fracture of LF MCIII with complete disarticulation of the metacarpophalangeal joint. Comminted mid-body fracture of med psb</p>	



APPENDIX E

Equine distal limb fracture radiology report

Patient: *15/2HL*

Limb: *LF RF LH RH*

Clinician: Dr I Cilliers

Date: 19/08/2005

- Articular fracture*
- Non-articular

- Open fracture
- Closed fracture*
- Displaced*
- Non-displaced

- Distal radius
- Proximal row of carpal bones
- Distal row of carpal bones
- Proximal metacarpus
- Mid metacarpus
- Distal metacarpus
- Proximal sesamoid bones*
- Proximal phalanx 1*
- Distal phalanx 1
- Phalanx 2
- Phalanx 3
- Distal sesamoid bone
- Other

- Medial proximal sesamoid bone*
- Base*
- Body
 - Transverse
 - Sagittal
- Apex
- Abaxial
- Axial
- Comminuted -sagittal # of basal fragment*

- Medial MCIII condyle
- Lateral MCIII condyle

Report:

DPA view: LF medial psb #. Medial psb: complete displaced basal fracture. The basal fragment is also sagittally fractured with a larger fragment axially (15 x 12mm) and a smaller fragment abaxially (10 x 6mm). The apical fragment is displaced proximally. Fracture gap = 10mm. On the medial aspect of Ph1 lipping of the joint margin is seen. The new bone is triangular in shape with its apex pointing proximally (enthesiophyte).

LM view: On the proximal aspect of the sagittal ridge dorsally there is a moderate concavity of the distal MCIII (synovial pad hyperplasia?). Both psb's show clubbing of both their proximal and distal aspects (DJD). One of the psb (med confirmed on other views) has a complete displaced basal #. The largest apical fragment is displaced proximally (1cm). The distal fragment appears to be displaced distally and rotated slightly dorsally. A 3rd sliver (2 x 8mm) is seen palmar to the aforementioned fragment.

DLPaM Oblique view: Lateral psb = NAD Medial psb: complete comminuted basal #. Large apical fragment with 2 smaller basal fragments, one much larger than the other (14 x 16mm vs 5 x 12mm). The smaller fragment located more abaxial.

DMPaL Oblique view: same #'s noted

Dx:

Medial comminuted displaced basal fracture.



APPENDIX E

Equine distal limb fracture radiology report

Patient: **15-3HL**

Limb: **LF RF LH RH**

Clinician: Dr I Cilliers

Date: 15/08/2005

- Articular fracture**
- Non-articular

- Open fracture
- Closed fracture**
- Displaced**
- Non-displaced

- Distal radius
- Proximal row of carpal bones
- Distal row of carpal bones
- Proximal metacarpus
- Mid metacarpus
- Distal metacarpus
- Proximal sesamoid bones**
- Proximal phalanx 1
- Distal phalanx 1
- Phalanx 2
- Phalanx 3
- Distal sesamoid bone
- Other

- Medial proximal sesamoid bone**
- Lateral proximal sesamoid bone**
- Base - medial - sagittal**
- Body - lateral**
 - Transverse
 - Sagittal
- Apex
- Abaxial
- Axial
- Comminuted

- Medial MCIII condyle
- Lateral MCIII condyle

Report:

DPa view:

Transverse oblique fracture of lateral psb. Proximal fragment is displaced proximally approx 5 mm.
Medial psb sagittal basal fracture. The fracture line extends proximally for a third of the length of the medial psb then changes to a horizontal direction to exit on the abaxial surface. A faint triangular line is visible at the base of the medial psb extending over the whole surface of the base.

LM view:

A horizontal fracture visible in one psb in distal third of body. The distal fragment is displaced distally for approx 4mm and the most distal border appears irregular.

DLPaM Oblique view:

Lat psb: Midbody fracture that transverses obliquely exiting more proximally on the abaxial surface.
The medial psb appears to have a sagittal basal fracture with a small fragment 3x2mm in diameter visible on the abaxial surface between the fracture gap. The fracture gap is displaced more on the disto-palmar aspect of the med psb.

DMPaL Oblique view:

Thin straight vascular channels visible. Midbody abaxial surface of medial psb appears more radiolucent than the rest of the psb as well as obliquely over base of medial psb.
Lateral psb radiolucent oblique midbody region indicative of fracture location.

Dx:

LF biaxial psb fracture: Medial psb sagittal basal #; Lateral midbody psb fracture.



APPENDIX E

Equine distal limb fracture radiology report

Patient: **16HL**

Limb: **LF RF LH RH**

Clinician: Dr I Cilliers

Date: 15/08/2005

- Articular fracture**
- Non-articular

- Open fracture
- Closed fracture**
- Displaced**
- Non-displaced

- Distal radius
- Proximal row of carpal bones
- Distal row of carpal bones
- Proximal metacarpus
- Mid metacarpus
- Distal metacarpus
- Proximal sesamoid bones**
- Proximal phalanx 1
- Distal phalanx 1
- Phalanx 2
- Phalanx 3
- Distal sesamoid bone
- Other

- Medial proximal sesamoid bone**
- Lateral proximal sesamoid bone**
- Base
- Body**
 - **Transverse**
 - Sagittal
- Apex
- Abaxial
- Axial
- Comminuted**

- Medial MCIII condyle**
- Lateral MCIII condyle**

Report:

DPa view:

Biaxial midbody fractures. Proximal fragment of medial psb displaced 5mm proximally; lateral psb displaced 6mm. Abaxially on both proximal fragments distally there appears to be an additional fragment (radiodense fragment with the lateral fragment being linear (5x1mm). Medial fragment more triangular in shape (12x6x6mm).

LM view:

Clubbing of psb's. mid horizontal fracture x 2 with proximal fragment being displaced 5mm proximally. On distal cranial third apical fragment 2 additional radiodense fragments visible:

1. irregular linear radiodense fragment approx 8x1mm
2. second fragment irregularly linear 10x2mm

Dorso-proximal Ph1 a well circumscribed loose osteochondral fragment (radiodense) seen (5x3mm) superimposed over sagittal ridge. Proximal dorsal aspect of Ph1 irregular. No fracture bed visible.

DLPaM Oblique view:

Midbody fracture of lateral psb with proximal fragment displaced proximally. Fracture gap=5mm. the distal fragment's axial surface shows an additional oblique fracture that runs from base of sesamoid obliquely to axial surface of distal fragment.

The midbody psb has a midbody transverse fracture with the prox fragment displaced 5mm proximally. On the abaxial surface between the 2 major fragments an additional radiodense fragment is visible (4x6x5mm).

On the dorso- medial aspect a concavity off the proximal phalanx is visible – fracture bed. 2 radiodense round chip fragments are superimposed over the medial condyle just proximal to Ph1.

DMPaL Oblique view:

Dorsolateral aspect of Ph1 mineralised rod shaped radiodense bodies appearing to be in a string stretched proximally (mineralization in capsule?).

Transverse midbody fracture of medial psb. Fracture gap=4-5mm. On axial surface of med psb just distal to apical fragment an additional rectangular radiodense fragment (5x3mm).

The lateral psb also has a transverse midbody fracture. The fracture ends appear to be fuzzy.

Dx:

RF biaxial midbody psb fracture with comminution of basal fragment of lateral psb. Osteochondral fragment off dorso-proximal surface of Ph1. Early signs of DJD.



APPENDIX E

Equine distal limb fracture radiology report

Patient: *16-1HL*

Limb: *LF RF LH RH*

Clinician: Dr I Cilliers

Date: 11/05/2006

- Articular fracture
- Non-articular

- Open fracture
- Closed fracture
- Displaced
- Non-displaced

- Distal radius
- Proximal row of carpal bones
- Distal row of carpal bones
- Proximal metacarpus
- Mid metacarpus
- Distal metacarpus
- Proximal sesamoid bones
- Proximal phalanx 1
- Distal phalanx 1
- Phalanx 2
- Phalanx 3
- Distal sesamoid bone
- Other

- Medial proximal sesamoid bone
- Lateral proximal sesamoid bone*
- Base
 - Transverse
 - Sagittal
- Apex
- Abaxial
- Axial
- Comminuted

- Medial MCIII condyle
- Lateral MCIII condyle

Report:

DPa view:

Both psb's are intact. They may however be displaced further proximally?. Lateral psb axial border proximally appears irregular. Vascular canals visible on both abaxial surfaces of both psb's.

LM view:

Vertical linear mineralized area caudal to palmar eminences of Ph1.

Psb = NAD

Possible chip # on dorso-proximal aspect of Ph1.

DLPaM Oblique view:

Vascular channels on abaxial surface mildly visible of lateral psb.

Possible chip #, minimally displaced off dorso-medial proximal aspect of Ph1.

DMPaL Oblique view:

Chip # off latero-dorso-proximal aspect of Ph1.

Medial psb vascular channels mildly visible on abaxial surface.

Dx:

RF osteochondral fragment off dorso-proximal surface of Ph1. Early signs of sesamoiditis. Psb's displaced further proximally – ruptured distal sesamoidean ligaments



APPENDIX E

Equine distal limb fracture radiology report

Patient: **17HL**

Limb: **LF RF LH RH**

Clinician: Dr I Cilliers

Date: 15/08/2005

- Articular fracture**
- Non-articular

- Open fracture**
- Closed fracture
- Displaced**
- Non-displaced

- Distal radius
- Proximal row of carpal bones
- Distal row of carpal bones
- Proximal metacarpus
- Mid metacarpus
- Distal metacarpus
- Proximal sesamoid bones**
- Proximal phalanx 1**
- Distal phalanx 1
- Phalanx 2
- Phalanx 3
- Distal sesamoid bone
- Other

- Medial proximal sesamoid bone**
- Lateral proximal sesamoid bone**
- Base
- Body**
 - **Transverse**
 - Sagittal
- Apex
- Abaxial
- Axial
- Comminuted**

- Medial MCIII condyle**
- Lateral MCIII condyle**

Report:

DPa view:

Moderate soft tissue swelling. Midbody lateral psb fracture. Proximal fragment displaced proximally. Fracture line runs transversely with an oblique angle with the axial aspect of the fracture line more proximal than the abaxial aspect. A separate small fragment is visible over the distal abaxial aspect of the proximal fragment. Fracture gap wider axially than abaxially.

LM view:

One psb is fractured in approximately 3 pieces. The proximal fragment displaced proximally. Midbody fracture of lateral psb. Distal to distal fragment an additional fragment visible which is displaced distally in direction of distal sesamoid ligaments.

DLPaM Oblique view:

Lateral psb midbody fracture. 2 large fragments visible with a third smaller fragment disto-abaxial to proximal fragment. A small fragment 3x2mm situated on dorso-lateral aspect of distal fragment.

DMPaL Oblique view:

Medial psb small linear vascular channels visible. Lateral psb midbody fracture. Fracture line transverse oblique with the highest line being axially. 3 Fragments visible. The proximal fragment appears to have fractured in two fragments. The axial and apical fracture being 3 times the size of the smaller abaxial fracture. The dorsolateral aspect of the distal MIII appears mottled (probably due to gas).

Dx:

Comminuted midbody lateral psb fracture.



APPENDIX E

Equine distal limb fracture radiology report

Patient: **18HL**

Limb: **LF RF LH RH**

Clinician: Dr I Cilliers

Date: 15/08/2006

- Articular fracture**
- Non-articular

- Open fracture
- Closed fracture**
- Displaced**
- Non-displaced

- Distal radius
- Proximal row of carpal bones
- Distal row of carpal bones
- Proximal metacarpus
- Mid metacarpus
- Distal metacarpus**
- Proximal sesamoid bones**
- Proximal phalanx 1**
- Distal phalanx 1
- Phalanx 2
- Phalanx 3
- Distal sesamoid bone
- Other

- Medial proximal sesamoid bone**
- Lateral proximal sesamoid bone**
- Base
- Body -medial**
 - **Transverse**
 - Sagittal
- Apex - lateral**
- Abaxial
- Axial
- Comminuted -both**

- Medial MCIII condyle
- Lateral MCIII condyle

Report:

DPa view:

Lateral psb displaced apical fracture. Fractured fragment displaced proximo-laterally. Proximql to proximal fragment a small radiodense fragment visible (4x2mm). A second small fragment less radiodense than that of abaxial surface also visible abaxial to apex of distal fragment.

Between proximal fragment of both sesamoids a triangular fragment visible – presumably the fracture arises from the axial surface of the lateral psb off the basal fragments proximal margin.

Comminuted midbody fracture. Two medium size triangular fragments visualized in fracture gap. Gap=4mm abaxially and 8mm axially. The abaxial aspect of the basal fragment appears less radiodense than the axial aspect – illusion due to curvature of condyle and where the collateral sesamoid ligaments attach.

LM view:

Not a true LM as slightly oblique.

The furthest psb bone shows a midbody fracture that is displaced proximally 4mm. The closer psb shows a midbody fracture more distal with the fracture gap much wider 12mm palmarly and 6mm dorsally. In the distal aspect of the proximal fragment a curvilinear radiolucent line visible probably aro superimposition of another fragment.

DLPaM Oblique view:

Lateral psb shows an apical fracture which is displaced proximally 4mm. Axial to the fracture gap is a less radiodense triangular fragment 8x8x8mm. Its # bed appears to be off the axial aspect of the proximal fragment. Medial psb shows a transverse oblique midbody #. The proximal fragment is displaced proximally. The # gap measures 7mm axially and 2mm abaxially. A large less radiodense triangular fragment is visible over the axial distal aspect of the proximal fragment. Moderate to severe lipping on dorso-medial aspect of Ph1 indicative of DJD.

DMPaL Oblique view:

The medial psb: midbody # with prox fragment displaced proximally. Gap = 5mm.

Lat psb: apical #. Proximal border of the distal fragment is irregular. On the most palmar aspect of the distal fragment a triangular less radiodense fragment is superimposed 9x9x12mm.

Distal to the medial psb on the palmar aspect of medial palmar eminence some radiodense bodies seen (mineralization in distal ses ligament?)

Dx:

Biaxial psb fractures. Comminuted midbody medial psb. Comminuted apical lateral psb.



APPENDIX E

Equine distal limb fracture radiology report

Patient: *MHL1*

Limb: *LF RF LH RH*

Clinician: Dr I Cilliers

Date: 29/05/2006

- Articular fracture*
- Non-articular

- Open fracture*
- Closed fracture
- Displaced*
- Non-displaced

- Distal radius
- Proximal row of carpal bones
- Distal row of carpal bones
- Proximal metacarpus
- Mid metacarpus
- Distal metacarpus
- Proximal sesamoid bones*
- Proximal phalanx 1*
- Distal phalanx 1
- Phalanx 2
- Phalanx 3
- Distal sesamoid bone
- Other

- Medial proximal sesamoid bone*
- Lateral proximal sesamoid bone*
- Base
- Body -medial*
 - Transverse*
 - Sagittal
- Apex - lateral*
- Abaxial
- Axial
- Comminuted

- Medial MCIII condyle
- Lateral MCIII condyle

Report:

DPa view: LF biaxial psb #.

Medial psb: mid-body open complete displaced transverse fracture. Proximal fragment displaced and rotated slightly abaxially.

Lateral psb: Complete apical fracture with slight displacement proximally.

LM view: biaxial psb #. Apical fragment of lateral psb displaced 10mm proximally. The medial psb's proximal fragment is displaced 18mm proximally.

DLPaM Oblique view: Lat psb apical fragment displaced proximally 7mm at its widest point. The Medial psb proximal fragment displaced 6mm proximally.

DMPaL Oblique view: same fracture noted as described above.

Dx:

LF Biaxial psb #. Open displaced mid-body medial psb fracture. Apical fracture of lateral psb.



APPENDIX E

Equine distal limb fracture radiology report

Patient: *MHL2*

Limb: LF *RF* LH RH

Clinician: Dr I Cilliers

Date: 11/05/2006

- Articular fracture*
- Non-articular

- Open fracture
- Closed fracture*
- Displaced*
- Non-displaced

- Distal radius
- Proximal row of carpal bones
- Distal row of carpal bones
- Proximal metacarpus
- Mid metacarpus
- Distal metacarpus
- Proximal sesamoid bones*
- Proximal phalanx 1*
- Distal phalanx 1
- Phalanx 2
- Phalanx 3
- Distal sesamoid bone
- Other

- Medial proximal sesamoid bone*
- Lateral proximal sesamoid bone*
- Base
- Body*
 - Transverse
 - Sagittal
- Apex
- Abaxial
- Axial
- Comminuted - medial + lat*

- Medial MCIII condyle
- Lateral MCIII condyle

Report:

DPa view: RF biaxial midbody psb #.

Medial psb: mid-body complete displaced comminuted fracture. Proximal fragment displaced proximally and consisting of 4 fragments. (2 large fragments one above the other with a smaller fragment axial to the apical fragment). Fracture gap = 7mm.

Lateral psb: Mid-body fracture. Fracture gap = 7mm. 2 tiny fragments visible on either side of the basal fragment. Axial surface of apical fragment irregular. Bulbous new bone smooth formation (splint) around button of lateral splint bone (MCIV).

LM view: biaxial psb #. Apical fragment displaced 8mm proximally. A small osteochondral fragment is visible within the joint dorso-proximal to Ph1. Splint on lateral MCIV has 2 spikes on palmar aspect

DLPaM Oblique view: Lat psb mid-body #. Fracture gap = 5mm. Bulbous new bone around button of metacarpus IV. Medial psb comminuted mid-body fracture. Small fragment displaced proximally and abaxially.

DMPaL Oblique view: Fracture gap of medial psb = 7mm. Comminution of proximal fragment.

Dx:

RF Biaxial mid-body comminuted psb #'s. Small osteochondral fragment in dorsal aspect of joint.



APPENDIX E

Equine distal limb fracture radiology report

Patient: *MHL2(2)*

Limb: LF *RF* LH RH

Clinician: Dr I Cilliers

Date: 31/05/2006

- Articular fracture*
- Non-articular

- Open fracture*
- Closed fracture
- Displaced*
- Non-displaced

- Distal radius
- Proximal row of carpal bones
- Distal row of carpal bones
- Proximal metacarpus
- Mid metacarpus
- Distal metacarpus
- Proximal sesamoid bones*
- Proximal phalanx 1*
- Distal phalanx 1
- Phalanx 2
- Phalanx 3
- Distal sesamoid bone
- Other

- Medial proximal sesamoid bone*
- Lateral proximal sesamoid bone*
- Base
 - Body - medial*
 - Transverse
 - Sagittal
- Apex
- Abaxial - lateral*
- Axial
- Comminuted

- Medial MCIII condyle
- Lateral MCIII condyle

Report:

DPa view: RF complete open luxation of metacarpophalangeal joint. Distal MCIII displaced medially.

Biaxial psb #. Medial psb: mid-body complete displaced fracture. Proximal fragment displaced proximally. Fracture gap = 15mm.

Lateral psb: Small fragment displaced abaxially from proximal aspect.

Button fractured off splint bone (MCII only identified at PM as obliquity of rads couldn't determine which splint bone it was).

LM view: Complete luxation of fetlock joint with MCIII displaced dorsally and distally. Mid-body fracture of one psb. Apical fragment displaced 12mm proximally at its caudal border.

DLPaM Oblique view: Same as above.

DMPaL Oblique view: Same as above.

Dx:

RF complete open luxation of metacarpophalangeal joint. Medial mid-body psb #'.
Small abaxial fragment off lateral psb. Fractured distal MCII (button) and mid-shaft MCIV.



APPENDIX E

Equine distal limb fracture radiology report

Patient: *MHL3*

Limb: *LF RF LH RH*

Clinician: Dr I Cilliers

Date: 24/05/2006

- Articular fracture*
- Non-articular

- Open fracture
- Closed fracture*
- Displaced*
- Non-displaced

- Distal radius
- Proximal row of carpal bones
- Distal row of carpal bones
- Proximal metacarpus
- Mid metacarpus
- Distal metacarpus
- Proximal sesamoid bones*
- Proximal phalanx 1
- Distal phalanx 1
- Phalanx 2
- Phalanx 3
- Distal sesamoid bone
- Other

- Medial proximal sesamoid bone*
- Lateral proximal sesamoid bone*
- Base -medial*
- Body -lateral*
 - *Transverse*
 - *Sagittal*
- Apex
- Abaxial Axial
- Comminuted -lateral**

- Medial MCIII condyle*
- Lateral MCIII condyle*

Report:

DPa view:

Midbody fracture of lateral psb. Lateral psb apical fragment is comminuted into 2 fragments ie one large apical fragment with a smaller axial fragment. The medial psb has sustained a transverse basal fracture. Both psb's proximal fragments are displaced proximally. Fracture gap medial = 3mm; lateral = 1mm.

LM view:

Basal fracture of medial psb (ascertained on DPa view) seen as a slight curvilinear line distally on psb's. The proximal fragment centrally is less radiodense indicating lysis or a further fracture line.

DLPaM Oblique view:

Lat psb: Midbody fracture. Fracture line runs obliquely with abaxial point being higher.
The medial psb basal fracture. Fracture gap larger = 6mm.

DMPaL Oblique view:

Midbody to basal fracture of medial psb. Small fragment of bone (radiodense superimposed in fracture gap. Vascular channels visible on abaxial surface of medial psb.

Dx:

LF biaxial psb fracture. Basal displaced fracture of medial psb. Comminuted displaced midbody fracture of lateral psb (apical fragment comminuted)



APPENDIX E

Equine distal limb fracture radiology report

Patient: *MHL4*

Limb: *LF RF LH RH*

Clinician: Dr I Cilliers

Date: 29/05/2006

- Articular fracture*
- Non-articular

- Open fracture*
- Closed fracture
- Displaced*
- Non-displaced

- Distal radius
- Proximal row of carpal bones
- Distal row of carpal bones
- Proximal metacarpus
- Mid metacarpus
- Distal metacarpus
- Proximal sesamoid bones*
- Proximal phalanx 1*
- Distal phalanx 1
- Phalanx 2
- Phalanx 3
- Distal sesamoid bone
- Other

- Medial proximal sesamoid bone*
- Lateral proximal sesamoid bone*
- Base
 - Body - medial*
 - Transverse
 - Sagittal
- Apex
- Abaxial - lateral*
- Axial
- Comminuted

- Medial MCIII condyle
- Lateral MCIII condyle

Report:

DPa view: LF complete open luxation of metacarpophalangeal joint. Distal MCIII displaced medially.

Biaxial psb #. Medial psb: mid-body complete displaced fracture. Proximal fragment displaced proximally. Fracture gap = 15mm.

Lateral psb: Small fragment displaced abaxially from proximal aspect.

Button fractured off splint bone (MCII only identified at PM as obliquity of rads couldn't determine which splint bone it was).

LM view: Complete luxation of fetlock joint with MCIII displaced dorsally and distally. Mid-body fracture of one psb. Apical fragment displaced 12mm proximally at its caudal border.

DLPaM Oblique view: Same as above.

DMPaL Oblique view: Same as above.

Dx:

RF complete open luxation of metacarpophalangeal joint. Medial mid-body psb #'.
Small abaxial fragment off lateral psb. Fractured distal MCII (button) and mid-shaft MCIV.



APPENDIX E

Equine distal limb fracture radiology report

Patient: *MHL5*

Limb: *LF RF LH RH*

Clinician: Dr I Cilliers

Date: 24/05/2006

- Articular fracture*
- Non-articular

- Open fracture
- Closed fracture*
- Displaced*
- Non-displaced

- Distal radius
- Proximal row of carpal bones
- Distal row of carpal bones
- Proximal metacarpus
- Mid metacarpus
- Distal metacarpus*
- Proximal sesamoid bones*
- Proximal phalanx 1*
- Distal phalanx 1
- Phalanx 2
- Phalanx 3
- Distal sesamoid bone
- Other

- Medial proximal sesamoid bone*
- Lateral proximal sesamoid bone*
- Base
- Body*
 - Transverse*
 - Sagittal
- Apex
- Abaxial Axial
- Comminuted - lateral*

- Medial MCIII condyle
- Lateral MCIII condyle

Report:

DPa view:

Biaxial midbody fracture of psb's. Apical fragment displaced far proximally and basal fragment displaced far distally superimposed over proximal Ph1. A further bony fragment visible medial to proximal aspect of condyle and is triangular in shape. Distal metacarpus luxated medially. On dorso-medial aspect of PH1 several small bony fragments visible.

LM view:

Distal MCIII luxated and displaced palmarly. Biaxial midbody fracture of psb's. Distal fragment at level of proximal thirs of Ph1. Apical fragments palmar to palmar cortical surface of MCII and displaced far proximally (one finger width higher than the proximal aspect of the condyles). An aditional fragment superimposed over dorsal aspect of MCIII at a slightly lower level than that of the proximal fragments of the psb's.

Dx:

RF biaxial midbody psb fracture. Basal fragments displaced far distally and apical fragments displaced far proximally. Complete luxation of metacarpophalangeal joint palmarly and medially.



APPENDIX E

Equine distal limb fracture radiology report

Patient: *MHL6*

Limb: *LF RF LH RH*

Clinician: Dr I Cilliers

Date: 26/05/2006

- Articular fracture*
- Non-articular

- Open fracture
- Closed fracture*
- Displaced*
- Non-displaced

- Distal radius
- Proximal row of carpal bones
- Distal row of carpal bones
- Proximal metacarpus
- Mid metacarpus
- Distal metacarpus
- Proximal sesamoid bones*
- Proximal phalanx 1
- Distal phalanx 1
- Phalanx 2
- Phalanx 3
- Distal sesamoid bone
- Other

- Medial proximal sesamoid bone*
- Lateral proximal sesamoid bone*
- Base - medial*
- Body - lateral*
 - Transverse*
 - Sagittal*
- Apex
- Abaxial Axial
- Comminuted

- Medial MCIII condyle*
- Lateral MCIII condyle*

Report:

DPa view:

Transverse oblique fracture of lateral psb. Proximal fragment is displaced proximally approx 4 mm. Basal fragment of lateral psb has a lip on its abaxial surface.

Medial psb transverse basal fracture. Proximal fragment is displaced proximally approx 4mm.

LM view:

A horizontal fracture visible in medial psb (determined on DPa view) in distal third of body. The apical fragment is displaced proximally with a wider gap palmarly. Another horizontal line is visualized (less defined) further proximally on the lateral psb. On the most palmar aspect of the lateral psb a saucershaped concavity is visible. An osteochondral fragment is visible dorso-proximal to Ph1. It is displaced approx 1mm.

DLPaM Oblique view:

Lat psb: Midbody fracture with basal fragment with the lip on its abaxial surface visible.
The medial psb has a neat transverse basal fracture.

DMPaL Oblique view:

Same as above. Additionally the vascular channels on the medial psb abaxial border are visible.

Dx:

LF biaxial psb fracture: Lateral psb midbody #; Medial psb basal fracture. Osteochondral fragment present dorso-proximal to Ph1.



APPENDIX E

Equine distal limb fracture radiology report

Patient: *MHL 7*

Limb: *LF RF LH RH*

Clinician: Dr I Cilliers

Date: 26/05/2006

- Articular fracture*
- Non-articular

- Open fracture*
- Closed fracture
- Displaced*
- Non-displaced

- Distal radius
- Proximal row of carpal bones
- Distal row of carpal bones
- Proximal metacarpus
- Mid metacarpus
- Distal metacarpus
- Proximal sesamoid bones*
- Proximal phalanx 1*
- Distal phalanx 1
- Phalanx 2
- Phalanx 3
- Distal sesamoid bone
- Other

- Medial proximal sesamoid bone*
- Lateral proximal sesamoid bone*
- Base
 - Transverse*
 - Sagittal*
- Body*
 - Transverse*
 - Sagittal*
- Apex
- Abaxial
- Axial
- Comminuted*

- Medial MCIII condyle*
- Lateral MCIII condyle*

Report:

DPa view: LF biaxial psb #.

Medial psb: mid-body complete displaced comminuted fracture; fracture gap at its widest 20mm; 3 fragments. Large apical and basal fragment with a small fragment positioned abaxially in the fracture gap just below apical fragment.

Lateral psb: mid-body complete displaced comminuted fracture; Fracture gap at its widest = 12mm. 3-4 fragments. Large apical and basal fragment with smaller fragment also positioned abaxially in fracture gap just above basal fragment. An additional suspect fragment seen on axial surface of apical fragment.

LM view: biaxial psb #. Fragments superimposed over each other.

DLPaM Oblique view: Lat psb comminuted mid-body # - three fragments ie large apical fragment; large basal fragment and much smaller fragment positioned midway in fracture gap. Fracture gap abaxially = 11mm; axially = 17mm. Medial psb mid-body # - three fragments with large apical and basal fragment with smaller fragment positioned within the fracture gap positioned closer to the apical fragment. Osteophyte visible on dorsomedial proximal aspect of Ph1 (djd)

DMPaL Oblique view: same #'s noted. Fracture gap of medial psb abaxially = 17mm and axially = 15mm. Vertical sliver fracture off dorsolateral aspect of proximal Ph1.

Dx:

Biaxial comminuted and displaced mid-body psb fractures of the LF. Small sliver osteochondral fragment off dorso-lateral proximal Ph1. Djd of fetlock joint (osteophyte dorsomedial Ph1).



APPENDIX E

Equine distal limb fracture radiology report

Patient: *MHL 8*

Limb: *LF RF LH RH*

Clinician: Dr I Cilliers

Date: 29/05/2006

- Articular fracture*
- Non-articular

- Open fracture
- Closed fracture*
- Displaced*
- Non-displaced

- Distal radius
- Proximal row of carpal bones
- Distal row of carpal bones
- Proximal metacarpus
- Mid metacarpus
- Distal metacarpus
- Proximal sesamoid bones*
- Proximal phalanx 1*
- Distal phalanx 1
- Phalanx 2
- Phalanx 3
- Distal sesamoid bone
- Other

- Medial proximal sesamoid bone*
- Lateral proximal sesamoid bone*
- Base
- Body*
 - *Transverse*
 - Sagittal
- Apex
- Abaxial
- Axial
- Comminuted -lat psb*

- Medial MCIII condyle
- Lateral MCIII condyle

Report:

DPa view: LF biaxial psb #.

Medial psb: mid-body complete displaced fracture; fracture gap at its widest 6mm; no signs of comminution

Lateral psb: Apical to mid-body fracture; comminution present as a small linear bone density seen axially in fracture gap (3 fragments in total). The proximal fragment is displaced proximally.

1. large apical fragment displaced proximally
2. axial linear fragment 1 x 3mm
3. very large basal fragment

LM view: biaxial psb #. Fragments superimposed over each other.

Proximal aspect of one psb show sharp horn-like projection (djd?)

Sliver like osteochondral fragment off dorso-proximal aspect of Ph1 and displaced approximately 1mm.

DLPaM Oblique view: Lat psb comminuted mid-body # - three fragments ie apical triangular fragment; large basal fragment and chip fragment positioned axially in fracture gap. Fracture gap abaxially = 10mm; axially = 6mm. Medial psb mid-body # with displacement of proximal fragment proximally.

DMPaL Oblique view: same #'s noted

Dx:

Biaxial displaced mid-body psb fractures of the LF; lateral psb comminuted #. Small sliver osteochondral fragment off dorso-proximal Ph1.



APPENDIX E

Equine distal limb fracture radiology report

Patient: MHL 9

Limb: LF *RF* LH RH

Clinician: Dr I Cilliers

Date: 26/05/2006

- Articular fracture*
- Non-articular

- Open fracture*
- Closed fracture
- Displaced*
- Non-displaced

- Distal radius
- Proximal row of carpal bones
- Distal row of carpal bones
- Proximal metacarpus
- Mid metacarpus
- Distal metacarpus*
- Proximal sesamoid bones*
- Proximal phalanx 1*
- Distal phalanx 1
- Phalanx 2
- Phalanx 3
- Distal sesamoid bone
- Other

- Medial proximal sesamoid bone
- Lateral proximal sesamoid bone*
- Base
- Body
 - Transverse
 - Sagittal
- Apex
- Abaxial
- Axial
- Comminuted*

- Medial MCIII condyle*
- Lateral MCIII condyle

Report:

Severely displaced open comminuted intra-articular fracture of the distal metacarpus through the medial condyle. The fracture line is sharply irregular.

The fracture line runs obliquely proximal for approximately 100mm before exiting on the medial aspect of the diaphysis.

The medial metacarpal fragment has a very sharp point proximally that punctured through the skin.

The lateral proximal sesamoid bone appears intact.

Comminuted fracture of medial proximal sesamoid bone: three large fragments visible of variable size with small fragments / chips interspersed.

On the DMPaL oblique view the proximo-medial aspect of phalanx 1 shows a vertical displaced fracture of the palmar process. Fracture gap approximately 1mm.

Dx:

Severely displaced open oblique intra-articular fracture of the medial condyle of the distal metacarpus III of the RF.

Displaced comminuted fracture of the medial proximal sesamoid bone.

Fractured medio-proximal palmar process of phalanx 1.



APPENDIX F

Equine tendon ultrasound report

Patient: *EG*
Limb: *RF*

Clinician: Dr I Cilliers
Date: 30/05/2006

Report:

SDFT and DDFT intact over palmar aspect of fetlock.

SDFT/DDFT and DSL's appear WNL below fetlock joint.

IOM: 0.9cm above insertion of medial branch of IOM on abaxial surface of psb linear, regular, and echogenicity normal.

Insertion of lateral branch of IOM on abaxial surface shows area that is ill-defined and has decreased echogenicity. Fibre alignment in this area is non-existent.

Lateral branch of IOM: decreased echogenicity. Linearity of fibres virtually non-existent..

Dx:

Biaxial psb #. Insertional desmitis of both branches of the IOM (lateral worse than medial).

Patient: *PP*
Limb: *LF*

Clinician: Dr I Cilliers
Date: 30/05/2006

Report:

Longitudinally the DDFT and SDFT appear normal up to level 3b. Thereafter the imaging became poor. Over the palmar fetlock region both the SDFT and DDFT lose their linearity and are less echogenic. The SDFT and DDFT were not clearly defined on the palmar pastern region. Proximally the SDFT had hypoechoic areas in the pastern region. Transverse images of the SDFT and DDFT were poor.

Scanning of the branches of the IOM was not possible.

Distal sesamoidean ligaments: SDSL looked hypoechoic just distal to the ergot.

Due to the severe undulations caused by the fractured psb's good images of the ps were unattainable.

Dx:

SDFT and DDFT tendonitis in region of fetlock jt and distally. IOM branch desmitis



APPENDIX F

Equine tendon ultrasound report

Patient: *1IC*
Limb: *LF*

Clinician: Dr I Cilliers
Date: 11/05/2007

Report:

Longitudinal scan of flexors proximal to mid-metacarpus distally.
DDFT loses its linearity and echogenicity in fields 3a to 3b.
IOM III difficult to visualise in mid-metacarpal region.
Both SDFT and DDFT not visible on palmar aspect of fetlock joint (3c).
Med psb: fracture gap = 3cm. Possible mid-body or basilar transverse fracture.
Lat psb basilar fracture: proximal fragment displaced proximally. Fracture gap similar to that of med psb (difficult to scan).
Lat branch of IOM not visualized due to reverberation artefacts as result of subcutaneous gas.
Medial branch at and near its insertion shows broadly dispersed hyperechoic speckles. The abaxial margin of the medial psb is mildly irregular.
Distal sesamoidean ligaments appear within normal limits.
The DDFT over the pastern has a decreased echogenicity.
The SDFT appears normal including its branches where they insert.

Patient: *2HL*
Limb: *LF*

Clinician: Dr I Cilliers
Date: 25/05/2006

Report:

SDFT and DDFT intact proximal and palmar to fetlock. In region 3b a shadow is cast from a mineralization on the palmar surface of the DDFT.
The mid MCIII palmar surface is irregular.
Medial psb = midbody #; gap = 0.94cm.
Lat psb = apical psb #, gap = 0.49cm.
Distal fetlock region: bone fragment of med psb casts a shadow on palmar aspect of DDFT.
IOM: insertion of medial branch of IOM on abaxial surface of ps linear, regular, and echogenicity normal.
Insertion of lateral branch of IOM on abaxial surface shows a break in continuity of psb close to its apex (apical #). Echogenicity slightly decreased. Linearity of fibres broken in areas close to insertion.
Medial branch of IOM (close to insertion): Area = 1.09 cm². Circumference = 4.38cm.
Lateral branch of IOM (close to insertion): Area = 1.32 cm². Circumference = 4.38cm.

Dx:

Biaxial psb #: Medial midbody #; lateral apical. Mineralization on palmar aspect of DDFT in region 3b. Lateral branch of IOM larger than medial branch. Insertional desmitis of lateral branch of IOM.



APPENDIX F

Equine tendon ultrasound report

Patient: *3HL*
Limb: *LF*

Clinician: Dr I Cilliers
Date: 17/08/2005

Report:

SDFT and DDFT appear normal in longitudinal scan. However the echogenicity and linearity of fibres sometimes difficult to determine due to limb not truly weight bearing.

At level 3c transverse scan: The lateral psb shows a discontinuation of cortex indicating a fracture. On the parasagittal scan of the lateral psb the fracture gap = 17.1mm.

Medial psb: Transverse: shows disruption in the continuity of the cortex with multiple hyperechoic debris to the abaxial surface. Parasagittally: fracture gap = 19.4mm

The insertion of the IOM on the abaxial surface of the lateral psb appears regular and that on the medial psb appears more hypoechoic than that of the lateral branch. .

Transversely near their insertions the branches appear less hyperechoic. Medial branch area=0.99cm²; circ = 41.1mm). Lateral branch area=1.13cm²; circ = 43.1mm)

Dx:

Biaxial psb fracture. Possible desmitis of the branches of the IOM.

Patient: *4HL*
Limb: *RF*

Clinician: Dr I Cilliers
Date: 31/05/2006

Report:

SDFT and DDFT appear to be WNL proximal and distal to the mid-fetlock region (3c). The DDFT showed irregularity in shape where it is positioned over the psb's.

Medial branch of IOM close to insertion has a decreased echogenicity and loses its linear pattern.

The distal SDFT and DDFT over the pastern appear to be WNL.

Basal fracture of lateral psb. Fracture gap = 1.36cm

The intersesamoidean ligament appears disrupted

Dx:

Basal fracture of the lateral psb (gap=1.36cm) with rupture of the intersesamoidean ligament. DDF tendonitis.



APPENDIX F

Equine tendon ultrasound report

Patient: *5HL*
Limb: *LF*

Clinician: Dr I Cilliers
Date: 09:05:2006

Report:

Transverse scan of flexor tendons above joint level (3b) shows that the DDF is displaced medially.
Further distally the DDFT is less echogenic
Distal sesamoidean ligaments - NAD
Medial psb #. Fracture gap = 2.74cm
Insertion of IOM on medial psb has a decreased echogenicity aprox 1.33cm proximal to its insertion
Transverse section of IOM branches just prior to insertion:
Medial branch: Area = 0.93cm² Circ = 3.93cm
Lateral branch: Area = 0.71cm² Circ = 3.39cm

Dx:

Medial psb fracture. Desmitis of the medial branch of the IOM.

Patient: *6HL*
Limb: *LF*

Clinician: Dr I Cilliers
Date: 01/06/2005

Report:

Not performed due to extent of injury — complete luxation of fetlock joint.

Dx:

Biaxial psb fracture with complete open luxation of fetlock joint



APPENDIX F

Equine tendon ultrasound report

Patient: *7HL*
Limb: *LF*

Clinician: Dr I Cilliers
Date: 19/08/2005

Report:

SDFT and DDFT appear to be within normal limits. Decreased echogenicity probably due to non-weight bearing. At level 3c the DDFT has an oblique hypoechogenicity just off the sagittal plane (possible artifact as on parasagittal view it was not found after multiple attempts).

The DDFT appears hypoechoic just distal to the psb's.

Transverse scan of lateral branch of IOM = decreased echogenicity. Transverse lateral branch area = 1.29cm^2 .

Transverse medial branch area 1.24cm^2

Medial mid-body psb fracture: gap = 32.3mm

Dx:

Biaxial mid-body psb fracture.

Patient: *8HL*
Limb: *LF*

Clinician: Dr I Cilliers
Date: 10/05/2006

Report:

SDFT and DDFT decreased echogenicity.

SDFT and DDFT also displaced medially.

Distal sesamoidean ligaments appear normal.

IOM: Proximally IOM very hypoechoic. IOM disrupted approximately 1 handsbreadth above (2a) fetlock.

The insertions on the psb are also disrupted.

Saucer shaped defect seen on abaxial surface of medial psb

Dx:

Medial psb abaxial avulsion fracture. Severe IOM desmitis of body and branches.

APPENDIX F

Equine tendon ultrasound report

Patient: *9HL*
Limb: *RF*

Clinician: Dr I Cilliers
Date: 10/05/2006

Report:

Limb not mimicking weight bearing as fetlock dropping too far palmarly due to fractured psb.
Limb was thus scanned lying flat on the table.
SDFT and DDFT echogenicity and fibre alignment difficult to evaluate over palmar fetlock region.
Architecture of SDFT; DDFT and DSL's completely disrupted. Architecture only being normalized at a level of 3 fingers below the ergot.
Medial psb fracture gap = 2.9mm
IOM: medial branch of IOM very disturbed and thicker than normal. Transverse medial branch area = 0.8cm²
Transverse lateral branch area = 1.11cm²

Dx:

Medial psb fracture. Insertional desmitis of both branches of the IOM

Patient: *10HL*
Limb: *LF*

Clinician: Dr I Cilliers
Date: 09/05/2006

Report:

Longitudinal scan over fetlock region: Core of SDFT decreased echogenicity in region 3a-Pl a. (not seen on transverse scan).
Distal SDFT appears normal.
Transverse scan of flexor tendons over fetlock joint level — shape of DDFT slightly abnormal — rest NAD.
The medial branch of the DDFT shows loss of margin medially and decreased echogenicity only in the most proximal aspect where origin of DSL's are.
The SDSL also show some degree of decreased echogenicity in this region
Rest of distal sesamoidean ligaments — NAD
Medial psb midbody fracture. Fracture gap = 1.45cm
Insertion of IOM branches mildly disrupted especially medially.

Dx:

Biaxial psb fracture. Desmitis of particularly the medial branch of the IOM. Core lesion in SDFT in fetlock region. DDFT tendonitis on medial aspect over fetlock region.

APPENDIX F

Equine tendon ultrasound report

Patient: 11HL
Limb: LF

Clinician: Dr I Cilliers
Date: 10/05/2006

Report:

Medial psb fracture with an additional fragment visualized on sagittal plane within fracture gap. Fracture gap of Medial psb fracture = 1.1cm.
Lateral psb fracture gap = 0.95cm
The SDFT and DDFT appear normal

Longitudinal scan of IOM:

Lateral branch: irregular bone of lat psb at insertion, fibres parallel and regular.
Medial branch: fibres regular and parallel near insertion.

Transverse scan of IOM:

Lateral branch: Area = 0.99cm^2 eke 3.82em

Medial branch Area = 94cm^2 eirc =3.99cm

Distal sesamoidean ligaments appear to be normal. Both the straight and the obliques easily visible.

Dx:

Biaxial psb # with comminution of medial psb

Patient: 13HL
Limb: LF

Clinician: Dr I Cilliers
Date: 18/03/2005

Report:

Transverse scan of flexor tendons in region 2b-3c very difficult to judge echogenicity. The tendons tend to be tilted towards the medial aspect. A hypoechoic circular core lesion noted on the most lateral aspect of the DDFT. This is confirmed on the longitudinal scan slightly parasagittal where it runs over the psb. This core is approximately 20-25% of the diameter of the tendon.

The branches of the IOM near their insertion are approximately the same size. Both however are more hypoechoic. On the medial branch it is very difficult to determine fibre alignment and linearity on longitudinal scan. There appears to be disruption of the tendon fibres at its insertion. On the abaxial surface of the medial psb hyperechoic speckles are seen near abaxial rim of psb.

The lateral psb appeared normal in longitudinal scan.

The medial psb showed up 2 clear fractures on parasagittal scan at 2 different levels. One closer to the base with the fracture gap =6.7mm. The other fracture was found closer towards the apex. Fracture gap=6mm. Indicating comminuted fracture of the medial psb.

Transverse scan at level 3c: the medial psb shows a break in continuation of its cortex. Fracture gap=6.1mm.

The distal sesamoidean ligaments were difficult to evaluate at their origin but appeared normal further distally. The DDFT in the pastern region appeared to contain hyperechoic specks.

Dx:

Comminuted fracture of medial psb. Core lesion on lateral aspect of DDFT. Desmitis of medial branch of IOM near insertion.



APPENDIX F

Equine tendon ultrasound report

Patient: 13/1HL
Limb: RF

Clinician: Dr I Cilliers
Date: 22/05/2006

Report:

The flexor tendons appear normal from level 1a to 3a.
In region 3c (fetlock region) the SDFT and DDFT fibres rim parallel and longitudinally, but the echo genicity is decreased (more hypoechoic).
Can not visualize the IOM transversely or longitudinally from 3a -3b.
Distal sesamoidean ligaments + DDFT + SDFT appear normal below fetlock P1b.
Fracture gap between medial psb fragments =12.7mm.
Lateral condylar fracture not imaged as a result of gas interference.

Dx:
Medial psb fracture

Patient: 15/1HL
Limb: LF

Clinician: Dr I Cilliers
Date: 18/08/2005

Report:

Ultrasound not performed due to severity of lesion.

Dx:
Open luxated lateral condylar fracture
Medial mid-body comminuted psb fracture

Patient: 15/2HL
Limb: LF

Clinician: Dr I Cilliers
Date: 19/08/2005

Report:

Flexors very difficult to scan as a result of the limb not fully weight bearing and also the presence of gas.
The medial branch of the IOM — unable to assess.
The lateral branch's echogenicity was decreased.
Medial psb fracture. Displacement so great could not get both fragments on sagittal scan.
Limb taken off stand and laid flat on table to facilitate scan. The imaging was not improved
Parasagittal view of L psb showed an irregular palmar surface of the bone.
Scanning aborted at this time.

Dx: Medial psb fracture



APPENDIX F

Equine tendon ultrasound report

Patient: 15-3HL

Limb: LF

Clinician: Dr I Cilliers

Date: 15/08/2005

Report:

Transverse scan of psb at level 3c:
DDFT and SDFT appear to be WNL.
Irregular surface of psb - probably indicating location of fracture.
The medial psb shows discontinuation in the cortex of the axial surface.
The lateral psb shows a complete discontinuation of the cortex towards its apex.

Parasagittal scan over lateral psb:
Discontinuation of cortex with fracture gap=10.4mm. Fracture situated close to its base.

Parasagittal scan over medial psb:
Discontinuation of cortex with fracture gap=10.5mm. Fracture midbody region.

Dx:

Biaxial psb fracture

Patient: 16HL

Limb: RF

Clinician: Dr I Cilliers

Date: 15/08/2005

Report:

Transverse scan of psb at level 3c:
DDFT has irregular circular hypoechoic lesion within the mid distal aspect. The medial psb shows discontinuation in the cortex of the axial surface. The lateral psb shows a complete discontinuation of the cortex towards its apex.

Transverse scan just above fracture:
The axial and apical surfaces of the psb appear irregular.

Longitudinal scan over lateral psb:
Discontinuation of cortex with fracture gap=6.2mm. The linearity and distinction of the SDFT and DDFT is difficult to determine.

Longitudinal scan over medial psb:
Discontinuation of cortex with fracture gap=14.2mm. The DDFT appears to have a central area of decreased echogenicity extending from the proximal fragment to past the distal fragment of the medial psb.

Dorsal parasagittal scan of fetlock joint:
Just medial to sagittal ridge hyperechoic fragment visible proximo-dorsal aspect of Ph1.

Transverse dorsal scan of fetlock joint:
Chip fracture = hyperechoic speck just medial to sagittal ridge.

Dx:

Biaxial midbody psb fracture. Osteochondral fragment on dorso-proximal aspect of Ph1.



APPENDIX F

Equine tendon ultrasound report

Patient: 16-1HL
Limb: RF

Clinician: Dr I Cilliers
Date: 11/05/2006

Report:

SDFT and DDFT appear normal above and over palmar aspect of fetlock.

The DDFT appears to have a core lesion on its lateral branch in palmar pastern region. SDFT NAD.

Lateral branch of IOM difficult to visualize on ultrasound — decreased echogenicity.

Medial branch of IOM also difficult to visualize — echogenicity mottled, also much wider (17mm) compared to lateral branch (12mm).

Transverse: Lateral branch of IOM: area = 0,57cm², circ = 31.4mm

Medial branch of IOM: area = 0.75cm², circ = 32.9mm

Difficult to visualize DSL's.

Dx:

**Rupture of distal sesamoidean ligaments with proximal displacement of the psb's.
Insertional desmitis of both branches of IOM. Core lesion in DDFT distal to fetlock.**

Patient: 17HL
Limb: LF

Clinician: Dr I Cilliers
Date: 15/08/2005

Report:

Transverse scans of IOM failed to produce clear outline of the interosseous probably due to it being non-weight bearing. Due to subcutaneous gas and gas in tendon sheath and around the wound unable to scan sagittally over SDFT and DDFT (even when skin removed and using stand-off pad). The lateral psb also displaced laterally and bulging severely not permitting great contact.

Transverse scan at level of psb: medial psb has irregular axial surface.

Lateral psb has 2 breaks in it cortex.

The DDFT also has an abnormal appearance and its shape is distorted laterally and becoming more triangular in shape.

Parasagittal longitudinal view discontinuation in outline of cortex with a fracture gap = 8.5 mm. The IOM insertion onto abaxial surface of distal fragments abaxial surface is hyperechoic.

Insertion of IOM on lateral psb abaxial surface with visible displaced cortex is hypoechoic over fragment which is displaced and becomes more regular and linear distally but still has hyperechoic specs within it. The insertion of the IOM on medial psb linearity is unclear and echogenicity is decreased.

Dx:

**Lateral comminuted midbody psb fracture. Insertional desmitis of lateral branch of IOM.
DDFT tendinitis in region of psb laterally.**



APPENDIX F

Equine tendon ultrasound report

Patient: *18HL*
Limb: *LF*

Clinician: Dr I Cilliers
Date: 15/08/2005

Report:

Transverse image of lateral psb: Discontinuation of cortex near apex of lateral psb. The distal fragments' cortex appears smooth and regular.

Transverse image of medial psb: Discontinuation of axial cortex of medial psb with a loose fragment lateral to DDFT- thus comminution of midbody fracture.

Longitudinal scan of lateral branch of IOM near insertion – there is discontinuation of the cortex of the abaxial surface ie apical fracture but linearity and echogenicity of IOM appear normal. The linearity and echogenicity of the medial branch of the IOM appears to be slightly less than that of the lateral branch.

Parasagittal scan of lateral psb – apical fracture with additional fragment visible in fracture gap. Distance between apical fragment and base = 15.5mm. Distance between apical fragment and additional fragment = 5.2mm.

Linearity and echogenicity of SDFT and DDFT visible but due to non-weight bearing appears decreased.

Parasagittal scan of medial psb: midbody discontinuation of cortex with gap being 11.4mm. Within gap 4-5 echogenic round bodies visible possibly smaller fragments of bone.

Decreased linearity and echogenicity of SDFT and DDFT – sig? as non-weight bearing.

Dx:

Medial midbody psb fracture. Comminuted apical fracture of lateral psb. Desmitis of medial branch of IOM.

Patient: *MHL1*
Limb: *LF*

Clinician: Dr I Cilliers
Date: 29/05/2006

Report:

DDFT and SDFT intact over fetlock joint but displaced medially. Medial psb fractured, fracture gap = 25.7mm. Medial aspect of limb not scanned due to gas accumulation resulting in reverberation artifacts.

Dx:

Biaxial psb fracture



APPENDIX F

Equine tendon ultrasound report

Patient: *MHL2*
Limb: *RF*

Clinician: Dr I Cilliers
Date: 11/05/2006

Report:

The SDFT and DDFT appear normal palmarly on MCIII. They are difficult to visualize over the fetlock region due to the psb #'s. Below the fetlock they are also difficult to visualize. Just above the scutum medium the straight distal sesamoidean ligament contains hyperechoic specks throughout the body. These hyperechoic specks are also seen in the lateral oblique distal sesamoidean ligament. The insertion of the medial branch of the IOM appears linear and regular. The abaxial surface of the medial psb is also irregular. The medial psb fracture is visible further distally. The medial branch of the IOM has a decreased echogenicity near its insertion. The abaxial surface of the medial psb is irregular. The fracture gap of the lateral psb = 1.96cm. The medial psb is difficult to image due to the irregular surface. Diameter of medial branch of IOM = 0.44cm²; circumference = 2.68cm. Diameter of lateral branch of IOM = 1.58cm²; circumference = 5cm.

Dx:

Biaxial mid-body psb #'s with comminution particularly of the medial psb. Desmitis of the lateral branch of the IOM.

Patient: *MHL2/2*
Limb: *RF*

Clinician: Dr I Cilliers
Date: 31/05/2006

Report:

No ultrasound performed due to severity of lesion making ultrasound impossible

Dx:

Complete luxation of the metacarpophalangeal joint with biaxial psb #'s.

Patient: *MHL3*
Limb: *LF*

Clinician: Dr I Cilliers
Date: 24/05/2006

Report:

Medial psb fracture. Fracture gap of medial psb = 14.1mm.

Lateral psb fractured further proximally closer to apex. Fracture gap = 5.9mm

SDFT and DDFT appear normal longitudinally and transversely upto level of fetlock. Distally the DDFT and SDFT also appeared normal.

Medial branch of IOM is mildly hypoechoic near its insertion.

Lateral branch of IOM has some disruption of its fibres aro proximally based fracture. Can clearly see a core lesion (in transverse plane) in lateral branch.

A core lesion also present in medial branch of IOM just before insertion.

Distal sesamoidean ligaments – NAD

Dx:

Biaxial psb fracture. Desmitis of the branches of the IOM with core lesions being present.



APPENDIX F

Equine tendon ultrasound report

Patient: *MHL4*
Limb: *LF*

Clinician: Dr I Cilliers
Date: 29/05/2006

Report:

No ultrasound performed due to severity of lesion making ultrasound impossible

Dx:

Complete luxation of the LF metacarpophalangeal joint with biaxial psb fractures.

Patient: *MHL5*
Limb: *RF*

Clinician: Dr I Cilliers
Date: 24/05/2006

Report:

Flexor tendons shifted medially. Surprisingly the flexor tendons appear to have a regular parallel orientation of fibres upto level of psb.

In region 3c imaging difficult. The DDFT appears intact.

Distal to fetlock in region P1a and P1b the lateral aspect of the DDFT appears to have a circular region of damage (hypoechoic).

The distal sesamoidean ligament appears disrupted.

Wavy appearance of medial branch of IOM 2cm above insertion onto the psb. Insertion of medial branch on medial psb: parallel fibres appear to be further apart. Circumference of medial branch = 34.7mm; area = 0.72cm².

Lateral branch of IOM: fibres still parallel but echogenicity decreased. Circumference of lateral branch = 33.8mm; area = 0.74cm².

Dx:

Biaxial psb fracture. Desmitis of the medial branch of the IOM.

Patient: *MHL6*
Limb: *LF*

Clinician: Dr I Cilliers
Date: 26/05/2006

Report:

Gas accumulation between digital flexor tendon and branches of IOM.

Origin of SDSL appears less echogenic and mottled on longitudinal scan

Lateral psb midbody fracture: fracture gap = 7.3mm

Medial psb basal fracture: fracture gap = 7.1mm

Insertion of lateral branch of IOM looks relatively normal even with visible psb fracture

Insertion of medial branch of IOM echogenicity decreased over apical fragment

Transversely lateral branch (area=0.85cm²; circ= 37.0mm) of IOM appears smaller in diameter than the medial branch (area = 1.34cm²; circ = 48.5mm)

Unable to get good images of distal sesamoidean ligaments and distal DDFT and SDFT.

Dx:

Biaxial psb fracture. Desmitis of medial branch of IOM. Desmitis of origin of SDSL



APPENDIX F

Equine tendon ultrasound report

Patient: *MHL 7*
Limb: *LF*

Clinician: Dr I Cilliers
Date: 26/05/2006

Report:

Imaging of flexor tendons impossible due to reverberation artifacts and gas accumulation under the skin. Where it was possible to scan both the SDFT and DDFT had a decreased echogenicity but appear intact sagittally.

Dx:
Biaxial psb fracture of LF

Patient: *MHL 8*
Limb: *LF*

Clinician: Dr I Cilliers
Date: 29/05/2006

Report:

Unable to scan flexor tendons due to reverberation artifacts and gas accumulation under the skin. Medially the SDFT appeared normal in the region 3c. Lateral branch of IOM at its insertion still attached to proximal fragment of lateral psb abaxially. A hypoechoic line running parallel to abaxial surface of lateral psb at its insertion was visualised. Medial branch of IOM echogenicity and fibre alignment much clearer than that of the lateral branch. Biaxial psb fracture. Fracture gap of medial psb largest part = 30mm. Hyperechoic bone fragment lying between major fragments on longitudinal scan.

Dx:
Biaxial psb fractures with displacement of proximal fragments proximally. Fracture gap of the medial psb = 30mm). Insertional desmitis of lateral branch of IOM.

Patient: *MHL 9*
Limb: *RF*

Clinician: Dr I Cilliers
Date: 26/05/2007

Report:

Ultrasonographic examination not performed due to severe destruction of the distal metacarpal region due to a medial condylar fracture piercing the skin and opening the joint leading to gas accumulation in surrounding areas making an ultrasonographic examination impossible.