

Procedures performed by family physicians in hospital practice in a developing country (South Africa) - an evaluation of clinical anatomy competence

Johannes Marinus Boon

Submitted to comply with the requirements of the degree:

Ph.D. (Anatomy)

**in the School of Medicine, Faculty of Health Sciences
University of Pretoria, Pretoria, South Africa**

**and one year period at the University of Cambridge, United Kingdom, on a
Commonwealth Academic Staff Scholarship ZACA-2000-135**

2000 - 2002

**Supervisors: Prof JH Meiring (University of Pretoria)
Prof PH Abrahams (Girton College,
University of Cambridge and Kigezi
International School of Medicine, Cambridge)**

12. Summary

Procedures performed by family physicians in hospital practice in a developing country (South Africa) -an evaluation of clinical anatomy competence

Boon Johannes Marinus¹

Supervisors: JH Meiring¹, PH Abrahams²

¹ **Department of Anatomy, School of Medicine, Faculty of Health Sciences, University of Pretoria, Pretoria, South Africa**

² **Girton College, University of Cambridge, Kigezi International School of Medicine, Cambridge, United Kingdom**

Ph.D. (Anatomy)

The safe and successful performance of office procedures, surgical procedures, and emergency procedures as well as radiological imaging procedures demand a working and yet specific knowledge of anatomy. This study focuses on the competency to perform clinical procedures, especially the underlying anatomical knowledge base necessary to perform a safe and successful procedure. No study reports on the assessment of clinical anatomy as part of the competency of family physicians to perform clinical procedures.

The aim of this study was to determine a) which clinical procedures are performed in hospital practices in South Africa; b) the frequency of performance; c) the importance rating of clinical procedures; d) the comfort of performance; e) difficulties and anatomically related complications encountered; f) the role of clinical anatomy competency in reducing difficulties and complications; g) the role of clinical anatomy in improving confidence of performance; h) a selection of 15 problem procedures; i) the relevant clinical anatomy necessary to perform these procedures and j) to develop a clinical anatomy training program for these procedures.

A list of 57 procedures relevant to family practice in South Africa was compiled and a questionnaire completed by doctors at various hospitals, which were randomly selected in three provinces in South Africa. A total of 102 questionnaires were obtained and analyzed.

The following procedures were selected which were performed often (>50%), ranked important, encountered most difficulties and complications, where more doctors were uncomfortable than comfortable and where the influence of clinical anatomy knowledge on the safe and successful performance of the procedure, was ranked highest: Central venous catheterization, cricothyroidotomy, pericardiocentesis, great saphenous vein cutdown, oro/naso tracheal intubation, lumbar puncture, appendectomy, cesarean section, reduction of uncomplicated forearm fractures, ectopic pregnancy surgery, epistaxis and nasal packing, rectal examination, proctoscopy and sigmoidoscopy, knee joint aspiration, wrist and digital nerve block and obstetric ultrasound. A referenced knowledge base was developed by an extensive literature search of the selected procedures under the following headings: Indications, contraindications/ precautions, step by step procedure, anatomical pitfalls and anatomically relevant complications. This was expanded to develop a Virtual Procedures Clinic, an interactive multimedia package.

Contents

1. Introduction	1
1.1 Importance of clinical anatomy for clinical procedures.....	1
1.2 Clinical competence	5
1.3 Procedures	6
1.4 South African context.....	7
1.5 Assessment of clinical competency.....	9
2. Aims and objectives	15
3. Materials and methods	17
3.1 Survey	
3.1.1 Development of survey questionnaire	17
3.1.2 Conduction of survey	21
3.1.3 Analysis of data produced by survey	25
3.2 Selection of procedures and criteria for selection.....	27
3.3 Comparison between urban and rural hospital practices.....	28
3.4 Development of a clinical anatomy knowledge base for each selected procedure.....	28
3.5 Development of a clinical anatomy training program for the selected procedures	29
4. Results	32
4.1 Development and conduction of survey.....	32
4.1.1 Incidence of performance.....	33
4.1.2 Frequency of performance.....	36
4.1.3 Importance rating.....	38
4.1.4 Measure of comfort rating.....	43
4.1.5 Difficulties of performance.....	48
4.1.6 Complications.....	53

4.1.7 The role of clinical anatomy in reducing difficulties and complications.....	59
4.1.8 The role of clinical anatomy to increase the confidence of family physicians in performing procedures.....	64
4.2 Selection of problem procedures.....	69
4.3 Comparison between urban and rural practices.....	70
4.4 Development of a clinical anatomy knowledge base for each selected procedure.....	77
4.4.1 Emergency procedures.....	78
4.4.1.1 Cricothyroidotomy	78
4.4.1.2 Oro/naso tracheal intubation.....	94
4.4.1.3 Lumbar puncture.....	113
4.4.1.4 Central venous catheterization	129
4.4.1.5 Pericardiocentesis.....	153
4.4.1.6 Great saphenous vein catheterisation.....	164
4.4.2 Office procedures	172
4.4.2.1 Epistaxis management	172
4.4.2.2 Wrist and digital nerve blockade	189
4.4.2.3 Rectal examination, proctoscopy and sigmoidoscopy	209
4.4.2.4 Knee joint aspiration	237
4.4.3 Surgical procedures.....	250
4.4.3.1 Cesarean section	250
4.4.3.2 Appendectomy	281
4.4.3.3 Ectopic pregnancy surgery	305
4.4.3.4 Reduction of uncomplicated forearm fractures.....	322
4.4.4 Imaging procedures.....	349
4.4.4.1 Obstetric ultrasound examination.....	349
4.5 Development of a clinical anatomy training program.....	362
5. Discussion.....	364
5.1 Development and conduction of survey.....	364

5.1.1 Incidence of performance.....	365
5.1.2 Frequency of performance.....	367
5.1.3 Importance rating.....	369
5.1.4 Measure of comfort rating.....	371
5.1.5 Difficulties of performance.....	375
5.1.6 Complications.....	378
5.1.7 The role of clinical anatomy in reducing difficulties and complications.....	385
5.1.8 The role of clinical anatomy to increase the confidence of family physicians in performing procedures.....	387
5.2 Selection of problem procedures and criteria for selection.....	388
5.3 Comparison between urban and rural practices.....	389
5.4 Development of a clinical anatomy knowledge base for each selected procedure.....	396
5.5 Development of a clinical anatomy training program.....	396
5.5.1 The use of computer technology in a clinical anatomy program...399	
5.6 Limitations of the study.....	405
5.7 Recommendations.....	406
6. References.....	408
7. Addendum 1 – Questionnaire.....	414
8. Addendum 2 – Scoring options for procedure selection.....	415
9. Acknowledgements.....	419
10. List of figures.....	423
11. List of tables.....	424
13. Attached: CD-ROM: The Virtual Procedures Clinic	

1. Introduction

1.1 Importance of clinical anatomy for clinical procedures

The safe and successful performance of office procedures, surgical procedures, emergency procedures and radiological imaging procedures demand a working and yet specific knowledge of anatomy¹.

Clinical anatomy forms the basis of medical practice and is usually defined as anatomy applied to patient care². This is certainly true for developing countries where high technology is often lacking. General practitioners are therefore often dependent on their anatomical knowledge for the performance of clinical procedures. Despite the information revolution from medical research and the rapidly expanding diagnostic and therapeutic possibilities in medical technology, effective performance of procedures in family practice still rests on a solid anatomical basis. This includes the performance of all clinical procedures, which depend heavily on a sound knowledge of human anatomy^{3,4}.

Coupland *et al*⁵ points out by referring to an address by Dr D Hines to the Royal College of Surgeons of England titled "Anatomy in general medical practice", that general practitioners need and make use of anatomical knowledge in everyday practice. Referring to 7500 consecutive consultations, Hines found a specific need for anatomical knowledge in 814 cases. This was phrased as conscious use of anatomy, which does not involve subconscious use.

In a recent survey⁶ done in the USA to determine deficient areas of anatomical knowledge in students starting with their residency in Family Medicine, clinical application of anatomy was pointed out to be the most deficient area in anatomical knowledge. This means simply a desire that students be able to apply their anatomical knowledge to real problems in the clinical setting.

Clinical procedures that fail to achieve their objective or that result in complications, can often be linked to a lack of understanding or misunderstanding of anatomy⁷. Dando⁸ confirms this by referring to injury to nerves and arteries and other injuries in anatomically complicated areas associated with minor surgical procedures. In particular he refers to the:

- i) Mandibular branch of the facial nerve on the lateral aspect of the jaw, when division of the nerve leads to paralysis of the lip and angle of the mouth.
- ii) Common fibular nerve on the lateral side of the popliteal fossa and in close relation to the neck of the fibula. Division of this nerve leads to weakness of dorsiflexion and eversion of the foot.
- iii) The spinal accessory nerve in the posterior triangle of the neck. Injury to this nerve leads to a shoulder drop.

These examples refer to superficial nerves that are at risk during minor surgical

procedures like removal of skin lesions and do not even dwell on more complicated anatomical regions associated with complications for example found during the insertion of a central venous catheter or the removal of the appendix.

Behrs *et al*⁹ states that it is a fact that a large percentage of medicolegal cases are based upon an inadequate knowledge of anatomy. For example inserting a needle into the chest to withdraw fluid from the pericardial cavity can cause complications if a coronary vessel is pierced, a thoracocentesis from a lateral or posterior approach may result in a liver or a spleen injury if the needle is inserted too deeply and a simple intramuscular injection can cause an axillary or sciatic nerve palsy if the nerve is struck¹⁰. Damage to nerves can result in loss of function. The facial nerve is at risk when operating deep in the facial area and damage will cause a serious loss of expression.

Ger¹¹ rightly points out that doctors who are deficient in anatomy are responsible for prolonging the operation and the anesthesia. This may be accompanied by complications of various degrees. Behrs *et al*⁹ points out that prolongation of a procedure due to lack of anatomical knowledge leads to increased morbidity and mortality. With expert knowledge of the relevant anatomy, a procedure can be carried out safely. Complications may be even worse for the so-called minor procedures, which are carried out in the ward, often without supervision and a proper understanding of the anatomical implications⁴¹.

The importance of a sound understanding of the anatomy underlying clinical procedures is therefore primarily to the benefit of patients. Ger¹¹ points out that both the American and British training programs in clinical anatomy have declined from the high standards which they once maintained. This may have implications on patient care. It is therefore timely to foster new interest and emphasis on clinical anatomy, the foundation stone for the safe and successful performance of clinical procedures.

Grossman¹² also points out how anatomy was marginalized over the last few decades to a point where students have limited opportunity actually to dissect and therefore have a first-hand experience of three dimensional relationships of anatomical structures.

Anatomy teaching has now often declined to group observation of prosections, aided by computer technology. It is argued that those specializing in the surgical disciplines will do in-depth postgraduate anatomy once in their residency and therefore do not need it during their undergraduate training. Ger¹¹ points out that this is seldom the case.

Surgical residents in this state of anatomical education often end with great gaps in anatomical knowledge, especially outside their field of expertise. In developing countries, general practitioners often perform surgical procedures that are usually performed by surgeons in developed countries. They therefore usually have to perform a very wide range of procedures compared to their colleagues in developed countries¹³.

A sound anatomical basis of not only one region, but a working knowledge of diverse

anatomical regions is therefore important to secure safe and successful performance of all clinical procedures.

Due to the decreasing amount of time spent by students studying anatomy, it has been shown that the retention of anatomical knowledge is less than desirable¹⁴. Rennie¹⁵ argues that this may in part be due to anatomical teaching in the early years of medical education, before students have a clinical framework to incorporate anatomical knowledge. There is therefore a need to move anatomical teaching to later years in medical undergraduate and definitely to boost its presence in postgraduate training.

It is widely accepted that retention of anatomical knowledge is increased by correlating anatomical knowledge to the clinical world for example the performance of practical procedures¹⁶.

This is reinforced by Rennie¹⁵ when arguing that students need to incorporate new anatomical facts into a clinical framework. A problem solving approach is necessary.

Crisp¹⁷ states that the hallmark of the medical practitioner is the fact that he invades the human body in the sole interest of his patient. This invasion may be investigative and diagnostic by means of physical examination or accessing body cavities. It may also be therapeutic, either by means of needles, knives or radiological means. Competency and confidence to perform these is derived from a sound anatomical dissection of the human body. Crisp¹⁷ goes on to point out that anatomical dissection heavily contributes to the safe and successful performance of various practical skills and clinical procedures.

Many surgical procedures that were previously performed in an operating theatre are now done in the office. The concept of office procedures has gained increasing popularity. Needles and catheters are nowadays passed into various anatomical regions that were less well known before advances of radiological imaging, emergency medicine and minimal invasive surgery. Ger¹¹ states that relevant anatomy applied to clinical procedures is therefore important to identify. This does not mean trivial anatomy with no practical application. Anatomy should move into the clinical sphere. This means that the anatomy necessary and relevant for specific procedures needs to be studied in depth. Vague or too detailed gross anatomy of the region in which the procedure is performed is not helpful. Relevant anatomy needs to be identified from a clinical perspective, and therefore does indeed mean the development of a new academic discipline.

Phillips¹⁸ points to the importance of identifying those features of anatomical relationships that are of special interest to clinicians, such as the relationship of the subclavian artery and vein inferior to the clavicle as applied to central venous catheterization. The anatomy of practical procedures often becomes a very focused and intense regional endeavor, because it deals with structures or portions thereof that are immediately and directly related to the needle, tube or knife.

In his landmark book, "A colour atlas of Applied Anatomy", McMinn *et al*¹⁹ rightly remarks that the anatomy of "how to get at things" is of great importance. Bridging the "awkward gap" as McMinn states it between academic anatomy and clinical practice is

vitality important. With new advances in medical technology like minimal invasive surgery, a sound anatomical knowledge will become even more important. McMinn *et al*¹⁹ refers to various anatomical hazards, safeguards and surgical approaches for various clinical procedures.

Hamilton *et al*¹⁴ rightly states that a sound understanding of human anatomy is vital for the field of emergency medicine with its strong procedural orientation. An understanding of “what’s there ?” is crucial for making correct decisions. There is a need for focused clinical anatomy training regarding the performance of procedures. Hamilton *et al*¹⁴ points out that the average score of a clinically oriented anatomy exam for emergency residents was 40%. First year medical students scored 78% on the same exam. The need for clinical anatomy refresher courses is evident. In such a course, basic anatomy should strongly be integrated with clinical correlations with hands-on dissection elements. Hamilton *et al*¹⁴ states the need to better research the integration between basic anatomy and clinical practice. The aim of this study is to advance “one small step” along this road.

Clinical anatomy is an important component in the area of clinical knowledge and judgement²⁰. Competent general practitioners must be able to distinguish between normal and abnormal structures and know about normal relationships of structures.

Focus on this component (clinical anatomy) of the knowledge domain is necessary for competency with clinical procedures. Clinical anatomy is not the only component of knowledge that should be mastered by the competent family physician, but certainly an important one. The knowledge domain of clinical anatomy cannot be separated from motor and technical skills to perform a safe and successful procedure²¹. Clinical anatomy can therefore never be isolated from skills and attitudes.

Valuable lessons on how to integrate anatomy with surgical procedures can be learned from Peuker *et al*²² who developed clinical anatomy refresher courses on surgical approaches for various surgical procedures. An innovative method of teaching procedural anatomy has been introduced by Hubbell *et al*²³ in which regional anatomy is taught both before and during a surgical procedure in the operating room. In this way an immediate relevance is brought into the learning process.

Barrows *et al*²⁴ noted the following in 1969 regarding students and residents of the McMaster University in Canada: “ I discovered that medical students and residents, for the most part, did not seem to think at all. Some gathered data ritualistically and then tried to add it up afterwards, while others came up with as diagnosis based on some symptom or sign, never considering possible alternatives.” The outcome of their curriculum did not match their expectations. Consequently the curriculum was changed to a problem-oriented one, a now very common type of medical curriculum worldwide. The basic philosophy of this approach lies in the fact that both knowledge and skills are trained and learned in an environment similar or identical to that of the final working environment of the student. When applying this principle to anatomy, it means that anatomy which involves the knowledge, attitudes and skills domain, should be taught in a clinical environment as well, or at least in a clinical reasoning framework. The means to do this is to elevate anatomy teaching into the real clinical world, or at least a virtual clinical world which can be based on various technological modalities ranging from

paper based clinical cases to state of the art multimedia environments.

1.2 Clinical competence

Clinical procedures are an important part of the daily work of general practitioners²⁵. The competency general practitioners display in procedural skills may be considered a very relevant aspect of their overall clinical competence²⁰. Competence is defined as what a doctor is capable of doing and differs from performance, which reflects on the actual day-to-day practice. Competence however predicts performance²⁶.

In family practice, the competence of a physician can be categorized into three areas: a) Attitudes and interpersonal skills which involves the behavior and ethics of the profession that are necessary for communicating and working with patients; b) Intellectual faculties and abilities such as cognitive knowledge, ability to organize and to synthesize; and c) Motor and technical skills which include the manual skills required to conduct a physical examination and to perform necessary procedures²⁷. Competency is therefore an issue of professional responsibility. Failure to exercise the skill a doctor claim to have is in breach of his/her duty of care and is therefore negligent⁸.

There is a need to focus on the competency to perform clinical procedures, especially the underlying anatomical knowledge framework necessary to perform a safe and successful procedure. The performance of any clinical procedure needs a certain level of competency²⁸. Competency exists when a practitioner has sufficient knowledge and manual skill, such that a procedure can be performed to obtain the intended outcomes and without harm to the patient. Competency is especially important when the procedure has the potential to harm or cause patient discomfort²⁰. An important part of this competency is the knowledge base necessary to perform a safe and successful procedure. Recognition of the anatomy relevant to the specific procedure is an important part of this knowledge base.

There are basically three general areas of knowledge in the development of competency for performing clinical procedures. They are: 1) Clinical knowledge and judgement, 2) Knowledge of the equipment, instruments and supplies, and 3) Knowledge of the procedure. These elements are in fact closely interrelated²⁰.

The Royal College of General Practitioners²⁹ states that it is essential only to undertake those procedures, which a doctor feels competent to perform. This includes an adequate competency level of the relevant anatomy.

Wigton³⁰ states that the most important elements of procedural competency are the cognitive aspects. Anatomy plays an important part in this domain: This includes knowing the indications and contra-indications, knowing the anatomical pitfalls and possible complications, identifying them and managing them. Kneebone³¹ points out that confidence in performing a procedure comes from a knowledge base, which knows what to expect. This underscores the notion that a sound clinical anatomy knowledge base is essential to perform a procedure.

1.3 Procedures

Clinical procedures form an important part of competency in general practice²⁵. Literature from developed countries generally appears to agree on which procedures should be performed in general practice^{32,25,33,34,35}. These include a variety of minor operations such as excision of cysts and skin lesions, suturing uncomplicated lacerations, injection or incision of hemorrhoids, resection of ingrown toenails, injection of joints, bursae and tendons, emergency procedures such as advanced cardiac life support, arterial puncture for blood gases, chest tube placement, electrocardioversion and diagnostic tests like flexible sigmoidoscopy, laryngoscopy, lumbar puncture and chest radiology.

General practitioners usually have long-standing relationships with their patients. Especially concerning office procedures, patients will want to come to the family physician, which is both convenient and reassuring. General practitioners therefore have a duty to perform clinical procedures competently³⁶.

The following list is provided for general practitioners in the UK by the National Health Services (NHS)³⁷: *Injections*: intra-articular, peri-articular, varicose veins, haemorrhoids; *Aspirations*: joints, cysts, bursae, hydrocoele; *Incisions*: abscesses, cysts and thrombosed piles; *Excisions*: sebaceous cysts, lipoma, skin lesions for histology, intradermal nevi, papilloma, dermatofibroma, warts, removal of ingrown toenails; *Curettage, cautery and cryocautery*: warts, verrucae and other skin lesion; *Other*: removal of foreign bodies and nasal cautery. The Society of teachers of emergency medicine identified 26 important procedures in emergency medicine³⁸. A minimal set of 39 procedures has been defined by the American Board of Family Practice³⁹. Wigton³⁰ has published widely on procedural skills in the field of internal medicine. His comments and suggestions are very helpful in the field of family medicine as well. Certainly procedural competency is of the utmost importance in the invasive procedures that general practitioners are expected to perform in South Africa, yet the research in this field is strikingly lacking for developing countries.

It is clear that various clinical procedures are done in family practice. These procedures can be divided into office procedures²⁷, surgical procedures^{33,40}, emergency procedures²⁸ and radiological imaging procedures. In a South African context, various clinical procedures are performed by general practitioners. There is however not much data available on which procedures are done by general practitioners and would therefore be included in family practice residency programs. One would assume that this will reflect in the residency programs of academic institutions were general practitioners are trained.

Patient safety and quality of diagnostic and therapeutic information depend on the skill with which practitioners perform procedures. It is often assumed that residents in Family Practice receive adequate procedural training, but this is not always the case. Many learn to perform procedures only after their training. General practitioners need however to be fully competent in every procedure they perform. Wigton³⁰ points out that average resident knowledge traditionally reflect excellence in one area, which compensates for

weakness in another. This is not the case for procedural competency where proficiency in one procedure does not compensate for deficiency in another. Patients expect absolute competence. Our challenge is to ensure that general practitioners acquire competency in the procedures they will need in practice, not only regarding technical ability but also cognitive skills regarding the performance of the procedure.

There is a need to identify the problem procedures and address the cognitive skills domain of clinical anatomy necessary to perform a safe and successful procedure.

Concerns like patient safety and potential liability exposure have increased interest in procedural skills of medical practitioners. Training of procedural skills did not always receive great attention in the literature in the past⁴¹. Certainly for general practitioners in South Africa, training in procedures is not aggressively monitored, partly because of the conception of regional variations in the procedures performed and consequently the lack of consensus about which procedures are necessary to be mastered. Little information is available on which procedures are performed by general practitioners and whether these procedures match those they possibly learned during residency.

There is a need to identify the procedures that are required in developing countries as well.

The need for procedural training is not confined to postgraduate medical education. The General Medical Council in the UK⁴² states that the acquisition of a range of practical skills, which every graduate must have in preparation for house officer responsibilities, is essential to a core undergraduate curriculum. Clinical anatomy has a definite responsibility in this field. This notion is underscored by the Association of American Medical Colleges⁴³, by stating that before graduation a student should have demonstrated to the satisfaction of the faculty the ability to perform routine technical procedures including the following *minimum*: venipuncture, inserting an intravenous catheter, arterial puncture, thoracocentesis, lumbar puncture, inserting a nasogastric tube, inserting a Foley's catheter and suturing lacerations.

1.4 South African context

Different family practice situations exist in South Africa. They can be differentiated as follows:

- a) General practitioners working in hospital practice in urban and rural hospitals.
- b) General practitioners working in private practice situations in urban and rural practices.

In South Africa the term general practitioner is usually used for referring to a practitioner without a postgraduate masters degree including a Masters in Family Medicine. If a practitioner would obtain a Masters degree in Family Medicine which is called differently depending on the institution where it was obtained, he/she would be referred to as a family physician. The scope of this study is however broader and includes both general

practitioner and family physician working in hospital practice. Private practice situations (where general practitioners or general practitioners run their own practice) were not included in this study.

It is generally accepted that rural general practitioners will have to perform more procedures than their urban counterparts^{44,45,46,47}. These studies have all been conducted in developed countries. No study has however been done to compare and correlate the performance of procedures in different South African hospital practices. We do not really know what procedures general practitioners are doing in their practices and we certainly do not know what the influence of clinical anatomy on the performance of these procedures are.

A minimal set of 39 procedural skills (both inpatient and outpatient) has been defined by the American Board of Family Practice³⁹. This may have some relevancy in South Africa, but procedures performed in developing countries may be very different. Although various studies determined the type of procedures done in family practice^{27,28,34,48}, none of them were done in developing countries especially not in South Africa.

A variety of clinical procedures being both diagnostic and therapeutic are performed by general practitioners in developing countries like South Africa. Arterial and venous access, fluid drainage from body cavities, nerve blocks, not to mention the almost infinitely variable manifestations of trauma are but a few of the examples in South African family practice.

Research in clinical procedures in family practice is of particular importance for several reasons.

- Firstly, general practitioners in rural areas need to perform several different clinical procedures, since other specialists are not always readily available for referral and the nearest hospital may be many kilometers away.
- Secondly, although many procedures can be safely performed, even relatively common procedures can be associated with significant morbidity if not performed correctly. Training and supervision in such procedures are important as part of the residency program of general practitioners.
- Thirdly, governments, insurance companies and patients increasingly demand procedures to be done on an outpatient basis to reduce health care costs and to avoid the inconvenient stay in hospital and often long waiting periods to see a specialist²⁷. One British study estimated savings of £15000 to a local health authority in one year if one general practitioner performed four procedures weekly³². Performing procedures in family practice has been shown to be cost effective, convenient for patients and professionally satisfying for general practitioners⁴⁹.

General practitioners in developing countries have to rely heavily on their anatomical knowledge in performing clinical procedures. Medical schools in developing countries therefore have a responsibility in teaching their students clinical anatomy to ensure that their qualified physicians that can best provide their patients with proper performance of diagnostic and therapeutic procedures.

Developing countries are often deprived of high technology for the performance of clinical procedures. Patients in this environment still need good quality care, although the infrastructure is less developed.

Doctors in family practice should therefore have an appropriate and sound knowledge of clinical anatomy. Improvement of the status of knowledge of clinical anatomy will therefore be of tremendous importance in improving patient care in developing countries. No study has been undertaken in the past to evaluate and improve on clinical anatomy as the basis for performance of clinical procedures in developing countries.

Training programs in developing countries have unique challenges. This is also true for clinical anatomy training programs:

- General practitioners in hospital practices often lack the infrastructure and manpower to attend continued medical education programs located at tertiary learning centers⁵⁰.
- Training programs for procedural competency regarding the knowledge base and skills are often based on data from developed countries and do not address the specific needs for developing countries where a higher level of competency is often required to perform a wider range of clinical procedures.
- Successful training programs often have more emphasis on self-directed learning within the available infrastructure of the family physician. Various modalities of telematic education deliveries need to be explored¹³. Online courses are perhaps not ideal due to problems to access the internet via small capacity modems. A training program on a CD-ROM platform may therefore be a better choice needing only a personal computer. Such training programs make a whole range of media available in an interactive way to facilitate self-directed learning¹³.

1.5 Assessment of clinical competency

Assessment of the competency of general practitioners to perform clinical procedures is important to evaluate the outcome of quality patient care. Competency can be assessed in basically three different ways or combinations of them. A performance based test, a written knowledge test of skills or a self- assessment questionnaire. Performance based testing (multiple station evaluation) is obviously the best method to assess proficiency in hands-on procedures⁵¹. In this study Jansen *et al*⁵¹ assessed competency of technical skills of general practitioners with all three methods. They showed that the score on the self-assessment questionnaire showed a rather low correlation with the performance-based test. They also showed that, although performance-based testing is obviously the best method to assess proficiency in hands-on procedures, a written test can serve as a reasonable alternative, particularly for screening and research purposes. A written test on the knowledge framework of clinical procedures could therefore correlate well with a performance-based test. This notion is underscored by Wigton³⁰ stressing the importance of the clinical knowledge background in the performance of clinical procedures. This could however be quite different among general practitioners working in variable practice situations in developing countries. No study report on the assessment of clinical anatomy

as part of the competency of general practitioners to perform clinical procedures.

Page *et al*⁵² described the so-called “key features approach” to assess basic sciences within a clinical context. Key features of clinical anatomy are according to this approach assessed within a clinical context. A Key feature applied to clinical anatomy competency with regard to procedures, can be defined as follows:

- i) A crucial step in the procedure where it is more likely to make errors during the performance of the procedure. This means clinical anatomy features which are crucial to prevent difficulties and complications. Introduction
- ii) A difficult concept to identify during the performance of the procedure.
- iii) Key anatomical features imply that there are clinical anatomy points during the performance of the procedure that are not of equal importance when compared to the critical key features.

It is believed that these features are discriminating measures of competence⁵².

During the key features assessment approach a rich stimulus format is provided which represents the clinical context. This means an outline of a clinical case or clinical scenario from which the key feature is to be asked. The stimulus format is followed by the response format (question) in which the key feature is assessed. This assessment can be done by various assessment modalities including multiple-choice questions, essay type questions or identification on images. The stimulus format of the test, dictates the validity of the test rather than the response format⁵³. This is the case when problem solving is measured, i.e. when clinical anatomy concepts are tested within the procedural scenario.

Van der Vleuten⁵³ describes the concept of utility of assessment methods. He defines the utility of an assessment method as follows:

$$U(\text{utility}) = \text{Reliability} + \text{Validity} + \text{Educational impact} + \text{Acceptability} + \text{Cost}.$$

These concepts are briefly discussed here and as they relate specifically to the key features approach of assessment.

Reliability

Reliability refers to the consistency and accuracy with which a test measures what it is supposed to measure. To achieve this wide sampling of content across the area is needed. This is imperative to allow for stable and reproducible scores.

Validity

It is important to make sure that an assessment actually assesses what is intended to be evaluated. This concept is referred to as the validity of an assessment method. Assessment can be performed on various levels as described by Miller’s assessment pyramid⁵⁴ (Fig 1). According to this model an assessment method can assess

knowledge (level 1), application of knowledge (level 2), simulation of the applied knowledge like in the case of a procedure (level 3) or the actual performance of a procedure in the real setting (level 4).

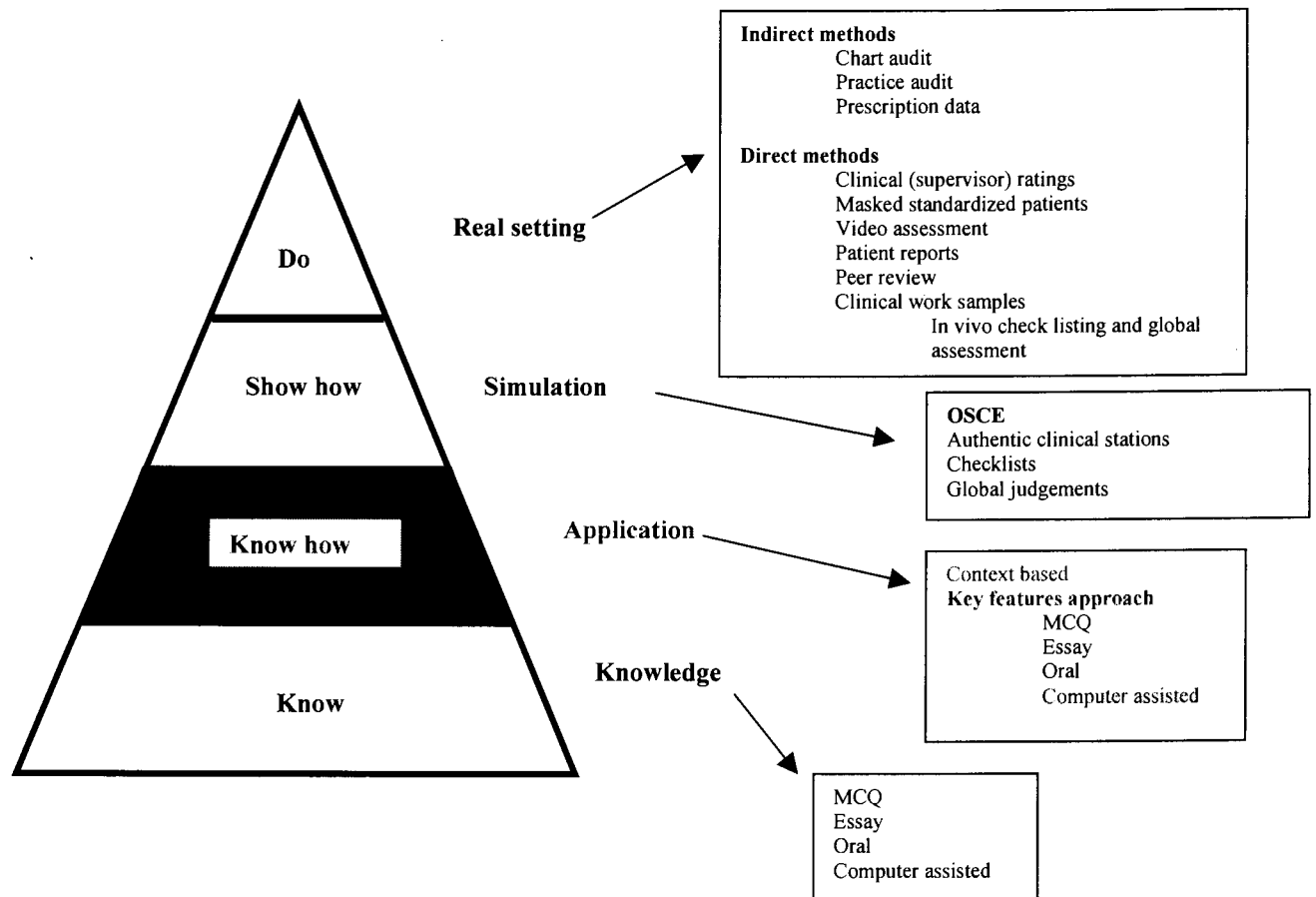


Fig 1. Miller's⁵⁴ assessment pyramid correlated with assessment methods as described by Van der Vleuten⁵³

Educational impact

Any assessment action has a natural educational reaction. By testing knowledge on the first level of Miller's pyramid by multiple-choice questions for example, students adapt a learning style of recognizing facts. This may be valuable for recognizing facts in the knowledge domain, but is detrimental for assessing actual procedural competency.

In clinical anatomy assessment we need to make sure that assessment occurs on the application of knowledge and performance levels. Clinical anatomy needs to be assessed within a clinical framework. By doing this students will adapt a learning style which always asks the question of relevancy.

Acceptability

Assessment programs need to be acceptable for faculty. Performance based assessment of procedural skills by means of an objective structural clinical exam (OSCE) may prove to be valid, reliable and have a desired educational impact, but may be unacceptable to the faculty who conduct the exam with regards to logistical constraints that may exist. This is often the case in developing countries. OSCE's are logistically complex and time consuming. Harden *et al*⁵⁵ introduced the OSCE about 25 years ago. This assessment method involves examinees rotating around a circuit of stations at which they are required to perform a variety of tasks. Tasks may include taking a brief history, performing some portion of a physical examination, demonstrating procedural skills on a cadaver, counseling a patient, and so on. Performance is rated on checklists to the content of each station. To reach adequate reliability long tests are necessary which must include large numbers of stations to obtain a stable reproducible assessment⁵⁶. Van der Vleuten *et al*⁵⁷ has shown that a knowledge test of skills correlates well with an OSCE but at relatively lower cost and easier logistics.

Cost

Good assessment programs are costly but are an invaluable investment in teaching and learning. A well-structured assessment of the application of knowledge and elements of simulation may be more cost effective than a performance based exam like an OSCE.

The following table illustrates the utility of both the key features assessment format, testing on the "know how" level of Miller's pyramid and the OSCE testing on the performance levels of Miller's assessment pyramid (Table 1).

	Key features approach	OSCE
Reliability	Fine with good sampling	Fine with good sampling
Validity	Level 2 of Miller's pyramid	Level 3 or 4 of Miller's pyramid
Educational impact	Good in problem solving skills and cognitive framework assessment	Good in performance skills
Acceptability	Good	Staff intensive, time intensive
Cost	Reasonable	May be very high

Table 1. Utility of both the key features approach and OSCE.

The key features assessment format allows to move from the test your knowledge domain of the assessment pyramid as described by Miller, to the “know how to do/use” domain. When emphasizing clinical reasoning skills we need to climb the pyramid to higher levels of assessment⁵³. This has particular relevance to clinical anatomy.

Computer technology provides an ideal platform to perform key feature assessment. A rich stimulus format can be created by various media including images, audio, video and text in an interactive manner. The response format can then assess the key anatomical features within the clinical context created in the stimulus format.

Proper development of the stimulus format is therefore extremely important since it dictates the validity of the test⁵³. When translating this model to training procedural skills and specifically the knowledge domain of clinical anatomy, the following is important:

- The clinical procedure provides a rich clinical context (stimulus format).
- Key anatomical features need to be identified, which are crucial to ensure the safe and successful performance of the procedure.
- These key anatomical features are found in both the anatomical pitfalls and complications of the clinical procedure.
- As soon as the key anatomical features are identified, a question format can be created to assess the anatomical knowledge base within the clinical context of the procedure.

The key anatomical features, once identified, can also be used to assess on higher levels of Miller's assessment pyramid, i.e. the levels of simulation and actual performance of the procedure. This can be done by checklisting the key anatomical features as the

procedure is performed in for example an OSCE⁵⁹. Assessment of knowledge can therefore occur within a performance based assessment environment, whether real or simulated⁵⁸.

Reznick *et al*⁵⁹ has developed the Objective Structured Assessment of Technical Skill (OSATS) for assessing surgical trainees. During this assessment surgeons carry out the procedure on a model or cadaver. Every station has a specialist examiner using task specific checklists and global rating scales. Clinical anatomy can be assessed by key anatomical features in the checklist. To run an OSATS exam is very expensive and it seems that when assessing clinical anatomy competency, the key feature approach as described by Page *et al*⁵² with key elements of simulation may be adequate.

Chapman *et al*⁶⁰ has described a unique approach using computer based multimedia to assess the performance of procedures. To perform a thoracotomy a student would use the mouse and a menu set to indicate each procedural action with corresponding instruments and materials needed. Placement, orientation and extent of each action is also indicated by the examinee. A still frame or motion video then displays the procedural action as the sequence was entered. A score is then derived from the electronically generated data.

Areas of cognitive orientation like anatomy need to be assessed in a clinically rich environment. This can be done in a virtual, simulated or real clinical environment. Hager *et al*⁵⁸ develops further on this notion when he argues that it is important to advance from traditional methods of testing knowledge which tend to focus on recall and understanding and assess knowledge in the clinical situation where emphasis is laid on synthesis and application. Assessing basic anatomical knowledge in a clinical situation requires comprehension, application, analysis, synthesis and evaluation.

To evaluate the effectiveness of a training program, objective data from structured observations or performance assessment examinations need to be obtained. Self-assessment of clinical competence does not necessarily reflect true ability²⁵.

2. Aims and Objectives

2.1 To develop a survey to determine the following objectives:

- 2.1.1 To determine which clinical procedures are performed in both urban and rural hospital practices in South Africa.
- 2.1.2 To determine the frequency of performance of the procedures determined.
- 2.1.3 To determine the importance rating of clinical procedures by general practitioners in their practice situation.
- 2.1.4 To determine the comfortability of general practitioners in performing the procedures.
- 2.1.5 To determine the difficulties associated with the procedures.
- 2.1.6 To determine the anatomically related complications encountered whilst performing the procedures.
- 2.1.7 To evaluate the assessment of doctors on the role of clinical anatomy competency in reducing difficulties and complications.
- 2.1.8 To evaluate the assessment of doctors on the role of clinical anatomy in improving confidence in the performance of clinical procedures.

2.2 To conduct the developed survey.

2.3 To select a total of **15 problem procedures** from the list determined proportional in every category (emergency procedures, surgical procedures, office procedures and imaging procedures),

- which are often performed (incidence more than 50%),
- essential,
- which more practitioners are uncomfortable with rather than comfortable,
- with which doctors experience difficulties and complications,
- where most practitioners thought that improvement of critical anatomy knowledge necessary to perform the procedure will reduce difficulties and complications and
- where most practitioners thought that improvement of anatomy knowledge necessary for the procedure will increase confidence in performing the procedure.

2.4 To compare the clinical procedures as well as **competency levels** in the different hospital practice settings in South Africa (urban and rural).

2.5 To determine the **knowledge domain** relevant to the clinical anatomy necessary to perform the procedures selected in 2.3 regarding the following aspects:

- Indications,
- Contraindications/ Precautions,
- Step-by-step procedure,



- Materials,
- Anatomical pitfalls and
- Anatomically relevant complications.
- References

2.6 To develop a **clinical anatomy-training program** for the procedures selected in 2.3, within a continued medical education environment.

3. Materials and Methods

3.1 Development of a survey-questionnaire

Objectives 2.1.1 - 2.1.8 were determined by a survey that was conducted as stated in 2.2 by means of a questionnaire.

A list of 57 procedures relevant to family practice in South Africa was determined by consulting various resources. An extensive literature survey was performed to determine what procedures are regarded as important for general practitioners in various practice situations all over the world. These included the standard procedures that are identified by family practice bodies like the American Board of Family Practice in the United States of America³⁹ and the National Health Service (NHS) in the United Kingdom³⁷. After determining the list of procedures from the literature, they were discussed with experts in the field of Family Practice in South Africa and modified appropriately.

From the literature, clinical procedures in Family Practice can be divided in emergency procedures, surgical procedures, office procedures and imaging procedures^{25,32,33,34,35}. Most procedures were chosen because of their relative importance. Procedures where a sound understanding of anatomy is crucial were included as well as those procedures determined by the American Association of Clinical Anatomists¹.

The questionnaire was reviewed at several stages.

Table 2 provides the list of procedures determined.

Statements or questions were developed to reflect the specific aims and objectives and determine the response(s) of the general practitioners. This is summarized in Table 3.

Table 2. List of procedures

<i>Emergency procedures</i>	
1	Oro/nasotracheal intubation
2	Cricothyroidotomy
3	Vascular access: Peripheral arm veins
4	Vascular access: Femoral vein
5	Vascular access: Great saphenous vein
6	Subclavian vein catheterization
7	Internal jugular vein catheterization
8	Pretibial intraosseous puncture/ infusion
9	Intercostal drain insertion
10	Lumbar puncture
11	Arterial blood puncture for blood sampling
12	Pericardiocentesis
13	Umbilical line placement
14	Suprapubic catheterization and puncture
15	Eye injury examination
<i>Surgical procedures</i>	
16	Reduction of uncomplicated forearm fractures
17	Sigmoidoscopy and proctoscopy
18	Dilatation and curettage
19	Episiotomy
20	Normal vaginal delivery
21	Caesarian section
22	Sterilization
23	Ectopic pregnancy surgery
24	Circumcision
25	Excision of external thrombosed hemorrhoids, Injection or ligation of internal hemorrhoids
26	Appendectomy
27	Tonsillectomy and adenoidectomy
28	Wrist block and digital nerve block
29	Pudendal nerve block
30	Brachial plexus block
<i>Office procedures</i>	
31	Injection of shoulder joint
32	Colposcopy
33	Paronychia incision and drainage
34	Upper gastrointestinal endoscopy
35	Knee joint aspiration
36	Liver biopsy
37	Indirect laryngoscopy
38	Epistaxis and nasal packing
39	Bone marrow aspiration
40	Aspiration of pleural effusion
41	Reduction of shoulder dislocation
42	Reduction of elbow dislocation
43	Reduction of interphalangeal joint dislocation

44	Reduction of hip dislocation
45	Nasopharyngoscopy
46	Slit lamp examination
47	Rectal examination
48	Vaginal examination
<i>Imaging procedures</i>	
49	Musculoskeletal ultrasound
50	Abdominal CT scan
51	Brain CT scan
52	Chest X-Ray
53	Abdominal X-Ray
54	Pelvic X-Ray
55	Neck X-Ray
56	Obstetric ultrasound
57	Abdominal ultrasound

Table 3. Questionnaire development of aims and objectives, statements or questions and responses for every procedure

<i>Aim</i>	<i>Statement/ Question</i>	<i>Response</i>				
2.1.1 To determine which clinical procedures are performed in both urban and rural hospital practices in South Africa.	I perform this procedure in my practice.	Yes / No				
2.1.2 To determine the frequency of performance of the procedures determined.	How many times did you perform this procedure in the past year?	<table border="1"> <tr> <td>More than 20</td> <td>10-20</td> <td>5-10</td> <td>Less than 5</td> </tr> </table>	More than 20	10-20	5-10	Less than 5
More than 20	10-20	5-10	Less than 5			
2.1.3 To determine the importance rating of clinical procedures by general practitioners in their practice situation.	The performance of this procedure is important in my practice situation.	<table border="1"> <tr> <td>Essential</td> <td>Desirable but not essential</td> <td>Useful</td> <td>Not necessary</td> </tr> </table>	Essential	Desirable but not essential	Useful	Not necessary
Essential	Desirable but not essential	Useful	Not necessary			
2.1.4 To determine the comfort rating of general practitioners in performing the procedures.	I feel comfortable to perform this procedure.	<table border="1"> <tr> <td>Very comfortable</td> <td>Fairly comfortable</td> <td>Uncomfortable</td> <td>Very uncomfortable</td> </tr> </table>	Very comfortable	Fairly comfortable	Uncomfortable	Very uncomfortable
Very comfortable	Fairly comfortable	Uncomfortable	Very uncomfortable			
2.1.5 To determine the difficulties associated with the procedures.	I find difficulty to perform this procedure due to the following reason/s:	<table border="1"> <tr> <td>Knowledge of the procedure itself</td> <td>Equipment necessary for the procedure</td> <td>Practical skills to perform the procedure</td> <td>Regional anatomy knowledge</td> </tr> </table>	Knowledge of the procedure itself	Equipment necessary for the procedure	Practical skills to perform the procedure	Regional anatomy knowledge
Knowledge of the procedure itself	Equipment necessary for the procedure	Practical skills to perform the procedure	Regional anatomy knowledge			
2.1.6 To determine the complications encountered whilst performing the procedures.	I met the following complication/s after performing this procedure: ^a	Oro/nasotracheal intubation is given as an example: <table border="1"> <tr> <td>Esophageal intubation</td> <td>Laryngospasm</td> <td>Not able to visualize vocal cords</td> </tr> </table>	Esophageal intubation	Laryngospasm	Not able to visualize vocal cords	
Esophageal intubation	Laryngospasm	Not able to visualize vocal cords				
2.1.7 To evaluate the assessment of doctors on the role of clinical anatomy competency in reducing difficulties and complications.	The improvement of critical anatomy knowledge necessary to perform this procedure will reduce difficulties and complications.	<table border="1"> <tr> <td>Strongly agree</td> <td>Agree</td> <td>Disagree</td> <td>Strongly disagree</td> </tr> </table>	Strongly agree	Agree	Disagree	Strongly disagree
Strongly agree	Agree	Disagree	Strongly disagree			

^a The complications differ for every procedure. These complications were determined by an extensive literature review and by selecting those that are specifically anatomically relevant.

<p>2.1.8 To evaluate the assessment of doctors on the role of clinical anatomy in improving confidence in the performance of clinical procedures.</p>	<p>Improvement of anatomy knowledge necessary for the procedure will increase my confidence in performing the procedure.</p>	<table border="1" style="margin-left: auto; margin-right: auto;"> <tr> <td style="text-align: center;">Strongly agree</td> <td style="text-align: center;">Agree</td> <td style="text-align: center;">Disagree</td> <td style="text-align: center;">Strongly disagree</td> </tr> </table>	Strongly agree	Agree	Disagree	Strongly disagree
Strongly agree	Agree	Disagree	Strongly disagree			

(Table 3 continued)

Practitioners had to respond by ticking the appropriate box or boxes. This way of answering the questionnaire facilitated the practitioner response, eased the evaluation process and provided the means to compare data for various calculations.

A literature survey was performed to determine the most common complications for every procedure which are anatomically related. These were included in the questionnaire. General practitioners had to tick those complications that they have experienced before.

They were able to tick more than one box or add any complications that were not mentioned. When they did not tick any box, they did not experience any complications.

Demographic data for every practitioner was also obtained. This included age, sex, size of practice, type of hospital practice, data on year of graduation, additional postgraduate training, current practice profile and continuing education preferences.

The complete questionnaire is presented as Addendum 1.

3.1.2 Conduction of survey

Ethical clearance to conduct the survey was obtained from the Ethics and Research Committee of the Faculty of Health Sciences at the University of Pretoria as well as from the relevant people in charge of the different hospital practices, either the superintendent of the hospital or the senior family physician in charge of the department.

The hospitals were selected in three different provinces namely Gauteng, Mpumalanga and Northern Province. The aim was to reach at least a sample size of 40 fully completed questionnaires for each of the urban and rural hospital practices.

The selection of the hospitals was not done on a random basis in the sense that every hospital in each province had an equal chance of being selected. The hospitals in Gauteng that were selected being Pretoria Academic Hospital, Kalafong Hospital and Mamelodi hospital were all in the municipal boundaries of the Tswane municipality and are regarded as urban. Another urban hospital being Rob Ferreira was also selected from the Mpumalanga province. These hospitals were regarded to sufficiently represent the urban hospital practices.

For the rural hospital practices 4 hospitals were selected for their remote location being Warmbaths (120 km from Pretoria), Elim (100 km from Pietersburg), Tshilidzini (160 km

11642834
b15860863

from Pietersburg) and Donald Fraser Hospitals (> 250 km from Pietersburg) from the Northern Province and Temba Hospital (60 km from Nelspruit) from the Mpumalanga Province. These hospitals being up to 250 km from an urban setting were regarded as a good sample representing the rural hospital practices.

General practitioners in various hospital practices filled out the 21-page descriptive cross sectional questionnaire. The average time to fill out the questionnaire was 45 to 75 minutes. Various hospitals were randomly selected from three provinces in South Africa (Fig 2). Gauteng, Northern Province and Mpumalanga are the provinces from which the Faculty of Health Sciences at the University of Pretoria receives patient referrals and where student training is done.

For Gauteng:
(Fig 3) Kalafong Hospital (urban)
Pretoria Academic Hospital (urban)
Mamelodi Hospital (urban)

Northern Province:
(Fig 4) Warmbaths Hospital (rural)
Elim Hospital (rural)
Tshildzini Hospital (rural)
Donald Fraser Hospital (rural)

Mpumalanga:
(Fig 5) Themba Hospital (rural)
Rob Ferreira Hospital (urban)

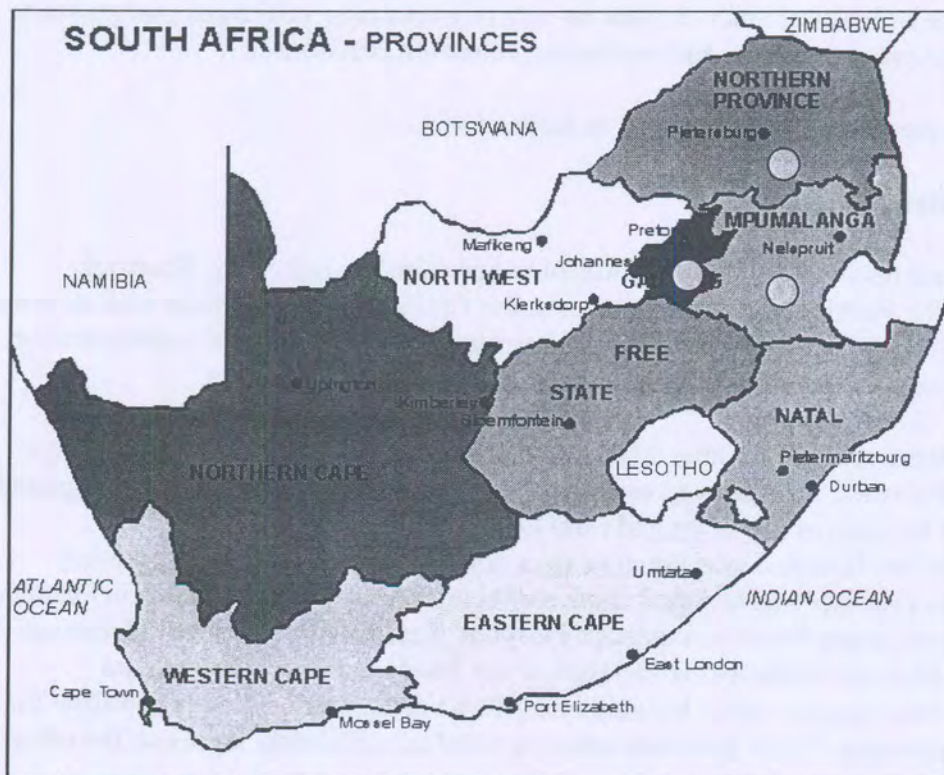


Fig 2. Map of South Africa⁶¹. The survey was performed in Gauteng, Northern Province and Mpumalanga. (Indicated by the (●))

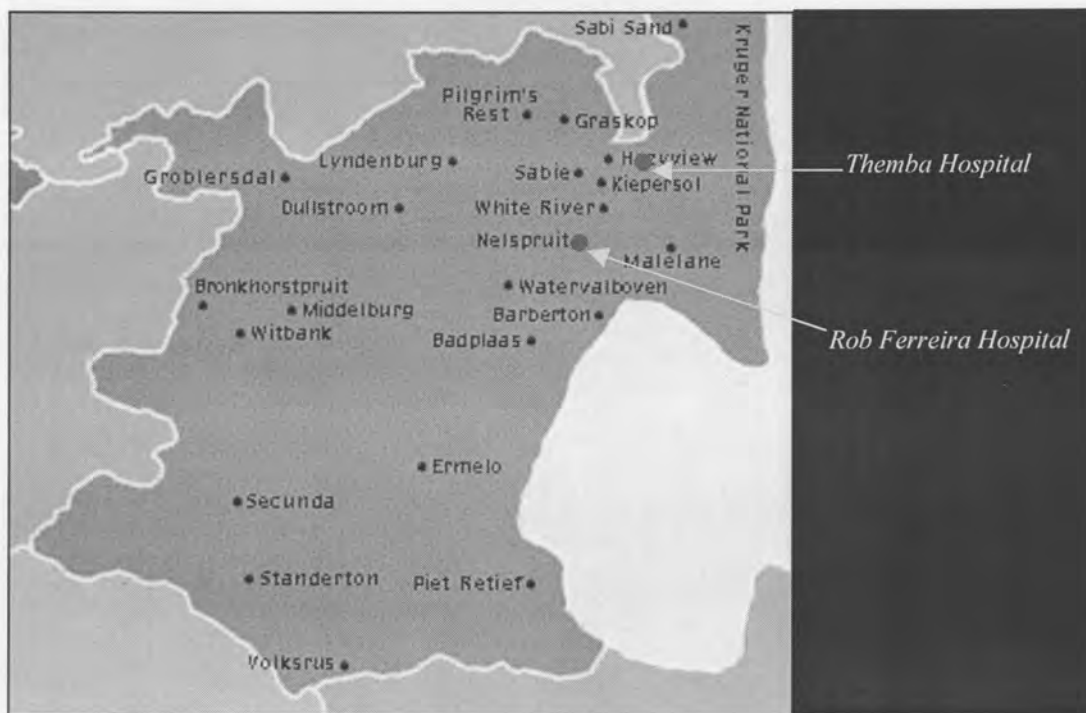

Fig 5. Mpumalanga⁶² with the following hospitals indicated: Themba Hospital and Rob Ferreira Hospital

The aim was to reach at least a sample size of 40 fully completed questionnaires for each of the urban and rural hospital practices. An urban hospital practice was defined to lie within the boundaries of a municipally declared urban area and a rural hospital practice outside the urban boundaries.

An appointment was made with the superintendent of the hospital or family physician in charge of the Department of the listed hospitals. This appointment had the following aims:

- a) To meet the general practitioners available at the hospital at the time of the appointment (all general practitioners except those busy in either casualty with an emergency or in the operating room busy with an emergency operation or those on leave). The appointment was made during the weekly meeting of the doctors with either the superintendent or the Family Physician in charge. All doctors in the hospital not meeting the exclusion criteria listed below had the opportunity to fill in the questionnaire.
- b) To provide a short introduction on the aims of the study and to emphasize that taking part in the study is entirely voluntary and anonymous.
- c) To have the questionnaires completed to the best of the physician's knowledge.

All general practitioners except those busy in either casualty with an emergency or in the operating room busy with an emergency operation or those on leave, completed the questionnaire. This figure involved more than 80% of the total general practitioners working at the hospital.

Doctors that were busy in casualty or the operating room, on leave or ill during the conduction of the survey were similar to those completing the questionnaire if they were not excluded by the exclusion criteria.

Only practitioners with the MBChB degree with or without a postgraduate degree in Family Medicine or other diploma's were included in the study.

The following were exclusion criteria:

- Doctor registered a specialist different from Family Medicine
- Part-time doctors
- Doctor in private practice

The study's aim was to involve only doctors in hospital practice and no private practice was involved in the study.

General practitioners in various hospital practices filled out the 21-page descriptive cross sectional questionnaire in their own time. The average time to fill out the questionnaire was 45 to 75 minutes. Because the questionnaire was structured in a way that certain choices had to be made (see attached questionnaire), doctors had to tick the appropriate box. No interviews were performed. The completed questionnaire was handed over in a box supplied for the collection of the completed questionnaires. The researcher was available to answer any questions that may arise, although the questionnaire was self explanatory. There was therefore a slight theoretical chance for the researcher to identify a specific respondent completed questionnaire and therefore abridge anonymity, although the respondent was assured of staying anonymous due to above mentioned measures. The researcher however protected anonymity at all times and refrained from transgressing good ethical conduct.

General practitioners were free to add and rate on the same scales, any unlisted clinical procedure they perform.

3.1.3 Analysis of data produced by the survey

Every data-item on the questionnaire was given a numerical value for all eight questions. The data was meticulously entered into the Excel® statistical program for every procedure. There were 30 data points for every procedure. This means a total of 165 870 data points were entered.

Incidence of performance was calculated as being either yes (1) or no (2). The values were added by simple summation and mean values determined.

For **frequency of performance** analysis the following responses were quantified as follows: More than 20 (1); 10-20 (2); 5-10 (3); Less than 5 (4); no response (0). A simple count function was performed (COUNTIF) to determine how many doctors responded in the various categories.

For the **importance rating** of the various procedures, the different categories were quantified as follows and then summated by a simple count function (COUNTIF) to determine the result of hits in every category: Essential (1); Desirable but not essential (2); Useful (3); Very uncomfortable (4); no response (0).

Regarding the **determination of measure of comfort**, the different categories were quantified as follows and the summated by a simple count function (COUNTIF) to determine the result of hits in every category: Very comfortable (1); Fairly comfortable (2); Uncomfortable (3); Very uncomfortable (4); no response (0).

Regarding analyzing the **difficulties encountered**, the different categories were quantified as follows and then summated by a simple count function (COUNTIF) to determine the result of hits in every category: Knowledge of the procedure itself (1); Equipment necessary for the procedure (2); Practical skills to perform the procedure (3); Regional anatomy knowledge (4); no response (0).

The various **complications** encountered were analysed by quantifying every choice with a numerical value for each procedure and then summating the various categories.

To evaluate the assessment of doctors on the **role of clinical anatomy competency in reducing difficulties and complications**, the different categories were quantified as follows and then summated by a simple count function (COUNTIF) to determine the result of hits in every category: Strongly agree (1); Agree (2); Disagree (3); Strongly disagree (4); no response (0).

To evaluate the assessment of doctors on the **role of clinical anatomy in improving confidence in the performance** of clinical procedures, the different categories were quantified as follows and then summated by a simple count function (COUNTIF) to determine the result of hits in every category: Strongly agree (1); Agree (2); Disagree (3); Strongly disagree (4); no response (0).

The chi-square test for categorical data was employed by means of the STATISTIX for Windows version 7 statistical software to compare data from urban and rural hospital practice groups.

3.2 Selection of procedures and criteria for selection

Various selection models were developed to select a total of 15 problem procedures proportional in every category (emergency procedures, surgical procedures, office procedures and imaging procedures). This was done for no other means of selection criteria were found in the literature.

Scoring options A, B,C and D were developed and are attached as Addendum 2.

Scoring option C was selected to best represent the selection criteria of the study. These were the following:

- | | |
|--------------------------------------------------------------------------------------------------------------------------------------------------------|---------|
| 1. Incidence of performance (>50%) | 1 point |
| 2. Essentiality (>60%) | 1 point |
| 3. Comfortability (more are uncomfortable than comfortable) | 1 point |
| 4. Difficulty or complication related to anatomy experienced by more than 25% of doctors | 1 point |
| 5. More than 80% thought that improvement of critical anatomy knowledge necessary to perform the procedure will reduce difficulties and complications. | 1 point |
| 6. More than 80% thought that improvement of anatomy knowledge necessary for the procedure will increase confidence in performing the procedure. | 1 point |

Total: 6 points

Procedures that scored highest in every section (emergency procedures, surgical procedures, office procedures and imaging procedures) were subjected to the following to select the number (emergency procedures = 6, surgical procedures = 4, office procedures = 4 and imaging procedures = 1) in every category: Sum of the following categories: Uncomfortable + very uncomfortable + the highest difficulty or complication.

Due to the fact that the focus of this study is on the influence of clinical anatomy on the performance of procedures, procedures were scored in a way by giving aspects of difficulties and complications met and the assessment of the influence of clinical anatomy on performance, more weight than for instance frequency of performance alone. The fact whether the procedure was regarded as essential in the specific practice situation was regarded as important as well, because of its reflection on the need in the practice and the life saving nature of the procedure.

Scoring option C was therefore eventually chosen to select the procedures which general practitioners ranked important where most difficulties and complications were met and where the influence of clinical anatomy knowledge on the safe and successful performance of the procedure, was ranked highest.

3.3 Comparing urban and rural hospital practices

Data from the questionnaire was compared for the urban and rural hospital practices for objectives 2.1.1 to 2.1.8 regarding the selected problem procedures identified in 3.2 (Selection of procedures and criteria for selection). Statistical analysis to compare the urban and rural group regarding various aspects was done by the student t-test.

3.4 Development of a clinical anatomy knowledge base for each selected problem procedure.

After selecting the problem procedures according to the criteria in Scoring option C, the clinical anatomy content for every procedure was developed. This was done by developing a clinical anatomy knowledge base for every selected procedure with the following standard pattern for every procedure:

1. Indications
2. Contraindications/ Precautions
3. Step by step procedure
4. Materials
5. Anatomical pitfalls
6. Complications (anatomically relevant)
7. References

The clinical anatomy reference for the selected procedures was developed by an extensive literature study of the most recent and relevant publications, both in the basic medical and clinical sciences.

The Medline database was studied via an interactive windows-based search engine OVID WEB via the online service of the Academic Information Service of the University of Pretoria, as well as the catalogue of both the libraries of the University of Pretoria and the University of Cambridge. Publications in the following languages were included: Afrikaans, Dutch, English and German.

Content experts¹ in Cambridge (UK), Pretoria (South Africa), New York (USA), London (UK), Bath (UK) and Nijmegen (The Netherlands), were consulted in person on relevant and important references on the essential clinical anatomy for the 15 selected procedures.

3.5 Development of a clinical anatomy training program for the selected problem procedures

Due to the unique circumstances of general practitioners in hospital practices in South Africa, a training program was developed that took the following factors into account:

1. General practitioners in hospital practices are often practicing in rural areas, far from tertiary care institutions.
2. General practitioners have limited time to attend a program based at a tertiary teaching center like the Faculty of Health Sciences at the University of Pretoria. This is due to constrained resources in hospital practices.
3. Most general practitioners have access to computers but often have difficulty to get online¹³.
4. General practitioners need an accessible program addressing their specific needs.

Therefore a program was developed with the following characteristics:

1. A strong emphasis is laid on self-directed learning.
2. A multimedia platform is used from a CD-ROM. There is consequently no dependence on online facilities.
3. A non-linear mode to access the program is used to address specific and relevant needs and questions in a time efficient way.
4. No previous computer skills are necessary.
5. The platform used is easy to run and widely available (like PowerPoint®).
6. The platform can also be used both by teacher in teaching and small group interactions at hospital practices.
7. Various media are included to produce a Virtual Procedures Room, with the following components:

¹ The following content experts are named:

Prof PH Abrahams, Kigezi International School of Medicine, Girton College, Cambridge, UK

Prof JH Meiring, Department of Anatomy, University of Pretoria, South Africa

Mr T Welsh, Queens College, Cambridge, UK

Dr IG Parkin, Department of Anatomy, University of Cambridge, UK

Mr RH Whitaker, Department of Anatomy, University of Cambridge, UK

Mr B Logan, Department of Anatomy, University of Cambridge, UK

Prof T Olson, Albert Einstein School of Medicine, New York, USA

Dr Helen Bloch, Long Island Jewish Medical Centre, New York, USA

Dr W Rennie, Long Island Jewish Medical Centre, New York, USA

Dr R Kneebone, St Mary's Hospital, London and Bath University, UK

Dr T Silver, St Georges Hospital Medical School, London, UK

Mr V Mahadevan, Royal College of Surgeons of England, London, UK

Prof J Kauer, Katholieke Universiteit Nijmegen, The Netherlands

- Orientation Room
- Clinical anatomy laboratory to illustrate the anatomical pitfalls and complications.
- Simulation room for simulation of the procedure by animated sequences, which for example show the path of a needle puncture.
- Clinical background room with the following information: Indications, contraindications, step by step approach and materials necessary for the procedure.
- Library with all the full text papers and references.

Relevant high-resolution dissection images were selected to correlate with the clinical anatomy knowledge base in order to illustrate and animate key points relevant to the specific procedure. The prosection collection of the Departments of Anatomy at the University of Cambridgeⁱ and the University of Pretoriaⁱⁱ were used to obtain images for every selected procedure, illustrating the key anatomical pitfalls and complications as well as using them as the basis for the creation of animations. Photographs of the images were taken by the author and digitized.

Various key peopleⁱⁱⁱ in the field of multimedia educational development and medical

ⁱ A word of special thanks to Mr B Logan, University prosector at the Department of Anatomy, University of Cambridge, as well as his team Mal Lazenby, Lucie Whitehead and Martin Watson who prosected most of the prosections used in the training program.

ⁱⁱ A word of special thanks to Mr EO Brüne and several medical and dental students in the Department of Anatomy, University of Pretoria, who prosected a number of the prosections used in the training program, especially a substantial number of the section on knee joint aspiration.

ⁱⁱⁱ The following multimedia and medical educational experts in and outside the field of clinical anatomy are named:

Prof PH Abrahams, Kigezi International School of Medicine, Girton College, Cambridge, UK

Prof JH Meiring, Department of Anatomy, University of Pretoria, South Africa

Prof S Stensaas, University of Utah, Salt Lake City, USA

Prof C Van der Vleuten, University of Maastricht, The Netherlands

Dr IG Parkin, Department of Anatomy, University of Cambridge, UK

Prof T Olson, Albert Einstein School of Medicine, New York, USA

Dr W Rennie, Long Island Jewish Medical Centre, New York, USA

Dr R Kneebone, St Mary's Hospital, London and Bath University, UK

Prof J Dacre, Whittington Hospital, University College London, London, UK

Prof JA Boon, Telematic Learning and Education Innovation, University of Pretoria, South Africa

Prof J Kauer, Katholieke Universiteit Nijmegen, The Netherlands

Dr J Bulte, Katholieke Universiteit Nijmegen, The Netherlands

Dr C Daetwyler, Bern, Switzerland

Mr V Mahadevan, Royal College of Surgeons of England, London, UK

Mr T Welsh, Queens College, Cambridge, UK

Mr L Wiseman, Primal Pictures, London, UK

Prof E April, Columbia University, New York, USA

Prof B Bogart, New York University, New York, USA

Dr Mtui, Cornell University, New York, USA

Dr Levine, Downstate Brooklyn Hospital, New York, USA

Dr C Goodmurphy, St Georges University Grenada, West Indies

Prof I Treadwill, Skills Laboratory, University of Pretoria, South Africa

Dr Rupert Gabriel, Bath University, UK



education were consulted in person to develop a program with various multimedia platforms and based on sound educational philosophy. These included the following people from Cambridge (UK), Pretoria (South Africa), London (UK), Salt Lake City (USA), New York (USA), Maastricht (The Netherlands), Nijmegen (The Netherlands), Bern (Switzerland), Leiden (The Netherlands), Norwich (UK) and Grenada (West Indies).

4. Results

4.1 Development and conduction of survey

A total of 102 questionnaires were obtained from the different hospitals. Five of these questionnaires were not fully completed and were not included. A number of 44 were from urban hospital practices and 53 from rural hospital practices. Table 4 illustrates the number of questionnaires obtained from each hospital.

Urban hospital practice (n=44)	Rural hospital practice (n=53)
Kalafong Hospital (n=11)	Elim Hospital (n=16)
Pretoria Academic Hospital (n=11)	Tshilidzini Hospital (n=12)
Mamelodi Hospital (n=8)	Donald Fraser Hospital (n=5)
Rob Ferreira Hospital (n=14)	Themba Hospital (n=15)
	Warmbaths hospital (n=5)

Table 4. Questionnaires obtained from different hospitals

Table 5 illustrates a summary of the demographic data for both urban and rural general practitioners concerning age, sex, years in practice and postgraduate training.

Age	23-30	30-35	35-40	40-50	>50
<i>Urban (n=44)</i>	39%	9%	18%	16%	16%
<i>Rural (n=53)</i>	55%	15%	21%	6%	2%
Sex	Male	Female			
<i>Urban</i>	60%	40%			
<i>Rural</i>	73%	27%			
Years in practice	<5	6-10	11-20	21-30	>30
<i>Urban</i>	42%	11%	21%	21%	5%
<i>Rural</i>	62%	15%	19%	4%	0%
Postgraduate training	MMed(Fam Med)	Diploma (Anesthesia e.g.)	Other (ATLS e.g.)		
<i>Urban</i>	30%	23%	32%		
<i>Rural</i>	21%	11%	21%		

Table 5. Demographic data for both urban and rural hospital groups.

Considering the remoteness of the rural hospitals, the hospitals included in the study varied from being between 50 and 250 km from a hospital with specialist services.

4.1.1 Incidence of performance

Table 6 illustrates the incidence of performance for every procedure that was included in the questionnaire. Additional procedures were mentioned at the space provided at the end of the questionnaire.

Table 6. Incidence of performance

<i>Procedure</i>		<i>Incidence of performance by doctors (%)</i>
Emergency procedures		
1	Oro/nasotracheal intubation	95.79
2	Cricothyroidotomy	26.32
3	Vascular access: Peripheral arm veins	100
4	Vascular access: Femoral vein	66.32
5	Vascular access: Great saphenous vein	56.84
6	Subclavian vein catheterization	56.84
7	Internal jugular vein catheterization	45.26
8	Pretibial intraosseous puncture/ infusion	41.05
9	Intercostal drain insertion	90.53
10	Lumbar puncture	90.53
11	Arterial blood puncture for blood sampling	67.37
12	Pericardiocentesis	23.16
13	Umbilical line placement	50.53
14	Suprapubic catheterization and puncture	75.79
15	Eye injury examination	89.47
Surgical procedures		
16	Reduction of uncomplicated forearm fractures	69.47
17	Sigmoidoscopy and proctoscopy	29.47
18	Dilatation and curettage	80.00
19	Episiotomy	73.68

<i>Surgical procedures (cont.)</i>		<i>Incidence of performance by doctors (%)</i>
20	Normal vaginal delivery	78.95
21	Cesarian section	74.74
22	Sterilization	70.53
23	Ectopic pregnancy surgery	54.74
24	Circumcision	72.63
25	Excision of external trombosed hemorrhoids, Injection or ligation of internal hemorrhoids	38.95
26	Appendectomy	38.95
27	Tonsillectomy and adenoidectomy	27.37
28	Wrist block and digital nerve block	56.84
29	Pudendal nerve block	15.79
30	Brachial plexus block	16.84
Office procedures		
31	Injection of shoulder joint	29.47
32	Colposcopy	14.74
33	Paronychia incision and drainage	71.58
34	Upper gastrointestinal endoscopy	9.47
35	Knee joint aspiration	78.95
36	Liver biopsy	5.26
37	Indirect laryngoscopy	30.53
38	Epistaxis and nasal packing	95.79
39	Bone marrow aspiration	45.26
40	Aspiration of pleural effusion	85.26
41	Reduction of shoulder dislocation	81.05
42	Reduction of elbow dislocation	53.68
43	Reduction of interphalangeal joint dislocation	65.26
44	Reduction of hip dislocation	28.42
45	Nasopharyngoscopy	10.53
46	Slit lamp examination	13.68
47	Rectal examination	97.89
48	Vaginal examination	98.95

Procedure		Incidence of performance by doctors (%)
Imaging procedures		
49	Musculoskeletal ultrasound	
50	Abdominal CT scan	9.47
51	Brain CT scan	25.26
52	Chest X-Ray	30.53
53	Abdominal X-Ray	92.63
54	Pelvic X-Ray	93.68
55	Neck X-Ray	92.63
56	Obstetric ultrasound	91.58
57	Abdominal ultrasound	82.11
		58.95

The following additional procedures were mentioned by general practitioners working in rural hospital practices: Debridement, limb amputation, laparotomy for peptic ulcer perforation, herniorrhaphy, incision and drainage of an abscess, suturing of lacerations, skin grafting, hydrocelectomy, hydrocele aspiration, prostate biopsy, breast biopsy, fistulectomy, ECG, removal of foreign bodies from nostrils, eyes and ears, removal of lipomas, ganglia and breast lumps, open reduction and internal fixation of forearm and ankle fractures, general anesthesia, pap smear, hysterectomy and assisted deliveries.

The following additional procedures were reported by general practitioners working in urban hospital practices: hydrocelectomy, pap smear, manipulation of the back, application of casts, trigger point infiltration, incision and drainage of an abscess, skin and breast biopsies, fine needle aspiration, cervix biopsy, tonometry for measurement of intra-ocular pressure, myringotomy, regional nerve blocks: femoral nerve block, suboccipital nerve block, ECG, urinary catheterization, suturing, removal of foreign bodies from nostrils, eyes and ears, colpotomy (culdocentesis).

4.1.2 Frequency of performance

Table 7 illustrates the frequency of performance of the procedures evaluated.

Table 7. Frequency of performance

<i>Procedure</i>		<i>Frequency of performance per annum</i>			
		<i>>20</i>	<i>10-20</i>	<i>5-10</i>	<i><5</i>
<i>Emergency procedures</i>					
1	Oro/nasotracheal intubation	52.63	14.74	11.59	15.79
2	Cricothyroidotomy	0	0	3.16	23.16
3	Vascular access: Peripheral arm veins	91.58	4.21	1.05	3.16
4	Vascular access: Femoral vein	22.11	12.63	9.47	23.16
5	Vascular access: Great saphenous vein	5.5	11.1	11.1	74.07
6	Subclavian vein catheterization	5.26	11.58	7.37	32.63
7	Internal jugular vein catheterization	2.11	9.47	4.21	29.47
8	Pretibial intraosseous puncture/ infusion	0	6.32	7.37	27.37
9	Intercostal drain insertion	32.63	23.16	17.89	16.84
10	Lumbar puncture	42.11	13.68	11.58	22.11
11	Arterial blood puncture for blood sampling	30.53	15.79	8.42	15.79
12	Pericardiocentesis	0	2.11	1.05	20
13	Umbilical line placement	6.32	6.32	9.47	26.32
14	Suprapubic catheterization and puncture	12.63	11.58	22.11	29.47
15	Eye injury examination	42.11	17.89	18.95	10.53
<i>Surgical procedures</i>					
16	Reduction of uncomplicated forearm fractures	29.47	12.63	10.53	17.89
17	Sigmoidoscopy and proctoscopy	3.16	6.32	10.53	12.63
18	Dilatation and curettage	49.47	17.89	5.26	8.42
19	Episiotomy	27.37	12.63	16.84	15.79
20	Normal vaginal delivery	35.79	12.63	9.47	20
21	Cesarian section	41.05	5.26	17.89	10.53
22	Sterilization	23.16	22.11	14.74	11.58
23	Ectopic pregnancy surgery	11.58	6.32	11.58	26.32
24	Circumcision	25.26	10.53	14.74	22.11

Surgical procedures (cont.)		Frequency of performance per annum			
		>20	10-20	5-10	<5
25	Excision of external thrombosed hemorrhoids, Injection or ligation of internal hemorrhoids	3.16	7.37	9.47	15.79
26	Appendectomy	3.16	6.32	8.42	21.05
29	Pudendal nerve block	2.11	4.21	2.11	7.37
30	Brachial plexus block	2.11	2.11	3.16	9.47
Office procedures					
31	Injection of shoulder joint	6.32	4.21	4.21	14.74
32	Colposcopy	2.11	4.21	1.05	7.37
33	Paronychia incision and drainage	17.89	17.89	11.58	23.16
34	Upper gastrointestinal endoscopy	4.21	2.11	0	3.16
35	Knee joint aspiration	23.16	14.74	20	21.05
36	Liver biopsy	1.05	2.11	4.21	17.89
37	Indirect laryngoscopy	7.37	1.05	4.21	17.89
38	Epistaxis and nasal packing	24.21	26.32	15.79	29.47
39	Bone marrow aspiration	2.11	7.37	9.47	26.32
40	Aspiration of pleural effusion	31.58	17.89	23.16	12.63
41	Reduction of shoulder dislocation	11.58	6.32	31.58	32.63
42	Reduction of elbow dislocation	5.26	9.47	10.53	27.37
43	Reduction of interphalangeal joint dislocation	4.21	12.63	20	27.37
44	Reduction of hip dislocation	1.05	2.11	1.05	24.21
45	Nasopharyngoscopy	2.11	1.05	1.05	6.32
46	Slit lamp examination	1.05	4.21	4.21	4.21
47	Rectal examination	82.11	8.42	5.26	2.11
48	Vaginal examination	95.79	2.11	0	0
49	Musculoskeletal ultrasound	0	2.11	3.16	4.21
Imaging procedures					
50	Abdominal CT scan	4.21	6.32	3.16	11.58
51	Brain CT scan	5.26	6.32	6.32	11.58
52	Chest X-Ray	86.32	3.16	0	2.11
53	Abdominal X-Ray	75.79	12.63	0	3.16

<i>Imaging procedures (cont.)</i>		<i>Frequency of performance per annum</i>			
		<i>>20</i>	<i>10-20</i>	<i>5-10</i>	<i><5</i>
54	Pelvic X-Ray	68.42	15.79	1.05	5.26
55	Neck X-Ray	65.26	16.84	6.32	3.16
56	Obstetric Ultrasound	44.21	18.95	12.63	6.32
57	Abdominal Ultrasound	16.84	17.89	13.68	8.42

4.1.3 Importance rating

General practitioners rated the every procedure according to its importance regarding their own practice situation, irrespective of whether they performed the procedure or not. The results are illustrated in Tables 8, 9, 10 and 11.

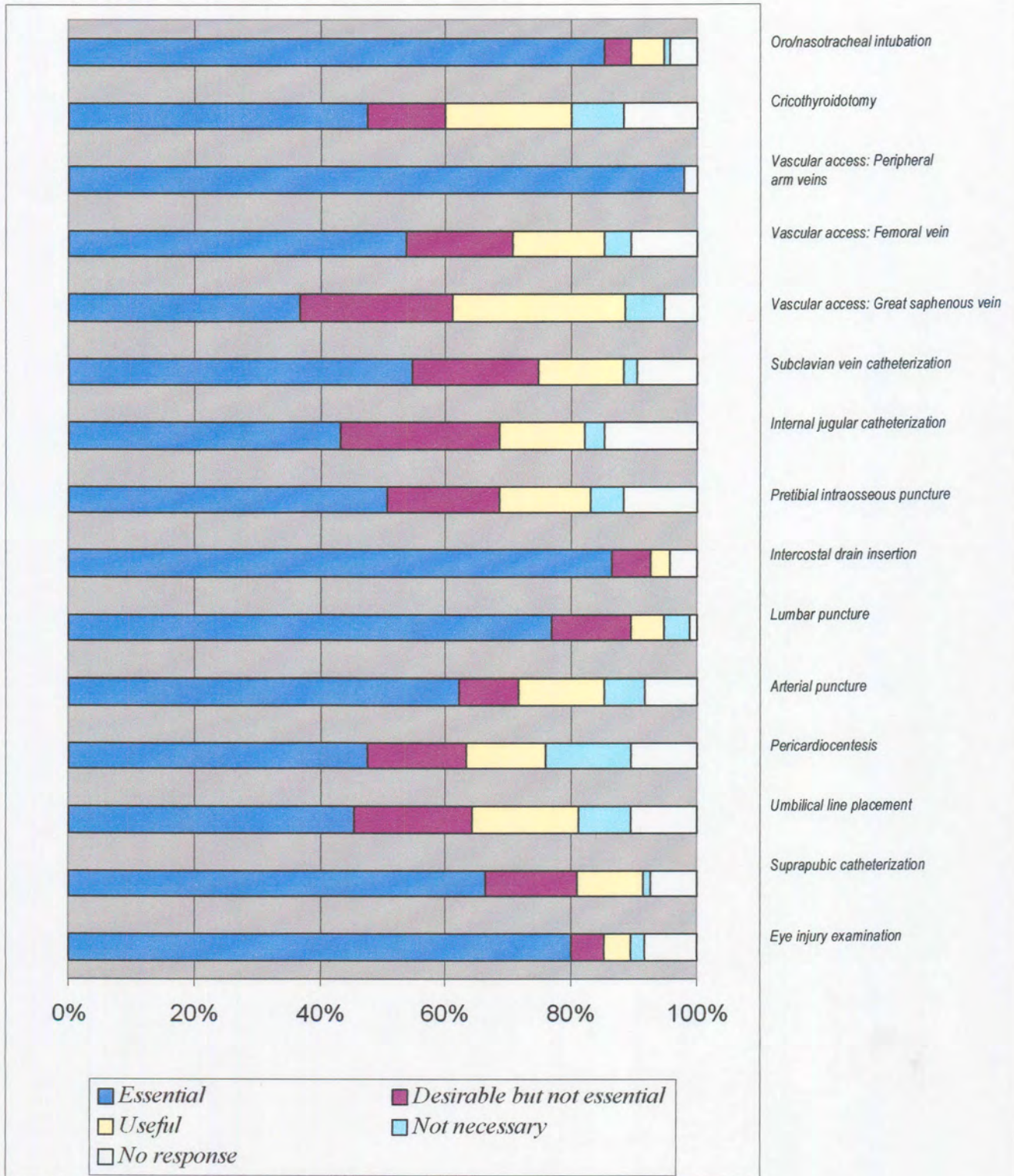


Table 8. Importance rating of emergency procedures.

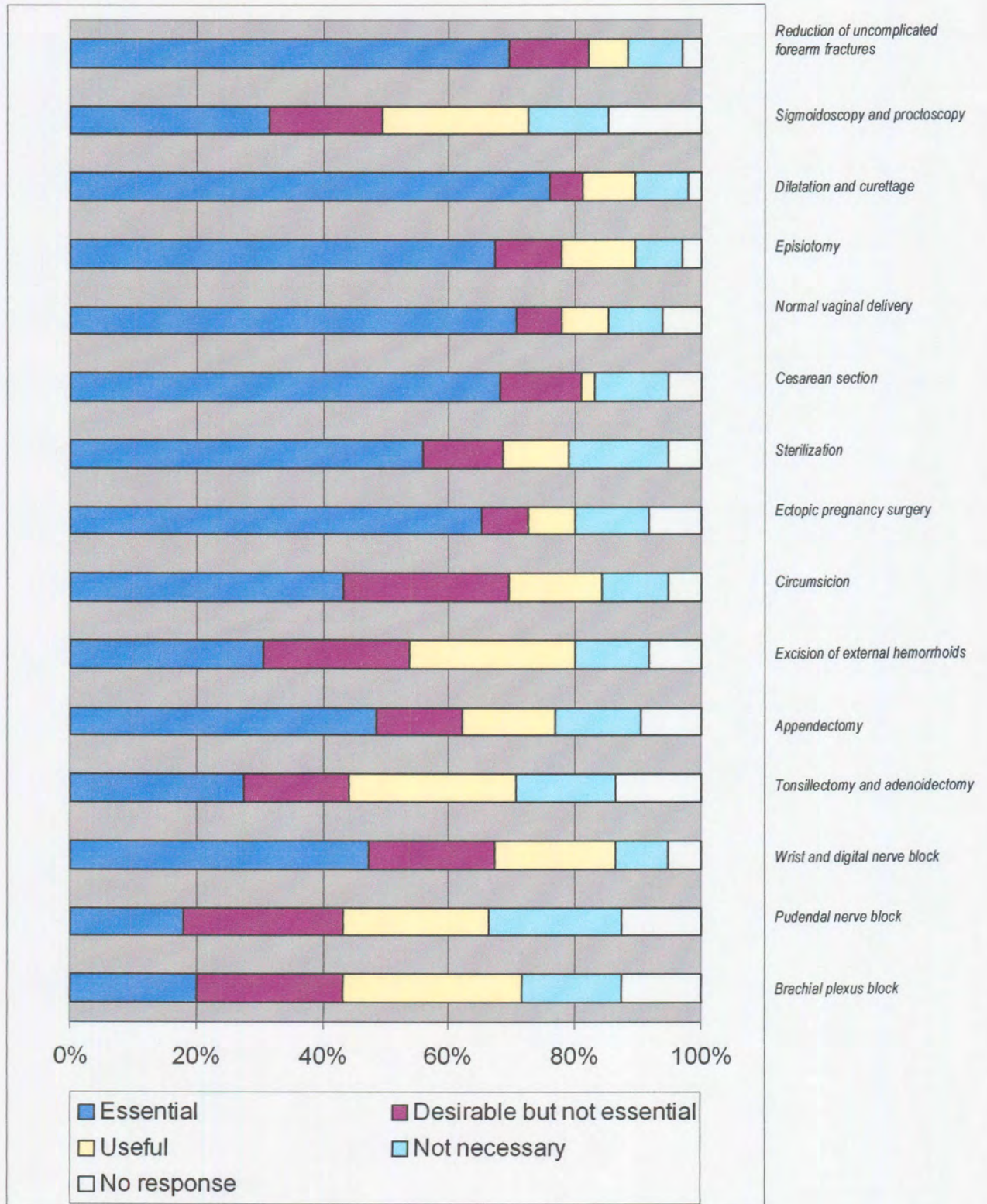


Table 9. Importance rating of surgical procedures

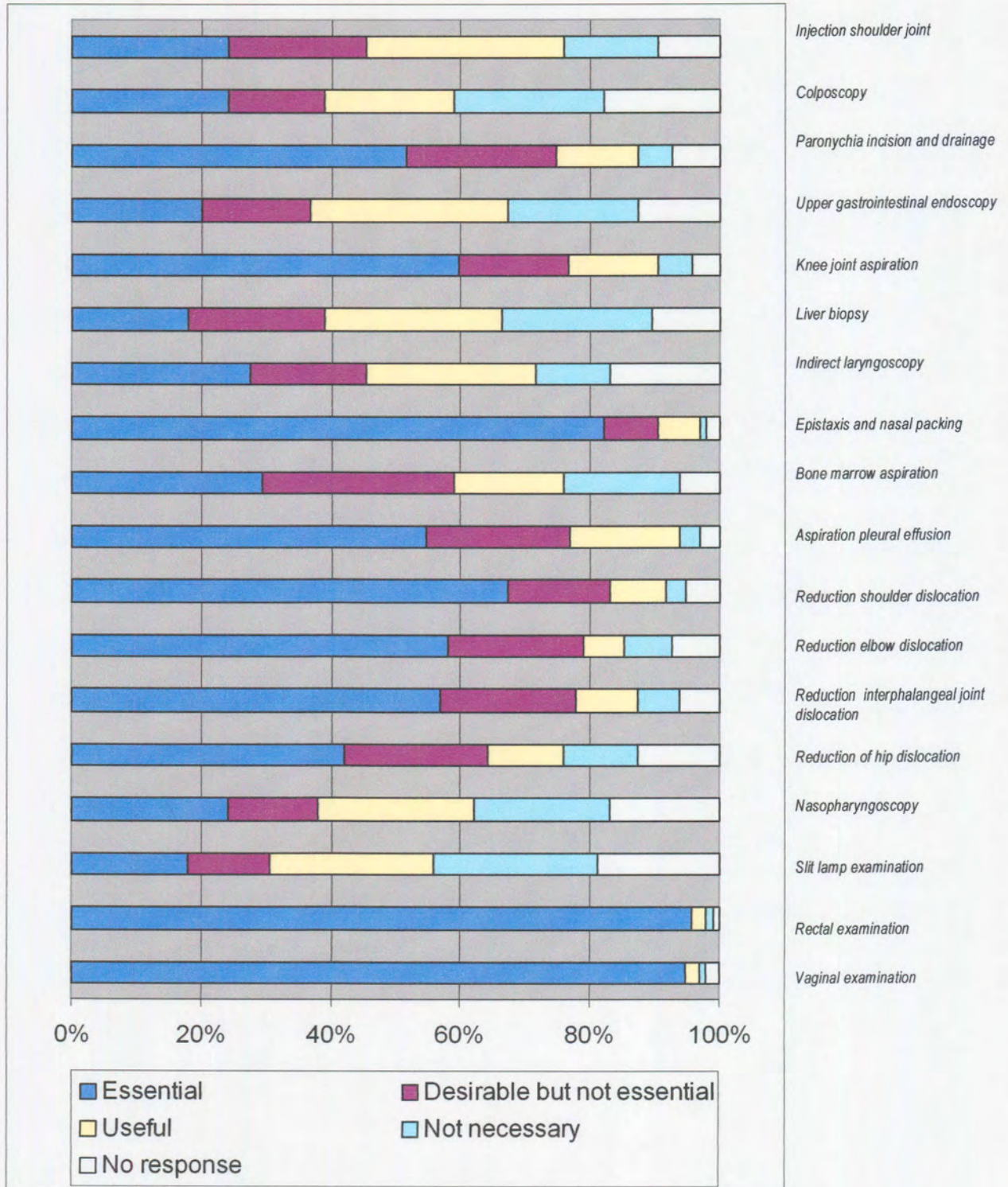


Table 10. Importance rating of office procedures

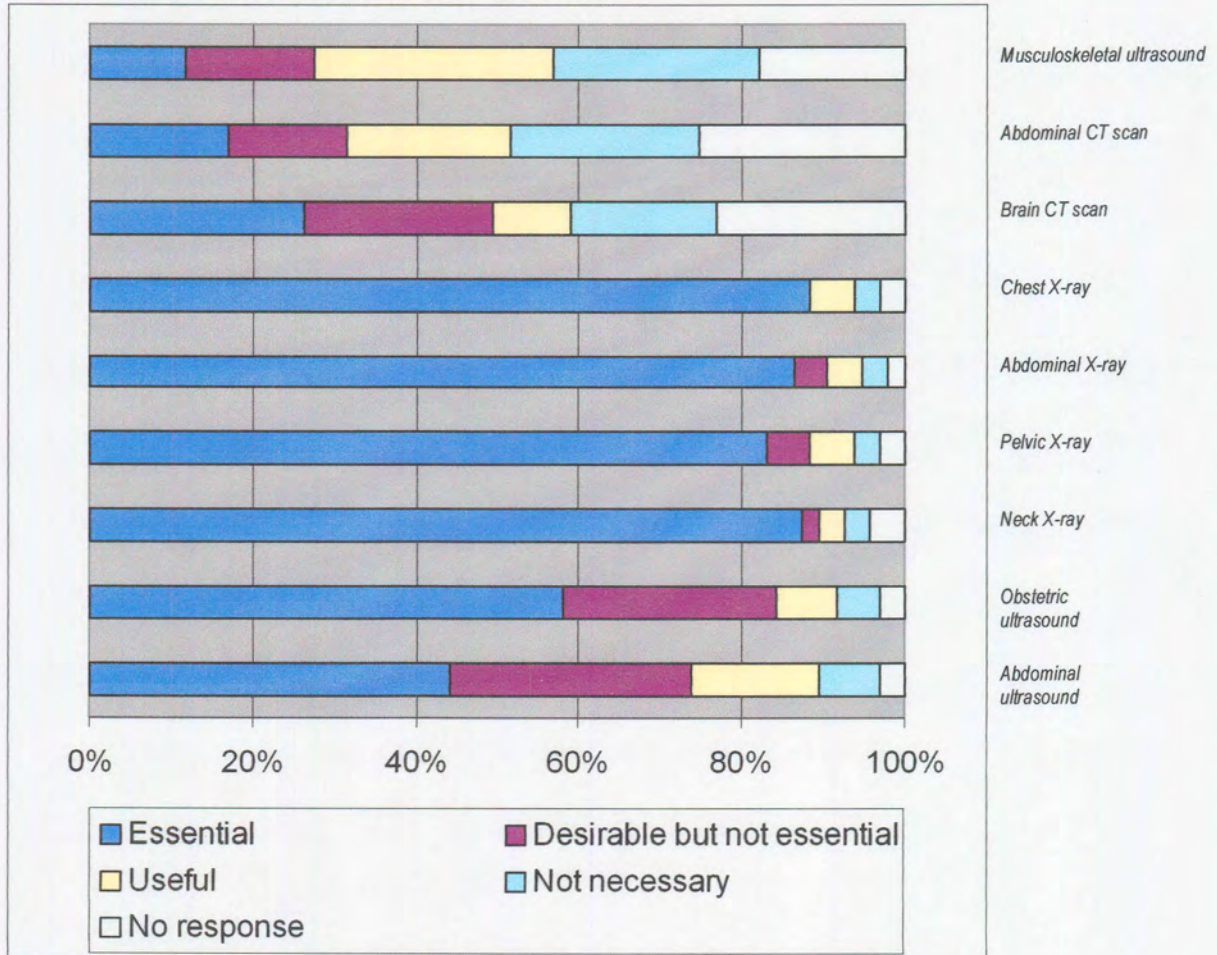


Table 11. Importance rating of imaging procedures



4.1.4 Measure of comfort rating

General practitioners rated their measure of comfort with which they perform every procedure. The results are illustrated in Table 12, 13, 14 and 15.

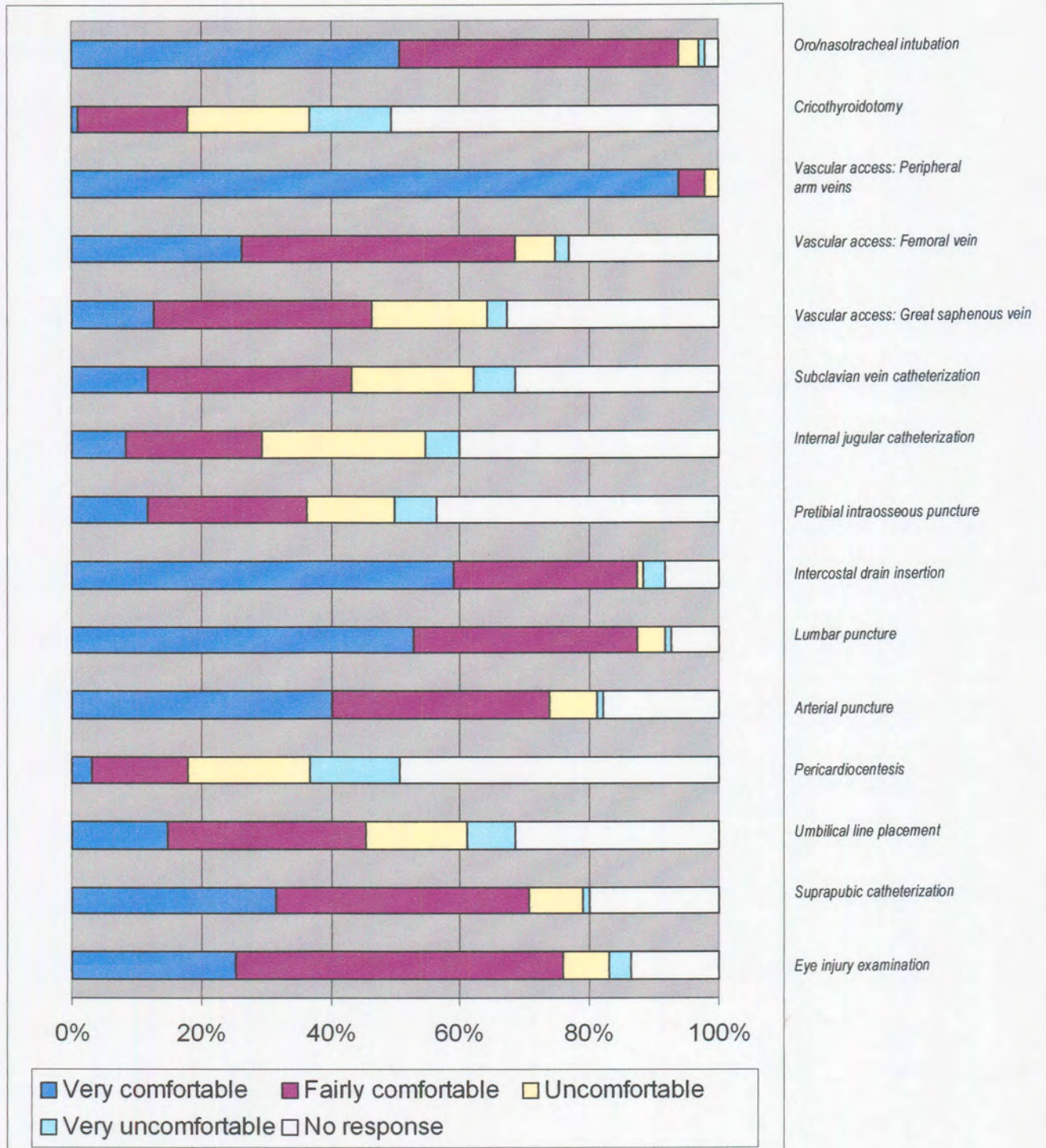


Table 12. Comfort with which emergency procedures are performed

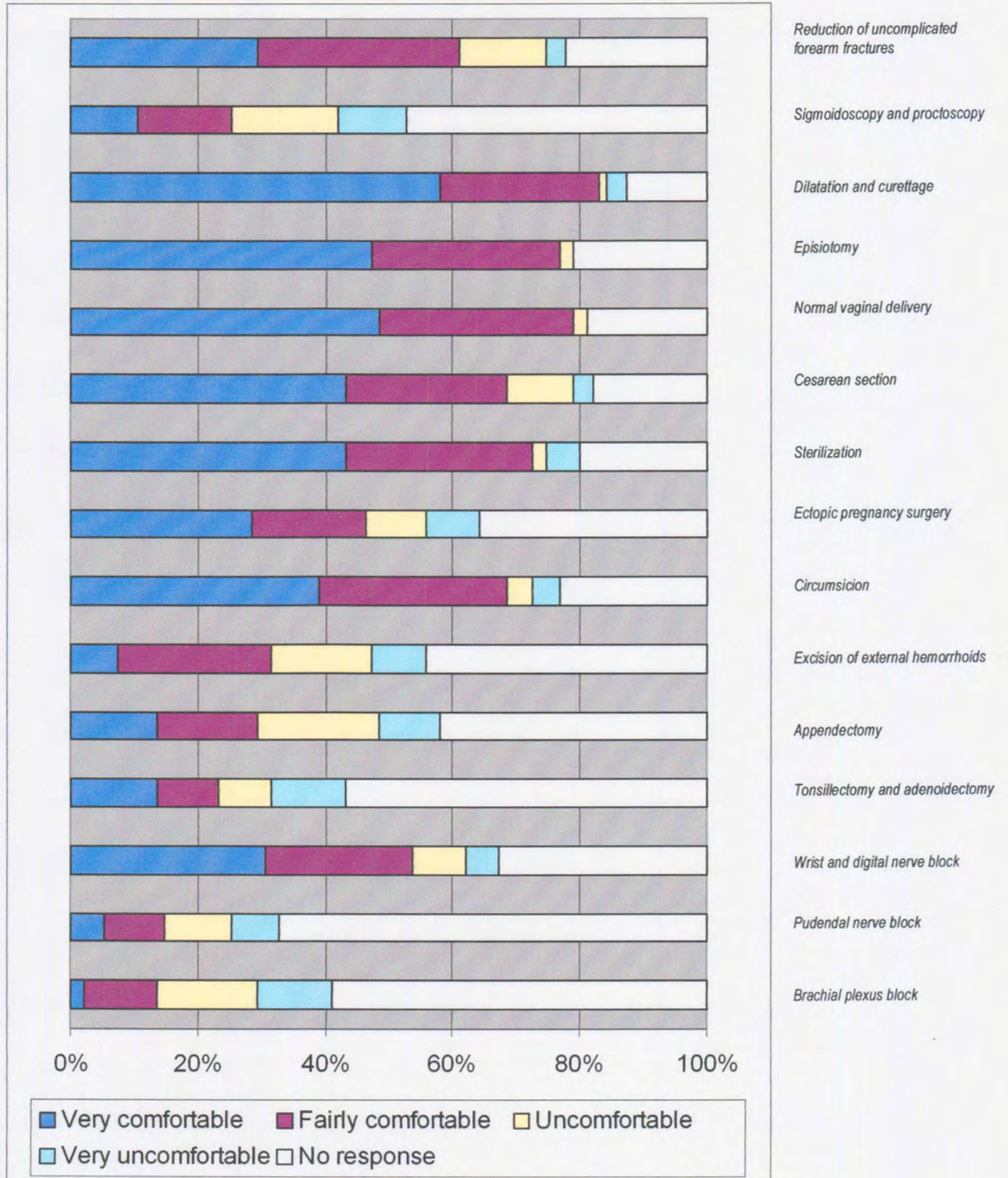


Table 13. Comfort with which surgical procedures are performed.

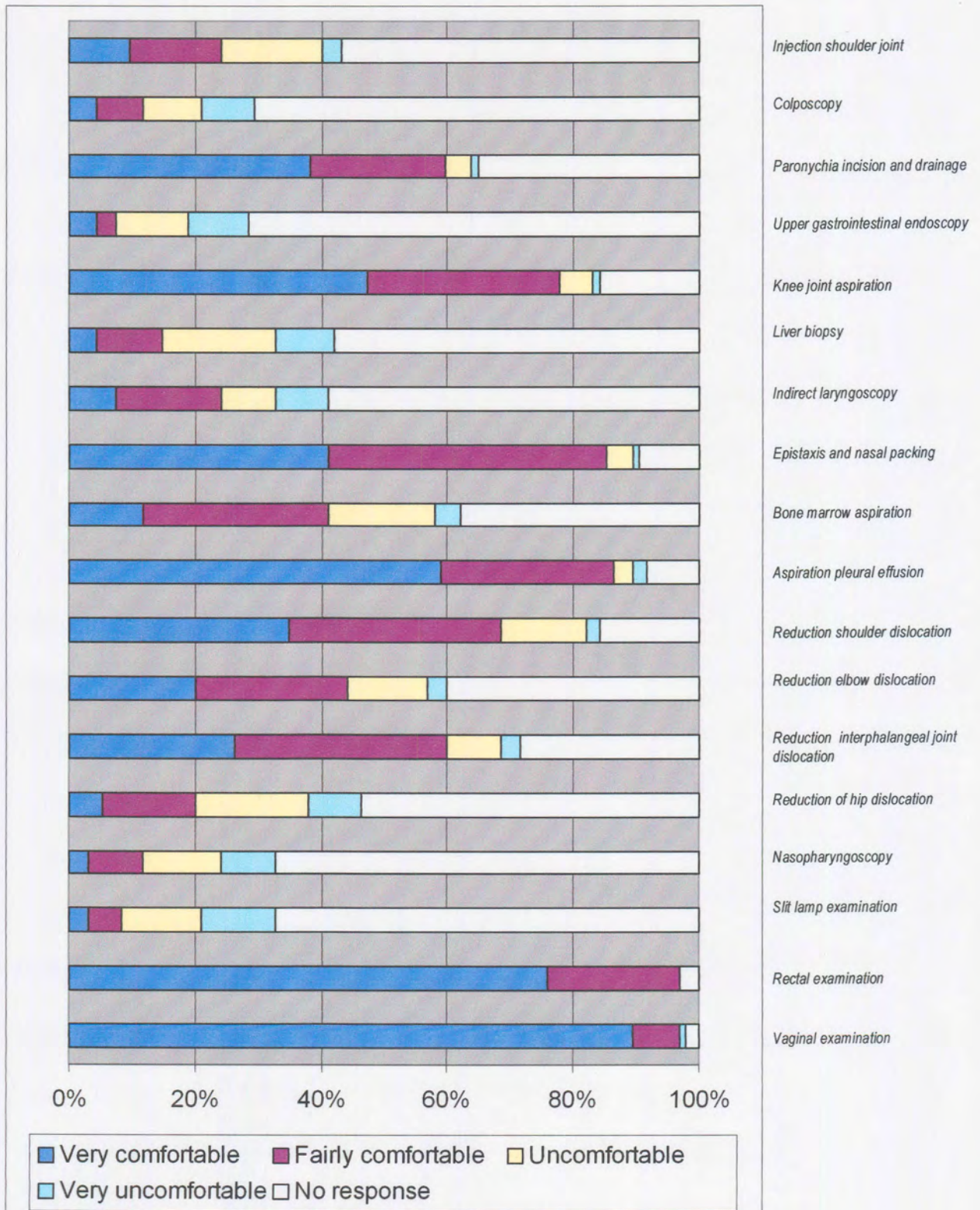


Table 14. Comfort with which office procedures are performed

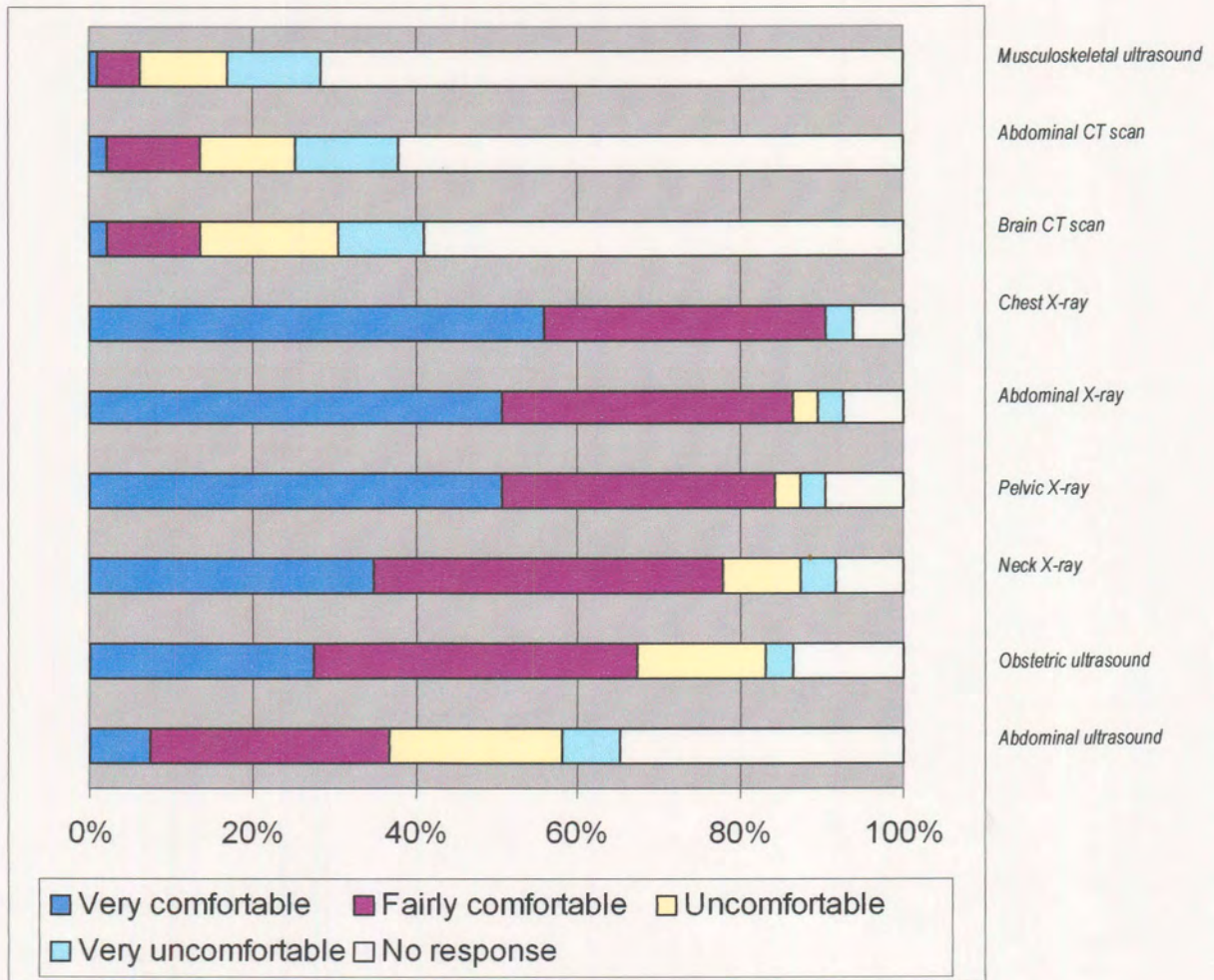


Table 15. Comfort with which imaging procedures are performed.



4.1.5 Difficulties of performance

Tables 16,17,18 and 19 illustrate the distribution of difficulties that were encountered by general practitioners in the performance of the procedures evaluated.

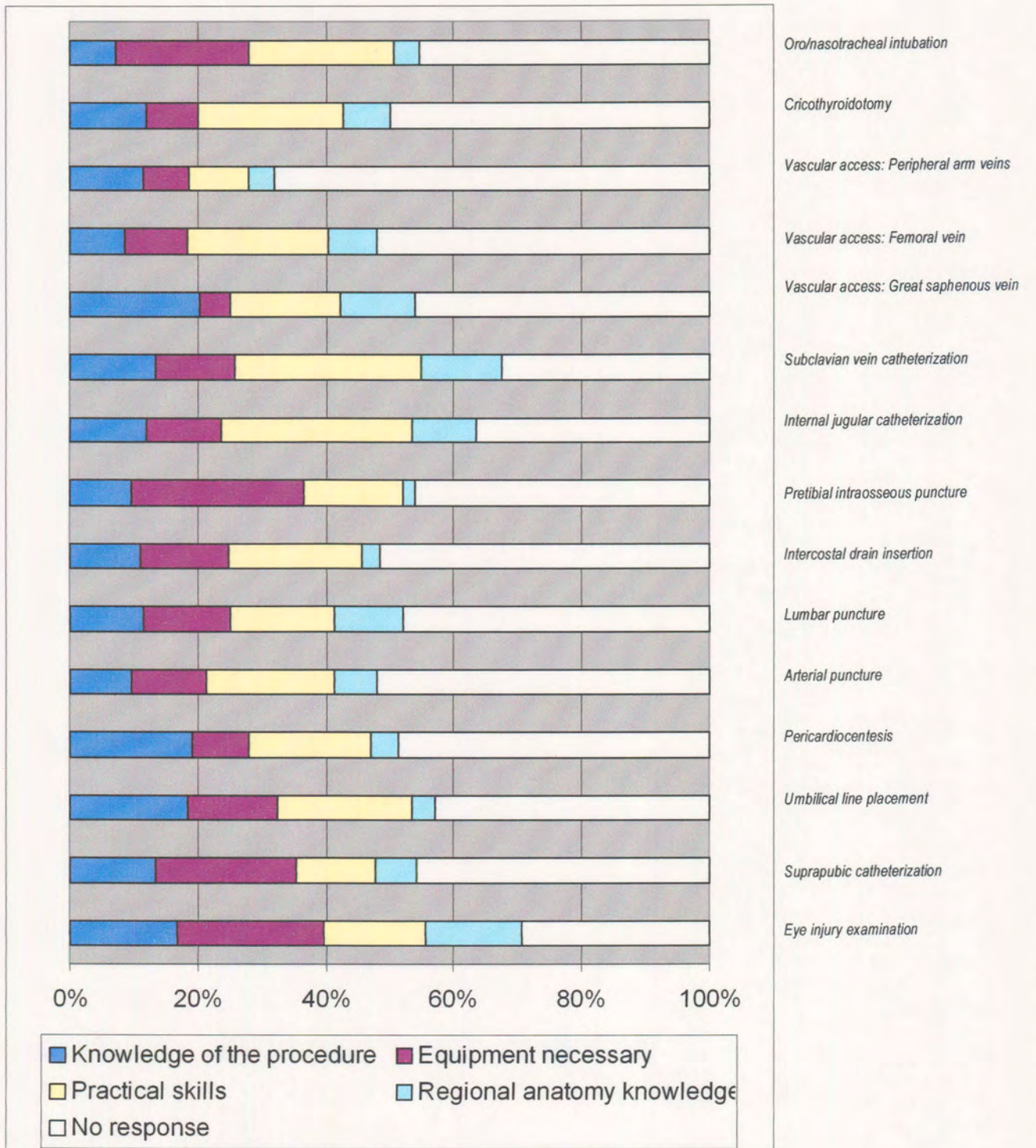


Table 16. Difficulties with emergency procedures

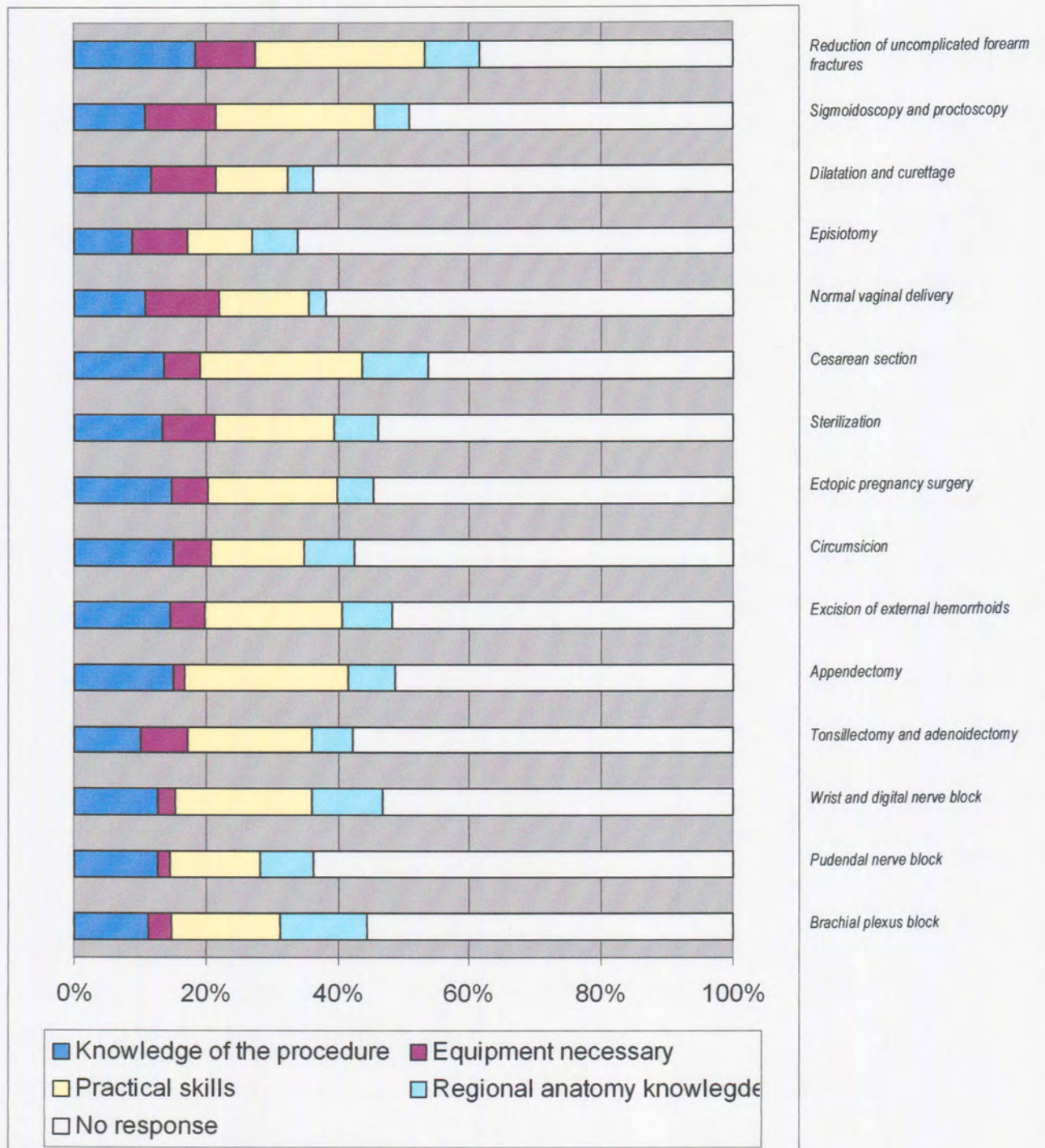


Table 17. Difficulties with surgical procedures

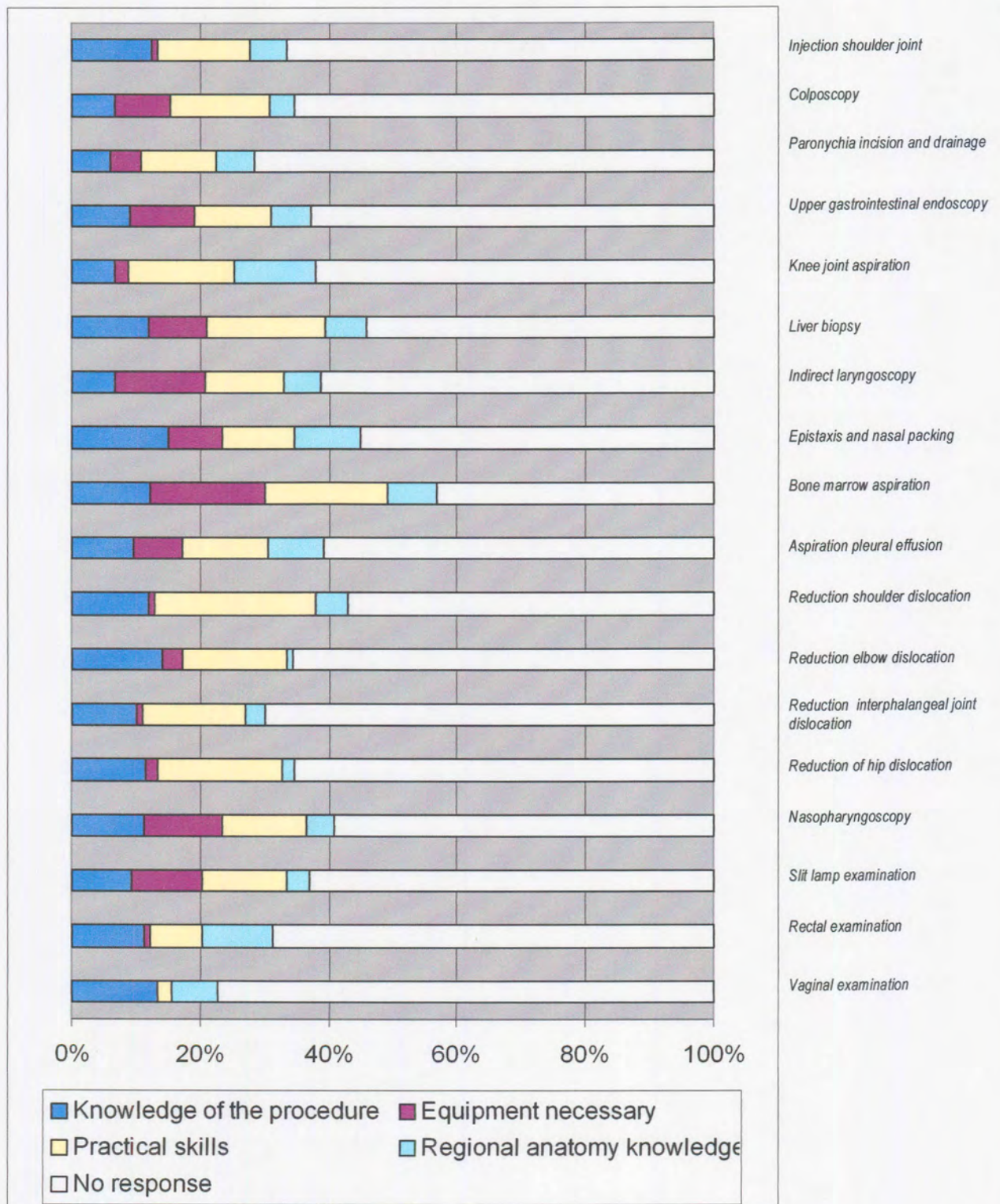


Table 18. Difficulties with office procedures

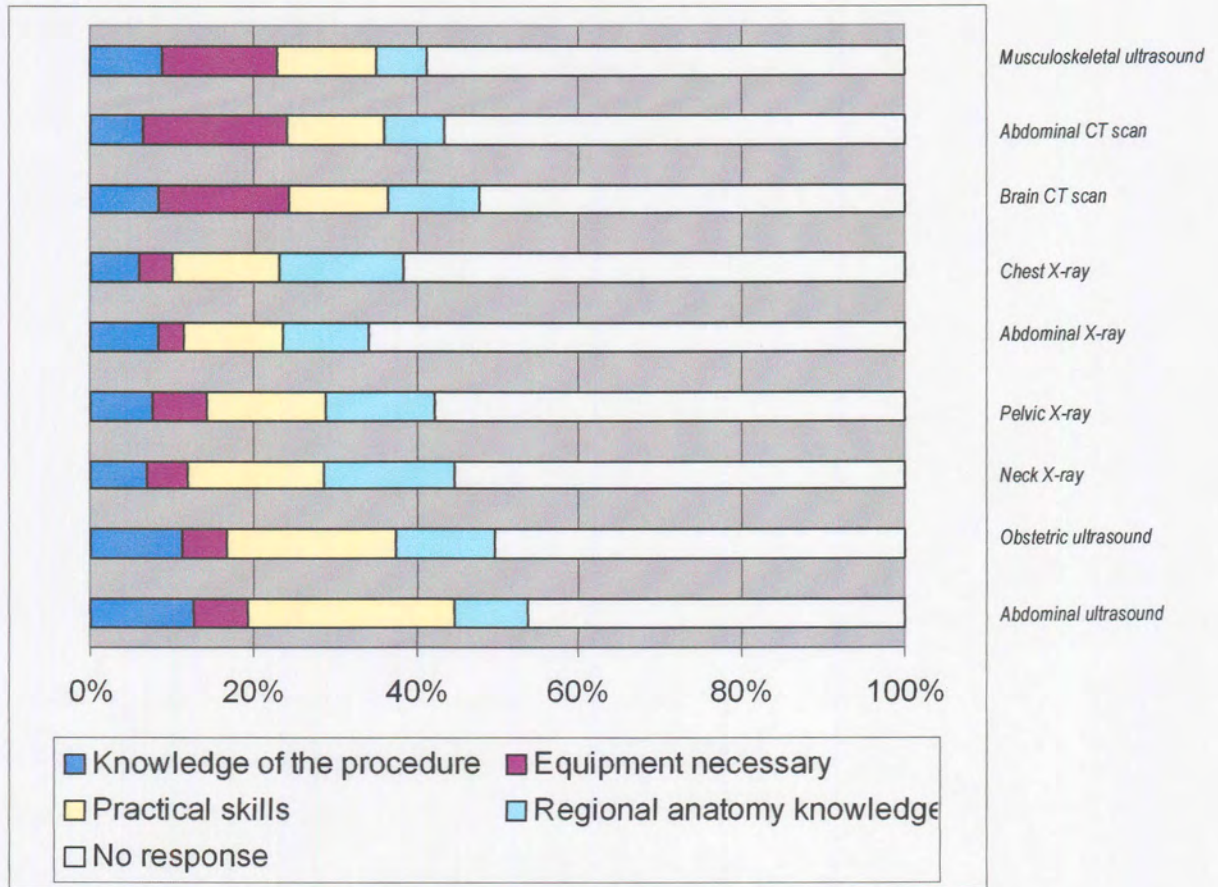


Table 19. Difficulties with imaging procedures

4.1.6 Complications

Table 20 illustrates the complications that were reported by general practitioners for all the procedures.

Table 20. Complications reported for all the procedures

<i>Procedure</i>	<i>Complication</i>	<i>%</i>	<i>Compli- cation</i>	<i>%</i>	<i>Compli- cation</i>	<i>%</i>	<i>Compli- cation</i>	<i>%</i>
<i>Oro/nasotracheal intubation</i>	Esophageal intubation	36.84	Laryngo-spasm	36.84	Not able to visualize the vocal cords	47.37		
<i>Cricothyroidotomy</i>	Unable to find entry site for needle	8.42	Vocal cord paralysis	2.10	Esophageal perforation	1.05	Thyroid perforation	1.05
<i>Vascular access: Peripheral arm veins</i>	Brachial artery puncture	10.53	Median nerve damage	1.05	Inability to locate vein	47.37		
<i>Vascular access: Femoral vein</i>	Femoral artery puncture	28.42	Femoral nerve transection and/or puncture	1.05	Inability to locate vein	33.68	Hip joint sepsis	1.05
<i>Vascular access: Great saphenous vein</i>	Inability to locate vein	32.63	Saphenous nerve damage	0	Arterial transection	2.11		
<i>Subclavian vein catheterization</i>	Inability to locate vein	45.26	Subclavian artery puncture	12.63	Hemopneumothorax	9.47	Brachial plexus puncture	0
<i>Internal jugular vein catheterization</i>	Inability to locate vein	37.89	Pneumothorax	5.26	Common carotid artery puncture	7.37	Chylothorax	1.05
<i>Pretibial intraosseous puncture/infusion</i>	Inability to find the correct site of placement	14.74	Epiphyseal plate injury	3.16	Osteomyelitis	4.21	Subcutaneous or subperiosteal infiltration	15.79
<i>Intercostal drain insertion</i>	Inability to find the correct site of placement	16.84	Bleeding from intercostal vessels	17.89	Damage to the intercostal nerves	2.11	Puncture of intrathoracic and/or abdominal organs	5.26
<i>Lumbar puncture</i>	Inability to find the correct placement of the needle	33.68	Inability to appreciate the position of the needle	15.79	Bloody tap	45.26		

<i>Procedure</i>	<i>Complication</i>	<i>%</i>	<i>Compli- cation</i>	<i>%</i>	<i>Compli- cation</i>	<i>%</i>	<i>Compli- cation</i>	<i>%</i>
<i>Arterial blood puncture for blood sampling</i>	Inability to perform a radial artery puncture	20	Inability to locate the femoral artery	6.32	Uncertain on which artery to use in pediatric patients	22.11		
<i>Pericardiocentesis</i>	Inability to find the correct site of placement	10.53	Inability to appreciate the position of the needle while placing	18.95	Injury to a coronary vessel, inferior vena cava, aorta, esophagus	2.11	Aspiration of ventricular blood	3.16
<i>Umbilical line placement</i>	Inability to find the umbilical vein	21.05						
<i>Suprapubic catheterization and puncture</i>	Unsure about the site of placement of the puncture	17.89	Intra-abdominal placement	10.53				
<i>Eye injury examination</i>	Unsure about anatomical structures	26.32	Inability to visualize the retina and optic disc	37.89	Unsure of innervation of the eye musculature	11.58		
<i>Reduction of uncomplicated forearm fractures</i>	Unsure about correct rotation	38.95						
<i>Sigmoidoscopy and proctoscopy</i>	Unsure of the anatomy of the bowel mucosa	7.37	Unsure about the differences between sigmoid colon, rectum and anus	10.53	Bowel perforation	3.16		
<i>Dilatation and curettage</i>	Unsure about the extent of the uterus in a non pregnant women	15.79	Uterus perforation	18.95				
<i>Episiotomy</i>	Unsure about site of incision	6.32	Unsure about perineal layers when suturing	16.84				
<i>Normal vaginal delivery</i>	Second or third degree tear	28.42	Unsure about determining the position of the fetal head	13.68	Unsure about anatomical landmarks during vaginal examination	9.47		



<i>Procedure</i>	<i>Complication</i>	<i>%</i>	<i>Complication</i>	<i>%</i>	<i>Complication</i>	<i>%</i>	<i>Complication</i>	<i>%</i>
<i>Cesarian section</i>	Unsure about anatomy of the abdominal wall when suturing	7.37	Difficulty to determine the site of uterine incision	9.47	Damage to the ureter	4.21	Difficulty to perform a Pfannenstiel incision	27.37
<i>Sterilization</i>	Bleeding	13.68	Difficulty to locate the uterine tubes	36.84				
<i>Ectopic pregnancy surgery</i>	Bleeding	29.47	Unsure about the anatomy of the abdominal wall when suturing	2.11				
<i>Circumcision</i>	Bleeding	33.68	Difficulty to find the site for incision	5.26				
<i>Excision of external thrombosed hemorrhoids, Injection or ligation of internal hemorrhoids</i>	Difficulty to find and distinguish between hemorrhoids	7.37	Unsure about possible site of incision	17.89				
<i>Appendectomy</i>	Unsure of site of incision	7.37	Bleeding	5.26	Unable to locate appendix	23.16	Damage to cutaneous nerves	3.16
<i>Tonsillectomy and adenoidectomy</i>	Bleeding	27.37	Unable to remove tonsil in fascial plane	8.42	Nerve damage	0	Unsure about the location of the adenoids	3.16
<i>Wrist block and digital nerve block</i>	Unable to locate nerves in relation to the wrist	15.79	Unable to locate nerves in relation to the digits	14.74				
<i>Pudendal nerve block</i>	Unsure about anatomical landmarks to find the nerve	20						
<i>Brachial plexus block</i>	Pneumothorax	3.16	Phrenic nerve paralysis	3.16	Unsure about site of entrance and direction of the needle	16.84		



<i>Procedure</i>	<i>Complication</i>	<i>%</i>	<i>Complication</i>	<i>%</i>	<i>Complication</i>	<i>%</i>	<i>Complication</i>	<i>%</i>
<i>Injection of shoulder joint</i>	Unsure of site of entrance and direction of needle	20						
<i>Colposcopy</i>	Unsure about anatomical landmarks	9.47						
<i>Paronychia incision and drainage</i>	Unsure about site of incision	18.95	Unable to locate root of the nail	5.26				
<i>Upper gastrointestinal endoscopy</i>	Unsure about anatomical landmarks of the mucosal anatomy	8.42						
<i>Knee joint aspiration</i>	Unable to locate the site of entry	13.68	Damage to cutaneous nerves of the knee joint	2.11	Damage to the articular cartilage	9.47		
<i>Liver biopsy</i>	Unsure about site of entrance	15.79	Bleeding	8.42	Pneumo-thorax	0	Pneumo-peritoneum	0
<i>Indirect laryngoscopy</i>	Unsure about anatomical landmarks in the larynx	10.53						
<i>Epistaxis and nasal packing</i>	Unable to control bleeding	47.37						
<i>Bone marrow aspiration</i>	Unsure about site of entry	20						
<i>Aspiration of pleural effusion</i>	Unsure about site of needle entrance	14.74						
<i>Reduction of shoulder dislocation</i>	Unsure about technique and its rationale	21.05	Brachial plexus injury	7.37				
<i>Reduction of elbow dislocation</i>	Brachial artery injury	2.11	Median nerve injury	2.11	Unsure about the technique and its rationale	16.84		
<i>Reduction of interphalangeal joint dislocation</i>	Collateral ligament injury	8.42	Unsure about technique and its rationale	10.53				

<i>Procedure</i>	<i>Complication</i>	<i>%</i>	<i>Complication</i>	<i>%</i>	<i>Complication</i>	<i>%</i>	<i>Complication</i>	<i>%</i>
<i>Reduction of hip dislocation</i>	Unsure about technique and its rationale	17.89						
<i>Nasopharyngoscopy</i>	Unsure about the anatomy of the nasopharynx	12.63						
<i>Slit lamp examination</i>	Unsure about anatomy of structures in the eye	13.68						
<i>Rectal examination</i>	Unable to locate the prostate gland	9.47	Unable to locate the seminal vesicles	30.53	Unable to locate the cervix and uterus in a female patient	5.26		
<i>Vaginal examination</i>	Unable to locate the bladder	7.37	Unable to locate the adnexae	5.26	Unable to locate the recto-uterine pouch	6.32	Unable to appreciate the position of the ureters	21.05
<i>Musculoskeletal ultrasound</i>	Unable to locate anatomical structures	12.63						
<i>Abdominal CT scan</i>	Unable to locate abdominal structures	13.68						
<i>Brain CT scan</i>	Unable to locate brain structures	13.68						
<i>Chest X-Ray</i>	Unable to locate the borders the heart	3.16	Unable to count the ribs on the X-ray	4.21	Unable to visualize pulmonary vasculature	18.95		
<i>Abdominal X-Ray</i>	Unable to differentiate small bowel from large bowel	10.53	Unable to visualize soft tissue	7.37	Unable to visualize the psoas line	22.11		
<i>Pelvic X-Ray</i>	Unable to locate bony landmarks	11.58	Unable to evaluate the pelvic brim	7.37				
<i>Neck X-Ray</i>	Unsure about assessment of soft tissue spaces	21.05	Unsure about assessment of bony landmarks	18.95	Unsure about assessment of cartilage	21.05		



<i>Procedure</i>	<i>Complication</i>	<i>%</i>	<i>Complication</i>	<i>%</i>	<i>Complication</i>	<i>%</i>	<i>Complication</i>	<i>%</i>
<i>Obstetric ultrasound</i>	Unable to locate anatomical structures	34.74	Unable to do standard obstetric measurements	16.84				
<i>Abdominal ultrasound</i>	Unable to locate anatomical structures	34.74						

4.1.7 The role of clinical anatomy in reducing difficulties and complications

The following statement was evaluated for every procedure by the general practitioners: “The improvement of critical anatomy knowledge necessary to perform this procedure will reduce difficulties and complications”.

Tables 21-24 illustrate how this statement was rated, regarding emergency procedures (Table 21), surgical procedures (Table 22), office procedures (Table 23) and imaging procedures (Table 24).

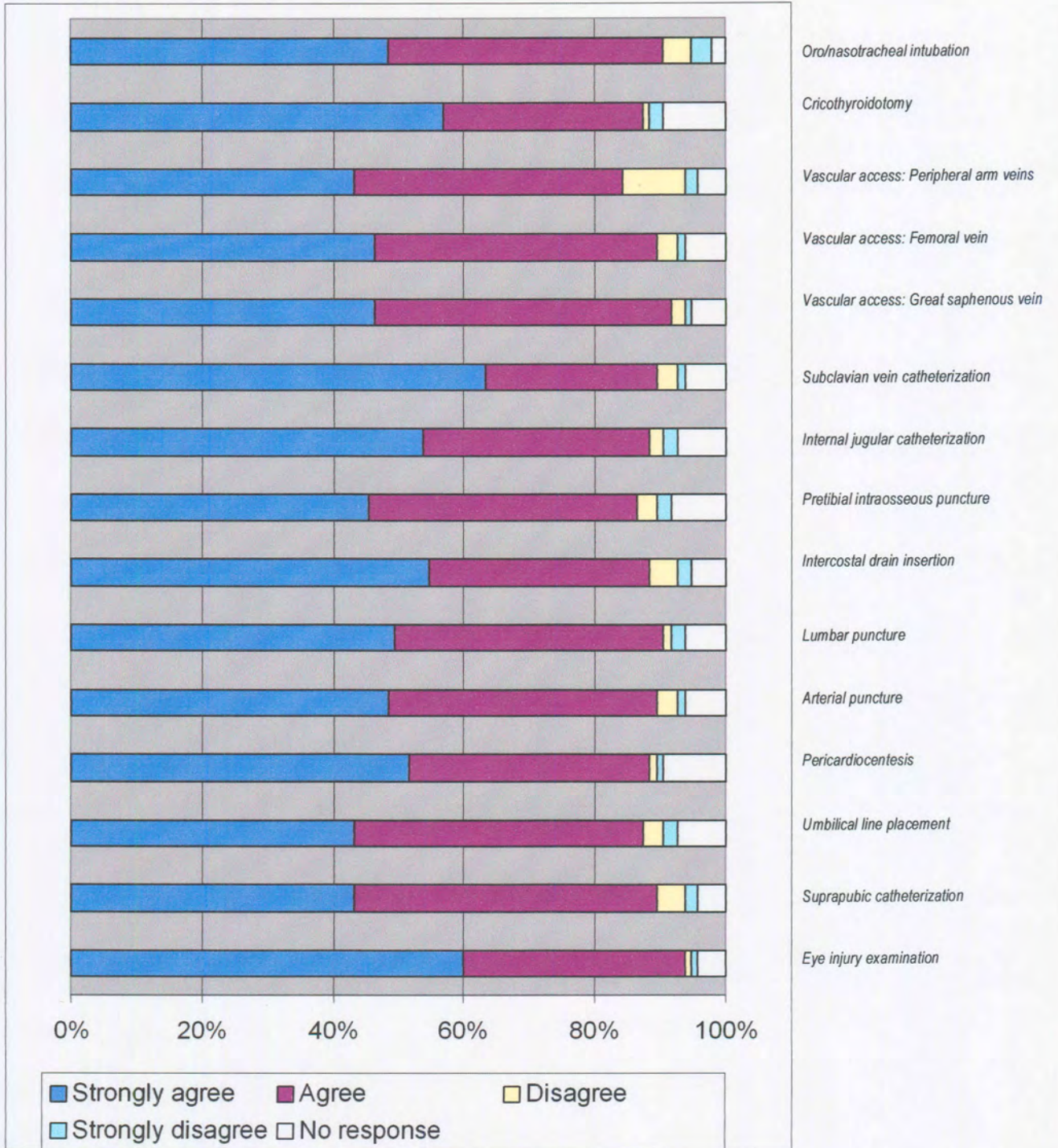


Table 21. Evaluation of statement: “The improvement of critical anatomy knowledge necessary to perform this procedure will reduce difficulties and complications” for emergency procedures.

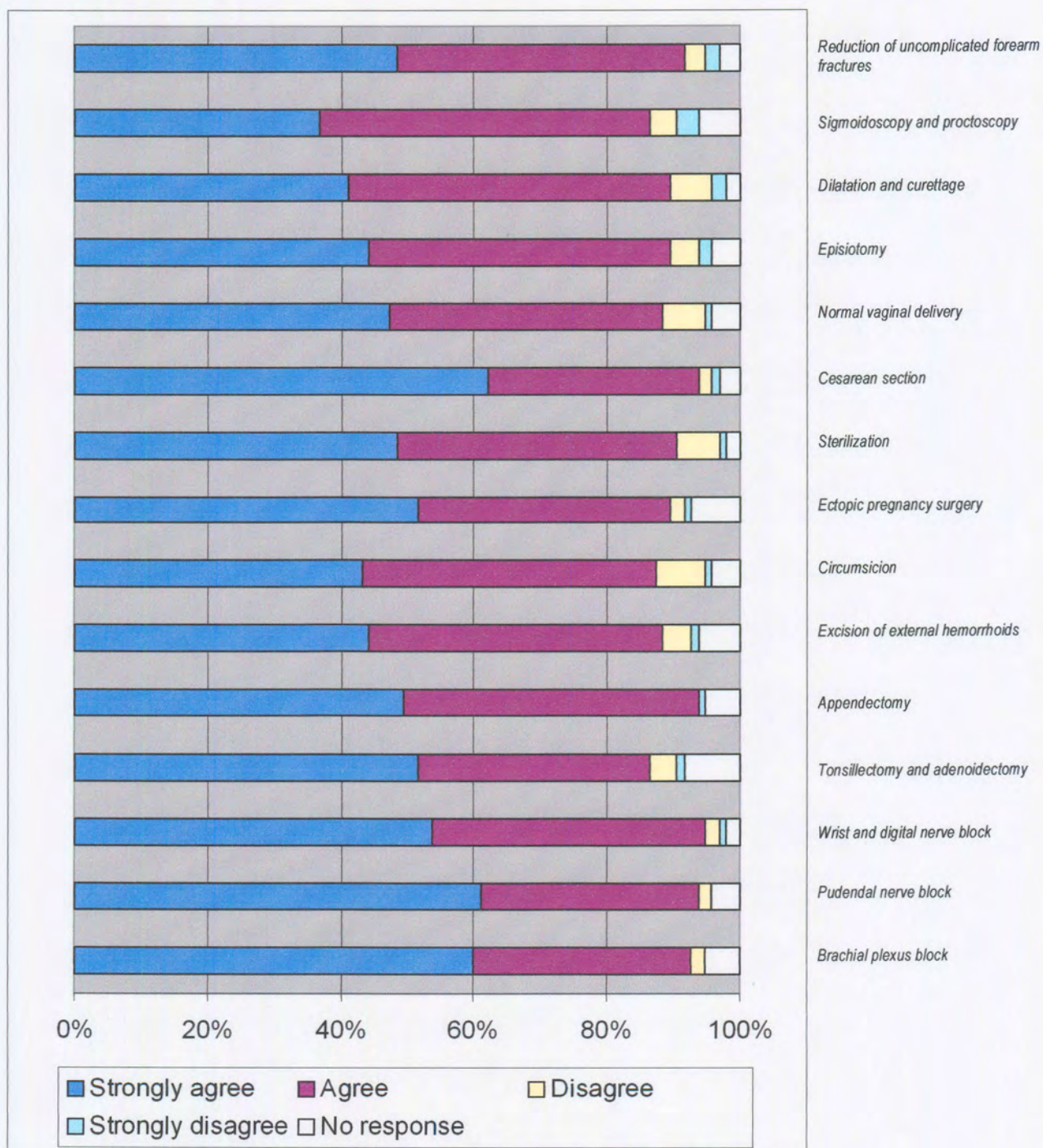


Table 22. Evaluation of statement: “The improvement of critical anatomy knowledge necessary to perform this procedure will reduce difficulties and complications” for surgical procedures.

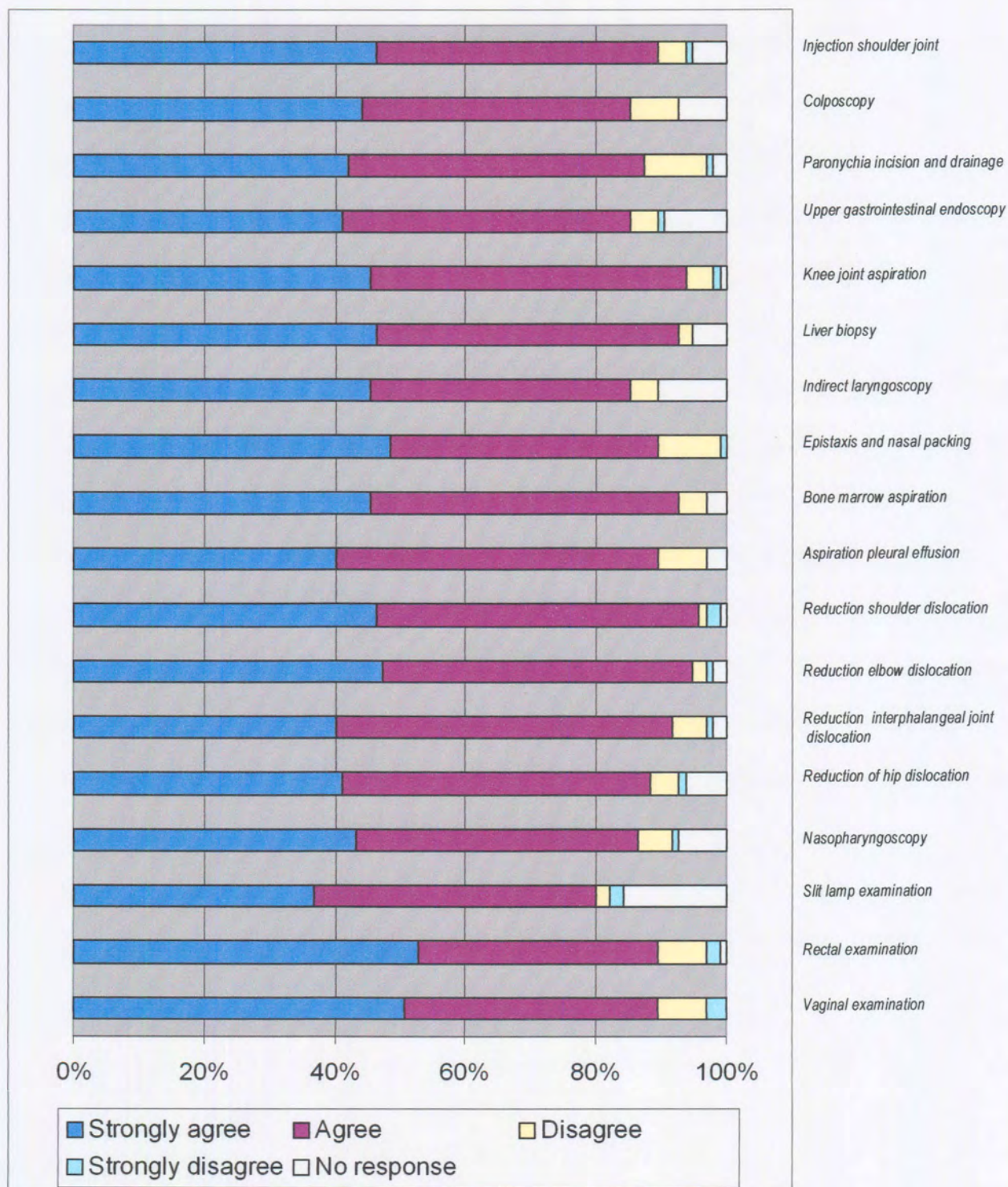


Table 23. Evaluation of statement: “The improvement of critical anatomy knowledge necessary to perform this procedure will reduce difficulties and complications” for office procedures.

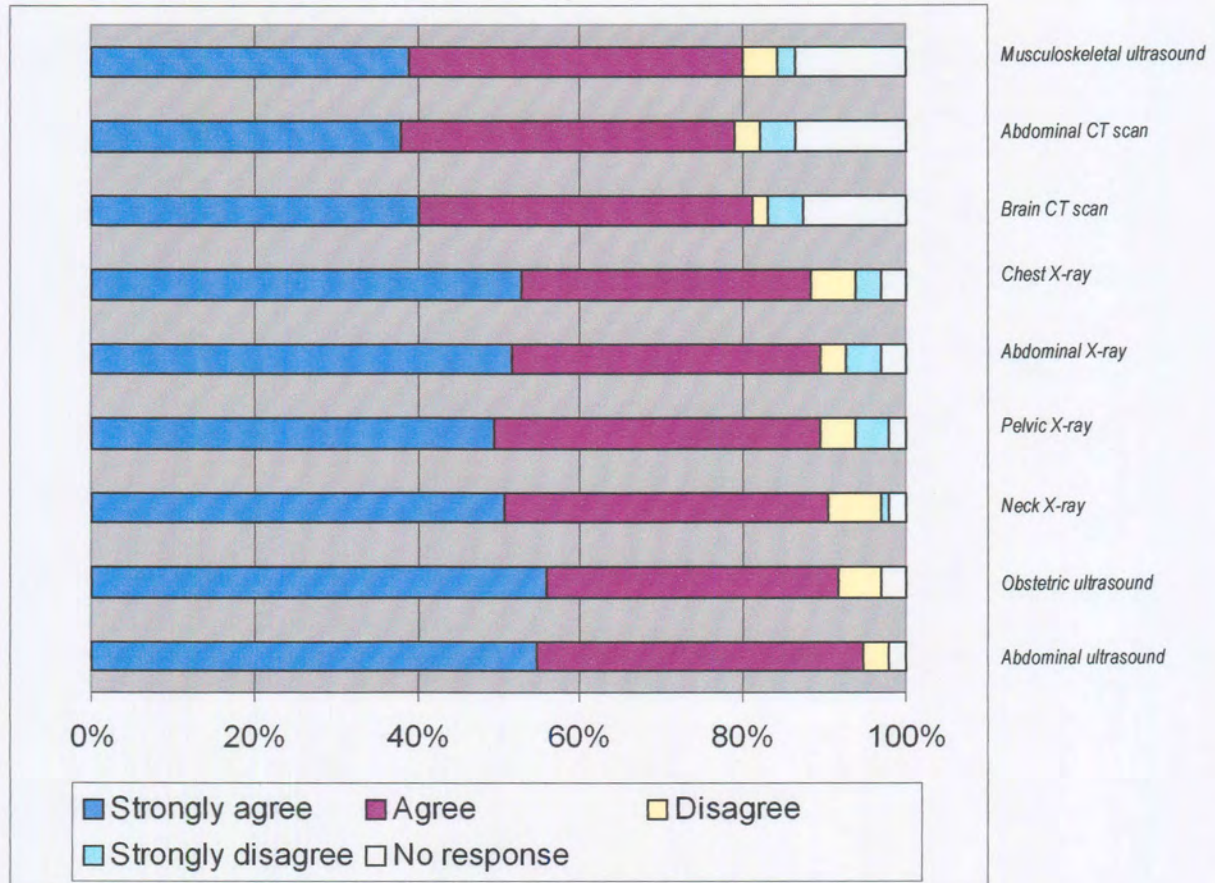


Table 24. Evaluation of statement: “The improvement of critical anatomy knowledge necessary to perform this procedure will reduce difficulties and complications” for imaging procedures.

4.1.8 The role of clinical anatomy to increase the confidence of general practitioners in performing procedures.

The following statement was evaluated for every procedure: “Improvement of anatomy knowledge necessary for the procedure will increase my confidence in performing the procedure”.

Tables 25-28 illustrate how this statement was rated, regarding emergency procedures (Table 25), surgical procedures (Table 26), office procedures (Table 27) and imaging procedures (Table 28).

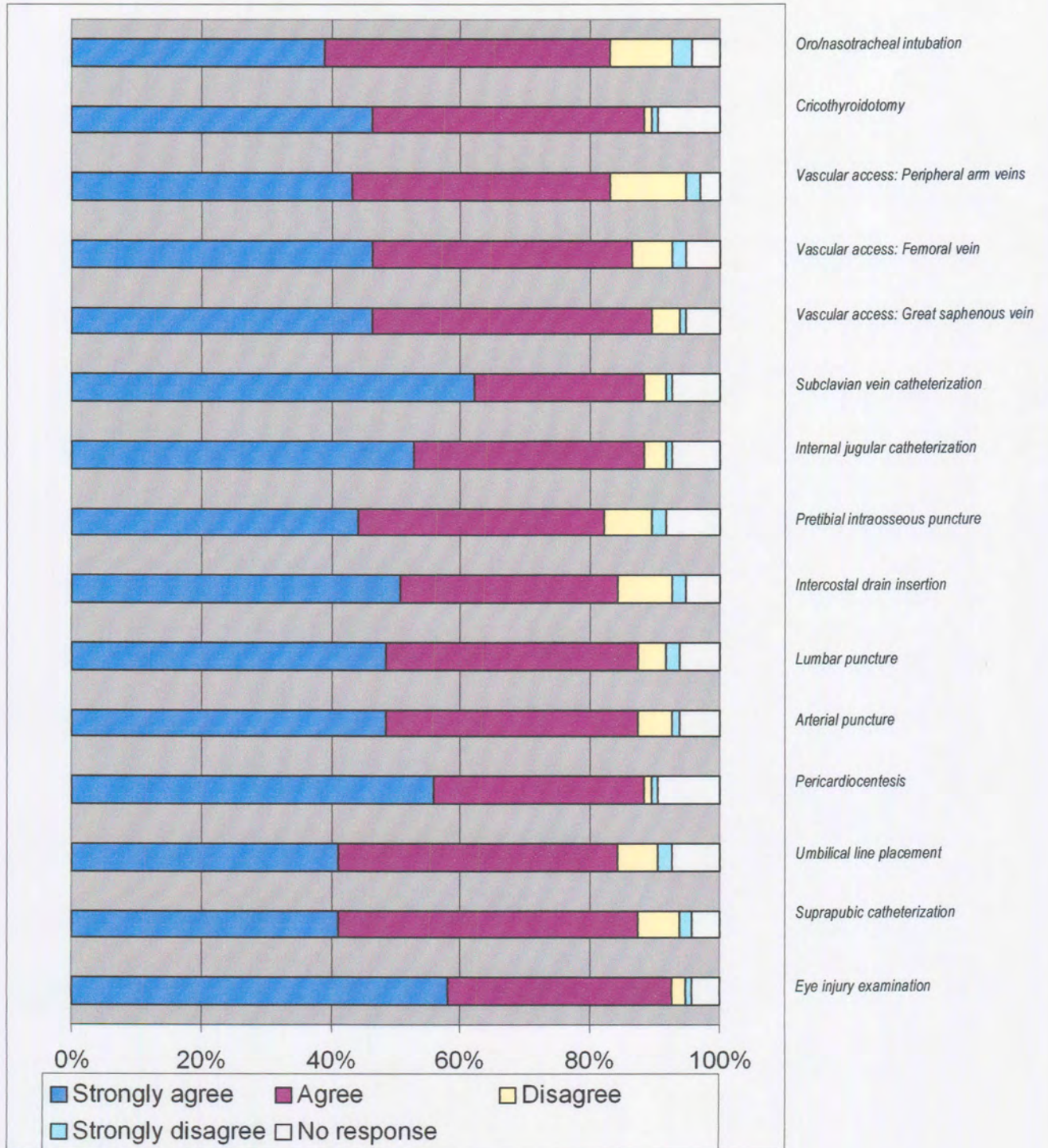


Table 25. Evaluation of statement: “Improvement of anatomy knowledge necessary for the procedure will increase my confidence in performing the procedure” for emergency procedures.

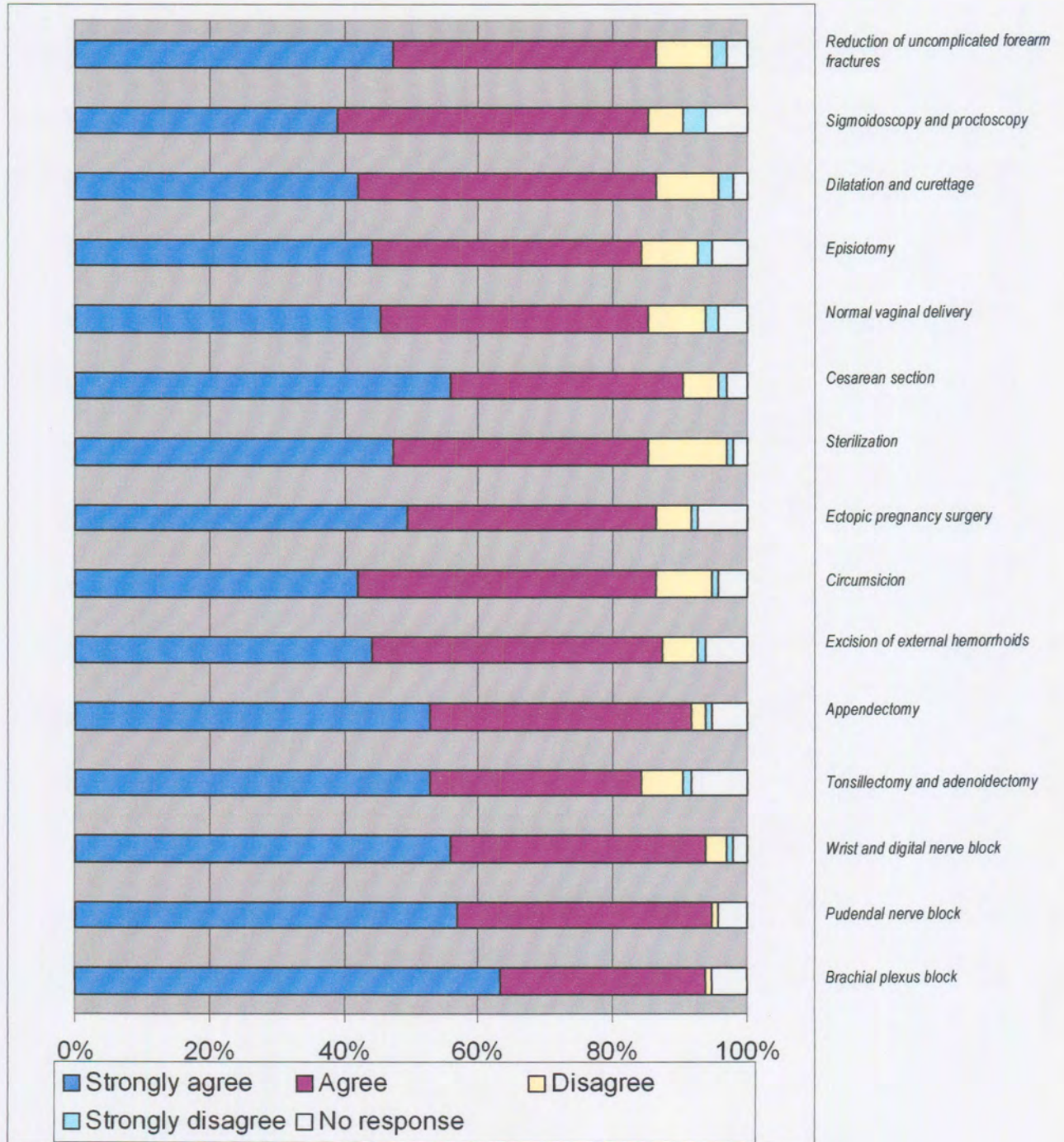


Table 26. Evaluation of statement: "Improvement of anatomy knowledge necessary for the procedure will increase my confidence in performing the procedure" for surgical procedures.

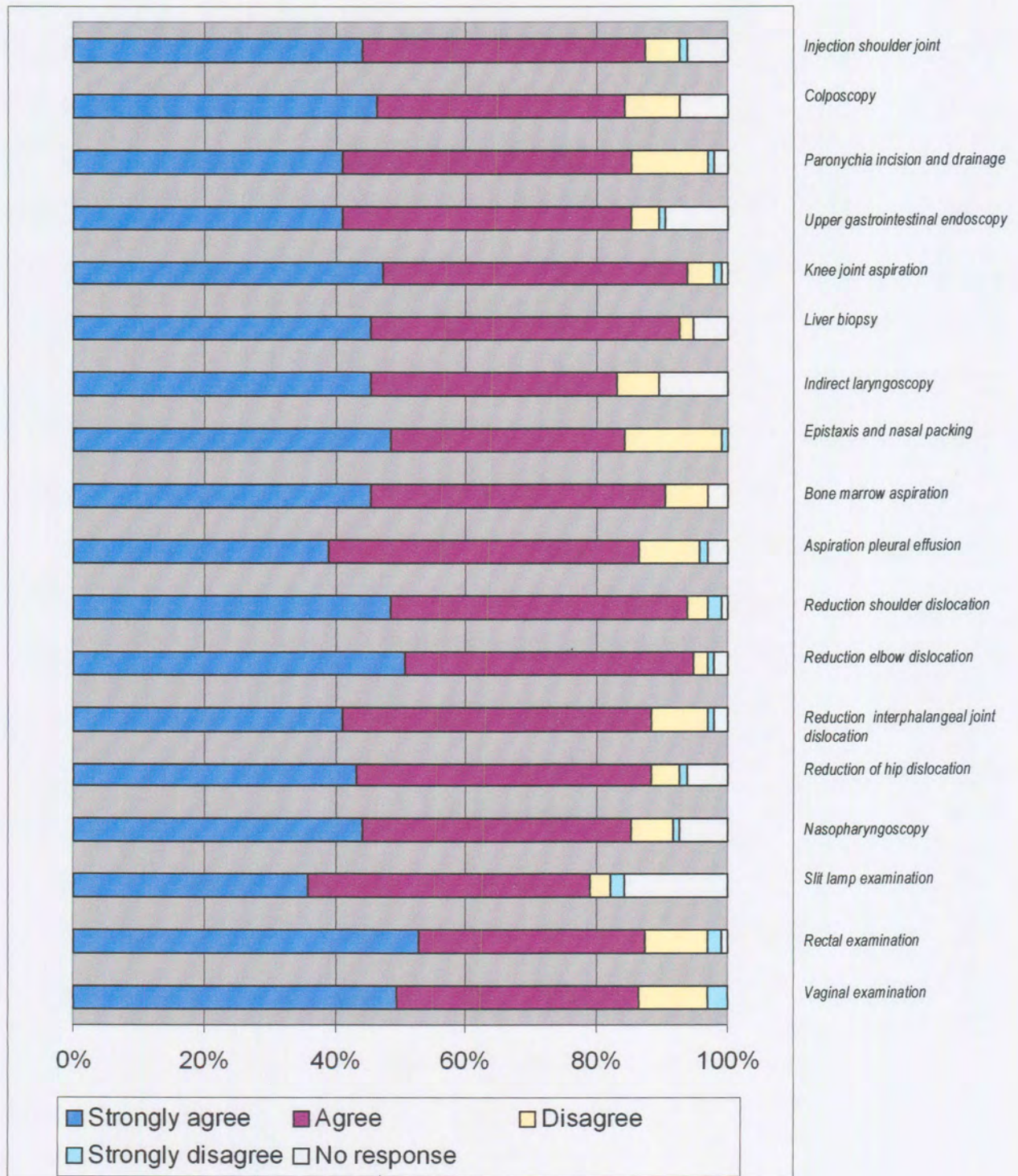


Table 27. Evaluation of statement: “Improvement of anatomy knowledge necessary for the procedure will increase my confidence in performing the procedure” for office procedures.

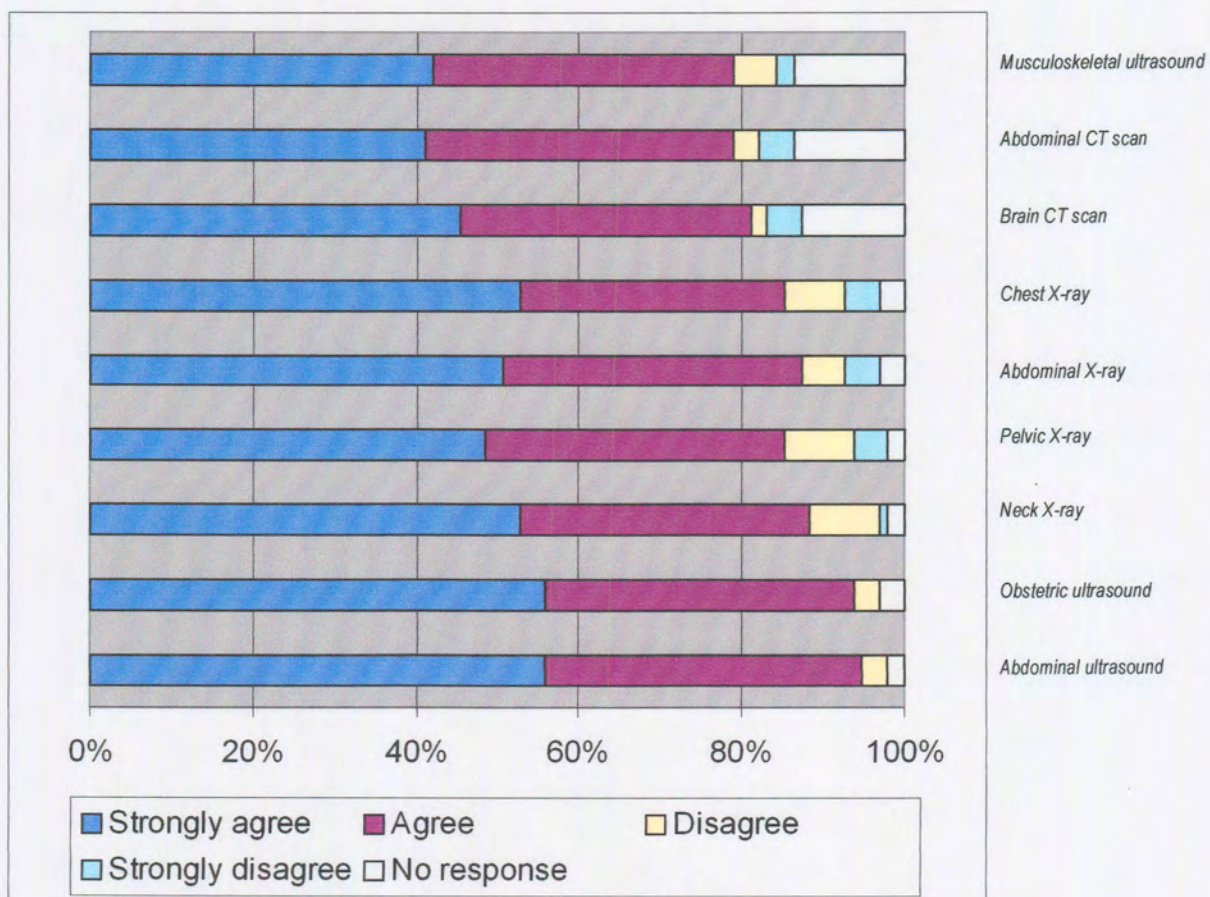


Table 28. Evaluation of statement: “Improvement of anatomy knowledge necessary for the procedure will increase my confidence in performing the procedure” for imaging procedures.

4.2 Selection of problem procedures and criteria for selection

Scoring option C was chosen to resemble best the following aspects that were regarded as the focus of our study:

- The procedure is performed by at least 50% of the general practitioners.
- The procedure is regarded as essential by at least 60% of the general practitioners.
- More doctors are uncomfortable with the procedure than comfortable.
- Difficulties and complications that are anatomically related were met.
- The assessment of the influence of clinical anatomy knowledge relevant to the procedure was to reduce difficulties and complications and increase confidence of performance.

Scoring system for scoring option C

1. Incidence of performance (>50%)	1 point
2. Essentiality (>60%)	1 point
3. Comfortability (more are uncomfortable than comfortable)	1 point
4. Difficulty or complication related to anatomy experienced by more than 25% of doctors	1 point
5. More than 80% thought that improvement of critical anatomy knowledge necessary to perform the procedure will reduce difficulties and complications.	1 point
6. More than 80% thought that improvement of anatomy knowledge necessary for the procedure will increase confidence in performing the procedure.	1 point
Total:	6 points

Procedures that scored highest in every section (emergency procedures, minor surgery, office procedures and imaging procedures) were subjected to the following to select the number (emergency procedures = 6, minor surgery = 4, office procedures = 4 and imaging procedures = 2) in every category:

Sum of the following categories: Uncomfortable + very uncomfortable + the single highest difficulty or complication.

A proportional number of problem procedures in every category (emergency procedures, surgical procedures, office procedures and imaging procedures) were selected. Table 29 shows the problem procedures that were selected by means of Scoring option C.

<i>Emergency procedures:</i>	<ol style="list-style-type: none"> 1. Central venous catheterization (Subclavian vein and internal jugular vein catheterization) 2. Cricothyroidotomy 3. Pericardiocentesis 4. Vascular access: Great saphenous vein 5. Oro/nasotracheal intubation 6. Lumbar puncture
<i>Surgical procedures</i>	<ol style="list-style-type: none"> 1. Appendectomy 2. Caesarian Section 3. Reduction of uncomplicated forearm fractures 4. Ectopic pregnancy surgery
<i>Office procedures</i>	<ol style="list-style-type: none"> 1. Epistaxis and nasal packing 2. Rectal examination, proctoscopy and sigmoidoscopy 3. Knee joint aspiration 4. Wrist block and digital nerve block
<i>Imaging procedures</i>	<ol style="list-style-type: none"> 1. Obstetric ultrasound

Table 29. List of selected problem procedures by means of Scoring option C.

4.3 Comparison between urban and rural practices

A total of 44 questionnaires from practitioners from urban hospital practices and 53 from rural practices were obtained and compared.

Table 30 represents the comparison between urban and rural hospital practices regarding *only the 15 selected problem procedures*. The p-value is provided as well and statistical significance is highlighted.

Table 30. Comparison between urban and rural hospital practices regarding the 15 selected problem procedures.

Procedure		Significance	
		(-) no significant difference (+) significant difference	
		<i>p- value</i>	
Oro/nasotracheal intubation	<i>Incidence</i>	0.378	-
	<i>Frequency</i>	0.015	+ Doctors in rural areas perform more often
	<i>Essentiality</i>	0.750	-
	<i>Comfortability</i>	0.064	-
	<i>Difficulties</i>	0.778	-
	<i>Complications</i>	0.287	-
	<i>Influence of clinical anatomy on reducing difficulties and complications</i>	0.001	+ Rural doctors regard the influence as more important
	<i>Influence of clinical anatomy to increase confidence</i>	0.0236	+ Rural doctors regard the influence as more important
Cricothyroidotomy	<i>Incidence</i>	0.026	+More urban doctors perform this procedure
	<i>Frequency</i>	0.0001	+ Doctors in urban areas perform more often
	<i>Essentiality</i>	0.908	-
	<i>Comfortability</i>	0.052	-
	<i>Difficulties</i>	0.003	+ Urban doctors have more difficulties
	<i>Complications</i>	0.439	-
	<i>Influence of clinical anatomy on reducing difficulties and complications</i>	0.053	-
	<i>Influence of clinical anatomy to increase confidence</i>	0.068	-

Procedure		Significance	
		(-) no significant difference (+) significant difference	
		<i>p- value</i>	
Great saphenous vein cannulation	<i>Incidence</i>	0.511	-
	<i>Frequency</i>	0.044	+Urban doctors perform more often
	<i>Essentiality</i>	0.347	-
	<i>Comfortability</i>	0.183	-
	<i>Difficulties</i>	0.212	-
	<i>Complications</i>	0.489	-
	<i>Influence of clinical anatomy on reducing difficulties and complications</i>	0.006	+ Rural doctors regard the influence as more important
	<i>Influence of clinical anatomy to increase confidence</i>	0.003	+ Rural doctors regard the influence as more important
	Lumbar puncture	<i>Incidence</i>	0.0002
<i>Frequency</i>		0.304	-
<i>Essentiality</i>		0.0001	+More rural doctors regard the procedure as essential
<i>Comfortability</i>		0.265	-
<i>Difficulties</i>		0.873	-
<i>Complications</i>		0.732	-
<i>Influence of clinical anatomy on reducing difficulties and complications</i>		0.010	+ Rural doctors regard the influence as more important
<i>Influence of clinical anatomy to increase confidence</i>		0.052	-
Pericardiocentesis		<i>Incidence</i>	0.367
	<i>Frequency</i>	0.028	+ Doctors in urban areas perform more often
	<i>Essentiality</i>	0.098	-
	<i>Comfortability</i>	0.201	-
	<i>Difficulties</i>	0.632	-
	<i>Complications</i>	0.074	-
	<i>Influence of clinical anatomy on reducing difficulties and complications</i>	0.012	+ Rural doctors regard the influence as more important
	<i>Influence of clinical anatomy to increase confidence</i>	0.027	+ Rural doctors regard the influence as more important

Procedure		Significance	
			(-) no significant difference (+) significant difference
		<i>p- value</i>	
Subclavian vein catheterization	<i>Incidence</i>	0.0002	+More urban doctors perform this procedure
	<i>Frequency</i>	0.0002	+ Doctors in urban areas perform more often
	<i>Essentiality</i>	0.684	-
	<i>Comfortability</i>	0.0005	+Rural doctors are more uncomfortable
	<i>Difficulties</i>	0.004	+Urban doctors have more difficulties
	<i>Complications</i>	0.0008	+Urban doctors experience more complications
	<i>Influence of clinical anatomy on reducing difficulties and complications</i>	0.0066	+ Rural doctors regard the influence as more important
	<i>Influence of clinical anatomy to increase confidence</i>	0.005	+ Rural doctors regard the influence as more important
Internal jugular vein catheterization	<i>Incidence</i>	0.082	-
	<i>Frequency</i>	0.004	+Doctors in urban areas perform more often
	<i>Essentiality</i>	0.0008	+More rural doctors regard the procedure as essential
	<i>Comfortability</i>	0.002	+Urban doctors are more uncomfortable
	<i>Difficulties</i>	0.0001	+Urban doctors have more difficulties
	<i>Complications</i>	0.0009	+Urban doctors experience more complications
	<i>Influence of clinical anatomy on reducing difficulties and complications</i>	0.079	-
	<i>Influence of clinical anatomy to increase confidence</i>	0.035	+ Rural doctors regard the influence as more important
Cesarian section	<i>Incidence</i>	0.0001	+More rural doctors perform this procedure
	<i>Frequency</i>	0.108	-
	<i>Essentiality</i>	0.0001	+More rural doctors regard the procedure as essential
	<i>Comfortability</i>	0.935	-
	<i>Difficulties</i>	0.804	-

Procedure	Significance		
	(-) no significant difference (+) significant difference		
	<i>p- value</i>		
Reduction of uncomplicated forearm fractures	<i>Complications</i>	0.0009	+Rural doctors experience more complications
	<i>Influence of clinical anatomy on reducing difficulties and complications</i>	0.445	-
	<i>Influence of clinical anatomy to increase confidence</i>	0.214	-
	<i>Incidence</i>	0.0001	+More rural doctors perform this procedure
	<i>Frequency</i>	0.673	-
	<i>Essentiality</i>	0.0001	+More rural doctors regard the procedure as essential
	<i>Comfortability</i>	0.259	-
	<i>Difficulties</i>	0.785	-
	<i>Complications</i>	0.045	+Rural doctors experience more complications
	<i>Influence of clinical anatomy on reducing difficulties and complications</i>	0.022	+ Rural doctors regard the influence as more important
Ectopic pregnancy surgery	<i>Influence of clinical anatomy to increase confidence</i>	0.056	-
	<i>Incidence</i>	0.0002	+More rural doctors perform this procedure
	<i>Frequency</i>	0.034	+Doctors in rural areas perform more often
	<i>Essentiality</i>	0.0001	+More rural doctors regard the procedure as essential
	<i>Comfortability</i>	0.699	-
	<i>Difficulties</i>	0.970	-
	<i>Complications</i>	0.054	-
	<i>Influence of clinical anatomy on reducing difficulties and complications</i>	0.196	-
	<i>Influence of clinical anatomy to increase confidence</i>	0.258	-
	Appendectomy	<i>Incidence</i>	0.855
<i>Frequency</i>		0.904	-
<i>Essentiality</i>		0.0001	+More rural doctors regard the procedure as essential

Procedure		Significance	
		(-) no significant difference (+) significant difference	
		<i>p- value</i>	
Appendectomy (continued)	<i>Comfortability</i>	0.219	-
	<i>Difficulties</i>	0.162	-
	<i>Influence of clinical anatomy to increase confidence</i>	0.210	-
Wrist and digital nerve block	<i>Incidence</i>	0.936	-
	<i>Frequency</i>	0.772	-
	<i>Essentiality</i>	0.021	+More rural doctors regard the procedure as essential
	<i>Comfortability</i>	0.387	-
	<i>Difficulties</i>	0.485	-
	<i>Complications</i>	0.736	-
	<i>Influence of clinical anatomy on reducing difficulties and complications</i>	0.222	-
Knee joint aspiration	<i>Influence of clinical anatomy to increase confidence</i>	0.470	-
	<i>Incidence</i>	0.006	+More rural doctors perform this procedure
	<i>Frequency</i>	0.982	-
	<i>Essentiality</i>	0.0001	+More rural doctors regard the procedure as essential
	<i>Comfortability</i>	0.375	-
	<i>Difficulties</i>	0.051	-
	<i>Complications</i>	0.390	-
Epistaxis and nasal packing	<i>Influence of clinical anatomy on reducing difficulties and complications</i>	0.023	+ Rural doctors regard the influence as more important
	<i>Influence of clinical anatomy to increase confidence</i>	0.187	-
	<i>Incidence</i>	0.938	-
	<i>Frequency</i>	0.951	-
	<i>Essentiality</i>	0.294	-
	<i>Comfortability</i>	0.805	-
	<i>Difficulties</i>	0.146	-
	<i>Complications</i>	0.146	-

Procedure		Significance	
		(-) no significant difference (+) significant difference	
		<i>p- value</i>	
	<i>Influence of clinical anatomy on reducing difficulties and complications</i>	0.190	-
	<i>Influence of clinical anatomy to increase confidence</i>	0.163	-
Rectal examination	<i>Incidence</i>	0.796	-
	<i>Frequency</i>	0.573	-
	<i>Essentiality</i>	0.560	-
	<i>Comfortability</i>	0.181	-
	<i>Difficulties</i>	0.794	-
	<i>Complications</i>	0.741	-
	<i>Influence of clinical anatomy on reducing difficulties and complications</i>	0.013	+ Rural doctors regard the influence as more important
	<i>Influence of clinical anatomy to increase confidence</i>	0.027	+ Rural doctors regard the influence as more important
Obstetric ultrasound	<i>Incidence</i>	0.281	-
	<i>Frequency</i>	0.666	-
	<i>Essentiality</i>	0.0003	-
	<i>Comfortability</i>	0.242	-
	<i>Difficulties</i>	0.298	-
	<i>Complications</i>	0.849	-
	<i>Influence of clinical anatomy on reducing difficulties and complications</i>	0.055	-
	<i>Influence of clinical anatomy to increase confidence</i>	0.305	-

4.4 Development of a clinical anatomy knowledge base for each selected problem procedure

A detailed knowledge database was developed for every problem procedure selected by Scoring option C. This was done in a standard way by means of the following headings:

- 1. Indications*
- 2. Contraindications/ Precautions*
- 3. Step by step procedure*
- 4. Materials*
- 5. Anatomical pitfalls*
- 6. Complications (anatomically relevant)*
- 7. References*

The most recent and relevant literature was studied extensively to compile a referenced clinical anatomy synopsis for each problem procedure separately.

The result of this study is presented here for each selected problem procedure:

4.4.1 Emergency procedures

4.4.1.1 Cricothyroidotomy – (needle and surgical)

1. <i>Indications</i>	78
2. <i>Contraindications/ Precautions</i>	79
3. <i>Step by step procedure</i>	79
4. <i>Materials</i>	81
5. <i>Anatomical pitfalls</i>	82
6. <i>Complications (anatomically relevant)</i>	86
7. <i>References</i>	91

1. Indications

- The quickest, safest and easiest way to obtain an airway where intubation is difficult¹. The advantages of a cricothyroidotomy are the speed with which the procedure can be performed and that it can be done safely outside the operating room in contrast to a tracheostomy, which should always be performed under controlled conditions in the operating room.
- Any patient requiring airway management who cannot be intubated by the oral or nasal route.
- Trauma patients whose cervical spine has a possible injury and where manipulation of the neck is contraindicated¹⁵.

1.1 Needle cricothyroidotomy

- Temporarily for a few minutes. High-pressure jet insufflation may be used through a 14- or 16-gauge needle, which is readily available in emergency department settings. The problem is accumulation of carbon dioxide. The oxygen pressure must be at least 50 psi and intratracheal pressures should not exceed 20 cm H₂O for adult patients^{17 18}. Most hospital wall outlets deliver oxygen at 50psi.

1.2 Surgical cricothyroidotomy

- Inability to intubate the trachea is a clear indication for creating a surgical airway. This may be due to:
 - Severe maxillofacial trauma.
 - Edema of the glottis and inability to visualize the vocal cords e.g. angioneurotic edema and anaphylactic shock e.g. secondary to a bee sting, snakebite, burns or toxic inhalation.
 - Severe oropharyngeal or tracheobronchial hemorrhage.
 - Unstable cervical spine fracture with contraindications for neck manipulation.
 - Fracture of the base of the skull.

- Foreign body obstruction.
- Creating an emergency airway where equipment is lacking and where oral or nasal endotracheal intubation cannot be performed rapidly and safely.
- Technical failure to intubate¹⁴.
- Clenched teeth¹⁴.
- Masseter spasm following succinylcholine¹⁴.

2. Contra-indications/ Precautions

- A less invasive method is possible to secure a patent airway, e.g. intubation.
- Patients under 5 years of age (A needle cricothyroidotomy may be done). However, a formal tracheostomy is preferred.
- Fracture of the larynx and existing pathology of the larynx⁸.
- Transection of the trachea with retraction of distal end of the trachea into the mediastinum.
- Anatomical barriers like a vast hematoma or massive subcutaneous emphysema in the region, which makes palpation of the anatomical landmarks such as the thyroid and cricoid cartilage impossible.

3. Step by step procedure

3.1 Needle Cricothyroidotomy

Skill acquisition and maintenance are less complicated compared to a surgical cricothyroidotomy¹⁵.

1. Ensure a free flow tubing of oxygen. Cut a hole towards the end of the tubing. This will allow for intermittent oxygen delivery.
2. Place the patient in a supine position with a non-twisted neck.
3. Assemble a 12 or 14 gauge over the needle catheter attached to a 5 ml syringe
4. Surgically prepare the neck using antiseptic swabs.
5. Identify the cricothyroid membrane, between the cricoid cartilage and the thyroid cartilage. Stabilize the trachea with the thumb and forefinger of one hand to prevent lateral movement of the trachea during performance of the procedure.
6. Puncture the skin in the midline with the needle attached to the syringe, directly over the cricothyroid membrane. A small incision with a #20 scalpel may facilitate passage of the needle through the skin.
7. Direct the needle at a 45-degree angle inferiorly to avoid vocal cords, while applying negative pressure to the syringe and carefully insert the needle through the lower half of the cricothyroid membrane.

8. Aspiration of air signifies entry into the tracheal lumen. This is important because it assures that the posterior tracheal wall was not penetrated (thus avoiding possible massive paratracheal emphysema) and it assures that the catheter tip is not embedded in the tracheal mucosa avoiding tracheal mucosa damage.
9. Remove the syringe and withdraw the needle while advancing the catheter downward into position, being careful not to perforate the posterior wall of the trachea.
10. Attach the oxygen tubing over the catheter needle hub.
11. Intermittent ventilation can be achieved by occluding the open hole. The ventilatory rate should be about 20/min, with the inspiratory phase lasting about 1 second. The expiratory phase should be at least 2 seconds.

3.2 Surgical cricothyroidotomy

1. Place the patient in a supine position with the neck in a neutral position. Palpate the thyroid notch, cricothyroid membrane, the sternal notch and hyoid bone for orientation. Assemble the necessary equipment.
2. Surgically prepare and anesthetize (if there is time) the area, if the patient is conscious.
3. Stabilize the thyroid with the non-dominant hand, keeping the skin taut over the thyroid notch. This is important in order not to lose the anatomical landmarks during the procedure.
4. Make a *vertical* skin incision (2cm) over the cricothyroid membrane. Locate the membrane and then carefully incise *horizontally*¹⁴ (1.5cm) through the lower half of the membrane in order to avoid the cricothyroid arteries. Make sure only the tip of the scalpel blade enters the airway, to avoid injury to the posterior cricoid cartilage. The tracheal hook can be used to stabilize the larynx especially in the patient with a fat neck or hypermobile larynx.
5. Insert the scalpel handle into the incision and rotate it 90 degrees to open the airway. Extend the incision laterally for approximately 1 cm on each side of the midline.
6. Insert an appropriately sized, cuffed endotracheal tube or tracheotomy tube into the cricothyroid membrane incision, directing the tube distally into the trachea. The tube should always be aimed downwards in order not to injure the vocal cords above.
7. Inflate the cuff and ventilate the patient.
8. Observe bilateral lung inflation and auscultate the chest for adequate ventilation.
9. Perform suction of the trachea.
10. Secure the endotracheal tube to the patient to prevent dislodging.
11. Caution: Do not cut or remove the cricoid, or thyroid cartilages.

Alternative methods:

1. Brofeldt's rapid four-step technique¹⁶.

This technique is simple to perform, aids comprehensive retention, lacks the need for specialized surgical equipment and may be ideal for the out-of-hospital environment.

The materials needed are a #20 scalpel, tracheal hook and a cuffed tracheostomy tube (#6 Shiley for most adults)

Step 1. Palpation

The operator is positioned at the *left* shoulder of the patient.
Palpate the cricothyroid membrane with the left hand's index finger.
The middle finger and thumb palpate the carotid pulses and stabilize the trachea.

Step 2. Incision

With the right hand, make a horizontal incision over the skin.
Make a subsequent horizontal incision into the inferior aspect of the cricothyroid membrane.
Push the scalpel through the membrane, creating a 2.5 cm horizontal incision. This eliminates the need for an extension of the incision or spreading the incision transversely as is usually recommended²².

Step 3. Traction

Use the left hand and place the tracheal hook through the incision made into the trachea. Turn the hook 90 degrees inferiorly and apply caudal traction to the superior margin of the cricoid cartilage with the left hand resting on the patient's sternum.

Step 4. Intubation

Insert the tube with the right hand
Remove the tracheal hook and inflate the cuff.
The hand motion during this method is similar to that of intubation, when using a laryngoscope in the left hand and inserting the tube with the right hand.

2. Method reported by Toye and Weinstein²⁶.

Toye and Weinstein²⁶ report on their success with a cricothyroidotomy device, consisting of a tube, dilator and needle. The needle is able to split after guiding the dilator through it into the infraglottic space. The tube is then percutaneously inserted over the dilator, after which the dilator is removed.

The advantage of this method is the speed of performance, less bleeding, smaller stoma scar, less assistance and fewer instruments are required.

4. Materials

- Sterile pack and gloves.
- Local anesthetic.
- #20 or #11 scalpel.
- Size 4-6 endotracheal tubes (male no 6, female no 4 or 5) or size 4-6 cuffed tracheostomy tubes.

- Mosquito clamps.
- Tracheal hook if available.
- Pair of Mayo Scissors.
- 10 cc syringe.
- Adhesive tape.
- Ambubag with tubing, oxygen.
- Suction.
- For PTV (percutaneous transtracheal ventilation): Over the needle type catheter (12-14 gauge).

5. Anatomical pitfalls

5.1 Infraglottic cavity

- The infraglottic cavity is the most superficial part of the airway at the cricothyroid membrane. It can therefore easily be accessed surgically.

5.2 Cricothyroid membrane (median cricothyroid ligament)

- The cricothyroid membrane forms the first indentation inferior to thyroid cartilage, it is easily identifiable, even in obese patients. It is located immediately subcutaneously and is a dense fibro elastic membrane. The membrane is bordered laterally by the cricothyroid muscles. The area of the membrane is trapezoidal in shape.
- The membrane is specifically referred to as the median cricothyroid ligament. It is the superficial, thickened anteromedial part of the conus elasticus below the laryngeal mucosa²⁷. It arises from the cricoid cartilage with ventral densely arranged fibres, which make the ligament clearly distinguishable from the anterior overlying tissues, and looser arranged collagenous fibres towards the airway lumen. It stretches superiorly to the thyroid and arytenoid cartilages with the free superior margin being the cord³⁵.
- The membrane may be pierced by small blood vessels, usually situated at its attachments to the thyroid and cricoid cartilages³⁵.
- Size of the membrane: Adult: 22-33 mm wide (beyond the cricothyroid muscles), 9-10 mm high⁹. The endotracheal tube's outer diameter should not exceed 8 mm and an inner diameter of at least 5 mm is recommended to provide good airflow¹².
- Dover *et al*²⁷ reported on the dimensions of the cricothyroid membrane in a study on 15 cadaveric specimens. The average width of the cricothyroid membrane between the cricothyroid muscles was 8.2 mm and the average height 10.4 mm. The average width and height were consistently smaller in females. Females: average 6.9mm(width) by 9.5mm (height). Males: 8.8mm (width) by 10.9mm (height).

- In an autopsy-based study, Bennett *et al*¹⁹ demonstrated that the vertical measurement of the cricothyroid membrane ranged from 8-19mm (13.69mm:mean) and the width between the cricothyroid muscles between 9 and 19mm (12.38 mm: mean). They also showed that the vertical height measurement of the cricothyroid membrane is influenced by the synovial cricothyroid joint. Mobility can be limited in patients with rheumatoid arthritis.

5.3 Easily identifiable landmarks

- These are the anterior midline structures of the neck (from superior to inferior): Mandible, floor of the mouth, hyoid bone, thyrohyoid membrane, thyroid cartilage, cricothyroid membrane and cricoid cartilage. The landmarks may change due to the injury that mandated the cricothyroidotomy. The thyroid notch can however be palpated in most patients¹⁷.

5.4 Arteries and veins

- There are no major arteries, veins and nerves in the area of the cricothyroid membrane. The blood supply of the larynx comes from the superior laryngeal artery, a branch of the superior thyroidal artery, as well as the inferior laryngeal artery branching from the inferior thyroidal artery. There is an extensive anastomosis between these two laryngeal arteries¹⁹. The right and left cricothyroid arteries transverse the superior part of the cricothyroid membrane, and have not been found to be clinically significant for the procedure. Bennett *et al*¹⁹ reported a 62% incidence of an artery running transversely across the cricothyroid membrane.
- The cricothyroid artery usually arises from the superior laryngeal artery, a branch of the superior thyroid artery²⁹.
- Dover *et al*²⁷ reports on the cricothyroid artery arising from the superior thyroid artery in 93% of the 15 cases studied. In most specimens the artery crossed the upper half of the cricothyroid membrane. The artery gives off branches which penetrate the membrane and then run superiorly toward the thyroid cartilage. It is therefore recommended to make the incision in the lower half of the cricothyroid membrane⁷ along the superior border of the cricoid cartilage. This will also avoid damage to the vocal cords¹⁹. The incision should not be made alongside the inferior border of the thyroid cartilage.

In 54% of cases, the superior thyroid artery coursed anterior to the sternothyroid muscle and on the lateral border of the cricothyroid membrane. This underscores the important fact that the incision of the membrane should not extend laterally more than 1cm. Dover *et al*²⁷ also found venous tributaries of the superior and inferior thyroid veins, crossing the cricothyroid membrane. In 80% of the 15 dissections, Dover *et al*²⁷ found small veins from the region of the thyroid isthmus crossing the cricothyroid membrane.

Occasionally two cricothyroid arteries anastomose in the midline to form the median descending artery supplying a pyramidal lobe of the thyroid gland.

- Lateral to the cricothyroid membrane, the thyroid and cricoid cartilages are bridged by adipose tissue and delicate connective tissue, which also forms the route for blood vessels entering or leaving the larynx³¹. Further laterally the gap between the cricoid and thyroid cartilages are bridged by the cricothyroid muscles.

5.5 Anterior jugular veins

- These veins run in a vertical fashion in the lateral aspect of the neck and should be uninvolved if one stays to the midline. Some authors recommend an initial vertical incision of the skin and cervical fascia to avoid these vascular structures laterally and ease identification of structures in difficult situations^{7,11}. Thereafter the cricothyroid membrane is incised horizontally.
- Dover *et al*²⁷ described the presence of paired anterior jugular veins in the subcutaneous tissue, crossing the cricothyroid membrane in a vertical direction in the majority of the 15 dissections.

5.6 Esophagus

- There is a lesser chance of injuring the esophagus during a cricothyroidotomy, than with a tracheostomy due to the circumferential cricoid cartilage posterior at the level of a cricothyroidotomy²¹. There is deficient tracheal cartilage posterior (C-shaped cartilage ring) on a lower level where a tracheostomy is performed.

5.7 Vocal cords

- The cords are situated superiorly, at least 1 cm above the site of incision⁷. The tube should be aimed downwards in order not to injure the vocal cords. The vocal cords are attached to the internal anterior surface of the thyroid cartilage.
- Bennett *et al*¹⁹ demonstrated in a cadaver study, that the distance from the upper border of the cricothyroid membrane to the vocal cords was 9.78mm.

5.8 Anterior cervical fascia

- Due to an injury of this fascial layer, soft tissue edema may develop and can make location of the cricothyroid membrane extremely difficult¹⁰.

5.9 Children

- The thyroid cartilage in the midline (laryngeal prominence) is difficult to palpate in children for it does not develop until adolescence.
- The most prominent structures are the hyoid bone and cricoid cartilage.

- The cricothyroid membrane is situated more cephalad in children compared to adults.
- The height of the cricothyroid membrane is not as high as in the adult (3 mm in infants compared to 9-10 mm in adults). Therefore a needle cricothyroidotomy is indicated for children younger than 12 years. An endotracheal tube, which is too large, may damage the cartilage structures permanently.
- Because of difficulty in palpating the anatomical landmarks, it is better to do a formal tracheostomy than a cricothyroidotomy in children under 5 years of age.
- There may be an increased risk of damaging the only completely circumferential supporting structure (cricoid cartilage) in a child. This is also the narrowest segment of the infant airway. In adults the narrowest segment of the airway is the glottic opening.
- The airway is also narrower and more flexible than in the adult, making posterior penetration of the tracheal wall much more likely in the child and infant.
- The mucosa is more fragile, looser and softer, making edema and laceration more likely and thus cause subglottic stenosis.
- The risk of subglottic stenosis is higher in children and adolescents²⁰.

5.10 Vascular anomalies

- A few vascular anomalies, where a major artery crosses the neck are usually found lower in the neck. Major anomalous vessels do not overlie the cricothyroid membrane.

5.11 Cricoid cartilage

- The cricoid cartilage consists of an arch (anterior) and lamina (posterior). The cartilage is situated at level C6. It is the only complete cartilaginous ring in the larynx and trachea, serving as a stent and maintaining a patent airway following cricothyroidotomy²⁴.

5.12 Thyroid gland and isthmus

- The isthmus is absent in 10% of cases¹³. The thyroid gland has a pyramidal lobe in 40% of people. Others report a 60-65% incidence and regard the lobe as a normal component of the thyroid gland³³. This lobe may extend as high as the hyoid bone and therefore may be at risk of injury when performing a cricothyroidotomy. It represents a persistent portion of the inferior end of the thyroglossal duct. The lobe is usually situated on the left of the midline. The thyroid gland descends anterior to the hyoid bone and laryngeal cartilages. The isthmus is usually 1.25 cm wide and lies anterior to the second and third tracheal cartilages³⁰.

- The thyroid gland may also impinge on the cricothyroid membrane, and if injured during the procedure, cause bleeding.

5.12 Recurrent laryngeal nerve

- These nerves run bilaterally between the trachea and the esophagus on the plane of the cricoid cartilage and supplies the larynx sensorically as well as all the laryngeal muscles except the cricothyroid.

5.13 Common carotid artery and internal jugular vein

- These structures lie posterolaterally to the cricoid cartilage and staying in the midline will prevent injury to these structures

6. Complications (anatomically relevant)

One needs to remember, that the complications listed are minor when thinking of the catastrophic morbidity associated with failure to secure an airway. This procedure is usually done in the Emergency Room or in the field, and therefore necessarily has a higher complication rate than if the procedure is performed electively^{7,14}. However, Miklus *et al*⁶ reports no serious complications in a retrospective analysis of 20 patients on which a cricothyroidotomy was performed outside of the hospital on a helicopter transport team.

Complication rates of between 6.1 and 8.6% are reported for elective cricothyroidotomies compared to 40% in the Emergency Room¹⁴.

6.1 Incision over the thyrohyoid space

- McGill *et al*¹⁴ found in a study of 38 cricothyroidotomies, that the most frequent complication was incorrect placement of the tube through the thyrohyoid membrane. According to them, an initial horizontal incision of the skin may contribute to misplacement of the tube through the thyrohyoid space. They argue that vertical incisions can be extended when necessary to get to the appropriate level of the cricothyroid space.

Furthermore, proper identification of the anatomical landmarks are crucial, including the cricoid cartilage, thyroid cartilage, cricothyroid membrane and the hyoid bone. The position of the cricothyroid membrane should also be reconfirmed after the skin incision has been made.

- Incision over the thyrohyoid space should be prevented by careful identification of the anterior midline structures of the neck.

6.2 Intra- and postoperative bleeding

- Evidence from cadaver studies shows that vessels may actually complicate the

procedure by bleeding more commonly than originally recognized³. Severe bleeding is however seldom encountered²¹. When treating a patient in severe respiratory distress rapid and effective control of the airway is the first priority and bleeding can be dealt with secondary.

- Bleeding is usually due to a superficial venous plexus injury. This can be prevented by incising directly over the cricothyroid membrane, and staying in the midline. The incision should not be extended too far laterally. Bleeding usually occurs from the edges of the incision. This complication is minimized if the skin incision is performed vertically². McGill *et al*¹⁴ also reports on two cases of 38 where hemorrhage required ligation due to horizontal incisions. The bleeders occurred at the margin of the incision and may be avoided in vertical incisions.
- One study done on cadavers reported a high number of small vessels in the region of the cricothyroid membrane at risk³. The complication of bleeding can however be present even when doing the procedure correctly, therefore one needs to be aware and treat appropriately. Caution should be taken not to incise the thyroid isthmus, which is a highly vascular structure. The thyroid isthmus is found on the level of the 2nd and 3rd tracheal rings.
- The cricothyroid artery courses through the superior half of the cricothyroid membrane. Therefore the incision should be made through the inferior half of the membrane. McGill¹⁴ refers to a case of fatal airway hemorrhage followed by aspiration when the cricothyroid artery was disrupted.
- Fatal airway hemorrhage after cricothyroidotomy has also been reported by Schillaci *et al*²⁸ with laceration of the cricothyroid artery with resultant endobronchial bleeding and asphyxia. Autopsy revealed that this patient had a larger than normal cricothyroid artery coursing horizontally across the midportion of the membrane. These arteries run closer to the thyroid cartilage and the incision should therefore be made closer to the cricoid cartilage.
- Brofeldt *et al*¹⁶ reports on bleeding from the anterior jugular veins in one patient, which was controlled without any problem.
- Bleeding from the cricothyroid arteries can be controlled by ligation of the branches of the superior thyroidal artery, which may be necessary due to the extensive collateral blood supply²⁸.
- Donald *et al*³⁴ reports a brisk persistent endolaryngeal hemorrhage probably due to one of the vessels running in the submucosal area of the larynx in the region of the cricothyroid membrane. The endolaryngeal arteries in the submucosa of the subglottic region anastomose with the cricothyroid arteries via a perforating branch.

6.3 Execution time of greater than 3 minutes.

- A cricothyroidotomy should easily be established within 2 minutes²².

6.4 Misplaced tube resulting in endobronchial intubation

- This can occur, especially when using an endotracheal tube, which is inserted too deeply. Usually the tube goes down the right primary bronchus, which is more vertical, is shorter and has a greater diameter when compared with the left.

6.5 Subglottic stenosis

- Subglottic stenosis is believed not to be a common complication⁸, even in the presence of laryngeal pathology. The most common cause of subglottic stenosis is endotracheal intubation⁵. This condition is caused by mucosal damage due to a tube eroding the mucosal surface by excessive cuff pressures, frequent tube movement and rigid tubes. This complication was more frequently seen when large bore tubes were used¹⁹.
- It has been said that a cricothyroidotomy tube should be removed after 48 hours due to the risk of subglottic stenosis. Sise *et al*²⁰ showed in a prospective analysis that there is long-term morbidity associated with cricothyroidotomy. However it seems similar to that seen in tracheostomy. When comparing the complications in cricothyroidotomy and tracheostomy they are different. Subglottic stenosis due to cricothyroidotomy is most frequently reported in long-term cricothyroidotomy. It is rare in tracheostomy. But major vessel erosion and pneumothorax have been described after tracheostomy³² and not after cricothyroidotomy^{20 21}. Ger³² describes the complications of tracheostomy and links these to the anatomy. Tracheostomies, especially those done below the isthmus level are prone to pneumothoraces (due to the pleura reaching 2.5 cm above the medial third of the clavicle) and there is a risk of possible injury to the brachiocephalic artery (especially in older patients with a short neck). Cricothyroidotomy therefore offers a distinct advantage due to its ease in performance.
- Brantigan *et al*²¹ reported in 1976 no chronic subglottic stenosis in long term cricothyroidotomies, however later studies by the same author showed that the complication was prevalent, although not high⁸. This was published after the landmark paper by Jackson²³ which convinced the medical profession for nearly 40 years that the incidence of subglottic stenosis was high and the procedure should therefore be abandoned. This was appropriate in Jackson's patient population where there was a significant number of infectious laryngeal diseases such as diphtheria, tuberculosis and Ludwig's angina.
- Should a cricothyroidotomy be used for a longer period, it should only be used in patients free of acute laryngeal pathology⁸. This includes an already injured larynx

due to prolonged endotracheal intubation²². Weymuller *et al*²⁵ also suggest that a cricothyroidotomy should not be used after prolonged intubation due to the high risk of subsequent subglottic stenosis.

- Usually the cricothyroidotomy stoma heals satisfactory with granulation tissue and more than 50% re-epithelialization after two weeks^{22 24}.

6.6 Vocal cord damage

- It is important to avoid vocal cord damage by directing the needle caudally at 45°.

6.7 Laryngeal damage

- This may occur due to an oversized tube being forced through the relatively small cricothyroid space. Injury to the vocal cords is associated with too vigorous superior traction on the thyroid cartilage¹⁶. This technique is suggested to expose the incision made in the cricothyroid membrane⁹. To avoid the risk of injury to the vocal cords traction can be applied to the inferior side of the incision on the cricoid cartilage¹⁶.

6.8 Dysphonia and hoarseness

- Dysphonia and hoarseness due to damage to the vocal cords have been reported⁴. It may be the result of cutting the vocal cords, especially if the incision through the cricothyroid membrane is made close to the thyroid cartilage. It should be made alongside the superior border of the cricoid cartilage¹⁹.
- Dysphonia can occur secondary to a tracheal cartilage fracture, usually due to the insertion of an oversized tube^{14,19}. The outer diameter of the tube should not exceed 8 mm^{12,14}. A number 4 Shiley tube has an internal diameter of 5 mm and an outer diameter of 8.5 mm.
- Hoarseness has been reported due to a small amount of granulation tissue below the cords secondary to cricothyroidotomy²².
- Gleeson *et al*⁴ reports a high incidence of vocal disturbance after cricothyroidotomy in patients requiring a prolonged period of mechanical ventilation. Subjective vocal changes like loss of volume, a voice that fatigues easily, deep and husky voices and limited vocal ranges have been reported. These subjective findings were found to correlate with objective analysis of laryngographs.

6.9 Pretracheal intubation

- Pretracheal intubation has also been reported¹⁶. This complication is more likely to occur when the incision of the cricothyroid membrane is opened by superior traction on the thyroid cartilage. This can be avoided by inferior traction on the cricoid cartilage. A large diameter tracheal hook can be used for this by placing the hook

around the posterior wall of the anterior arch of the cricoid cartilage.

6.10 Aspiration

- During a needle cricothyroidotomy or PTV (percutaneous transtracheal ventilation), the airway is not protected from the aspiration of upper airway secretions, blood or emesis¹⁵.

6.11 Tube dislodgement

- The incidence is low due to the proximity of the airway to the skin surface²¹.

6.12 Massive subcutaneous emphysema¹⁵

- Found especially in PTV (percutaneous transtracheal ventilation). This serious complication may occur due to misplacement or dislodgment of the catheter into the subcutaneous tissue. The catheter should be securely placed.
- Subcutaneous emphysema may also develop due to leakage of air via a secondary puncture site.
- It may also occur after removal of the catheter, which can be avoided by applying digital pressure over the puncture site.

6.13 Tracheal stenosis

- Pressure necrosis of the trachea occurs due to a high-pressure balloon cuff. Therefore a low-pressure cuff should be used.

6.14 Recurrent laryngeal nerve injury

- Injury to these nerves may lead to vocal cord paralysis. The nerves lie between the trachea and the esophagus at the level of the cricoid cartilage and enter the larynx from posteriorly. Therefore, staying in the midline without injuring the posterior wall of the subglottic airway, will ensure avoidance of these nerves.

6.15 Perforated esophagus

- This is a theoretical complication¹⁵. So is the formation of a tracheo-esophageal fistula⁶. Care should be taken not to incise or push the needle too deeply after entering the infraglottic cavity.

6.16 Tracheo-left brachiocephalic vein fistula formation

- This complication may be due to a too high pressure in the cuff and can be prevented by using a low-pressure cuff tube.

- In children, the relative shortness of the neck places the cervical and upper thoracic structures at a higher level and the brachiocephalic vein may have a cervical rather than mediastinal position³².

6.17 Pneumothorax, Pneumomediastinum

- These have been reported in PTV (percutaneous transtracheal ventilation) due to barotrauma¹⁵. The procedure should therefore be avoided in patients with emphysema.
- Mediastinal emphysema may occur with cannula misplacement posterior to the esophagus.

6.18 Thyroid cartilage fracture

- McGill¹⁴ reports a case, where due to an oversized tube through the cricothyroid membrane, a longitudinal fracture occurred through the thyroid cartilage with consequent severe dysphonia. The tube used had an outer diameter of 12 mm, which is 3 mm larger than the average height of the cricothyroid membrane of 9-10 mm⁹. Various authors^{12, 14} advise that the outer diameter of the tube should not be more than 8 mm.

7. References

- ¹ Mace SE. Cricothyroidotomy. *J Emerg Med* 1988;6:309
- ² Little CM, Parker MG, Tarnopolsky R. Modification of cricothyroidostomy. *Ann Emerg Med* 1986;15:1254
- ³ Little CM, Parker MG, Tarnopolsky R. The incidence of vasculature at risk during cricothyroidostomy. *Ann Emerg Med* 1986;15:805
- ⁴ Gleeson MJ, Pearson RC, Armistead S, et al. Voice changes following cricothyrotomy. *J Laryngol Otol* 1984;98:1015
- ⁵ Kuriloff DB, Setzen M, Portnoy W. Laryngotracheal injury following cricothyroidotomy. *Laryngoscope* 1987;99:125
- ⁶ Miklus RM, Elliott C, Snow N. Surgical cricothyrotomy in the field: Experience of a helicopter transport team. *J Trauma* 1989;29:506
- ⁷ Walls RM. Cricothyroidotomy. *Emerg Med Clin North Am.* 1988 Nov;6(4):725
- ⁸ Brantigan CO, Grow JB: Subglottic stenosis after cricothyroidotomy. *Surgery* 1982;91:217-221
- ⁹ Kress TD, Balasubramaniam S. Cricothyroidotomy. *Ann Emerg Med* 1982;11:197-201
- ¹⁰ Simon RR, Brenner BE, Rosen MA. Emergency cricothyroidotomy in the patient with massive neck swelling. Part 1: Anatomical aspects. *Crit Care Med* 1983;11:114-118
- ¹¹ Narrod JA, Moore EE, Rosen P. Emergency cricothyrostomy – technique and anatomical considerations. *J Emerg Med* 1985;2:443-446
- ¹² American Association of Clinical Anatomists, Educational affairs committee. The Clinical anatomy of several invasive procedures. *Clin Anat* 1999;12:43-54

- ¹³ Skandalakis JE, Skandalakis PN, Skandalakis LJ. Surgical anatomy and technique. Springer Verlag, 1995:36
- ¹⁴ McGill J Clinton JE, Ruiz E. Cricothyroidotomy in the emergency department. *Ann Emerg Med* 1982;11:361-64
- ¹⁵ Jorden RC. Percutaneous transtracheal ventilation. *Emerg Med Clin North Am* 1988;6(4):745-752
- ¹⁶ Brofeldt BT, Panacek EA, Richards JR. An easy cricothyrotomy approach: The rapid four-step technique. *Acad Emerg Med* 1996;3(11):1060-1063
- ¹⁷ Stewart RD. Manual translaryngeal jet ventilation. *Emerg Med Clin North Am* 1989;7(1):155-164
- ¹⁸ Yealy DM, Stewart RD, Kaplan RM. Myths and pitfalls in emergency translaryngeal ventilation: Correcting misimpressions. *Ann Emerg Med* 1988;17:690-692
- ¹⁹ Bennett JDC, Guha SC, Sankar AB. Cricothyrotomy: The anatomical basis. *J R Coll Surg Edinb* 1996;41:57-60
- ²⁰ Sise MJ, Shackford SR, Cruickshank JC, Murphy G, Fridlund PH. Cricothyroidotomy for long-term tracheal access. A prospective analysis of morbidity and mortality in 76 patients. *Ann Surg* 1984;200(1):13-17
- ²¹ Brantigan CO, Crow JB. Cricothyroidotomy: Elective use in respiratory problems requiring tracheotomy. *J Thorac Cardiovasc Surg* 1976;71:72
- ²² Boyd AD, Romita MC, Conlan AA, Fink SD, Spencer FC. A clinical evaluation of cricothyroidotomy. *Surg Gynecol Obstet* 1979;149:365-368
- ²³ Jackson C. High tracheotomy and other errors the chief causes of chronic laryngeal stenosis. *Surg Gynecol Obstet* 1921;32:392
- ²⁴ Romita MC, Colvin SB, Boyd AD. Cricothyroidotomy – its healing and complications. *Surg Forum* 1977;28:174-175
- ²⁵ Weymuller EA, Cumming CW. Cricothyroidotomy: The impact of antecedent endotracheal intubation. *Ann Otol Rhinol Laryngol* 1982;91:437-439
- ²⁶ Toye FJ, Weinstein JD. Clinical experience with percutaneous tracheostomy and cricothyroidotomy in 100 patients. *J Trauma* 1986;26(11):1034-1040
- ²⁷ Dover K, Howdieshell TR, Colborn GL. The dimensions and vascular anatomy of the cricothyroid membrane: Relevance to emergent surgical airway access. *Clin Anat* 1996;9:291-295
- ²⁸ Schillaci RF, Iacovoni VE, Conte RS. Transtracheal aspiration complicated by fatal endotracheal hemorrhage. *New Engl J Med* 1976;295:488-490
- ²⁹ Bergmann RA, Thompson SA, Afifi AK. *Compendium of Human Anatomic Variation*. Baltimore: Urban and Schwarzenberg, 1988: 353-367
- ³⁰ Yüksel M, Yüksel E, Kaymaz F. Failure of the isthmus lobe to fuse in the midline. *Clin Anat* 1995;8:33-35
- ³¹ Reidenbach MM. Subglottic region: Normal topography and possible clinical implications. *Clin Anat* 1998;11:9-21
- ³² Ger R, Evans JT. Tracheostomy: An Anatomico-Clinical review. *Clin Anat* 1993; 6:337-341
- ³³ Blumberg NA. Observations on the pyramidal lobe of the thyroid gland. *S Afr Med J* 1981;59:949-950
- ³⁴ Donald PJ, Bernstein L. Subglottic hemorrhage following translaryngeal needle aspiration. *Arch Otolaryngol* 1975;101:395-396

³⁵ Reidenbach MM. The attachments of the conus elasticus to the laryngeal skeleton: Physiological and clinical implications. *Clin Anat* 1996;9:363-370

Published Books

Abrahams PH, Webb P. *Clinical anatomy of Practical procedures*. London: Pitman Medical, 1975: 55-59

Vander Salm TJ, Cutler BS, HB Wheeler. Cricothyroidotomy for Emergency airway. In: *Atlas of bedside procedures*. Boston: Little, Brown, 1979:169

American College of Surgeons, Committee on Trauma. *Advanced Trauma Life Support Course for Physicians Student Manual*. Chicago: American College of Surgeons, 1993: 71-73

Pfenninger JL, Grant CF. *Emergency Cricothyroidotomy and Tracheostomy*. In: *Procedures for primary care physicians*. St Louis London: Mosby, 1994: 270

Dunmire SM, Paris PM. *Airway procedures*. In: *Atlas of emergency procedures*. Philadelphia; London: Saunders, 1994: 31

Sharon E Mace *Cricothyrotomy and translaryngeal jet ventilation*. In: *Clinical procedures in emergency medicine* by Roberts JR, Hedges JR, 3rd ed, Philadelphia; London: Saunders, 1998: 58

4.4.1.2 Orotracheal and nasotracheal intubation

1. Indications	94
2. Contraindications/ Precautions	94
3. Step by step procedure	94
4. Materials	96
5. Anatomical pitfalls	97
6. Complications (anatomically relevant)	102
7. References	110

1. Indications

- Any clinical situation where a definite airway is necessary.

2. Contra-indications/ Precautions

- An unstable neck injury is a relative contraindication. Intubation could however be done without extending or rotating the neck.
- Nasotracheal intubation is contraindicated in patients with a suspected skull base fracture and severe nasal injury, as well as if acute epiglottitis¹⁷ is suspected.

3. Step by step procedure

3.1 Orotracheal intubation

1. Assure adequate ventilation and oxygenation. Make sure suctioning equipment is immediately available in case the patient vomits.
2. Inflate the cuff of the endotracheal tube to ascertain that the balloon does not leak, and then deflate the cuff.
3. Connect the laryngoscope blade to the handle, and check the bulb for brightness
4. Have an assistant manually immobilize the head and neck. The patient's neck must not be hyperextended or hyperflexed during the procedure.
5. Hold the laryngoscope in the left hand (For left handed people the opposite is true).
6. Insert the laryngoscope into the right side of the patient's mouth, displacing the tongue to the left.
7. Visually examine the epiglottis and then the vocal cords.
8. Gently insert the endotracheal tube into the trachea without applying pressure on the teeth or oral tissues. The cuff should just disappear inferior to the vocal cords.
9. Inflate the cuff with enough air to provide an adequate seal. Do not overinflate the cuff.
10. Check the placement of the tube by auscultating the chest and abdomen with a stethoscope to ascertain tube position.
11. Visually observe lung expansion with ventilation.

12. Secure the tube. If the patient is moved, the tube placement should be reassessed.
13. If endotracheal intubation is not accomplished within seconds or in the same time required to hold your breath before exhaling, discontinue attempts, ventilate the patient with a bag-valve mask device, and try again later.
14. Placement of the tube must be assessed carefully. A chest X-ray may be helpful to assess the position of the tube, but it cannot exclude esophageal intubation.

3.2 Nasotracheal intubation

1. In suspected neck injury, leave the cervical collar in place to assist in maintaining immobilization of the neck.
2. Assure adequate ventilation and oxygenation.
3. Inflate the cuff of the endotracheal tube to ascertain that the balloon does not leak, and then deflate the cuff.
4. If the patient is conscious, spray the nasal passage with an anesthetic.
5. Have an assistant maintain manual immobilization of the head and neck.
6. Lubricate the nasotracheal tube and insert the tube into the nostril.
7. Guide the tube slowly but firmly into the nasal passage, straight posteriorly from the nostril and then backward and down into the nasopharynx. The curve of the tube should be aligned to facilitate passage along this curved course. The tube should not be directed superiorly, as expected from the external nasal anatomy, but rather straight posteriorly. The bevel of the tube should be placed to face the septum to avoid damage to the turbinates.
8. As the tube passes through the nose and into the nasopharynx, it must turn downward to pass through the oropharynx. This is the most painful part as the tube turns 90 degrees down the nasopharynx.
9. Proceed with the procedure as with an oro-tracheal intubation, guiding the tube through the vocal cords with a Magill's forceps. It may be necessary to apply pressure on the thyroid cartilage.
10. Inflate the cuff with enough air to provide an adequate seal. Avoid overinflation.
11. Check the placement of the tube by auscultating the chest and abdomen with a stethoscope to ascertain tube position.
12. Visually observe lung expansion with ventilation.
13. Secure the tube. If the patient is moved, the tube placement should be reassessed.
14. If endotracheal intubation is not accomplished within seconds or in the same time required to hold your breath before exhaling, discontinue attempts, ventilate the patient with a bag-valve mask device, and try again later.
15. Placement of the tube must be assessed carefully. A chest X-ray may be helpful to assess the position of the tube, but it cannot exclude esophageal intubation.

Danzl *et al*¹⁷ reports on successful translaryngeal anesthesia prior to nasotracheal intubation. During this technique topical anesthetic is injected through the cricothyroid membrane into the larynx. After aspirating air, 1.5-2.0 ml of 4% lignocaine is injected swiftly, usually causing a mild cough. Performing this technique before intubation facilitates passing a tube through the vocal cords. However, the major disadvantage of this procedure is the small time interval before intubation, where the protective reflexes

are depressed and resultant aspiration can occur¹⁷.

Advantages of nasotracheal intubation:

- The procedure minimizes neck movement and is reported by Danzl¹⁷ to be an alternative to cricothyroidotomy and tracheostomy where the X-ray status of the cervical spine is unknown in a trauma patient.
- The procedure does not require opening of the mouth and can therefore be performed in patients with temporomandibular joint dislocation and masseter spasm.
- It is suitable for patients with a short thick neck or other anatomical characteristics that would make orotracheal intubation difficult. Also where there is inability to properly align the oral-pharyngeal-laryngeal axis because of cervical spine anomalies, ankylosing spondylitis, obstructing inflammatory processes like Ludwig's angina and a paratonsillar abscess.
- It is possible to perform the procedure with the patient in a sitting position, advantageous in patients with severe congestive cardiac disease who cannot tolerate lying flat.
- The procedure can be performed blindly. In this case breathing sounds are used to guide the tube towards the vocal cords. If the breathing sounds diminish, the tube is deviating away from the glottis and if the sounds increase in loudness and clarity, the tube is moving closer to the glottic opening⁴⁰.

4. Materials

- Laryngoscope.
- Endotracheal tubes with high volume low-pressure balloon. Adult men: 7.5 to 9.0mm, women: 7.0 to 8.0 mm. For nasal intubation a slightly smaller tube is chosen.
- In children a formula of: tube size = $(4 + \text{age (years)})/4$, is used. Easier to assess using the width of the fingernail of the little finger of the child. Children under 8 years, are intubated with an uncuffed tube, therefore adequate tube size is essential to prevent aspiration.
- 20 cc syringe.
- Scissors.
- Magill's forceps.
- Suction.

Preintubation checklist in optimal circumstances:

- Monitors connected: Blood pressure, O₂ saturation, ECG

- IV Line connected
- Necessary drugs drawn up
- Bag-valve mask connected to oxygen source
- Stylet ready to be inserted in tracheal tube if necessary
- Check integrity of the balloon
- Have tape ready
- Check laryngoscope light
- Check oral suction device
- Remove patient's dentures
- Check optimal head positioning: neck slightly flexed, and head extended on the neck.

5. Anatomical pitfalls

5.1 Arytenoid cartilages²³

- These are paired cartilages forming the posterior aspect of the laryngeal inlet, articulating on the posterior shoulders of the cricoid cartilage.

5.2 Nasopharynx

- The nasopharynx extends from the posterior aspect of the nasal cavity to the soft palate. The nasotracheal tube is passed via the nasopharynx.

5.3 Oropharynx

- The oropharynx extends from the soft palate to the superior edge of the epiglottis.

5.4 Laryngopharynx

- The laryngopharynx extends from the epiglottis to the inferior border of the cricoid cartilage and proximal esophagus.

5.5 Vallecula

- The vallecula or pit is a space at the base of the tongue, bordered posteriorly by the epiglottis. The tip of the blade of the laryngoscope is inserted in this space to lift the tongue and epiglottis forward in order to visualize the vocal cords.

5.6 Laryngeal inlet

- The laryngeal inlet forms the opening to the larynx, bordered anterior and superior by the epiglottis, laterally by the aryepiglottic folds and posteriorly by the arytenoid cartilages.

5.7 Piriform fossae

- The piriform fossae are spaces on both sides of the laryngeal inlet, separated from the larynx by the quadrangular membranes.

5.8 Quadrangular membranes

- These membranes run from the lateral sides of the epiglottis to the arytenoid cartilages posteriorly, with the aryepiglottic fold as the superior free edge and the false vocal cords or vestibular folds as the inferior free edge. The aryepiglottic folds can close from both sides to protect the glottic inlet from foreign bodies. The aryepiglottic folds have both muscular and ligamentous components. The posterior part of each aryepiglottic fold are characterized by the presence of the corniculate and cuneiform cartilage. Closure of the aryepiglottic folds occurs under neural control³³.

5.9 Glottis

- The glottis constitutes the space between the vocal cords, both false and true as well as the glottic opening. It acts as a closed valve protecting against aspiration²⁶.

5.10 Nasal septum and cavity²⁶

- The nasal septum may be deviated, which may cause nasal obstruction, and complicate nasotracheal intubation.

5.11 Inferior turbinate (inferior concha)

- A nasotracheal tube passing the inferior turbinate may fracture the concha²⁶.

5.12 Pharynx²⁶

- The pharynx is a U-shaped fibromuscular tube extending from the base of the skull to the cricoid cartilage at the entrance of the esophagus.

5.13 Additional cartilages

- Corniculate cartilage. These cartilages are found in the posteromedial portion of the arytenoid cartilage just anterior to the arytenoid cartilages in the ary-epiglottic fold.
- Cuneiform cartilage. These cartilages form the anterolateral prominence of the arytenoid cartilage slightly anterior to the corniculate cartilage.

5.14 Anatomical factors predicting a difficult intubation¹:

5.14.1 Adults

It has been estimated that inability to successfully manage difficult airways, has been responsible for as many as 30% of deaths totally attributable to anesthesia²⁷. The following anatomical factors play a major role in difficult intubations:

- Prominent upper incisors.
- Limited ability to extend at the atlanto-occipital joint.
- Poor visibility of the pharyngeal structures with tongue extension (Mallampati classification⁴) and limited ability to open the mouth⁵.

Class 1 predicts an easy intubation and Class 4 a difficult intubation⁴.

Class 1: soft palate, uvula, fauces and tonsillar pillars visible.

Class 2: soft palate, uvula, fauces visible.

Class 3: soft palate, base of uvula visible.

Class 4: Only hard palate visible.

The classification is based on the clinical sign used to predict a difficult intubation, which is the concealment of the palatoglossal and palatopharyngeal arches as well as the uvula by the posterior third of the tongue, with it maximally protruded.

If the base of the tongue is disproportionately large, it overshadows the larynx as well as the faucal pillars and uvula, complicating visualization. Mallampati argues that because of the fact that it is impossible to measure the volume of the posterior third of the tongue, the size should be predicted by how much it masks other structures. The tongue is the single largest structure in the mouth affecting direct laryngoscopy.

- A short distance from the thyroid notch to the chin with the neck in extension. Matthew *et al*⁶ showed that patients with a thyromental distance < 6 cm (distance from the thyroid notch to the mental prominence with the neck extended) and a horizontal length of the mandible < 9 cm (distance from the angle of the mandible to the symphysis menti) showed a good correlation with Grade 3 and 4 according to the Mallampati classification⁴. Therefore, if present, intubation is likely to be difficult.
- A difficult intubation may also be expected if the distance from the anterior point of the chin to the hyoid bone in an adult is less than 3 fingerbreadths when the head is extended. Patients with a shortened distance may have a poorly developed mandible or a short thick neck. The larynx is then usually situated anteriorly, and one may need to use the straight laryngoscope blade as well as cricoid pressure.
- Previous surgery in the oral cavity, or any swelling, neck tumors, burns etc. that cause distortion of the anatomy and thus complicate intubation. Care should be taken in patients with tumors in the neck region, for it may point to a possible difficult

intubation. Wakeling *et al*²⁵ reported a case with large goiter, where the larynx was found to be pushed over to the other side.

- Patients with ankylosing spondylitis, Down's syndrome or a hypoplastic mandible are difficult to intubate due to neck rigidity and displacement of the tongue.
- Radiographic indicators for the ease of intubation include the mandibular length to height ratio² and the distance from the spinous process of the atlas to the occiput³. White and Kander²⁸ compared the lateral, postero-anterior and submentovertical skull radiographs of a group of patients where difficult laryngoscopy was experienced with a control group. The most significant factor for ease of direct laryngoscopy was the posterior depth of the mandible. This measurement was taken from the alveolus immediately behind the third molar tooth to the lower border of the mandible. An increase in this measurement is thought to hinder displacement of the soft tissues by the laryngoscope blade.

Van der Linde *et al*³⁸ showed in a similar study that a combination of anatomical factors determine the ease of intubation for e.g. the distance of the occiput to the spine of C1 and ratios expressed to either the maxillary length or effective mandibular length.

These are however of no use in the emergency situation.

- Benumof²⁷ elaborates on three extremely easy-to-perform, no-cost pre-intubation examinations, that predict subtle anatomic causes for intubation difficulty:
 - i) Relative tongue/pharyngeal size:** The size of the tongue relative to the oral cavity can be simply graded by looking into the patient's mouth. Grading is done according to Mallampati's classification⁴ earlier described.
 - ii) Atlanto-occipital joint extension** – It is known that flexion of the neck on the chest with extension of the head on the neck, brings the oral cavity, pharynx and larynx in a more straight line, which may ease intubation³⁰. The natural tendency to extend the neck actually makes intubation more difficult. No other study has however improved on Magill's³⁰ clear description. In this position less of the tongue will obscure the view of the larynx. Examination of the extent of this movement can be done at the bedside. Movement of 35 degrees of extension is usually possible. This examination is obviously absolutely contraindicated in the patient presenting in the emergency room with a suspected neck injury.
 - iii) Mandibular space** – This space is expressed as the distance from the hyoid bone or thyroid cartilage to the mandible, by means of fingerbreadths. This distance will determine how easily the larynx will fall in line with the pharyngeal axis when the atlanto-occipital joint is extended. A thyromental distance of more than 6 cm, strongly suggest that laryngoscopy will be relatively easy.

Benumof²⁷ recommends that all patients for elective intubation, should have these three anatomical points examined: the ability to open their mouth widely for

examination of oral cavity structures, size of the mandibular space and ability to extend the head with the neck held in flexion.

5.14.2 Children

Children have some anatomical factors which make intubation more difficult:

- Infants have a proportionately larger head, which naturally extends the head and flexes the neck. The head may be floppy and the larynx may be positioned posteriorly making visualization of the cords difficult. This may be overcome by putting a towel under their shoulders. The use of a pillow under the head to align the airway axes is not necessary and makes visualization of the glottis more difficult²⁶.
- Children have an increased tongue-to-oropharynx ratio, a shorter neck, which makes forward movement of the tongue more difficult, and a long U-shaped epiglottis, which makes visualization of the glottis difficult²⁶. These factors make the use of a straight blade necessary.
- The infant's larynx is situated higher and more anterior (level of C2, C3, compared to the C4-C6 level of the adult)²⁶.
- The vocal cords are concave upwards, with the anterior attachment lower than the posterior. This may effect ventilation. The vocal cords of an adult are horizontal²⁶.
- The relatively short trachea in children increases the risk of primary bronchus intubation. This may be prevented by following the formula for correct placement in children: $\text{Depth (cm)} = \text{age}/2 + 12$ ²⁶.
- The airway diameter is smaller and is smallest at the cricoid ring. Therefore, trauma with the laryngoscope and tubes is a risk. Cricoid pressure may cause complete airway obstruction and an endotracheal tube may be able to pass through the vocal cords, but not the cricoid cartilage ring just inferior to the level of the vocal cords. If this happens, the next smaller tube should be used²⁶.
- Children have a smaller residual lung capacity. Therefore they can become hypoxic more rapidly than an adult. Prolonged periods without ventilation should therefore be avoided.
- Teeth in children are easily knocked out and aspirated.
- Children have large palatine and pharyngeal tonsils (adenoids). These structures may obscure visualization of the vocal cords and when performing a nasotracheal intubation cause excessive bleeding, with possible airway obstruction²⁶.

5.15 Superior laryngeal nerve

- The superior laryngeal nerve is a branch from the vagus nerves and divides into an internal and external branch. The external branch supplies the cricothyroid muscles and the internal branch pierces the thyrohyoid membrane and innervates the laryngeal mucosa from the upper surface of the vocal folds to the base of the tongue. The superior laryngeal nerve can be anesthetized to perform intubation while the patient is awake. During this procedure, anesthetic solution is injected midway between the thyroid cartilage and hyoid bone, deep to the thyrohyoid membrane into the paraglottic space³². The disadvantage of this procedure is the unprotected airway from the time of injection until intubation has been successfully completed.

5.16 Trachea

- The average adult trachea has an external diameter of 20mm and length of 11cm. Whiffler *et al*³⁷ measured the transverse tracheal diameter of the tracheal air space on 200 postero-anterior chest X-rays. The average measurement of this internal diameter was 17 mm.

6. Complications (anatomically relevant)

6.1 Inability to visualize the vocal cords

- Cormack *et al*⁵ reports three main factors contributing to a difficult intubation:
 - a) Forward displacement of the larynx
 - b) Forward displacement of the teeth
 - c) Backward displacement of the tongue.This may be the case in the absence of any pathology, due to a normal anatomical variation.
- May be due to **incorrect initial placement** of the laryngoscope blade. The blade should slide alongside the right side of the tongue, therefore displacing the tongue to the left side. If the blade is placed initially over the middle of the tongue, the tongue will fold over the lateral edges of the tongue and obscure the airway.
- The **laryngeal aperture** may be seen in different grades, as discussed by Benumof²⁷. Grade 1 is the visualization of the entire laryngeal aperture, Grade 2 only the posterior portion of the aperture is seen, Grade 3 is visualization of only the epiglottis and grade 4 the visualization of only the soft palate. The grade 3 and 4 views will often lead to an impossible intubation. The incidence of a grade 3 laryngoscopic view is 1-4% and that of grade four 0.05 to 0.35 %²⁷.
- After the blade of the laryngoscope has reached the posterior one third of the tongue, sliding into the vallecula, the laryngoscope should be lifted upward and forward at a 45-degree angle. The epiglottis should become visible and continuation of anterior elevation will expose the vocal cords. Bending of the operator's wrist may lead to dental injury.

- If the blade tip is pushed too deeply into the vallecula, the epiglottis is pushed down and obscures the laryngeal inlet⁴.
- When using a straight blade, the tip of the blade is placed posterior and slightly beyond the epiglottis, thus directly lifting it anteriorly. Too deep placement may result in the entire larynx being lifted anteriorly and thus out of the field of vision.
- Head positioning - The extended head, with the neck flexed, allows for the shortest distance and straightest line between the teeth and the vocal cords. The line from the upper incisors through the pharynx to the larynx is almost a straight line. By flexing the neck and extending the head, this line is converted to a straight line³⁸. In suspected neck injuries this position is absolutely contraindicated. Alexopoulos *et al*²⁴ has demonstrated that extension of the head does not necessarily make intubation easier, and one should be aware of restricting circulation through the vertebral arteries to the brain in patients already having some circulatory impairment by hyperextending the head.
- Difficult intubations in obstetric care are more common, due to the more frequent grade 3 airway, in which the epiglottis can be visualized, but not the vocal cords⁵. The laryngoscope blade tends to depress the epiglottis and therefore hide the vocal cords.
- Cricoid pressure – This maneuver, called Sellick's maneuver, is done to displace the larynx posteriorly in order to visualize the vocal cords. This maneuver should always be used to intubate obstetric patients to prevent regurgitation of stomach content and to stabilize the larynx³⁹.

6.2 Esophageal intubation

- The only way to prevent esophageal intubation is to ensure that the tube is seen passing through the vocal cords^{20,26}.
- Absent or diminished breathing sounds, vocalization, increased abdominal size and gurgling sounds over the epigastrium, are clinical signs of esophageal placement.
- The problem is that esophageal placement is not always obvious. Normal breathing sounds may be heard in the midline. Therefore auscultation of both lung fields in the lateral axillary line is mandatory³⁴.
- Fog formation inside the tube with each breath, suggests correct endotracheal placement.
- Observation of chest rise and fall with positive pressure ventilation also suggests correct endotracheal placement.
- Correct placement can also be assessed by means of a fiberoptic scope. The fiberoptic scope may be passed down the endotracheal tube. Visualization of the tracheal

cartilage rings confirms correct placement as well as placement within the trachea.

6.3 Too deep placement

- A major complication of endotracheal intubation is accidental migration of the tip of the endotracheal tube into a primary bronchus²⁰. This may lead to hypoxemia and collapse of the contralateral lung with possible resultant tension pneumothorax.
- Asymmetrical breathing sounds, suggest a primary bronchus intubation: the tube has been inserted too deeply. Most frequently the right primary bronchus is intubated due to its vertical alignment with the trachea, wider diameter and shorter length when compared with the left primary bronchus²⁶. The cuff should be deflated and the tube withdrawn until equal breath sounds are present.
- Bloch *et al*¹³ reports correct tube placement in children as follows: After hearing equal breathing sounds in both lungs, the tube is withdrawn 2 cm in children under 5 years, and 3 cm in older children.
- After the cuff has passed through the vocal cords, it should not be advanced more than 3 cm. The tip of the tube should desirably lie between 3 and 7 cm above the carina, according to Conrardy *et al*⁸.
- Owen *et al*¹² reported in a study involving more than 500 patients the following lengths, representing the distance between the tip of the tube to the upper incisors in adults of average size:
Tracheal tube depth (cm) = 21 cm in females.
Tracheal tube depth (cm) = 23 cm in males.
Owen *et al*¹² reported that the measurement of the tube beforehand, to be more reliable than auscultation to determine the correct position of placement.
- Reed *et al*¹⁵ reported the optimum distance from the external nose to the tip of the nasotracheal tube to be about 28 cm in males and 26 cm in females. This is to ensure adequate positioning of the tip of the tube being at least 2cm above the carina.
- Auscultation is essential, not only anteriorly but also laterally for the right middle lobe and lingula on the left. Midline auscultation only may lead to an erroneous impression of tracheal placement when the tube is actually in the esophagus.
- Radiographic confirmation

- **Adults**

On a radiograph, the tip of the endotracheal tube should ideally be 5 cm \pm 2 cm above the carina in a neutral head and neck position. The carina overlies the 4th, 5th or 6th thoracic vertebral body.

The carina is situated more superior in children, consistently aligned between the

3rd and 5th thoracic vertebral body.

- **Children**

Blayney and Logan⁹ reported that T1 is the sole best reference point to be used to assess the tip of the endotracheal tube in children. The tip of the tube should not lie below T1 vertebral body. Previously the medial ends of the clavicles were used to determine correct placement, but the position of the clavicles is highly variable. Cole¹⁰ and Morgan *et al*¹¹ developed a formula to determine the proper depth of tube placement with lengths representing the distance from the tube tip to the upper incisors in children. Tracheal tube depth (cm) = age (years)/2 + 12.

Kuhns *et al*³⁵ proposes that a 9-cm distance should be marked on the operator's index finger for tube length of infants. For 1-year old infants 2 cm should be added and for very small infants 2 cm should be subtracted. This method is more practical in the emergency situation where formulae are impractical. The average length of the infant's trachea is 5.7 cm.

6.4 Cervical strain

- Cervical strain, subluxation/ dislocation of cervical vertebrae may occur. This is especially the case in the emergency patient and patients with rheumatoid arthritis^{20,26}.

6.5 Aspiration

6.5.1 Aspiration of gastric content

- Cricoid pressure or Sellick's maneuver³⁹ is essential for all emergency intubations, including general anesthesia for emergency procedures and obstetric procedures to help prevent gastric content from entering the airways.

6.5.2 Aspiration on extubation

- Before extubation, a substantial amount of fluid may accumulate above the cuffed endotracheal tube, which may consist of secretions, blood or gastric contents. This must be aspirated before extubation. To prevent this, proper suction is necessary before extubation, a cuffed endotracheal tube with the largest diameter for the individual patient should be used to reduce dead space above the cuff, and a gauze pack can be used in the laryngopharynx³⁶.

6.6 Oral cavity injury

- Soft tissue injury of the oral cavity resulting in abrasion and hemorrhage, which may involve the lips, tongue, soft and hard palate, buccal mucosa and pharynx^{20,27}.

6.7 Vocal cords

- Spasm, avulsion and laceration may occur due to the passing of the endotracheal tube. Laryngeal injury is however very rare²⁶.
- Pediatric patients are far more prone to laryngospasm⁷. This occurs when the vocal cords are stimulated, e.g. when touching them with the endotracheal tube. Consequently the adductors of the cords contract, which may prevent passing of the tube. The tube should not be forced, due to possible permanent damage to the cords.
- Laryngospasm usually occurs due to inadequate anesthesia. If laryngospasm is prolonged a muscle relaxant may be necessary.

6.8 Piriform fossae

- These fossae may be perforated resulting in a pneumothorax and pneumomediastinum²⁶.
- Injury to upper airway structures greatly increases in the case of a difficult intubation. Benumof²⁷ stated that in patients where multiple attempts at laryngoscopy were made, the incidence of upper airway complications increased dramatically.

6.9 Malpositioning of the tube due to head movement

- Conrardy *et al*⁸ has shown in a controlled study that the endotracheal tube moves on average 1.9 cm towards the carina with flexion of the neck and 1.9 cm away from the carina with extension. It moves 0.7 cm away from the carina with lateral head rotation. Therefore head movement may lead to inadvertent extubation or endobronchial intubation.
- Bosman *et al*³⁴ documented that head movement in infants is an important factor of both malpositioning and displacement of the endotracheal tube. This may be both endobronchial intubation and accidental extubation. The reason for this is the short distance of the glottis to the carina in infants. It is not less than 4cm and movement not greater than 1,8cm. Therefore, Bosman *et al*³⁴ advises to mark the tube in adults 22 cm from the tip, and to fix the tube when this mark has reached the vocal cords. Fixation of the tube to the lower lip, rather than the upper lip is advised.

6.10 Cardiovascular

- The laryngeal reflex is perhaps the body's most potent reflex. Endotracheal intubation, which involves the advancing of a foreign body through the larynx, may evoke either a sympathetic (usually) or parasympathetic (more often in younger patients) reflex^{20,26}.

- Sympathetic – The sympathetic reflex usually results in hypertension, dysrhythmia and tachycardia. Cerebral hemorrhage, left ventricular failure and cardiac ischemia or arrhythmias have been reported¹⁷.
- Parasympathetic – The parasympathetic reflex usually involves a bradycardia and even asystole. This is due to pharyngeal and laryngeal stimulation (pharyngeal plexus of which the vagus nerve forms part). Prolonged pharyngeal stimulation may also result in laryngospasm, bronchospasm and apnea.

6.11 Dental injury

- Loose teeth may be aspirated²⁷. Therefore an avulsed tooth not found in the oral cavity makes a chest X-ray necessary. McGovern *et al*¹⁴ found broken teeth to be the most common complication of laryngoscopy.

6.12 Injury to the arytenoid cartilages

- Dislocation and avulsion of these cartilages may occur²⁶. This may cause impaired movement of the cricoarytenoid joint with hoarseness and immobility of the vocal ligament after endotracheal intubation. Paulsen *et al*²³ demonstrated in 30 unfixed cadaver larynges, that intubation trauma may damage the cricoarytenoid joint, especially the large synovial fold, which after hemarthrosis of the joint may lead to cricoarytenoid joint dysfunction. Anatomically the cricoarytenoid joint is a diarthrodial joint supported by a wide joint capsule lined with synovial membrane and a strong posterior cricoarytenoid ligament. The joint allows two principle types of motion: A rotating movement around the axis of the joint, and a linear glide on the shoulders of the cricoid cartilage. This allows for abduction, adduction and changing the length of the vocal cords. Damage to the cricoarytenoid joint may consequently lead to vocal fold immobility and hoarseness. Care should be taken, not to damage the laryngeal inlet with the endotracheal tube or laryngoscope when intubating.

6.13 Rupture of the trachea

- Although rare, reckless movement of intubated patients may cause rupture of the trachea in its membranous part, which is susceptible to tearing in the elderly²⁰. This may be caused by overinflation of the tube, for the pilot balloon does not accurately reflect the degree of tube inflation. Signs and symptoms pointing to this complication are subcutaneous and mediastinal emphysema, dyspnoea and hemoptysis³⁶.

6.14 Dysphonia and aphonia (traumatic laryngitis)

- This is found in up to 50% of intubated patients. The reason for this is temporarily epiglottic and arytenoid edema²⁰.

6.15 Subglottic edema and stenosis

- This is especially dangerous in children. Due to the relatively small internal cross section of the larynx in children, minor swelling of the mucosal layer can cause airway obstruction²⁰. This is more dangerous in the subglottic region, where the cricoid forms a circumferential ring of cartilage and forms the narrowest part of the airway.
- Children have a higher risk of developing subglottic stenosis compared to adults³¹.
- Subglottic stenosis develops due to pressure from the airway to the loose connective tissue and submucous blood vessels against the nonresilient cartilage. This may cause edema and necrosis, leading to scarring³¹.
- The main reasons for subglottic stenosis are too large a size of airway tubes, traumatic technique and prolonged intubation.
- Most pressure is exerted on the cricoid lamina in an intubated patient positioned with the head bent backward. This pushes the cricoid lamina against the tube.

6.16 Laryngeal granulomas, polyps and ulcers.

- These laryngeal conditions may develop after endotracheal intubation¹⁷. Patients present with hoarseness, and a sore throat²⁰.

6.17 Paresis of the hypoglossal and or lingual nerves

- Blanc²⁰ points to this possibility due to pressure of a laryngoscope blade in the retrolingual region.

6.18 Specific complications related to nasotracheal intubation

Danzl *et al*¹⁷ reports a complication rate of 3% for nasotracheal intubation. It is an easily mastered skill with a low complication rate.

6.18.1 Nasal injury

- Mild to moderate bleeding is the most common complication¹⁸.
- Epistaxis – Danzl *et al*¹⁷ reports that severe epistaxis was encountered in only 5 of 300 cases. Four required pharyngeal suctioning. Tintinalli *et al*¹⁸ reported 1 case of severe epistaxis in 71 patients and less serious bleeding in 12 others.
- Nasal septum injury occurred when too much force was applied¹⁸.
- Other complications as described by Taryle *et al*¹⁹ and Blanc *et al*²⁰ are the following: concha fracture, intracranial placement through skull base fracture and retropharyngeal laceration or dissection.
- Brodman *et al*²⁹ has reported on a method to pass the endotracheal tube through the

nose with minimal damage. A suction catheter is placed through the endotracheal tube and being soft, thin and pliable, easily moves through the nasopharyngeal curve into the nasopharynx. The endotracheal tube is then threaded over the catheter. After reaching the oropharynx the catheter is removed and the endotracheal tube inserted through the vocal cords under direct vision. They have not experienced epistaxis and other injury to the nasal cavity.

6.18.2 Misplacement of the tube in blind intubation:

- Van Elstraete¹⁶ reported a less than 50% success rate of blind nasotracheal tube placement within the first attempt in the operating room. Four potential locations may then be considered for the tip of the tube to lie: 1) in the vallecula, 2) on the arytenoid cartilage or vocal cord, 3) in the piriform fossae and 4) in the esophagus.
- In blind nasotracheal intubation, breathing sounds are used to guide the tube towards the vocal cords. If the breathing sounds diminish, the tube is deviating away from the glottis and if the sounds increase in loudness and clarity, the tube is moving closer to the glottic opening. By listening carefully at the proximal end of the tube, the tube can be rotated to the point where the breathing sounds are heard loudest. At this point the tube can be inserted through the vocal cords during inspiration⁴⁰.

6.18.3 Sinusitis

- Sinusitis²⁰ is a frequent complication and may be an unrecognized source of sepsis as reported by Deutschman *et al*²¹. They report on paranasal sinusitis secondary to prolonged nasotracheal intubation. The diagnosis should be suspected in case of sepsis of undetermined origin. The major factor in precipitating sinusitis is the blockage of sinus outflow via the nasal openings. Simply moving the tube to the oral route or performing a tracheostomy seems to solve the problem²¹. In addition to the maxillary sinus draining into the middle meatus at the semilunar hiatus²⁶, all the sinuses drain into the nasal cavity.

6.18.4 Mediastinitis

- Seaman *et al*²² reports on a rare complication of mediastinitis following a retropharyngeal abscess due to nasotracheal intubation. The abscess dissected into the mediastinum through the retrovisceral space. A retropharyngeal abscess should be considered a medical emergency¹⁸.

6.18.5 Damage to the tube cuff with the Magill forceps.

6.18.6 Intracranial penetration

- Several cases have been reported associated with attempted blind nasotracheal intubation¹⁷. It is therefore a contraindication to intubate a patient via the nasal route in a suspected head injury.

6.18.7 Transient bacteremia

- Patients with known heart valve lesions need to be given prophylactic antibiotics¹⁷.

6.18.8 Otitis media

- This may occur during prolonged intubation especially in neonates and resultant obstruction of the opening of the auditory tube¹⁷.

6.18.9 Retropharyngeal laceration

- Retropharyngeal laceration and subsequent dissection is rare. This space is bordered, anteriorly by the pharyngeal wall, prevertebral fascia and carotid sheath. It extends from the skull base down to the posterior mediastinum.
- Loss of flow of air from the tube, once the tube has passed the turbinates, indicates that the tip of the tube is abutting the pharyngeal mucosa. Slight pressure at this point may lead to retropharyngeal perforation. A suspicion of the occurrence of this complication is important.

7. References

Papers

- ¹ Whitten CE. Preintubation evaluation: Predicting the difficult airway. *Emerg Med* 1989;21:111
- ² White A, Kander PL. Anatomical factors in difficult direct laryngoscopy. *Br J Anaesth* 1975;47:468
- ³ Cass NM, James NR, Lines V. Difficult direct laryngoscopy complicating intubation for anaesthesia. *Br Med J* 1956;1:488
- ⁴ Mallampati SR, Gatt SP, Gugino LD. A clinical sign to predict difficult tracheal intubation: A prospective study. *Can J Anaesth* 1985;32:429
- ⁵ Cormack RS, Lehane J. Difficult tracheal intubation in obstetrics. *Anaesthesia*. 1984;39:1105
- ⁶ Matthew M, Hanna LS, Aldrete JA. Pre-operative indices to anticipate difficult tracheal intubation. *Anaesth Analg* 1989;68:S187
- ⁷ Roy WL, Lerman J. Laryngospasm in paediatric anaesthesia. *Can J Anaesth* 1988;35:93
- ⁸ Conrardy PA, Goodman LR, Laing F et al. Alteration of endotracheal tube position. *Crit Care Med* 1976;4:8
- ⁹ Blayne MP, Logan DR. First thoracic vertebra body as reference for endotracheal tube placement. *Arch Dis Child* 1994;71:F32
- ¹⁰ Cole F. Pediatric formulas for the anesthesiologist. *Am J Dis Child* 1957;94:472
- ¹¹ Morgan GAR, Steward DJ. Linear airway dimensions in children: Including those with cleft palate. *Can Anaesth Soc J* 1982;29:1
- ¹² Owen RL, Cheney FW. Endobronchial intubation: a preventable complication.

Anesthesiology 1987;67:255

- ¹³ Bloch EC, Ossey K, Ginsberg B. Tracheal intubation in children: A new method for assuring correct depth of tube placement. *Anesth Analg* 1988;67:590
- ¹⁴ McGovern FH, Fitz-Hugh GS, Edzeman LJ. The hazards of endotracheal intubation. *Ann Otol Rhinol Laryngol* 1971;80:556
- ¹⁵ Reed DB, Clinton JE. Predicting optimal depth of nasotracheal intubation prior to chest x-ray (abstract). *Acad Emerg Med* 1996;3:526
- ¹⁶ Van Elstraete AC, Pennant JH, Gajraj NM et al. Tracheal tube cuff inflation as an aid to blind nasotracheal intubation. *Br J Anaesth* 1993;70:691
- ¹⁷ Danzl DF, Thomas DM. Nasotracheal intubation in the emergency department. *Crit Care Med* 1980;8:677
- ¹⁸ Tintanelli JE, Claffey J. Complications of nasotracheal intubation. *Ann Emerg Med* 1981;10:142
- ¹⁹ Taryle DA, Chandler JG, Good JT et al. Emergency room intubations: Complications and survival. *Chest* 1979;75:541
- ²⁰ Blanc VF, Tremblay NA. The complications of tracheal intubation: A new classification with a review of the literature. *Anesth Analg* 1974;53:202
- ²¹ Deutschman CS, Wilton P, Sinow J et al. Paranasal sinusitis associated with nasotracheal intubation: A frequently unrecognized and treatable source of sepsis. *Crit Care Med* 1986;14:111
- ²² Seaman M, Ballinger P, Sturgill TD et al. Mediastinitis following nasal intubation in the emergency department. *Am J Emerg Med* 1991;9:37
- ²³ Paulsen FP, Jungmann K, Tillmann BN. The cricoarytenoid joint capsule and its relevance to endotracheal intubation. *Anesth Analg* 2000;90(1):180-185
- ²⁴ Alexopoulos C, Larsson SG, Lindholm CE. The anatomical shape of the airway during endotracheal intubation. *Acta Anaesthesiol Scand* 1983;27(4):331-334
- ²⁵ Wakeling HG, Ody A, Ball A. Large goitre causing difficult intubation and failure to intubate using the intubating laryngeal mask airway: lessons for the next time. *Br J Anaesth* 1998;81:979-981
- ²⁶ Morris IR. Functional anatomy of the upper airway. Review. *Emergency Medicine Clinics of North America* 1988 Nov;6(4):639-69
- ²⁷ Benumof JL. Management of the difficult airway. *Anesthesiol* 1991;75:1087-1110
- ²⁸ White A, Kander PL. Anatomical factors in difficult direct laryngoscopy. *Br J Anaesth* 1975, 47: 468
- ²⁹ Brodman E, Duncalf D. Avoiding the trauma of nasotracheal intubation (letter). *Anesth and Analg* 1981;60:618
- ³⁰ Magill IW. Technique in endotracheal anaesthesia. *BMJ* 1930;2:817-20
- ³¹ Reidenbach MM, Schmidt HM. Anatomical aspects of postintubational subglottic stenosis. *Clin Anat* 1995;8:273-280
- ³² Stockwell M, Lozanoff S, Lang SA, Nyssen J. Superior laryngeal nerve block: An anatomical study. *Clin Anat* 1995;8:89-95
- ³³ Reidenbach MM. Aryepiglottic fold: Normal topography and clinical implications. *Clin Anat* 1998;11:223-235
- ³⁴ Bosman YK, Foster PA. Endotracheal intubation and head posture in infants. *S Afr Med J* 1977;52:71-73
- ³⁵ Kuhns LR, Poznanski AK. Endotracheal tube position in the infant. *J Pediatr*

1971;78:991-6

³⁶ Moar JJ, Acafrao EMM, Ninin DT. Tracheal rupture – an anaesthetic mishap? S Afr Med J 1986;69:312-314

³⁷ Whiffler K, Andrew WK, Thomas RG. The hazardous cuffed endotracheal tube – aspiration and extubation. S Afr Med J 1982;61:240-241

³⁸ Van der Linde JC, Roelofse JA, Steenkamp EC. Anatomical factors relating to difficult intubation. S Afr Med J 1983;63:976-977

³⁹ Sellick BA. Cricoid pressure to control regurgitation of stomach contents during induction of anaesthesia. Lancet 1961; 2: 404-406

⁴⁰ Cullen DJ. Nasoendotracheal intubation. In: MGH textbook of emergency medicine. Wilkins EW, Dineen JJ, Moncure AC, Gross PL. 2nd Ed. Baltimore, London: Williams & Wilkins, 1983:914-919

Books

American College of Surgeons, Committee on Trauma. Advanced Trauma Life Support Course for Physicians Student Manual. Chicago: American College of Surgeons, 1993: 47-68

VanderSalm TJ, Cutler BS, Wheeler HB. Atlas of Bedside Procedures. Boston(Mass): Little Brown, 1979:159-168

Abrahams PH, Webb P. Clinical anatomy of Practical procedures. London: Pitman Medical, 1975: 50-54

Scarpinato L. Endotracheal intubation. In: Procedures for primary care physicians. Pfenninger JL, Grant CF. St Louis London: Mosby, 1994: 452-463

McGill JW, Clinton JE. Tracheal intubation. In: Clinical procedures in emergency medicine. Roberts JR, Hedges JR. Philadelphia; London: Saunders 3rd ed, 1998

4.4.1.3 Lumbar puncture

1. Indications	113
2. Contraindications	114
3. Step by step procedure	114
4. Materials	116
5. Anatomical pitfalls	117
6. Complications (anatomically relevant)	120
7. References	126

1. Indications

1.1 Diagnostic

- Suspected central nervous system (CNS) infection.
 - High index of suspicion in infants younger than 12 months of age, they may have no meningeal signs or even fever. Most common signs in a child between 3 months and 3 years: irritability and vomiting, uncomfortable fever of unknown origin, alteration in consciousness and meningeal signs
 - Patients with AIDS infection with unusual organisms like Cryptococcus, Toxoplasma and Listeria, and a fever of unknown origin.
- Possibility of CNS infection with the exception of brain abscess.
- Suspected spontaneous subarachnoid bleeding – Finding blood in the cerebrospinal fluid (CSF).
CT scan is the first line investigation and not lumbar puncture²¹. If the scan is negative a lumbar puncture is necessary to examine the CSF.
- Neoplasia – diagnostic cells may be found in patients with leukemia or carcinomatous meningitis.
- Performance of a myelogram by introducing contrast fluid (Nowadays since MRI seldomly performed).
- Diagnosis of Guillain-Barré syndrome or multiple sclerosis.
- Despite the redundancy of lumbar puncture since the emergence of CT and MRI, suspected purulent or viral meningitis is still an indication for lumbar puncture¹².

1.2 Therapeutic

- Spinal anesthesia: intrathecal or epidural.

- Chemotherapy and palliative pain management – drugs may be administered via the epidural or spinal route.

2. Contraindications

- Raised intracranial pressure from a space-occupying lesion. Especially in the case of a brain abscess. Caution should be taken when signs of herniation are present, for example a unilateral third nerve palsy with altered level of consciousness. Tentorial or cerebellar coning may be precipitated. It is important to examine the fundi to establish the presence of papilloedema before performing a lumbar puncture. If present a lumbar puncture should be avoided. A careful history and clinical examination should provide adequate information whether increased intracranial pressure is present or not³².
- Absolutely contraindicated in patients with infection near the site of insertion.
- Coagulopathies, unless essential when platelet infusion should be given beforehand.
- Spinal cord compression. Removal of CSF in this situation may drastically alter fluid dynamics and may impair bladder function³².

3. Step by step procedure

3.1 Position: Lateral recumbent position:

The patient should be positioned in the lateral recumbent position with the back flexed as far as possible. Ask the patient to try to touch the flexed knees with his/her chin²⁶. One pillow under the head and one between the knees for support. Neck maximally flexed. There is no need for the patient's knees and neck to be forcibly flexed. The back should be at right angles to the floor with one hip exactly above the other. The needle is passed horizontal to the floor. This ensures that the needle stays in the midline³³.

Upright position:

The patient is seated with the neck and back fully flexed. Flexion facilitates the course of the needle through the widened gaps between adjacent lumbar spinous processes.

3.2 Wash hands

3.3 Clean skin – Prepare the area with an antiseptic solution.

3.4 Determine site of insertion: A line joining the posterior superior iliac crests (most cephalad part of both iliac crests) will intersect the midline at L4/L5 interspace (Tuffier's

line)^{15,26}. The space above L4 is therefore L3/L4 and below L4/L5. Both these spaces are below the termination of the spinal cord at L1/L2 in the majority of adults²⁶. In a small percentage of people, the spinal cord may extend down to L2/L3. The exact space used influences the segmental anesthetic level.

3.5 Infiltrate skin and deeper subcutaneous tissue with anesthetic solution – Solution may also be deposited in the area of the interspinous ligament and even deeper in a vertically fanning distribution on both sides of the spinous process. This anesthetizes the recurrent spinal nerves innervating the muscle and interspinous ligament.

3.6 Insertion of needle:

- i) Use index and thumb to hold the skin taut, push the lumbar needle through the skin, exactly in the midline²⁶.
- ii) The puncture may be performed through the L3-4 or L4-5 interspace in adults.
Insert the needle at the superior aspect of the spinous process that lies inferior to the space to be entered. Aim for the umbilicus (15 degrees cephalad) if the L4/5 interspace is used¹⁹. The spinal cord ends at L3 in children. Therefore it is recommended that L4/5 or L5/S1 is used in children.
- iii) The bevel should be in the sagittal plane so as not to cut the longitudinal fibres of the dura mater, diminishing injury to the dura mater by separating the fibres of the dura, rather than cutting through them. This will reduce leakage of CSF.
- iv) Pass the needle through the supraspinous ligament, which connects the spinous processes and the interspinous ligaments which connect adjacent borders of spinous processes.
- v) Pass the needle through the ligamentum flavum – feel a ‘pop’ as it is penetrated. In older patients the ligament may provide significant resistance since it is often calcified. The resistance of the ligamentum flavum is felt at a depth of 4-7 cm.
- vi) After entering the ligamentum flavum, remove the stylet at each 2mm interval of needle advancement to check for flow of CSF.
- vii) A second ‘pop’ represents penetration through the dura mater into the subarachnoid space.
If bone is encountered – withdraw the needle partially to the subcutaneous tissue. Repalpate the back to make sure the needle is in the midline. If bone is encountered again, slightly withdraw the needle and re-angle with point angling more superiorly.

- viii). Clear fluid will appear if the subarachnoid space is penetrated. If not, it is worth rotating the needle through 90 degrees as the opening at the end of the needle may be obstructed by a nerve root³².
- ix). The subarachnoid space will be entered well below the spinal cord. The needle will push isolated nerves of the cauda equina to the side during advancement.

3.7 Connect the manometer and read the pressure while holding the manometer tube perpendicular to the spinal needle. A normal value for a relaxed patient is 80-200 mm CSF. This can be slightly higher in an anxious patient, but values above 200mmCSF are abnormal. Manometer readings can only be performed in the lateral decubitus position. The zero-mark is at the level of the spinal needle.

3.8 Caveat: Do not have more than 3 attempts in any single interspace before either obtaining assistance from a senior colleague or proceeding to another interspace. Never try to aspirate CSF. This may have serious neurological consequences³².

3.9 Removal of the spinal needle. It has been said that reinserting the stylet before needle removal helps prevent post spinal headache. This reduces the risk that a frond of arachnoid will be pulled out and prevent closure of the dural puncture defect¹⁹.

Alternative method: Lateral approach

This method may be used in case of calcification of the supraspinous ligament in older persons, complicating a midline approach. The needle is inserted in the paramedian line and is angled horizontally and not towards the umbilicus.

The needle passes through skin, superficial fascia, fat and dense posterior layer of the thoracolumbar fascia and erector spinae muscles, ligamentum flavum, epidural space, dura and enters the subarachnoid space.

In this way the supraspinous and interspinous ligaments are bypassed.

4. Materials

- Sterile gloves.
- Antiseptic solution.
- Skin-marker pen.
- Spinal needle (atraumatic needle 20-gage needle in adults, 22-gage or smaller in children).
- Three way stopcock, manometer.
- 4 specimen tubes.
- Local anesthetic solution and needles.
- Sterile drapes.

5. Anatomical pitfalls

5.1 Needle pierces in order:

- Skin, subcutaneous tissue, supraspinous ligament, interspinous ligament, ligamentum flavum, epidural space with posterior intervertebral venous plexus, dura, arachnoid and eventually the subarachnoid space.

5.2 Lumbar vertebra

- Spinous process, lamina, superior articular process, inferior articular process, lamina and facet joint. The needle may be stopped by these bony structures if the needle is not placed exactly in the midline. The spinous processes of lumbar vertebrae project horizontally backwards, in contrast to those in the thoracic vertebrae.

5.3 Tuffier's line¹⁵:

- A line joining the posterior superior iliac crests (most cephalad part of both iliac crests) will intersect the midline at L4/L5 interspace.

5.4 Lumbar lordosis¹⁹

- The normal lumbar lordosis narrows the interspace between adjacent spinous processes and laminae. To overcome this the patient is positioned in a fetal-like position with the hips and knees flexed as well as the vertebral column. In the sitting position the patient leans forward with the head flexed. These positions open up the interspaces between the spinous processes and laminae to facilitate spinal needle advancement.

5.5 External vertebral venous plexus

- The posterior part of the external vertebral venous plexus is located in the epidural space and may be involved in a bloody tap. The internal vertebral venous plexus forms a ring around the cord.

5.6 Nuchal rigidity

- This sign is seen in children older than 3 years and involves the posterior group of longitudinal neck muscles. This sign is distinguished from primary pain in the cervical muscles by the usual preservation of lateral movement in meningeal irritation.

5.7 End of spinal cord

- **Adults:** The vertebral level at which the spinal cord terminates varies widely from T12 to L3/L4 intervertebral disc²⁴. The spinal cord extends to the L1-2

disc in 51% of people and to the L2-3 disc or below in 12%¹⁵. Reimann *et al*²⁴ studied the termination of the spinal cord in 129 cadavers which became the standard reference for the vertebral level of the termination of the spinal cord: The mean level of the spinal cord lies opposite the disc between the first and second lumbar vertebra. One sacral cord is described by Reimann *et al*²⁴. In a recent MRI study including 136 adult scans, MacDonald *et al*²⁸ showed that the median level of termination of the spinal cord for both males and females was the middle one-third of the first lumbar vertebra, a higher level than usually stated. This ranged from the middle one-third of T11 to the middle one-third of L3. It is important to note that only 25% of cords ended below the disc between L1 and L2, compared to the 49% of cords below this level in the cadaver study done by Reimann²⁴. Due to the great enhancement of the understanding of human anatomy by MRI, and the problems of shrinkage and as most cadavers are those of elderly patients, this new modality is widely recognized as the gold standard for demonstrating the anatomy of the lumbosacral region. The advantages of MRI are the fact that the anatomy of live healthy subjects can be studied, the age range is wider and the spinal cord can be studied in the supine position²⁸.

- Puncture may be performed from L3/L4 interspace to L4/L5 interspace²⁷. The conus medullaris can be as low as L2 and L3, even as far as midway along the body of L3. Therefore it is recommended that the L3/4 or L4/5 interspace are used as the entry site¹⁹.
- **Infants:** The spinal cord ends at L3. Needle placement should therefore be at L4/5 or L5/S1.

The differences in adults and children are due to longitudinal growth of the spinal canal and cord growth not keeping up to this.

5.8 Height of anesthesia

- The height of anesthesia is related to the level of lumbar puncture. An anesthetic level as high as T1 may be reached with intradural anesthesia where the L2-3 interspace is used, but only up to T6 when performed at L4-5 level²⁵.

5.9 Meninges

- **Dura mater** – The dura mater lines the spinal canal to the level of S2. MacDonald *et al*²⁸ found in their MRI study, that the median level of termination of the dural sac was the middle one-third of S2. The upper one-third of S2 was the median level for males and the middle one-third of S2 for females. They determined a range extending from the upper border of S1 to the upper border of S4.
- **Arachnoid mater** – The arachnoid mater lines the dural sac to the level of the middle one-third of S2²⁸.

The subarachnoid and epidural spaces are related to the meninges and also continue down to S2 at the level of the posterior superior iliac spine (PSIS) also called the dimple of Venus.

- **Pia mater**- The pia mater leaves the spinal cord at the conus medullaris to form the filum terminale, traversing the subarachnoid space and terminating on the periosteum of the coccyx, after penetrating the dura and arachnoid at level S2.

5.10 Lumbar cistern

- This cistern represents the expansive portion of the subarachnoid space inferior to the spinal cord, where the spinal needle can be safely introduced¹⁹. Within the cistern run the dorsal and ventral roots of L2 to Co1 (coccyx 1) as the cauda equina, before exiting the vertebral canal through their respective intervertebral foramen.

5.11 Epidural space

- There is debate in the literature whether the epidural space is an actual or potential space. Parkin *et al*³¹ concludes in a cadaver-based study that the use of the term space is meaningless and confusing as it implies that there is an open space where there does not exist one. A space is only artificially created when the dura is separated from the vertebral canal by solutions as local anesthetics. Newell²⁹ refers to the space as a potential space lined by a mesothelial layer, which can be easily opened without tissue damage. It contains the internal venous plexus, epidural fat and bands of fibrous tissue connecting the dura to the vertebral canal. Routine diagnostic MRI studies indicate the space to be completely filled with tissue with a signal matching that of fat²⁹.

5.12 Cauda equina

- The cauda equina represents the anterior and posterior roots of the lumbar and sacral nerves.

5.13 Ligamentum flavum

- The ligamentum flavum forms a strong elastic yellow membrane. It can be up to 1 cm thick in the lumbar region and covers the interlaminar space between adjacent vertebrae. It helps the paraspinal muscles to maintain an upright position. Fibres are stretched in the flexed position and can be more easily crossed by the spinal needle. If the needle is exactly in the midline, it will go between the two ligaments, which spans the space between the laminae of adjacent vertebrae.

In a flexed spine, the extent of the ligamentum flavum that is exposed is much greater compared to the extended spine²⁶.

5.14 Children

- Beware of a too long a period of flexion of the neck while positioning the child, for this may produce dangerous airway obstruction.
- Positioning is best accomplished by an assistant overlying the child and maintaining the spine maximally in a flexed position by holding the child behind the shoulders and knees. Make sure to maintain the airway.
- Newborn and premature babies may experience severe hypoxia, so a sitting position is preferable².

6. Complications (anatomically relevant)

6.1 Traumatic tap

- A traumatic tap usually occurs due to too lateral placement of the needle. The posterior external vertebral venous plexus in the epidural space may be involved in a bloody tap. A traumatic tap is defined as a tap containing macroscopic blood¹⁴.
- A traumatic tap should be distinguished from a subarachnoid hemorrhage. Fluid generally clears after the first and second tubes in a traumatic tap. The presence of a clot in one of the tubes strongly favors a traumatic tap. Clotting does not occur in a subarachnoid hemorrhage due to defibrinated blood being present in the CSF.
- Entry of the internal or external vertebral venous plexi, poses a slight risk of neurological symptoms, as clots may compress the spinal nerve roots or nerves¹⁹.

6.2 Dry tap

- A dry tap is usually due to incorrect positioning of the patient and misdirection of the needle. The needle is often advanced onto bony structures. This is often due to a too cephalad direction of the needle, with obstruction by the lamina or spinous process of the superior or inferior vertebrae. If the needle is directed too laterally, an inferior or superior articular process may provide obstruction. A too lateral approach may also injure the spinal nerve root in the intervertebral foramen¹⁹.
- The back may also not be fully flexed, with the gaps between the lumbar spinous processes not widened²⁶.
- If only one iliac crest is used to locate L4, 30% of needles are misplaced at L2-3. This high misplacement figure is diminished to 4% if Tuffier's line is used to determine L4¹⁵, as determined by a cadaver study. By physically defining Tuffier's line, too high placement of the needle will be avoided, decreasing the risk of injuring the spinal cord.
- If bony resistance is encountered, remove the needle to the subcutaneous layer, change the angle, make sure to be in the midline and readvance. If no CSF emerges, rotate the needle 90 degrees, as a nerve root may be lying across the end. If there is still no fluid, replace the stylet and advance the needle a millimeter or two.

If firm resistance is encountered, do not force the needle, as it may be against the bone or an intervertebral disc.

- A low pressure may indicate that flow in the spinal canal is impaired. This is the case in spinal lesions or with cerebellar tonsillar impaction. No attempt should ever be made to aspirate CSF. This may cause neurological damage³².

6.3 Difficulty to find landmarks

- Difficulty in finding the landmarks may be experienced in obese patients and in patients with osteoarthritis where osteophytes may impede access to the spinal canal. This may also be the case in patients suffering from ankylosing spondylitis and kyphoscoliosis²⁶.

6.4 Headache

- Headache is the most common complication of lumbar puncture⁸.
- Headache occurs in 5-30% of spinal taps^{4,17}. Usually it starts 48 hours after the procedure²⁰ and may last up to 1 to 2 days and even two weeks. The headache starts with rising and disappears in the recumbent position. The longer the patient is upright the longer it takes before the headache subsides²⁰. Head shaking and jugular vein compression worsens the headache. A frontal, occipital or diffuse headache may occur, but the typical localizations are occipital, at the vertex, or posterior to the eyes⁸.

Most patients recover in a week's time.

Sometimes it is accompanied by nausea, vomiting, vertigo, tinnitus, diminished hearing and blurred vision.

- The reason for the headache is due to leakage of CSF through the dural puncture site into the epidural and paravertebral spaces faster than the production rate of CSF^{5,8}. The incidence of headache after lumbar puncture is directly related to the size of the needle and therefore the dural puncture site⁵. This leads to low CSF pressure and traction on pain sensitive structures in the cranial cavity, especially the pain sensitive basal dura. Dura mater is richly innervated with adrenergic, cholinergic and peptidergic fibres²⁰.

Another postulate is that the headache is due to an absolute reduction of CSF volume below the cisterna magna decreasing the supportive cushion of the brain²⁰. The result is downward movement of brain tissue with stretching of pain sensitive structures, like meninges and vessels. The loss of CSF causes a compensatory dilatation of the cerebral vasculature⁸. Relief in the recumbent position is due to upward movement of the weight of the brain.

A decrease in CSF volume leads to labyrinth changes, which may account for the diminished hearing, tinnitus and vertigo occasionally associated with the headache²⁰.

- The following risk factors for a post lumbar puncture headache are listed: female,

lower body mass index, young age, large needle size, beveled needle type compared with pencil-point needle of same size, bevel of needle cutting longitudinal dural fibres⁷ and multiple punctures.

- The pencil-point needle separates, rather than cuts through the dural fibers, giving a lower incidence of post lumbar puncture headaches¹⁸. The pencil point needle (22-25 gauge) is indicated for spinal anesthesia, but not for diagnostic use, as they do not allow free flow of CSF with resultant difficulty to obtain sufficient fluid.
- The size of the needle used and therefore the dural rent seems to correlate with the frequency of post lumbar puncture headaches^{5, 7}. The incidence of headache is smaller if a thinner needle is used. Headache is also milder when the thinner needle is used. The thinner needles make manipulation of the needle tip more difficult because of intermittent obstruction by nerve root filaments⁵.
- Position during performance of the procedure was not found to influence the incidence of the headache⁶. Brocker⁷ however reported in a controlled study of 894 patients that the incidence of post lumbar puncture headache is reduced from 36.5% to 0.5% by having patients lie in a prone position for 3 hours after the puncture. This, according to him, causes hyperextension of the spine and disrupts alignment of the holes in the dura and arachnoid and releases the tension on the dura. Brocker⁷ convincingly shows that the dura migrates cephalically during extension and comes in closer contact with the bony elements and therefore obliterates the epidural space.

Prevention:

- The smallest possible atraumatic needle with a stylet should be used and multiple punctures should be avoided. Prolonged bed rest does not reduce the incidence of post lumbar puncture headache^{6,17}. This was the finding in a randomized study of 110 patients, where the effect of immediate mobilization with 4 hours bed rest was compared to a group with prolonged bed rest after a first diagnostic lumbar puncture. There was no significant difference between the groups.
- An epidural blood patch can be placed, stopping the CSF leak and increasing the CSF pressure⁸ by compressing the spinal dura. This has become the most rapidly effective measure for terminating post lumbar puncture headache. 10-20 ml autologous blood is injected epidurally and spreads over nine spinal segments, six upward and three downward²⁰. The needle is placed at the same level as the previous lumbar puncture into the epidural space. Patients may suffer transient paresthesias in their lower extremities after the blood injection. Accidental injection of blood in the subarachnoid space may cause a chemical meningitis. Blood usually clears in 1-4 weeks from the CSF and usually has no major neurological complications⁸.
- Adequate hydration may reduce the incidence of post lumbar puncture headache²⁰.

- It has been suggested that the incidence of post lumbar puncture headache may be reduced by removing the needle when the patient is prone in Trendelenburg's position. The hydrostatic pressure in the lumbar subarachnoid space is negative in this position. Therefore, when removing the needle, there is inversion of the dural puncture site instead of eversion. Maintaining the patient in this position for 60 minutes ensures sealing of the dural hole^{20,23}.

6.5 Herniation syndromes

- Large pressure gradients exist between the cranial and lumbar compartment in supratentorial mass lesions. By lowering the pressure in the spinal compartment by performing a lumbar puncture transtentorial and foramen magnum herniation may occur²². Duffey¹⁰ reported on 30 patients with post-lumbar puncture herniation syndromes of which half lost consciousness immediately after the lumbar puncture. The role of lumbar puncture in the subsequent deterioration was not clear. Other studies report very low complication rates. Zisfein *et al*¹¹ report 38 patients with CT documented intracranial lesions (distortion of ventricles, cisterns or sulci by hematomas, abscesses, subdural collections and tumors), who underwent lumbar puncture, with low complications. They conclude that lumbar puncture carries little measurable risk to most patients with CT-documented intracranial mass lesions. Pre-existing tentorial herniation is however a contraindication for the performance of a lumbar puncture. This can easily be diagnosed by findings of pupillary and oculomotor fixation, quadriparesis, posturing and respiratory changes.

- **Anatomy of herniation**

The decrease of pressure in the lower spinal segment precipitated by performing a lumbar puncture and removing CSF, will cause downward movement of the transtentorial and tonsillar structures¹². Therefore anybody is at risk of herniation during a lumbar puncture. Gower *et al*¹² points out that those with a pressure gradient between the intracerebral and intraspinal CSF are at a greater risk of herniation.

- i) Uncal herniation – expanding lesions in the temporal cranial fossa shift the medial temporal lobe medially over the notch of the tentorium and compress the midbrain, peduncle and third cranial nerve. The third cranial nerve and posterior cerebral artery are caught between the swollen uncus and the free edge of the tentorium. The earliest sign is a slightly dilated pupil unilaterally. Impaired consciousness is not consistently present.
- ii) Tonsillar herniation – The cerebellar tonsils compress the medulla at the foramen magnum.
- iii) The anterior cerebral artery may be compressed against the falx and increases ischemia and edema.
- iv) Posterior midline displacement compresses the deep great cerebral vein.
- v) Compression of the posterior cerebral artery at the tentorial notch can produce occipital infarction.

- vi) Kinking of the aqueduct may interfere with CSF drainage.
 - vii) Transtentorial herniation displaces the brain stem inferiorly, stretching the medial perforating arteries of the basilar artery, which produces brainstem ischemia.
 - viii) Transient unilateral or bilateral sixth nerve palsy may be caused by stretching of the abducent nerve as it crosses the petrous ridge of the temporal bone.
- **Prevention:** A CT-scan should first be performed if there is any indication or history suggesting raised intracranial pressure¹².
A careful neurological examination should precede any lumbar puncture.
 - The decision to perform a lumbar puncture is based on risk-benefit analysis. Failure to perform a lumbar puncture in the case of meningitis may be fatal if there is delay for example waiting for CT- results. It may be difficult to distinguish between herniation and bacterial meningitis, as the latter can produce similar signs. If either condition cause herniation this may result in papilledema, pupil inequality, stupor, seizures and focal neurological deficits.
 - No more than 3-6 ml of CSF should be collected¹².
 - **CT findings suggesting raised intracranial pressure :**
 - Lateral shift of midline structures (septum pellucidum and third ventricle). Gower¹² points out that asymmetry of the lateral ventricles alone, may not give an accurate assessment as ipsilateral ventricle dilatation may occur secondarily to a stroke or there may be coaptation of a frontal horn which may be a normal anatomical variant.
 - Loss of suprachiasmatic and basilar cisterns. Loss of these cisterns, reflect symmetrical supratentorial pressures higher than infratentorial pressure.
 - Obliteration of the fourth ventricle. This is strongly suggestive of a posterior fossa mass, which if present is the strongest contraindication to perform a lumbar puncture. Removal of a small amount of CSF from the spinal compartment may result in the cerebellar tonsils moving into the foramen magnum and causing tonsillar herniation. The posterior fossa and foramen magnum are difficult to visualize with CT. Therefore obliteration of the fourth ventricle should be regarded as highly suspicious of a posterior fossa mass.
 - Failure to visualize the superior cerebellar and quadrigeminal plate cisterns with sparing of the ambient cistern. These findings suggest upward herniation.

6.6 Pain referred to the lower limb

- If the patient complains about a shooting pain down a leg during the procedure, a nerve may have been hit. The needle was probably angled away from the midline

towards the side of the pain. If this happens, the needle should be withdrawn completely and the procedure started again.

- Do not withdraw the plunger of a syringe if it is attached to the needle or when injecting anesthetic solution. The negative pressure may pull a spinal nerve root against the needle tip and produce paresthesia, pain or injury¹⁹.

6.7 Infection

- It is very difficult to distinguish between spontaneous meningitis and lumbar puncture induced meningitis. The risk for lumbar puncture induced meningitis is higher in the presence of a bacteremia in children under one year of age⁹. A lumbar puncture must however be performed on any child in whom meningitis is suspected, due to its mortality and sequelae.

6.8 Subdural hematoma

- In elderly people, the removal of a large volume of CSF may result in a tear or avulsion of a perforating vein.

6.9 Backache

- Transient sensory symptoms due to irritation of individual nerve roots of the cauda equina are common and present as a shooting pain. The patient may feel momentary discomfort, but the nerve root will be pushed away by the point of the needle and is not damaged.
- Disk herniation has been reported due to the needle passing beyond the subarachnoid space into the annulus fibrosis, with resultant rupture of the nucleus pulposus^{30, 32}.
- Multiple attempts may lead to paraspinal muscle spasm, presenting as backache.

6.10 Retroperitoneal abscess

- One case of a retroperitoneal abscess is reported, produced by dural laceration in a patient with meningitis¹³. The patient developed a psoas abscess due to extravasation of infected CSF into the retroperitoneal space.

6.11 Unexpected abnormal raised CSF pressure

- If an abnormally high pressure is encountered, collect the fluid from the manometer and withdraw the needle. Obtain intravenous access in case it may be necessary to give mannitol and contact expert neurological help. Jugular compression (Queckenstedt test) should not be performed for it is dangerous¹⁶.

6.12 Hypoxia and ventilation-perfusion mismatches in children

- Gleason *et al*³ demonstrated that performing a lumbar puncture on an ill, premature baby using the traditional recumbent position with neck flexion, may result in significant respiratory ventilation-perfusion imbalance leading to hypoxemia. They recommend that the neck should not be flexed, but extended or the infant should be in the upright position³.
- One cause of clinical deterioration is compression of the diaphragm during flexion rather than upper airway obstruction. This could also be avoided by performing the procedure in either the sitting position or with the neck in extension²¹.
- Weisman *et al*² compared the grade of hypoxemia in three different positions. The sitting and lateral position without knees-to-chest position experienced less hypoxemia than those in the lateral knees-to-chest position. The neck should be kept in the neutral position.

6.13 Interspinal epidermoid tumor

- This complication usually arises due to the failure to use a stylet¹. This tumor constitutes a mass of desquamated cells containing keratin, caused by viable epithelial cells introduced into the spinal canal by the spinal needle. Skin tissue can easily be excised by a hollow needle and then implanted into the subarachnoid space. The stylette should not be removed until the needle tip has passed the skin¹. Congenital lesions are rare, and arise from epithelial tissue becoming sequestered at the time of closure of the neural groove in week 3 to 5. Unstyletted lumbar puncture needles should be avoided²¹.

7. References

7.1 Scientific papers

¹ McDonald JV, Klump TE. Intraspinial epidermoid tumors caused by lumbar puncture. *Arch Neurol* 1986; 43: 936

² Weisman LE, Merenstein GB, Steenbarger JR. The effect of lumbar puncture position in sick neonates. *Am J Dis Child* 1983; 137:1077

³ Gleason CA, Martin RJ, Anderson JV et al. Optimal position for a spinal tap in preterm infants. *Paediatrics* 1983; 71: 31

⁴ Leibold RA, Yealy DM, Coppola M et al. Post-dural headache: Characteristics, management and prevention. *Ann Emerg Med* 1993; 22: 89

⁵ Tourtellote WW, Henderson WG, Tucker RP. et al. A randomized double-blind clinical trial comparing 22 versus the 26 gauge needle in the production of the post-lumbar puncture syndrome in normal individuals. *Headache* 1972; 12: 73

⁶ Kuntz KM, Kokmen MD et al. Post-lumbar puncture headaches: experience in 501

- consecutive procedures. *Neurology* 1992; 42: 1884
- ⁷ Brocker RJ. A technique to avoid post spinal-tap headache. *JAMA* 1958; 168: 261
- ⁸ Olsen KS. Epidural blood patch in the treatment of post-lumbar puncture headache. *Pain* 1987; 30: 293
- ⁹ Teele DW, Dashefsky B, Rakusan T, Klein JO. Meningitis after lumbar puncture in children with bacteremia. *N Engl J Med* 1981; 305: 1079
- ¹⁰ Duffy GP. Lumbar puncture in the presence of raised intracranial pressure. *BMJ* 1969; 1: 407
- ¹¹ Zisfein J, Tuchman AJ. Risks of lumbar puncture in the presence of intracranial mass lesions. *Mt Sinai J Med* 1988; 55: 283
- ¹² Gower DJ, Baker AJ, Bell WO, Ball MR. Contraindications to lumbar puncture as defined by computed cranial tomography. *J Neurol Neurosurg Psychiatry* 1987; 50: 1071
- ¹³ Levine JF, Hiesiger EM, Whelan MP et al. Pneumococcal meningitis associated with retroperitoneal abscess. *JAMA* 1982; 248: 2308
- ¹⁴ Mehl AL. Interpretation of traumatic lumbar puncture. *Clin Pediatr* 1986; 25: 523
- ¹⁵ Ievins FA. Accuracy of placement of extradural needles in the L3/4 interspace: comparison of two methods of identifying L4. *British Journal of Anaesthesia* 1991; 66: 381-382
- ¹⁶ Patten J. *Neurological differential diagnosis*. London: Harold Starke; New York: Springer-Verlag, 1996
- ¹⁷ Spriggs DA, Burn DJ, French J, Cartlidge NEF, Bates D. Is bed rest useful after diagnostic lumbar puncture? *Postgrad Med J* 1992; 68: 581-3
- ¹⁸ Lynch J, Krings-Ernst I, Strick K, Topalidis K, Schaaf H, Fiebig M. Use of a 25 gauge Whitacre needle to reduce the incidence of post-dural puncture headache. *British Journal of Anaesthesia* 1991; 67: 692-3
- ¹⁹ American Association of Clinical Anatomists, Educational Affairs Committee. The clinical anatomy of several invasive procedures. *Clin Anat* 1999; 12: 43-54
- ²⁰ Raskin NH. Lumbar puncture headache: a review. *Headache* 1990; 30: 197
- ²¹ Halliday HL. When to do a lumbar puncture in a neonate. *Arch Dis Child* 1989; 64: 313
- ²² Quincke H. Die Lumbalpunktion des Hydrocephalus. *Berl Klin Wochenschr* 1891; 28: 929
- ²³ Easton JD. Headache after lumbar puncture. *Lancet* 1979, i: 974-975
- ²⁴ Reimann AF, Anson BJ. Vertebral level of termination of the spinal cord with report of a case of sacral cord. *Anatomical Record* 1944; 88: 127-138
- ²⁵ Tuominen M, Taivainen T, Rosenberg PH. Spread of spinal anaesthesia with plain 0.5% bupivacaine: influence of the vertebral interspace used for injection. *British Journal of Anaesthesia* 1989; 62: 358-361
- ²⁶ Ellis H, Feldman S. *Anatomy for anesthetists*, Oxford: Blackwell Science, 7th Ed, 1997: 108-112
- ²⁷ Abrahams PH, Webb P. *Clinical anatomy of Practical procedures*. London: Pitman Medical, 1975: 13-15
- ²⁸ MacDonald A, Chatrath P, Spector T, Ellis H. Level of termination of the spinal cord and the dural sac: A magnetic resonance study. *Clin Anat* 1999; 12:149-152
- ²⁹ Newell RL. The spinal epidural space. *Clin Anat* 1999; 12(5): 375-9
- ³⁰ Roberts JR, Hedges JR. *Clinical procedures in emergency medicine*. Philadelphia;

London: Saunders 3rd ed, 1998: 1065-1066

³¹ Parkin IG, Harrison GR. The topographical anatomy of the lumbar epidural space. *J Anat* 1985;141:211-217

³² Van Dellen JR, Bill PLA. Lumbar puncture – an Innocuous diagnostic procedure? *S Afr Med J* 1978; 53: 666-668

³³ Welch T. Personal communication. Cambridge, 2001

7.2 Published books

Davidson RI. Lumbar puncture. In: *Atlas of Bedside Procedures*. VanderSalm TJ, Cutler BS, Wheeler HB. Boston (Mass): Little Brown, 1979: 341-350

Abrahams PH, Webb P. *Clinical anatomy of Practical procedures*. London: Pitman Medical, 1975: 13-15

Patten J. *Neurological differential diagnosis*. London: Harold Starke; New York: Springer-Verlag, 1996

O'Brien J. Lumbar puncture. In: *Procedures for primary care physicians*. Pfenninger JL, Grant CF. St Louis London: Mosby, 1994: 1109-1114

Ford MJ, Munro JF. *Practical procedures in clinical medicine*. Edinburgh: Churchill Livingstone, 1980: 24-28

Roberts JR, Hedges JR. *Clinical procedures in emergency medicine*. Philadelphia; London: Saunders. 3rd ed, 1998: 1054-1077

Terry H. Lumbar puncture. In: *Essential Medical Procedures*. Toghil PJ London, Sydney, Auckland: Arnold, 1997: 133-140

4.4.1.4 Central venous catheterization (subclavian and internal jugular vein)

1. Indications	129
2. Contraindications	129
3. Step by step procedure	130
4. Materials	132
5. Anatomical pitfalls	132
6. Complications (anatomically relevant)	139
7. References	148

1. Indications^{29, 45}

- Emergency care patients needing fluid status monitoring after initial fluid resuscitation.
- Severely injured patients for venous access.
- Patients needing central venous pressure monitoring.
- Patients needing various infusions of fluid, medication, chemotherapy or temporary pacemakers
- Patients needing intensive care with regular blood specimens and blood transfusions.
- Patients needing total parenteral nutrition.
- Route to obtain vascular access once peripheral sites are exhausted, especially in children³⁵.

2. Contraindications

- Distortion of local anatomy or landmarks.
- Suspected injury to the superior vena cava with penetrating wounds of the thorax.
- Bleeding diathesis or anticoagulation therapy.
- Pneumothorax or hemothorax on the contralateral side.
- Previous radiation therapy to the clavicular area.
- Subclavian route not recommended in small children.

- Relative contraindication: Left side catheterization due to the thoracic duct on the left side which if punctured may cause a chylothorax with high morbidity.
- Cervical trauma with distortion of the anatomy at the entry site or swelling.
- Lack of experience.
- Presence of apical bullous disease or patients with emphysematous lungs¹⁵.

3. Step by Step procedure

3.1 Subclavian vein ^{13, 14, 15, 43}

1. Place the patient in a supine position, at least 15 degrees head down (Trendelenburg's position), to distend the neck veins and prevent air embolism. Only if the cervical spine has been cleared radiographically can the patient's head be turned away from the puncture site⁵⁹.
2. Clean the skin surgically and drape the area. Sterile gloves should be worn during the procedure.
3. Use a local anesthetic if the patient is awake.
4. Introduce a larger caliber needle attached to a syringe, 1 cm below the junction of the middle and medial thirds of the clavicle.
5. Direct the needle medially and slightly superiorly to stay on the inferior border of the clavicle, in the direction of the suprasternal notch where the index finger of the other hand is placed.
6. Slowly advance the needle until its tip comes in contact with the inferior border of the clavicle¹², while gently withdrawing the plunger of the syringe.
7. It is then gently advanced on the inferior border of the clavicle until the vein is entered. When free flow of blood appears, remove the syringe and occlude the needle with a finger to prevent air embolism. With newer catheter packs, the guidewire can be inserted via a separate port and the needle does not need to be removed.
8. Insert the guidewire and remove the needle. Then insert the catheter over the guidewire.
9. Remove the guidewire and connect the catheter to the intravenous line.
10. Fix the catheter in place. Subcutaneous fixation is easier to perform in the pectoral region than in the neck region⁸.
11. Attach the central venous pressure set-up to the intravenous tubing and adjust the manometer to level zero with the level of the patient's right atrium.
12. Obtain a chest X-ray to identify the position of the tip of the catheter and a possible pneumothorax.
13. Obtain free flow intravenous fluid with gravity and flow of blood through the catheter tubing on lowering the intravenous fluid bag below the level of the patient.

3.2 Internal jugular vein ⁴³

1. Place the patient in the supine position, 15 degrees Trendelenburg's position, to distend the veins of the neck and thus preventing air embolism. Only if the cervical spine has been cleared radiographically can the patient's head be turned away from the puncture site⁵⁹, not more than 30° to the opposite side¹⁴.
2. Clean the skin around the puncture site and drape the area. Sterile gloves should be worn during the procedure.
3. Use a local anesthetic if the patient is awake.
4. Locate the carotid artery by palpation in the space between the trachea and sternocleidomastoid muscle. Thereafter do not palpate the carotid pulse again¹⁴. The vein is located immediately lateral to the carotid pulse⁵⁶
5. Introduce a large caliber needle attached to a syringe into the center of the triangle formed by the sternal and clavicular heads of the sternocleidomastoid muscle and the clavicle.
6. Direct the needle inferiorly, parallel to the sagittal plane, 30-45 degrees posterior with the frontal plane. The needle should be advanced inferiorly and slightly laterally towards the anterior end of the first rib behind the clavicle.
7. Slowly advance the needle while gently withdrawing the plunger of the syringe.
8. When free flow of blood appears, remove the syringe and occlude the needle with a finger to prevent air embolism.

Alternative method³²: Find a point one-third of the distance along the line between the sternal head of the clavicle and the mastoid process, just lateral to the sternocleidomastoid muscle³². At this point the external jugular vein (which should not be used due to its valves) crosses over the sternocleidomastoid muscle. Introduce the needle and cannula at an angle of 30 to 40 degrees to the skin, deep to the sternocleidomastoid muscle and advance inferiorly and medially towards the suprasternal notch until entering the internal jugular vein at a depth of 2 to 3 cm^{12, 15}. The needle is hence advanced through skin, superficial fascia, platysma muscle and deep cervical fascia.

9. Insert the guidewire and remove the needle. Then insert the catheter over the guidewire.
10. Remove the guidewire and connect the catheter to the intravenous line.
11. Fix the catheter in place.
12. Attach the central venous pressure set-up to the intravenous tubing and adjust the manometer to level zero with the level of the patient's right atrium.
13. Obtain a chest X-ray to identify the position of the tip of the catheter and a possible pneumothorax.
14. Obtain free flow intravenous fluid with gravity and flow of blood through the catheter tubing on lowering the intravenous fluid bag below the level of the patient.

Advantages:

- Slightly fewer complications compared to the subclavian route, but a slightly higher incidence of failure^{13, 30}.
- Chest compressions during CPR can continue.
- Bleeding complications are more easily detectable and compression can be applied.

The internal jugular vein is compressible at the insertion site whereas the subclavian vein is not.

- Less risk of a pneumothorax.
- Malpositioning is rare (almost a straight course to the superior vena cava on the right).

4. Materials

- Sterile pack with gloves.
- Lignocaine 1%.
- 25-ga needle with 5cc syringe.
- Central intravenous fluid set.
- Central venous catheter and insertion set.
- Nylon sutures.
- Needle holder.
- Suture scissors.

5. Anatomical pitfalls

5.1 Subclavian vein

- The subclavian vein has a large diameter (1 to 2 cm) and stays patent even in the case of hypovolaemia. This is due to the connective tissue around it, attaching it to surrounding structures^{3, 60}. The vein is 3-4 cm long in the adult^{29, 45}. The problem with this vein is its association with immediate intrathoracic complications and close relation to the subclavian artery and brachial plexus, which are just posterior to the anterior scalene muscle⁴³. Furthermore in the case of bleeding, controlling the bleeding is a problem due to the overlying clavicle.
- The vein lies posterior to the medial third of the clavicle. No valves are found in the vein. The subclavian vein joins the internal jugular vein to form the brachiocephalic vein posterior to the sternoclavicular joint. The angle of the subclavian vein joining the internal jugular vein is 90 degrees or greater⁴⁴.
- Anterior to the vein are the clavicle and subclavius muscle. Posteriorly lie the anterior scalene muscle, subclavian artery and brachial plexus. Inferior is the first rib and the apical portion of the pleura. Sometimes the subclavian vein appears to be sunken into the apex of the pleura. Before it is joined by the internal jugular vein to form the brachiocephalic vein on both sides, the external jugular vein drains into it and the right lymphatic duct on the right and thoracic duct on the left⁶⁰.

5.2 Internal jugular vein

- The internal jugular vein is most frequently used for central venous catheterization⁶⁰.

- Its surface anatomy is represented by a straight line connecting the mastoid process and the medial end of the clavicle.
- Posterior to the vein are the transverse process of the atlas, medial and anterior scalene muscles and cervical plexus in the upper neck. More inferiorly the phrenic nerve, thyrocervical trunk and first part of the subclavian artery are found posterior to the internal jugular vein.
- Medially lie the common carotid artery and vagus nerve.
- Anterior lie the sternocleidomastoid muscle in the mid-neck and the omohyoid muscle crosses the vein in the base of the neck.
- The internal jugular vein has a large diameter, is easy to locate and has a short straight route to the superior vena cava, especially on the right. The problem with this vein is its connection with intrathoracic complications and its close relation to the common carotid artery. It has an anterolateral relation to the common carotid artery throughout its course¹⁴. As the vein approaches the supraclavicular junction with the subclavian vein, it takes a more medial position in the triangle between the two heads of the sternocleidomastoid muscle.
- The brachial plexus is separated from the internal jugular vein by the anterior scalene muscle. The phrenic nerve is anterior to the anterior scalene muscle and the stellate ganglion lies anterior to the lower brachial plexus.
- The vessel is more distensible than the subclavian vein, which is shown by narrowing of the diameter of the vein with prolonged palpation of the carotid pulse³⁶. The diameter of the internal jugular vessel is greatest below the cricoid cartilage, where it may reach 2 to 2.5cm¹⁴.
- A head-down tilt of 14 degrees (Trendelenburg position) causes significant distension of the vein. Both extensive palpation of the neck and rotation of the head increases the difficulty to cannulate the vein. Extensive palpation of the carotid artery, may distort the anatomy. Therefore, Bazaral *et al*¹⁴ recommends that after locating the artery, palpation should be discontinued.
- The internal jugular vein is more collapsible compared to the subclavian vein⁵². This may complicate catheterization. The advancing needle may press the anterior wall of the vein against the posterior wall. This may result in passing the needle through both walls without locating the lumen. If no blood is found after advancing the needle at a depth of 2.0-2.5 cm, the needle should be withdrawn and therefore reestablishing a lumen by drawing the anterior wall from the posterior wall.
- The right internal jugular vein is preferred due to its straight course into the superior vena cava and right atrium, which facilitates successful and correct placement of the catheter⁶⁰.

5.3 Patient position

5.3.1 Subclavian vein

- **Turning of the head** – Turning the head should only be done if a possible neck injury has been excluded. Anatomical studies have not confirmed that a head turned away from the site of insertion is beneficial to the insertion of a catheter, either by increasing the diameter of the vein or by influencing the relation of the subclavian vein to the clavicle⁴⁴. Turning of the head may however decrease the risk of contamination and patient anxiety during the procedure¹³. One author states that the acuteness of the angle of the subclavian-internal jugular vein is increased by turning the head⁴⁴.

In a very well performed study, Jesseph *et al*⁴⁴, showed by means of anatomical dissection and MRI, that the traditional recommendations of positioning the patient with the shoulders retracted and the head turned away, actually distort the anatomy of the subclavian vein, making successful cannulation of the vein more difficult. They suggest a position of lying supine with the head and shoulders in a neutral position. This is a favorable position considering the fact that many patients needing a central venous catheter in the emergency department have suspected neck injuries where manipulation of the head is totally contraindicated.

The angle of the subclavian vein with the internal jugular vein is more or less 90 degrees⁴⁴, and increases when the head is turned to one side. This suggests that turning the head away from the side of the puncture may in fact promote malpositioning in the internal jugular vein. Turning the head towards the site where the procedure is performed may prevent the advancing catheter from moving into the internal jugular vein.

- **Retraction of the shoulders** - Retracting the shoulders by placing a sand bag or rolled towel between the scapulae of a patient, decreases the space between the clavicle and the first rib, making catheterization of the subclavian vein more difficult^{13, 29}. It is therefore better to keep the shoulders in the neutral position.
- The patient should be positioned in the Trendelenburg position. This facilitates filling of the vein and decreases the risk of air embolism⁶⁰.

5.3.2 Internal jugular vein

- Rotation of the head will not change the size of the internal jugular vein significantly. Full neck extension also reduces the diameter of the vein considerably. Armstrong *et al*³⁶ demonstrated in a study of 35 people, that the mean size of the internal jugular vein in the normal position is 11.5mm. There was poor correlation between neck size and diameter. The vein was located lateral to the common carotid artery in most cases, but was anterior to the artery in two

cases and anterolateral to the artery in 12 cases. The anterolateral position of the vein to the artery increased to 25 cases when the head was turned to the opposite side.

- Head position has been found to alter the relative position of the internal jugular vein but not the size of the vessels except for full neck extension where the diameter of the vein is reduced considerably. Use of the Trendelenburg position and the Valsalva maneuver both increased internal jugular vein size³⁶. The Valsalva maneuver had greatest effect on the vein diameter due to its increase of intrathoracic pressure.

5.4 Direction of the needle

5.4.1 Subclavian vein

- 1cm below and 1 cm lateral to the junction of the middle and medial thirds of the clavicle. The needle is advanced toward the tip of the opposite index finger, which is placed deeply in the suprasternal notch. The direction of the needle is now aligned with the central axis of the subclavian vein, minimizing the risk of puncturing the subclavian artery, pleura or apex of the lung²⁹. By keeping the needle in a horizontal plane, the risk of arterial or pleural injury is minimized⁶⁰.
- On its course the needle goes through skin, superficial fascia, the subclavius muscle, clavipectoral fascia and subclavian vein.

5.4.2 Internal jugular vein

- The needle is inserted at the apex of the triangle formed by the sternal and clavicular heads of the sternocleidomastoid muscle. The apex is situated approximately 5 cm superior to the clavicle. The vein lies at a depth of 1.0-1.5 cm below the skin between the sternocleidomastoid muscle and the cervical pleura. The needle should be directed in a caudal direction at an angle of 30- 45 degrees to the frontal plane, keeping the needle parallel to the sagittal plane. This ensures that the needle is directed along the central axis of the vein⁵².
- Bazaral *et al*¹⁴ suggests a needle insertion at or above the cricoid cartilage. The needle should be inserted at a 30-40 degree angle to the skin, expecting the internal jugular vein 1-2 cm inferior to the cricoid cartilage ring at a depth of 1-1.5 cm. The head should not be extremely rotated, which may cause the sternocleidomastoid muscle to overlie the vein.

5.5 Phrenic nerve

- The phrenic nerve runs on the anterior surface of the anterior scalene muscle. It lies medial to the attachment of the anterior scalene muscle to the scalene tubercle on the first rib, in contact with the postero-inferior side of the subclavian vein at the junction

of the subclavian and internal jugular veins²⁹. The nerve may be injured if the needle is advanced too deeply. The internal thoracic artery runs in close relation to the phrenic nerve after branching from the subclavian artery⁴⁵.

5.6 Subclavian artery

- The subclavian artery runs posterior to the anterior scalene muscle, and has a superior and more posterior course than the subclavian vein²⁹.

5.7 Thoracic duct

- The thoracic duct drains into the left subclavian vein, in the angle where the left subclavian vein joins the left internal jugular vein, after running across the anterior scalene muscle²⁹. The danger of left cannulation is injury to the thoracic duct, which is a rare complication³⁴. However it is associated with high morbidity⁴⁸. Shimada *et al*⁵⁹ reports on several branching patterns of the terminal thoracic duct. The most common type drains into the venous angle between the internal jugular and subclavian veins (38%), followed by the type draining into the external jugular vein (28%) and internal jugular vein (27%) and a complex drainage pattern in 7%. The thoracic duct is therefore at risk of injury in both the subclavian and internal jugular routes for central venous catheterization on the left side.

5.8 Right lymphatic duct

- This duct drains into the right subclavian vein, in the angle where the subclavian vein joins the internal jugular vein on the right, also running across the anterior scalene muscle²⁹ behind the internal jugular vein⁴⁵.

5.9 Apex of the lung

- The apex of the right pleura is usually lower than the left¹³, making the right side the preferred side (with the thoracic duct found on the left side). If subclavian catheterization fails, first attempt the ipsilateral internal jugular vein, before considering the left side.

5.10 The cervical pleura

- The cervical pleura is covered by the supra-pleural membrane (Sibson's fascia) with surface markings from the junction of the medial and middle thirds of the clavicle to the sterno-clavicular joint. Its highest point can be as high as 2.5 cm above the clavicle¹². The apical pleura is in contact with the postero-inferior surface of the subclavian vein^{29, 45}. Therefore, if a needle is advanced through both walls of the subclavian vein, the parietal pleura, pleural space and lung may be penetrated with a resulting pneumothorax. A concurrent laceration of a blood vessel, will result in a hemothorax.

5.11 Brachial plexus

- All the roots of the brachial plexus (C5-T1) run posterior to the subclavian artery^{29, 45}.

5.12 Common carotid artery

- The common carotid artery usually lies medial to the internal jugular vein⁴³, but the position of the vein to the artery varies considerably in children⁴² and with the turning of the head to the opposite side³⁶.

5.13 Correct placement of catheter tip

- The catheter tip should be placed 3-4 cm above the junction of the superior vena cava and the right atrium¹.

5.14 Vagus nerve

- The vagus nerve is located in the carotid sheath, usually behind the internal jugular vein.²⁹ On a lower level, the vagus nerve lies postero-medial to the jugulosubclavian junction⁴⁵.

5.15 External jugular vein

- The external jugular vein crosses over the sternocleidomastoid muscle at a point one third of the distance along the line between the sternal head of the clavicle and the mastoid process. It is separated from the sternomastoid by the cervical fascia and often has one or more sets of valves in its course through the neck^{12, 34, 60}.

5.15 Anterior scalene muscle

- This muscle is attached to the scalene tubercle of the first rib, with the subclavian vein anterior to it and the subclavian artery and brachial plexus posterior to it²⁹. This muscle is approximately 10 to 15 mm thick in the adult and 5 to 8 mm in children⁴⁵. Thus venipuncture of the subclavian vein has less risk of injuring the subclavian artery which lies directly posterior to the anterior scalene muscle and the brachial plexus which lies posterior to the subclavian artery.

5.16 Fascial layers of the neck

- These layers predispose to subcutaneous emphysema and hydromediastinum after both subclavian or internal jugular vein catheterization. Air dissects in the pretracheal fascial layer down into the mediastinum.

5.17 Sternocleidomastoid muscle

- The sternal and clavicular heads of the sternocleidomastoid muscle form an apex

where they meet. This apex forms the site of needle insertion for the internal jugular vein⁴³.

- An alternative insertion site is found at a point one third of the distance along the line between the sternal head of the clavicle and the mastoid process.

5.18 Suprasternal notch

- This is the anatomical landmark towards which the needle is aimed when performing a subclavian vein cannulation^{43, 29}.

5.19 Superior vena cava

- This central vein varies in length, from 3 to 10 cm, depending on the length of the patient⁴⁵. The junction of the superior vena cava with the right atrium is one-third the distance from the suprasternal notch to the xiphoid process⁴⁵. The tip of the central venous catheter should normally be positioned not more than 3-4 cm superior to the junction of the superior vena cava and the right atrium¹.

5.20 Children

- Cobb *et al*³⁴ studied the anatomy of the subclavian and internal jugular veins on several autopsies, by measuring the angles of vessels to each other, the distances of the vessels to bony and muscular landmarks, and their diameters. In the infant the right and left subclavian veins entered the central venous system at an acute angle. The left brachiocephalic vein joined the right brachiocephalic vein at a right angle. After one year of age, these angles become less acute and have a similar configuration than adults. This may be the reason for the relative ease of cannulating the subclavian vein in older patients, but misplacement of the catheter upwards into the internal jugular vein is often found. This is more often found on the right due to the acute angle of the subclavian vein joining the internal jugular vein, and consequently some authors prefer to use the left hand side⁵³. The danger of left cannulation is injury to the thoracic duct, which is a rare complication³⁴. However it is associated with high morbidity⁴⁸.
- The internal jugular vein however, enters the superior vena cava almost in a straight line. Cobb *et al*³⁴ suggests that using the internal jugular vein in infants is a safe and reliable route to use for gaining central venous access. There was no significant difference in diameter between the internal jugular and subclavian venous system. The external jugular vein can also be used in children, but Cobb *et al*³⁴ identified several sets of valves in its curved and nonfixed course. The internal jugular vein may, on the basis of anatomical relationships, be the site of choice in children.
- Mallison *et al*³⁷ pointed out in an ultrasonographic anatomical study on the position of the internal jugular vein in children, that the internal jugular vein varies in position. In a series of 25 patients, the internal jugular vein was anterior to the common carotid

in 14 cases, in 1 anterolateral and in 10 lateral to the common carotid artery at the level of the apex of the two heads of sternocleidomastoid. These relations differed at the level of the cricoid cartilage. This anatomical fact is the reason for a high failure rate of cannulating the internal jugular vein in children, despite the correct identification of anatomical landmarks and palpation of the common carotid artery. Mallison *et al*³⁷ argues that due to the considerable variation in the position of the internal jugular vein in children, the routine use of ultrasound guidance, if only to locate the vessels, may be sensible. They found a portable ultrasound easy to use and requiring little training.

- Alderson *et al*⁴² studied the possible variations of the internal jugular vein, which could account for some of the difficulties during landmark-guided percutaneous cannulation of the internal jugular vein. In 50 patients under 6 years, they found an antero-lateral position of the vein to the common carotid artery in 82% of cases, 10% anterior to the artery, 4 % in the same position as the artery, 2 % widely lateral to the artery and 2% that could not be seen. Eighteen percent of their population group therefore had anatomical factors, possibly complicating a landmark-approach to the internal jugular vein. They also showed that the diameter of the vein correlated poorly with age, weight and height.
- Due to the fact that the subclavian vein in neonates, run more cephalad than in older patients, the needle should be directed midway between the sternal notch and the chin, or 1cm above the sternal notch³⁵. The course of the vein becomes less cephalad with an increase in age and weight. The needle should therefore be directed towards the sternal angle in adults.

6. Complications (anatomically relevant)

There are different opinions concerning the complication rate of subclavian and internal jugular vein approaches for central venous access. Moosman²⁹ holds that the supraclavicular route is more likely to be associated with complications. Other studies show the contrary¹³.

The complications for central venous catheterization are summarized in Table 1, a modified version of Hegarthy's classification²⁷.

6.1 Pneumothorax

- A pneumothorax is the most common complication of subclavian vein cannulation and may be partial, total, bilateral or under tension. It occurs with an incidence of 30% of all complications⁴⁵.
- Damage to the parietal pleura due to the surface anatomy of the pleura, 2.5 cm above the first rib. A pneumothorax can usually be avoided if correct technique is used, especially the correct direction of the needle. However, repeatedly deep unsuccessful probings after failure to obtain venous blood clearly raises the chances of injuring the pleural space and producing a pneumothorax. Chest X-ray is mandatory after the

procedure is performed.

Maggs *et al*¹⁵ was one of the first to report on fatalities due to tension pneumothorax, bilateral pneumothorax and combined hemopneumothorax.

- The pleura is only 5 mm directly posterior to the subclavian vein beyond the protective edge of the first rib⁴⁶.
- **Prevention:** Adhere to the proper line of needle advancement. If the needle is placed too far posteriorly, the pleural cavity may be entered and the lung lacerated⁴⁵. Abandon the procedure after two unsuccessful attempts. If the puncture and catheterization fails on one side, radiographic exclusion of a pneumothorax is advisable before attempting the other side. Clinical bedside examination may fail to pick up a slowly developing pneumothorax.

It is important that doctors who perform this procedure should be able to perform an immediate tube thoracostomy if necessary¹⁵. The major factor in keeping the incidence of a pneumothorax low, is the experience of the person behind the needle. Holt *et al*⁵⁰ reports that in a retrospective survey of over 600 subclavian venepunctures, serious traumatic complications occurred in seven patients, six of them in the hands of inexperienced operators (staff who have performed less than 12 supervised cannulations).

6.2 Arterial puncture^{27,29}

- Arterial puncture usually involves the **subclavian artery** posterior to the anterior scalene muscle on the first rib. The subclavian artery is intimately located posterior to the subclavian vein²⁸. This is the second most common complication of central venous catheterizations (20%). In subclavian vein catheterization the subclavian artery is punctured if the needle is directed too far laterally and posteriorly⁴⁵. It is said to be easily recognized and without sequelae⁵⁴.
- Embolization to the carotid and basilar vessels can occur from the subclavian artery. Hurwitz *et al*²⁸ even reported two patients developing fatal cerebral infarctions after subclavian vein catheterization associated with inadvertent arterial puncture.
- The **common carotid artery** medial to the internal jugular vein in the neck may also be punctured. This artery is punctured in 0.6%-30% of internal jugular vein catheterizations⁷. Usually it responds well to local pressure⁴⁵.
- **Ascending aorta.** One study reported the puncturing of the ascending aorta⁵, within the pericardial reflection causing a fatal hemopericardium. The patient reported by Childs *et al*⁵ had gross abdominal distension, causing superior movement of the intrathoracic structures and therefore change in the classical anatomical landmarks.
- **Pulmonary artery.** Puncturing of this vessel has also been documented⁶.

6.3 Hemothorax^{27,29,46}

- Due to puncturing a vessel as well as the pleural membrane. A hemothorax usually occurs due to injury to the subclavian vein and direct infusion of blood into the pleural space. A tube thoracostomy is usually required⁴⁵. Holt *et al*⁵⁰ reported a case where an apical branch of the pulmonary artery was lacerated, with resulting hemothorax and requiring a thoracostomy.

6.4 Venous air embolism^{27,29,17}

- Venous air embolism can occur with negative air pressure in the thorax with inspiration. If the site of insertion is vertically higher than the level of the heart an air embolism may result⁴⁵. Air moves as a bolus to the heart where it lodges at the pulmonary valve, which may break up due to ventricular contractions and enter the pulmonary circulation, cause tissue hypoxia and lowered cardiac output⁵⁵. Symptoms of tachypnoea, elevated jugular venous pressure (JVP), chest pain and hypotension may be found. The mortality rate is high.
- Flanagan *et al*¹⁷ reports on the fatal outcome of venous air embolism, pointing out that a 14-ga needle can transmit 100 ml of air per second with a 5-cm pressure difference across the needle. It seems that hypovolemic patients are at higher risk of developing air embolism.
- Prevention: Position the patient in the Trendelenburg position. Check catheter equipment, catheter ports, connections etc. There is a higher risk with central catheters due to the connective tissue around the central veins connecting it to surrounding structures. This is especially true for the subclavian vein. The veins therefore stay patent even in hypovolaemia and have a higher risk of air embolism occurring than the peripheral veins which collapse³. The needle should be occluded in the interval between removal of the syringe and threading of the guide wire or catheter²⁷.
New central venous catheters make this step unnecessary due to the fact that the guide wire is advanced through the syringe.

6.5 Brachial plexus injury^{27,29,46}

- With the subclavian and internal jugular vein catheterization the brachial plexus may be injured when the correct technique is not followed and the needle is not directed correctly. The brachial plexus is posterior to the subclavian artery behind the anterior scalene muscle on the first rib. Therefore, a brachial plexus injury is usually also associated with a subclavian artery puncture.
The brachial plexus with the subclavian artery cross the first rib only 2 cm lateral to the subclavian vein⁴⁶.
- Usually the problem is caused by placement of the needle too far laterally and deeply,

injuring the roots of the brachial plexus with consequent motor and sensory deficits of the shoulder, arm or hand⁴⁵.

Extensive neurological damage has been reported with internal jugular vein catheterization³¹. This includes damage to a phrenic nerve, the sympathetic chain on the left, the IX, X, XI and XII cranial nerves and the anterior branches 2nd, 3rd and 4th cervical nerves³¹.

- Paschall *et al*³² comments on upper root brachial plexus injury after internal jugular vein cannulation. The patient complained of sensory loss over C5/C6 distribution and loss of motor function of the muscles around the shoulder joint. The upper trunk of the brachial plexus (C5, C6) lies at the level of the cricoid cartilage, close to the puncture site of the internal jugular vein. The upper trunk lies in the posterior triangle of the neck and the internal jugular vein in the anterior triangle. Therefore, when using the posterior access route to the vein at the junction of the middle and lower thirds of the sternocleidomastoid muscle, aiming at the suprasternal notch, the upper trunk of the plexus may be injured if the needle is slightly posterior when entering the posterior triangle³². This complication is however rare, but one should be aware of the possibility of injury to the upper trunk of the brachial plexus when using the posterior approach.
- Smith⁴⁶ reports on a case with brachial plexus injury where the injury consisted of motor function deficiencies to the shoulder, elbow, and hand as well as sensory loss to the lateral upper arm.

6.6 Malpositioning of catheter tip

- The correct position of the catheter tip is in the superior vena cava, not more than 3-4 cm above the junction of the superior vena cava and the right atrium¹. If a saline filled catheter tip is, for example, in the superior vena cava, 5 cm above the reference point which is on the mid right atrial level, the recorded pressure would be 0.3 cm H₂O too low, which is clinically insignificant due to the consistent nature of the error in successive readings³³.
- Sheep *et al*²⁰ and Greenall *et al*⁴ argue that the tip of the catheter should lie in the proximal superior vena cava above the reflection of the pericardium and therefore above the level of the ascending aorta. Collier *et al*¹⁹ argues for a point at least 2 cm above the junction of the superior vena cava and the right atrium. The pressure at this point is within 1 mm Hg of that in the right atrium⁵⁷.
- Malpositioning is least likely with the internal jugular approach, but approximately 5% will not lie within the superior vena cava or the right atrium⁵³.
- Most malpositioned catheters occur in the following locations: Internal jugular vein (43,4%), contralateral brachiocephalic vein (11.2%) and right atrium (9.8%)².
- Deitel⁴⁷ reports on catheters inserted via the subclavian route entering the internal

jugular vein and passing up into the neck. Pressure applied above the clavicle or lateral rotation of the head in the direction of the operator while the catheter is advanced may inhibit its passage into the neck.

- Subclavian vein catheters that are misplaced into the internal jugular vein are more common on the right (15%) when compared to the left (2%)¹⁰. The reason for this is shown by the more acute angle of the right subclavian vein with the right internal jugular vein when forming the right brachiocephalic vein when compared to the less acute angle on the left. This was confirmed on coronal magnetic resonance image (MR) studies of the two angles¹¹.

Complications of a malpositioned catheter may result in a hydrothorax, hemothorax, ascites²⁴, chest wall abscesses²⁵ (reported in a patient with long term catheterization and administration of total parenteral nutrition), chest pain²⁶, embolization to the pleural space²⁷ etc.

Unusual chest pain syndromes may indicate central venous catheter malposition²⁶. Webb *et al*²⁶ described this phenomenon in three incidents involving cannulation of the left internal thoracic vein.

- Malpositioning of catheters via the internal jugular vein appears to be more common via the left. This is due to the brachiocephalic vein on the left being longer and oblique in its course. Furthermore the left brachiocephalic vein has frequent small tributaries e.g. the left internal thoracic vein, pericardiophrenic vein^{21,40} and left superior intercostal vein²⁶.

6.7 Failure to locate the internal jugular vein

- Locating the internal jugular vein becomes more difficult after common carotid arterial puncture because of vein compression by hematoma formation from blood leaking out of the artery³⁶.
- The anterior wall of the vein may also, due to the collapsible nature of the vein, be pushed against the posterior wall by the needle. The needle may therefore puncture both walls without reaching the lumen. Withdrawal of the needle at this point, may draw the anterior wall away from the posterior wall and with aspiration the lumen of the vein may so be encountered⁵².

6.8 Cardiac tamponade^{27,29}

- Cardiac tamponade occurs due to perforation of the superior vena cava, right atrium or right ventricle. The pericardium inserts on the base of the heart over the superior vena cava, ascending aorta and pulmonary trunk²⁰. The catheter should therefore not lie too deeply, certainly not in the right atrium or ventricle⁴⁷. Furthermore, the catheter should lie parallel to the wall of the superior vena cava. One study reports a mortality rate of 87% in patients developing cardiac tamponade⁴. Collier *et al*¹⁹ reports that cardiac tamponade develops due to prolonged contact of the rigid catheter with the myocardial wall. Sheep *et al*²⁰ showed that cardiac tamponade is more often

the result of injury to the right atrium than the right ventricle. He reports on a case of cardiac tamponade following superior vena cava perforation after using rather rigid Teflon catheters on the left hand side. It is thought that direct contact with the constantly moving vessel wall and subsequent erosion, eventually cause perforation by the catheter.

- Van Haeften *et al*²¹ reports on cardiac tamponade resulting from a misplaced central venous line in the pericardiophrenic vein. These veins drain to the brachiocephalic veins on both sides. However they are more likely to be cannulated via left sided internal jugular vein catheterization. This can be prevented by preferential use of the right internal jugular vein, routine use of a J-tipped guide wire and roentgenographic control. Van Haeften *et al*²¹ argues that this malpositioning is probably more common and deserves more attention due to a resultant potentially fatal cardiac tamponade.
- Cardiac tamponade is clinically described by Beck's triad⁶²: Elevated central venous pressure, decreased blood pressure and absent heart sounds. Patients may complain of chest pain (stretching of the pericardium which is innervated by the phrenic nerve), nauseousness (referred via the vagus nerve), abdominal pain (referred pain via the splanchnic nerves) and shortness of breath (pulmonary edema). Unexpected hypotension with venous distension in a patient with a central venous catheter, should be regarded as being due to cardiac tamponade until proven otherwise²⁰. A high degree of suspicion should exist because the diagnosis is often delayed because of similar findings in other more common post-operative problems¹⁹.
- Cardiac tamponade is prevented by using soft poly-urethane catheters, measuring the desired length of the catheter beforehand, securing the catheter tightly to the skin and confirming the position of the catheter with a Chest X-ray^{4,19,20,55}. Catheters with beveled edges are unacceptable.
- Perforation of the superior vena cava is more likely to occur via the left sided internal jugular vein approach compared to the right due to the circuitous course of the catheter. First it bends in one direction to accommodate the brachiocephalic vein on the left and then in the opposite direction into the superior vena cava. The path of a catheter inserted via the right internal jugular vein is however straight^{20,21}. Sheep *et al*²⁰ therefore pleads for avoiding the use of the left internal jugular vein for catheterization.
- Due to the serious nature of cardiac tamponade caused by central venous catheters, especially when the tip of the catheter is located in the right atrium, periodic radiographs are necessary to confirm correct catheter placement⁴⁷. Aslamy *et al*⁴¹ argues convincingly that the absence of normative data to determine the dimensions of central venous vasculature and relationships of venous structures with radiographic landmarks, complicates confirmation of the location of the catheter tip. It is proposed that the caudad margins of the clavicles correspond with the origin of the superior vena cava⁴, or the intervertebral disk between the fifth and sixth

thoracic vertebrae, would show the upper limit of the superior vena cava. Greenall *et al*⁴ suggests that the tip of the catheter should lie no more than 2 cm below a line drawn below the lower surface of each clavicle. None of these have been anatomically correlated and may well be of limited value due to the effects of parallax and radiographic technique. However, new MRI studies of the central venous anatomy, have revealed better anatomical correlates to determine catheter position on a radiograph. MRI provides an opportunity to gather normative information on anatomic relationships, allowing imaging in transverse, sagittal and coronal planes. In studying the MR anatomy of the central venous system of 101 patients, Aslamy *et al*⁴¹ showed that the level of the right tracheobronchial angle would always be within the cephalad portion of the SVC. Their data suggest that placement of the catheter tip < 2.9cm caudad to the right tracheobronchial angle as seen on a normal chest radiograph, avoids intracardiac placement in most patients⁴¹.

- Abduction and adduction of the arm, rotation of the trunk and flexion of the neck can change the position of the tip of the catheter over a distance of several centimeters²¹. This may explain the development of cardiac tamponade after several days. Krog *et al*⁵⁸ examined catheter movement in a cadaver based study and found that catheters inserted correctly via antecubital veins, advance up to seven cm with elevation and abduction of the arm. Displacement of catheters via the subclavian or internal jugular vein was approximately two centimeters.

6.9 Dysrhythmias

- If the tip of the catheter is too deeply placed into the right atrium or ventricle, it can irritate the wall of the heart chambers and cause dysrhythmias²⁹. During internal jugular vein catheterization it may also be due to stimulation of the carotid sinus in the neck where the common carotid artery bifurcates. Dysrhythmias are prevented by correctly measuring the catheter beforehand and confirming correct positioning of the tip of the catheter by a chest X-ray⁵⁵.

6.10 Catheter related infection.

- The catheter is a foreign body and may carry bacterial agents into the vein, which may lead to bacterial endocarditis. This complications is the most common complication of central catheters used long term⁶¹.

6.11 Chylothorax^{8,27,29}

- A chylothorax mostly occurs on the left hand side. The thoracic duct drains into the subclavian vein where it is joined by the internal jugular vein to form the brachiocephalic vein. The smaller right lymphatic duct on the right hand side is however also at risk and puncturing can also lead to a chylothorax⁹. The right lymphatic duct crosses the anterior scalene muscle to enter the superior margin of the subclavian vein near its junction with the internal jugular vein. Therefore placing a needle above or behind the vein or penetrating both walls could

injure the right lymphatic duct.

- It is however rare when compared to the left hand side. Vellani *et al*⁸ reports one case where the thoracic duct was injured via the left subclavian vein. The chylous discharge however stopped after four days.
- Even on the left this complication is extremely rare³⁴. Hinckley⁴⁸ reports on a bilateral fatal chylothorax secondary to a thrombus surrounding a central venous catheter with occlusion of the thoracic duct. Although this complication may be rare according to the literature, the morbidity associated with it is high. Tachypnea and hypotension progressing to sudden death due to a chylothorax is described. Shock develops after a latent period of lymph collection in the extrapleural space, then rupturing through the pleura. A chylothorax may be resolved by ligating a leaking thoracic duct, or spontaneously through development of adequate collateral circulation⁴⁸.

6.12 Accidental mediastinal entry

- Albertson *et al*³⁹ reports on two cases of cannulation of the left internal jugular vein with mediastinal entry, and warns of the need for extreme caution when using this vein. This may be explained by a venous anomaly: The most common variant of systemic venous drainage is a persistent left superior vena cava. It occurs in 0,3% of persons with otherwise normal hearts, and in 4.3% of patients with congenital heart disease³⁸. It may also be due to cannulation of the left pericardiophrenic vein, and subsequently entering the mediastinal space as reported by Weeden *et al*⁴⁰.

6.13 Hydrothorax^{27,29}

- This complication develops when both the intrathoracic vein and pleura or pleura alone are perforated by the catheter. The intravenous fluid leaks out into the pleural space and gives the picture of a pleural effusion. Again this complication is seen in too deeply placed catheters⁵⁵. The hydrothorax may be bilateral because of the presence of congenital or acquired interpleural communications²⁰. Allsop *et al*²⁴ reports a case of actual cannulation of the pleural space. This should be recognized at the time of insertion by failing to aspirate blood as the cannula is advanced and by lowering the whole infusion set below the level of the patient to observe the reflux of blood.

6.14 Hydromediastinum

- This is a rare complication, but has been documented by Adar *et al*¹⁶. In their case, the movement of the catheter relative to the fixed subclavian vein, caused the tip of the catheter to perforate the brachiocephalic vein with resultant leakage into the mediastinum. The negative pressure in the mediastinum during inspiration, would encourage continuous leakage.

6.15 Phrenic nerve injury

- Both Drachler *et al*²² and Obel²³ reported on phrenic nerve damage after subclavian vein catheterization, with a resulting paralysis of the hemidiaphragm. This can be fatal in a patient whose respiratory function is compromised.
- The phrenic nerve runs on the anterior scalene muscle, immediately behind the subclavian vein at the puncture point²³. It is therefore surprising that this nerve is not injured more frequently. The nerve may also be anaesthetized by the local anesthetic injected at the site of catheter insertion. In this case, rapid recovery of diaphragmatic movement will occur.

6.16 Horner's syndrome

- Damage to the sympathetic chain is possible as it has a close relation to the subclavian artery. Briscoe *et al*³¹ have reported a patient with a lesion of the cervical sympathetic chain after internal jugular vein cannulation.

6.17 Catheter embolization

- This especially happens in catheter through needle devices. A high mortality is reported and Propp *et al*¹⁸ points out various complications following embolization of a catheter such as arrhythmias, venous thrombosis, myocardial perforation and pulmonary embolism. Transvenous techniques are used to retrieve the catheter, or otherwise surgery may be necessary.
- Physical damage to the catheter can result in a small piece of catheter embolizing in the blood stream. Predisposing factors include the use of a catheter through needle device. The sharp point of the needle can easily damage the catheter, especially when the catheter is withdrawn slightly⁵⁵. A catheter through cannula device should always be used. A poorly fixed catheter may also predispose to catheter embolization. Signs and symptoms suggesting catheter embolism include shortness of breath, palpitations and dysrhythmias on ECG.

6.18 Hoarseness

- Theoretically the vagus nerve may be injured when both the internal jugular and subclavian vein is cannulated, by injuring the vagus and therefore the recurrent laryngeal branch posterior to the internal jugular vein²⁹.

6.19 Massive subcutaneous air development

- The development of subcutaneous air may be severe enough to cause respiratory distress⁴⁵. Smith *et al*⁴⁶ reported two patients who needed a tracheostomy due to a compromised airway after subclavian vein catheterization.

6.20 Thrombosis

- Thrombosis may occur, due to intimal damage caused by the catheter, which acts as a foreign body in the vein. Thrombosis is more commonly seen in longterm catheterizations. Brown *et al*⁶¹ reports on a case of superior vena cava thrombosis in a patient with a longterm central venous line for parenteral nutrition.

6.21 Laceration of the internal thoracic artery

- Larsen *et al*⁴⁹ reported on lacerating the internal thoracic artery from an attempt to catheterize the subclavian artery, with resulting bleeding in the mediastinum requiring a sternotomy.

6.22 Laceration of the ascending cervical artery

- Laceration of the ascending cervical artery with massive hemothorax was reported by Wisheart *et al*⁵¹ after the internal jugular approach.

6.23 Prevention of complications

To keep complications to a minimum, the following basic factors need to be observed²⁷:

- The indications for central venous catheterization should be carefully considered.
- Thorough acquaintance of the clinical anatomy of the subclavian and internal jugular vein as well as their neighboring structures. Meticulous technique should be followed.
- There is no substitute for experience. Most complications are found in the hands of inexperienced operators.
- Awareness of the complications, their frequency and reason for occurrence is very important. The reason for the complications can in almost every instance be explained by the regional anatomy.

7. References.

7.1 Scientific papers

¹ Blitt CD, ed. Monitoring in Anaesthesia and Critical care medicine. Central venous pressure monitoring. New York, NY: Churchill Livingstone, 1985:121-165

² Lum PS, Soski M. Management of malpositioned central venous catheters. J Intravenous Nursing. 1989 Dec;12:356-365

³ Cahill DR. Lachman's case studies in anatomy. New York, Oxford: Oxford University Press, 4th ed, 1997:94

⁴ Greenall MJ, Blewitt RW, McMahon MJ. Cardiac tamponade and central venous catheters. British Medical Journal 1975;2:595

⁵ Childs D, Wilkes RG. Puncture of the ascending aorta – a complication of subclavian venous cannulation. Anaesthesia 1986;41:331

- ⁶ Rosen M, Latto P. Handbook of percutaneous central venous catheterization. London, Philadelphia, Toronto, Sydney, Tokyo: WB Saunders Company 2nd edition, 1992:101
- ⁷ English ICW, Frew RM, Pigott JF et al. Percutaneous catheterization of the internal jugular vein. *Anaesthesia* 1969;62:97
- ⁸ Vellani CW, Tildesley G, Davies LG. Endocardial pacing: a percutaneous method using the subclavian vein. *British Heart Journal* 1969;31:106
- ⁹ Ryan DW. Lymph leakage following catheterization of the right subclavian vein. *Anesthesia and Analgesia* 1978;57:123
- ¹⁰ Matthews NT, Worthley LIG. Immediate problems associated with infraclavicular subclavian catheterization; a comparison between left and right sides. *Anesthesia and Intensive Care*. 1982;10:113
- ¹¹ Boon JM, Richards PA, Baumbach J, Scholtz L. Left or right access for successful central venous catheterization – the anatomical answer: a preliminary study. *Clin Anat* 1999;12:199-212 (Abstract)
- ¹² Abrahams PH, Webb P. *Clinical anatomy of Practical procedures*. London: Pitman Medical, 1975: 32
- ¹³ Dronen SC, Younger JG. Central catheterization and central venous pressure monitoring. In: *Procedures for primary care physicians*. Pfenninger JL, Grant CF. St Louis London: Mosby 1994: 270
- ¹⁴ Bazaral M, Harlan S. Ultrasonic anatomy of the internal jugular vein relevant to percutaneous cannulation. *Crit Care Med* 1981;9:307
- ¹⁵ Maggs PR, Schwaber JR. Fatal bilateral pneumothoraces complicating subclavian vein catheterization. *Chest* 1977;71:552
- ¹⁶ Adar R, Mozes M. Hydromediastinum. *JAMA* 1970;214:372
- ¹⁷ Flanagan J, Gradisar I, Gross R. Air embolus – a lethal complication of subclavian venepuncture. *N Engl J Med* 1970;281:372
- ¹⁸ Propp DA, Cline D, Hennenfent BR: Catheter embolism. *J Emerg Med* 1988;6:17
- ¹⁹ Collier PE, Ryan JJ, Diamond DL. Cardiac tamponade from central venous catheter: A report of a case and review of the English literature. *Angiology* 1984;35:595
- ²⁰ Sheep RE, Guiney WB. Fatal cardiac tamponade: Occurrence after left internal jugular vein catheterization. *JAMA* 1982;248:1632
- ²¹ Van Haeften TW, Van Pampus ECM, Boot H, et al: Cardiac tamponade from misplaced central venous line in pericardiophrenic vein. *Arch Intern Med* 1988;148:1649
- ²² Drachler D, Kopeke G, Weg J. Phrenic nerve injury from subclavian vein catheterization: Diagnosis by electromyography. *JAMA* 1976;236:2880
- ²³ Obel IW. Transient phrenic nerve paralysis following subclavian venepuncture. *Anesthesiology* 1970;33:369
- ²⁴ Allsop JR, Askew AR. Subclavian vein cannulation: A new complication. *Br Med J* 1975;4:262
- ²⁵ Oakes DD, Wilson RE. Malposition of subclavian lines. *JAMA* 1975;233:532
- ²⁶ Webb JG, Simmonds SD, Chan-Yan C: Central venous catheter malposition presenting as chest pain. *Chest* 1986;89:309
- ²⁷ Hegarthy MM. The hazards of subclavian vein catheterization: Practical considerations and an unusual case report. *S Afr Med J* 1977;52:250
- ²⁸ Hurwitz BJ, Posner JB. Cerebral infarction complicating subclavian vein catheterization. *Ann Neurol* 1977;1:253

- ²⁹ Moosman DA. The anatomy of infraclavicular subclavian vein catheterization and its complications. *Surg Gynecol Obstet* 1973;136:71
- ³⁰ Sterner S, Plummer DW, Clinton J, et al. A comparison of the supraclavicular approach and the infraclavicular approach for subclavian vein catheterization. *Ann Emerg Med* 1986;15:421
- ³¹ Briscoe CE, Bushman JA, McDonald WI. Extensive neurological damage after cannulation of the internal jugular vein. *Br Med J* 1974;1:314
- ³² Paschall RM, Mandel S. Brachial plexus injury from percutaneous cannulation of the internal jugular vein (letter). *Ann Emerg Med* 1983;12:58
- ³³ Russell WJ. Central Venous Pressure. Its clinical use and role in cardiovascular dynamics. London: Butterworths, 1974: 43
- ³⁴ Cobb LM, Vinocur CD, Wagner CW, Weintraub WH. The central venous anatomy in infants. *Surg Gynecol Obstet* 1987;165:230-234
- ³⁵ Eichelberger M, Rous P, Hoelzer D et al. Percutaneous subclavian venous catheters in neonates and children. *J Pediatr Surg* 1981;16:547-553
- ³⁶ Armstrong PJ, Sutherland R, Scott DHT. The effect of position and different manoeuvres on internal jugular vein diameter size. *Acta Anaesthesiol Scand* 1994; 38:229-231
- ³⁷ Mallison C, Bennett J, Hodgson P, Petros AJ. Position of the internal jugular vein in children. A study of the anatomy using ultrasonography. *Paediatric Anaesthesia* 1999;9:111-114
- ³⁸ Godwin DJ, Chen JTT. Thoracic venous anatomy. *AJR* 1986; 147:674- 684
- ³⁹ Albertson TE, Fisher CJ, Vera Z. Accidental mediastinal entry via left internal jugular vein cannulation. *Intensive Care Med* 1985;11:154-157
- ⁴⁰ Weeden D, Abel M. Malposition of a central venous catheter. *Br J Anaesth* 1982; 54:109
- ⁴¹ Aslamy Z, Dewald CL, Heffner JE. MRI of central venous anatomy. Implications for central venous catheter insertion. *Chest* 1998;114:820-826
- ⁴² Alderson PJ, Burrows FA, Stemp LI, Holtby HM. Use of ultrasound to evaluate internal jugular vein anatomy and to facilitate central venous cannulation in paediatric patients. *Br J of Anaesthesia* 1993;70:145-148
- ⁴³ Edwards N, Morgan AR. How to insert a central venous catheter. *Br J of Hosp Med.* 1989;42:312-315
- ⁴⁴ Jesseph JM, Dewey JC, Augustyn GT. Patient positioning for subclavian vein catheterization. *Arch Surg* 1987;122:1207-1209
- ⁴⁵ Mitchell SE, Clark RA. Complications of central venous catheterization. *AJR* 1979;133:467-476
- ⁴⁶ Smith BE, Modell JH, Gaub ML, Moya F. Complications of subclavian vein catheterization. *Arch Surg* 1965;90:228-229
- ⁴⁷ Deitel M, McIntyre JA. Radiographic confirmation of the site of central venous pressure catheters. *Can J Surg* 1971;14:42-52
- ⁴⁸ Hinckley ME. Thoracic-duct thrombosis with fatal chylothorax caused by a long venous catheter. *N Engl J Med* 1969;280:95-96
- ⁴⁹ Larsen HW, Lindahl F. Lesion of the internal mammarian artery caused by infraclavicular percutaneous catheterization of the subclavian vein. *Acta Chir Scand* 1973;139:571-572

- ⁵⁰ Holt S, Kirkham N, Myerscough E. Hemothorax after subclavian vein cannulation. *Thorax* 1977;32:101-103
- ⁵¹ Wisheart JD, Hassan MA, Jackson JW. A complication of percutaneous cannulation of the internal jugular vein. *Thorax* 1972;27:496-499
- ⁵² American Association of Clinical Anatomists, Educational affairs committee. The Clinical anatomy of several invasive procedures. *Clin Anat* 1999;12:43-54
- ⁵³ Malatinsky J, Kadlic T, Majek M et al. Misplacement and loop formation of central venous catheters. *Acta Anaesthesiologica Scand* 1976;20:237
- ⁵⁴ Defalque RJ. Subclavian venepuncture: a review. *Anaesthesia and Analgesia* 1968;47:677-682
- ⁵⁵ Boon JM, Monitoring van resussitasie in 'n perifere omgewing deur perifere sentraal veneuse lyne. *Verhandeling vir MMed(Huisartskunde)* University of Pretoria, 1998
- ⁵⁶ Ellis H, Feldman S. *Anatomy for Anaesthetists*. Oxford: Blackwell Science 7th Ed, 1997: 359-363
- ⁵⁷ Guyton AC, Jones CE. Central venous pressure: Physiological significance and clinical implications. *Am Heart J* 1973;86:431-437
- ⁵⁸ Krog M, Berggren L, Brodin M, Wickbom G. Pericardial tamponade caused by central catheters. *World J Surg* 1982;6:138-143
- ⁵⁹ Shimada K, Sato I. Morphological and histological analysis of the thoracic duct at the jugulo-subclavian junction in Japanese cadavers. *Clin Anat* 1997;10:163-172
- ⁶⁰ Mathers LH, Smith DW, Frankel L. Anatomic considerations in placement of central venous catheters. *Clin Anat* 1992;5:89-106
- ⁶¹ Brown RA, Millar AJW, Cywes S. Central venous catheters. Technique and experience at Red Cross War Memorial Children's Hospital, Cape Town, 1987-1990. *S Afr Med J* 1991;80:11-13
- ⁶² Beck GS. Acute and chronic compression of the heart. *Am Heart J* 1937;14:515

7.2 Published books

- American College of Surgeons, Committee on Trauma. *Advanced Trauma Life Support Course for Physicians Student Manual*. Chicago: American College of Surgeons, 1993: 97-98
- VanderSalm TJ, Cutler BS, Wheeler HB. *Atlas of Bedside Procedures*. Boston(Mass): Little, Brown, 1979
- Abrahams PH, Webb P. *Clinical anatomy of Practical procedures*. London: Pitman Medical, 1975: 31-35
- Dronen SC, Younger JG. Central catheterization and central venous pressure monitoring. In: *Procedures for primary care physicians*. Pfenninger JL, Grant CF. St Louis London: Mosby, 1994: 270
- Donnelly JF, Passmore JM, Jr. Central Venous Catheter insertion. In: *Procedures for primary care physicians*. Pfenninger JL, Grant CF. St Louis London: Mosby, 1994: 304
- Ford MJ, Munro JF. *Practical procedures in clinical medicine*. Edinburgh: Churchill Livingstone, 1980: 18
- Rosen M, Latta P. *Handbook of percutaneous central venous catheterization*. London, Philadelphia, Toronto, Sydney, Tokyo: WB Saunders Company 2nd edition, 1992: 101
- Cahill DR. *Lachman's case studies in anatomy*. New York, Oxford: Oxford University Press 4th ed. 1997: 94

Russell WJ. Central Venous Pressure. Its clinical use and role in cardiovascular dynamics. London: Butterworths, 1974: 43
 Roberts JR, Hedges JR. Clinical procedures in emergency medicine. Philadelphia; London: Saunders, 3rd ed, 1998
 Hall IP. Insertion of a central venous line. In: Essential Medical Procedures. Toghil PJ London, Sydney, Auckland: Arnold, 1997: 11-17
 Shami SK, Hassanally DA. Manual of ambulatory general surgery: a step-by step guide to minor and intermediate surgery. London: Springer, 2000: 29-33

Table 1. Complications for central venous catheterization, modified from Hegarthy's classification²⁷.

Minor	Major
Failure to puncture the vein Failure to advance the catheter Catheter dislodgement Subcutaneous infusion Subcutaneous infection	Damage to structures in the proximity of the puncture site: Pleura - Pneumothorax Subclavian artery Brachial plexus Thoracic duct Other vessels: Common carotid artery Internal thoracic artery Ascending cervical artery Other nerves: Phrenic nerve Sympathetic chain Recurrent laryngeal nerve
	Damage to structures away from the puncture site: Superior vena cava Right atrium Blood vessels: Ascending aorta, pulmonary artery Mediastinum Pericardium, pericardial space
	Functional Overtransfusion Air embolism Dysrhythmias Catheter embolism Thrombosis
	Infection Bacterial Fungal

4.4.1.5 Pericardiocentesis

1. Indications	153
2. Contraindications	153
3. Step by step procedure	153
4. Materials	154
5. Anatomy pitfalls	154
6. Complications (anatomically relevant)	158
7. References	162

1. Indications

- Cardiac tamponade may present as an emergency, for example after a knife stab wound of the thorax. Many stab wounds of the heart can be treated initially by means of a single or multiple pericardiocenteses¹⁰. This procedure is done to relieve pressure in the pericardial sac on the heart, while arranging to perform a thoracotomy¹⁷. The risk of recurrence is high and the procedure should be considered before a patient can get to theatre. Cardiac tamponade, or compression of the heart by fluid or blood in the pericardial sac, may develop rapidly after heart injury¹⁰. It will temporarily improve the patient's hemodynamic situation². This is illustrated in a case report by Eisenman *et al*¹⁷ where a pericardiocentesis was performed on a patient with an acute hemopericardium secondary to cardiac rupture after a myocardial infarction, with resultant hemodynamic improvement. After performance of the pericardiocentesis, the patient was transferred to the operating room. It should not delay the performance of a thoracotomy and there should be a readiness to proceed to surgery. When done correctly, the procedure can be performed at a low risk¹¹.
- Rapid collection of pericardial effusion. Diagnostic and therapeutic pericardial effusion drainage should be done with echocardiographic guidance¹⁹.
- Diagnostic – In an elective situation under sonographic guidance.

2. Contra-indications

- Facilities for cardio-respiratory resuscitation should ideally be available.
- Trombocytopenia and anticoagulant therapy are relative contraindications³.

3. Step by step procedure

Occasionally drainage of cardiac tamponade is done with the subxiphoid approach as a matter of great urgency and a large bore needle is used¹⁰. However, usually there are a few minutes to perform a complete and controlled aspiration⁷. If possible, echocardiographic demonstration of fluid in the pericardial space, to confirm the clinical diagnosis, should be considered before performing the procedure¹³.

1. Monitor the patient's vital signs, CVP and ECG before, during and after the procedure. Send a blood specimen to the laboratory for blood grouping.
2. The defibrillator should be ready.
3. Surgically prepare the xiphoid and subxiphoid areas and locally anesthetize the area if time permits. Position the patient in a supine position.
4. Use a 16 to 18-ga, 15 cm long catheter over a needle device, attached to a 20 cc syringe. Connect the chest terminal (V) of the ECG using a crocodile clip.
5. Assess the patient for any mediastinal shift that may have caused the heart to shift significantly.
6. The needle is inserted into the angle between the xiphisternum and the left costal margin at about 45° to the anatomical transverse plane⁷, directing the needle towards the left shoulder.
7. Carefully advance the needle and aim toward the tip of the left scapula. After advancing the needle to the inner aspect of the rib cage, the needle is cautiously advanced 5 to 10 mm until fluid is reached. A distinctive 'give' may be sensed when the needle penetrates the parietal pericardium. The needle should be advanced slowly with continuous negative pressure created by the syringe.
8. If the needle is advanced too far, an injury pattern (e.g. extreme ST-T wave changes or widened and enlarged QRS complex) appears on the ECG monitor⁶. If this appears, withdraw the needle until the previous baseline ECG tracing reappears²⁴. This occurs secondary to irritation of the ventricular myocardium. Should the injury pattern persist, withdraw the needle completely. PR segment elevation is present with atrial contact⁸.
9. When the needle tip enters the pericardial sac, withdraw as much nonclotted blood as possible. Advance the catheter and withdraw the needle.
10. After aspiration, remove the syringe and attach a stopcock. Secure the catheter in place.
11. Should the cardiac tamponade persist, the stopcock may be opened and the pericardial space aspirated again.

With an acute traumatic cardiac tamponade, aspiration of as little as 10-50 ml may greatly relieve cardiac output.

4. Materials

- ECG (electrically isolated machine)
- 16 to 18-ga 15 cm long catheter over a needle device, 18-ga spinal needle with obturator
- 20 cc syringe
- Defibrillator at hand
- Ready theatre and surgeon / speedy arrangement for transferring patient

5. Anatomical pitfalls

5.1 Subxiphoid approach.

- The needle is inserted into the angle between the xiphisternum and the left costal margin at about 45° to the anatomical transverse plane^{7,15,20,21}, directing the needle towards the left shoulder.
- The needle advances about 6 to 8 cm from the skin in an adult and 5 cm or less in children before reaching the pericardium¹⁰.
- This approach has been criticized by some authors for causing greater number of injuries, usually to the right atrium. Instead an echocardiographic-directed pericardiocentesis has been proposed in the intercostal space near the apex of the heart¹⁹. A cadaver study demonstrated greater safety with a parasternal approach in the fifth intercostal space⁵. There are however studies showing a greater risk of a pneumothorax when parasternal and intercostal approaches are used⁵. During a so-called blind pericardiocentesis, the subxiphoid approach is recommended. A blind pericardiocentesis means that the needle is not echocardiographically directed.
- This approach enters the fibrous pericardium, where it is in direct contact with the chest wall, and not covered with pleura due to the pleural recess (cardiac notch)
- The needle pierces through the skin, superficial fascia, anterior rectus sheath (as it comes off the costal cartilage) and the left rectus abdominis muscle. Thereafter it pierces the posterior rectus sheath (transversus abdominis muscle) and over the dome of the diaphragm and through the fibrous and parietal serous pericardium¹⁸.
- In the supine position, most of the fluid/blood in the pericardial space is located laterally, inferior and posterior to the heart. The safest access route is therefore the subxiphoid route. Furthermore, this approach holds very little risk of injuring the lung¹⁰.

5.2 Parasternal approach

- The needle is placed perpendicular to the skin in the 5th intercostal space medial to the border of cardiac dullness. This route is not advised due to the risk of injuring the internal thoracic artery³, as well as causing a pneumothorax⁵. Lung inflation brings the edge of the lung closer to the needle.

5.3 Apical approach

- A less commonly used approach is where the needle is placed 1cm outside of the apex beat in the intercostal space, within the area of cardiac dullness. The needle is directed to the right shoulder⁷. If the apex beat is not palpable, insert the needle through the skin just inside the area of cardiac dullness. This area is close to the lingula and left pleural space and is therefore more likely to result in a pneumothorax, although there is a bare area over the cardiac apex where pleura is usually absent²³. The pericardial sac is superficial here and has a relatively large

transverse diameter. There is therefore minimal risk to injure the pleura, myocardium, liver or lung³. Theoretical arguments are held for this technique, such as there are smaller sized vessels near the heart apex⁷ and the thicker wall of the left ventricle that can seal off if punctured. However, piercing the left ventricle has a higher incidence of ventricular fibrillation¹¹. The arteries are however by no means invulnerable. Clarke *et al*³ advises the puncture site to be identified ultrasonically. They regard the apical approach as the best site of insertion, with the patient in the left posterior oblique position to allow fluid to accumulate around the apex of the heart. This may be done in elective patients, but is not indicated in the emergency situation.

5.4 ECG changes

- There is an obvious change in the ECG when the needle touches the myocardium. The purpose of using an ECG is to prevent ventricular puncture. An injury pattern can occur when touching the ventricular wall. - e.g. extreme ST-T wave changes or widened and enlarged QRS complex⁶. Careful attention should also be paid to the PR segment as well as the ST segment during the procedure⁸. The appearance of these changes is a signal to withdraw the needle²⁴.
- If ST segment elevation or PR segment elevation are seen, this may signal contact between the needle and an intact pericardium immediately overlying the heart with no fluid in the pericardial sac. If however bloody fluid is obtained from the needle in the absence of these ECG changes, it signifies that fluid has been obtained from the pericardial sac and not from the chambers of the heart²⁴.
- If the needle touches the ventricle, marked ST segment elevation²⁴ or ventricular ectopic beats can be seen⁷.
- Contact with the atrium can cause atrial dysrhythmias, change of P-wave morphology, elevation of the PR segment, atrial arrhythmias or atrioventricular dissociation⁸. Previous myocardial injury may obscure the current generated by the needle touching the myocardium⁹. Sobol *et al*⁹ reported a case where a myocardial laceration occurred without electrocardiographic recording, due to the needle entering a metastatic tumor, which is electrically silent.
- ECG monitoring should only be used with fully isolated electrical equipment. Currents may be responsible for ventricular fibrillation during the procedure⁷.

5.5 Ultrasound guided insertion

- Blind performance is reported to cause possible perforation of the heart and can lead to death¹³. Therefore, elective pericardiocentesis is currently done with ultrasound fluoroscopic guidance¹² minimizing cardiac injury by visualizing the relation of the tip of the needle to the surrounding organs.
- Ultrasound guided pericardiocentesis has the advantage that fluid depth and

quantity can be assessed and fluid location can be detected³. The site of entry can be determined where the fluid or blood is closest to the chest wall and where the needle track avoids any underlying vital structures¹⁹.

- However this high technology equipment is not available in an emergency department. Therefore, the complication rate of the procedure will naturally be higher.

5.6 Xiphoid process

- The xiphisternum articulates with the posterior aspect of the body of the sternum, occasionally making palpation difficult⁷. However with the easily identifiable costal margin, the position of the xiphisternum can be predicted. Deep palpation in the area may be uncomfortable.

5.7 Pericardium

- The distance from the skin to the pericardium is 6 to 8 cm in an adult and 5 cm or less in a child¹⁰.
- The pericardium can stretch to accommodate 2-3 liters of fluid. If the increase in fluid occurs over a long period of time, there will be a very gradual increase in intrapericardial pressure. However, less than 100 ml of fluid or blood accumulating rapidly may sharply increase intrapericardial pressure and may be fatal. The patient presents with shock (arterial hypotension) distended neck veins and diminished or absent heart sounds. This is also referred to as Beck's triad²². The liver is normal in size due to the fact that in the acute situation there is no time for it to enlarge. The same is true for the development of ascites and subcutaneous edema. Cardiac output may drop acutely, even when arterial pressure stays at reasonable levels. Venous pressure is therefore regarded as a better indicator for cardiac tamponade¹⁰.
- The pericardium is extremely sensitive due to its extensive innervation by the phrenic nerve. Therefore, when touching it with the needle pain is experienced. This may also reassure the operator that he is in the correct space⁷.

5.7 Coronary vessels

- These vessels may be injured if the needle after piercing the pericardium is not drawn slightly backward until the injury current disappears from the ECG. The operator should be aware that due to motion of the heart the needle can still touch the myocardium from time to time.
- Lying in the anterior interventricular sulcus are the anterior interventricular artery and vein.
- **Marginal artery**

The marginal artery courses on the acute angle of the right ventricle, where the pericardium reflects to become the diaphragmatic pericardium. It is at risk of being injured during the procedure⁷.

5.8 Liver

- An angle of below 45 degrees may let the needle enter the peritoneal cavity and injure the liver and stomach¹⁸. Entering at 45 degrees the needle enters the pericardium at the angle at which it becomes the diaphragmatic pericardium. It thus avoids the diaphragm and enters the fibrous pericardium and parietal serous pericardium.
- The left lobe of the liver is situated in close relation to the xiphisternum, especially in the presence of hepatomegaly⁷.

5.10 Right ventricle

- The needle enters the pericardial sac more or less where the pericardium reflects acutely to become the diaphragmatic pericardium. In this angle lies the margin of the rather thin walled right ventricle⁷.

5.11 Right atrium

- Because of its thin wall, it is extremely dangerous to enter the right atrium with the needle. This is more likely to happen if the needle is directed towards the right shoulder⁵ instead of the tip of the left scapula⁶.

5.14 Direction of needle

- Aim towards the tip of the left scapula⁶. Other recommendations include directing the needle to the right shoulder, the left shoulder and even the sternal notch⁷. One anatomical study demonstrated that the subxiphoid approach is likely to injure the right atrium when aiming at the right shoulder⁵. Aiming for the left shoulder directs the needle to either the right or left ventricular wall. If the needle is directed towards the tip of the left left scapula it is more likely to pierce the right ventricle. If it were to pierce the left ventricular wall, there is a higher incidence of ventricular fibrillation¹¹.

6. Complications (anatomically relevant)

- Anatomically, both the amount and the location of pericardial fluid or blood are important. Most complications of the procedure are due to the needle either touching or penetrating the heart. Therefore the more fluid or blood there is between the myocardium and pericardium the less chance of a complication. In an

echographic study, Wong¹¹ found that the width of the anterior clear space as seen with an echocardiogram (reflecting the amount of pericardial fluid) correlates significantly with the increase of complications.

6.1 Cardiac muscle perforation.

- Most perforations occur in the right ventricle⁸. Authors differ on the adverse effect of ventricular puncture². Most right ventricular perforations are without adverse effect¹¹, but some are fatal^{12, 13, 16}. The right ventricle is usually punctured on its inferior surface. Due to the lower pressure in the ventricle, bleeding is not as severe when compared to the left, but is more vulnerable to laceration due to the thinner ventricular wall.
- Cardiac puncture with hemopericardium is the prime risk, which can occur despite the use of an ECG.
- Preis *et al*⁴ demonstrated the development of an intrapericardial thrombus developing in 24 hours, by slow-motion analysis of a two-dimensional echocardiogram, after a needle has penetrated the right ventricular myocardium.
- Duvernoy *et al*¹² reported complications in 352 cases where a pericardiocentesis was performed. They found three cardiac perforations which were regarded as major complications. A total of 23 (6.5%) accidental cardiac perforations occurred.
- Accidental cardiac perforation with a fine needle seems to be a minor complication, as long as the needle is directed towards the anterior diaphragmatic border of the right ventricle. Due to the contractility of the myocardium, the canal produced by a fine needle soon closes after withdrawal of the needle.

6.2 Cardiac arrhythmias

- Arrhythmias may also occur as a result of the cardiac tamponade itself¹².
- Ventricular fibrillation – Due to puncture of either the right or left ventricle. Inadvertent right ventricular puncture is less hazardous than left ventricular puncture. This may require DC cardioversion. Premature ventricular contractions occur most commonly. The incidence of ventricular and atrial dysrhythmias is rare¹¹.
- Krikorian *et al*¹³ describes one series of 123 patients presenting during 6 years in a specialized unit where one episode of ventricular tachycardia was observed. This episode was reverted with intravenous lignocaine.

6.3 Puncture of coronary arteries

- The right coronary artery is more at risk of injury than the left coronary artery¹².
- One study reports the injury of a coronary vessel with a subsequent hemopericardium¹³. Lacerations have also been reported in human cadaver studies^{5, 14}.
- Duvernoy *et al*¹² reports a case where the posterior descending branch of the right coronary artery was injured. To avoid injury to this artery, the needle should be directed towards the tip of the left scapula and the anterior diaphragmatic border of the right ventricle.
- Brown *et al*⁵ reports in an autopsy-based study of 20 cases, where the subxiphoid approach was used aiming at the left shoulder, injury to the distal or marginal branches of the right coronary artery was found in 3 cases.

6.4 Pneumothorax

- Pericardiocentesis can lead to a pneumothorax because of the close relation of the pleura and the pericardial spaces.
- Duvernoy *et al*¹² reports in a series of 352 patients only two cases with the complication of a pneumothorax. These were both children. Since the subxiphoid approach was used, it seems that this is a safe route in adult patients as far as the risk of a pneumothorax is concerned.
- The approach makes it unlikely for the lung or pleural tissue to be injured due to the reflection over the cardiac notch, however this can occur¹. A Chest X-ray should be performed after the procedure. Most pneumothoraces that were reported have been without clinical consequences.

6.5 Hypotensive episodes.

- This is due to vagal stimulation, which is inevitable during the procedure¹³. These episodes can be associated with bradycardia in which case appropriate administration of atropine, intravenous fluid and elevation of the legs if necessary.

6.6 Puncture of right atrium

- Puncturing the atria is a major complication and great care should be taken to avoid it. The atria have a thin and poorly contractible myocardium¹². A canal caused by a needle is therefore unlikely to close after withdrawal of the needle.

6.7 Pain after piercing the pericardium.

- Patients that are awake may complain of chest pain as the needle goes through the pericardium. This is due to the sensory innervation of the pericardium by the phrenic nerve on both sides.

6.8 Dry tap

- If most of the pericardial fluid or blood is situated posteriorly or laterally, it will not be reached via a subxiphoid approach⁴.
- Wong *et al*¹¹ has found four false negative pericardiocenteses in a study of 52 patients. Two had a loculated posterior hemopericardium and could not be reached by the anterior subxiphoid approach.
- The needle may have injured the pleura to cause a pneumothorax, the myocardium or coronary vessel to cause a hemopericardium or the peritoneum to cause a pneumoperitoneum.

6.9 Hemothorax

- A hemothorax may develop secondary to arterial injury as well as injury to the pleura³.

6.10 Arterial bleeding

- Duvernoy *et al*¹² reports arterial bleeding from the diaphragm and the left internal thoracic artery. Laceration of this artery cannot always be avoided with the subxiphoid approach, but the risk of injuring the internal thoracic artery is higher when the parasternal approach is used as the artery is more prominent proximally and runs on the lateral side one finger breadth of the sternum.
- The vascular structures of the diaphragm include the inferior phrenic artery.
- Aiming the needle at the tip of the left scapula avoids the diaphragmatic vessels as well as the right coronary artery. Arterial injury may lead to hemopericardium, hemothorax or arteriovenous fistulae³.

6.11 Abdominal and shoulder pain

- Abdominal pain and referred shoulder pain are caused by irritation of the diaphragm via the subxiphoid approach¹².

6.12 Infections

- This is a very rare complication, which can lead to costochondritis, pericarditis and septicemia¹².

6.13 Stomach or colon penetration

- Due to the close relationship of the stomach and the transverse colon in the epigastrium to the subxiphoid placement of the needle, these structures may be injured¹⁸.

6.14 Liver injury

- The left lobe of the liver is closely related to the subxiphoid region and puncturing the liver may lead to leakage of blood or bile³.
- Brown⁵ reports in an autopsy based study on four liver punctures using the subxiphoid approach aiming at the tip of the left shoulder.
- The risk of injuring the liver is higher if the needle is inclined below the suggested 45° to the transverse plane of the patient¹⁸.

7. References

- ¹ Ford MJ, Munro JF. Practical procedures in clinical medicine. Edinburgh: Churchill Livingstone, 1980: 112-114
- ² Harper RJ, Callahan ML. Pericardiocentesis and intrathoracic injections. In: Clinical procedures in emergency medicine by Roberts JR, Hedges JR. 3rd ed, Philadelphia; London: Saunders, 1998: 231-253
- ³ Clarke D, Cosgrove D. Real-time ultrasound scanning in the planning and guidance of pericardiocentesis. Clin Radiol 1987;38:119
- ⁴ Preis L, Taylor G, Martin R. Traumatic pericardiocentesis: two-dimensional echocardiographic visualization of an unfortunate event. Arch Intern Med 1982; 142:2327
- ⁵ Brown C, Gurley H, Hutchins G et al. Injuries associated with percutaneous placement of transthoracic pacemakers. Ann Emerg Med 1985;14:223
- ⁶ American College of Surgeons, Committee on Trauma. Advanced Trauma Life Support Course for Physicians Student Manual. Chicago: American College of Surgeons, 1993: 139-140
- ⁷ Treasure T, Cottler L. Practical procedures: How to aspirate the pericardium. Br J Hosp Med 1980;24:488
- ⁸ Kerber R, Ridges J, Harrison D. Electrocardiographic indications of atrial puncture during pericardiocentesis. N Eng J Med 1970;282:1142
- ⁹ Sobol S, Thomas H, Evans R. Myocardial laceration not demonstrated by continuous electrocardiographic monitoring occurring during pericardiocentesis. N Eng J Med 1979;292:1222
- ¹⁰ Baue A, Blakemore W. The pericardium. Ann Thorac Surg 1972;14:81
- ¹¹ Wong B, Murphy J, Chang CJ et al. The risk of pericardiocentesis. Am J Cardiol 1979;44:1110
- ¹² Duvernoy O, Borowiec J, Helmius G, Erikson U. Complications of percutaneous pericardiocentesis under fluoroscopic guidance. Acta Radiol 1992;33:309

- ¹³ Krikorian J, Hancock E. Pericardiocentesis. *Am J Med* 1978;65:808
- ¹⁴ Sabin HI, Coghill SB, Khunti K, McNeill GO. Accuracy of intracardiac injections determined by a postmortem study. *Lancet* 1983;2:1054
- ¹⁵ Dunmire SM, Paris PM. Atlas of emergency procedures. Philadelphia; London: Saunders, 1994
- ¹⁶ Ockene IS. Pericardiocentesis. In: Atlas of bedside procedures. Vander Salm TJ, Cutler BS, HB Wheeler Boston: Little Brown, 1979: 136
- ¹⁷ Eisenman B, Bareiss P, Pasifico AD, et al. Anatomic, clinical, and therapeutic features of acute cardiac rupture. Successful surgical management fourteen hours after myocardial infarction. *J Thor Cardiovasc Surg* 1987 Jul; 76(1):78-82
- ¹⁸ Abrahams PH, Webb P. Clinical anatomy of Practical procedures. London: Pitman Medical, 1975: 24
- ¹⁹ Callahan JA, Seward JB, Nishimura RA et al. Two-dimensional echocardiographically guided pericardiocentesis: experience in 117 consecutive patients. *Am J Cardiol* 1985;55:476-479
- ²⁰ Arom KV, Richardson JD, Webb G et al. Subxiphoid pericardial window in patients with suspected traumatic pericardial tamponade. *Ann Thorac Surg* 1977; 23:545
- ²¹ Santos GH, Frater RWM. The subxiphoid approach in the treatment of pericardial effusion. *Ann Thorac Surg* 1977;23:467
- ²² Beck GS. Acute and chronic compression of the heart. *Am Heart J* 1937;14:515
- ²³ Last RJ. Anatomy – regional and applied. Edinburgh: Churchill Livingstone 7th Ed, 1984: 231
- ²⁴ Bishop LH Jr, Estes EH Jr, McIntosh HD. The electrocardiogram as a safeguard in pericardiocentesis. *JAMA* 1956;162:264-265

4.4.1.6 Vascular access: Venous cutdown, Great saphenous vein

1. Indications	164
2. Contraindications	164
3. Step by step procedure	164
4. Materials	166
5. Anatomical pitfalls	166
6. Complications (anatomically relevant)	169
7. References	170

1. Indications

- Hypovolemic shock with failed access to peripheral blood veins. (Should be done simultaneously with attempts to find a large-bore antecubital vein³)
- Operator not experienced in central venous catheterization.
- Especially useful in children¹¹ and infants of only a few months old^{4,22}.

2. Contra-indications

- If less invasive alternatives exist.
- When excessive delay would be required for the procedure to be performed.
- Previous coronary bypass surgery where the veins have been harvested
- Where hypertonic solutions need to be given intravenously.
- Local inflammatory process.
- History of severe peripheral vascular disease.

Relative contraindications:

- Abdominal trauma¹⁷.
- Lower extremity trauma.

3. Step by step procedure^{1, 2, 4, 10, 19, 20}

With small variations, this procedure is still performed very close to the original description of the procedure by Kirkham⁴ in 1945.

1. Prepare the skin of the ankle with antiseptic solution and drape the area.
2. Infiltrate the skin if time permits. Be careful not to injure the vein for it will obscure the field with blood. Apply a tourniquet high on the thigh.
3. Distal saphenous vein approach: Perform a full-thickness transverse skin incision of 2.5 cm over the vein, 1.5 cm superior and 1.5 cm anterior from the medial malleolus

if the vein cannot be seen¹⁸. The incision should commence at the anterior border of the tibia and extend to the posterior border of the tibia. (The incision should not commence over the anterior compartment of the leg where various muscle tendons including anterior tibialis muscle are found).

4. Identify the vein with blunt dissection and dissect it free from the accompanying structures as well as underlying periosteum. Take care to separate the saphenous nerve from the vein. Randolph⁵ refers to this step as the key to the procedure. Delivering the vein can be accomplished with a curved mosquito hemostat, twisting it firmly down through the incision to the periosteum and with a sweeping motion passing posteriorly to the vein to deliver it.
5. Elevate and dissect the vein for a distance of approximately 2-cm, to free it from its bed.
6. Ligate the distal, mobilized vein, leaving the suture in place for traction in the case of the distal great saphenous vein. If the proximal great saphenous vein is used, do not ligate the vein.
7. Pass a tie about the vein more proximally.
8. Make a small transverse incision (venotomy) and gently dilate the venotomy with the tip of a closed mosquito hemostat. Use the hemostat as a stage on which to perform the venotomy¹⁵.
9. No ligation, tying or incision of the vein is necessary if a standard intravenous (IV) catheter with a standard large lumen IV catheter is used. The vein is then punctured under direct vision, the cannula is threaded into the vein, and the needle is withdrawn to the skin surface.
10. Introduce a cannula through the venotomy and secure it in place by tying the upper ligature about the vein and cannula. The cannula should be inserted with adequate distance to prevent dislodging.
11. Attach the intravenous line to the cannula.
12. Stitch the catheter in place and close the incision with skin sutures.
13. Secure the catheter to the skin with adhesive tape after applying topical antibiotic ointment over the incision.

Alternative methods:

- Shiu¹⁰ describes a method where the skin is cut but the vein is not dissected, but subcutaneous tissue still covers the vein. The vein is also not ligated, but a catheter over needle device is inserted into the vein like any standard intravenous catheter. After inserting the catheter, the tissue is approximated with a stitch, thus preventing bleeding from around the catheter. The problem with ligating the vein is that it will never be suitable for reuse in the future¹⁶.
- A method where a small venotomy of 1-2 mm and a standard Seldinger wire-guided catheter are used has been described by Shockley *et al*¹⁶ and Klofas *et al*¹⁶. A wire-dilator-catheter assembly is passed into the lumen of the vein. The venotomy is then dilated to fit the catheter. Thereafter the wire and dilator are removed from the catheter. In a randomized, prospective crossover

study¹⁶, it was shown that the performance of the wire-guided technique was 22% faster on average compared to the classic technique.

Alternative veins:

- Great saphenous vein at the groin level.
- Basilic vein proximal and medial to the cubital fossa¹⁸.
- Cephalic vein at the wrist¹⁸.

4. Materials¹⁸

- Tourniquet
- Antiseptic skin preparation
- Sterile gloves and drapes
- Local anesthetic solution
- 3cc syringe with 25-ga needle
- Silk ligatures
- Nonabsorbable skin suture
- Tissue dissection scissors
- Needle holder
- Mosquito hemostat
- No 11 scalpel blade
- IV catheter – large-bore catheters preferred¹⁷. (A large bore catheter by itself does not guarantee high flow rates. The tubing size, fluid type and temperature also play an important role.)
- Forceps
- Intravenous fluid setup
- New Seldinger wire guided catheter if available¹⁵. (The use of this catheter makes tying off the distal vein unnecessary.)

5. Anatomical pitfalls

5.1 Distal saphenous vein

- This vein is the classic pediatric cutdown site⁵.
- The great saphenous vein originates on the dorsum of the foot at the medial marginal vein. It runs anterior to the medial malleolus halfway between the medial malleolus and the tendon of the tibialis anterior muscle, one handbreadth posterior to the patella at the knee joint and terminates in the femoral vein, 3 cm inferior to the inguinal ligament⁶.
- The following anatomical characteristics make the great saphenous vein ideal for

use as described by Randolph⁵:

- i) The vein is anatomically most consistently situated just anterior to the medial malleolus⁴.
 - ii) The vein is the only important structure in the region, with no tendons or arteries situated anterior to the medial malleolus. The saphenous nerve running along the vein should be avoided, but if injured has no great clinical implication. (The tendon of tibialis anterior is found in the anterior compartment of the leg).
 - iii) The vein lies on tough periosteum⁴.
 - iv) The vein can be withdrawn from a relatively small incision without injuring the vein. This is due to the elasticity of the vein.
- The great saphenous vein is located in the superficial fat layer. Therefore, if the incision exposes muscle fascia it is too deep. The vein is pulseless and thin-walled. The vein does not disrupt other emergency actions like taking arterial blood from the femoral artery, chest compressions in CPR etc. The vein has a very constant location: crosses one fingerbreadth anterior to the medial malleolus (or halfway between the medial malleolus and the anterior tibialis muscle) and continues up the anteromedial aspect of the leg.
 - Surface anatomy: one fingerbreadth anterior to the medial malleolus with the incision 1.5 cm anterior and superior to the medial malleolus⁹. Similar descriptions are given by others^{4,5}. In a normal volemic patient the vein can usually be identified by these methods. However, in a severely hypovolemic patient, it is difficult to identify the vein and distinguish the empty vein from the saphenous nerve and underlying periosteum¹⁴. Simon *et al*¹⁴ describes the incision to be made just above the medial malleolus, extending from the anterior tibial shin to the posterior border of the tibia. A curved hemostat is then advanced posterior to all the tissue within the incision. When spreading the tissue apart, all the structures can be identified. The saphenous vein can be easily distinguished from the white periosteum of the tibia. Simon *et al*¹⁴ have compared their anatomically based method to identify the vein, with previously identified methods^{4,5}. They found that the vein was identified in significantly less time. They did not use estimated measurements like fingerbreadths or centimeters because of individual patient variance. Their method also allows for easy memorization, a very important aspect in any emergency situation.
 - A method with a guide wired catheter by Shockley *et al*¹⁶ has been shown to be easier and 22% faster.
 - Klofas¹⁵ described the incision line as two finger breadths proximal to the medial malleolus, with a length of the anteromedial surface of the tibia. The incision should be through the skin, but not significantly into the subcutaneous tissue, for the vein is often just subcutaneous.

5.2 Proximal great saphenous vein

- Venous cut downs can also be performed at the proximal great saphenous vein at the groin level, the basilic vein in the cubital fossa and the cephalic vein²¹ at the wrist.
- The proximal great saphenous vein lies in the subcutaneous fat along the anteromedial aspect of the thigh with an outside diameter of 4-5mm⁶. This outside diameter permits a high rate of infusion.
- Proximal saphenous vein approach¹⁴: Make a horizontal incision of skin only from the point where the scrotal or labial fold meets the medial thigh and extend it laterally to a point past a vertical line coming from the lateral aspect of the pubic tubercle. The vein is found most frequently where an imaginary line running from the lateral aspect of the pubic tubercle crosses a horizontal line on the level where the scrotal or labial fold meet the medial aspect of the thigh. The vein is found in the superficial fat. The proximal saphenous vein is more easily identified by this method, compared to the description of making an incision on the anterolateral thigh parallel to the inguinal ligament and about 5-6 cm distal to it⁶.
- Another method: An incision is made at a point 3 to 4 cm below and lateral to the pubic tubercle¹².
- Schiowitz method¹³: The line of incision to find the proximal saphenous vein is found inferior to the groin skin crease, just medial to a perpendicular line dropped from the midinguinal point. The vein is identified and a venotomy done to pass bladder irrigation tubing. This ensures high flow rates (1330 ml/min) when compared to a 16F Foley (500ml/min) and 14F Foley (237ml/min) catheter. This study illustrates the point that large bore access is essential in severe hypovolemic states. This is consistent with Pouseille's law, which states that flow is proportional to catheter diameter. Cannulation of the great saphenous vein can be a good alternative when skill is lacking in gaining central venous access which is sometimes associated with higher complication rates.

5.3 Periosteum

- The great saphenous vein lies adjacent to the tibial periosteum

5.4 Saphenous nerve

- The nerve runs alongside the great saphenous vein. Injury to the nerve leads to sensory loss over a small area alongside the medial aspect of the foot. A longitudinal incision may prevent injury to the nerve, but does not provide sufficient exposure⁷.

- Injury to the nerve can be prevented by separating the nerve from the vein before ligating the vein.

5.5 Medial malleolus

- The great saphenous vein is found anterior to the medial malleolus and the tendons of tibialis posterior and flexor digitorum longus muscles as well as the posterior tibial artery⁵ and posterior to the tendon of the tibialis anterior muscle.

6. Complications (anatomically relevant)

- There is a minimal risk or complications.

6.1 Infection

- There is a higher risk of phlebitis in veins of the lower extremity.
- Septic complications vary, from local suppuration and phlebitis to systemic infection. These are related to the time the intravenous cannula remains in the vein. The infection rate rises from 50% to 78% when the catheter is left in place for more than 48 hours⁸. Moran *et al*⁸ showed that there is a poor correlation between phlebitis and infection. Non-bacteriologic phlebitis is most likely caused by chemical irritation due to the plastic catheter. Early catheter removal is important. Infection at the entry site can be diminished by applying a combined topical antibiotic ointment (containing neomycin, bacitracin and polymyxin) as was shown in a double-blind trial⁸.

6.2 Hematoma

- To prevent hematoma formation a catheter over needle device (standard large lumen IV cannulation set) should be used. The needle should not be larger in diameter than the catheter inserted due to consequent oozing of blood around the catheter which has been advanced through a bigger hole in the vein.

6.3 Time consuming

- The procedure can be time consuming especially if a venotomy is also performed. However, studies show that the time from skin preparation to bandaging averages less than 5 minutes⁵.

6.4 Trombotic occlusion

- This complication is usually seen when the technique of ligating the vein is followed¹⁰. The reuse of the same vein is usually not possible after vein ligation. This may be important in patients needing repeated venous infusions⁴.

- The complication can be avoided by using a different method for surgical cut-down of the vein. Shiu¹⁰ describes a method where the vein is not circumferentially dissected after the skin incision, but after visualizing the vein, a standard catheter over needle device is inserted. Because the catheter lumen is greater in diameter than the needle oozing from the entry site on the vein is minimal. This is additionally prevented by approximating the subcutaneous tissue over the vein by a thin stitch. In this way venous flow is not compromised. The catheter should be secured firmly to the surrounding skin after the procedure.

6.5 Inability to advance the catheter

- This complication may be encountered due to the valves in the vein and is usually found if the initial skin incision is made too far proximally⁴.

6.6 Incising the vein with the initial skin incision

- This complication can be avoided by grasping the skin with toothed forceps in the neighborhood of the incision and lifting it up. The vein is attached to the periosteum and therefore does not lift up with the skin⁴.
- The initial incision should be through the skin, but not through the subcutaneous tissue because the vein is found directly subcutaneously¹⁵.

6.7 Incorrect placement

- The catheter may advance alongside the vein in the subcutaneous tissue. In an exsanguinated patient it may be impossible to aspirate blood from the vein even when the catheter is correctly placed. Indications that the catheter was placed correctly are¹⁵:
 - i) The fact that the catheter was placed into the vein under direct vision,
 - ii) The ease of passage of the catheter and
 - iii) The unrestricted fluid flow through the vein.

6.8 Injury to the vein

- The great saphenous vein may be transected, perforated or the adventitia dissected during the procedure. This will make the vein unsuitable for use¹⁶. The potential for perforation of the posterior wall of the vein is considerably less with the wire-guided technique, compared to using a large bevelled needle¹⁶.

7. References

¹ American College of Surgeons. Committee on Trauma. Advanced Trauma Life Support Course for Physicians Student Manual. Chicago: American College of Surgeons, 1993: 107-110

² Shami SK, Hassanally DA. Manual of ambulatory general surgery: a step-by-step guide

- to minor and intermediate surgery. London: Springer, 2000: 27-28
- ³ Fowler GC. Venous Cutdown . In Procedures for primary care physicians, Pfenninger JL, Grant CF. St Louis London: Mosby, 1994: 332-339
- ⁴ Kirkham JG. Infusion into the internal saphenous vein at the ankle. *Lancet* 1945; 2:815
- ⁵ Randolph J. Technique for insertion of plastic catheters into the saphenous vein. *Pediatrics* 1959; 24:631
- ⁶ Dronen SC, Yee AS, Tomlanovich MC. Proximal saphenous vein cutdown. *Ann Emerg Med* 1981; 10:328
- ⁷ Dronen SC, Lanter P Venous cutdown In: Clinical procedures in emergency medicine by Roberts JR, Hedges JR, 3rd ed, Philadelphia; London: Saunders, 1998: 341
- ⁸ Moran JM, Atwood RP, Rowe M. A clinical and bacteriologic study of infections associated with venous cutdown. *N Eng J Med* 1965; 272:554
- ⁹ VanderSalm TJ, Cutler BS. Atlas of bedside procedures. Boston: Little Brown, 1979: 11-24
- ¹⁰ Shiu MH: A method for conservation of veins in the surgical cutdown. *Surg Gynecol Obstet* 1972; 134:315
- ¹¹ Dunmire SM, Paris PM. Atlas of emergency procedures. Philadelphia; London: Saunders, 1994
- ¹² Abrahams PH, Webb P. Clinical anatomy of Practical procedures. London: Pitman Medical, 1975: 39
- ¹³ Schiowitz MF. A Method for rapid intravenous infusion in shock resuscitation. *Am J Emerg Med* 1998;16:293-295
- ¹⁴ Simon RR, Hoffman JR. Modified new approaches for rapid intravenous access. *Ann Emerg Med* 1987;16:44-49
- ¹⁵ Klofas Ed. A quicker saphenous vein cutdown and a better way to teach it. *The J of Trauma: Injury, Infection, and Critical Care* 1997; 43(6):985-987
- ¹⁶ Shockley LW, Butzier DJ. A modified wire guided technique for venous cutdown access. *Ann Emerg Med* 1990;19:393-395
- ¹⁷ Dutky PA, Stenens SL, Maull KI. Factors affecting rapid fluid resuscitation with large-bore introducer catheters. *J Trauma* 1989;29:856-860
- ¹⁸ Eggertsen SC. Teaching venous cutdown techniques with models. *J Fam Pract* 1983;16(6):1165-1167
- ¹⁹ Knopp R. Venous cutdowns in the emergency department. *JACEP* 1978;7:439-443
- ²⁰ Wax PM, Talan DA. Advances in cutdown techniques. *Emerg Med Clin North Am* 1989;7:65-82
- ²¹ Talan DA, Simon RR, Hoffman JR. Cephalic vein cutdown at the wrist: Comparison to the standard saphenous vein ankle cutdown. *Ann Emerg Med* 1988;17:79-83.
- ²² Wright JE. Cutdown technique for intravenous infusion in infants. *Med J Australia* 1972;37:1203-1206

4.4.2 Office procedures

4.4.2.1 Epistaxis and nasal packing

1. Indications	172
2. Contraindications/ Precautions	172
3. Step by step procedure	172
4. Materials	176
5. Anatomical pitfalls	177
6. Complications (anatomically relevant)	184
7. References	187

1. Indications

- Any continuing episode of epistaxis, despite continuous external pressure of the ala nasi for at least ten minutes.

2. Contraindications

- The use of nasal balloons and catheters should be excluded in massive facial trauma with a suspected skull base fracture as the catheter may travel into the skull cavity.
- Clotting abnormalities. Aggressive nasal packing may cause further bleeding.
- Chronic obstructive airway disease. Posterior nasal packing may result in a significant drop in partial oxygen pressure in these patients
- Known or suspected cerebrospinal fluid leak.

Precaution: Epistaxis may be the presenting symptom of an underlying disease like leukemia, malignancies of the nose, sinuses or nasopharynx, congenital or traumatic arterial-venous malformations and Rendu-Osler-Weber disease³.

3. Step by step procedure

Step 1. Hemodynamic status

- Make sure the patient is hemodynamically stable. Intravenous fluid replacement should be given and the patient be sedated if necessary.

Step 2. History

- Enquire about illnesses like hypertension, angina and chronic obstructive airway disease.
- Many patients with epistaxis are hypertensive as well. However, no direct correlation has been proven between hypertension and epistaxis. Most authors now consider hypertension not to be a cause of epistaxis, but due to anxiety experienced by the patient suffering from the bleeding³. Therefore hypertension does not need treatment until the bleeding is controlled.

Shaheen²⁰ showed that there is an association between epistaxis and cardiovascular disease. Rigid and calcified arteries tend to bleed more persistently.

- Enquire about drug usage.

Step 3. Local compression

- Compression of the ala nasi or soft cartilaginous portion of the nose for at least 10 minutes, with the patient sitting up and leaning forwards to prevent blood from running into the nasopharynx. This will stop most nosebleeds. Pressure is applied directly on Little's area, where most nosebleeds (90%) originate^{2,15,17}. Ice packs across the nose may also help. Compression of the nasal bone has no effect on the nose bleeding at all¹⁵.

Step 4. Position.

- Position the head of the patient horizontally. Tilting of the head only allows inspection of the antero-superior area. Keep the base of the nose parallel to the floor. Let the patient sit upright, in the sniffing position: Head extended on the neck and neck flexed.
- Drape the patient with a gown and let the patient hold an kidney basin to collect bleeding.
- Light sedation can be given if the patient is very anxious.
- Allow the patient to clear his or her nose or use suction.

Step 5. Examination of the nares:

- Insert a nasal speculum in the nose. Good light is essential
- Remove blood clots from the nose and inspect the nose with a good light to find the site of bleeding.
- Identify the source of the bleeding – anterior or posterior by inspection.
- The middle turbinate is a convenient landmark to relate the bleeding to, either above, below, in front or behind.
- If the bleeding is too profuse, administer a topical anesthetic and a vasoconstrictor (lignocaine with epinephrine) on cotton pledgets. Cocaine solution can also be used.
- Most cases of anterior epistaxis occur in Little's area¹⁵. Inspect the area closely for bleeding or ulceration.
- If no anterior source is found and bleeding continues down the nasopharynx, assume a posterior source and pack the nose with an anterior and posterior pack

Step 6. Cautery

- This may be chemical or electrical. Chemical cauterization with silver nitrate is more suitable for use in the Accident and Emergency Department and is ideal in children.

- The bleeding must be visible and accessible.
- In case of an anterior source bleeding, the site can easily be identified and very effectively cauterized. If the site can not be identified, it should be found. A dilated vessel, small crust or heaped-up mucosa may be the source of bleeding³.
- Silver nitrate sticks may cauterize the area, cause sclerosis of the vessels and thickening of the mucosa. Silver nitrate does not cauterize an active bleeding, therefore hemostasis must first be achieved.
 - Cauterize above the bleeding source first.
 - Cauterize around the bleeding source in a circular fashion which will provide hemostasis to cauterize the bleeding source.
 - Wipe away any excess silver nitrate to prevent cauterization of other areas.
 - Cauterization with silver nitrate should be done for at least 20 seconds.
- **Electrocautery** – Electrocautery is done in the same manner as the silver nitrate.
Cauterization is more intense and penetrates more quickly than silver nitrate.
Take care not to perforate the septum due to repeated and aggressive cauterization.
If hemostasis is achieved no nasal packing is necessary. If there is recurrent bleeding the anterior cavity should be packed.

Step 7. Anterior nasal packing

Adequate anesthesia and proper visualization is essential.

- Packing is applied in a layer fashion, Each layer spans the entire length of the nasal cavity. This will prevent the gauze from migrating to the nasopharynx.
- Usually a bismuth iodoform paste pack (BIPP) is used, which is both antiseptic and comforting.
 - Visualize the floor of the nasal cavity.
 - Lay the first layer across the nasal floor.
 - Withdraw the speculum and reintroduce it on top of the first layer.
 - Place a second layer in an identical way.
 - Use a bayonet forceps to push the previously placed packing down onto the floor of the nose.
 - A complete anterior nasal pack, can tamponade a bleeding point anywhere in the nasal cavity.
 - The pack functions by direct pressure on the bleeding site and by causing inflammation and edema of the nasal mucosa³.
 - Remove the pack after 2-3 days, depending on the severity of the bleeding.

- Newly designed tampons can also be used. After insertion, contact with moisture will cause them to swell. An example is the Merocel nasal pack. This pack expands to many times its original size when it is wet. Prophylactic antibiotics should accompany the pack and it should be removed within 48 hours.

Step 8. Posterior nasal packing

- This pack is necessary if no source of bleeding is found anteriorly and the patient continues to bleed down the nasopharynx. Anterior nasal packing will not tamponade this source of bleeding.
- The goal of a posterior pack is to directly compress the sphenopalatine artery or the ethmoidal arteries²⁶.
- Anesthetize the patient's nasal cavity and nasopharynx with a topical anesthetic spray.
- Prepare a roll of gauze, with two no 2 silk ties secured around the middle and extending in opposite directions.
- Place a no 10 rubber Foley's catheter through the bleeding nostril.
- When seen in the oropharynx, grasp it into and out of the oral cavity.
- Attach the Foley's catheter to one of the silk ties secured to the gauze pack. Retract the Foley catheter through the nose, thus carrying the no 2 silk tie through the nasopharynx into and out of the nasal cavity.
- Pull the pack into the nasopharynx
- The tie coming from the nose is to secure the position of the nasal pack
- The tie in the oral cavity will be used to remove the pack and is taped on the cheek, but should not be under any tension for it will cut into the soft palate¹³.
- Pack the anterior nasal cavity as well.
- The pack can be left in for 3 days until oozing has stopped.
- The pack is uncomfortable for patients, and they often need to be sedated.
- Juselius²³ reports on 1724 patients of which 24.8% required posterior nasal packing, 5.6% required some form of surgery and 28.5 percent required blood transfusion.

Alternative 1: Inflatable balloon pack

- Wurman *et al*³ suggests using balloon tamponade for posterior epistaxis, as an emergency measure before referring the patient the next day. It can also be kept in place for two and up to a maximum of three days.
- A Foley's catheter can be very successfully used as a posterior pack^{4, 24}. This is due to direct pressure of the balloon on the bleeding point and by pressure on the turbinates and therefore decreasing the vascularity of the nose⁵. A Foley's catheter is cheap and is usually readily available.
- Insert a no 12F Foley with 30ml balloon through the bleeding nostril into the oropharynx.
- Inflate the balloon half way with half the required volume of saline. Balloon inflation with air deflates over time.

- Slowly pull the catheter into the nasopharynx and secure it against the posterior aspect of the middle turbinate. Then inflate the remainder of the volume.
- This method should minimize discomfort and complications⁵.
- When inflating the balloon before the balloon is in position will require strong anterior pulling which is very uncomfortable and it will be impossible to wedge the balloon into the smaller posterior choana.
- If there is pain or inferior displacement of the soft palate, deflate the balloon until the pain resolves.
- Do not inflate the balloon if it is not in the correct position in the nasopharynx. This will cause ineffective hemostasis⁵.
- A dual balloon pack may also be used. It has a posterior balloon, which is inflated with 10ml of saline, and an anterior balloon, which is inflated with 30 ml of saline. The posterior balloon is located in the posterior aspect of the nasal cavity and proximal nasopharynx, whereas the anterior balloon is in the anterior nasal cavity.
- Wareing describes an improved technique to fixate the Foley's catheter⁴ by using a syringe clamped around the catheter.

Advantages:

- According to Wurman³, the use of a Foley's catheter as a balloon pack is more convenient for the patient compared to a posterior nasal pack.
- If bleeding starts again, more water can be added to the balloon. An amount of 1 cc can be added at a time until bleeding is controlled or maximal balloon volume is reached.
- A balloon pack exerts more pressure directly onto the bleeding site than gauze packing.

Alternative 2: Avitene

Walike *et al*²⁴ reports the use of Avitene. This is an absorbable hemostatic agent made from purified bovine corium collagen. It is applied topically. According to Walike *et al*²⁴ it works effectively.

4. Materials

- Good light, ideally a headlight. An otoscope can also be used.
- Suction.
- Gloves, gown and mask for the physician.
- Topical anesthetic.
- Topical vasoconstrictor.
- Nasal speculum.
- Tongue depressor.
- Scissors.
- Bayonet forceps.
- Kidney basin.

- Gauze.
- Dental rolls or cotton.
- Surgical silk ties.
- Silver nitrate sticks or electrocautery.
- Pediatric Foley catheters and a no 12F Foley's catheter.
- Topical antibiotic ointment.

5. Anatomical pitfalls

5.1 External nose

- The external nose consists of a bony vault, a cartilaginous vault and a lobule. The bony vault consists of the nasal bones, the frontal processes of the maxillae, and the nasal spine of the frontal bone¹.

5.2 Nasal cavity

- The nasal cavity is a pyramidal structure with its base attached to the facial skeleton. The nasal cavity continues posterior with a right angle to the face¹.
- The nasal cavity is divided by the nasal septum into two compartments opening anterior via the nares and posterior via the choanae to the nasopharynx². Each compartment has a roof, floor, medial and lateral wall.
- The mucosal lining of the nose consists of ciliated columnar epithelium, interspersed with mucous-secreting goblet cells.

5.3 Roof of the nose

- The roof of the nasal cavity is formed from anterior to posterior by the nasal and frontal bones, the cribriform plate of the ethmoid bone and posteriorly the downslowing body of the sphenoid bone².

5.4 Nasal septum

- The nasal septum is formed by the perpendicular plate of the ethmoid from superior and the vomer from inferior. Anteriorly attached to these bony structures is the cartilaginous part of the septum. The nasal septum has a free posterior edge¹.
- Deviations of the septum are common (up to 75% of the adult population²) and may be associated with compensatory hypertrophy of the lateral wall which may cause nasal obstruction. Most of the deviated septae are from traumatic origin, probably from minor injuries in childhood causing a minor dislocation of the septal cartilage².

5.5 Nasal lobule

- The nasal lobule consists of the nasal tip, the lower lateral cartilages, the fibro fatty

alae forming the lateral margin of the nostril, the vestibule and columella. The lower lateral cartilages have a medial and lateral crus to form the U-shaped dome of the nasal vestibule to keep the nostril patent¹.

5.6 Lateral wall of the nasal cavity.

- The lateral wall of the nasal cavity is formed by the frontal process of the maxilla anteroinferiorly, the nasal bones anterosuperiorly, the nasal aspect of the ethmoid superiorly and the perpendicular plate of the palatine and medial pterygoid plate behind.
- Three conchae bones forming the three turbinates are found with three meati. The superior and middle concha are part of the ethmoid bone and the inferior concha is a separate bone.
- The paranasal sinuses open to orifices in the lateral nasal wall²:
 - Sphenoid sinus – spheno-ethmoidal recess
 - Posterior ethmoidal cells – superior meatus
 - Middle ethmoidal cells – middle meatus on the bulla ethmoidalis
 - Maxillary sinus – middle meatus in the hiatus semilunaris
 - Anterior ethmoidal cells – middle meatus, anterior to the hiatus semilunaris at the infundibulum
 - Frontal sinus – middle meatus through the frontonasal duct.
 - Nasolacrimal duct – inferior meatus

5.7 Floor of the nasal cavity

- Anteriorly, the floor is formed by the palatine process of the maxilla and posteriorly by the horizontal plate of the palatine bone².

5.8 Conchae

- These horizontal bony ridges project medially from the lateral wall, each overhanging a meatus.

5.9 Meati

- The paranasal sinuses and nasolacrimal duct open into these meati. Of special importance is the nasolacrimal duct opening in the inferior meatus and the maxillary sinus, which opens into the hiatus semilunaris in the middle meatus.

5.10 Blood supply¹

Blood supply to the nose come from the internal and external carotid arteries. The majority comes from the external carotid artery¹³.

There is a free anastomosis between the branches of the external carotid on the same side

and corresponding branches on the other side¹³.

- The **sphenopalatine artery**, a branch from the maxillary artery (branch of the external carotid) enters the nose via the sphenopalatine foramen and supplies the postero-inferior aspect of the lateral wall and the corresponding aspect of the septum. From here it descends to reach the incisive foramen to the surface of the hard palate. The sphenopalatine artery has a medial and lateral branch. The lateral branch supplies the lateral nasal wall and the medial also called the **nasopalatine artery** supplies the septal wall.
The **greater palatine artery**, also a branch of the maxillary artery, supplies the posterior part of the nasal septum. It also supplies the turbinates and meati laterally³. The sphenopalatine artery is considered the primary source of blood supply to the nasal septum.
- **The anterior and posterior ethmoidal arteries** of the internal carotid artery supply the anterosuperior aspect of the lateral wall as well as the corresponding aspect of the nasal septum. They reach the nasal cavity via the ophthalmic artery.
The **anterior ethmoidal artery** enters the nasal cavity next to the crista galli and runs downward over the anterior superior aspect of the nasal cavity¹³. The posterior ethmoidal artery is much smaller than the anterior ethmoidal artery.

Bleeding from these arteries arise from the superior nasal vault and the superior and posterior part of the nasal septum.

Histological sections of the anterior ethmoidal artery and sphenopalatine artery at their entry point into the nose show that the anterior ethmoidal artery is much smaller in diameter. Therefore bleeding from the ethmoid region must be rare.

This bleeding is very occasional¹³ and can only be identified endoscopically³.

- **The superior labial branch** of the facial artery, supplies the anterior part of the septum as well as the anterior lateral nasal mucosa.
- **The vestibule of the nose** receives terminal branches of both the anterior ethmoid and the sphenopalatine artery as well as nasal branches from the superior labial artery
- **Anterior epistaxis**
 - Branches from both the internal and external carotid arteries supply the nasal septum. An anastomotic site is found on the anteroinferior septum, which is known as Little's area, and is the most common site for epistaxis^{2,15}. Little¹⁷ first described bleeding from this lower anterior part of the septum in 1879. Kiesselbach¹⁸ also described the area a few years later in 1884. Little's area and Kiesselbach's area are therefore both used to describe the same area. Both authors did not describe the anatomy of the area. Three of the four cases described by Little¹⁷ were due to arterial bleeding.

- The four main branches anastomosing on the anteroinferior nasal septum (Little's area¹⁷) are:
 - Anterior and posterior ethmoidal arteries of the ophthalmic artery, from the external carotid artery,
 - Sphenopalatine artery from the maxillary artery, from the external carotid artery and the
 - Superior labial artery, from the facial artery, from the external carotid artery.

A prominent blood vessel in this area can often be seen running from inferior to superior. The blood vessels are found within the epithelium, tunica propria and perichondrium of the cartilaginous portion of the nasal septum. The capillary bed of this portion of the nose can easily be traumatized¹⁶.

- Bleeding can also come from the mid portion of the septum, and can usually be easily managed by cautery³.
- Spontaneous bleeding through the nares is almost always septal in origin³.

- **Posterior epistaxis**

- Posterior epistaxis may be either arterial or venous³.
- The bleeding is almost certainly posterior if the patient's first awareness of bleeding is into the nasopharynx³.
- Posterior epistaxis is usually a vigorous bleeding, lasting for minutes or even hours. Significant blood loss is associated with posterior epistaxis, of which the patient is usually unaware.
- The most common source of posterior epistaxis, is the sphenopalatine artery, emerging from the sphenopalatine foramen, which is located at the posterior aspect of the middle turbinate. The artery supplies the turbinates from their posterior aspect and the posterior part of the nasal septum. More elderly patients usually bleed from the posterior nasal passages.
- Woodruff⁸ identified a venous plexus on the posterior section of the lateral wall of the inferior meatus extending posterior to the soft palate, the so-called naso-nasopharyngeal plexus. There is an accompanying inferolateral branch of the sphenopalatine artery¹⁶.
- Wurman *et al*³ uses the eponym 'Woodruff's plexus⁸' to describe blood vessels in the following areas: 1 cm posterior of the nasal floor, inferior meatus, inferior turbinate and middle meatus, the vertical strip of mucosa anterior to the Eustachian tube and the mucosa lateral and superior to the posterior choana.

- Hallberg¹³ reports that in 50.9% of their 106 patients requiring hospitalization, the source of bleeding was from Little's area and in 40% from the posterior part of the nose. Of the posterior bleeders, half seems to be from the sphenopalatine artery and the other half from the venous naso-nasopharyngeal plexus.
- Hallberg¹³ classified the source of nose bleeding of 106 patients requiring hospitalization during a five year period as follows: Little's area¹⁷ (27.3%), sphenopalatine or nasopalatine artery (10.4%), diffuse bleeding (6.6%), turbinates (4.7%), naso-nasopharyngeal plexus (11.3%), anterior septal perforation (5.7%), behind spurs and severe septal deflections (5.7%), anterior ethmoidal artery and vein (5.7%) and undetermined (posterior) (22.6%).
- Woodruff⁸ summarizes the blood supply to the lateral wall of the nose and the nasal septum as follows:

Arteries of the lateral wall of the nose

- External carotid
 - Sphenopalatine from the maxillary artery
 - Greater palatine from the maxillary artery
 - Infraorbital from the maxillary artery
- Internal carotid
 - Anterior and posterior ethmoidal arteries from the ophthalmic artery

Arteries of the nasal septum

- External carotid -
 - Sphenopalatine from the maxillary artery
 - Greater palatine from the maxillary artery
 - Septal branch of the superior labial artery from the facial artery
- Internal carotid -
 - Septal branches of the anterior and posterior ethmoidal arteries from the ophthalmic artery.

- Walike *et al*²⁵ gives a useful conceptual overview of the arteries supplying the nose:

External carotid artery

- Maxillary artery
 - Sphenopalatine artery
 - Posterior nasal septal artery
 - Posterior lateral nasal artery
 - Nasopalatine artery
 - Descending palatine artery
 - Greater palatine artery
 - Lesser palatine arteries
- Facial artery
 - Superior labial artery
 - Septal artery
 - Alar artery

Lateral nasal artery
Angular artery
Ascending palatine artery

Internal carotid artery

Ophthalmic artery Anterior ethmoidal artery
Posterior ethmoidal artery

- Zuckerkandl²¹ divided the arterial distribution in the nose into two regions from the internal and external carotid arteries. Weddell²² describes the middle turbinate on the lateral nasal wall and a corresponding imaginary line on the nasal septum as the division between the internal and external carotid artery's distribution. The region above the line is supplied by the internal carotid artery and below the line by the external carotid artery.
- Zuckerkandl²¹ reports that the middle turbinate is exclusively supplied by the maxillary artery from the external carotid artery. A vessel from the same maxillary artery, supplies the posterior part of the superior turbinate and meatus as well as a corresponding vessel to the septum. The area that is supplied by the internal carotid artery is therefore smaller than Weddell's²² description.
- Shaheen²⁰ reports in a series of 72 patients, that there were very few bleeders originating from the anterior ethmoidal area and no cases from the lateral nasal wall at all.

5.11 Mechanics of the arterio-arterial anastomoses

- The internal and external carotid arteries form an anastomoses in the nose. This explains why there is still persistent bleeding in a number of cases after ligation of the external carotid artery. Previously it was thought that the wrong artery was ligated²⁰. Lowering of the pressure in the external carotid artery, will cause shifting of blood from the upper internal carotid area of the nose to the lower external carotid area across the anastomoses in the nasal mucosa.
- Shaheen²⁰ demonstrated the anastomotic network by injecting dye into the internal carotid artery and studying the spread of dye with and without occlusion of the external carotid artery. In the two cases where there was no occlusion of the external carotid, the dye appeared in the periorbital skin but not in the nose. In six cases where the external carotid artery was occluded, there was a dramatic inflow and displacement of blood (dye) from the cribriform plate towards the upper half of the nasal septum and lateral nasal wall.
- Shaheen²⁰ also demonstrated that bleeding from a point in the territory of the external carotid artery continued after maxillary artery ligation. This is explained by the anastomoses between the sphenopalatine (maxillary artery; external carotid) and ethmoidal arteries (ophthalmic artery; internal carotid).

5.12 Venous drainage¹

- Venous drainage from the nose is via the sphenopalatine, facial and ophthalmic veins, which communicate with the dural sinuses especially the cavernous sinus². Small veins also pass the cribriform plate to the inferior surface of the frontal lobes of the brain. Infection in the nasal cavity and paranasal sinuses can therefore spread intracranially.
- Batson¹⁹ studied the veins of the nose by corrosion preparations. He found that the veins form a mat throughout the nasal mucous membrane, being thickest in the nasopharynx and the turbinates of the nose. There are numerous interconnections with veins in the nasal mucosal network and with veins of the underlying bone. The veins continue at the ostia of the sinuses into the cavities of the sinuses.

This venous network forms the basis for edema and engorgement with blood. The nasal venous network of the septum of the nose has a thickness of 0.5 to 1.0 mm.

The veins form a valveless network.

5.13 Nerve supply¹

- The nasociliary branch of the ophthalmic division as well as the maxillary division of the trigeminal nerve provide sensation to the nasal cavity.
- Most of the septum is supplied by the nasopalatine branch of the sphenopalatine nerve, which comes from the maxillary division via the pterygopalatine ganglion in the pterygopalatine fossa. The anterior part of the septum is supplied by the anterior ethmoidal nerve branch of the ophthalmic division of the trigeminal nerve.
- The posterior aspect of the lateral nasal wall is innervated by the short sphenopalatine nerves. Anteriorly the lateral nasal wall is supplied mostly by the anterior ethmoidal nerve. The inferior turbinate is supplied by the anterior superior alveolar nerve and the greater palatine nerve.
- The floor of the nose is anteriorly supplied by the anterior superior alveolar nerve and posteriorly by the greater palatine nerve.
- The nasopharynx is supplied by the glossopharyngeal nerve (IX) and when provoked by a nasal pack or endoscope, may give rise to the 'gag' reflex, of which the motor function is supplied by the vagus nerve (X).
- The olfactory nerve supplies the olfactory zone of the nose, which is the most superior part of the nasal septum as well as the lateral walls of the nasal cavity².

5.14 Cribriform plate¹

- This forms the roof of the nasal cavity and forms part of the ethmoid bone. The cribriform plate is just inferior to the anterior cranial fossa. Branches from the olfactory bulb enter the nasal cavity through the cribriform plate and thus explains why patients with a skull base fracture may present with anosmia.

5.15 Children^{3 12}

- Epistaxis in children is mostly from Little's area^{2,15}. Nose picking associated with crust formation in the presence of an upper airway infection is often the cause.
- A nasopharyngeal angiofibroma should be considered in the case of a posterior nosebleed.
- Two-finger compression of the soft sides of the nose (ala nasi) usually stops the bleeding effectively.
- In a randomized clinical trial, Ruddy *et al*¹² demonstrated no significant difference in treating epistaxis in children with an antiseptic nasal barrier cream (Naseptin) or with silver nitrate cautery. Both methods work by stopping the bleeding vessels by heat and scar tissue formation.
- Von Willebrand's disease is not uncommon in children presenting with isolated epistaxis.

6. Complications (anatomically relevant)

6.1 Septal perforation

- A septal perforation may cause bleeding, which may result in a chronic anemia³.
- Silver nitrate cautery is less likely to cause a septal perforation than electrocautery. It is however less effective for large bleeders.
- Bilateral cautery should be avoided as cutting off the blood supply to the nasal septum from both sides may result in perforation.
- Always palpate the nasal septum before cauterization, to ensure the integrity of the cartilage³.

6.2 Septal hematoma

- A septal hematoma may be due to trauma to the nasal septum. This hematoma forms between the perichondrium and the cartilage. A septal hematoma should be treated, or it may cause septal perforation, a septal abscess and cartilage destruction with a saddle-nose deformity.
- A septal hematoma is diagnosed by inspecting the nasal septum for swelling and pain.
- Drainage of the hematoma is done by incising the mucosa horizontally over the hematoma. The blood clot should be removed by suction and the septum rinsed with normal saline. A small amount of mucosa should be excised to prevent premature closure of the incision. The nasal cavity should then be packed.

6.3 Persistent bleeding in the elderly

- Shaheen²⁰ has demonstrated in a histological study that the vessels in the elderly are more prone to bleed persistently, due to a collagenous change in the muscular wall of the medium and small arteries supplying the nose. The larger vessels

demonstrated significant calcification and not atheroma formation in his study. Elderly patients usually bleed from the posterior nasal passages.

- Epistaxis is usually more severe in elderly people due to the atherosclerotic changes of the blood vessels which cause them to gape and therefore bleed more persistently¹³.

6.4 Infection: Sinusitis, rhinitis and nasopharyngitis

- Any anterior nasal pack may obstruct drainage of the paranasal sinuses and nasolacrimal duct. Also, due to the foreign body in the nose, mucous production will increase and be a focus for infection. This includes sinusitis and nasopharyngitis. Sinusitis is usually seen if the nasal pack stays in for more than 24 hours. Prophylactic antibiotics are necessary to prevent sinusitis³.
- Rhinitis is associated with anterior packing.

6.5 Toxic shock syndrome

- Toxic shock syndrome has been described by Tag *et al*⁷ related to nasal packing. The syndrome is caused by a toxin released by *Staphylococcus aureus* growing on the nasal pack itself³. The onset is characterized by vomiting and diarrhea with high fever. This may lead to multisystem organ dysfunction. The gauze should therefore be coated with topical broad-spectrum antibiotics. Systemic antibiotics should also be given.

6.6 Tissue necrosis

- Alar necrosis can occur due to too much pressure from a Foley's catheter or posterior nasal pack.
- Nasal mucosa and soft palate necrosis can occur secondary to improper placement of the pack or balloon.
- All packing should be removed within 3 days³.

6.7 Hemotympanum

- A hemotympanum develops when blood is forced up the Eustachian tube into the middle ear. This complication has been reported with the use of postnasal packs¹³.

6.8 Otitis media.

- Otitis media may result from obstruction of the Eustachian tube orifice by a posterior nasal pack²⁴.

6.9 Transient bacteremia

- Approximately 12% of patients with nasal packs develop transient bacteremia²⁴.

Patients with cardiac valve disease should be appropriately treated and other treatment options should possibly be sought.

6.10 Iatrogenic bleeding

- Anterior bleeding from the lateral wall is often due to trauma caused by an inexperienced practitioner looking for an unidentified bleeder³.

6.11 Breakthrough bleeding^{3,6}

- Bleeding may continue despite cautery and nasal packing. It may be necessary for an otolaryngologist to perform one of two advanced procedures. The internal maxillary artery can be ligated. During this procedure the sphenopalatine artery is ligated as well. The second recent procedure is a posterior endoscopic cautery. The latter has no complications associated with posterior nasal packing or balloon tamponade.
- Bleeding from the inferior and middle meatus, or the medial surface of the inferior turbinate, cannot be stopped effectively by nasal packing or balloon tamponade³. Endoscopic cautery is necessary.

6.12 Dislodgement of the nasal pack

- The nasal pack may dislodge and fall into the oropharynx and further down into the laryngopharynx causing asphyxiation, vomiting and aspiration²⁴.

6.13 Hypoventilation

- Patients with posterior nasal packs should be admitted in hospital for sedation and monitoring. Especially those patients with lung disease who are at risk of hypercarbia and hypoxia with a posterior nasal pack. Monitoring of arterial gas levels is necessary in these patients²⁴.

6.14 Complications associated with posterior nasal packs

- Fairbanks⁹ reports on disadvantages like hypoxia and hypoventilation being responsible for the increased rate of myocardial infarction and cerebrovascular accidents in patients with posterior nasal packs. Work on dogs suggests that packing stimulates the vagal reflex, causing bradycardia, hypotension and inhibition of respiratory function¹⁰.
- Wetmore *et al*¹¹ also demonstrated that posterior nasal packing can cause sleep apnea.
- Spar *et al*¹⁴ reports on osteomyelitis of the base of the sphenoid bone with meningitis and cranial nerve lesions due to a nasopharyngeal abscess after posterior nasal packing. Injury to the mucosa in the nasopharynx secondary to nasal packs or instrumentation may give rise to the development of a

nasopharyngeal abscess²⁴.

- Wurman³ suggests that due to these disadvantages this procedure should be rarely used.

6.15 Complications associated with nasal balloon tamponade³

- The pressure is unlikely to be directed at the exact bleeding site posteriorly. Control actually comes from mucosal edema.
- Balloons leak slowly through the valve and the latex.
- Discomfort of the balloon in the nasopharynx may make pain medication and sedation necessary.
- Pressure necrosis of the nostril rim can occur. A gauze pad should be used over the skin. Wareing *et al*⁴ describes an improved technique to fixate the Foley's catheter by using a syringe clamped around the catheter on the external surface of the nose.
- There are no studies showing the risk of balloon tamponade regarding hypoxia, myocardial infarction and sleep apnea.

6.16 Cardiac arrhythmias

- Cardiac arrhythmias can occur due to vagal stimulation¹⁰.

6.17 Aspiration

- Aspiration of blood or packing material is a definite risk²⁴.

7. References

- ¹ Morris IR. Functional anatomy of the upper airway. Review. Emergency Medicine Clinics of North America 1988 Nov;6(4):639-69,
- ² Ellis H, Feldman S. Anatomy for Anaesthetists, 6th Ed. Oxford: Blackwell Scientific Publications, 1993: 6-16
- ³ Wurman LH, Sack JG, Flannery JV. The management of epistaxis (review). Am J Otolaryngol 1992;13:193
- ⁴ Wareing MJ, Gray RF. Foley catheter fixation in posterior epistaxis. J Laryngol Otol 1993;107:1032
- ⁵ Hartley C, Axon PR. The Foley catheter in epistaxis management: A scientific appraisal. J Laryngol Otol 1994;108:399-402
- ⁶ Viducich RA, Blanda MP, Gerson LW. Posterior epistaxis: Clinical features and acute complications. Ann Emerg Med 1995;25:592
- ⁷ Tag AR, Mitchell FB, Harell M, Morrison WV. Toxic shock syndrome: Otolaryngologic presentations. Laryngoscope 1982;92:1070
- ⁸ Woodruff GH Cardiovascular epistaxis and the naso-nasopharyngeal plexus. Laryngoscope 1949;59:1238
- ⁹ Fairbanks DNF Complications of nasal packing. Otolaryngol Head Neck Surg 1986;

94:412

- ¹⁰ Angell James JE, Daly Md. Nasal reflexes. *Proc R Soc Med* 1969; 62(12):1287-93
- ¹¹ Wetmore SJ, Scrima L, Hiller FC Sleep apnea in epistaxis patients treated with nasal packs. *Otolaryngol Head Neck Surg* 1989;98:596
- ¹² Ruddy J, Proops DW, Pearman K, Ruddy H. Management of epistaxis in children. *International J of Pediatr Otorhinolaryngol* 1991;21:139-142
- ¹³ Hallberg OE. Severe nosebleed and its treatment *JAMA* 1952;148:355
- ¹⁴ Spar AA, Williams HL. Osteomyelitis of the basisphenoid and basiocciput with meningitis and cranial nerve palsies as a complication of nasopharyngeal packing for control of epistaxis: Report of a case with recovery. *Arch Otolaryngol* 1947;46:473-477
- ¹⁵ McGarry GW, Moulton C. The first aid management of epistaxis by accident and emergency department staff. *Arch Emerg Med* 1993;10:298-300
- ¹⁶ Hara HJ Severe epistaxis. *Arch Otolaryngol Head Neck Surg* 1962;75:258
- ¹⁷ Little JL. A hitherto undescribed lesion as a cause of epistaxis, with four cases. *The Hospital Gazette* 1879;6:5
- ¹⁸ Kiesselbach W. Ueber spontane Nasenblutungen. *Berliner Klinische Wochenschrift* 1884(June);16:375
- ¹⁹ Batson OV. Venous networks of the nasal mucosa. *Ann Otol* 1954;63:571-580
- ²⁰ Shaheen OH Arterial epistaxis. *J Laryngol Otol* 1975;89:17
- ²¹ Zuckerkandl E. Normale und Pathologische Anatomie der Nasenhöle. W. Braumuller: Wien und Leipzig 1892;1:128
- ²² Weddell G. The surgical treatment of severe epistaxis in relation to the "ethmoidal" artery. *Br J Surg* 1946;33:387
- ²³ Juselius H. Epistaxis – a clinical study of 1724 patients. *J Laryngol Otol* 1974;88: 317-327
- ²⁴ Walike JW, Chinn J. Evaluation and treatment of acute bleeding from the head and neck. *Otolaryngologic Clinics of North America* 1979;12(2):455- 464
- ²⁵ Walike JW. Anatomy of the nasal cavities. *Otol Clin N Am* 1973;6:609-621
- ²⁶ LaForce RF. Treatment of nasal hemorrhage. *Surg Clin N Am* 1969;49:1305-1310

4.4.2.2 Wrist and digital nerve blockade

1. Indications	189
2. Contraindications	190
3. Step by step procedure	190
4. Materials	194
5. Anatomical pitfalls	195
6. Complications (anatomically relevant)	204
7. References	207

1. Indications

1.1 Wrist block:

- Diffuse lesions that are difficult to anesthetize with local infiltration.
- Deep abrasions with embedded debris, often the result of 'road burn', in order to do a proper debridement.
- Multiple and complex lacerations.
- Skin grafting.
- Incision and drainage of hand infection.
- Reduction of metacarpal fractures, especially 'boxer's fracture'.
- Removal of foreign bodies in the palm of the hand.
- Reconstructive hand surgical procedures like tendon grafts, arthrolysis, arthroplasty and tenolysis²².

1.2 Digital nerve block:

- Repair of finger lacerations. Local infiltration of a finger injury has been shown to be less effective and more painful compared to digital nerve block¹⁸. The reason is the limited amount of anesthetic solution that can be accepted by tense surrounding tissue of the distal part of the finger compared to the loose connective tissue at the base of the finger.
- Finger amputations.
- Reduction of metacarpophalangeal, distal interphalangeal and proximal interphalangeal joint dislocations and fractures.
- Drainage of finger infections (relative contraindication).
- Drainage of felons and paronychia.
- Relief of pain from fractures or burn wounds.
- Particularly useful where it is desirable to retain some motor function during surgery².
- Finger nail removal.
- Intrinsic extensor tenolysis²².
- Release of a trigger finger.

2. Contraindications

2.1 Both wrist and digital nerve block

- Sensitivity to 'caine-type' anesthetic solutions.
- Local sepsis in area where the block needs to be administered.

2.2 Wrist block

- Median nerve – the presence of carpal tunnel syndrome is a contraindication.²

2.3 Digital nerve block

- In the case of extensive injuries to the digits, it is better to choose a more proximal site for the block e.g. a wrist block².
- If more than one digit is involved, due to the risk of ischemia, alternatives such as a wrist block should be considered⁷.
- Patients with peripheral vascular disease.⁷

3. Step by Step procedure

Various techniques are described for both the wrist block and digital nerve block. The step by step procedure that is described here, is the author's preferred procedure. Other alternatives are described in the Anatomical pitfalls section.

- Basic principle: If paresthesias are experienced by the patient, the site of the needle point needs to be changed¹⁹.

3.1 Digital nerve block

- **Step 1.** Determine the extent of possible associated nerve injury by two point discrimination before the block.
- **Step 2.** Prepare the skin of the injection site with alcohol or povidone-iodine.
- **Step 3.** Use sterile gloves
- **Step 4. Site of needle entrance:**
 - The following needle entrance sites can be used:
 - The finger,
 - The web space between the fingers (digital nerve block) and
 - Between the metacarpals in the hand (metacarpal block).

- A dorsal or palmar approach to the nerves can be used. The dorsal approach is less painful due to less pain sensitive skin.
- The preferred site is at the base of the finger in the web space. There is more soft tissue space at this site to accommodate the volume of anesthetic solution. The nerve's location is more consistent here than in the hand. Knoop *et al*¹ showed that this approach requires less time to anesthetise the finger when compared to the metacarpal block.
- Leverage *et al*⁹ describe a method where the needle is directed into the dorsal surface of the web space between two fingers to a depth of 1.5 cm and injecting 2-3 ml of anesthetic solution.
- **Step 5** Start at the dorsal positions where the skin is less pain sensitive. Introduce the needle from the dorsal side at the 2:30 and 10:30 positions (with the mid-dorsal point the 12:00 position). No attempt is made to elicit paresthesia. Inject 0.5 to 1 ml of anesthetic solution. Pass the needle on the lateral side of the proximal phalanx and the extensor expansion toward the palmar surface. The needle is aspirated for checking not to be in a vessel and another 0.5 to 1 ml of anesthetic is deposited. Repeat this procedure for the other side of the finger. The result is a circumferential band of anesthesia around the base of the finger.
- **Step 6.** Massage of the area of injection promotes diffusion of the anesthetic.
- **Step 7.** Palmar and dorsal web space approaches can be used for the middle and index finger, to block the palmar digital nerves. This will provide anesthesia for the whole finger.
- **Step 8.** Thumb – A circumferential block can be performed for the thumb. A band of anesthetic solution is delivered in a subcutaneous fashion over the dorsal and ventral sides of the base of the thumb.

Alternative method: Transthecal digital block technique.

- A single injection is given into the flexor tendon sheath, which produces fast and complete finger anesthesia. Cadaver studies suggest that the local anesthetic diffuses out of the tendon sheath and around the phalanx and all 4 digital nerves are anesthetized⁵.

Technique:

- **Step 1.** The flexor tendon sheath is palpated as it glides over the protuberance of the metacarpal head on the palmar surface.
- **Step 2.** A palmar percutaneous injection of 2 ml of lignocaine is delivered into the potential space of the flexor tendon sheath at the level of the palmar flexion crease (approximately 1 cm proximal to the metacarpophalangeal crease). A small

needle (25-30 ga) must be used to minimize damage to the flexor tendon sheath.

- **Step 3.** Direct the needle at an angle of 45° distally.
- **Step 4.** Resistance to injection suggests that the needle is against the flexor tendon.
- **Step 5.** Carefully withdraw the needle until free flow of the anesthetic solution is obtained. This means the fluid is entering the space between the tendon and the sheath.
- **Step 6.** Apply pressure on the palm of the hand to facilitate diffusion of the solution through the sheath.

Advantage: The advantage of this technique is that a single injection and small volume of anesthetic solution is used. Furthermore the block has a quick onset and there is no risk of mechanical trauma to the neurovascular bundle. However, great care must be taken to adhere to sterile techniques, as contamination of the flexor tendon is disastrous.

3.2 Wrist block

3.2.1 Median nerve^{2, 6,7}

- **Step 1. Position:** Abduct the arm with the elbow extended and the forearm supinated on a rest pad. Place a small towel under the wrist of the hand to dorsiflex the hand.
- **Step 2.** Insert a fine needle between the tendons of palmaris longus and flexor carpi radialis, at the level of the proximal wrist crease of the skin. If the flexor palmaris tendon is absent, the point of insertion is approximately 1 cm medial to the ulnar border of the flexor carpi radialis tendon. Insert the needle at right angle with the long axis of the forearm.
- **Step 3.** Advance slowly until a slight 'pop' is felt. This represents penetration of the flexor retinaculum. At this point, inject 3-5 ml of the anesthetic solution⁹.
- **Step 4.** If paresthesias are felt, withdraw 2-3 mm and inject to avoid intraneural injection. If no paresthesias are elicited, deposit the anesthetic solution in the proximity of the nerve, 1cm deep under the tendon of palmaris longus. The solution is actually injected into the ulnar bursa proximal to the carpal tunnel¹⁶.
- **Step 5.** The superficial palmar branch of the median nerve should also be blocked. This nerve is located directly radial to the palmaris longus tendon in the subcutaneous tissue¹⁹.

3.2.2 Ulnar nerve

Ulnar approach

- **Step 1.** First palpate the ulnar artery, pisiform bone and flexor carpi ulnaris tendon. Palpate the flexor carpi ulnaris tendon. Flex the hand against resistance to facilitate palpation of the tendon just proximal to the pisiform bone, with slight ulnar deviation to relax the tendon of flexor carpi ulnaris¹¹. Find the radial border of the tendon of flexor carpi ulnaris by flexing the wrist with reasonable force and pressing the fingers together⁹. The artery can usually be palpated a few millimetres radial to the tendon, especially if the hand is flexed. The ulnar nerve is just deep and to the ulnar side of the ulnar artery.
- **Step 2. Site of needle insertion.** The site of insertion is on the ulnar aspect of the flexor carpi ulnaris tendon at the proximal wrist crease⁷.
- **Step 3.** Direct the needle horizontally under the flexor carpi ulnaris tendon for a distance of 1-1.5 cm. This will bring the tip close to the ulnar nerve, without the risk of injuring the ulnar artery.
- **Step 4.** Deposit 3 to 5 ml of anesthetic solution.
- **Step 5.** The dorsal cutaneous branch of the ulnar nerve runs around the wrist to supply part of the dorsum of the hand. Block this nerve by depositing 5 to 10 ml subcutaneously from the *same* insertion site to the dorsum of the wrist. The advantage with this approach is that the ulnar artery is less often injured¹⁶ and both the superficial and deep branches as well as the dorsal cutaneous branch of the ulnar nerve can be blocked through the same site of insertion⁷.

Alternative: Volar approach

- **Step 1.** First palpate the ulnar artery, pisiform bone and flexor carpi ulnaris tendon. Palpate the flexor carpi ulnaris tendon. Flex the hand against resistance to facilitate palpation of the tendon just proximal to the pisiform bone, with slight ulnar deviation to relax the tendon of flexor carpi ulnaris¹¹. Find the radial border of the tendon of flexor carpi ulnaris by flexing the wrist with reasonable force and pressing the fingers together⁹. The artery can usually be palpated a few millimetres radial to the tendon, especially if the hand is flexed.
- **Step 2.** Insert the needle at a right angle with the skin on the radial side of the tendon of flexor carpi ulnaris and the ulnar side of the ulnar artery. The ulnar nerve lies between the tendon of the flexor carpi ulnaris and ulnar artery at the proximal palmar crease.
- **Step 3.** Insert the needle vertically to a depth of 1.5 to 2 cm and inject 3 to 5 ml of anesthetic solution. If paresthesias are felt, withdraw 2-3 mm and inject to avoid intraneural injection.
- **Step 4.** The dorsal cutaneous branch of the ulnar nerve can be anesthetized by a subcutaneous injection given just distal to the proximal flexor wrist crease. Start

at the ulnar side of the tendon of flexor carpi ulnaris and advance subcutaneously for 2 to 3 cm around the ulnar side to the dorsum of the wrist⁹. A ring of local anesthesia can also be placed subcutaneously around the ulnar aspect of the wrist, just distal to the ulnar styloid¹².

3.2.3 Radial nerve

- **Step 1.** Palpate the radial artery.
- **Step 2 (first injection).** Block the superficial branch of the radial nerve, by infiltrating superficially under the brachioradialis tendon 6-8 cm proximally to the proximal wrist crease. Use a hypodermic needle and inject 0.5-1 ml of anesthetic solution.
- **Step 3.** Position the forearm in pronation.
- **Step 4.** Identify the anatomical snuffbox and mark the bordering tendons. Identify the extensor pollicis longus and brevis muscles and the abductor pollicis longus muscle, bordering the anatomical snuffbox.
- **Step 5.** Take a point over the tendon of the extensor pollicis longus tendon, opposite the base of the first metacarpal. The nerve is often palpable here¹⁶.
- **Step 6 (second injection).** Direct a 25-ga needle proximally along the tendon as far as the dorsal radial tubercle and inject 2 ml subcutaneously.
- **Step 7.** Withdraw the needle almost to the skin and redirect across and superficially to the anatomical snuffbox, to a point just past the extensor pollicis brevis tendon, and inject a further 1 ml anesthetic solution⁷.

Alternative: ⁷

- Inject 2-5 ml, immediately lateral to the radial artery at the level of the proximal palmar crease. Melone *et al*¹² refers to the radial styloid as a landmark to find the terminal branches of the radial nerve, which can be easily blocked here.
- Another 5 to 10 ml is injected subcutaneously away from the initial point of injection to the dorsal midline. Deposit a superficial ring of solution over the anatomical snuffbox created by the tendons of the abductor pollicis longus and extensor pollicis brevis muscles. Withdraw the needle and reposition in an already anesthetised region to minimize pain.

4. Materials

- Sterile gloves.
- Alcohol and povidone-iodine.
- Lignocaine, bupivacaine or mepivacaine without adrenaline for the digital nerve block. With or without adrenaline can be used for the wrist block⁹.
- 25-30-ga hypodermic needle.
- 10 cc syringe
- 18-ga needle to draw up solution.
- Standard resuscitation equipment.

5. Anatomical pitfalls

5.1 Easy access

- The nerves around the wrist (median, radial and ulnar) as well as the digital nerves in the hand or fingers are superficial and can therefore easily be accessed by percutaneous injection⁹.
- Nerves at the wrist joint can more easily be located compared to the elbow and the axilla.

5.2 Digital nerves

- Each finger has two sets of nerves²: palmar and dorsal digital nerves. They run along the finger for the dorsal pair, at the 2 and 10 o'clock positions and for the palmar pairs, at the 4 and 8 o'clock positions.
- The digital nerve to the radial side of the index finger, is the only common digital nerve supplying only one side of a digit.¹¹
- The digital nerves are volar to the lumbrical tendons in the web space⁹.
- A peripheral nerve consists of a number of fascicles embedded in loose connective tissue (epineurium). This tissue is often sheetlike on the outer border. Each fascicle is surrounded by a perineurium. Inside the perineurium the nerves fibres are packed between thin septae of connective tissue, the endoneurium⁴.
- The thumb can be blocked by performing both a median and radial nerve block at the wrist, or with a circumferential block.

5.2.1 Finger or web space injection

- The finger has tight skin and can allow only a limited volume of anesthetic solution with local infiltration¹⁸. This may increase pressure in the restricted space and impair capillary blood flow. Fibrous septae in the fingertip prevent the anesthetic solution from spreading evenly.
- The level of the fingers should be avoided due to the danger of ischemic changes arising from increased pressure caused by solution in a limited digital space¹. The web space between the fingers is ideal due to increased tissue space and constant

anatomical position of the palmar digital nerves. The digital nerves are surrounded by loose fibrous areolar tissue in the web space. This favours the injection of anesthetic solution and does not cause surrounding tissue pressure and obstruction of venous outflow from the digit⁹. When anesthetic solution is injected into this space, opposing surfaces of the fingers will be blocked¹¹.

5.2.2 Palmar digital nerves

- The principal nerves supplying the finger are the palmar digital nerves, branching from the common digital nerves, just proximal to the metacarpal heads¹.
- The palmar digital nerves follow the artery along the volar lateral aspects of every side of the bone. They supply sensation to the volar skin and interphalangeal joints of all 5 digits.
These nerves also supply the dorsal aspects of the index, middle and half of the ring finger distal to the proximal interphalangeal joint¹.
- **Surface anatomy** – The palmar digital nerves run on the edges of the skin creases made by flexing the DIP, PIP and metacarpophalangeal joints. Therefore, if the needle is inserted at the tip of the skin crease, the nerve will be blocked. The digital nerve on the radial side of the second digit and the ulnar side of the fifth digit, lie directly anterior to the metacarpal heads¹⁰. Blocking these nerves requires injecting the solution into the fatty tissue at the metacarpal heads⁹.
- The palmar digital nerves can be blocked at different levels: within the finger, in the web space between the fingers (site of a digital nerve block) and at the level of the metacarpal bones (metacarpal block).
- The palmar digital nerves are accompanied by digital vessels and run on the ventrolateral aspect of the finger immediately lateral to the flexor tendon sheath⁷.

5.2.3 Dorsal digital nerves

- The dorsal digital nerves originate from the radial and ulnar nerves, which run on the dorsomedial and dorsolateral aspects of the fingers. They supply the nail beds of the thumb and little finger and half of the ring finger as well as the dorsal aspects of the index, middle and half of the ring finger up to the proximal/distal interphalangeal joint. All four digital nerves should therefore be blocked in the thumb, little finger and ring finger, especially to obtain anesthesia of the fingertip and nail bed.
- The dorsal digital nerves lie very close to the bone. Therefore as the bone is touched, the needle should be withdrawn 1-2 mm to inject the solution.

5.2.4 Site of injection for digital nerves

- Digital nerves at the base of the finger
 - This is the preferred site for injection to block the digital nerves. It has a quick onset.
 - Introduce the needle from the dorsal side at the 2:30 and 10:30 positions (with the mid-dorsal point the 12:00 position). Inject here 0.5-1 ml for the dorsal sensory branches. Then push the needle to a point next to the flexor tendon sheath and inject 0.5-1 ml for the palmar digital branches.
 - Knoop¹ showed in a randomised prospective study, that a digital nerve block is more efficient and requires less time for anesthesia when compared to a metacarpal block.
- Digital nerves in the hand (Metacarpal block)
 - The injection is made at the distal palmar crease on the palmar side of the hand. This crease overlies the bifurcation of the common digital nerves, which is found just proximal to the metacarpal heads and deep to the palmar aponeurosis. This is a relatively sensitive area. 3 ml of solution can be injected in the intermetacarpal space¹¹ to block the common digital nerve¹². Because the block is performed proximal to the digital artery collaterals, the risk of vascular compromise is minimized¹. This approach has the drawback of causing significant pain when piercing the palmar skin and palmar aponeurosis.
 - The metacarpal space can also be accessed from the dorsal side¹. Advance the needle 90° to the dorsum of the hand, 1 cm proximal to the metacarpal phalangeal joint, until the resistance of the palmar aponeurosis is felt. Inject 3 ml anesthetic solution and another 1 ml as the needle is withdrawn. The advantage of this approach is that the palmar skin need not be pierced and the dorsal sensory branches can be blocked via the same injection site.

5.2.5 Alternative techniques to block the digital nerves. (See preferred technique in Section 3)

- **Bradfield's method⁸:**
 - Inject into the side of the base of the finger (the side is less sensitive than the dorsum)
 - Fill the pulp of the finger with anesthetic solution by passing the point of the needle to the other side superficial to the flexor tendons.
 - It is not necessary to aim for the digital nerves
 - Apply the tourniquet (fine rubber tube) at the base of the finger just

proximal to the injection site.

- Secure the tourniquet with a pair of artery forceps.
- Scrub up for the procedure. This time will allow the finger to be fully anesthetized.

- **Mauldin's method¹⁶**

- Insert a 25-ga needle at a point on the dorsomedial and dorsolateral aspect of the base of the finger.
- Direct the needle anteriorly and slide past the base of the phalanx
- Advance the needle until resistance of the palmar dermis is felt.
- Inject 1ml while withdrawing the needle slightly for the palmar digital nerve
- Inject 0.5-1 ml just under the point of entry for the dorsal digital nerve.
- The palmar digital nerves of the second and fifth digits, may be easier to reach from the sides

- **Ramamurthy's method²³:**

- Insert the needle from the dorsal aspect at the proximal end of the finger to the side of the extensor expansion.
- Inject 1 ml of anesthetic solution into the region of the dorsal digital nerve.
- Advance the needle to the volar aspect of the digit to inject another 1 ml.
- Repeat the procedure on the other side.
- Do not exceed 5 ml solution to each digit.

- **Transthecal(synovial) digital nerve block**

- Hill *et al*¹⁷ showed in a prospective randomised controlled study that transthecal digital nerve blocks are clinically equal to the traditional digital nerve block regarding length of time to achieve anesthesia and pain associated with the procedure.
- The following are advantages of the block¹⁷, although the complications of the traditional method of digital nerve blockade are very low:
 - A single injection is used
 - A smaller amount of anesthetic solution is used
 - The risk of injuring the neurovascular bundle is avoided, reducing direct injury or spasm
- Disadvantages of the block are the following¹⁷:
 - The barrier of the flexor synovial sheath is crossed
 - Tendon trauma and infection is a risk, although minimal with a small needle (25-ga or higher) and sterile technique.

5.3 Median nerve^{2,7}

- **Sensory innervation:** The median nerve supplies the radial aspect of the palm of the hand and the palmar surface of the first (thumb), second and third digits and the radial side of the fourth digit. It also supplies the dorsal surface of the distal

two phalanges of the second and third digits and the radial aspect of the distal two phalanges of the fourth digit⁹.

- **Motor innervation:** The median nerve supplies the two lateral lumbrical muscles in the hand as well as the thenar group of muscles.
- The median nerve is the most superficial structure beneath the flexor retinaculum in the carpal tunnel¹⁶.
- The median nerve lies in the midline and deep to the fascia, invested by the ulnar bursa and accompanied by tendons of flexor pollicis longus, flexor digitorum profundus and superficialis which lie deep to it.
- The median nerve lies just deep to the palmaris longus tendon, or slightly radial to it between palmaris longus and flexor carpi radialis⁹. These tendons can be easily palpated. The palmaris longus tendon is the most superficial tendon and can be easily identified by forced flexion of the wrist while opposing the thumb and the fifth digit. The relation of the nerve to the tendons along the radial part of the wrist is remarkably constant²⁵.
- Palmaris longus is absent in 5 to 10% of people¹⁰. If this is the case the median nerve is more or less 1 cm to the ulnar side of the flexor carpi radialis muscle. The midpoint between the ulnar and radial styloid processes can also be used as a reference point¹⁶.
- The median nerve gives off a palmar branch before entering the carpal tunnel. This branch is located subcutaneously and radial to the palmaris longus tendon¹⁹. This branch should also be blocked by injecting a small amount of anesthetic solution subcutaneously just radial to the palmaris longus tendon.
- **Site of nerve block** - on the radial side of palmaris longus, just proximal to the proximal wrist crease. Insert a 25-ga needle perpendicularly and advance slowly until a slight 'pop' is felt (penetration of the flexor retinaculum) and a paresthesia is produced. If no paresthesia is elicited, deposit 3-5 ml of the anesthetic solution in the proximity of the nerve, 1cm deep under the tendon of palmaris longus. The solution is actually injected into the ulnar bursa proximal to the carpal tunnel¹⁶.
- If only the median nerve is blocked at the wrist level, the extrinsic flexor and extensor function of the hand as well as the intrinsic muscles of the hand supplied by the ulnar nerve, stay intact. This may be valuable in assessing function perioperatively during hand surgery²².

5.4 Ulnar nerve^{2,7}

- There are fewer risks and complications when blocking the ulnar nerve at the

wrist compared to blocking the nerve at the elbow¹⁶. The ulnar nerve may also be locally anesthetized at the elbow joint, where the nerve lies 0.5 cm below the skin but blocking of the nerve at that level is associated with a significant incidence of residual ulnar neuritis⁷.

- **Sensory innervation:** The ulnar nerve supplies the ulnar aspect of the hand on both the dorsal and palmar surface. It supplies the ulnar aspect of the fourth digit and the whole fifth digit. It may also supply parts of the dorsal surface of the proximal third and fourth digits⁹.
- **Motor innervation:** The ulnar nerve supplies all of the intrinsic muscles of the hand, except the thenar muscles and lateral two lumbrical muscles, which are innervated by the median nerve. In the forearm it supplies flexor carpi ulnaris and the ulnar part of flexor digitorum profundus.
- The ulnar nerve follows the ulnar artery to the wrist joint.
- The ulnar artery lies radially and superficial to the ulnar nerve¹⁶. The ulnar nerve lies between the tendon of flexor carpi ulnaris and the artery and *deep* to the artery, making a volar approach to the nerve difficult without injuring the artery. The artery is therefore at risk when using a volar approach to the ulnar nerve.
- Both the ulnar artery and nerve lie covered by the flexor carpi ulnaris muscle, and lie directly beneath the flexor carpi ulnaris tendon at its insertion to the pisiform bone¹¹.
- The artery and nerve lie at the level of the proximal wrist crease just next to the radial border of flexor carpi ulnaris.
- **Branches of the ulnar nerve at the wrist:** In the distal third of the forearm, approximately 5 cm proximal to the wrist, the ulnar nerve gives off the dorsal cutaneous branch of the ulnar nerve⁹. The dorsal cutaneous branch of the ulnar nerve is entirely sensory and proceeds beneath the tendon of flexor carpi ulnaris and reaches the dorsal aspect of the wrist and hand. The ulnar nerve, a mixed nerve, runs along the tendon of flexor carpi ulnaris to divide at the pisiform bone in Guyon's canal into a superficial palmar cutaneous branch and deep motor branch. The superficial palmar cutaneous branch of the ulnar nerve is entirely sensory supplying the ulnar aspect of the palm of the hand and the palmar surfaces of the little finger and ulnar side of the ring finger. The deep motor branch continues through Guyon's canal and supplies the hypothenar muscles, interosseous muscles, the medial two lumbrical muscles and the adductor pollicis muscle.
- During an ulnar nerve block at the wrist, the nerve is blocked before it bifurcates into the deep motor branch and superficial palmar cutaneous branch⁷.

- **Site of needle insertion:**

- **Ulnar approach:** The site of insertion is on the ulnar aspect of the flexor carpi ulnaris tendon at the proximal wrist crease. Direct the needle horizontally under the flexor carpi ulnaris tendon for a distance of 1-1.5 cm. Deposit 3 to 5 ml of anesthetic solution after finding paresthesia. The dorsal cutaneous branch of the ulnar nerve runs around the wrist to supply part of the dorsum of the hand. Block this by depositing 5 to 10 ml subcutaneously from the *same* insertion site to the dorsum of the wrist. The advantage with this approach is that the ulnar artery is less often injured¹⁶ and both the superficial and deep branches of the ulnar nerve as well as the dorsal cutaneous branch can be blocked through the same site of insertion⁷.
- **Alternative: Volar approach:** Insert needle at a right angle with the skin on the radial side of the tendon of flexor carpi ulnaris and the ulnar side of the ulnar artery, about 1 cm proximal to the pisiform bone at the level of the proximal wrist crease¹⁶. The superficial palmar cutaneous branch of the ulnar nerve lies between the tendon of the flexor carpi ulnaris and ulnar artery at the proximal wrist crease. Find the radial border of the tendon of flexor carpi ulnaris by flexing the wrist with reasonable force and pressing the fingers together⁹.

- **Variation of the ulnar nerve**

- Kaplan²⁷ describes an anomalous branch emerging from the dorsal cutaneous branch of the ulnar nerve, 2 cm proximal to the ulnar styloid process. It then coursed on the ulnar side of the pisiform bone to join the superficial palmar cutaneous branch of the ulnar nerve distal to the pisiform bone.
- König *et al*²⁸ reports a case where the ulnar nerve divided into three branches just before entering Guyon's canal.
- Olave *et al*²⁹ reports an ulnar nerve dividing into two branches approximately 6 cm proximal to the distal wrist crease, with the artery between the two branches. The medial branch was prominent and gave off the deep motor branch of the ulnar nerve 6 mm distal to the distal wrist crease. The lateral and medial branches joined again 35 mm distal to the distal wrist crease forming the common palmar digital nerve of the 4th interosseous space.

- **Guyon's canal**

- This fibroosseous tunnel extends for about 4 mm from the palmar carpal ligament at the proximal edge of the pisiform bone to the origin of the

hypothenar muscles at the level of the hamulus²⁰.

- The ulnar nerve bifurcates into the superficial palmar cutaneous branch and the deep motor branch, at a mean distance of 12 mm from the proximal border of the pisiform bone in the middle part of the tunnel²¹. This is a confirmation of an earlier cadaver based study done by Gross *et al*²⁰, where an average distance of 11 mm was found.
- The diameter of the ulnar nerve at the level of the pisiform bone is approximately 3 mm²¹.
- The ulnar artery divides into two branches, 3-7 mm beyond the bifurcation of the ulnar nerve.
- Gross *et al*²⁰ divides the tunnel into three zones. Zone 1 is the part proximal to the bifurcation of the ulnar nerve. Zone 2 represents the deep motor branch of the nerve and zone 3 surrounds the superficial palmar cutaneous branch of the ulnar nerve. Ulnar nerve compression syndromes can occur in any zone with subsequent motor (deep branch) and or sensory (superficial branch) loss.
- Cobb²⁶ proposed that from an anatomical point of view, Guyon's canal should be referred to as the carpal ulnar neurovascular space. The roof is formed by the antebrachial fascia's extension and the palmaris brevis muscle. The floor is formed by the muscles of the hypothenar eminence. The radial border is formed by the junction of the roof and the flexor retinaculum. The ulnar border is formed by the pisiform bone proximally and the fusion of the roof and the hypothenar eminence.

5.5 Radial nerve²

- The radial nerve is entirely superficial to the fascia as seen on a cross section of the wrist, just proximal to the styloid process of the radius¹⁹.
- **Sensory innervation:** The radial nerve supplies the radial aspects of the dorsum of the hand and portions of the dorsal aspects of the first digit. It also supplies portions of the second, third and radial dorsal aspect of the fourth digits. It supplies the dorsal surface up to the proximal or distal interphalangeal joint. It supplies part of the palmar aspect of the first digit as well⁹ and the lateral aspect of the thenar eminence¹⁶.
- **Motor innervation:** The radial nerve has no motor innervation in the hand.
- The superficial branch of the radial nerve follows the radial artery along the

medial side of the brachioradialis muscle. About 6-8 cm proximal to the wrist the nerve passes underneath the tendon of brachioradialis and lies subcutaneously on the extensor surface of the distal forearm⁹. It gives off branches before crossing the wrist. These branches supply the dorsolateral aspect of the hand.

- The superficial radial nerve runs subcutaneously on the roof of the anatomical snuffbox
- The superficial radial nerve can be palpated over the lateral border of the radius, just dorsal to the radial styloid process and proximal to the deepest palpable portion of the anatomical snuffbox¹¹.
- **Site of needle insertion**
 - Block the superficial branch of the radial nerve, by infiltrating under the brachioradialis tendon 6-8 cm proximally from the wrist.
 - Position the forearm in pronation. Identify the anatomical snuffbox and mark the bordering tendons. Identify the extensor pollicis longus and brevis muscles and the abductor pollicis longus muscle, bordering the anatomical snuffbox. Take a point over the tendon of the extensor pollicis longus tendon, opposite the base of the first metacarpal. The nerve is often palpable here¹⁶.
Direct a 25-ga needle proximally along the tendon as far as the dorsal radial tubercle and inject 2 ml subcutaneously. Withdraw the needle almost to the skin and redirect across and superficially to the anatomical snuffbox, to a point just past the extensor pollicis brevis tendon, and inject a further 1 ml anesthetic solution⁷.

5.6 Variation of the nerve supply of the hand

5.6.1 Sensory

- There is occasional crossover of sensory supply to the hand and fingers¹⁹. Exceptions are the distal portion of the second digit, which is as a rule supplied by the median nerve, and the fifth digit, which is as a rule supplied by the ulnar nerve⁹.
- Anatomic variation of the sensory nerve supply to the hand is often the reason for apparent failure of a regional block^{11,16}.
- The radial and ulnar supply to the dorsum of the hand, may enlarge and therefore reduce the area of supply of the other nerve. The ulnar nerve may even be absent in supplying the dorsum of the hand¹⁵.
- On the palmar side, the ulnar nerve may supply the whole of the fourth digit, reaching to the ulnar side of the third digit. It may also be demarcated to the fifth digit only¹⁵.

5.6.2 Motor supply

- The radial nerve never supplies any intrinsic muscles of the hand¹⁵.
- The ulnar nerve may supply part of or even all of the thenar muscles¹⁵.
- The median nerve may supply adductor pollicis and the 1st dorsal interosseous muscle¹⁵.

5.7 Facial compartments of the forearm at the wrist joint

- Both the median and ulnar nerves give off subcutaneous branches before they cross the wrist joint. The radial nerve however is entirely subcutaneous. The median and ulnar nerves are therefore deep to the volar fascia in a relatively large enclosed facial compartment. This makes it possible to inject a small amount of anesthetic solution without the need to elicit paresthesia¹⁹.
- Too large amounts of anesthetic solution injected in these confined facial compartments may lead to compression of vascular and lymphatic structures¹⁹.

5.8 Long flexor and extensor tendons

- An additional advantage of the wrist and digital nerve block is the fact that the long flexor and extensor tendons of the hand are not affected. This enables the patient to move his or her fingers and makes it possible to test for muscle-tendon integrity during the procedure and for example to test for the adequacy of a trigger-finger release¹². Also the patient can appreciate the extent of movement postoperatively and help the surgeon determine the extent of reconstructive surgical hand procedures²².

6. Complications (anatomically relevant)

6.1 Nerve damage

- There were many advocates for the need to elicit paresthesia during regional nerve blocks. This view has changed with studies of Selander *et al*⁴ showing nerve damage due to needle injury. Nerve stimulators have made the need to elicit paresthesia unnecessary. The need for a thorough knowledge of the anatomy, however, has not changed. The insertion site of the needle is still based on sound anatomical knowledge. The relations of the specific nerve are therefore very important.
- Smaller nerves lying over bone and in restricted fascial compartments are more vulnerable to ischemia or traumatic injury¹³. They do not slide away from the advancing needle and are more vulnerable to intraneural injection.
- For all nerve blocks it is best not to directly inject into the nerve, but around it.

- Selander *et al*⁴ showed that the damage caused by a needle depositing the local anesthetic solution may be significant. Neurological sequelae like sensory disturbances such as paresthesia, hyperesthesia, dysesthesia and pain as well as muscular paralysis can occur. Nerve impairment may be due to direct injury to the nerve, intraneural micro vascular injury as well as the toxic effects of the injected agent.
- In a subsequent study, Selander *et al*¹⁴ showed that intraneural injections should be avoided and solutions with epinephrine should also be avoided. It also seems that the sharp pointed needle (14° bevel) causes more axonal damage than a blunt tipped needle (45° bevel)⁴.
- Earle *et al*¹¹ confirms that intraneural injection should be avoided. This is suggested when intense paresthesia is felt on small volume injection⁷. Frederick *et al*²⁴ reports on the nerve damage of both median and ulnar nerves due to intraneural injection during carpal tunnel syndrome treatment.
- When searching for paresthesia, a nerve trunk may be injured, even though nerve fascicles have a tendency to slide and roll away from the advancing needle point.
- Possible pre-existing nerve injuries should be determined by two-point discrimination before the block is performed and should be documented properly. Advise the patient before the block.
- Except for anesthetic causes, wrong positioning of the patient, tight casts and dressings, tourniquet use and surgical trauma may also result in injury to peripheral nerves.

6.2 Vascular insufficiency

- **Vascular insufficiency** may result after digital nerve block as a result of digital arterial occlusion. This may be due to:
 - Epinephrine containing solutions⁷.
 - Excessive amount of local anesthesia injected². The mechanical pressure caused by the volume of anesthetic solution may obstruct the blood supply to the digit and cause ischemia. It may even result in gangrene of the finger⁶. Maximum volumes of 2 ml on each side should not be exceeded⁷.
 - Tourniquets, which are used to create a bloodless field⁷. The tourniquet should not be used for more than 15 minutes⁸.
 - Direct vascular injury, caused by the needle.
 - Inadvertent intravascular injection causing digit ischemia. Blanching of the

finger while injecting the anesthetic solution suggests intravascular injection, after which injection should be discontinued. The ischemia is usually transient. This may be different in patients with underlying vascular disease.

- Peripheral vascular disease. This technique should be avoided in patients with small vessel disease.

- **Gangrene of the finger**
 - Bradfield⁸ analysed the reported cases of gangrene of the finger following a digital nerve block. The following factors are mentioned: whether adrenaline was used, whether a finger tourniquet was used and the time of application, the volume of anesthetic solution injected and the presence of peripheral vascular disease. It seems that a combination of these factors increase the risk of finger gangrene developing. In a series of 267 patients, Bradfield⁸ showed that a finger tourniquet should not be applied for more than 15 minutes.

 - The following precautions should be taken:
 1. Never use adrenaline in the anesthetic solution
 2. Never use a tourniquet when there is a history of Raynaud's phenomenon.
 3. Should a tourniquet be used, do not use more than 2 ml of anesthetic solution on each side⁷.
 4. Do not apply the tourniquet for more than 15 minutes⁸
 5. Do not inject into an infected area.

6.3 Ineffective median nerve block

- This may be the case if the anesthetic solution is injected too superficially. The flexor retinaculum should be penetrated with the needle, because it forms a barrier between the nerve and the superficial tissue. A subcutaneous wheal after injection reveals inadequate depth of the needle¹².

6.4 Ineffective blocking of the palmar digital nerves

- These nerves are more palmar than often appreciated, and are almost adjacent to the flexor tendon. Injecting from the lateral side of the finger may miss the nerve. The palmar digital nerves are found on the edges of the skin creases made by flexing the DIP and PIP joints.

6.5 Ulnar artery injury

- When using a volar approach for blocking the ulnar nerve at the wrist, the artery may be injured due to its position superficial and medial to the ulnar nerve at this point. It is therefore recommended to use the ulnar approach to the nerve.

6.6 Block failure

- This may be due to variational anatomy of the sensory nerve supply to the hand.
- Certain areas of the hand need combined blocks at the wrist. The thumb for instance is innervated by both radial and median nerves and the ring finger by both median, radial and ulnar nerves. For effective anesthesia over the dorsum of the hand, both the superficial radial nerve and dorsal cutaneous branch of the ulnar nerve need to be blocked¹².

6.7 Reactions to the anesthetic solution^{8, 13}

- The dose used in digital nerve blocks is so small, that toxic reactions are very rare. Lignocaine is safe and should be regarded as the anesthetic solution of choice. Toxic signs should however always be kept in mind. These may be sensory disturbances peri-orally, visual disturbances, skin rash or anaphylactic reaction.

7. References

¹ Knoop K, Trott A, Syverud S. Comparison of digital versus metacarpal blocks for repair of finger injuries. *Ann Emerg Med* 1994;23:1296-1300

² Eriksson E. *Illustrated handbook in local anaesthesia*. 2nd ed. London: Lloyd-Luke(Medical Books), 1979: 50

³ Moberg E, Rathke FW. *Dringliche Handchirurgie*. Stuttgart: Georg Thieme Verlag, 1964

⁴ Selander D, Dhuner KG, Lundborg G. Peripheral nerve injury due to injection needles used for regional anesthesia. An experimental study of the acute effects of needle point trauma. *Acta Anaesthesiol Scand* 1977;21:182-188.

⁵ Chiu DTW. Transthecal digital block: Flexor tendon sheath used for anesthetic infusion. *J Hand Surg* 1990;15A:471

⁶ Abadir A. Anesthesia for hand surgery. *Orthop Clin North Am* 1970;1:205

⁷ Brown DL, Bridenbaugh LD. In the upper extremity, somatic block. In: Cousins M, Bridenbaugh PO (eds): *Neural blockade in clinical anesthesia and management of pain*. 2nd ed. Philadelphia: JB Lippincott, 1988: 364-70

⁸ Bradfield WJD Digital block anaesthesia and its complications. *Br J Surg* 1962;50:495-498

⁹ Lerversee JH, Bergman JJ. Wrist and digital nerve blocks. *Journal of Family Practice* 1981;13(3):415-421

¹⁰ Grant JC, Basmajian JV. *Grant's Method of Anatomy*, ed 7. Baltimore: Williams & Wilkins, 1965

¹¹ Earle AC, Blanchard JM. Regional anesthesia in the upper extremity. *Clinics in Plastic Surgery* 1985;12(1):97-114

¹² Melone CP, Isani A. Anesthesia of hand injuries. *Emerg Med Clinics of North Am*. 1985;3(2):235-243

¹³ Swerdlow M. Complications of local anesthetic neural blockade. In: Cousins M,

- Bridenbaugh PO (eds): Neural blockade in clinical anesthesia and management of pain. 2nd ed. Philadelphia: JB Lippincott, 1988: 655-661
- ¹⁴ Selander D, Brattsand R, Lundborg G et al. Local anesthetics: Importance of mode of application, concentration, and adrenaline for the appearance of nerve lesions. *Acta Anaesthesiol Scand* 1979;23:127
- ¹⁵ Ellis H, Feldman S. *Anatomy for anaesthetists*, 7th Ed., Oxford: Blackwell Science, 1997: 188-189
- ¹⁶ Mauldin CC, Brooks DW. Arm, Forearm, and Hand Blocks. In: *Pain Procedures in Clinical Practice*. TA Lennard, 2nd ed Philadelphia: Hanley & Belfus, 2000: 96-107
- ¹⁷ Hill RG, Patterson JW, Parker JC, Bauer J, Wright E, Heller MB. Comparison of transthecal digital block and traditional digital block for anesthesia of the finger. *Ann Emerg Med* 1995;25(5):604-607
- ¹⁸ Robson AK, Bloom PA Suturing of digital lacerations: Digital block or local infiltration? *Ann R Coll Surg Engl* 1990;72:360-361
- ¹⁹ Burnham PJ. Regional block at the wrist of the great nerves of the hand. *JAMA* 1958;167:847
- ²⁰ Gross MS, Gelberman RH. The anatomy of the distal ulnar tunnel. *Clinical Orthopaedics and Related Research* 1985;196:238-247
- ²¹ Zeiss J, Jakab E, Khimji T, Imbriglia J. The ulnar tunnel at the wrist (Guyon's canal): normal MR anatomy and variants. *American Journal of Roentgenology* 1992;158:1081-1085
- ²² Conolly WB, Berry FR. The place of peripheral nerve blocks in reconstructive hand surgery. *Hand* 1977;9:157-160
- ²³ Ramamurthy S. Anesthesia, in Green DP (ed): *Operative Hand Surgery*, 3rd Ed. London and Edinburgh: Churchill Livingstone, 1991: 47-48
- ²⁴ Frederick HA, Carter PR, Littler JW. Injection injuries to the median and the ulnar nerves at the wrist. *J Hand Surg* 1992;17A:645-647
- ²⁵ Robbins H. Anatomical study of the median nerve in the carpal tunnel and etiologies of the carpal tunnel syndrome. *J Bone Joint Surg* 1963;45A:953-66
- ²⁶ Cobb T, Carmichael S, Cooney W. Guyon's canal revisited: an anatomic study of the carpal tunnel neurovascular space. *Journal of Hand Surgery* 1996;21A:861-869
- ²⁷ Kaplan E. Variation of the ulnar nerve at the wrist. *Bulletin of the Hospital of Joint Diseases* 1963;24:85-88
- ²⁸ König P, Hage J, Bloem J, Prosé L Variations of the ulnar nerve and ulnar artery in Guyon's canal: a cadaveric study. *Journal of Hand Surgery* 1994;19A:617-622
- ²⁹ Olave E, Del Sol M, Gabrielli C, Prates JC, Rodrigues CF. The ulnar tunnel: a rare disposition of its contents. *Journal of Anatomy* 1997;191: 615-616

4.4.2.3 Rectal examination, proctoscopy and sigmoidoscopy

1. Indications	209
2. Contraindications	210
3. Step by step procedure	210
4. Materials	216
5. Anatomical pitfalls	216
6. Complications (anatomically relevant)	230
7. References	234

1. Indications

- The following are indications for digital rectal examination. Those that also apply for proctoscopy and/or sigmoidoscopy are marked P (Proctoscopy: Visualization of the anal canal and distal part of the rectum) and S (Sigmoidoscopy: Visualization of the anal canal, rectum and distal part of the sigmoid colon.)
- Anal foreign bodies. (P,S)
- Anal tears and fissures. (P)
- Hemorrhoids. (P,S)
- Bright red blood per rectum. (P,S)
- Recent change in stool character, from diarrhea to constipation. (P,S)
- Pain on defecation. (P)
- Anal pruritis, warts and fistulae. (P)
- Fecal impaction. (P)
- Proctitis/ colitis. (P)
- Rectal prolapse.
- Rectal polyps. (P,S)
- Diarrhea in the elderly. (S,P)
- Backache. (P,S)
- Urinary symptoms – prostatism. Digital prostatic evaluation.

- Anemia. (P,S)
- Chronic inflammatory bowel disease. (P,S)
- Assessing fecal incontinence²¹ – external sphincter dysfunction due to e.g. a spinal cord injury.
 - Internal sphincter dysfunction – Autonomic sphincter dysfunction, diabetes mellitus, central nervous system lesions.
- Assessing patients with abdominal symptoms. (S,P)
- Anorectal trauma. (S,P)
- Assessing the presence of fecal matter, its color, amount and consistency. (P)
- To trigger defecation in patients with obstructive constipation.
- Follow-up of patients after radical prostatectomy, combined with PSA screening.
- Abdominal pain in children especially in the presence of constipation, gastroenteritis, appendicitis, abdominal adhesions and abdominal pain of unclear origin¹³.
- Appendicitis – Good technique is necessary, to distinguish anal discomfort from the effect of pressure on the pelvic peritoneum.
- Removal of a foreign body in the rectum. (P,S)

2. Contraindications

- Imperforate anus
- Anal stenosis
- Precautions:
 - Active inflammation of the bowel.
 - Recent radiotherapy in the pelvic region.
 - Rectal surgery.
 - Patients with a history of abuse.
 - Spinal patients with known autonomic dysreflexia.

3. Step by step procedure

- Explain the procedure fully and reassure the patient that the procedure is not unduly painful although inconvenient. It may stimulate a desire to evacuate. Ng¹² did a survey amongst 103 patients who were rectally examined and found that patients

would like to be informed about the procedure. Informed verbal consent should be sufficient. The examiner should ideally be accompanied by a chaperone.

- Check if all the equipment is ready as well as an assistant.
- Appropriate analgesia and sedation is important.
Topical lidocaine jelly can be applied 5-10 minutes prior to the examination.
- **Position:**
 - The patient should be positioned in the lateral decubitus position or the knee-chest position. In the lateral decubitus position the knees and hips are flexed with the knees drawn to the chest and the patient's buttocks placed just over the edge of the bed. The patient's head and shoulders should remain in the center of the table. The back should be kept relatively straight with a pillow under the head.
This position directs the axis of the anal canal and rectum directly toward the examiner.
 - The knee-chest position is difficult in patients who are in severe pain and elderly and sick patients.
- Wash hands and put on gloves.

Digital rectal examination

Step 1. Inspection

- Look for signs of perianal inflammation, which may suggest pruritis or a dermatological condition.
- Gently evert the buttocks to visualize the presence of any anterior and posterior fissures.
- Be diligent especially if there is a sentinel tag in either the posterior midline or anterior midline.
- Anal skin tags, perianal abscesses, pilonidal sinuses, warts, fissures, fistulas, prolapsed rectal mucosa and external thrombosed hemorrhoids can be visible at this stage. Bulging or redness may result from a perianal or ischioanal fossa abscess.
- A bluish discoloration of the perianal region is typical of Crohn's disease⁸.
- Perianal pain is suggestive of a possible perianal abscess, fissure or thrombosed external hemorrhoids.
- Internal and external hemorrhoids are classically located in the right anterior (11 o'clock), right posterior (7 o'clock) and left lateral (3 o'clock) quadrants.

Step 2. Palpation

- Perform the rectal examination with a well lubricated finger, initially pressing with the finger against the anal verge at the 6 o'clock position.
- Ask the patient to strain before digital rectal examination, to evaluate the amount of perineal descent or tissue prolapse¹¹. This may reveal bleeding from internal hemorrhoids
- Sweep the finger over the smooth rectal mucosa in search of any abnormality lying in the bowel lumen, the bowel wall or outside the rectum. The transverse rectal folds (Houston's valves) of the ampulla can also be palpated⁹.
- Determine the presence of fecal impaction, fecal load, prostate size, bleeding, a mass, a foreign body, localized pain or pathology and the axis of the anal canal.
- Internal hemorrhoids and the pectinate line are not palpable. A large hypertrophic anal papilla may be palpable at the level of the pectinate line.
- Digital anal examination in the presence of an anal fissure can be very painful. The finger should be well lubricated and the patient asked to strain down¹.
- The left hand can be used simultaneously to palpate the abdomen. Masses and other possible pathology may now come into reach of the examining finger in the rectum.
- Explore the posterior and posterolateral walls of the rectum with the palmar surface of the finger. This can be done by sitting in a half-crouched position and pronating the wrist. The anterior surface of the rectal mucosa should also be palpated. Normal rectal mucosa is smooth and mobile.
- Male
 - Anterior: palpate the bulb of the penis and the spongy urethra, prostate and seminal vesicles.
 - Normal prostate:
 - A normal prostate gland is smooth on palpation. The palpation of two lateral lobes separated by a median sulcus is indicative of hypertrophy of the prostate gland²⁶. Bowel mucosa should move freely between the examiner's finger and the prostate.
 - A normal prostate is 3.5cm from side to side and protrudes 1cm into the rectum⁸. It has a smooth and rubbery consistency, with a shallow groove separating the left and right lobes.
 - Patients may experience an urge to urinate on palpation. The prostate gland is usually not tender.
 - Size, consistency, nodularity and tenderness are evaluated during

palpation.

- Abnormal prostate
 - Benign prostatic hypertrophy- smooth, rubbery and symmetrical enlargement of the prostate. The median sulcus can become indistinct and bulge more than 1 cm into the rectal lumen.
 - Cancerous prostate – assymetrical, stony hard consistency and discrete nodules may be palpable. The median sulcus is obliterated.
 - Tenderness of the prostate may reflect acute prostatitis, a prostatic abscess or inflammation of the seminal vesicles.
- Female
 - Posterior vaginal wall
 - Cervix,
 - Fundus of a retroverted uterus,
 - The ovaries can occasionally be palpated if situated in the recto-uterine pouch.
 - Tenderness in the right or left iliac fossa with salpingitis and ectopic pregnancy.
- Both sexes
 - Ischioanal fossa and ischial spines laterally.
 - Masses in the iliac fossa (best palpated with bimanual palpation).
 - Tenderness in the right iliac fossa with appendicitis.
 - Posterior – sacrum and the coccyx.
- Assess sphincter tone. For that, the finger is flexed slightly posterior and the patient asked to squeeze down as if to stop a bowel movement. The tightening of the external anal sphincter may be felt at the base of the examining finger.
An easy test to evaluate a possible major incontinence problem: give a 100 ml water enema in the office and observe how long the patient can retain it. If the patient is still continent after 5 minutes, a major incontinence problem is unlikely²¹.

Step 3. Examination of a specimen

- Examine the stool on the glove after the examination. Stools may be blood stained or pale or there may be pus or melenā stool representing gastrointestinal bleeding. Protozoal infection may be diagnosed, which can cause rectal bleeding.
- A prostatic smear can be done for microscopy and culture, by massaging the prostate gland to squeeze prostatic fluid to the urethral meatus.

Children

- Rectal examination should be considered a specialist examination in children to be performed in certain limited situations¹⁴.
- Dickson *et al*¹⁵ classifies the discomfort experienced by children during rectal examination as severe (major crying or screaming) or mild (minor crying or facial grimacing).
- The information obtained often has limited usefulness and a rational decision should be made on when it is indicated¹⁴. Dickson *et al*¹⁵ reports that in only two patients of 103 patients, rectal examination altered management.
- Information obtained from a rectal examination in children can often be obtained from modern imaging techniques like ultrasonography.
- Indications for rectal examination in children are: acute abdomen, trauma, gastrointestinal bleeding, abnormal neurology (e.g. spinal lesions) and congenital anomalies¹⁴.
- Advanced Pediatric Life Support (APLS) recommends a rectal examination should be carried out only when the result will alter management¹⁶.

Proctoscopy

Step 1. Insert the well-lubricated proctoscope with the obturator in place by gently advancing the scope. The scope should initially be directed anteriorly in the direction of the umbilicus and after reaching the rectum in a posterior direction. Once the anal sphincters at the anal orifice are passed, the proctoscope usually passes easily through the recto-anal area.

Keep the thumb on the obturator, for if it slides backwards, reinserting it may pinch the mucosa causing pain. Reinsert the obturator only if the whole proctoscope is removed.

Step 2. Guide the instrument through the anal sphincters to the upper anal canal. Once through the anal sphincters, tilt the tip of the proctoscope posteriorly to avoid pressure on the prostate gland. At this point the instrument can be advanced further.

Step 3. Once inserted, remove the obturator, visualize the anal canal and gradually remove the proctoscope while inspecting the walls of the anal canal. Internal hemorrhoids may be seen prolapsing into the lumen of the instrument.

Step 4. Take a swab if there is any discharge.

Step 5. The proctoscope can be rotated to visualize the whole anal wall.

Look for:

- Internal and external hemorrhoids.
- Anal fistulae.
- Tumors.
- Blood, pus.
- Ulceration and mucosal irregularities.
- Parasites.

Step 6. At the last stage of withdrawal, the reflex spasm of the anal sphincters cause the proctoscope to exit quickly.

Sigmoidoscopy

Step 1. Positioning the patient:

Placing a sandbag under the patient's left hip makes it easier to negotiate the bends in the rectosigmoid region. The patient's buttocks should be positioned close to the edge of the examination couch⁴¹.

Step 2. A digital rectal examination should be done first²⁸.

Step 3. Rigid sigmoidoscopy should be performed under general anesthesia.

Step 4. After passing the anal sphincter, remove the obturator and connect the light source.

Step 5. Direct the sigmoidoscope in the direction of the umbilicus.

Step 6. Advance the scope only when the lumen is visible, and do not use any force.

Step 7. Avoid stool or clear the stool with cotton wool pledgets held in a long biopsy forceps.

Step 8. Having entered the rectum, swing the viewing end of the sigmoidoscope anteriorly to facilitate for the sacral concavity of the rectum and advance into the rectum under direct vision. This is necessary due to the angle of the distal rectum as it joins the anal canal.

Step 9. Some side-to-side movement may be necessary to bypass the rectal inflexions or valves of Houston²².

Step 10. Keep going in this direction for about 15 cm until the recto-sigmoid junction is reached. Here the sigmoid colon bends forward and to the left.

- Step 11.** Therefore the viewing end of the scope should be swung posteriorly and superiorly to the patient's right hip. Advance the scope gently for it can easily perforate the bowel at this point.
- Step 12.** The distal part of the sigmoid colon can now be viewed to the full length of the sigmoidoscope (25-30 cm).
- Step 13.** Having reached the limit of the examination, note the color of the stool. Blood suggests bleeding proximal to this point.
- Step 14.** Withdraw the instrument carefully and look for evidence of mucosal abnormalities, polyps, carcinoma, ulceration, bleeding, exudates, fissures etc.
- Step 15.** Note the location of the lesions: distance from the anus and position on circumference of the sigmoid colon or rectal mucosa. This forms the formal part of the examination.

Caveat:

- Inflating enough air in the bowel for visualization is important however over inflation should be avoided due to patient discomfort. The pressure in the air reservoir bulb is the same as that in the rectum.
- Force should never be used and the scope should only be advanced in the presence of a visible lumen.
- Navigating the sigmoidoscope round the rectosigmoid junction can be difficult and uncomfortable for the patient.
- Avoid the insufflation of large volumes of gas during sigmoidoscopy in the event of anorectal trauma. Stool can be forced through a proximal bowel perforation into the peritoneal cavity¹⁰.
- Visualization of the sigmoid colon is seldom achieved during sigmoidoscopy.

4. Materials

- Sterile gloves.
- Lidocaine jelly.
- Sedation as needed.
- Proctoscope.
- Sigmoidoscope (rigid), with facilities for general anesthesia.

5. Anatomy pitfalls

5.1 Rectosigmoid junction

The rectosigmoid junction is approximately 15 cm from the anal margin. At this point the lumen crosses the sacral promontory.

5.2 Sigmoid colon

At the rectosigmoid junction the sigmoid colon bends forward and to the left. Therefore the viewing end of the scope should be swung posteriorly and superiorly to the patient's right hip. Perforation of the bowel can easily occur at this point.

5.3 Rectum

- The rectum starts where the sigmoid colon loses its mesentery opposite the third sacral vertebra. This is called the rectosigmoid flexure⁹.
- The rectum ends at the tip of the apex of the prostate in men and at the posterior wall of the vagina in women, 2.5-3.1 cm below the tip of the coccyx. Here it changes direction at right angles to become the anal canal⁴. Its total length is approximately 12.5 cm.
- The anorectal junction is called the perineal flexure of the rectum and is pulled anteriorly by the puborectalis muscle⁹.
- The inferior dilated part of the rectum is called the ampulla. The finger enters the ampulla after passing through the resistant external sphincter. The ampulla follows the concavity of the sacrum, which is called the sacral flexure⁹.
- The inferior third of the rectum is free of peritoneum as the peritoneum sweeps forward to form the recto-vesical pouch in the male and the recto-uterine pouch or pouch of Douglas in the female.
- The middle third of rectum is posterior and laterally free from peritoneum and most of the upper third of the rectum is covered by peritoneum anteriorly and laterally.
- Normal rectal mucosa has a smooth glistening and pink appearance. The vascular pattern is visible through the mucosa.
- The following mucosal changes may be experienced: granularity, hyperemia, contact bleeding, pus and blood and active ulceration.
- Rectal wall penetration of rectal carcinoma can be rather accurately determined by digital rectal examination, as Rafaelsen¹⁸ demonstrated. Penetration of the rectal wall was correctly identified in 56 of 61 patients by digital rectal examination compared to 59 of 61 patients with transrectal linear ultrasonography. Cases without penetration of the rectal wall were identified in 26 of 33 patients by transrectal linear ultrasonography and only in 13 of 33 cases by digital rectal examination. Ultrasonography is therefore superior to digital rectal examination in detecting early Dukes A rectal tumors¹⁸.

- Regional lymph node metastasis was not diagnosed in any patient by digital rectal examination. Tumors situated superiorly in the rectum cannot be reached with the finger¹⁸.
- The rectum is straighter in a child and relatively larger⁴.

5.3.1 Endoscopic anatomy of the rectum

5.3.1.1 Rectal curves

- The rectum curves in an antero-posterior or sagittal plane. It has a marked antero-posterior curve following the concavity of the sacrum.
- The rectum also curves in a coronal plane. The upper and lower thirds are straight, but the middle third curves to the left. This causes inflections into the rectum. Usually two lie to the left and one to the right⁴. These inflections can be seen with a sigmoidoscope and are referred to as the valves of Houston who first described them²². See Fig 1.

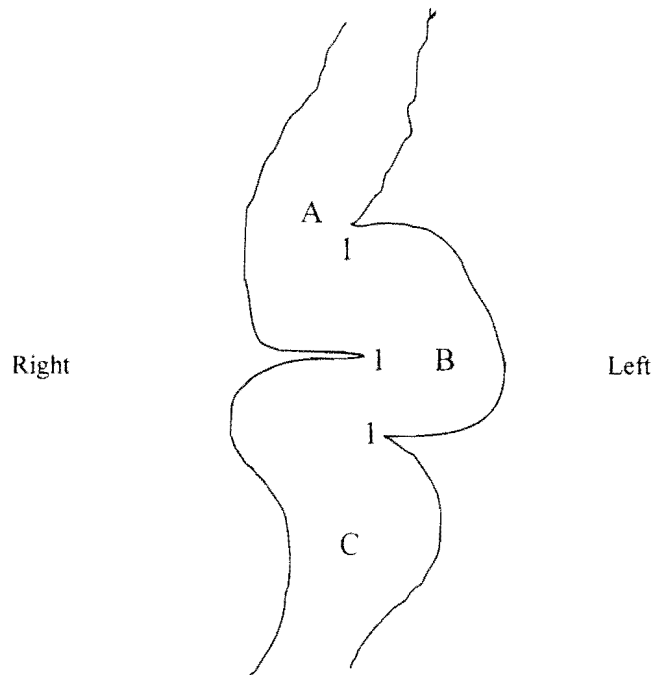


Fig 1. Diagram illustrating the rectum (sagittal section) with the transverse rectal folds (Houston's valves) (1), the upper third (A), the middle third (B) and the lower third (C)

5.3.1.2 Valves of Houston²² (transverse rectal folds)

- Houston²² describes the position of the largest and most regular fold to be three inches from the anus opposite the base of the bladder. Another fold is found near the upper end of the rectum and a third fold somewhere between these two. Houston²²

described an infrequent fourth fold found approximately an inch above the anus.

- The valves contain all the layers of the rectal wall including the outer longitudinal muscular layer. Silver²³ describes their embryological development. First the submucosa becomes thickened followed by the invasion of the circular and longitudinal muscular layers and the perirectal connective tissue. The same findings were reported by Shafik *et al*²⁴ who rarely found that the folds were purely mucosal. The rectal folds thus formed contain mucosa and circular muscle, unlike the mucous membrane only of the valvulae conniventes of the small bowel. This minimizes the risk of perforation during a rectal biopsy.
- The lumen of the rectum therefore has a tortuous path through the valves of Houston²² and is described by Silver²³ as 'horizontal baffle plates' from the lateral wall of the rectum.
- Shafik *et al*²⁴ reports in a cadaver-based study (n=18) that the number of the transverse rectal folds varies. Most had two or three folds, but in a few cases there were more than three folds and even no folds at all. The folds are thick at the base and become thinner towards the midline. Most folds actually extend beyond the midline of the rectal lumen.
He also studied the folds radiologically on barium enemas. In most subjects two or three folds were present. The folds approach the midline of the rectum in two thirds of the subjects.
Of the 54 subjects studied, either radiologically (n=36) or dissection-based (n=18), the folds were absent in 3.7% of cases. The total number of cases with two or three folds was 77.7%, with the threefold pattern being the most frequently observed.
- Shafik *et al*²⁴ proposes that the transverse rectal folds delay the passage of stool due to the fact that they compartmentalize the rectum in a shelving fashion. This prevents a sudden entrance of stool into the rectum and resulting defecation sensation in inopportune circumstances.
- Shafik *et al*²⁴ describes the position of the folds from superior to inferior in most of his cases: Left, right and again left on the inner aspect of the rectal wall. The second fold from superior was in all cases positioned on the right.
- Two folds are found in the rectal ampulla: longitudinal and horizontal. The longitudinal folds are mucosal folds that disappear during distention of the rectum. The horizontal folds are circular muscular layers and are enhanced with distention.
- According to Godlewski *et al*⁹, three prominent folds can be identified: superior, middle and inferior.
 - The superior fold is found below the rectosigmoid flexure. The superior fold forms the upper margin of the ampulla. It also represents the junction between the upper part of the rectum from the hindgut and the middle part from the cloaca.

- The middle fold divides the ampulla in a superior suprapерitoneal part, which can distend laterally in the pelvirectal cavity and therefore serve as a space for storage of feces, and an inferior infraperitoneal part in a confined position in the pelvic cavity and therefore usually empty between defecation. The clinical implication of the middle transverse rectal fold is important. Perforation above the middle fold result in an intraperitoneal perforation whereas perforation below this fold does not lead to an intraperitoneal perforation.
- The inferior fold is found 2-3 cm below the middle fold, is not always present and is situated on the left side of the ampulla.

- **Measurements²⁴**

- **Distances from the anal verge:**
Inferior fold: 7.2 cm (adult); 2.8cm (neonates)
- **Distance between folds:**
Adults: 2.8cm
Neonates: 1.2 cm
- **Mean length of folds:**
Adult: 4.8cm
Neonates: 1.1cm
- **Mean thickness at the base:**
Adults: 0.8cm
Neonates: 0.36cm

5.3.2 Relations of the rectum

Posterior

- The anterior surface of the sacrum (S3,S4 and S5) and coccyx can be felt. Lesions of the bone and presacral space can be palpated.
- Coccydynia may be diagnosed on producing pain during movement of the coccyx.
- The median sacral artery and branches of the superior rectal artery are found posterior to the rectum⁹.

Anterior

Male:

- The seminal vesicles may just be reached with the tip of the finger. It is difficult to palpate normal seminal vesicles, but a pathologic vesicle may be palpated.
- The bladder lies directly anterior to the seminal vesicles and can only be

palpated when it is distended.

- The prostate lies inferior to the bladder. The rectum slides easily over the posterior surface of the prostate due to the rectovesical septum.

Female:

- The cervix can be palpated with superior to it the recto-uterine pouch and inferiorly the posterior vaginal wall.
- Between the rectum and the bladder in a male and rectum and uterus in the female, loops of ileal coils and sigmoid colon may be found.

In both male and female, lesions of the peritoneum may be felt through the anterior wall of the rectum

Lateral

- The superior part of the rectum has the pararectal fossae laterally. During distention of the ampulla, the lateral surface can stretch to the parietal pelvic peritoneum, the superior part of levator ani, the pelvic ureter and the posterior branches of the internal iliac artery and vein.
- In women, the uterine tubes and ovaries are lateral to the superior part of the rectum.
- Below the peritoneal attachment line, the parasympathetic sacral splanchnic nerves (S2,3,4), hypogastric nerves and hypogastric plexus with the sympathetic trunks of left and right are found lateral to the rectum.

5.3.3 Arterial supply

- The rectum is supplied by the superior, middle and inferior rectal arteries and the median sacral artery.
- The superior rectal artery emerges from the inferior mesenteric artery.
- The middle rectal artery arises from the internal iliac artery and is unilateral in 22% of cases
- The inferior rectal artery arises from the internal pudendal artery.
- The median sacral artery emerges from the abdominal aorta and runs posterior to the rectum.

5.3.4 Veins

- Three rectal venous plexuses are found: the external, internal and perimuscular plexus. The external rectal venous plexus is found between the subcutaneous part of the external sphincter and the anal skin. Enlargement of this plexus causes external hemorrhoids⁹. They occur below the pectinate line and can easily be identified on inspection¹.
- The plexuses drain via the superior rectal vein (portal route), middle and inferior rectal veins (systemic route) as well as the median sacral vein

(systemic route).

5.3.5 Lymphatic drainage

- The lymphatic vessels follow the venous drainage of the rectum via the superior, middle and inferior rectal veins.

5.4 Anus

- The anus forms the terminal 3.1 to 3.75 cm of the gastrointestinal tract⁴.
- The anal canal starts from the rectum below the tip of the coccyx in a downward and posterior direction.
- Any instrument that is passed into the anal canal, should therefore initially be directed anteriorly in the direction of the umbilicus and after reaching the rectum in a posterior direction.
- Two parts with distinct differences concerning arterial blood supply, venous drainage, nerve supply, lymphatic drainage, epithelium and embryological origin, can be identified superior and inferior of the pectinate line.

5.4.1 Embryology⁹

- The upper part is derived from the cloaca and the mucous membrane forms sinuses and anal columns. The epithelial lining is stratified columnar epithelium.
- The lower part below the pectinate line is of ectodermal origin and is lined by squamous epithelium.

5.4.2 Endoscopic anatomy of the anal canal⁹

- The lumen is divided into three parts: the columnar zone, the transitional zone or pecten and the cutaneous zone.
- Columnar zone: this is the superior part of the anal canal. It has 5 to 10 longitudinal mucosal folds called the anal columns of Morgagni. Every column has a terminal branch of the superior rectal vessels. Enlargements of these veins are called internal hemorrhoids.
The color of the mucosa is purple due to the rectal venous plexus. At the base of every column, small mucosal folds, called anal valves are found. The alignment of these valves forms the pectineal line⁹.
The anal sinuses are above the anal valves and inbetween the anal columns. These may get infected or form abscesses.
Anal glands empty into the anal crypts in the region of the anal sinuses at the pectinate line.

- The transitional zone extends approximately 1.5cm. It forms a purple ring sometimes called the white line, between the columnar epithelial mucosa and the anal skin. It is located at the intersphincteric groove (between the subcutaneous part of the external anal sphincter and the lower border of the internal anal sphincter).
- The cutaneous zone appears white or brown and the epithelium contains sweat glands and sebaceous glands.

5.4.3 Relations

- Posterior: Coccyx and anococcygeal raphé
- Anterior:
 - Perineal body
 - Bulb of the penis in the male
 - Posterior vaginal wall in the female.
- Lateral: Ischioanal fossa with the inferior rectal nerve and vessels.

5.4.4 Nerve supply⁹

- Proximal to the white line the anal mucosa is supplied by the autonomic nerves plexus and inferior to it by the inferior rectal nerve (somatic nerve). Lesions below the white line are therefore very painful and conditions above the line are usually without pain.
- The sympathetic nerves are inhibitory to the musculature and responsible for the tonus of the internal sphincter. The parasympathetic supply causes movement of the muscles of the rectum and relaxes the internal sphincter for defecation.

5.4.5 Epithelium

- The pectinate line contains glands, which secrete mucus to lubricate the anal canal. It also has anal valves that lie at the distal end of numerous (5 to 10) vertical anal columns.
- Anal crypts are found at the pectinate line and can cause perianal abscess.
- A number of 4 to 8 anal glands open into the anal crypts. They may become infected or be the site for neoplastic change.
- Squamous epithelium is found distal to the white line and columnar epithelium proximal to the white line.
- The squamous epithelium is modified skin devoid of skin appendages.

- Proctoscopically, the epithelial color changes from pink mucosa above, to purplish near the pectinate line and pale below the white line.
- At the anorectal junction, there is mixing of the two epithelial layers, which is called the transition zone.

5.4.6 Arterial blood supply

- Proximal to the pectinate line, the anal canal is supplied by the superior rectal artery from the inferior mesenteric artery and the middle rectal artery from the internal iliac artery, and distal to the line by the inferior rectal artery, which is a branch of the internal pudendal artery.

5.4.7 Venous drainage

- A porto-systemic anastomoses is formed around the pectinate line. Hemorrhoids may theoretically form. Ger⁴ states that it is difficult to prove cause and effect, but strong bleeding after biopsies in patients with schistosomiasis reflect the importance of this anastomosis.

5.4.8 Hemorrhoids

- **Internal hemorrhoids** are just proximal to the pectinate line, and external hemorrhoids just distal to the line. These are considered to be collections of veins and arteries that represent normal anatomy and are not considered varicose veins.
- Internal hemorrhoids are varicosities of the submucous plexus in the wall of the anal canal and lower rectum. They are radicles of the superior rectal vein and contain a branch of the superior rectal artery and mucosal covering.
- Unless thrombosed they are not palpable.
- The branches of the superior rectal vessels are regularly distributed, explaining the common positions of the internal hemorrhoids at 3,7 and 11 o'clock as seen in the lithotomy position.
- Internal hemorrhoids can be better appreciated at proctoscopy¹.
- Hemorrhoids can be classified as: Grade 1 hemorrhoids which bulge and bleed at the time of defecation. Grade 2 which prolapses during defecation but return spontaneously. Grade 3 which prolapses from the anal canal at any time, but especially during bowel movement. They require digital replacement. Grade 4 represents permanently prolapsed hemorrhoids¹.
- The cardinal symptoms of hemorrhoids are pruritis ani (itching), bleeding, protrusion

and pain.

5.5 Anal sphincters

- Voluntary continence is maintained by the external anal sphincter and puborectalis muscle. Involuntary continence is maintained by the internal anal sphincter.
- Modern imaging techniques like endosonography of the anus, gives a 360° view of the sphincters, both internal and external¹¹.

5.5.1 External anal sphincter.

- The external anal sphincter is external to the internal sphincter not only from a medial to lateral aspect, but also from a cephalad to caudad aspect at the anal verge.
- The external sphincter extends from the anal verge to the anorectal ring.
- The sphincter has three parts: subcutaneous, superficial and deep.
 - The deep part is found around the superior part of the anal canal. with its fibers mixing with the puborectalis muscle.
 - The superficial part is found at the level of the anocutaneous or white line.
 - The subcutaneous part is found surrounding the cutaneous zone of the anal canal.
- Cagnard *et al*⁴⁰ described the nerve supply to the external anal sphincter. In a study of 45 dissections, three branches were identified: 1) Inferior rectal branch, 2) the anterior branch from the external perineal nerve and 3) an independent posterior branch. The inferior rectal branch and anterior branch always emerged from the pudendal plexus. The posterior branch emerged either from S4 or from the inferior rectal nerve and was found in 31% of cases. Cagnard *et al*⁴⁰ suggests that suitable names for these nerves would be anterior, middle and posterior anal nerves.

5.5.2 The anorectal ring

- The anorectal ring is located 1 to 2 cm above the pectinate line.
- This palpable anorectal ring represents mainly the puborectalis muscle, but also includes the deep portion of the external anal sphincter and the internal anal sphincter, encircling the very distal rectum from its anterior point of attachment at the pubis.
- The puborectalis comes from the posterior aspect of the pubis and passes postero-inferior to the rectum to form a sling with the other side. Some of the muscles blend with the external anal sphincter⁴. This sling forms the

80-90° angle of the anteriorly and inferiorly directed rectum passing into the posteriorly and inferiorly directed anal canal.

- The puborectalis muscle is palpable along its whole length during rectal examination.

5.5.3 Internal anal sphincter

- The internal anal sphincter consists of a double muscular layer, which is a thickening of the circular muscle coat of the rectum. It is controlled by autonomic nerves.
- The intersphincteric groove is formed between the upper border of the subcutaneous part of the external anal sphincter and the lower border of the internal anal sphincter. This can be palpated during rectal examination.

5.6 Anal sphincter tone

- Resting tone is reflected by function of the internal anal sphincter whereas squeeze pressure is reflected by function of the external anal sphincter. The difficulty to initially insert the digit is due to the tone of the internal anal sphincter³⁶.
- Kaushal *et al*²¹ has demonstrated that the estimation of anal sphincter squeeze pressure by digital examination compares favorably with objective manometric determinations of anal sphincteric pressure. Digital examination is therefore an excellent screening tool for assessing sphincter tone.
- The anal sphincter squeeze pressure can be subjectively estimated by the following scale²¹: 1=absent, +1=markedly reduced, +2=reduced, +3= normal.
- Puborectalis will also contract (in the anorectal ring) during squeezing of the anal sphincter, pulling the tip of the examining finger from posterior to anterior. When sweeping the finger around the circumference of the distal rectum at the level of the anorectal ring, the point of fixation of the puborectalis at the symphysis pubis may be palpated.

5.7 Peritoneum

- Reflections of the peritoneum form the recto-uterine pouch in female and the rectovesical pouch in male.
- The visceral pelvic peritoneum surrounds the rectosigmoid junction.
- The peritoneum is attached to the posterior wall of the vagina in women to form the recto-uterine pouch. This pouch is on a lower level compared to the rectovesical pouch in men. The distance from the pouch to the anus is 5.5 in women cm and 7.5

cm in men. The recto-uterine pouch is bordered laterally in women by the recto-uterine folds.

- The recto-uterine pouch contains ileal coils and sigmoid colon in women.
- The rectum can be divided into a superior part that is located intraperitoneally and an inferior part, which is located subperitoneally. This division is usually at the level of the middle transverse rectal fold (valve of Houston ²²) ⁹.

5.8 Pelvic cavity

- Tenderness high up in the rectum during digital examination may reveal pathology in the pelvic cavity.
- Tenderness in the recto-uterine or rectovesical pouches may suggest injury to an intra-abdominal organ with blood collection in the pouch, or a ruptured ectopic pregnancy or pus from an inflamed organ such as the uterine tube or appendix.
- Deposits from an intra-abdominal malignancy like stomach carcinoma may be palpable in the pouch through the wall of the rectum.

5.9 Right iliac fossa

- Tenderness in the right iliac fossa as experienced by digital rectal examination, is more common in patients with acute appendicitis. However the other symptoms and clinical signs of acute appendicitis such as pain, anorexia, nausea and vomiting, tenderness in the right iliac fossa, rebound tenderness and guarding are more specific. Dixon *et al* ³² studied 1204 patients with pain in the right iliac fossa, 1028 of who had a digital rectal examination. He found that the abdominal signs are better predictors of appendicitis. If rebound tenderness in the right iliac fossa is present, a rectal examination does not provide any further diagnostic information.
- In a study performed by Dickson *et al* ¹⁵ on 103 children, the correct diagnosis was made in 90% of cases by the history and abdominal findings during physical examination. Rectal examination altered management in only two cases. He also found that a rectal examination was a poor indicator for pelvic sepsis postoperatively. Rectal tenderness was present in the absence of acute appendicitis in 12% of children. Dickson concludes that the rectal examination is not necessary in children presenting with a clear history and abdominal signs of appendicitis. It remains important in those with acute abdominal symptoms, but inconclusive abdominal signs. This may be the case in pelvic appendicitis with or without abscess formation.

5.10 Coccyx

- The fifth sacral vertebra and the first coccygeal vertebra are commonly fused⁴.

- A fracture of the coccyx will present with extreme pain when palpating the posterior wall of the rectum.

5.11 Prostate

- The prostate has a firm rubbery consistency and a smooth surface. Nodules or smooth enlargement may be palpated. Tenderness may indicate infection of the gland.
- The following are abnormal findings of the prostate during digital rectal examination³⁴: Nodularity, induration, asymmetry or absence of the median sulcus.
- A normal prostate is 3.5cm from side to side and protrudes 1cm into the rectum⁸. It has a smooth and rubbery consistency, with a shallow groove separating the left and right lobes.
- There is no exterior lobular configuration of the prostate gland. The prostate is divided in zones rather than lobules. McNeal²⁵ described a peripheral zone, a central zone surrounding the ejaculatory duct and a transitional zone lateral to the prostatic urethra. Benign prostatic hypertrophy (BPH) develops in the transitional zone. In BPH, an identifiable lobar architecture develops, which was absent before the hyperplasia²⁶. Above the age of 35, the hyperplastic process starts with the growth of adenomatous acini forming right and left lateral lobes, a middle lobe surrounding the urethra and sometimes a periurethral anterior lobe. These are adenomatous lobes growing from the transitional zone compressing the peripheral zone, by displacing the normal relatively homogenous prostate. Therefore, when performing a rectal examination and palpating a left and right lateral lobe, this will be attributed to BPH. The normal prostate becomes a thin compressed capsule. A lobar architecture of the prostate as palpated during rectal examination is therefore abnormal²⁶.
- Except for digital examination, the prostate can also be imaged by magnetic resonance and transrectal ultrasonography.

5.11.1 Accuracy of rectal examination in detecting prostate carcinoma:

- **Size of the gland**
 - Digital rectal examination underestimates the size of the prostate¹⁷.
 - Bissada *et al*³⁸ found that more than 50% of the estimates for prostate size differed from the actual adenoma weight.
- **Size of nodule or indurated area**
 - Spigelman *et al*³⁷ found that the rectal examination estimates of

tumor size correlated poorly with the actual tumor area as determined histologically. They conclude that the examining finger actually only assesses differences in firmness between regions of the prostate. The digital rectal examination is useful as a screening method, but not for staging or grading prostate carcinoma.

- Phillips *et al*²⁰ concludes that a digital examination is not an accurate examination for prostate carcinoma.

5.11.2 Reliability of rectal examination (Will the conclusions of different observers be the same?)

- In a study done by Phillips *et al*²⁰ to assess the reliability of the digital rectal examination, the interobserver variability was high.
- However with proper teaching, the reliability increased. They correlated the rectal examination with rectal ultrasonography and propose the teaching of digital rectal examination by correlating it to rectal ultrasonography of the prostate gland.

5.11.3 Specificity and sensitivity

- For prostate carcinoma, a digital rectal examination is a specific test. Phillips *et al*²⁰ reports that if a patient has a prostate cancer with a palpable nodule, it is very likely to be adenocarcinoma.
- Digital rectal examination is however not very sensitive. Many patients who are dying from prostate carcinoma, never develop a palpable abnormality of the prostate²⁰. This justifies the use of rectal ultrasonography, which is more sensitive.
- Phillips *et al*²⁰ categorically states that although there are limitations to the value of digital rectal examination regarding the diagnosis of prostate carcinoma, it remains the principal method for the early detection of prostate carcinoma.

5.11.4 Posterior surface of the prostate

- Roehrborn *et al*¹⁷ has demonstrated that the posterior palpable surface of the prostate as examined by digital rectal examination, correlates well with prostate size. The posterior surface area of the prostate should not be more than 7 cm².

6. Complications (anatomically relevant)

6.1 Pain

- Dickson *et al*¹⁵ reports that pain is an important consideration in children undergoing rectal examination. In a study of 103 children over a third experienced severe discomfort.
- External hemorrhoids below the pectinate line cause significant pain¹. Internal hemorrhoids found above the pectinate line present with painless bleeding.
- Crampy abdominal pain can be experienced during sigmoidoscopy due to insufflations of air.

6.2 Digital rectal examination not performed

- Studies show that only half of patients with anorectal symptoms have a rectal examination before being referred. Delay in the diagnosis of colorectal cancers is related to the doctor in a quarter of cases²⁹.
- De Klerk³⁰ reports that 35% of patients with prostate cancer do not have a rectal examination performed before referral.
- Hennigan *et al*³¹ points out that the proper undergraduate and postgraduate training of digital rectal examination, increases the frequency of the performance of rectal examination.
- Yanoshak *et al*³⁹ reports on improved performance of prostate evaluation by digital rectal examinations by general practitioners. He used a three dimensional prostate model to teach the procedure.
- No patient with anorectal symptoms should be reassured by his doctor without performing a rectal examination.

6.3 Cardiac dysrhythmias

- Munter *et al*² reports on a 75-year-old man who developed ventricular fibrillation during a digital rectal examination.
- Syncope and bradydysrhythmias have also been reported. These are all very rare complications and are postulated to be vagally mediated.
- Fletcher *et al*⁶ showed that 70% of patients during routine sigmoidoscopy, demonstrated ECG changes like increased heart rate, ectopic beats and bradycardia in 4% of patients. These changes were not seen during digital rectal examination or

during insertion of the sigmoidoscope. The increased heart rate and ectopic beats were probably due to anxiety and catecholamine release. Fletcher *et al*⁶ demonstrated that there was a significantly greater frequency of an increase in the ectopic beats of those patients with existing heart disease (40%) than those without (17%).

- In a subsequent study Earnest *et al*³⁵ performed digital rectal examinations on 86 patients with acute myocardial infarctions 24 hours after admission to the hospital. They observed no electrocardiographic effects and no angina pectoris was elicited. They found 12 patients with marked prostate enlargement. It is therefore clear that the benefits gained from a digital rectal examination outweigh the small risk of bradycardia and arrhythmias.
- Rectal examination is important in clinical situations like acute gastrointestinal bleeding, trauma patients, patients with neurological deficits, patients with unexplained postural hypotension or anemia, or before starting anticoagulant therapy². Patients need to be individualized and a patient with an acute myocardial infarction with no specific reason to perform a digital rectal examination can wait a week or so for this examination.
- There may be two reasons for ventricular fibrillation during rectal examination. The rectum is innervated by parasympathetic fibers, which are pressure sensitive. They transmit via the parasympathetic sacral splanchnic pathway (S2,3,4) and relay in thalamic and brainstem nuclei resulting in increased vagal tone⁷. This causes a bradycardia and ventricular ectopic beats that can cause ventricular arrhythmias. The second reason may be catecholamine release.

6.4 Elevated Prostatic Specific Antigen (PSA)

- There has been concern that a serum-PSA level done after digital rectal examination may be falsely elevated due to the procedure.
- Crawford *et al*³ however demonstrated in a prospective trial of more than 2000 patients, that digital examination did not significantly elevate levels of serum-PSA.

6.5 Injury to the mucosal wall

- Both a proctoscopic and sigmoidoscopic examination may result in irritation of the mucosal wall, with abrasion and increased bleeding.

6.6 Transmittance of infectious diseases

- Infectious diseases like Hepatitis B, Condilomata accuminata, Genital Herpes simplex virus and Human Immuno deficiency Virus (HIV) can be transmitted with the procedure. Sterilizing instruments is an imperative.

6.7 Perforation

- The most common cause for anorectal trauma is iatrogenic by diagnostic and therapeutic procedures¹⁰.
- Perforation is a surgical emergency and requires prompt operation.
- No force should be applied to advance the proctoscope or sigmoidoscope. This is especially true at the angles of the rectosigmoid junction and recto-anal junction as well as the concave curve of the rectum anterior to the sacrum.
- The risk of perforation during the taking of a biopsy is reduced by performing the biopsy postero-laterally. This area is not intraperitoneally but extraperitoneally.
- A barium enema should not be performed for 5 days after a biopsy was done.
- The scope should not be advanced unless bowel lumen is clearly seen at the tip of the scope.
- Excessive depth of biopsy in the rectal wall should be avoided and great care should be taken with electrocautery.
- Perforation of the rectal wall involving the superior two thirds of the rectum, usually involves the peritoneal cavity whereas perforation of the inferior third does not involve the peritoneal cavity. This is due to the peritoneal coverings of the rectum.
- Foreign bodies in the rectum can be classified in high and low lying objects. High lying objects are above the rectosigmoid junction and low-lying objects below this junction and therefore digitally palpable. Perforation may occur during insertion of the object or during attempts to remove the object⁵.
- The American Association of the Surgery of Trauma has graded rectal injuries according to an anatomical description¹⁰. Grade 1 – Hematoma, contusion without devascularization or a partial-thickness laceration, Grade 2 – laceration of <50% of the mucosal circumference, Grade 3 – laceration of > 50% of the mucosal circumference, Grade 4 – Full thickness laceration with extension into the perineum and Grade 5 – devascularized segment.
- Colon perforation combined with genitourinary injuries, can result in pelvic, suprapubic and subphrenic abscesses as well as fistulae and strictures¹⁰.

6.8 Excessive bleeding

- Excessive bleeding may occur due to a biopsy of a vascular lesion, tear of the bowel wall, a coagulation defect and palpation of an ulcerating tumor in the rectum.

6.9 Underestimating the size of the prostate gland

- Roehrborn *et al*¹⁷ showed in a study correlating prostate size estimated through digital rectal examination with volume measured by transrectal ultrasonography, that prostate size was underestimated in 25-55% of men with a prostate volume of over 40 ml.
However, the posterior surface area of the prostate as measured by digital examination, correlated well with the transrectal ultrasonography measurement. It seems that the posterior surface area of the prostate greater than 7 cm² to determine large prostates is a useful preliminary assessment.
- The ratio of the posterior prostate surface to the prostate volume decreases with age. This explains why a digital rectal examination will underestimate the volume of the prostate as it enlarges. Furthermore, the lateral borders of the posterior surface of the prostate gland are difficult to exactly demarcate during a digital rectal examination with underestimation of the prostatic volume as a result¹⁷.
- Transrectal ultrasonography and MRI can determine prostate volume more accurately.

6.10 Missing pathology

- The sensitivity of digital rectal examination to rectal carcinoma and appendicitis is low. It is difficult to feel abnormalities of the rectal mucosa¹⁹.
It is however higher for prostate carcinoma¹⁹, although patients with prostate cancer may never develop a palpable abnormality²⁰. Hoogendam *et al*³³ did a meta-analysis of several studies to determine the specificity, sensitivity and positive and negative predictive values for digital rectal examination in the screening of prostate carcinoma. The examination has a high specificity and negative predictive value but lower sensitivity and positive predictive value. Therefore a digital rectal examination should be confirmed with other confirming tests, whether it is positive or negative.
- A lower rectal tumor may be missed if only a proctoscopy or sigmoidoscopy is done. A digital rectal examination should always be done first.
- Digital rectal examination and PSA screening remain the standard in early detection tests of prostate carcinoma³⁴.

6.11 Bacteremia

- Due to trauma to mucosal surfaces, transient bacteremia may occur. It has been reported in 0-9.5% of patients after a sigmoidoscopy. Hoffman *et al*²⁷ reports in a study of 74 patients undergoing a digital rectal examination with an initial negative blood culture, an incidence of 4% having positive blood cultures after the procedure. The venous drainage of the anal canal below the pectinate line is systemic via the inferior and middle rectal veins. Blood from above the pectinate line drains into the

portal system. A porto-systemic anastomosis exists. Trauma to the inferior part of the anus (systemic venous drainage) during a sigmoidoscopy, proctoscopy and digital rectal examination, is more likely to cause bacteremia, for the liver serves as an excellent filter for bacteria (portal venous drainage).

- Trauma during digital rectal examination is probably little more than that occurring during defecation.
- Hoffman *et al*²⁷ states that there is no reason to give prophylactic antibiotics to patients with cardiac lesions undergoing rectal examination, for the bacteria isolated are not known to cause endocarditis.

6.12 View obscured by feces

- Cotton wool pledgets may be used during a sigmoidoscopy to clear the view. The procedure may also be repeated after the patient had an enema. This may be necessary due to the fact that patients with chronic constipation may have feces present in the whole rectum⁹.

7. References

- ¹ Mazier WP. Hemorrhoids, fissures and pruritis ani. *Surg Clin North Am* 1994;74:1277
- ² Munter DW, Stoner RS. Ventricular fibrillation during rectal examination. *Am J Emerg Med* 1989;7:57
- ³ Crawford ED, Schultz MJ, Clejan S et al. The effect of digital rectal examination on prostate-specific antigen levels. *JAMA* 1992;267:2227
- ⁴ Ger R. Surgical anatomy of the pelvis. *Surg Clin North Am* 1988;68:1201-1216
- ⁵ Wigle RL. Emergency department management of retained rectal foreign bodies. *Am J Emerg Med* 1988;6(4):385-389
- ⁶ Fletcher GF, Earnest DL, Shuford WF et al. Electrocardiographic changes during routine sigmoidoscopy. *Arch Intern Med* 1968;122:483-486
- ⁷ Adams RD, Victor M. *Principles of Neurology* (ed 2). New York; McGraw-Hill, 1981: 362-383
- ⁸ Epstein O, Perkin GD, De Bono DP, Cookson J. *Clinical Examination*. London: Mosby, 1992: 8.36-8.39
- ⁹ Godlewski G, Prudhomme M. Embryology and anatomy of the anorectum. *Basis of surgery*. *Surg Clin North Am* 2000; 80:319-343
- ¹⁰ Fry RD. Anorectal trauma and foreign bodies. *Surg Clin North Am* 1994; 74(6):1491-1505
- ¹¹ Hull TL, Milsom JW. Pelvic floor disorders. *Surg Clin North Am* 1994; 74(6): 1399-1413
- ¹² Ng DPK, Mayberry JF, McIntyre AS, Long RG. The practice of rectal examination. *Postgrad Med J* 1991;67:904-906
- ¹³ Scholer SJ, Pituch K, Orr DP, Dittus RS. Use of the rectal examination in children with acute abdominal pain. *Clin Pediatr* 1998;37(5):311-6

- ¹⁴ Jesudason EC, Walker J. For debate: Rectal examination in paediatric surgical practice. *Br J Surg* 1999;86:376-8
- ¹⁵ Dickson AP, MacKinlay GA. Rectal examination and acute appendicitis. *Arch Dis Child* 1985;60:666-7
- ¹⁶ Advance Life Support Group. *Advanced Pediatric Life Support: The practical approach*. 2nd Ed London: BMJ Publishing Group, 1997
- ¹⁷ Roehrborn CG, Girman CJ, Rhodes J, Hanson KA et al. Correlation between prostate size estimated by digital rectal examination and measured by transrectal ultrasound. *Urology* 1997;49(4):548-57
- ¹⁸ Rafaelsen SR, Kronborg O, Fenger C. Digital rectal examination and transrectal ultrasonography in staging of rectal cancer. A prospective, blind study. *Acta Radiologica* 1994;35(3):300-4
- ¹⁹ Muris JW, Starmans R, Wolfs GG, Pop P, Knottnerus JA. The diagnostic value of rectal examination. *Family Practice* 1993;10(1):34-7
- ²⁰ Phillips TH, Thompson IM. Digital rectal examination and carcinoma of the prostate. *Urol Clin North Am* 1991;18(3):459-65
- ²¹ Kaushal JN, Goldner F. Validation of the digital rectal examination as an estimate of anal sphincter squeeze pressure. *Am J Gastroenterol* 1991;86(7):886-7
- ²² Houston J. Observations of the mucous membrane of the rectum. *Dublin Hosp. Rep* 1830;5:159-165
- ²³ Silver PHS. Observations on the valves of Houston in the human embryo and foetus. *J of Anatomy* 1955;89:217-224
- ²⁴ Shafik A, Doss S, Ali YA, Shafik AA. Transverse folds of the rectum: Anatomic study and clinical implications. *Clin Anat* 2001;14:196-203
- ²⁵ McNeal JE. Regional morphology and pathology of the prostate. *Am J Clin Pathol* 1968;49:347-357
- ²⁶ Myers RP. Structure of the adult prostate from a clinician's standpoint. *Clin Anat* 2000;13:214-215
- ²⁷ Hoffman BI, Kobasa W, Kaye D. Bacteremia after rectal examination. *Annals of Internal Medicine* 1978;88:658-659
- ²⁸ Balkan E, Kiristioglu A, Gürpınar A, Özel KS, Dogruyol H. Sigmoidoscopy in minor lower gastrointestinal bleeding. *Arch Dis Child* 1998;78:267-268
- ²⁹ Holliday H, Hardcastle J. Delay in diagnosis and treatment of colorectal cancer. *Lancet* 1979; i: 309-311
- ³⁰ De Klerk DP. Rectal examination in the detection of prostate cancer. *S Afr Med J* 1988;73:157-8
- ³¹ Hennigan TW, Franks PJ, Hocken DB, Allen-Mersh TG. Rectal examination in general practice. *BMJ* 1990;301:478-480
- ³² Dixon JM, Elton RA, Rainey JB, Macleod DA. Rectal examination of patients with pain in the right lower quadrant of the abdomen. *BMJ* 1991;302:386-8
- ³³ Hoogendam A, Buntinx F, De Vet HCW. The diagnostic value of digital rectal examination in primary care screening for prostate cancer: a meta-analysis. *Family Practice* 1999;16:621-626
- ³⁴ Brett TD. An analysis of digital rectal examination and serum-prostate-specific antigen in the early detection of prostate cancer in general practice. *Family Practice* 1998;15:529-533

-
- ³⁵ Earnest DL, Fletcher GF. Danger of rectal examination in patients with acute myocardial infarction – fact or fiction? *New Eng Jour Med* 1969;281:238-241
- ³⁶ Addison R. Digital rectal examination-2. *Nursing Times* 1999;95:39-40
- ³⁷ Spigelman SS, McNeal JE, Frieha FS, Stamey TA. Rectal examination in volume determination of carcinoma of the prostate: Clinical and anatomical correlations. *J of Urol* 1986;136:1228-1230
- ³⁸ Bissada NK, Finkbeiner AE, Redman JF. Accuracy of preoperative estimation of resection weight in transurethral prostatectomy. *J Urol* 1976;116:201
- ³⁹ Yanoshak SJ, Roehrborn CG, Girman CJ, Jaffe JS, Ginsberg PC, Harkaway RC. Use of a prostate model to assist in training for digital rectal examination. *Urology* 2000;55:690-693
- ⁴⁰ Cagnard C, Godlewski G, Prat D, Lan O, Cousineau J, Maklouf Y. The nerve branches of the external anal sphincter: the macroscopic supply and microscopic structure. *Surg Radiol Anat* 1986;8:115-119
- ⁴¹ Personal communication, Mr T Welsh, Fellow of Queens College, Cambridge, Sept 2001

4.4.2.4 Knee joint aspiration

1. <i>Indications</i>	237
2. <i>Contraindications</i>	237
3. <i>Step by step procedure</i>	238
4. <i>Materials</i>	240
5. <i>Anatomical pitfalls</i>	241
6. <i>Complications (anatomically relevant)</i>	246
7. <i>References</i>	249

1. Indications

1.1 Diagnostic²

- Sepsis (septic arthritis).
- Traumatic effusion.
- Gout: Monosodium urate crystals.
- Hemarthrosis due to damage to the cruciate ligaments and meniscal tears.
- Diagnosis of nontraumatic joint disease by synovial fluid analysis.
- Diagnosis of ligamentous or bony injury by confirmation of the presence of blood in the joint.
- Establishment of the existence of an intra-articular fracture by the presence of blood with fat globules in the joint.

Synovial fluid analysis may provide vital data in establishing the diagnosis³, whether the diagnosis is noninflammatory, inflammatory or septic¹².

1.2 Therapeutic²

- Relief of pain of an acute hemarthrosis or tense effusion. The performance of an arthrocentesis may permit examination of the joint. Furthermore, the effects of hemosiderin and proteolytic enzymes on the joint are detrimental¹⁸.
- Local instillation of medications like steroids in different types of arthritic disease for example rheumatoid arthritis, osteoarthritis and psoriasis. This is done as an adjunct to systemic medical therapy.
- Drainage in acute arthritis is a medical emergency¹⁵. The reason for this is not only due to the pain suffered, but also due to the potential of joint destruction. The three most likely causes for joint destruction are bacterial infection, crystal-induced arthritis and hemarthrosis.

2. Contraindications

- Presence of infection in the tissue overlying the joint. The potential of contaminating the joint should be weighed against the consequence of not recognizing an already septic joint¹⁵.
- Bleeding disorders.
- Patient suffering from a systemic disease.
- Aspiration of a Baker's cyst.
- Contraindications for intra-articular corticosteroid injection¹²:

Absolute: Cellulitis in the area of placement.
Suspected or proven septic arthritis

Relative: Minimal relief following a trial of injections.
Underlying coagulopathy.
Recent intra-articular fracture.
Evidence of surrounding joint osteoporosis.

3. Step by step procedure

- With attention to sterile technique and careful observation of anatomical landmarks, knee joint aspiration can be as safe and painless as a normal venipuncture.
- The following are four basic principles for intra-articular injection:
 1. Make an accurate diagnosis.
 2. Revise local anatomy knowledge before injecting.
 3. Use aseptic technique.
 4. Use the correct size needle.

Step 1. Aseptic technique is crucial. Wash the area with soap and sterile alcohol. It is not necessary to gown up or to go to theatre.

Step 2. Explain the rationale of the procedure to the patient². The use of local anesthesia can make the procedure less painful, but is usually not necessary.

Step 3. Position

- Position the patient on a bed with the knee in the fully extended position. The result is relaxation of the quadriceps muscle and patellar tendon which greatly facilitates needle placement. Relaxation of the quadriceps muscle is essential, as a tense muscle will clamp the patella down into the patellar groove, blocking entry of the needle. Position the patient on a bed. With a large tense effusion, the knee is most comfortably held in a mild flexion

position. Put a pillow under the knee for support.

Step 4. Landmarks¹:

- Identify the surface anatomy and bony landmarks by inspection and palpation. Carefully palpate the bony margin of the patella, which can be moved freely before the needle is inserted. Palpate the medial surface of the patella, just below the superior border of the patella and insert the needle approximately 1 cm medial to the medial patellar edge.

Step 5. Needle direction

- A 20- or 21-ga needle (18-ga to aspirate thick effusion)¹² is used.
- The needle is directed between the posterior surface of the patella and the intercondylar femoral notch avoiding the undersurface of the patella. Although touching of the patella with the needlepoint may occur and does not do harm, this is very uncomfortable for the patient¹⁶.
- Slight negative pressure is kept on the syringe while advancing the needle.
- Synovial fluid is often found after just 1 cm of penetration. Deep advancement of the needle is thus unnecessary. Avoid obvious superficial blood vessels.

Step 6. If a steroid injection is to be given after aspiration, all the fluid should not be aspirated, in order to keep the joint space open and keep the needle in place for injection of the steroid.

Step 7. Patients are allowed to walk from the office, but need to limit activities for the first 24 hours.

Alternative approaches

- **Medial retropatellar approach:** An 18-ga needle is inserted at the midpoint or superior portion of the patella approximately 1 cm medial to the anteromedial patellar edge just proximal to the joint space between the femur and tibia¹⁶.
- **Lateral approach.** The knee can also be entered anterolaterally. However, the space between the patella and the femoral surface is considerably narrower on the lateral side. For the lateral approach, palpate the superior lateral aspect of the patella and insert the needle 1 cm superior and lateral to this point¹⁷.
 - o Apply gentle pressure on the contralateral side to pool the fluid in the area of aspiration.

- o Direct the needle under the patella at a 45° angle to the midjoint area¹².
- o If in doubt, examine the opposite unaffected joint to understand the optimal entry site².
- o One hand can be placed on the medial aspect of the patella slightly displacing the patella laterally and therefore increasing the gap between the patella and femur on the lateral side¹⁰.
- o Zuckerman *et al*¹² strongly prefers a lateral approach because it avoids injury to the saphenous nerve. Placement of the needle through muscle is also not necessary for this may cause bleeding. Pfenninger¹⁷ also favors the lateral approach for easier access.

Brown's approach⁴:

- Another method for arthrocentesis is described by Brown⁴ in the flexed knee. The needle is directed in the midline through the patellar tendon, ½ inch distal to the lower pole of the patella, through the fat pad and onto the intercondylar notch.

Posterior approach:

- A posterior approach is never advisable, due to the popliteal vessels and nerve posterior to the knee joint.

- **Suprapatellar approach:** The needle can be introduced into the suprapatellar bursa superior and just lateral to the patella in the presence of a very large effusion¹⁰. The needle is introduced above and to the lateral side of the patella. Aiming down and medially proceed with the needle under the posterolateral aspect of the patella. Aspirate as the needle is advanced. The free hand is used to tip the patella laterally and apply pressure on the suprapatellar pouch.

- **Infrapatellar approach:** This approach should rather be avoided according to Zuckerman *et al*¹² because of the close relation to the patellar fat pad, which if injected may result in fat necrosis.

4. Materials

- 18 or 20-21 ga needle
- 20cc syringe
- Drapes
- Aseptic solution and gauze.
- Sterile gloves

5. Anatomical pitfalls

5.1 Diagnosis of knee effusion

The following are physical signs of a knee joint effusion:

- The hollows alongside the kneecap disappear, and a suprapatellar bulge may appear.
- Patellar tap. This is performed by ballotment of the patella on the joint. The left hand performs pressure from the suprapatellar bursa, while the right index and middle fingers tap the patella against the underlying femur. The knee should be in extension.
- Synovial thickening may indicate synovitis.
- Bony prominences like osteophytes appear in osteoarthritis.
- The temperature over the knee may be slightly higher than the other side.
- A small effusion is best defined by the bulge test. Fluid is stroked by the palm of the right hand from the medial side starting at the tibial condyle, upwards into the suprapatellar bursa. The left hand is placed with the thumb on the patella controlling the fluid in the suprapatellar bursa. A bulge at the medial patellar gutter, confirms a small effusion. This should be distinguished from movement of the patella or movement of soft tissues by the controlling thumb on the patella.

5.2 Surface anatomy

- The needle is inserted at the midpoint or superior position of the medial patellar edge, approximately 1 cm medial to the medial patellar edge.

5.3 Synovial joint fluid⁴

- A normal joint contains at most a few drops of synovial fluid, just enough to lubricate the articular surfaces and cartilage. There is always some joint fluid present, but only 1-2 ml may be able to be aspirated. Fluid in the normal knee averages 1 ml. The knee can easily accommodate 50-70 ml of fluid.
- Synovial fluid is basically a dialysate of plasma, to which hyaluronate is added. Synovial fluid has the function of nourishing the avascular articular cartilage and lubricating the joint surfaces³. The high viscosity is due to the hyaluronic acid.
- The anteromedial approach is recommended if there is little excess fluid¹⁶. There is more space between the patella and the femoral condyle on the medial side.

5.4 Quadriceps muscle

- A tense quadriceps tendon will greatly hinder needle placement. The reason for this is that a contracted quadriceps muscle clamps the patella down in the patellar groove.

5.5 Knee capsule¹⁰

- No defined complete capsule exists, but rather a thick ligamentous sheath

compromising mainly of tendons or expansions of them.

- According to Fullerton¹¹ the capsule of the knee joint with the ligaments, tendons and fascia form a complete investment around the joint except at those places where communications with bursae exist. This investment is very thin above the patella, only represented by a layer of synovial membrane. A septic arthritis may actually break through the synovial membrane into the fascial planes of the thigh.
- The borders of the knee capsule are:
 - Anterior: The capsule is continuous with the muscles. Tension can therefore be changed with muscle movement. The capsule is formed by fused fibres of the rectus femoris and vastus medialis and lateralis muscles, with superficial fibres crossing anterior to the patella to the ligamentum patellae. The medial and lateral retinacula attach to the anterior border of each tibial condyle. Expansions of the iliotibial tract descend over the anterolateral aspect of the knee joint to the lateral tibial condyle.
 - Posterior: True capsular fibres are found posteriorly, attaching inferior to the proximal part of the tibia and superior to the condyles on the femur. It is strengthened by the oblique popliteal ligament and the arcuate popliteal ligament.
 - Medial: True capsular fibres arise from the medial collateral ligament. They are strengthened by the expansions of the semimembranosus tendon, which also attaches to the medial meniscus and the medial proximal part of the tibia.
 - Lateral: The lateral capsule is separated from the lateral collateral ligament and strengthened by fascia from the fascia lata. The tendon of the popliteus muscle lies between the capsule and the lateral collateral ligament.

5.6 Synovial membrane

- The synovial membrane is attached to the articular cartilage margin over the femur and tibia. The joint cavity is large and communicates with the suprapatellar bursa¹.
- The synovial membrane is the largest and most complex in the body. A large surface is exposed to potential bacterial toxin absorption. should infection occur¹¹.
- The synovial membrane has diverticulae, folds, recesses and communications with bursae. This makes it very difficult to drain thoroughly.
- The synovial membrane involves the suprapatellar bursa as well as an extension along the course of the popliteus muscle tendon between the lateral collateral ligament and lateral meniscus of the knee joint.
- The cruciate ligaments form a septum, dividing the synovial pouch in the intercondylar notch. The cruciate ligaments are therefore outside the knee joint.

5.7 Bursae¹

- **Suprapatellar bursa:**

- The suprapatellar bursa extends under the quadriceps muscle for a distance of about 7 cm above the superior border of the patella. This upward protrusion also extends considerably on the lateral sides.
- A knee effusion is first evident as a loss of the medial and lateral dimples around the patella. A large effusion presents like a horseshoe swelling of the suprapatellar bursa and to either side of the patella. Fluid may also collect predominantly posteriorly as a popliteal cyst, which should not be aspirated.

- **Infrapatellar bursa:**

- The infrapatellar bursa has a superficial and deep part. The superficial part is most commonly involved during infrapatellar bursitis (clergyman's knee). The deep infrapatellar bursa is posterior to the patellar tendon and anterior to the tibial tuberosity.
- Confusion exists on the position of the deep infrapatellar bursa. LaPrade⁵ in a cadaver based study (n=50), demonstrated that the deep infrapatellar bursa has a consistent anatomic location. The bursa is located directly posterior to the distal third of the patellar tendon, just proximal to its insertion on the tibial tuberosity. No communication was shown with the knee joint in this study. The bursa was found to be partly compartmentalized, with a portion of the retropatellar fat pad dividing the bursa in an anterior and posterior compartment. Doherty *et al*¹⁰ also states that the deep infrapatellar bursa is separated from the knee joint synovium by a fat pad. Fullerton¹¹ confirmed this already in 1916 by stating that the bursa between the patellar tendon and the tibial tuberosity, should not be confused with the actual knee joint. There is no communication.
- LaPrade⁵ suggests a recommended route to the deep infrapatellar bursa along the lateral edge of the patellar tendon just proximal to the tibial tubercle.
- Injection for clergyman's knee (infrapatellar bursitis): The injection is made directly into the inflamed area, introducing the needle from the medial side and directing it anterior to the patellar tendon into the superficial part of the infrapatellar bursa which is commonly involved during infrapatellar bursitis.

- **Prepatellar bursa:**

- Prepatellar (housemaids knee) and infrapatellar bursitis (clergyman's knee), occur due to recurrent pressure or trauma during kneeling. It is not the same as an

effusion of the knee joint. The prepatellar bursa does not communicate with the knee joint. It is present in 90% of people, is subcutaneous and covers the lower half of the patella and the superior half of the patellar tendon¹⁰.

- Injection for housemaid's knee: One should make sure that the patellar tap sign is absent, showing that the fluid is outside of the joint. The injection is made directly in the area, anterior to the patella.
- **Popliteus bursa:**
 - This bursa is found around the popliteus tendon intra-articularly.
- **Anserine bursa**
 - This bursa is found under the anserine pes.
- **Semimembranosus bursa**
 - This bursa is found between the head of gastrocnemius and semimembranosus. When communicating with the knee joint it is referred to as a Baker's or popliteal cyst. This may rupture presenting with sudden upper calf pain. It is important to distinguish this from deep vein thrombosis by means of a venogram⁸.

5.8 Cruciate ligaments¹⁰

- The anterior cruciate ligament originates anterior on the intercondylar area of the tibia, to insert posterior on the medial surface of the lateral condyle of the femur. It prevents anterior displacement of the tibia, as well as hyperextension.
- The posterior cruciate ligament originates posterior on the intercondylar area of the tibia, to insert anterior on the lateral surface of the medial condyle of the femur. It prevents posterior displacement of the tibia, as well as hyperflexion.
- The anterior drawer test is used to test for integrity of these ligaments. With the knee in 90° flexion, the examiner pulls the leg forward with both hands. The anterior cruciate ligament prevents backward displacement of the femur on the tibial plateau. The anterior cruciate ligament is tested in the neutral position. Anterior drawer movement in the neutral position is called the anterior drawer sign and reflects a torn anterior cruciate ligament. The tibia slides forward on the femur when pulling the tibia.
- The posterior drawer test is used when a posterior cruciate tear is suspected. Compare the two knees in a 90°-flexion position to see if there is posterior subluxation of the tibia. If there is subluxation, the anterior drawer test will correct this position. This is therefore called the posterior drawer sign.

- A hemarthrosis may point to a cruciate ligament injury, frequently involving concomitant meniscal tears in up to 70% as seen on MRI¹³.

5.9 Cutaneous nerves

- The knee joint is supplied by various nerves, including branches of the femoral nerve, common fibular nerve, tibial nerve and obturator nerve¹⁰.
- The saphenous nerve may be injured when using a medial approach¹². The saphenous nerve is a branch of the femoral nerve running in relation to the great saphenous vein on the medial side of the knee joint.

5.10 Patella

- Various abnormalities of the patella exist, which may influence the surface anatomy for needle placement:
 - Patella alta – a high and small patella.
 - Patella baja – a low patella.
 - Bipartite patella – a small gap in the patella is present. It is usually bilateral.
 - A patellar plica (synovial fold) may be present especially on the medial side⁶.

5.11 Joint cavity

- The joint cavity extends beyond the articular ends of the bones into numerous extensions of the synovial membrane¹¹. One extension, the suprapatellar bursa extends under the quadriceps muscle for a distance of about 7cm above the superior border of the patella. This upward protrusion also extends considerably on the lateral sides. Therefore, a penetrating wound involving the distal third of the circumference of the thigh within 7cm of the patella, would almost undoubtedly involve the knee joint. This is also the reason why the joint can be aspirated from this level.
- There are rare cases where the suprapatellar bursa does not communicate with the knee joint cavity.
- Fullerton¹¹ refers to the opening of the suprapatellar bursa and the knee joint cavity. Apparently this opening is quite small.
- The communication of the suprapatellar bursa with the knee joint is confirmed on MRI of knees with effusions¹⁴. Effusions appeared to be present within the suprapatellar bursa, intercondylar notch and posterior recesses. MRI cannot distinguish between hemorrhagic and non-hemorrhagic effusions.

6. Complications (anatomically relevant)

Complications of knee joint aspiration (arthrocentesis) are rare³.

6.1 Unproductive arthrocentesis

- Although an arthrocentesis is a relatively straightforward procedure performed in the office setting, failed taps are relatively common due to multiple causes as reported by Roberts *et al*⁷. The authors demonstrate these causes by means of MRI:

1. There may simply be no effusion at all, provided that the needle moves freely into the joint space.
2. Especially in obese patients, but even in patients of average weight, a small triangular fat pad at the medial aspect of the patella, may be confused with an effusion.
3. A chronically inflamed synovium may undergo fat replacement and thickening. This condition is referred to as lipoma arborescens⁹. This is a rare intra-articular condition with villous lipomatous proliferation of the synovium in the knee joint, especially the suprapatellar bursa. This can easily obstruct the needle during a knee joint aspiration.
4. The presence of a medial plica (e.g. patellar plica)⁶ acting like a valve may obstruct the lumen of the needle. Owen⁸ also explains failure to aspirate fluid from the knee by this mechanism.

Several folds, pleats, bands or shelves of synovial membrane may exist in the knee joint. The term plica is used to describe some of these remnants of synovial tissue development. During development of the knee, the lateral and medial compartments as well as the suprapatellar bursa of the knee are separated by thin membranes⁶. These membranes later involute and the knee becomes a single cavity. A plica is a remnant of embryonic synovial septum that persists, and has an incidence of approximately 20% in the general population.

They are classified to be infrapatellar, suprapatellar and mediopatellar (in order of frequency), depending on the membrane from which they come.

The suprapatellar plica rarely completely divides the suprapatellar bursa from the rest of the knee joint, but leaves an opening of variable diameter. The medial suprapatellar plica is the most common plica, extending to the medial wall of the joint.

The mediopatellar plica also lies along the medial wall of the joint.

The infrapatellar plica stretches from the intercondylar notch to the infrapatellar fat pad, sweeping through the anterior part of the joint space.

All these plicae may block the needle during aspiration of the knee joint⁶.

5. Highly viscous fluid may be difficult or impossible to aspirate through relatively small needles. It may actually be impossible to obtain any fluid from either the medial or lateral side. A maneuver to overcome this may be to ask a second operator to

compress the fluid from three sides of the knee. If the lateral approach is used, this means applying pressure from the medial, inferior and superior sides with both hands⁷.

6. Obstruction of the needle lumen by particles in the synovial fluid, especially seen in a rheumatoid effusion.
7. Leverage¹⁶ reports that normal synovial membrane may block the withdrawal of fluid. This can be overcome by twisting the needle, reaspirating or by injecting some fluid back into the joint to clear the needle.

6.2 Unsuccessful entrance to the knee joint:

- Unsuccessful aspiration from the medial side, should be followed by a lateral approach. Roberts *et al*⁷ concludes that although surface anatomy markings make a medial approach easier, the lateral approach is more likely to produce fluid in difficult aspirations. This finding is based on the fact that more free synovial fluid was imaged on the lateral side on MRI studies⁷. They therefore recommend the use of the lateral approach for training purposes.
- The knee may be impossible to enter from both medial and lateral sides due to a flexion deformity, large osteophytes, or patellar ankylosis. In these cases, the needle may be placed between the condyles of the femur adjacent to the patellar tendon².
- The knee may also be entered with the knee in flexion. This is particularly useful if the patient is confined to a wheelchair. The point of entry is below the lower border of the patella, above the tibia and just lateral (or medial) to the patellar tendon.

6.3 Infection

- Skin bacteria may be introduced into the joint space during the procedure. The possibility of initiating such an infection is enhanced when the overlying skin is not properly cleaned and when sterile technique is not adhered to².

6.4 Injection of drugs into a vein or artery

- This should be prevented by aspirating before injecting.

6.5 Tendon rupture

- This complication usually occurs after multiple injections. To reduce the possibility of tendon rupture, injection should never be given intratendinously. No ligaments are in danger when the recommended route of needle insertion is adhered to. The anterior approach in the flexed knee may however injure the anterior cruciate ligament.

6.6 Damage to articular cartilage

- Damage to the articular cartilage may be avoided by careful aspiration and needle advancement. Too deep advancement may possibly damage the articular cartilage¹⁰.

6.7 Marked discomfort

- Marked discomfort is experienced when the needle hits periosteum.

6.8 Obstruction of fluid flow

- If the flow of fluid becomes intermittent or stops, this may be due to:
 - Obstruction by synovial membrane.
 - Blockage by fibrin or debris.
 - Displacement of the needle outside the joint cavity.
- If the fluid stops flowing, one can squeeze the soft tissue area around the suprapatellar region to further empty the suprapatellar bursa of fluid.
- A small amount of fluid can be injected back in the joint to clear the needle. If this does not help, the needle should be withdrawn and placed again.

6.9 Complications associated with steroid injections

- Soft tissue atrophy, periarticular calcification and tendon rupture have all been associated with steroid injection.
- Long term effects include osteonecrosis and ligamentous laxity resulting in joint instability¹².
- The joint should therefore not be injected more than three times in one year. However, there is no evidence base for this frequency rate.

6.10 Post aspiration care

- Temporarily support with tubigrip of the quadriceps muscles is necessary after a knee joint aspiration as well as exercises to prevent wasting of the quadriceps muscles.

6.11 Bleeding

- Bleeding is a very rare complication except in patients with a bleeding diathesis.

7 References

- ¹Silver T. Joint and soft tissue injection. Injecting with confidence. Abingdon, New York: Radcliffe Medical Press, 1996: 67-71
- ²Samuelson CO, Cannon GW, Ward JR. Arthrocentesis. *The Journal of Family Practice* 1985;20:179-184
- ³Samuelson CO, Ward JR. Examination of the synovial fluid. *J Fam Pract* 1982; 14:343-349
- ⁴Brown PW. Arthrocentesis for diagnosis and therapy. *Surgical Clinics of North America* 1969;49:1269-1278
- ⁵LaPrade RF. The anatomy of the deep infrapatellar bursa of the knee. *The American Journal of Sports Medicine* 1998;26:129-132
- ⁶Hardaker WT, Whipple TL, Bassett FH. Diagnosis and treatment of the plica syndrome of the knee. *J Bone Surg* 1980;62A:221
- ⁷Roberts WN, Hayes CW, Breitbach SA, Owen DS. Dry taps and what to do about them: A pictorial essay on failed arthrocentesis of the knee. *Am J Med* 1996;100(4): 461-464
- ⁸Owen DS. Aspiration & injection of joint and soft tissues. In: Kelly WN, Harris ED, Ruddy S, Sledge CB, eds. *Textbook of Rheumatology*. Philadelphia: WB Saunders Company, 1993:545-561
- ⁹Feller JF, Rishi M, Hughes EC. Lipoma arborescens of the knee: MR demonstration. *Am J Roentgenol* 1994;163:162-164
- ¹⁰Doherty M, Hazleman B, Hutton C, Maddison P, Perry D. *Rheumatology examination and injection techniques*. London: WB Saunders, 1992
- ¹¹Fullerton A. The surgical anatomy of the synovial membrane of the knee joint. *Br J Surg* 1916;4:191-200
- ¹²Zuckerman JD, Meislin RJ, Rothberg M. Injections for joint and soft tissue disorders, when and how to use them, *Geriatrics* 1990;45(4):45
- ¹³Reicher MA, Hartzman S, Bassett LW et al. MR imaging of the knee. Part I. Traumatic disorders. *Radiology* 1987;162:547-551
- ¹⁴Hartzman S, Reicher MA, Bassett LW et al. MR imaging of the knee. Part II. Chronic Disorders. *Radiology* 1987;162:553-557
- ¹⁵Kolba KS. The approach to the acute joint and synovial fluid examination. *Prim Care* 1984;11:211
- ¹⁶Leversee JH. Aspiration of joints and soft tissue injections, *Prim Care* 1986;13:579
- ¹⁷Pfenniger JL. Injections in joints and soft tissue: Part II. Guidelines for specific joints, *Am Fam Physician* 1991;44:1690
- ¹⁸Heim M, Martinowitz U, Horoszowski H. Is joint aspiration in acute haemarthrosis really necessary? *S Afr Med J* 1985;67:531-532

4.4.3 Surgical procedures

4.4.3.1 Cesarean section

1. <i>Indications</i>	250
2. <i>Contraindications/ Precautions</i>	251
3. <i>Step by step procedure</i>	251
4. <i>Materials</i>	259
5. <i>Anatomical pitfalls</i>	259
6. <i>Complications (anatomically relevant)</i>	264
7. <i>References</i>	277

1. Indications

In labor:

- Fetal or maternal distress.
- Prolongation of the first stage of labor – usually due to a combination of factors like arrested cervical dilatation due to malpositioning of the fetal head, excessive soft tissue resistance and minor degrees of disproportion.
- Cephalopelvic disproportion after a trial of labor.

Not in labor:

- Fulminating pre-eclampsia.
- Placenta praevia.
- Malpositions and malpresentations of the child.
- Breech presentation.
- Failed induction.
- Failed instrumental delivery.
- Prolapsed cord.
- Abruptio placentae.
- Previous repair of a vesicovaginal fistula or prolapse.
- Previous classical cesarean section.
- Previous uterine injury or surgery such as hysterotomy and myomectomy.
- To minimize the hypoxia associated with labor and the trauma of delivery to the fetus, as in the case of a premature fetus, especially when presenting as a breech or one affected by growth retardation.
- Cardiac disease – indicated in cases of uncorrected aortic coarctation.
- Previous vaginal surgery.
- Pelvic tumors.
- Cervical carcinoma.
- Active maternal genital herpes simplex virus.
- Fetal thrombocytopenia.
- Fetal macrosomia.

2. Contraindications

- Lack of practitioner training¹³.

3. Step by step procedure

Lower segment cesarean section

Step 1. Preparation

- Place a urinary bladder catheter.
- Clean and paint the whole abdomen, perineum and upper thighs with antiseptic solution (povidone-iodine, chlorhexidine or hexachlorophene) and drape in a standard way.
- A large bore intravenous line should be in place
- Type specific blood should be available as well as a recent hemoglobin level.

Step 2. Position

- Position the patient in a left lateral tilt and slight Trendelenburg position (5°). This maneuver ensures that the gravid uterus does not press on the inferior vena cava²⁶ and partially on the abdominal aorta and therefore cause a fall in cardiac output and placental perfusion^{25, 27}. This is known as the supine hypotensive syndrome.

Step 3. Anterior abdominal wall incision

a) Midline:

- Indications for midline incision: Acute fetal distress, prolapsed cord, hypovolemic shock, prior midline incision and obesity.
- Perform a vertical midline incision extending 2.5 cm below the umbilicus to the upper border of the symphysis pubis. It should not extend over the symphysis pubis, for this will result in a tender scar.
- Coagulate or ligate bleeders from the superficial epigastric vessels.
- Open the rectus sheath through the line alba.
- Open the peritoneum in the upper third of the incision. This avoids injuring the bladder, which may be at a higher position than expected due to the gravid uterus.
- The peritoneum should be grasped with a nontoothed forceps or hemostat and inspected and palpated to exclude the presence of bowel or bladder.

- In obese patients, with thick preperitoneal fat, identification of the obliterated urachus (median umbilical ligament and fold) will help to identify the peritoneum.

Disadvantages:

- o The midline incision may be associated with a bad scar.
- o The incidence of wound dehiscence is higher.

b) Pfannenstiel incision¹⁵:

- The skin incision is made following a semilunar natural skin line. The average incision begins and ends 2-3 cm below and medial to the anterior superior iliac spines. The incision is made two fingerbreadths above the symphysis pubis.
- Incise through the fatty (Camper) and membranous (Scarpa) layers of the superficial fascia, as well as the anterior rectus sheath.
- Dissect the anterior rectus sheath off the underlying rectus muscle superiorly for approximately 8 cm and inferiorly to the level of the symphysis pubis.
- Care must be taken to coagulate and ligate bleeders from the superficial epigastric vessels.
- Separate the muscle bellies in the midline with simple finger dissection.
- Incise the peritoneum vertically with scissors to gain access to the peritoneal cavity. Be careful not to injure bowel, omentum or bladder.

Disadvantages¹⁶

- o A Pfannenstiel incision may be too slow for an emergency section. This is due to the subaponeurotic dissection of the rectus sheath taking time.
- o Postoperative hematoma is not uncommon and the space is usually drained.
- o A Pfannenstiel incision does not strictly follow Langer's lines. It may result in guttering when the patient stands.

Step 4. Packing

- Use two large taped gauze swabs to pack the lateral recesses of the wound and attach the tapes each to an artery forceps. No free swabs should be used.

Step 5. Detect uterine torsion

- Identify the round ligaments of the uterus and identify any rotation of the uterus.

Dextrorotation is commonly found. It is important to correct rotation to avoid incision into the large vessels near the base of the broad ligament, which will result in vigorous bleeding.

- Identify the uterine vessels, by feeling for the round ligament, which is situated anteriorly near the superior portion of each side of the uterus.

Step 6. Incising the visceral peritoneum overlying the lower segment of the uterus and pushing the bladder down

- Identify the vesico-uterine reflection.
- Lift the loose peritoneum over the lower segment of the uterus with a dissecting forceps, assisted by using the Doyen retractor, which can be moved from side to side.
- Strip the lower peritoneal flap downward with the bladder for about 5 cm. This maneuver results in the development of a potential space between the bladder and the lower uterine segment and the creation of a bladder flap.
- Be careful in a patient who had a previous cesarean section, due to the adhesion that may be present. The risk of injuring the bladder is higher.

Step 7. Opening the uterus

- Confirm the lie and presentation of the infant before opening the uterus.
- Confirm the lower segment of the uterus by palpation and identify the area where the incision is to be made. This should be done in the lower segment of the uterus over the head of the infant at its widest possible diameter.
- With the scalpel, cut a small transverse incision of about 2cm in the midline into the uterine muscle. Cut down to the amniotic membrane until it bulges in the wound.
- Be careful to avoid too low an incision which may result in bladder injury. A too low incision will be very short due to the downward converging lateral walls of the uterus. There is also a danger of tearing into the broad ligament causing vigorous bleeding.
- Any bleeding venous sinus should be controlled by applying a Green Armytage spring clamp.
- Extend the incision laterally to both sides with curved scissors. Use the index and middle fingers of the opposite hand to lift the uterine wall while using the scissors to avoid cutting the child's ear, which may be just below. A 10-12 cm incision for a term baby is required. The incision is curvilinear, extending upward at the edges to prevent tearing into the broad ligament and ureteral injury.

- If required, one of the lateral edges can be elongated superiorly to form a J incision. A T-incision should not be made for it heals poorly.
- The incision may also finally be enlarged by inserting the index fingers into the incision and stretching the incision from side to side. The whole width of the uterine incision should however not be made by crude tearing of the uterine wall, which will result in uncontrolled tearing with possible uterine vessel laceration³¹ and inaccurate repair of the uterine wall.
- Vertical uterine incisions should be avoided, because of the associated incidence of uterine rupture in following pregnancies as well as iatrogenic premature delivery.
- Be careful not to incise the infant. Continuous suction of the incision is essential to clear the field of blood for safe incision.
- Open the amniotic membranes if they have not already ruptured and administer continuous suction to clear the field of blood and amniotic fluid.

Step 8. Extracting the fetus and placenta

a) Head presenting:

- Insert the hand between the anterior uterine wall and head of the infant and elevate the head into the incision. This will cause flexion of the head and therefore a smaller diameter going through the uterine incision.
- Make sure the occiput and not the sinciput is lifted towards the incision.
- If the head is deeply engaged in the pelvis, an assistant is asked to lift the head vaginally.
- As the occiput is in the incision, the assistant should apply fundal pressure to deliver the head.
- From this point the delivery continues as with a normal vaginal delivery.
- Hook the finger in the nearest axilla and deliver the shoulder and arm. Repeat the same on the other side.
- Completely extract the infant and clamp the cord.
- Suction the nasal and oral passages after delivery of the head.
- Apply fundal pressure to deliver the rest of the body.

- Doubly clamp the cord.
- Use of forceps:
 - Hook the chin forward and apply the obstetric forceps, with the pelvic curve of the blades facing towards the symphysis pubis.
 - Dislodge the head from the uterus by gentle rocking movements.
- Administer ergometrine intravenously to reduce the amount of bleeding, from the uterine incision as bleeding may start after the stretching of the uterine muscle is eased.
- Remove the placenta by traction on the cord, or by manually shearing it from its uterine attachment if necessary. Remove all the membranes, and vernix caseosa. Clean the inside of the uterus with a towel to remove remnants of the membranes.

b) Breech presenting:

- Delivery is done according to the normal breech extraction procedure.

Step 9. Application of Green Armytage clamps

- Control bleeders with the Green Armytage clamps. Apply them to the lateral angles of the uterine incision and lower margin of the incision. This margin may retract and make identification difficult in the presence of a pool of blood. The lower margin can be identified in these circumstances by slipping a finger from a lateral angle of the incision to get hold of the lower margin of the uterine wall incision.
- With serious bleeding from a lateral angle of the wound, lift the lateral part of the uterus with two fingers behind the broad ligament. This makes the site of the vessels easier to visualize and compresses the vasculature for clamping.

Step 10. Stitching the uterus

- The uterus can be left in situ or delivered onto the anterior abdominal wall of the mother for better exposure. When returning the uterus into the abdominal cavity, the uterus should be inspected for bleeding from the uterine vessels which may have kinked temporarily while the uterus was outside the abdominal cavity⁴⁰.
- The uterus is closed in two layers of continuous running sutures.
- First place a figure of eight stitch in each corner of the uterine incision.

- Use chromic 1.0 catgut with a round-bodied needle. A cutting needle should not be used for it can cut the deeper layer that has already been inserted.
- Insert the first stitch in the lateral angle of the uterine incision on the far side of the surgeon. Space the stitches so that they control the bleeding sinuses that were clamped by the Green Armytage clamps.
- Take care not to injure the bladder.
- The upper edge is usually much thicker and the unstitched part will be sutured during the second layer. Keep a firm pull on the suturing material when suturing this layer. Insert the suture in a slightly oblique direction.
- Stitch the second row by picking up all the unstitched muscle on the upper edge of the uterus and shut the inner row of sutures. When completed, tie the second catgut to the free end of the first catgut strand.
- Further spots where blood oozes may be stitched with finer catgut by taking one transverse bite below the bleeder and one above the bleeder in a Z-shaped stitch.
- The uterine stitches should be put in more firmly than usually. The reason for this is the fact that the uterus involutes quickly with subsequent loosening of the sutures within hours after the operation.

Step 10. Closing the abdomen

- Both the visceral and parietal peritoneum can be left unsutured¹⁸. Hull *et al*⁴¹ has demonstrated reduced need for postoperative analgesia and faster return of bowel function when both peritoneal layers are left unsutured. Leaving the peritoneal layers unsutured also significantly reduces operating time. Peritoneal defects demonstrate indistinguishable healing with no scar by 5 days¹⁹.
- Make sure all free blood and clots are removed, the packs are removed and all instruments counted.
- Inspect the uterine tubes and ovaries for pathology and make sure the paracolic gutters and recto-uterine pouch is clean.
- Close the abdomen in three layers, suturing the rectus sheath separately with a continuous suture, as well as the superficial fascia and fat and finally the skin.
- Insert a subcutaneous suction drain in cases where adequate hemostasis was

not established especially in the case of a Pfannenstiel incision.

Alternative: Misgav Ladach method¹⁶

- This method uses the Joel-Cohen incision of the abdominal wall and follows the principle of surgical minimalism. Manual manipulation is used where possible instead of surgical instruments to injure the tissues as little as possible.

Method

1. Make a horizontal 17 cm incision through the skin, 3 cm below the line on the plane of the anterior superior iliac spines.
2. Deepen the incision in the midline through the fat to the rectus sheath in a short transverse cut of 2-3 cm. Do not free any subcutaneous tissue. This means the subcutaneous blood vessels and nerves stay intact and the midline is virtually bloodless.
3. Make a small transverse incision in the sheath.
4. Enlarge the transverse incision of the sheath underneath the subcutaneous tissue by sliding scissors (one blade under the cut sheath and one above).
The incision is above the level of pyramidalis, therefore the rectus muscle moves freely over the fascia.
5. Separate the fascial borders and the rectus muscle by pulling caudally and cranially using two fingers.
6. Pull the rectus muscles apart. This is done by both surgeon and assistant inserting their index and middle fingers in the midline between the muscles and then pulling with balanced increasing force to make a big enough opening. This displaces the vessels and nerves under the subcutaneous tissue.
7. Stretch the parietal peritoneum with the index finger and enlarge the hole with the fingers in a caudal and cranial direction. Enlargement in a caudal and cranial direction causes the peritoneum to open transversely saving the bladder from injury. By using the fingers there is less danger of injuring the bowel.
8. Identify the lower segment of the uterus and the superior border of the bladder.
9. Make a transverse incision over the visceral peritoneum 1 cm above the bladder with a scalpel. Avoid blood vessels and go far enough to the lateral side using a retractor for the bladder to give better visibility.
10. Push the visceral peritoneum and bladder down.
11. Make a small transverse incision in the lower uterine segment using a scalpel or finger.
12. Stretch the hole to either side using thumb to steady and the left index to separate the uterine fibers. Open more to the right than the left for the uterus is usually rotated to the right in late pregnancy
13. Place two fingers below the head. The assistant applies fundal pressure while the fingers guide the head through the uterine opening.
14. Manually deliver the placenta. Give 10 units oxytocin or 0.5 mg ergometrine.
Manual removal makes the third stage quicker and prevents unnecessary bleeding.
15. Bring the uterus out of the abdominal wound and massage manually to stimulate

- contraction to minimize bleeding.
16. Clean the inside of the uterus with a towel to remove remnants of the membranes.
 17. Grasp the center of the caudal part of the uterine cut with a Green Armytage forceps and repair the uterine wall with a one layer continuous locked stitch. Start at the edge of the cut nearest to you and use long length chromic catgut. Take large enough bites from the upper and lower edge to secure hemostasis. Take care to stay away from the bladder when taking bites from the lower edge. Sometimes a second layer may be necessary or a cross-stitch for a bleeder. One layer suturing is quicker to perform and healing is better with fewer sacculations. Stitching of the uterus is only for hemostasis and not so much for mechanical strength, because with retraction the sutures loosen within hours after the operation.
 18. Check for proper hemostasis.
 19. Remove clots in the abdomen, but do not put packs in the intraperitoneal cavity for mopping. Minimal interference with the bowel is necessary for early alimentation.
 20. Visceral and parietal peritoneum can be left unstitched. This prevents adhesion formation. A new peritoneum will form. Stitching of the peritoneum leads to ischemia stimulating a repair response with adhesions.
 21. Identify the rectus sheath and fascia at both corners and at the lower and upper cut edges. Start stitching at the end nearest to you from the inside in to the outside out to bury the knot inside the fascia. Use a continuous stitch (Vicryl 1.0).
 22. Close the skin with mattress sutures and pinch the skin edges together with non-toothed forceps for 5-10 minutes.
 23. Start oral fluids immediately and get the patient out of bed as soon as possible after the anesthetic has worn off.

Advantages¹⁷:

- Darj *et al*¹⁷ showed in a prospective randomized trial, that the Misgav Ladach method compares as follows with the Pfannenstiel method:
 - o Operating time was significantly less with the Misgav Ladach method (12.5 minutes compared to 26 minutes with the Pfannenstiel method).
 - o The amount of blood loss was significantly less in the Misgav Ladach method (448 ml compared to 608 ml of the Pfannenstiel method).
 - o Significantly less analgesic was needed after the Misgav Ladach method.
- Less traumatic for the mother and the mother has quicker postoperative recovery.
- Less febrile reactions.
- Shorter period before bowel function reappears. No use of bowel packs or towels in the peritoneal cavity is important for quicker recovery of bowel function²².
- Fewer peritoneal adhesions and less scarring.
- It causes less bleeding in the abdominal wall.
- Can be used for an emergency section as well.
- Because the incision is higher than the Pfannenstiel incision, no subaponeurotic dissection is necessary and therefore less bleeding²¹. The incision heals better than a midline vertical incision because it is horizontal. There is also less risk of

herniation²⁰.

- The subcutaneous tissue is not disrupted except in the midline¹⁶. Hemostasis, electro-coagulation or tying off of blood vessels with resultant localized ischemia is not necessary. This also decreases the risk of infection.
- There is less risk of keloid formation¹⁶, a complication with specific relevance in Africa.
- Amniotic fluid left behind in the peritoneal cavity brings no risks and is actually bacteriostatic²³.

4. Materials

- Laparotomy tray
- Doyen universal retractor
- Green-Armytage spring clamps
- Suction

5. Anatomical pitfalls

5.1 Embryology

- The female genital tract is formed by the paired Mullerian ducts (paramesonephric ducts). The caudal ends usually fuse to form the uterus and the rostral part descends to become the uterine tubes. Fusion may fail to happen, which may result in two separate hemi-uteri. A bicornuate uterus is more common. A notch forms in the rostral part with a septum protruding into the lumen of the uterus. Spencer⁵⁶ reports a case where a child's head was wedged into a horn of a bicornuate uterus with a pressure wound forming in the neck due to the septum.

5.2 Anterior abdominal wall

5.2.1 Subcutaneous tissues

- Johnson *et al*¹² describes the subcutaneous fascia in a study performed with CT and MRI on 20 patients as follows: There is a circumferential subcutaneous fascial plane dividing the subcutaneous fat into a single superficial fat compartment and a single deep fat compartment. The superficial fat compartment remains relatively constant in thickness, but the deep compartment varies in thickness, being thickest in the lumbar region and thinnest laterally. The subcutaneous fascia passes superficial to the linea alba, without fusing with it.

5.2.2 Anterior abdominal wall muscles:

- **External abdominal oblique muscle:** This muscle runs in an oblique medial and inferior course and forms part of the anterior rectus sheath around the rectus abdominis muscle.

- **Internal abdominal oblique muscle:** This muscle runs in an oblique medial and superior course and forms part of the anterior and posterior rectus sheath around the rectus abdominis muscle except in its lower part where it lies anterior to the rectus abdominis muscle.
- **Transversus abdominis:** This muscle runs in a transverse course and contributes to the posterior rectus sheath above a point midway between the umbilicus and pubis (arcuate line). Below this point the muscle contributes to the anterior rectus sheath. The lower limit of the transverse abdominis fascia forming part of the posterior rectus sheath is therefore called the arcuate line. Below this line, the posterior rectus sheath is absent and the transversalis fascia, extraperitoneal fat and parietal peritoneum form the posterior relations of the rectus abdominis muscle.
- **Rectus abdominis:** This muscle attaches on the pubic crest inferiorly and superior on the thoracic cage. It has three to four fibrous insertions, one at the level of the umbilicus, one midway between the umbilicus and the upper insertion and the third midway between the umbilicus and the lower insertion on the pubic crest. The fibrous insertions are attached to the anterior rectus sheath, which limits its retraction.

5.2.3 Blood supply of the anterior abdominal wall

- The abdominal wall is supplied by the superior and inferior epigastric arteries for most of its medial part and the lateral part by the musculophrenic and deep circumflex iliac arteries.
- There is a rich collateral circulation.
- The superior epigastric artery is a branch of the internal thoracic artery. It descends posterior to the midportion of the rectus abdominis muscle, and anastomosis with the inferior epigastric artery.
- The inferior epigastric artery branches from the external iliac artery at the midinguinal point and runs superiorly along the postero-lateral portion of the rectus abdominis muscle. The artery runs medially towards the midline and forms the lateral border of the inguinal triangle (Hesselbach's triangle). It is unlikely to be damaged during a Pfannenstiel incision. The epigastric vessels are at risk during rectus abdominis splitting incisions, which are not advised for cesarean section.
- The deep circumflex iliac artery branches from the external iliac artery at the same point as the inferior epigastric artery and courses behind the inguinal ligament along the iliac crest to anastomose with the musculophrenic artery from above.
- The musculophrenic and deep circumflex iliac arteries can be injured if a transverse

incision is extended too far laterally.

5.2.4 Linea alba

- The linea alba is the insertion point of the fasciae of all three anterior abdominal muscles in the midline.
- The linea alba is relatively bloodless therefore wound healing in the midline is associated with more scar tissue formation.

5.2.5 Nerve supply of the anterior abdominal wall

- The anterior abdominal wall is supplied by the seventh to eleventh intercostal nerves, the subcostal nerve and the iliohypogastric and ilioinguinal nerves (both from L1).
- The nerves run in the plane between the internal abdominal oblique and transversus abdominis muscles and supply all the anterior abdominal wall muscles.
- The nerves enter the rectus sheath, run posterior to the rectus abdominis muscle and more or less at the midpoint of the muscle pass anteriorly through the muscle to supply the muscle and the overlying skin.
- A vertical incision lateral to the midline either lateral to the rectus abdominis muscle or through the muscle will injure the nerves and denervate the structures medial to the incision. The result is atrophy of the rectus abdominis muscle at that level with a greater risk of hernia formation.

5.3 Lower segment of the uterus

- The lower segment of the uterus progressively increases in width and length as pregnancy advances. It also decreases in thickness. The lower segment is found posterior to the bladder. The bladder should therefore be pushed downward to expose the lower segment for incision.
- Kerr⁵⁰ describes the advantages of the lower segment incision of the uterus in anatomical terms:
 - o The wall of the uterus is thin in this area, especially if labor has been in progress for some time. It is often not more than 5 mm in thickness.
 - o The uterine wall consist of fibromuscular tissue with the fibrous tissue being much more abundant.
 - o The lower segment is less vascular.
 - o As there is less bleeding the uterine wound surfaces can be more accurately approximated.
 - o The effects of retraction are less active in this segment compared to the superior segment.
 - o The wound is covered with bladder and peritoneum and is therefore

extraperitoneal. This limits adhesion formation.

- o The wound in the lower segment is not stretched during a subsequent pregnancy and the risk of uterine rupture is much lower than a classical vertical midline incision of the uterus. Uterine rupture does however occur during prolonged labor.
- The myometrium in the fundus consist of 65-70% of smooth muscle and only 25% in the upper cervical segment⁴⁷. Connective tissue increases proportionately toward the cervix. The cervix consists of about 80% collagenous tissue⁴⁸.

5.4 Position of the uterus

- The uterus is frequently dextrorotated, which result in a midline position of the left round ligament as well as anteromedial movement of the base of the broad ligament with the large vessels on the left and the left ureter lying anteriorly.

5.5 Peritoneum

- Both the visceral and parietal peritoneum should be left unsutured to reduce the risk of adhesions and to save time. The peritoneum soon heals by forming a new peritoneal layer^{18, 19}.

5.6 Bladder and ureters^{14, 42}

- As a result of the enlargement of the uterus, the bladder rises out of the pelvis and into the abdomen. Therefore the relationship of the bladder, urethra and ureters to other structures changes⁵².
- In a non-pregnant patient, the ureter normally lies 1.5-2cm lateral to the cervical isthmus and passes beneath the uterine artery and then medially towards the trigone of the bladder.
- In a pregnant patient the ureter is much closer to the uterus and cervix due to the development of the lower segment of the uterus. The trigone is also elevated due to the uterine enlargement and has a convex shape instead of the normal concave shape. The ureteral orifices are therefore displaced laterally. Due to uterine dextrorotation, the left ureter is drawn anteriorly.
- These factors make the bladder and ureters more susceptible to injury during cesarean section.
- The anatomy returns to its prepregnancy position at about 6 weeks after delivery.
- Hydronephrosis and hydroureter are commonly seen during pregnancy. This may be due to mechanical obstruction by the gravid uterus and the physiological effects of progesterones and prostaglandins. Hydronephrosis and hydroureter are more

commonly found on the right. This may be explained by the dextrorotation of the gravid uterus and ureteral compression by engorged right ovarian vessels. Intravenous pyelography shows that the ureter distal to the pelvic brim is not dilated. Therefore a mechanical explanation of anatomical compression on the ureter on the level of the pelvic brim seem appropriate.

5.7 Uterine artery⁴⁹

- The uterine artery arises from the anterior division of the internal iliac artery. It runs medially superior to the endopelvic fascia and crosses the ureter (with the ureter inferior to the artery) about 2-3 cm lateral to the uterus. It gives off an inferior branch, which anastomoses with the vaginal artery. The superior branch anastomoses with uterine branches of the ovarian artery. The uterine artery is found at the base of the broad ligament on the lateral sides of the lower segment of the uterus.
- During pregnancy the artery elongates and undergoes hypertrophy. Therefore the diameter of the lumen increases. Due to increased elastic fibers in the arterial wall it is more flexible and may vary from its normal position. The ovarian arteries on the contrary do not undergo these changes. The ovarian veins however become dilated to accommodate the increased circulatory load of the gravid uterus.
- O'Learly *et al*⁴⁹ describes a method to ligate the uterine arteries in the case of severe bleeding. This is easier to perform than internal iliac artery ligation, requiring less dissection.

5.8 Langer's lines³⁸

- Langer's lines in the abdominal skin are almost transverse. Therefore, transverse incisions of the abdomen wall like a Pfannenstiel incision tend to be the most cosmetic.

5.9 Inferior vena cava and abdominal aorta

- Compression on the aorta will cause uterine hypoperfusion and compromises the acid-base status of the fetus. Compression or partial obstruction of the inferior vena cava may reduce venous return to the heart, causing a fall in maternal cardiac output and arterial blood pressure. This is known as the supine hypotensive syndrome.
- Positioning in the left lateral tilt position is even more important when regional anesthesia is used due to vasodilatation of the veins of the lower extremity and a further decrease in venous return to the heart. Studies showed a clinically and biochemically more favorable status of the fetus during left lateral tilt²⁷.
- Downing *et al*²⁷ measured blood flow in 20 pregnant women with strain gauge plethysmography in the supine, right tilt and left tilt positions in both the upper and

lower limbs. There was no change in the perfusion of the upper limb in all the positions. However, perfusion to the lower limb significantly increased in both the right and left tilt positions and decreased again when turning to the supine position.

- The biochemical status of the newborn is improved when the supine position is avoided during Cesarean section.
- Kerr *et al*²⁶ demonstrated that respiratory changes were not transmitted from the thorax to the inferior vena cava in the supine position in patients late in pregnancy. These cyclical changes were however seen in the lateral tilt position. He also demonstrated a high venous pressure in the inferior vena cava in the supine position. Radiological studies revealed that in 10 of the 12 cases examined there was complete obstruction of passage of contrast medium at the level of the bifurcation of the inferior vena cava. The other 2 were partially occluded. The venous return passed via the lumbar veins and veins surrounding the spinal canal to the azygos veins.
- In the lateral tilt position, some degree of compression of the inferior vena cava was seen. The compression is evenly distributed along the length of the inferior vena cava as far as the fundus of the uterus.
- Kerr²⁶ therefore concludes that inferior vena cava occlusion is the rule rather than the exception in the supine position. The collateral circulation via the vertebral and azygos venous systems is responsible for the venous return in the supine position.
- Obstruction of the inferior vena cava at the level of the entry of the renal veins will cause increased renal venous pressure.

5.10 Round ligament²⁹

- The round ligament helps to identify the uterine vessels. It is situated on the anterior and superior portions of each side of the uterus.

6. Complications (anatomically relevant)

6.1 Incidence

- Nielsen *et al*⁷ showed in a prospective study in 1984, involving 1319 patients, an 11.6% intraoperative complication rate for cesarean sections. Elective cesarean sections had a lower complication rate (4.2%) compared to emergency cesarian sections (18.9%). The most frequent complications are blood loss and infection.
- Nielsen *et al*⁷ classifies complications as minor and major complications. The minor complications are: blood transfusion necessary due to bleeding, minor lacerations on the lower segment of the uterus and minor injuries to the infant such as a minor laceration of the ear. Major complications are: injury to the urinary bladder, vaginal

and cervical tears, lacerations of the corpus uteri and those into the broad ligament, bowel injury and injury to the infant with noticeable morbidity. Nielsen found no major complications in the elective group.

6.2 Risk factors for major complications

The following are risk factors for major surgical complications during emergency cesarean sections:

- The station of the presenting part of the infant in relation to the ischial spines. The lower the presenting part the higher is the risk for complications. The complication rate in cases where the presenting part was below the plane of the ischial spines was as high as 60%.
- Labor prior to surgery.
- Low gestational age less than 32 weeks. A higher incidence of technical problems can arise in extracting the preterm infant from the uterus. The uterine wall is usually thick in these cases.
- Rupture of membranes prior to surgery.
- Previous cesarean section.
- Experience of the surgeon.

6.3 Infection^{2, 7, 9}

- There is an increased risk of infection after cesarean section with rupture of the membranes. The length of membrane rupture and the length of labor prior to surgery influences the risk of infection. The longer the membranes are ruptured and the longer the patient is in labor prior to surgery, the higher the risk.
- Less experienced doctors have higher rates of postoperative infections.
- The diagnosis of endometritis is made in the presence of a body temperature of 38 degrees or higher on two successive readings at an 8-hourly interval with uterine tenderness and foul smelling lochia^{8, 15}.
- Wound infection is the most common complication in cesarean section with the following risk factors: Duration of ruptured membranes prior to operation, duration of labor prior to operation, anemia and obesity⁸. Wound infection is diagnosed on the basis of purulent drainage from the incision site with or without fever.
- Farrell *et al*⁴⁵ found in a series of 457 cesarean sections, that the only significant risk factor for endometritis was a primary cesarean section. The risk of a primary cesarean section developing endometritis is greater than a repeat section. Labor, rupture of membranes and the use of internal fetal-maternal monitoring were not found to be significant risk factors. They report a 23.8% incidence of endometritis.
- Prophylactic antibiotics are indicated for women with previously ruptured

membranes. Other high-risk indications for prophylactic antibiotics are: long period of labor, multiple examinations and internal fetal monitoring.

- Amniotic fluid is spilled and the subsequent wet drapes may be contaminated. Therefore it is advisable to paint the anterior aspects of the thigh with antiseptic solution.
- Abdominoperineal shaving increases the risk of infection.
- There is always a higher risk of infection from the danger of upward infection from the vagina⁵⁰.
- Ott⁵⁵ studied the factors related to postpartum infection. Internal monitoring had little effect on the development of postpartum endometritis. Postpartum anemia, increased time between rupture of membranes and delivery, and patients with a high risk (increased parity and age, early membrane rupture, medical and legal complications) have a higher incidence of postpartum endometritis.

6.4 Extension of the transverse uterine incision

- Extension of the uterine incision carries the risk of injuring structures at the base of the broad ligament like the uterine vessels and ureter. This is avoided by making a central incision into the uterine wall of about 2 cm through to the amniotic sac. Then the incision is extended laterally to both sides with scissors guided by two fingers in the uterine cavity. This is ideally done before rupture of the membranes to allow for better visualization. The extension is done laterally and slightly superiorly to avoid the lateral uterine vessels. The finger spreading technique tends to tear in an inferior direction and is therefore more likely to extend into the uterine vessels.
- Extending the incision by lateral tearing will cause a downward concave tear due to the circular muscles in the lower uterine segment that are directed downwards. There is no control over the tear at all with the risk of injuring the large parametrial veins. Attempts to control this bleeding may result in tying the ureter. Jovanovic³¹ reports such a case, as well as a case where 36 units of blood had to be transfused. Another patient had a hysterectomy to save her life.
- In the case of a low-birth weight infant or big baby from a nonlabored uterus where a large incision is necessary, Jovanovic³¹ reports that it is best to make an upward curved transverse incision over the lower segment of the uterus.

6.5 Injury to blood vessels

- The fascia that covers the uterine surface should not be incised or damaged when incising the visceral peritoneum overlying the lower segment of the uterus. Vigorous bleeding may occur if this is done at a point during the operation where it should be bloodless. The peritoneum should therefore be picked up with forceps and

cut with scissors rather than using a knife against the uterine surface.

- It is important to identify any torsion of the uterus before performing the lower segment incision of the uterus. Dextrorotation is commonly found, and if not corrected, can result in extending the incision into the large blood vessels near the base of the broad ligament. This is more likely with the surgeon standing on the right side of the patient. Incising these vessels may result in vigorous bleeding.
- Injury to the uterine artery is associated with vigorous bleeding. The artery needs to be ligated in the broad ligament as well as the ovarian-uterine anastomosis just below the attachment of the ligament of the ovary.
- **Vigorous bleeding from the angles of the uterine incision.**

The problem with this complication is limited exposure of the angles of the uterine wound.

With serious bleeding from a lateral angle of the wound, the lateral part of the uterus should be lifted with two fingers behind the broad ligament. This makes the site of the vessels easier to visualize and compresses the vasculature for clamping. This maneuver also avoids injury to the ureters and bladder.

Care should especially be taken during the lower segment incision that lateral extension of the incision does not occur, due to the close relation of the uterine vessels.

- **Internal iliac ligation**

Vigorous bleeding may occur during cesarean section. Internal iliac artery ligation has been described as a method to stop the bleeding. Evans *et al*⁵³ reports on 18 patients where the procedure was performed. The three main collateral vessels are the iliolumbar, middle sacral-lateral sacral and superior rectal-inferior rectal arteries. However, due to the variability of the pelvic vasculature in individual patients, ligation of the internal iliac artery may have serious consequences due to insufficient collaterals. Evans⁵³ describes a case of pelvic and perineal ischemia in one patient. The procedure is also not effective in placenta accreta and uterine lacerations. A Hysterectomy is the procedure of choice in patients who are hemodynamically stable.

6.6 Complications of the Pfannenstiel incision³⁸

- Dead spaces are created by the dissection of layers of fascia and muscles during this incision. Therefore more bleeding occurs. A subcutaneous drain is often necessary.
- The incision takes relatively more time to complete.
- Transverse incisions may result in nerve divisions. The iliohypogastric and

ilioinguinal nerves may be injured in a wide Pfannenstiel incision. This will result in loss of sensation over the suprapubic region (iliohypogastric nerve) and over the labia majora (ilioinguinal nerve). The ilioinguinal nerve also supplies the conjoint tendon (inferior fibers of the internal oblique and transversus abdominis muscles). This may predispose to the development of an inguinal hernia.

6.7 Injury to the bladder¹⁵

Eisenkop *et al*⁵ reports an incidence of 0.3% of bladder injuries and 0.09% of ureteral injuries in 7527 cesarean sections.

- This is more likely to happen in patients with previous cesarean sections when the visceral peritoneum overlying the lower segment of the uterus is opened and stripped downwards. Eisenkop⁵ reports that dissection of the bladder off the lower uterine segment was the most common cause of bladder injuries, especially in the presence of scar tissue from previous surgery. Meticulous sharp dissection is therefore necessary in a case of previous cesarean sections. The bladder is separated from the lower segment of the uterus to better visualize the lower segment of the uterus and to get the ureters out of the field. This should not be done too aggressively in order to avoid injury to the bladder.
- Bladder integrity can be tested intraoperatively by injecting methylene blue dye to distend the bladder and evaluate its integrity.
- With a previous cesarean section, the peritoneum should be incised close to the umbilicus in a midline incision to avoid injury to the bladder.
- A too low incision over the lower segment of the uterus, may result in the uterine muscle disappearing below the bladder. This may lead to subsequent inclusion in a suture of the bladder or even the ureters during subsequent suturing of the uterine wall.
- Extension of the uterine incision may lead into the bladder.
- The bladder can easily be injured during the suturing of the lateral angles of the uterus when the bladder was not separated properly from the lower segment of the uterus.
- The bladder should be catheterized. An empty bladder provides better exposure and decreases the risk of bladder injury.
- Signs of bladder injury: A red vascular appearance of the muscularis of the bladder, urine leaking from the dome of the bladder and a visible Foley's bulb. Hematuria may be indicative of bladder wall trauma.
- Bladder perforation should be dealt with immediately to avoid continuous

urine leakage and to avoid enlargement of the perforation. The most important prognostic indicator for morbidity is the time of recognition of the injury⁵.

- Method: Apply Allis clamps on either side of the defect and inspect the trigone and ureteral orifices. Suture the bladder in two layers. First the submucosa and intermediate muscularis layers with continuous 3-0 chromic catgut. Then the rest of the muscularis and serosa with the same suture. Test the bladder integrity by gentle distention of the bladder. Adequate bladder drainage should be secured for at least 7 days.
- Urinary fistula formation should be avoided by early detection and repair of bladder injuries⁷.
- Faricy *et al*⁵² confirms that bladder injuries are associated with failure to empty the bladder preoperatively, inadequate bladder flap reflection and vaginal incision instead of lower uterine segment incision.
- Complications if bladder injury is not recognized during surgery include: vesicovaginal fistulae, calculi due to penetrating non-absorbable suture material and menouria due to a vesicovaginal fistula⁵².

6.8 Injury to the ureters

- This is a very rare complication with a rate of 0.09% reported by Eisenkop⁵.
- Ureteral obstruction, ureterovaginal fistulae and ureterouterine fistulae have been reported⁵¹.
- The cause of ureteral injury is usually due to extension of the uterine incision laterally towards the base of the broad ligament or by hemostatic sutures that are placed at the angles of the uterine incision⁵. Ureteral injuries are associated with large infants or in cases of breech or transverse lie where difficulty is experienced during delivery.
- If a ureteral injury is suspected, a urologist should be consulted. The following procedures can be done to assess ureteral patency:
 - Intraoperative or postoperative pyelography.
 - Diagnostic cystotomy with intravenous injection of dye and direct observation of efflux of dye from the ureteral orifice.
 - Diagnostic cystotomy with passage of catheters in the ureter through the ureteral orifice.

6.9 Injury to the bowel²⁹

- The bowel may be injured while entering the peritoneal cavity through the parietal peritoneum. Therefore, the peritoneum should be elevated by a non-toothed forceps

or hemostat in the superior third of the peritoneum. The peritoneum should be inspected and palpated to ensure that no bowel or omentum or even bladder is at risk of being injured when the peritoneal cavity is entered.

- More care should be taken if the patient had a previous cesarean section. The risk of adhesions of the bowel or omentum to the anterior abdominal wall is higher.
- Bowel injuries involving the bowel lumen, may lead to fecal contamination of the peritoneal cavity with resultant peritonitis and possible abscess formation.
- Bowel may be injured with the scalpel blade, clamps during surgery or with a suturing needle during abdominal wall closure.
- The risk of bowel injury is increased when the incision needs to be enlarged and when blind attempts are made to control bleeding.
- The following principle should be followed when dealing with adhesions: Gentle blunt dissection with filmy adhesions and sharp dissection with thick adhesions.
- If bowel injury is suspected, the different layers of the bowel involved should be assessed. Small bowel serosa tears may be sutured with 4-0 absorbable suture. If the muscular layer is also involved, a single layer of interrupted 4-0 nonabsorbable suture may be used, at right angles to the longitudinal direction of the bowel. If the lumen has been entered, approximate the muscular layer with interrupted 4-0 absorbable suture and the serosal layer with nonabsorbable 4-0 silk²⁹.

6.10 Uterine rupture after previous cesarean section.

- Merrill *et al*¹ has shown that 49% of 526 patients with a previous cesarean section delivered vaginally with low morbidity. Unfavorable factors tending to increase the risk of scar rupture are sepsis following the operation and the implantation of the placenta beneath the scar in a subsequent pregnancy.
- The clinical signs of abruptio placentae in a woman with a previous cesarean section should always raise concern about a possible uterine rupture¹⁰.
- The diagnosis of uterine rupture may be difficult due to the fact that large amounts of blood can collect in the broad ligament and extraperitoneal spaces⁴⁴. The diagnosis should always be on the list when an obstetric patient presents with shock.
- The lower segment uterine scar is less likely to rupture compared to the classical cesarean section scar¹¹. Rupture of a lower segment uterine scar happens during labor and is essentially a dehiscence of the wound with minimal bleeding. Rupture of a classical scar may however result in serious bleeding for the placenta usually overlies the scar.
- Miller *et al*³⁹ reports that 0.6 % of women with one previous cesarean section had a

uterine scar rupture, 1.8% of women with two previous cesarean sections and 1.2% with three or more previous cesarean sections. Uterine rupture was therefore three times more common with two or more previous cesarean sections. Miller *et al*³⁹ concludes that trial of labor is acceptable in the majority of women with previous cesarean sections.

6.11 Extracting the head of the fetus with uterine tearing

- The hand may be used to extract the fetal head, by scooping the head out of the pelvis and then through the uterine incision. The uterine incision is stretched with the head of the fetus and the hand of the surgeon. This may cause tearing of the uterine incision laterally with subsequent bleeding from the dilated veins in relation to the broad ligament.
- Using the hand in the case of a small head may be easy, but the use of a forceps puts less stress on the uterine incision in the case of a bigger head.
- The surgeon should be very careful not to flex the wrists when the hand is between the inferior edge of the incision and the fetal head. This maneuver will cause the incision to tear laterally into the broad ligament or even downward into the vagina.

6.12 Problems with fetal extraction

- The child's head may be impacted in the pelvis. In this event, the table should be put in the Trendelenburg position, and the assistant should pull the fetal shoulder upwards or if this does not help, dislodge the fetal head by means of a vaginal examination.
- If the fetal arm presents the arm should be put back into the uterine cavity. The arms should never be pulled.
- The head can also be rotated to the transverse position and then the head lifted out manually by lateral flexion of the neck.
- With a head high in the uterus fundal pressure may be applied or a vacuum extractor may be used.

6.13 Low Apgar scores

- The interval between opening the uterus and delivery of the infant is important for neonatal outcome. During general anesthesia, induction-to-delivery intervals of more than 8 minutes and uterine incision-to-delivery intervals of more than 3 minutes, are associated with significantly more cases of neonatal acidosis and low 1-minute Apgar scores. During spinal anesthesia, only the uterine-to-delivery interval of more than 3 minutes is important in fetal outcome³². The patient needs to be draped before the induction during general anesthesia.

6.14 Pulmonary embolism^{3,4,7}

- Moldin⁴ reports on pulmonary embolism being one of the most common causes of maternal mortality after cesarean section.
- Preventative measures like early postoperative ambulation, elevation of the extremities and stockings can be used³. Prophylactic drug therapy may be considered in high-risk patients.

6.15 Amniotic fluid embolism⁴

- Together with pulmonary embolism, amniotic fluid embolism was the principle cause of death of the cases reported in Moldin *et al*'s study⁴. In his study 8 patients died from causes directly associated with the cesarean section out of a total of 63 075 cesarean sections performed over 7 years.

6.16 A too low incision

- A too low incision over the lower segment of the uterus may result in the uterine muscle disappearing below the bladder. This may lead to a subsequent inclusion of a suture of the bladder or even the ureters.
- Due to the downward converging of the lateral walls of the uterus, a too low incision may be too short in width with possible difficulty in extracting the head and tearing of the broad ligament which causes vigorous bleeding.

6.17 Inaccurate suturing of the uterine wall

- This may be the result of initial tearing of the uterine aperture with the index fingers laterally after the initial small transverse incision in the lower segment of the uterus. Apart from uncontrolled tearing into the broad ligament, the surfaces of the tear are ragged and result in inaccurate suturing of the uterus.
- The strength of the uterine scar depends on the accuracy with which the suturing of the uterus is done when approximating the anatomical margins of the uterus.

6.18 Complications related to suturing of the uterus

- The bladder may be included in the sutures if the bladder has not been properly displaced from the lower segment of the uterus
- Dilated veins in relation to the broad ligament may be injured if the incision was made too far laterally or was torn during delivery of the fetal head.
- The upper edge of the uterine incision may be mistakenly sutured to a

transverse retraction ring appearing from the posterior uterine wall, and not to the lower edge of the uterine incision.

6.19 Infant injuries⁴³

- Most injuries are mild and self-limiting. Rubin³³ reports an incidence of 2 to 7%.
- Soft tissue injuries are most common including tissue bruising.
- The following factors may play a role:
 - Too small abdominal and/or uterine incisions,
 - Impatience during delivery and the amount of manipulation necessary during the delivery.
 - Facial bruising may occur during use of a forceps.
 - The use of a vacuum extractor may cause caput and rarely a cephalohematoma.
- **Fetal skin lacerations** are caused by incision during entrance into the uterine cavity. This complication is more likely in the presence of oligohydramnios. Adequate visualization is necessary in the operating field to avoid incising the infant's skin. The ear of the child may be situated just below the lower segment of the uterus and can be injured when performing the lower segment incision. Therefore, when extending the lower segment incision laterally with the scissors, the opposite finger should lift the uterine wall to avoid injuring an ear just below the surface. Continuous suctioning while entering the uterine cavity is essential to have a good field of vision. Fetal skin lacerations usually only require 'Steri-Strips'.
- **Skeletal complications** are the same as for vaginal delivery and are associated with breech deliveries.
 - Humerus fractures can occur due to manipulation of the arm. Haste should be avoided during displacement.
 - Clavicular fractures can occur with raised arms.
 - Femur fractures are not common. Long bone fractures usually occur during extraction. Fractures may be green stick fractures, complete or through the diaphysis or epiphyseal plate.
 - Temperomandibular dislocations may occur during the Mauriceau-Smellie-Viet maneuver in breech deliveries.
- **Brachial plexus palsy** can occur on the opposite side of the neck (lateral extension) due to lateral flexion of the neck during extraction of the head through an insufficient incision or in the presence of a contraction ring or raised arms. Injury of the brachial plexus may vary from individual nerve injury to avulsion of nerve roots³⁴. Erb's palsy has also been reported. This occurs at the junction of the 5th and 6th cervical

nerve roots also referred to as Erb's point. Lower brachial plexus injuries were described by Klumpke³⁴. Greenwald *et al*³⁴ reports an incidence of 2/1000 births. Most cases had a good prognosis with early recovery.

- **Spinal cord trauma** can occur in breech presentations with a hyperextended head³⁵.
- **Intra-abdominal organ injury** may occur to the spleen, liver and also kidneys or adrenals if inappropriate pressure is exerted on the abdomen during extraction. The mortality rate of a ruptured spleen or liver is high³⁶. The child will present with shock and abdominal distension. Cullen's sign of bluish discoloration of the umbilicus is a recognized sign of intraperitoneal bleeding³⁶.
- **Depressed skull fracture.** Skajaa *et al*⁵⁴ reports a depressed skull fracture of a child born by cesarean section. The cause was digital impression on the parietal bone during delivery by the doctor. He also speculates that the impaction of the fetal head against the promontory, ischial spines or the symphysis pubis may weaken the bone during prolonged labor.
Although rare, these fractures may be accompanied by intracranial hemorrhage.

6.20 Laceration of the cervix and vagina⁷

- Especially during an emergency cesarean section, the lower segment of the uterus can be mistaken with the vagina.
- Vaginal incision may happen especially if the patient has been pushing in the second phase of labor. Bryan *et al*⁴⁶ reports two cases of inadvertent entry into the superior part of the vagina. The incision may then be thought to be through the lower segment of the uterus, but actually enters the upper vagina. There is a high risk of associated bladder injury and secondary fistula formation, either vesicouterine or vesicovaginal fistulae.
Due to the extension of the incision, the cardinal ligaments of the cervix, the ureters and descending branch of the uterine artery may be injured as well.
- In women with a history of prolonged second stage of labor, entry into the vagina during the uterine incision should be avoided by making the incision just above the reflection of the vesicouterine peritoneum. The muscles of the uterus in the lower segment are more transversely oriented compared to the more longitudinal directions of the vaginal musculature. This may also help to distinguish the lower segment of the uterus from the vagina.

6.21 Incisional hernia and postoperative wound disruption

- Greenall *et al*²⁰ has shown in a randomized clinical trial comparing the abdominal midline incision with a transverse incision, that the midline incision has a higher incidence of incisional hernias and tends to burst more easily than transverse abdominal incisions. There is less tension on the edges of the transverse abdominal incision like a Pfannenstiel incision compared to a midline incision.

- Using the Pfannenstiel incision minimizes this complication. Mowat *et al*²⁸ showed that vertical incisions have an eightfold increase in wound dehiscence compared to transverse incisions.
Patients with wound disruptions and infection usually have a longer hospital stay. Therefore the risk of thromboembolism is considerably increased.
The risk of wound dehiscence is higher in the presence of prolonged rupture of the membranes. The transverse incision should be used in these patients.

6.22 Pseudo-obstruction of the colon²⁴

- This complication is characterized by an unobstructed colon which is adynamic. The cecum and transverse colon rapidly dilates and eventually may lead to perforation of the cecum. The cecal perforation occurs due to the increased pressure in the bowel and the large diameter of the cecum. This may be a fatal condition if not diagnosed early.
- Rapid abdominal distention without pain, tenderness or vomiting is the first clinical symptom. Symptoms of obstruction occur later. A gas-filled colon especially in the cecum and an ascending colon with a cut off sign at the hepatic or splenic flexures, as seen on a plain abdominal X-ray, are diagnostic.
- Colonic decompression by a nasogastric tube and cecostomy should be performed.
- The pathogenesis of the complication may be explained by an imbalance between sympathetic and parasympathetic innervation. Sacral (S2,3,4) parasympathetic involvement is likely to be implicated. Hence the cut off sign at the splenic flexure where the parasympathetic innervation of the colon changes from vagal (CN X) to sacral (S2,3,4). The gravid uterus applies pressure on the sacral plexus and therefore on the hypogastric parasympathetic plexus as well.

6.23 Superficial hematoma formation

- Hematoma formation in the superficial fascia of the abdominal wall is a common complication. This can be prevented by suturing the superficial tissue layer separately especially in women with a thicker fatty layer. Fine 2.0 catgut can be used for this purpose.
- Pfannenstiel incisions have a higher tendency for hematoma formation, due to the division of multiple layers of fascia and therefore the formation of potential spaces²⁹. A subcutaneous drain is often necessary.
- During a Pfannenstiel incision care should be taken to ligate the superficial epigastric vessels. This will help avoid subfascial hematoma formation.

6.24 Meconium granuloma formation³⁰

- Blood and amniotic fluid may result in meconium granuloma formation. This can be prevented by using laparotomy packs in each paracolic gutter to absorb these fluids. Spillage of meconium during cesarean section may produce a foreign body granulomatous response resulting in adhesions and abdominal pain. This is a rare condition. Freedman *et al*³⁰ reported two cases.

6.25 Nausea and vomiting

- Patients under regional anesthesia may experience nausea and vomiting due to stretching of the peritoneum when the laparotomy packs are inserted or taken out.

6.26 Injury to the femoral nerve³⁷

- The retractor may damage the femoral nerve during pelvic surgery due to prolonged pressure.
- Salzberg *et al*³⁷ reports that a transverse incision is a predisposing factor. With a Pfannenstiel incision, the retractor can be placed more laterally and therefore increases the risk of injuring the nerve. Patients with thin anterior abdominal walls have a higher risk of femoral nerve injury.
The retractor usually injures the femoral nerve about 4 cm superior to the inguinal ligament. The retractor blade can either directly injure the nerve or compress the psoas major muscle and the femoral nerve against the pelvic wall with resultant ischemic damage to the nerve.
- The femoral nerve comes from L2,3,4 and runs in a groove between the iliacus and psoas major muscles. It then runs under the inguinal ligament and enters the femoral triangle.
- Femoral nerve injury may result in paralysis of knee joint extension, wasting of the quadriceps muscle, an absent knee jerk reflex and weakness of hip flexion. These symptoms may range from motor function loss to paresthesias in the cutaneous distribution of the femoral nerve to the anterior aspect of the thigh and the medial surface of the leg.
- Injury to the femoral nerve should be prevented by using appropriate retractors, which do not impinge on the psoas major muscle. Pads can also be placed between the retractor blades and the pelvic wall.
- The absence of the femoral pulse may indicate that too much pressure is placed on the external iliac artery and the femoral nerve.
A too long incision should also be avoided to keep the retractors away from the nerve.

6.27 Injury to the genitofemoral nerve³⁷

- Injury to this nerve presents with pain in the inguinal region with radiation to the genitalia and the upper medial aspect of the thigh. The mechanism of injuring this nerve is the same as for the femoral nerve.
- The genitofemoral nerve comes from L1 and L2 and is mainly a sensory nerve. It pierces the psoas major muscle, runs on the muscle and divides in a genital and femoral branch near the inguinal ligament. The femoral branch innervates the skin over the femoral triangle and the genital branch enters the deep ring of the inguinal canal. It accompanies the round ligament of the uterus in the inguinal canal and supplies the skin of the mons pubis and labium majora.

6.28 Unexpected placenta directly beneath the incision⁴⁰

- Discovery of an anteriorly positioned placenta is usually made while entering the uterine cavity if an ultrasound did not reveal this before the operation. Heavy bleeding may occur. The placenta may be displaced laterally or the incision may be done through the placenta. Therefore there may be fetal blood loss as well. When there is difficulty in extracting the fetus, the cord can be clamped prior to delivery. Resuscitation should commence as soon as the baby is delivered. Maternal hemodynamic function should be supported.

6.29 Formation of fibrous post-operative adhesions

- This complication is common after laparotomies and is caused, as shown by Ellis¹⁹ in animal studies by tissue ischemia and not serosal damage. These adhesions are actually vascular 'grafts' from viable structures in the area providing blood supply to host tissues to remain viable.
- The peritoneum should therefore not be sutured. Suturing of the peritoneum creates ischemic tissue at the suture line and therefore initiates adhesion formation at the sites of reperitonealization. The peritoneum heals by differentiation of a new mesothelium from underlying connective tissue cells.

7. References

¹ Merrill BS, Gibbs CE. Planned vaginal delivery following cesarean section. *Obstet Gynecol* 1978; 52: 50-2

² Evrard JR, Gold EM. Cesarean section and maternal morbidity in Rhode Island. Incidence and risk factors, 1965-1975. *Obstet Gynecol* 1977; 50: 594

³ Rubin GL, Peterson HB, Rochat RW, McCarthy BJ, Terry JS. Maternal death after cesarian section in Georgia. *Am J Obstet Gynecol* 1981; 139: 681

⁴ Moldin P, Hökegard KH, Nielsen TF. Cesarean section and maternal mortality in Sweden 1973-1979. *Acta Obstet Gynecol Scand* 1984; 63: 7-11

⁵ Eisenkop SM, Richman R, Platt LD, Paul RH. Urinary tract injury during cesarean section. *Obstet Gynecol* 1982; 60: 591

- ⁶ Evrard JR, Gold EM, Cahill TF. Cesarean section: a contemporary assessment. *J Reprod Med* 1980; 24: 147
- ⁷ Nielsen TF, Hokegard K-H. Cesarean section and intraoperative surgical complications. *Acta Obstet Gynecol Scand* 1984; 63: 103
- ⁸ Nielsen TF, Hokegard K-H. Post-operative cesarean section morbidity: a prospective study. *Am J Obstet Gynecol* 1983; 146: 911
- ⁹ Petitti DB. Maternal mortality and morbidity in cesarean section. *Clin Obstet Gynecol* 1985; 28: 763-769
- ¹⁰ Chazotte C, Cohen WR. Catastrophic complications of previous cesarean section. *Am J Obstet Gynecol* 1990; 163: 738-42
- ¹¹ Meehan FP, Magni IM. True rupture of the cesarean section scar. *Eur J Obstet Gynecol Reprod Biol* 1989; 30: 129-35
- ¹² Johnson D, Dixon AK, Abrahams PH. The abdominal subcutaneous tissue: Computed Tomographic, Magnetic Resonance, and anatomical observations. *Clin Anat* 1996; 9: 19-24
- ¹³ Kriebel SH, Pitts JD. Obstetric outcomes in a rural family practice: an eight-year experience. *J Fam Pract* 1988, 27: 377-384
- ¹⁴ Hibbard LT. Extraperitoneal cesarean section. *Clin Obstet Gynecol* 1985, 28: 711-721
- ¹⁵ Deutchman M, Connor P, Gobbo R, FitzSimmons R. Outcomes of cesarean sections performed by family physicians and the training they received: a 15-year retrospective study. *J AM Board Fam Pract* 1995; 8: 81-90
- ¹⁶ Holmgren G, Sjöholm L, Stark M The Misgav Ladach method for cesarean section: method description. *Acta Obstet Gynecol Scand* 1999; 78: 615-621
- ¹⁷ Darj E, Nordström ML. The Misgav Ladach method for cesarean section compared to the Pfannenstiel method. *Acta Obstet Gynecol Scand* 1999; 78: 37-41
- ¹⁸ Ellis H, Heddle R. Does the peritoneum need to be closed at laparotomy? *Br J Surg* 1977; 64: 733-6
- ¹⁹ Ellis H. The aetiology of post-operative abdominal adhesions. *Br J Surg* 1962; 50: 10-16
- ²⁰ Greenall MJ, Evans M, Pollack AV. Mid-line or transverse laparotomy? A random controlled trial. Part 1: Influence on healing. *Br J Surg* 1980; 67: 188-93
- ²¹ Stark M, Finkel AR. Comparison between the Joel-Cohen and Pfannenstiel incisions in cesarean section. *Eur J Obstet Gynecol Reprod Biol* 1994; 53: 121-2
- ²² Down RH, Whithead R, Watts JM. Do surgical packs cause peritoneal adhesions? *Aust N Z J Surg* 1979; 49: 379-82
- ²³ Larsen B, Davis B, Charles D. Critical assessment of antibacterial properties of human amniotic fluid. *Gynecol Obstet Invest* 1984; 18: 100-4
- ²⁴ Ravo B, Pollane M, Ger R. Pseudo-obstruction of the colon following cesarean section: a review. *Dis Colon Rectum* 1983; 26: 440-444
- ²⁵ Howard BK, Goodson JH, Mengert WF. Supine hypotensive syndrome in late pregnancy. *Obstet Gynecol* 1953; 1: 371
- ²⁶ Kerr MG, Scott DB, Samuel E. Studies of the inferior vena cava in late pregnancy. *Br Med J* 1964; 1: 532
- ²⁷ Downing JW, Bees LT. The influence of lateral tilt on limb blood flow in advanced pregnancy. *S Afr Med J* 1976; 50: 728
- ²⁸ Mowat J, Bonnar J. Abdominal wound dehiscence after cesarean section. *Br Med J*

1971; 2: 256

²⁹ Abuhamad A, O'Sullivan MJ. Operative techniques for cesarean section. In: Plauche WC, Morrison JC, O'Sullivan MJ. *Surgical Obstetrics*. Philadelphia: WB Saunders Company, 1992: 419

³⁰ Freedman SI, Ang EP, Herz MG et al. Meconium granulomas in post-cesarean section patients. *Obstet Gynecol* 1982; 59: 383

³¹ Jovanovic R. Incisions of the pregnant uterus and delivery of low birth weight infants. *Am J Obstet Gynecol* 1985; 152: 971

³² Datta S, Ostheimer GW, Weiss JB et al. Neonatal effect of prolonged anesthetic induction for cesarean section. *Obstet Gynecol* 1981; 58: 331

³³ Rubin A. Birth injuries: Incidence, mechanisms and end results. *Obstet Gynecol* 1964; 23: 218

³⁴ Greenwald AG, Schute PC, Shiveley JL. Brachial plexus birth palsy: A ten year report on the incidence and prognosis. *J Pediatr Orthop* 1984; 4: 689

³⁵ Abrams J. Cervical cord injuries secondary to hyperextension of the head in breech presentations. *Obstet Gynecol* 1973; 41: 369

³⁶ Eraklis AJ. Abdominal injury related to trauma at birth. *Pediatrics* 1967; 39: 421

³⁷ Salzberg SI, DeLancey JOL. Injury to the femoral nerve during laparotomy. In: Nichols DH, DeLancey JOL. *Clinical problems, injuries and complications of gynecologic and obstetric surgery*. 3rd Ed. Baltimore: Williams & Wilkins, 1995: 174-178

³⁸ Hankins GDV, Clark SL, Cunningham FG, Gilstrap LC. Anatomy, incisions and closures. In: *Operative Obstetrics*. Norwalk: Appleton & Lange, 1995: 55-68

³⁹ Miller DA, Paul RH. Vaginal birth after cesarean section: a ten year experience. *Obstet Gynecol* 1994; 84: 225

⁴⁰ Hankins GDV, Clark SL, Cunningham FG, Gilstrap LC. Cesarean section. In: *Operative Obstetrics*. Norwalk: Appleton & Lange, 1995: 321-327

⁴¹ Hull DB, Verner MW. A randomized study of closure of the peritoneum at cesarean delivery. *Obstet Gynecol* 1991; 77: 818-20

⁴² Scotti RJ. Urologic complications. In: O'Grady JP, Gimovsky ML, McIlhargie JD. *Operative obstetrics*. Baltimore: Williams & Wilkins, 1995: 368-369

⁴³ Yasin SY, Walton DL, O'Sullivan MJ. Problems encountered during cesarean section. In: Plauche WC, Morrison JC, O'Sullivan MJ. *Surgical Obstetrics*. Philadelphia: WB Saunders Company, 1992: 431-445

⁴⁴ Plauche WC, Von Almen W, Muller R. Catastrophic uterine rupture. *Obstet Gynecol* 1984; 64: 792-7

⁴⁵ Farrell SJ, Andersen HF, Work BA. Cesarean section: Indications and postoperative morbidity. *Obstet Gynecol* 1980; 56: 696

⁴⁶ Bryan B, Strickler RG. Inadvertent primary vaginal incision during cesarean section. *Can J Surg* 1980; 23: 581

⁴⁷ Rorie DK, Newton M. Histological and chemical studies of the smooth muscle in the human cervix and uterus. *Am J Obstet Gynecol* 1967; 99: 466

⁴⁸ Danforth DN. The fibrous nature of the human cervix and its relation to the isthmic segment in gravid and non-gravid uteri. *Am J Obstet Gynecol* 1947; 53: 541

⁴⁹ O'leary JL, O'Leary JA. Uterine artery ligation in control of intractable postpartum hemorrhage. *Am J Obstet Gynecol* 1966; 94: 920-924

⁵⁰ Kerr JMM. The technic of cesarean section with special reference to the lower uterine

segment incision. *Am J Obstet Gynecol* 1926; 12: 729-732

⁵¹ Crichton D. Ureteric injuries in gynaecological surgery. *S Afr Med J* 1965; 39: 686

⁵² Faricy PO, Augspurger RR, Kaufman JM. Bladder injuries associated with cesarean section. *J Urol* 1978; 120: 762

⁵³ Evans S, McShane P. The efficacy of internal iliac artery ligation in obstetric hemorrhage. *Surg Gynecol Obstet* 1985; 160: 250-253

⁵⁴ Skajaa K, Hansen ES, Bendix J. Depressed fracture of the skull in a child born by cesarean section. *Acta Obstet Gynecol Scand* 1987; 66: 275

⁵⁵ Ott WJ. Primary cesarean section. Factors related to postpartum infection. *Obstet Gynecol* 1981; 57: 171

⁵⁶ Spencer R. A Clinical conundrum. *Clin Anat* 1999; 12: 430-431

4.4.3.2 Appendectomy

1. Indications	281
2. Contraindications	281
3. Step by step procedure	281
4. Materials	284
5. Anatomical pitfalls	284
6. Complications (anatomically relevant)	294
7. References	302

1. Indications

- Appendicitis
Appendicitis has a peak incidence in early adulthood. A review of 2000 patients showed a 1.3:1 male to female ratio³⁰.

2. Contraindications

- An appendectomy should not be performed in the presence of one of the differential diagnoses. These include acute mesenteric adenitis, acute gastroenteritis, urinary tract infection, ureteral stone, pelvic inflammatory disease, ovulation, pleuritis or consolidation of the lower lobe of the right lung, Henoch Schönlein purpura, testicular torsion, acute epididymitis and seminal vesiculitis, Meckel's diverticulitis, intussusception, perforated peptic ulcer and cecal carcinoma or diverticulitis.

3. Step by step procedure

Step 1. Prepare the patient for theatre making sure the patient is properly hydrated and preexisting cardiac and respiratory problems are addressed.

Step 2. Identify McBurney's point¹⁴. This point is situated at the junction of the lateral and middle third of the line between the superior anterior iliac spine and the umbilicus.

Step 3. Surgically prepare the skin of the anterior abdominal wall and the right thigh.

Step 4. McBurney's incision

- The incision is made obliquely for about 8-10cm, crossing a line from the anterior superior iliac spine to the umbilicus at right angles through McBurney's point. The incision extends one third above and two-thirds below McBurney's point¹⁴. McBurney stresses the importance of an incision of proper length: "Incisions should be long enough to allow complete and safe work to be done, and it is most unscientific and harmful to encourage

those of limited experience to believe that a special measure of good goes with a special length of incision”¹⁴

- This incision should be used in cases of acute appendicitis without perforation and peritonitis. In the case of a perforated appendix with generalized peritonitis a midline incision or paramedian incision is required due to the need of abdominal lavage and drainage in all abdominal quadrants.
- The McBurney’s incision can be extended medially for lower abdominal pathology, but for upper abdominal pathology, the wound should be closed and a midline laparotomy performed.

Alternative: Lanz incision. This incision is made 1-2 cm medial to the anterior superior iliac spine and continued medially in a slight curve, which is convex inferiorly. The advantage of this incision is that it can be extended medially through the rectus sheath or laterally by division of the abdominal muscles²⁹ for other intra-abdominal pathology, whereas the McBurney’s incision is poor in that regard.

Step 5. Incise the external abdominal oblique aponeurosis in the line of the skin incision, which is in the line of its fibers.

Step 6. Split the internal abdominal oblique and the transversus abdominis muscles in the line of their fibers to expose the peritoneum. The fibers of the transversus abdominis muscle become aponeurotic lateral to the point of the fibers of the internal oblique.

These muscles should be separated without cutting them, thus avoiding nerve injury.

Step 7. Insert the Langenbeck retractors beneath both muscles.

Step 8. Pick up the peritoneum with two artery forceps’s and make sure there is no underlying bowel that may be injured.

Step 9. Incise the peritoneum in a craniocaudal direction.

Step 10. Insert the Langenbeck retractors beneath the peritoneum and pull them perpendicular to the line of incision.

Step 11. Take swabs of any purulent fluid before suctioning it.

Step 12. Identify the cecum.

Step 13. Identify the appendix by rotating the cecum until the base of the appendix can be seen. The teniae of the cecum can also be followed to the base of the appendix. To expose the base of the appendix, the cecum should be drawn in order: inferiorly, anteriorly and superiorly.

Access the appendix. It can be easily picked out, when lying in the pelvis. It may be difficult to identify a retrocecal appendix.

- Step 14.** Grasp the mesoappendix with a forceps or the appendix with a Babcock tissue forceps.
- Step 15.** In the case of an immobile cecum bound down by peritoneum, it may be necessary to mobilize the cecum by incising the peritoneum on the lateral side of the cecum. This will also give access to a retrocecal appendix. It may be necessary to extend the wound upwards to allow mobilizing the cecum.
- Step 16.** Gradually mobilize the mesoappendix and transect the vessels in the mesoappendix.
- Step 17.** Identify the appendicular artery. It usually runs in the free edge of the mesoappendix. The artery should be doubly tied off as well as the smaller vessels towards the base of the appendix. These vessels at the base of the appendix may be difficult to ligate and can be controlled by diathermy.
- Step 18.** Clamp the fully mobilized appendix, approximately 5mm from the base and reapply the forceps 7-8 mm further distally. A 1.0 chromic catgut ligature is tied to the crushed area.
- Step 19.** Transect the appendix with a scalpel on the cecal side of the forceps. Discard the appendix with the forceps.
- Step 20.** It is not necessary to bury the stump, and it is not advised to bury the stump routinely. Williams *et al*²⁹ report on 700 appendectomies where the stump was left unburied. The stump as well as the base on the cecum should be clearly viable.
- Step 21.** Suction any fluid from the pelvis and right paracolic gutter. Pass a gauze swab on a forceps through these areas to clean them properly.
- Step 22.** Inspection of the abdominal organs
- If the appendix appears normal, first inspect the other abdominal organs before the normal appendix is removed. There may possibly be a contraindication for removal of the appendix, for example the risk of fistulae forming in the presence of Crohn's disease⁴⁷.
 - Inspect the cecum, proximal ascending colon and the distal ileum.
 - Inspect the ileum from the ileocecal valve for a possible Meckel's diverticulum at about 20-70 cm from the ileocecal valve²⁴.
 - The presence of mesenteric adenitis may be seen in the ileal mesentery.
 - With a head down tilt and packing of the ileum, the pelvic organs in the female can be inspected.
- Step 23.** Close the peritoneum with continuous suture of catgut under direct vision.

Step 24. As soon as the retractors are removed the abdominal muscles fall together. Use interrupted sutures of catgut to approximate the internal oblique and transversus abdominis muscles. It is advisable to close the transversus abdominis aponeurosis and transversalis fascia separately to help prevent subsequent possible hernias²². The sutures should not be too tight and therefore cause strangulation of the muscles.

Due to the different directions of the muscular fibers, it forms a grid, which provides strength to the anterior abdominal wall.

Step 25. Close the external oblique aponeurosis with continuous catgut from end to end.

Step 26. Close the skin with mattress sutures of monofilament nonabsorbable material.

Advantages of McBurney's incision¹⁴:

- Except for incising the skin, there is very little bleeding.
- Muscular and tendinous fibers are separated and not incised. This means that after the operation, the fibers fall in place and approximate the edge where they were separated.
- No nerves are usually injured.
- The incision can be enlarged if necessary by continued separation of muscular fibers inferiorly and superiorly as high as the iliac crest.

4. Materials

- Standard laparotomy pack.

5. Anatomical pitfalls

5.1 Embryology

- A transient appendix appears on the embryonic midgut in week five and disappears soon after that.
- The appendix develops in the eighth week of life as a protuberance of the developing cecum. During subsequent development of the cecum the appendix is displaced towards the ileocecal valve. Its final position is on the posteromedial wall of the cecum inferior to the ileocecal valve²⁹.
- Duplication of the appendix is rare as reported by Bluett *et al*¹² and Collins¹¹. Waugh¹³ differentiated between three types: 1) appendix with two separate luminae and a common muscular wall, 2) two completely separated appendices originating

from the cecum, 3) a normal appendix with an atypical one. The current accepted classification is that of Wallbridge²⁷:

- Type A is a single based appendix with duplication of the appendix from a single cecum.
 - Type B anomaly consists of two separated appendices coming from a single cecum.
 - Type B1 is two appendices appearing on either side of the ileocecal valve and in Type B2, a normal appendix appearing from the normal site and a rudimentary appendix from the cecum along the lines of one of the teniae at a varying distance from the first.
 - Type C anomaly has a double cecum, each with its own appendix.
- Embryology of duplication of the appendix¹²: If fusion of the transient appendix-like structure with the normal appendix occurs, a type A duplication develops. Type B1 results from improper differentiation of the cloaca. If the transient appendix-like structure does not disappear, without fusion with the normal appendix, a type B2 duplication develops. Partial twinning of hindgut structures with duplications of other structures as well explains the type C duplication.
 - Triplications of the appendix can occur, as well as an accessory appendix without communication to the cecum, helical appendix³⁹, intramural appendix and an appendix-umbilicus fistula⁴.

5.2 Appendix

- The appendix arises approximately 1.7 cm from the terminal end of the ileum⁸, its base at the union of the teniae. This is at the posteromedial border of the cecum.
- The three teniae converge at the base of the appendix. This is a useful landmark for identification of the appendix during surgery. After joining each other at the base of the appendix, the teniae form a continuous muscular layer on the outside of the appendix⁴. At the orifice of the appendix, muscle fibers branch from the teniae to form a mesh of muscle fibers. The same happens at the apex of the appendix⁴.
- The appendix is not a vestigial organ, but part of the lympho-epithelial tissue in the gastrointestinal tract². It actively participates in the secretion of immunoglobulins, especially IgA. It forms part of the gut-associated lymphoid tissue (GALT) system. Removal of the appendix has however not been associated with any manifestation of immune compromise³⁰.
- Lymphoid tissue is present in the appendix from about 2 weeks after birth. The lymphoid tissue increases throughout puberty and then stays stable for the next decade. After that there is a steady decrease of lymphoid tissue. After 60 years of age there is virtually no lymphoid tissue left and the lumen of the appendix can actually be obliterated.
- The orifice of the appendix can be partially covered by an inconstant mucosal fold,

sometimes referred to as Gerlach's valve⁴.

- Length: Most appendices are 6-9 cm in length. Short forms (5cm) and long forms (35 cm) exist⁷. The luminal diameter is between 1 and 3 mm²⁹.
- Several variations of origin are seen as classified by Treves⁹:
 - Type 1: A fetal type with a funnel-shaped origin. This type is only found in 2-3% of adults.
 - Type 2: The appendix originates from the cecal fundus.
 - Type 3: The appendix originates posteromedially out of the cecum (most common).
 - Type 4: The appendix originates directly beside the ileal orifice.
- The muscular wall of the appendix has horizontal fibers allowing for minimal passive expansion of the lumen.
- Diverticula can be found on the appendix⁴.

5.3 Surface anatomy

- Charles McBurney¹⁴ described the point of maximum tenderness in appendicitis as a finger placed on the anterior abdominal wall, one-third the distance between the anterior iliac spine and the umbilicus.
- Karim *et al*²⁵ states that McBurney's point does not mark the site of the base of the appendix in many patients. They studied 51 barium enemas, and determined the position of the lower pole of the cecum and base of the appendix relative to bony landmarks in the supine position. They found that 70% of the appendices were situated inferior to the horizontal line joining the anterior superior iliac spine on the left and the right. By two lines, the horizontal line between the anterior superior iliac spine and the right midclavicular line, Karim *et al*²⁵ described four quadrants namely the iliac, inguinal, umbilical and pelvic quadrants. He then related the position of the base of the appendix to these quadrants. The base of the appendix was located in the iliac quadrant in 15%, the inguinal quadrant in 11%, the umbilical quadrant in 15% and the pelvic quadrant in 59%.
- The base of the appendix and inferior pole of the cecum lies more inferior and medial than previously thought according to Karim *et al*²⁵. He therefore concludes that an appendix incision should be done in the inguinal and pelvic quadrants. This may however increase the risk of nerve injury as described by Arnbjörnssen³⁵.
- Therefore, careful palpation of the point of maximal tenderness is important prior to surgery.
- Schumpelick *et al*⁴ describes three surface anatomy points for the origin of the

appendix⁴. The origin of the appendix projects either on McBurney's point, Lanz's point (right third point of the interspinal line) or Kümmell's point (right side somewhat below the umbilicus).

5.4 Appendix positions.

- The five typical locations of the tip of the appendix are in order of frequency:
 - 1. Retrocecal- retrocolic either free or fixed,
 - 2. Pelvic or descending,
 - 3. Subcecal, passing downward and to the right,
 - 4. Ileocecal, passing upward and to the left anterior to the ileum,
 - 5. Ileocecal, posterior to the ileum.
- Wakeley⁵ reports the position of the appendix in his study of 10 000 autopsy cases as follows:
 - Retrocecal in the retrocecal recess (65%),
 - Descending pelvic (31%),
 - Transverse retrocecal (2.5%),
 - Ascending paracecal, preileal (1%),
 - Ascending paracecal, postileal (0.5%).
- Buschard *et al*⁴⁰ described the position of the appendix as either anterior or posterior in relation to the cecum. Anterior positions are the preileal, postileal, promontoric (subileal), pelvic and subcecal positions. Posterior positions include the paracecal and retrocecal positions.
- More recently, O'Connor *et al*⁴³ studied the locations of the appendix in vivo on 129 patients. The findings were different from Wakeley's autopsy findings. O'Connor demonstrated that the retrocecal position of the appendix was actually the most common location, but occurred in only 33% of instances. In the other two thirds of cases, the appendix tip projected freely into the peritoneal cavity. There results are: preileal (4%), postileal (8%), subileal (15%), pelvic (19%), subcecal (11%), paracecal (10%), retrocecal (33%).
- According to O'Connor *et al*⁴³, Wakeley⁵ included in the category retrocecal appendices that were in a position just lateral or inferior to the cecum although they were lying free. All these positions could develop as a result of torsion of the appendico-cecal junction during embryological development. Wakeley⁵ proposed that the appendix is carried posterior to the cecum by helicoidal torsion. His reported figure of 65% retrocecal positions is thus higher.
- In an earlier report, Wakeley⁴⁶ reports his intraoperative findings in 120 patients. He found the retrocecal position in 35% of cases. This is similar to the O'Connor *et al*⁴³ data. Maisel⁴⁵ reports a retrocecal position of the appendix in 26.7% of cases in a South African based study.

- The retroceally positioned appendix may be mobile. Buschard *et al*⁴⁰ reported that 40% of the 56.7% retroceally positioned appendices were mobile. The rate of extraperitoneally positioned appendices is therefore lower, and O'Connor *et al*⁴³ reports it to be in the range of 20-35%.
- Knowledge of the position of the tip of the appendix is important for two reasons. Firstly it is important for finding the appendix during surgery, but secondly the different positions also influence the symptoms of appendicitis.
- Specifically the retrocecal position of the appendix requires a more extensive dissection often involving cecal mobilization⁴⁰. However, if the tip of the appendix is free, the dissection is much easier. This is especially the case in laparoscopic techniques that have been suggested for appendectomies.
- The base of the appendix at the site of the confluence of the teniae coli on the base of the cecum is a constant position. However, the position of the tip may vary greatly³⁰. The appendix may be fixed or non-fixed. The appendix in the pelvic position is usually non-fixed.

5.5 Mesentery^{4,8}

- The mesentery of the appendix is derived from the posterior side of the mesentery of the ileum, attaching to the cecum and the proximal appendix. It contains the appendicular artery within its free border.

5.6 Appendicular artery

- The appendicular artery arises from either the ileal branch or a cecal branch of the ileocolic artery. It is usually single but may be double. The artery runs posterior to the terminal ileum and enters the mesoappendix close to the base of the appendix.
- From the main appendicular artery, many small branches supply the appendix along its length⁹. These vessels enter the subserosal space, divide again and run in the muscularis propria into the submucosa to anastomose with the venules²⁸.
- The base of the appendix may be additionally supplied by a small branch or branches of the anterior or posterior cecal artery¹. If the stump of the appendix is insufficiently ligated, these may cause severe bleeding⁷.
- The ileocolic artery is a branch of the superior mesenteric artery, which supplies the midgut, of which the appendix forms part⁴.
- The appendicular artery is a terminal artery. Therefore perfusion of blood cannot be increased, so that ischemic damage may develop¹⁰.
- The anterior cecal artery⁴ runs in the superior ileocecal fold on the ventral side of the

cecum and usually does not reach the appendix.

- The inferior ileocecal fold extends from the antimesenterial border of the terminal ileum and spreads over the ventral side of the appendix. There are no blood vessels in this fold. Therefore it is often referred to as the 'bloodless fold of Treves'.
- The ileocolic artery⁴ runs in the angle between the cecum and the terminal part of the ileum and divides into several branches:
 - Ileal branche supplying the terminal part of the ileum,
 - Anterior cecal artery supplying the anterior aspect of the cecum,
 - Posterior cecal artery supplying the posterior aspect of the cecum,
 - The colic ramus running superiorly (ascending colic ramus) and supplying part of the ascending colon,
 - The appendicular artery running posterior and very rarely anterior to the terminal part of the ileum to the mesentery of the appendix.
- According to Lippert *et al*⁶, the appendicular artery originates in 35% of cases from the ileal branche, in 28% from the division of the ileocolic artery, in 20% from the anterior cecal artery, in 12% from the posterior cecal artery, in 3% from the ileocolic artery of cases and in 2% from the ascending colic ramus.
- The appendicular vein⁴ accompanies the appendicular artery in the mesentery. After joining the cecal veins it becomes the ileocolic vein draining into the superior mesenteric vein, which drains into the portal venous system²⁹.

5.7 Lymphatic drainage^{1, 4}

- Lymph nodes are situated in relation to the arteries supplying the appendix. Nodes are found in relation to the appendicular, ileocolic and superior mesenteric arteries, draining to the celiac nodes and cisterna chyli.
- Lymph vessels of the body and tip of the appendix drain to the posterior ileocolic nodes and the base of the appendix to the anterior ileocolic nodes.
- The amount of lymphoid tissue has a role in the development of acute inflammation of the appendix. The incidence of appendicitis peaks in the second and third decades of life. There is a steady decrease of lymphoid tissue towards the age of 60 years after which virtually no lymphoid tissue is left.

5.8 Lumen

- The luminal diameter is between 1 and 3 mm²⁹.
- Obstruction of the lumen by fecoliths seems to be the main reason for acute appendicitis. Fecoliths are found in 40% of acute appendicitis, 65% of gangrenous appendicitis without rupture and 90% of perforated gangrenous appendicitis⁴.

Collins¹¹ found the presence of fecoliths in a study involving 50 000 cases to be 38.8%. He also found the presence of unusual foreign bodies like metal screws and toothpicks in 1.3% of cases.

- The appendix secretes 2-3 ml of mucous daily. Normal secretion of the appendiceal mucosa continues after occlusion of the appendicular lumen, with resultant rapid distention. This can continue until gangrene and perforation occur. The process may be rapid due to the fact that the appendiceal lumen capacity is only about 0.1 ml³⁰. This leads according to the law of La Place ($T=P \times r/2$, T=wall tension, P= intraluminal pressure, r= radius), to increase of intraluminal pressure due to the appendiceal wall's inability to stretch¹⁵. Even only 0.5 ml of mucous secreted, leads to an increase of pressure of approximately 45mmHg¹⁶. This explains why the appendix can perforate within hours of the onset of appendicitis. Therefore hospitalization is essential in patients with suspected appendicitis.
- Vascular congestion leads to mucosal impairment and further bacterial invasion of deeper layers of the appendix. Infarction occurs in the area with the poorest blood supply (antimesenteric border) with consequent perforation.

5.9 Histology²⁹

- The appendix has the following structure, similar to the colon: serosa, muscularis propria (outer longitudinal and inner circular layer), submucosa, muscularis mucosa and large intestinal mucosa. Lymphoid follicles are found in the submucosa.
- With increasing age, there is increasing fibrosis, which is evident after 40 years of age. Also the amount of lymphoid tissue diminishes.

5.10 Innervation of the appendix

- The appendix is supplied by autonomic nerves. The sympathetic nerves come from the superior mesenteric plexus and the parasympathetic nerves from the vagus nerve.

5.11 Pain during appendicitis⁴

- The dull midline pain is due to distension of the bowel, which stimulates the nerve endings of visceral afferent pain fibers.
- Continued distension leads to occlusion of the capillaries and venules, while arterial inflow continues resulting in vascular congestion. Vagal stimulation due to the distension leads to nausea and vomiting and vague abdominal midline pain due to midgut distribution. Localization of the pain takes place when the inflammatory process has involved the parietal peritoneum, causing the characteristic shift of pain from the umbilical region to the right iliac fossa. The parietal peritoneum in the region of the cecum and appendix is supplied by segmental nerves also supplying the anterior abdominal wall (T12, L1). Localization usually takes place within 4-6 hours.

This is the classical presentation.

- Cutaneous hyperesthesia over the spinal nerves T10, T11 and T12 areas on the right may be present in acute appendicitis. This may be the first presenting sign according to Kozar *et al*³⁰, and is experienced as pain when gently picking up the skin in the area between the index finger and thumb. In very rare cases this can be confused with the early onset of Herpes Zoster of the same nerve roots.
- Cramping pain may occur due to peristalsis, which is stimulated by the distention.
- Due to anatomic variations in the position and dimensions of the appendix, there are variations in the sequence and position of the pain as well.
Kozar *et al*³⁰ gives a few examples:
 - A long appendix with the inflamed tip in the left iliac fossa may cause localized pain the left iliac fossa.
 - A retrocecal appendix may present with back pain or flank pain.
 - A pelvic appendix may present with suprapubic pain.
 - A retroileal appendix may cause testicular pain, thought to be secondary to irritation of the testicular neurovascular bundle.

5.12 Vagal stimulation³⁰

- Vomiting occurs in 75% of patients with appendicitis. Anorexia is a very constant symptom in appendicitis. Both are due to vagal stimulation.
The sequence of symptoms is very important in the diagnosis of appendicitis. 95% of patients first complain of anorexia, followed by abdominal pain and then vomiting. If the vomiting occurs before the abdominal pain, the diagnosis of appendix is probably less high on the differential diagnosis list.

5.13 Examination

- Physical palpation of the abdomen with a tender right iliac fossa over McBurney's point is the principal positive sign in appendicitis. This indicates peritoneal irritation with or without the presence of local rebound tenderness.
- Vital signs are usually normal in the presence of uncomplicated appendicitis. Fever, tachycardia and leucocytosis are due to absorption of bacterial toxins and necrotic tissue.
- Patients feel most comfortable lying supine with the right thigh drawn up to some degree. This position relaxes the peritoneum and provides some relief of pain.
- Muscle resistance starts with voluntary guarding and as peritoneal irritation progresses, involuntary reflex rigidity develops.
- The appendix position also influences the physical signs, for example:

- A retrocecal appendix may have fewer positive signs on the anterior abdominal wall during palpation, and more in the flank region.
- A pelvic appendix may present with no signs on the anterior abdominal wall at all. However the diagnosis is made on rectal examination. As the examining finger pushes against the peritoneum of the rectovesical pouch, pain is experienced locally and in the suprapubic region.
- Rovsing's sign – Pain is experienced in the right iliac fossa, when the left iliac fossa is palpated. This is a sign of peritoneal irritation.
- Psoas sign – This test is done by lying the patient supine on the edge of the bed and then slowly extending the right thigh. This action stretches the iliopsoas muscle and will illicit pain in the presence of appendicitis. The appendix is closely related to the psoas muscle.
- Obturator sign – This test is performed with the patient supine and with the right thigh flexed and internally rotated. This will stretch the obturator internus muscle and discomfort will be felt if the appendix is in close relation to the muscle as it would be in the pelvic position of the appendix.
- A mass in the right iliac fossa may be a periappendiceal abscess or loops of bowel around an inflamed appendix.

5.14 Anterior abdominal muscles²

- The external abdominal oblique muscle is aponeurotic because this muscle loses its muscle fibers below the spino-umbilical line. The internal abdominal oblique and transversus abdominis muscles are muscular at the level of incision. These muscles are split in the direction of their fibres by means of blunt dissection.
- The abdominal muscles are supplied by segmental nerves from T7 to T12 and L1. In the region of the incision during an appendectomy, the T12 and L1 nerves are in possible danger. The nerves run in the neurovascular plane between the internal oblique and transversus abdominis muscles in an inferior and medial direction. The classical McBurney's incision¹⁴ made in a similar direction over McBurney's point is unlikely to injure the nerves.

5.15 Extraperitoneal fat²

- This layer is variable in patients and is seen just before entering the peritoneal cavity.

5.16 Cleavage lines²

- An incision made in the direction of the cleavage lines (Langer's lines) as is the case with a McBurney's incision, tend to result in less scarring and dehiscence than incisions made across these lines.

5.17 X-ray Anatomy³⁰

- A plain X-ray of the abdomen is rarely helpful in the diagnosis of appendicitis. An abnormal gas pattern is often seen but this is a nonspecific finding. Rarely a fecolith may be seen on an X-ray.
- A chest X-ray may be important in excluding right lower lobe pneumonia. Pain may be referred to the right iliac fossa and may present as acute appendicitis.

5.18 Ultrasound anatomy³

- The appendix can be demonstrated by compression ultrasonography. A normal appendix is demonstrated as an easily compressible blind-ending tubular structure originating from the cecum, with an anteroposterior diameter of 5 mm or less⁴⁴. The appendix is compressed between the anterior abdominal wall and the iliopsoas muscle.
- The anteroposterior diameter of the appendix is measured with maximal compression. A positive scan for appendicitis is regarded as a non-compressible appendix with an anteroposterior diameter of 7 mm⁴⁴. Demonstration of a fecolith is diagnostic of appendicitis. These ultrasonographic signs should be interpreted when acute pain is present in the right iliac fossa.
- A retrocecal appendix may be difficult to visualize from the anterior approach. Scanning directly posterior to the cecum via a lateral flank approach is necessary.
- A dilated uterine tube may mimic the appearance of an appendix. The uterine tube does not have as prominent an echogenic submucosal ring as the appendix. A transvaginal ultrasound is necessary to rule out a hydrosalpinx⁴⁴.
- Ultrasound diagnosis of appendicitis has a sensitivity of 78 to 96 percent and specificity of 85 to 98 percent.
- False positive scans can be due to inflammation surrounding the appendix, dilated uterine tubes that are confused with the appendix, inspissated stool that is confused with a fecolith, or an uncompressible appendix due to a thick fatty layer in the anterior abdominal wall in obese patients.
- False negative scans can be due to demarcation of the disease process to the tip of the appendix, a retrocecal appendix, a dilated appendix that is confused with small bowel or a compressible appendix due to perforation.
- Surrounding structures like the pelvic organs should also be evaluated especially if the ultrasound examination fails to diagnose appendicitis.

5.19 CT Anatomy²⁰

- The appendix appears as a thin-walled tubular structure on CT scan and is seldom visualized during routine CT examinations. The reason for this is the variation in the size of the appendix, the presence of surrounding periappendiceal fat and the demonstration of the contrast-filled terminal ileal loops²¹. It is surrounded by mesenteric fat. The diameter of the appendix should not exceed 6 mm. Contrast filling of the appendix is best visualized after rectal administration of contrast. The inflamed appendix appears as either a fluid filled distended structure or a small collapsed tubular structure²¹. Circumferential wall thickening may be observed. Periappendiceal inflammation, fecoliths, appendiceal abscesses and mucocele can also be detected.
Appendicoliths appear as solid ring-like densities on CT.
- Kozar³⁰ reports that CT should be primarily used if an appendiceal abscess is suspected and to help decide whether percutaneous drainage is feasible. It also helps to identify the nature of the abscess, whether the abscess is small, well-localized or complex. Small abscesses may only require intravenous antibiotics, well-localized abscesses may be drained percutaneously and complex ones require surgical drainage.
- CT scanning should not delay operative treatment when clinically indicated.

5.20 Appendicitis in pregnancy³⁰

- The incidence of appendicitis in pregnancy is 1 in 2000 pregnancies. Acute appendicitis is more common in the first trimester.
- The appendix is gradually displaced laterally and superiorly from McBurney's point as the uterus enlarges. At 8 months it may be located as high as the right hypochondrium. This makes the diagnosis of appendicitis problematic.
- Fetal mortality increases markedly in the event of appendix rupture. There should be a high index of suspicion in the cases of abdominal pain during pregnancy.
- Guarding and rebound tenderness are difficult to assess due to the lax abdominal wall.

6. Complications (anatomically relevant)

6.1 Ruptured appendix

- Delayed operative treatment in appendicitis increases the risk of rupture of the appendix. Rupture occurs along the antimesenteric border of the appendix and usually distal to the point of lumen obstruction.
A fever greater than 39 degrees, and white blood cell count of more than

18,000/mm³ is highly suggestive of a ruptured appendix.

- About 16% of patients presenting with a history of appendicitis have a ruptured appendix³⁰. This is approximately 20% in children and as high as 49% in patients over 80 years.
- Mortality rates for the elderly are reported to be 15%.
- Rupture of the appendix gives rise to infection which is usually contained in the right iliac fossa but may spread to cause generalized peritonitis.
- Diagnosis of a ruptured appendix is important for the treatment differs from an unruptured appendix. An initial midline incision is necessary for a pre-operatively diagnosed ruptured appendix. The diagnosis of a ruptured appendix may be difficult and CT may be helpful.

6.2 Peritonitis, intra-abdominal abscesses and septicemia

- These complications usually occur after rupture of the appendix.
- The mortality rate is determined by age and whether the appendix ruptured before surgery.
- Abscess formation is greatly reduced by intravenous antibiotics. Abscesses are more likely to occur in generalized peritonitis and inadequate cleaning of the abdomen before closure. The most common cause is where a devitalized part of the appendix was not removed or where a fecolith was left behind²⁹.
- Abscesses can occur anywhere in the abdomen, but specifically in the following locations:
 - Pelvis. The pelvis is the commonest site for abscess formation²⁹. Patients present with a swinging fever, deep pelvic pain and diarrhea. The abscess can be diagnosed with a rectal or vaginal examination and may be drained via these routes as well.
 - Appendiceal fossa.
 - Recto-uterine space.
 - Subhepatic space.
 - Between loops of intestine.
 - **Subphrenic abscess** – This can be explained by the communication between the paracolic gutter to the right of the ascending colon, the hepatorenal space (right subhepatic space or Morrison's pouch) and the subphrenic space on the right. The right colic flexure has no ligament like the phrenicocolic ligament on the left attaching it to the diaphragm. Therefore there is a direct communication between the mentioned gutters and subphrenic spaces on the right.

- Septicemia may lead to cardiovascular and respiratory failure.

6.3 Inability to locate the appendix

- The appendix may be difficult to find during surgery. It may be overlooked or even congenitally absent. The retrocecal appendix may be difficult to find as it may be hidden in peritoneal folds or be attached to the posterior parietal peritoneum.
- Agenesis of the appendix is extremely rare. Collins studied 50 000 cases, and found four cases of agenesis¹¹.
- The clinical significance of double or triple appendices as classified by Waugh¹³ and Wallbridge²⁷ is that if a patient presents with typical symptoms of appendicitis but had a previous appendectomy, this should be included in the differential diagnosis. Anatomic anomalies of the appendix can make the diagnosis of appendicitis difficult. In cases of a diffuse clinical picture, especially in young and elderly patients, the spectrum of anatomic and embryological anomalies must be kept in mind.
- The location of the appendix has been reported to be very variable. This is usually the case in malrotation or situs inversus and even a thoracic appendiceal position has been reported associated with a diaphragmatic hernia¹⁸.
- The appendix can also be found in the cecal wall beneath the serosa¹⁹, which may necessitate incision of the cecal wall to remove the appendix. If no appendix is found during surgical exploration, a palpable thickening of the cecal wall may be the appendix.
- Izimbergenov²⁶ reports on a subhepatic position of the appendix. Treves⁹ also observed in a study of 100 dissections a position of the tip of the appendix in actual contact with the inferior surface of the liver in 4 cases. In one of the four the tip of the appendix was in direct contact with the gallbladder. Treves⁹ also found an appendix with an extensive mesentery lying across the midline with the tip on the left psoas major muscle.
- Du Toit³¹ reports on a case of situs inversus viscerum where the appendix is situated in the left iliac fossa. Situs inversus viscerum has an incidence of 1 in every 6-8000. Although the viscera are on the opposite side, components of the nervous system are not the other way round. Pain in an acute appendicitis on the left side, is therefore still initially found in the peri-umbilical area and falsely projected to the right iliac fossa, after which the pain will be locally experienced in the left iliac fossa over the peritoneal irritation⁴⁸.
- These positions should be kept in mind during surgical exploration.

6.4 Bacterial contamination of the peritoneal wall

- One study has demonstrated that invagination of the stump of the appendix significantly reduces the incidence of bacterial contamination of the peritoneal cavity¹⁷. Williams however report on 700 appendectomies where the stump was not buried without any adverse effects.

6.5 Wound infection

- Wound infection is regarded as a minor complication and usually occurs in the subcutaneous tissues. Dehiscence of a McBurney's incision is rare. Intravenous antibiotics including an antibiotic with an anaerobic spectrum, significantly reduces this complication.
- Williams *et al*²⁹ points out that this complication can be minimized by a 'no-touch' technique, adequate exposure of the operating field and gentle handling of the anatomical structures.

6.6 Differential diagnosis³⁰

- The differential diagnosis is dependent on a) the anatomical location of the inflamed appendix, b) the stage of the process and c) the age and sex of the patient.
- The differential diagnosis of appendicitis is an anatomical diagnosis in the sense that pathology of surrounding anatomical structures in the abdomen can present almost in the same way as acute appendicitis.
- The preoperative diagnosis of appendicitis should be more or less 85% correct to avoid unnecessary operations. However an accuracy rate of more than 90% should also raise concern, for this means that patients with an atypical presentation will not receive prompt operative intervention.

6.6.1 Acute mesenteric adenitis

- Acute mesenteric adenitis is most commonly confused with appendicitis, especially in children. Usually an upper respiratory infection is present or there is a recent history of such an infection. Pain is more diffuse and not sharply localized. Generalized lymphadenopathy is usually present.

6.6.2 Acute gastroenteritis

- Acute viral gastroenteritis can be differentiated from appendicitis by the presence of acute watery diarrhea, nausea and vomiting. Hyperperistaltic cramps are usually present and localizing pain and signs are absent. The abdomen is relaxed between cramps. Salmonella gastroenteritis may present with acute abdominal pain often localized and associated with rebound tenderness.

6.6.3 Urinary tract infection

- Pyelonephritis on the right may simulate the signs of a retroileal appendicitis. These patients also have chills, costovertebral angle tenderness and pus cells, blood and bacteria in the urine.

6.6.4 Ureteral stone

- The stone may be lodged in the vicinity of the appendix. Usually the pain is referred to the scrotum, labia majora or penis. Hematuria is present and leukocytosis absent. Intravenous pyelography confirms the diagnosis.

6.6.5 Pelvic inflammatory disease

- If confined to the right tube pelvic inflammatory disease presents in a similar way as appendicitis. Nausea and vomiting are not prominent. There is acute tenderness of the cervix on vaginal examination and a purulent vaginal discharge may be present.

6.6.6 Ovulation

- Ovulation may result in the spill of a small amount of blood and fluid from the Graafian follicle. This may cause brief abdominal pain and may be confused with appendicitis especially if ovulation is from the right ovary. History taking of the menstrual cycle will reveal that the pain is present at the midpoint of the menstrual cycle and therefore also referred to as mittelschmerz.

6.6.7 Pleuritis or consolidation of the lower lobe of the right lung

- Pain may be referred to the right iliac fossa and can be confused with appendicitis. It is therefore important in the clinical examination to also evaluate the chest.

6.6.8 Henoch Schönlein purpura

- Abdominal pain is prominent, but is associated with joint pain, purpura and nephritis.

6.6.9 Testicular torsion, acute epididymitis and seminal vesiculitis.

- These conditions may also mimic appendicitis. Seminal vesiculitis can be diagnosed by palpating an enlarged tender seminal vesicle on rectal examination.

6.6.10 Meckel's diverticulitis

- The signs and symptoms are very much the same as acute appendicitis. The operative treatment is the same and can be done through a McBurney's incision.
- A Meckel diverticle²⁴ is found in 2% of people, It usually presents at the age of two

with a brick-red stool because the diverticulum usually contains various types of cells, such as acid-producing cells causing local ulceration and hemorrhaging. The diverticulum occurs 2 feet (60 cm) from the ileocecal valve on the ileum, which is the middle of the midgut. The diverticulum may be 2 inches (5 cm) long. This rule of two's is not necessarily always applicable. The diverticulum is found on the antimesenteric border of the bowel.

6.6.11 Intussusception

- Intussusception usually occurs in children under two years, whereas appendicitis is very uncommon in this age group.

6.6.12 Perforated peptic ulcer

- If the gastroduodenal contents spread to the right iliac fossa it may mimic acute appendicitis. Usually there are epigastric signs as well.

6.6.13 Cecal carcinoma or diverticulitis

- Cecal carcinoma or diverticulitis may be confused with an appendiceal abscess especially in patients older than 50 years.

6.7 Hematuria

- Hematuria may be found in appendicitis due to its close relationship to the right ureter.

6.8 Pyogenic liver abscess³²

- Spread of the infective focus via the venous drainage of the appendix to the portal venous system in the abdomen, may result in liver abscesses. This complication was frequently encountered in the pre-antibiotic era with an incidence of 10-30%.
- Hematogenous spread of infection occurs via the portal venous system. Liver associated abscesses may also develop due to direct spread via the paracolic gutter lateral to the ascending colon to the hepatorenal space and the subphrenic space to the bare area of the liver. It may also be due to an inflamed appendix which is located in the right hypochondrium due to lack of cecal descent or with an unusually long appendix.
- Pylephlebitis or portal pyemia (endophlebitis of the portal venous system) due to appendicitis was also more common in the pre-antibiotic era. This endovascular infection has a high mortality.

6.9 Cecal fistula

A fistula may form due to sloughing of part of the cecum.

6.10 Hemorrhage³³

- The ligation of the appendicular artery may slip and cause serious bleeding either intraperitoneally or intraintestinally.
- Rectal bleeding has also been reported. Sandmarks³⁴ describes a case of a 17-year-old patient who presented with severe rectal bleeding and low Hb 7 days after appendectomy. A second laparotomy revealed that the catgut ligation on the appendix stump slipped off. Bleeding from the appendix stump occurred into the cecum.
- Hessert⁴¹ found that in 5% of cases an arterial branch running from the cecum extramurally to the appendix supplies the base of the appendix. The presence of this artery may increase the risk of postoperative hemorrhage from the appendix stump. Great care should be taken to secure ligation of the blood vessels supplying the base and proximal part of the appendix.

6.11 Femoral nerve injury

- A femoral nerve injury following appendectomy has been reported³⁶. Kourtopoulos³⁶ reports a case where due to an unusual position of the appendix, bleeding from the epigastric vessels was found. Subsequent efforts to stop the bleeding caused the femoral nerve being caught in one of the sutures, with a typical femoral nerve injury involving both sensory and motor functions of the nerve in the thigh.
- The femoral nerve runs in the groove between the iliacus and psoas muscles and underneath the inguinal ligament lateral to the femoral artery.
- Injury to the nerve usually occurs in low abdominal incisions where self-retaining retractors are used.

6.12 Appendicitis following appendectomy³⁷

- Francis³⁷ reports on a case where a patient developed appendicitis after having an appendectomy several years ago. The patient developed acute appendicitis in the appendix stump, which was 1 cm in length. It is therefore important to remove the entire appendix. The appendix should be ligated at the ceco-appendicular junction. The appendix may be bound to the cecum by a peritoneal fold or adhesion. The base of the appendix may also be obscured by inflammation. There are blood vessels supplying the proximal third of the appendix coming from the wall of the cecum. The appendix stump is therefore viable although the appendicular artery was ligated.

Ligation at the ceco-appendicular junction is therefore important to devascularise the proximal appendix.

6.13 Intussusception of the appendiceal stump³⁸

- Ileocolic intussusception is a very rare but potentially fatal complication after appendectomy. Wolfson³⁸ reports on a case where a hemicolectomy was done due to ileocolic intussusception with the appendiceal stump as the leading point of intussusception. The diagnosis is difficult due to the postoperative state.

6.14 Intestinal obstruction

- Intestinal obstruction may develop in the long term due to slowly resolving peritonitis, loculated abscesses and adhesion formation.

6.15 Inguinal hernia

- This late complication rarely occurs in a McBurney incision³⁵. Damage to the segmental nerve supply of the abdominal muscles may eventually lead to the development of hernias.
- Arnbjörnsson³⁵ studied 826 patients with inguinal hernias and found that 43 had previously undergone an appendectomy. A right inguinal hernia developed in 35 of the 43 cases, left inguinal hernia in 6 and a bilateral inguinal hernia in 2 cases. The ratio of right-sided to left-sided inguinal hernias in the post appendectomy patients was 6:1, compared to 2:1 in those patients who did not had a previous appendectomy. This is a significant difference. Gue²² found exactly the same ratio in a retrospective study of 701 patients. The most likely cause is injury to the nerves supplying the abdominal muscles and paralysis of the valve of the internal inguinal ring.
- Lytle⁴² describes the anatomy of the internal inguinal ring: ‘ The internal ring is “U” shaped; composed of thickened transversalis fascia, is suspended by its two pillars, medial and lateral to the posterior aspect of transversus abdominis muscle. The curve of the “U” lies at or just above the lower border of the aponeurosis of the transversus muscle. This aponeurosis forms the floor of the ring and is supported in front by the internal oblique muscle.’ This forms an efficient valve, which closes with increased intra-abdominal pressure. Injury to the nerve supply of or the transversus abdominis muscle itself may damage the valve action of the internal inguinal ring.
- All the muscles in the inguinal region receive their nerve supply from the iliohypogastric and ilioinguinal branches of L1.
- The ilioinguinal nerve emerges about 1.5 inch medial and inferior to the anterior superior iliac spine and is not in particular danger of injury during a McBurney’s incision. However, the iliohypogastric branch is found approximately 2.5 cm (1 inch)

above the ilioinguinal nerve and runs inferiorly and medially in the neurovascular plane between the internal oblique and transversus abdominis muscles. It crosses a line drawn from the umbilicus to the anterior superior iliac spine approximately 5 cm superior to the anterior superior iliac spine.

- A McBurney's incision runs parallel to the nerves. The nerves are in danger if the fibers of the internal oblique are cut. Therefore they should be separated by blunt dissection. The same should be done with the transversus abdominis muscle and posteriorly lying transversalis fascia²².
- Incisions below the level of the anterior superior iliac spine should be avoided. The ilioinguinal and iliohypogastric nerves may be damaged. Arnbjörnsson³⁵ and Gue²² suggest that incision below the horizontal line from the anterior superior iliac spine to the rectus abdominis muscle should be avoided. This is due to the fact that the segmental nerves pierce the anterior abdominal muscles at this level and run in an inferior and medial direction.
- Gue²² states that the higher incidence of inguinal hernia's on the right after appendectomy may be due to protrusion of peritoneum through the incomplete approximation of the transversus abdominis muscle and transversalis fascia. Separate suturing of the transversus abdominis aponeurosis with the transversalis fascia should therefore be performed.
- Injury to the ilioinguinal nerve may lead to paralysis of the conjoint tendon, which may lead to an indirect inguinal hernia.
- Leech *et al*²³ however has shown in a retrospective study including 549 patients, that right inguinal hernias are not associated with appendectomies.²²

6.16 Herpes Zoster

- In very rare cases this can be confused with the early onset of Herpes Zoster of the same nerve roots.

7. References

- ¹ Skandalakis JE, Gray SW, Rowe JR. Anatomical Complications in General Surgery. New York: McGraw-Hill, 1983
- ² Cahill DR, Carmichael SW. Supplemental clinical dissections for freshman gross anatomy. The Anatomical Record 1985;212:218-222
- ³ Ooms HWA, Koumans RKJ, Ho Kang You PJ, Puylaert JBCM. Ultrasonography in the diagnosis of acute appendicitis. Br J Surg 1991;78:315-318
- ⁴ Schumpelick V, Dreuw B, Ophoff K, Prescher A. Appendix and Cecum. Embryology, anatomy and surgical applications. Surgical Clinics of North America 2000;80:295-318
- ⁵ Wakeley CPG. Position of the vermiform appendix as ascertained by an analysis of 10 000 cases. J Anat 1933;67:277

- ⁶ Lippert H, Papst R. Arterial Variations in man. München: JF Bergmann, 1995
- ⁷ Stelzner F. Die Appendizitis. Handbuch der inneren medizin. Berlin: Springer, 1982
- ⁸ Skandalakis JE, Skandalakis PN, Skandalakis LJ. Surgical anatomy and technique. A pocket manual. Springer-Verlag, 1995: 389-399
- ⁹ Treves F. Lectures on the anatomy of the intestinal canal and peritoneum in man. *BMJ* 1885;1:415,527,580
- ¹⁰ Stelzner F, Lierse W: [Etiology of appendicitis] Über der Ursache der Appendicitis. *Langenbecks Arch Chir* 1972;330:273
- ¹¹ Collins DC. A study of 50 000 specimens of the human vermiform appendix. *Surg Gynecol Obstet* 1955;101:437
- ¹² Bluett MK, Halter SA, Salhany KE, et al. Duplication of the appendix, mimicking adenocarcinoma of the colon. *Arch Surg* 1987;122:817
- ¹³ Waugh TR. Appendix vermiformis duplex. *Arch Surg* 1941;42:311
- ¹⁴ McBurney C. The incision made in the abdominal wall in cases of appendicitis. *Ann Surg* 1894;20:38
- ¹⁵ Dreuw B, Truong S, Riesener KP, et al. Stellenwert der Sonographie bei der Diagnostik der Appendizitis. Eine prospektive Studie an 100 Patienten. *Chirurg* 1990;61:880
- ¹⁶ Arnbjornsson E, Bengmark S. Obstruction of the appendix lumen in relation to pathogenesis of acute appendicitis. *Acta Chir Scand* 1983;149:789
- ¹⁷ Arnbjornsson E. Invagination of the appendiceal stump for the reduction of peritoneal bacterial contamination. *Curr Surg* 1985;42:184
- ¹⁸ Fawcitt R. Appendix situated within thorax. *Br J Radiol* 1948;21:523
- ¹⁹ Abramson DJ. Vermiform appendix located within the cecal wall: anomalies and bizarre locations. *Dis Colon Rectum* 1983;26:386
- ²⁰ Curtin KR, Fitzgerald SW, Nemcek AA, Hoff FL Jr, Vogelzang RL. CT diagnosis of acute appendicitis: Imaging findings. *AJR* 1995;164:905-909
- ²¹ Balthazar EJ, Megibow AJ, Gordon RB, Whelan CA, Hulnick D. Computed tomography of the abnormal appendix. *J Comput Assist Tomogr* 1988;12:595-601
- ²² Gue S. Development of right inguinal hernia following appendectomy. *Br J Surg* 1972;59:352-3
- ²³ Leech P, Waddell G, Main RG. The incidence of right inguinal hernia following appendectomy. *Br J Surg* 1972;59:623
- ²⁴ Merrit WH, Rabe MA. Meckel's diverticulum. *Arch Surg* 1950;61:1083-1095
- ²⁵ Karim OM, Boothroyd AE, Wyllie JH. McBurney's point – fact or fiction. *Annals of the Royal College of Surgeons of England*. 1990;72:304-308
- ²⁶ Izimbergenov NI, Forafonova LN, Ostrovskii GK. Acute appendicitis of a subhepatic appendix. *Khiurgiiia (Moskva)* 1984;2(8):32-35
- ²⁷ Wallbridge PH. Double appendix. *Br J Surg* 1963;50:346-347
- ²⁸ Hashimoto S, Ogata T. Blood vascular organization of the human appendix: a scanning electron microscopic study of corrosion casts. *Tohoku Journal of Experimental Medicine* 1998;154:271-283
- ²⁹ Williams RA, Myers P. Pathology of the appendix. London: Chapman and Hall Medical, 1994: 9-29
- ³⁰ Kozar RA, Roslyn JJ The Appendix. In: Principles of Surgery, 4th edition. SI Schwartz, GT Shires, Spencer FC, Storer, eds. New York: McGrawHill Book Co. 1999: 1383-1394

- ³¹ Du Toit DF, Greeff M. Acute abdomen in patient with situs inversus. A case report. *S Afr Med J* 1986;69:201-202
- ³² Leigh PGA, Saron IJ. Pyogenic liver abscess following appendicitis. *S Afr J Surg* 1971;9:147-153
- ³³ Vo N, Hall FM. Severe post-appendectomy bleeding. *Am Surg* 1983;49:560-562
- ³⁴ Sandsmark M. Serious delayed rectal hemorrhage following uncomplicated appendectomy. *Acta Chir Scand* 1977;143:385-386
- ³⁵ Arnbjörnssen E. Development of right inguinal hernia after appendectomy. *Am J Surg* 1982;143:174-175
- ³⁶ Kourtópoulos H. Femoral nerve injury following appendectomy. *J Neurosurg* 1982;57:714-715
- ³⁷ Francis DMA. Appendicitis following appendectomy. *J R Coll Surg Edinb* 1984;29:61-62
- ³⁸ Wolfson S, Shachor D, Freund U. Ileocolic intussusception in an adult: a post-operative complication of appendicitis. *Dis Colon Rectum* 1984;27:265-266
- ³⁹ Mikat DM, Mikat KW. Appendix helicus: A unique anomaly of the vermiform appendix. *Gastrolenterology* 1976;71:303
- ⁴⁰ Buschard K, Kjaeldgaard A. Investigation and analysis of the position, fixation, length and embryology of the vermiform appendix. *Acta Chir Scand* 1973;139:293-298
- ⁴¹ Hessert W. Hemorrhage from the stump following appendectomy. *JAMA* 1906;47:2009-2011
- ⁴² Lytle WJ. The deep inguinal ring. development, function and repair. *Br J Surg* 1970;57:531-6
- ⁴³ O'Connor CE, Reed WP. In Vivo location of the human vermiform appendix. *Clin Anat* 1994;7:139-142
- ⁴⁴ Jeffrey RB, Jain KA, Nghiem HV. Sonographic diagnosis of acute appendicitis: Interpretive pitfalls. *Am J Roentgenol* 1994;162:55
- ⁴⁵ Maisel H. The position of the human vermiform appendix in fetal and adult age groups. *Anat Rec* 1960;136:385-391
- ⁴⁶ Wakeley CPG. Some notes on 120 cases of acute appendicitis operated on at the Royal Naval Hospital at South Queensberry. *Lancet* 1918; ii:1071-1076
- ⁴⁷ Personal communication, Mr T Welsh, Fellow of Queens College, Cambridge, Sept 2001
- ⁴⁸ Owen-Smith MS. Acute left-sided appendicitis. *Br J Surg* 1969; 56:233-234

4.4.3.3 Ectopic pregnancy surgery (Salpingectomy, Salpingo-oophorectomy)

1. Indications	305
2. Contraindications	305
3. Step by step procedure	305
4. Materials	307
5. Anatomical pitfalls	308
6. Complications (anatomically relevant)	318
7. References	320

1. Indications

- Ruptured ectopic pregnancy.

Settings where high technology equipment is not available, patients with ectopic pregnancies often present in a hemodynamically unstable condition with a low hematocrit.

- Incidence: In parts of Africa, one in every 40 pregnancies may be tubal¹⁰.

2. Contraindications

- An oophorectomy should be avoided unless the blood supply to the ovary has been seriously compromised¹.

3. Step by step procedure

Surgical treatment of ectopic pregnancies can be classified as either conservative or as an emergency lifesaving procedure in the case of a ruptured ectopic pregnancy.

- Conservative treatment involves the extraction of the ectopic pregnancy with as little damage to the uterine tubes as possible. Conservative treatment involves laparoscopic techniques of performing a linear salpingostomy and extraction of the ectopic pregnancy or salpingectomy³. Other treatment modalities include a linear salpingotomy, segmental excision and fimbrial expression as well as medical treatment with methotrexate⁹.
- The vast majority of ectopic pregnancies in first world countries are currently, with the aid of advanced diagnostic modalities like transvaginal ultrasound and laparoscopy, diagnosed as unruptured ectopic pregnancies⁶. Therefore, various conservative and nonsurgical modes of management are available. This means that the uterine tube is kept intact.
- Nonsurgical management involves the systemic administration of drugs, which stop

the growth of trophoblastic cells. These drugs can also be administered via laparoscopic or ultrasonographical route directly into the ectopic pregnancy⁶.

- Conservative treatment of ectopic pregnancies, require a hemodynamically stable patient, an unruptured uterine tube, an accessible tube and the desire for future fertility⁷. Hankins *et al*¹⁵ also adds the presence of an ectopic pregnancy in the ampulla with a size of less than 5 cm and an easily accessible route without extensive adhesions.
- This form of treatment is not in the scope of this paper, which deals with the emergency surgical treatment of a ruptured ectopic pregnancy. The aim in hemodynamically unstable patients is to control the bleeding site as soon as possible¹. This most often needs a salpingectomy with or without oophorectomy. During rupture of an ectopic pregnancy, the vasculature of the tube is disrupted and can bleed vigorously.

Salpingectomy

Step 1. Ensure that the patient is hemodynamically stable by having two high flow peripheral lines in place and blood either administered or on standby.

Step 2. Perform a standard lower abdominal laparotomy. A Phannenstiell incision can be performed, but usually takes more time to perform. In an emergency situation it is better to perform a vertical midline incision. This also allows alternative surgical procedures that may be necessary¹.

Step 3. Identify and then elevate the affected uterine tube with an Allis or Babcock clamp.

Step 4. Inspect the other uterine tube and ovary and make sure they are normal. If not, a special effort should be made to spare ovarian tissue on the affected side.

Step 5. Grasp the mesosalpinx with two clamps starting from the fimbrial end and advancing to the base of the uterine tube at the cornu. Avoid the tubal pregnancy. Cut between the clamps. A cautery may also be used, which has the advantage of sealing the small vessels. Do not perform a cornual resection. The advantage of performing a cornual resection is that it reduces the risk of a subsequent ectopic pregnancy implant. However, the disadvantage is that it weakens the myometrial wall and may lead to a uterine rupture in a subsequent pregnancy.

Step 6. Ligate the pedicles with 2.0-delayed absorbable suture.

Step 7. Clamp the tube at the intramural portion. After cutting the tube use a figure eight suture to close.

Step 8. In the case of an intramural pregnancy, a corneal wedge resection needs to be done. An incision is made in the cornu and a small wedge of tissue is removed with the tube at the base of the incision. The round ligament may be used to cover the surgical site and support the uterus.

Salpingo-oophorectomy

An ipsilateral oophorectomy is sometimes necessary. The decision to perform an oophorectomy should be reserved for those patients where the blood supply to the ovary has also been seriously affected¹. Attempts are currently made to preserve as much ovarian tissue as possible for future fertilization techniques¹⁵.

Step 1. Perform a standard lower abdominal laparotomy.

Step 2. Grasp the uterine tube and the ligament of the ovary with a clamp.

Step 3. Open the peritoneum (broad ligament) lateral to the ovary and uterine tube as well as the suspensory ligament of the ovary. Extend the incision superiorly and inferiorly. Take care to avoid damaging the ureter.

Step 4. Identify the ureter. Check the position of the ureter closely with all further clamping and suturing.

Step 5. Seek an avascular area in the broad ligament with the finger and create a large enough hole to place the clamps.

Step 6. Clamp the suspensory ligament of the ovary with two clamps and incise through the ligament. Ligate the ligament with a free tie and then with a suture ligature placed distally to the free tie. Use delayed absorbable suturing material. Make sure the ureter is away from the structures.

Step 7. Place a curved clamp adjacent to the uterus on the uterine tube and the ligament of the ovary. Excise the specimen.

Step 8. Ligate with a free tie followed by a suture ligature distal to the free tie.

Step 9. Close the peritoneum with continuous suturing of delayed absorbable suture. Take care to avoid the ureter. The two pedicles can be buried in the broad ligament.

4. Materials

- Laparotomy tray
- Equipment for blood transfusion and possible autotransfusion

5. Anatomical pitfalls

5.1 Possible locations of an ectopic pregnancy

- Ectopic pregnancy refers to all places apart from the normal place for development of the pregnancy (έκτοπος = out of place). It therefore includes all sites of implantation outside the uterus and the abnormal sites of implantation inside the uterus like the cervix and corner of the uterus or so-called angular pregnancy.
- The following sites for ectopic pregnancy occur in order of frequency:
 - Ampulla or infundibulum
 - Isthmus
 - Interstitial portion of the uterine tube
 - Peritoneum of the broad ligament, bowel, omentum, mesentery (primary abdominal pregnancy)
 - Ovary
 - Cervix
- Jarcho¹¹ documented the frequency of ectopic pregnancies according to the site of implantation in over a 1000 cases:

○ Ampulla and infundibulum:	65.5%
○ Isthmus	25.0%
○ Interstitial portion of the uterine tube	4.2%
○ Abdominal	1.6%
○ Entire tube with or without involvement of the ovary	2.3%
○ Ovary	0.5%
○ Broad ligament	0.5%
○ Cornu	0.3%
○ Rudimentary horn	0.1%
- Niles *et al*²⁶ reports that over 50% of cases involved the distal third of the uterine tube.
- More recently Hankins *et al*¹⁵ reports that 95% of ectopic pregnancies implant in the uterine tube (91% in the ampulla and 4% in the isthmus), 2.5% occur in the cornu of the uterus and 2.5% in other locations like the ovary (0.5%), cervix (0.1%) and abdomen (0.03%).

5.2 Uterine tube

- The uterine tube has the following parts: Ampulla, infundibulum, isthmus and cornu. An ectopic pregnancy may be found in any of these sites.
- The most common site for a tubal pregnancy is the ampulla of the uterine tube⁴.

Approximately 65.5 - 85% of tubal pregnancies attach to the ampullary region of the uterine tube, and 15 - 25% attach to the isthmus (proximal portion)^{7 11}. The ectopic pregnancy is located in the lumen of the uterine tube, within the wall of the tube or in both⁴.

- The left and right uterine tubes are involved with equal frequency¹⁰.

5.2.1 Ampulla

- The ovum attaches to the columnar epithelium of the ampulla of the uterine tube and affects the muscular tissue, connective tissue and blood vessels. The blood vessel walls are eroded by the trophoblast, similar to the intervillous space formation in the uterus. There is no support from muscles or deciduas as is the case in the uterus. The ectopic pregnancy can therefore easily rupture. It can also be aborted or in very rare cases develop in later months. Tubal abortion means that the ectopic pregnancy is expelled from the uterine tube leaving a damaged tube behind.
- Rupture or perforation of the ampulla of the uterine tube occurs as a rule between week 6 and 10 from the last menstrual period (LMP).
- Rupture may take place into the peritoneal cavity or extraperitoneally into the layers of the broad ligament. Intraperitoneal rupture is more common and bleeding is more serious. With extraperitoneal rupture the bleeding is limited by the layers of the broad ligament. Myerscough¹⁰ however describes a case of severe bleeding of an extraperitoneally ruptured ectopic pregnancy with blood spreading to the level of the umbilicus.
- A large quantity of blood can be lost into the peritoneal cavity in a short time, with a patient collapsing.
- Myerscough¹⁰ however reports that the rupture of the tubal wall is a gradual erosion with recurrent episodes of bleeding and possible syncope as well as lower abdominal pain.

5.2.2 Isthmus

- An ectopic pregnancy in the isthmus of the uterine tube usually perforates early between the second or third week. It may occur before a menstrual period is missed.
- The isthmus part of the tube is less distensible and the muscular wall less developed. Therefore rupture occurs early with sudden collapse and shock.

5.2.3 Interstitial part of the uterine tube (cornual pregnancy)

- Ectopic pregnancies rarely occur in the interstitial part of the uterine tube.

Myerscough¹⁰ reports one case in a series of more than 200 ectopic pregnancies. The gestational sac may extend to the uterine cavity or into the tube.

- Rupture may occur into the uterus but more commonly into the peritoneal cavity. It is accompanied by vigorous bleeding. This may occur on a later stage in the second trimester. It closely resembles an angular pregnancy or a pregnancy in a rudimentary horn.
- The interstitial part of the uterine tube is 1cm in length and is surrounded by myometrium.
- There is more extensive trophoblastic invasion, with increased vascularity. The diagnosis is often delayed and has a higher maternal morbidity and mortality¹⁵.
- Excision of these ectopic pregnancies often necessitates the resection of a portion of the myometrium as well.

5.2.4 Ovarian pregnancy

- True ovarian pregnancies have been reported¹⁰. Rupture occurs at a relatively early date although full term ovarian pregnancies are described. Spiegleberg¹⁷ defined the ovarian pregnancy according to the following criteria:
 - 1) The uterine tube and fimbriae should be intact on the affected side,
 - 2) The gestational sac should be located on the ovary,
 - 3) The ovary should be connected to the uterus by the ligament of the ovary and
 - 4) Ovarian tissue should be found in the wall of the gestational sac.

5.2.5 Abdominal pregnancy

- Primary attachment of the ovum in the peritoneal cavity is rare and abdominal pregnancies are usually due to a pregnancy being aborted or ruptured from the uterine tube and subsequent development in the peritoneal cavity.
- After rupture the ovum usually dies, but may nestle itself in the abdomen in surrounding structures like the omentum and mesenteries and continue to grow as an abdominal pregnancy.
- Iffy¹³ describes a case of primary implantation in the rectouterine pouch.
- Healy¹⁴ describes a case of primary abdominal pregnancy with the placenta attaching to the cecum.
- Hosking¹² describes a case where the placenta stayed in the tube, the cord ran through the ostium with an abdominal pregnancy reaching 2.3 kg, but the infant died soon after delivery.

- An abdominal pregnancy may also develop between the layers of the broad ligament. As the pregnancy grows the layers of the broad ligament are separated and the peritoneum of the bladder and rectum is dissected by the growing pregnancy and as it develops it forms adhesion with surrounding structures¹⁰.

5.2.6 Heterotopic pregnancies

- A heterotopic pregnancy refers to the simultaneous coexistence of an intrauterine and extrauterine pregnancy. The incidence is reported to be 1 in every 30 000 pregnancies¹⁵.

5.3 Histology

- An ectopic pregnancy may be located within the wall of the uterine tube, especially in the ampullary region of the uterine tube. The pregnancy therefore develops extraluminally². Senterman *et al*¹⁶ however reports on ampullary pregnancies being intraluminal in 56% of cases, extraluminal in 7% and both extra- and intraluminal in 37% of cases.
- In the isthmic region of the uterine tube, ectopic pregnancies are usually located within the lumen.
- In a histopathological study, Pauerstein⁴ showed that in 25 consecutive cases, the pattern of spread of the trophoblast and hemorrhage was intraluminal, extraluminal or both of the two. Maternal blood vessels are invaded by the trophoblast soon after implantation. This results in hemorrhage in the uterine tube, often leaking out of the abdominal ostium causing a great deal of destruction of maternal tissues.
- An intraluminal trophoblast sometimes leaves the entire epithelial lining intact, eroding the endosalpinx or persists as discontinuous islands along the periphery of the dilated tubal lumen.
- Extraluminal proliferation of the trophoblast occurs between the layers of the wall of the uterine tube. Initially implantation occurs in the lumen, which is soon followed by penetration into the lamina propria and muscularis.
- The invading trophoblast usually simulates the same responses of the trophoblast invading the decidua of the endometrium². After destroying the epithelium, the trophoblast invades the muscularis. The muscularis usually restricts the growth of the trophoblast up to a point where rupture occurs.

5.4 Mechanism of rupture

- The mucosal layer is usually destroyed and may only involve a small portion of the circumference of the mucosa. Blood vessels in the lamina propria and subserosa are

invaded by the trophoblast cells. The resulting hemorrhage into the lumen and uterine tube wall causes severe damage to the uterine tube.

- The muscularis is usually stretched until only a few fibers of muscle and serosa are left before rupture occurs. Distension of the tube is usually primarily due to an accumulation of intraluminal blood and secondarily due to the expanding pregnancy¹⁶.
- The muscularis is destroyed in more than half of the cases.
- Senterman *et al*¹⁶ reports that the disruption of the tubal wall is usually less severe in an ampullary pregnancy compared to an isthmic pregnancy.
- Timonen *et al*²⁵ found that ruptured tubal pregnancy was more frequent than unruptured tubal pregnancy in older age groups, possibly because of lowered elasticity of the tissues. They may also postpone seeking medical help, because they may have experienced various kinds of abdominal pains before.

5.5 Mechanism of oval pick-up⁴

- The fimbriae of the uterine tube sweep across the surface of the ipsilateral ovary during ovulation. The ovum has a sticky cumulus mass, which combined with the dense fimbrial network advances the ovum into the infundibulum of the uterine tube. The ovum is therefore picked up from the ovarian surface. This mechanism is so effective, that the ovum can also be picked up from as far down as the rectouterine pouch.

5.6 Ectopic pregnancy - mechanism

- Underlying salpingitis affects the transport of the fertilized ovum through the tube to the uterine cavity and is said to be the most significant risk factor for ectopic pregnancies due to scarring of the uterine tubes. This pelvic infection often involves *Chlamydia* and *Neisseria Gonorrhoea*. Niles *et al*²⁶ however has demonstrated in a histopathological study including 436 cases of ectopic pregnancy, that the histological diagnosis of chronic inflammatory disease was present in only 40% of the cases. Apart from structural defects, he postulates that there may also be a functional disturbance of the uterine tube responsible for ectopic pregnancy.
- Another possible mechanism is delayed oval pick up, where fertilization and early stages of pre-implantation development has already occurred. The fertilized ovum therefore implants in the ampullary region of the uterine tube.
- Another theory by McElin *et al*⁵ holds that ectopic pregnancy is due to delayed ovulation and fertilization. This fails to suppress menstruation, which flushes the fertilized oocyte from the uterine cavity into the uterine tubes.

- The following factors increase the incidence of ectopic pregnancies¹⁵:
 - o Pelvic inflammatory disease.
 - o Tubal sterilization.
 - o Tubal surgery like salpingostomy.
 - o Assisted reproductive technologies.
 - o Use of an intra uterine contraceptive device (IUCD).
 - o Diethylstilbestrol exposure.
 - o Use of low dose pregestational agents.
 - o Improvements in diagnostic techniques.

5.7 Diagnosis

5.7.1 History and physical examination

- The classic triad of an ectopic pregnancy is: Pain, vaginal bleeding and a palpable adnexal mass after missed menses. After rupture, the patient usually presents in shock.
- The onset of symptoms ranged from one to 27 weeks (counted from the last normal menstruation) in Dorfman *et al's* study⁸. Half of women developed symptoms within eight menstrual weeks and by 12 weeks 75% experienced symptoms related to the ectopic pregnancy.

- **Pain**⁷

Abdominal pain occurs in 85-100% of women with an ectopic pregnancy. The pain is caused by peritoneal stretching of the expanding uterine tube or from blood in the peritoneal cavity due to rupture or leakage from the uterine tube.

- **Vaginal bleeding**⁷

After pain, vaginal bleeding is the most common symptom, occurring in 60% of women. Bleeding is dark and continuous and is caused by insufficient hormonal support of the endometrial deciduas and consequent shedding.

- **Adnexal mass**²²

This mass can be palpated by vaginal or bimanual palpation. It can be difficult due to patient discomfort. The cervix is extremely tender on examination. There may be some tender resistance in the rectouterine pouch (Pouch of Douglas). With localized bleeding, there may be an irregular swelling in the adnexa.

- **Shock**¹⁵

Less than 5 percent of women with an ectopic pregnancy are reported to present with hypovolemic shock due to intraperitoneal blood loss. This is the situation in a first

world country.

- **Abdominal signs**

More typical is the presentation with abdominal pain, guarding and rebound tenderness in the suprapubic region or one or both of the iliac fossae due to blood irritating the peritoneum.

5.7.2 Biochemical tests

- New immunoradiometric assays can diagnose the presence of human chorionic gonadotrophin (HCG) as early as 1 week before expected menses²⁴.
- Kadar *et al*⁹ reports that β HCG levels double every 1.98 days in normal early intrauterine pregnancies. An increase of less than 66% in 2 days (48 hours) is predictive of an ectopic pregnancy.
- Low progesterone levels are also associated with ectopic pregnancy.

5.7.3 Culdocentesis (Culpotomy)

- A culdocentesis is done to obtain a specimen of possible fluid, pus or blood from the rectouterine pouch via the posterior fornix of the vagina.
- This procedure is especially valuable in the presence of a ruptured ectopic pregnancy.
- Culdocentesis is indicated in a patient with a possible ectopic pregnancy where sophisticated diagnostic modalities such as sensitive diagnostic assays and ultrasound are not available or may cause considerable delay before obtained¹⁸.
- Non-clotting blood obtained from a culdocentesis with a positive pregnancy test is 99 percent accurate for ectopic pregnancy and surgical treatment can commence¹⁸.
- A positive culdocentesis is not necessarily associated with a ruptured ectopic pregnancy. Romero *et al*¹⁸ found 62% of patients with a positive culdocentesis but unruptured ectopic pregnancy with slow and intermittent bleeding.
- The differential diagnosis of a ruptured ovarian cyst, ruptured endometrioma or bleeding from elsewhere should be considered. A negative culdocentesis does not rule out an ectopic pregnancy.
- Hematocrit determinations on culdocentesis fluid can differentiate between an ectopic pregnancy and a ruptured ovarian cyst. A hematocrit level of above 12 to 15% indicates an ectopic pregnancy²⁴.

- A negative culdocentesis does not rule out a hemoperitoneum. A hemoperitoneum may also present without the traditional signs of peritonitis during physical examination. Romero¹⁸ therefore argues that a culdocentesis should not be restricted to patients with physical signs of peritoneal irritation.
- **Anatomy of culdocentesis**
 - The vagina is approximately 9 cm long in an adult female.
 - The posterior vaginal wall is related from superior to inferior by the peritoneum of the rectouterine pouch, the rectum, anal canal and perineal body.
 - The upper 2 cm of the posterior wall of the vagina is related to the rectouterine pouch and is less than 5mm thick in this region.
 - The superior part of the vagina is supplied by branches of the uterine and vaginal arteries, which are both from the internal iliac artery.
 - The rectouterine pouch is formed by reflections of peritoneum and separates the rectum from the uterus and superior part of the vagina.
 - Free fluid can accumulate in the rectouterine pouch in both the upright and supine positions.
 - The pouch may contain small bowel and usually a small amount of peritoneal fluid.
- Contraindications for culdocentesis include an uncooperative patient, a pelvic mass (tubo-ovarian abscesses, appendiceal abscesses, pelvic kidneys), a non-mobile retroverted uterus and coagulopathies.
- Large masses in the rectouterine pouch should be excluded by careful bimanual examination.
- **Step by step procedure**
 - **Step 1.** Perform a careful bimanual examination
 - **Step 2.** Insert a vaginal speculum and open it widely
 - **Step 3.** Grasp the posterior lip of the cervix with the uterine cervical tenaculum. Stabilize the posterior vaginal wall by elevating the cervix
 - **Step 4.** Swab the posterior part of the vaginal wall with a surgical preparation
 - **Step 5.** Administer local anesthesia

- o **Step 6.** Attach a spinal needle to a 20ml syringe
- o **Step 7.** Advance the needle parallel to the posterior blade of the speculum.
- o **Step 8.** Penetrate the vaginal wall 1-1.5 cm posterior to the posterior border of the cervix in the midline. Penetrate 2 - 2,5cm²⁸.
- o **Step 9.** Aspirate while the needle is gradually withdrawn.
- **Complications of culdocentesis include:**
 - o Rupture of an unsuspected tubo-ovarian abscess
 - o Perforation of bowel (not usually associated with high morbidity)
 - o Puncture of the uterine wall
 - o Perforation of a pelvic kidney
 - o Bleeding from the puncture site, especially in the presence of clotting disorders.

5.7.4 Ultrasound anatomy

- Ultrasonographic findings include the absence of a gestational sac in the uterine cavity with endometrial reaction and a mass in one of the adnexae or a demonstration of a gestational sac outside the uterine cavity.
- High resolution vaginal ultrasonography and sensitive assays of β HCG (Human chorionic gonadotrophin) has made early detection of ectopic pregnancies possible and subsequently various conservative techniques to surgically manage ectopic pregnancies without removing the uterine tube and ipsilateral ovary.
- Kadar *et al*⁹ has shown that a gestational sac can be visualized by transabdominal ultrasonography with a concentration of HCG greater than 6500 mIU/ml⁹ and 1200 to 1500 mIU/ml when using a transvaginal probe²³. The absence of a gestational sac with a positive HCG test above this concentration indicates an ectopic pregnancy. Presence of the gestational sac indicates an intrauterine pregnancy. The absence of a gestational sac with HCG levels below this concentration has diagnostic value.
- Transvaginal sonography can however visualize the gestational sac at lower HCG levels and see the adnexal structures with better resolution. This is because the probe is closer in proximity to the pelvic organs.
An intrauterine gestational sac can first be seen with a transvaginal ultrasound at 5 weeks gestation¹⁵.
- Fleischer *et al*¹⁹ reports on the ultrasound findings in 47 women with ectopic pregnancy. This is presented in a table modified by Hankins *et al*¹⁵:

Ultrasonic findings	%
Uterus	
Thickened endometrium	43
Pseudogestational sac	15
Adnexal structures	
Tubal ring	49
With living embryo	21
With embryo and yolk sac	8
With dead embryo	4
With yolk sac	6
Without embryo and yolk sac	15
Corpus luteum	34
Nonspecific adnexal mass	28
Dilated tube	19
Peritoneal cavity	
Clear fluid	47
Particulate fluid	28

The tubal ring produced by the ectopic pregnancy in the uterine tube, represents an unruptured uterine tube.

5.7.5 Diagnostic laparoscopy¹⁵

Laparoscopy provides a direct visual assessment instrument of the pelvic organs and ectopic pregnancy. Surgical removal of most uncomplicated ectopic pregnancies can be done via this route.

5.7.6 Duplex Doppler techniques

Vascular patterns in the adnexae can be visualized with color flow Doppler and can be seen on the conventional B-mode at the same time. Trophoblastic flow gives a high velocity and low impedance signal. If this pattern is seen separate from the uterus and ovary, it suggests trophoblastic flow of an ectopic pregnancy¹⁵. Pellerito²⁰ reports a sensitivity of 95% for diagnosing an ectopic pregnancy with color flow imaging.

5.8 Differential diagnosis²²:

- Pyosalpinx
- Hematosalpinx
- Retroverted gravid uterus
- Early stage of uterine abortion
- Acute appendicitis
- Gastrointestinal disorders

- Urinary tract infection
- Intrauterine pregnancy

5.9 Uterus¹⁰

- The uterus may be displaced anteriorly, posteriorly or laterally due to the ectopic pregnancy in the uterine tube. The uterus also changes in size, shape and consistency.

5.10 Multiple ectopic pregnancies

Fujii *et al*²⁷ reports a case of a rare unilateral tubal quadruplet pregnancy. Unilateral twin and triplet pregnancies are rare as well. The cause of these multiple ectopic pregnancies are thought to be the same as for ectopic pregnancies, being pelvic inflammatory disease, congenital abnormalities, operative trauma and tumors.

6. Complications (anatomically relevant)

6.1 Delayed or misdiagnosis

- Delay or misdiagnosis by clinicians contributed up to 53% of cases of maternal death related to ectopic pregnancy in Dorfman *et al*'s study⁸. In an additional 5% of cases, the diagnosis was made without prompt enough intervention. Eight percent of maternal deaths were associated with both clinician and patient delay. Patient delay is usually due to the mild nature of symptoms, which the patient regards as unimportant.
- The diagnosis of ectopic pregnancy was often confused with gastrointestinal disorders (25%), intrauterine pregnancy (18%), pelvic inflammatory disease (14%), psychiatric disorders (9%), spontaneous abortion (9%), complications of induced abortion (7%) and urinary tract infection (7%)⁸.

6.2 Maternal mortality

6.2.1 Acute hemorrhage

- Ruptured ectopic pregnancy is a leading cause of maternal death in the USA. In a study of 86 deaths from 102 100 patients with ectopic pregnancies, 85% of the cases died due to acute hemorrhage⁸. About 70% of those who died from hemorrhage did not have any surgery for ectopic pregnancy. It is clear that early intervention is crucial.
- Most women (75%) died within 12 weeks gestational age of the pregnancy. This shows that most ectopic pregnancy deaths are seen in the first trimester. Ectopic pregnancy deaths seen after 12 weeks were mostly in interstitial, cornual or abdominal locations of the ectopic pregnancy.

- Of all maternal deaths related to ectopic pregnancy, 78% occurred within the fallopian tube distal to the uterine insertion, whereas 22% were situated in the interstitial, cornual or abdominal locations. The implantation site is an important risk factor. Although interstitial, cornual and nontubal implantations are rarely found¹¹, they accounted for 20% of maternal deaths in Dorfman *et al*'s study⁸. They are therefore two to five times more at risk compared to ectopic pregnancies distal to the cornual junction. The diagnosis is more difficult and due to their increased size and vascularity they present as an extremely dangerous clinical situation when ruptured.
- Abdominal and interstitial implantations were more likely in the same study⁸ to become symptomatic later in pregnancy when compared to more distal locations of ectopic pregnancies.
- Dorfman *et al*⁸ concludes that timelier diagnosis and treatment by health professionals might have prevented half of the deaths.

6.2.2 Infection

- Dorfman *et al*⁸ reports in his study that infection was after hemorrhage the second most common cause of death with an incidence of 5% leading to maternal mortality.

6.2.3 Anesthesia related deaths

- Dorfman *et al*⁸ reports that anesthesia related complications were the third leading cause of death in ectopic pregnancies with an incidence of 2%.

6.2.4 Other

- Other causes of death were pulmonary edema, transfusion reaction with cardiac and renal failure, and air embolism due to auto-transfuser malfunction and pulmonary embolism.

6.3 Fertility

- Dubuisson²¹ reported on the fertility of 125 women who had a unilateral salpingectomy. Of those with a normal contralateral uterine tube, 50% had a normal pregnancy and 20% a repeat ectopic pregnancy in the contralateral tube. Of those with an abnormal contralateral uterine tube, a quarter had a normal pregnancy or repeat ectopic pregnancy.
- Timonen *et al*²⁵ reports on 1085 patients treated for ectopic pregnancy. They found that of those treated with radical surgical procedures (77.5%), 49.3 % became pregnant again and 30.4% had normal term pregnancies.

7. References

- ¹ Diamond MP, DeCherney AH. Surgical techniques in the management of ectopic pregnancy. *Clin Obstet and Gynecol* 1987; 30:200-209
- ² Budowick M, Johnson TR Jr, Genadry R, Parmley TH, Woodruff JD. The histopathology of the developing tubal ectopic pregnancy. *Fertil Steril* 1980; 34:169
- ³ Aharoni A, Guyot B, Salat-Baroux J. Operative laparoscopy for ectopic pregnancy: how experienced should the surgeon be? *Human Reproduction* 1993;8:2227-2230
- ⁴ Pauerstein CJ, Croxatto HB, Eddy CA, Ramzy I, Walters MD. Anatomy and pathology of tubal pregnancy. *Obstet Gynecol* 1986; 67: 301-308
- ⁵ McElin TW, Iffy L. Ectopic gestation: A consideration of new and controversial issues relating to pathogenesis and management. *Obstet Gynecol Ann* 1976; 5:241
- ⁶ Pansky M, Golan A, Bukovsky I, Caspi E. Nonsurgical management of tubal pregnancy. Necessity in view of the changing clinical appearance. *Am J Obstet Gynecol* 1991; 164:888-95
- ⁷ Cowan BD, Morrison JC. Management of tubal pregnancy. In: Plauche WC, Morrison JC, O'Sullivan MJ. *Surgical Obstetrics*. Philadelphia: WB Saunders Company, 1992: 419
- ⁸ Dorfman SF, Grimes DA, Cates W Jr et al. Ectopic pregnancy mortality, United States, 1979 to 1980: Clinical aspects. *Obstet Gynecol* 1984; 64:386
- ⁹ Kadar N, DeVore G, Romero R. Discriminatory hCG zone: Its use in the sonographic evaluation for ectopic pregnancy. *Obstet Gynecol* 1981; 58:156
- ¹⁰ Myerscough PR. Ectopic pregnancy. In: Munro Kerr's *Operative Obstetrics*. 10th Ed. London: Bailliere Tindal, 1982: 371- 399
- ¹¹ Jarcho. Ectopic pregnancy with special reference to abdominal pregnancy. *Am J Surg* 1949; 77: 273, 423
- ¹² Hosking A. Cesarean section: Delivery of 254-day extrauterine foetus. *BMJ* 1934; 2:111
- ¹³ Iffy J. Early primary abdominal (pouch of Douglas) pregnancy with a report of a case. *Obstet Gynaec Br Emp* 1960; 67:997
- ¹⁴ Healy J. Specimen from a case of abdominal pregnancy. *Obstet Gynaec. Br Emp* 1951; 38:958
- ¹⁵ Hankins GDV, Clark SL, Cunningham FG, Gilstrap LC. Ectopic Pregnancy. In: *Operative Obstetrics*. Norwalk: Appleton & Lange, 1995: 437- 456
- ¹⁶ Senterman M, Jibodh R, Tulandi T. Histopathologic study of the ampullary and isthmic ectopic pregnancy. *Am J Obstet Gynecol* 1988; 159:939
- ¹⁷ Spiegleberg O. Zur causitik der ovarialshuvangerschaft. *Arch Gynaekol* 1878; 13:73
- ¹⁸ Romero R, Copel JA, Kadar N et al. Value of culdocentesis in the diagnosis of ectopic pregnancy. *Obstet Gynecol* 1985a; 65:519
- ¹⁹ Fleischer AC, Pennell RG, McKee MS et al. Ectopic pregnancy: features at transvaginal sonography. *Radiology* 1990; 174:375
- ²⁰ Pellerito JS, Taylor KJW, Quedens-Case C et al. Ectopic pregnancy: Evaluation with endovaginal color flow imaging. *Radiology* 1992; 183:407
- ²¹ Dubuisson JB, Aubriot FX, Foulot H et al. Reproductive outcome after laparoscopic salpingectomy for tubal pregnancy. *Fertil Steril* 1990; 53: 1004
- ²² Cook J, Sankaran B, Wasunna AEO. *Surgery at the district hospital: Obstetrics, gynecology, orthopaedics, and traumatology*. Geneva: WHO, 1991: 51-52

- ²³ Ory SJ. New options for diagnosis and treatment of ectopic pregnancy. *J Am Med Assoc* 1992; 267: 534-537
- ²⁴ Brenner PF, Roy S, Mishell DR. Ectopic pregnancy: A study of 300 consecutive surgically treated cases. *JAMA* 1980; 243: 673
- ²⁵ Timonen S, Neiminen U. Tubal pregnancy, choice of operative method of treatment. *Acta Obstet Gynecol Scand* 1967;46:327
- ²⁶ Niles JH, Clark JFJ, Pathogenesis of tubal pregnancy. *Am J Obstet Gynecol* 1969; 105:1230-1234
- ²⁷ Fujii S, Ban C, Okamura H, Nishimura T. Unilateral tubal quadruplet pregnancy. *Am J Obstet Gynecol* 1981; 141: 840-842
- ²⁸ Lucas C, Hassim AM. The place of culdocentesis in the diagnosis of ectopic pregnancy. *BMJ* 1970; I: 200

4.4.3.4 Reduction of uncomplicated forearm fractures

1. Indications	322
2. Contraindications	322
3. Step by step procedure	323
4. Materials	327
5. Anatomical pitfalls	327
6. Complications (anatomically relevant)	335
7. References	347

1. Indications

- The following uncomplicated types of fractures according to the Universal classification system²⁵ can be managed with closed reduction:

<i>Type</i>	<i>Fracture</i>	<i>Management</i>
Type I	Nonarticular, undisplaced	Cast or splint support
Type IIA	Nonarticular, displaced, stable	Closed reduction and cast
Type III	Intra-articular, undisplaced	Closed reduction and cast

2. Contraindications

- The following complicated types of fractures according to the Universal classification system²⁵ should be managed by an operative procedure, and not by closed reduction:

<i>Type</i>	<i>Fracture</i>	<i>Management</i>
Type IIB	Nonarticular displaced, unstable	Closed reduction and percutaneous pins, external fixation
Type IVA	Intra-articular, displaced, reducible	Closed reduction and percutaneous pins, external fixation, intramedullary rods
Type IVB	Intra-articular, displaced, not reducible	Open reduction (limited), external fixation, internal fixation, bone graft (unusual)
Type IVC	Complex	Open reduction (adequate), external fixation, internal fixation, bone graft (usual)

3. Step by step procedure

3.1 Colles' fracture reduction

- A Colles' fracture³³ should be reduced by correcting the following elements that characterize a Colles' fracture:
 - Impaction of the distal and proximal segments of the fracture (Shortening of the radial length). With the styloid of the radius and the ulna on the same plane.
 - The distal fragment is displaced dorsally (Dorsal displacement).
 - The distal fragment is angulated radially (Radial displacement).
 - Ulnar styloid avulsion.

Step 1. Radiographic confirmation

- An anteroposterior and lateral radiograph should be obtained. A control X-ray of the normal side should be obtained.
- Determine the radial length, the dorsal angle and the radial angle of the fracture.
- If available, radiological screening during the actual reduction is very helpful.

Step 2. Reduction

- Any rings should be removed from the fingers before reduction
- Reduction should be done under anesthesia (either general or regional anesthesia)

Regional anesthesia²²:

- Prepare the skin with 2% chlorhexidine in alcohol.
 - Inject 5-10ml of 1% lidocaine without adrenaline into the periosteum at and around the fracture site. The fragments are usually impacted. Therefore infiltration around the fracture site is necessary.
 - Wait 5- 12 minutes and manipulate the fracture.
- Distract the hand and the distal fragment to disimpact the fracture. This is an important step to restore radial length.
 - Apply three-point pressure to restore the dorsal angle by pressing on the distal fragment dorsally with both thumbs and counteracting the pressure with the index and middle fingers volarly.
 - Apply steady pressure from radially with the thenar eminence of the doctor's hand to restore the radial angle of the distal fragment. By this action the distal radial

fragment is pushed ulnarwards to reduce the radial displacement.

- After the radius is reduced and stabilized, the radio-ulnar joint should be assessed. Anatomical reduction of the radius means that the head of the ulna is in the ulnar notch of the radius.

There are three grades of distal radio-ulnar joint lesions²¹:

- Type 1 – the lesion is stable clinically and radiologically. There may be a minimally displaced avulsion of the ulnar styloid, but the primary stabilizers of the triangular fibrocartilage complex are intact
- Type 2 – Unstable distal radio-ulnar joint lesions with clinical and radiological evidence of subluxation due to a massive tear of the fibrocartilage complex and avulsion of the base of the ulnar styloid.
- Type 3 – potentially unstable lesions, due to skeletal disruption of the joint surface at the ulnar notch or ulnar head.

Most type 1 distal radio-ulnar lesions are successfully treated by immobilization in a cast in neutral rotation for 6 weeks²¹. Unstable radio-ulnar dislocations need percutaneous transfixation of the ulna to the radius, or operative treatment including open and arthroscopic techniques.

Step 3. Immobilization

- A plaster cast with the wrist slightly dorsiflexed and the metacarpophalangeal joints 90 degrees flexed, should be applied. A below the elbow radiodorsal plaster slab should be applied⁵.
- Immobilization should be done with the forearm in a neutral position with slight ulnar deviation and in moderate supination^{6, 25} and the neutral position. The wrist should not be in a flexed position²⁵.
- If a lot of swelling is present, apply a backslab, followed by a circular cast as soon as the swelling has diminished. A below the elbow cast should be applied.
- After 1 week, the position of the fracture should be checked radiographically to confirm anatomical reduction. If reduction is satisfactory a circumferential plaster can be applied if the swelling permits.

Step 4. Mobilization

The following exercises are described:

- Claw flexion is where the interphalangeal joints are flexed and the metacarpophalangeal joints extended.
- Tabletop flexion is where the interphalangeal joints are extended and the

- metacarpophalangeal joints are flexed.
- Fist flexion is where the wrist, metacarpophalangeal joints and interphalangeal joints are flexed.
- **Full extension of all the digital joints.**
- Abduction and adduction of the fingers.
- Opposition of the thumb tip to each fingertip.
- Elevation of the hand and forearm helps avoiding edema.

Step 5. Removal of the cast²⁴.

- Cut the plaster along its weakest or thinnest border.
- Avoid cutting through the slab where it overlies a subcutaneous border of a bone.
- Use the plaster scissors to cut through the plaster and then loosen the cast with a plaster spreader.
- In the case of a frightened child, the cast can be soaked in water for 10-15 minutes and then be removed like a bandage.

3.2 Smith's fracture

- Smith fractures occur in the same region of the radius but are associated with a palmar flexion deformity²⁵.
- Reverse the procedure of reducing a Colles' fracture.
- Strong supination is necessary.
- Recurrence of the deformity is common in a below-elbow cast in younger age groups. Therefore it is better to fix the arm in the supinated position by extending the cast above the elbow.
- Apply a volar cast where the plaster is moulded against the anterior aspect of the lower forearm and wrist. This prevents the fracture from slipping from the reduced position.

3.3 Other forearm fractures

3.3.1 Greenstick fracture

- A marked angular deformity is often seen that needs to be corrected. This can usually be done by rotating the forearm. In general, dorsal angulation is corrected by supination and volar angulation by pronation.
- Apply an above elbow cast.

- Retain the cast for three to six weeks, according to age.
- Watch for recurrence of the deformity while in the plaster.

3.3.2 Radius and ulna (middle third)

- Closed reduction is often possible in children but is difficult in adults
- The rotational deformity should first be corrected.
- Determine the rotation of the proximal fragment by comparing radiologically the tuberosities of the radius on the intact and fractured sides. Rotate the forearm to the correct position; apply strong manual traction with the elbow at 90 degrees and mould the cast into position.
- Apply the cast from the axilla to the metacarpal heads with the forearm still in the correct rotational position
- Keep the plaster on for twelve weeks.
- Shortening of one bone or angulation should not be accepted. If this cannot be corrected, proceed to open reduction and internal fixation.

3.3.3 Ulna (lower two thirds)

- Reduction is necessary with gross angulation or a secondary rotational deformity.
- Immobilize in an above the elbow cast

3.3.4 Ulna – upper third (Monteggia fracture dislocation)

- It is best to treat a Monteggia fracture dislocation by open reduction and fixation.
- Even a small return of angulation after reduction, permits the head of the radius to re-dislocate.

3.3.5 Proximal radius fracture in children¹

Fractures of the radial head and neck are seen in 5-10% of fractures around the elbow. Angulation of 30-60 degrees needs closed reduction under anesthesia.

1. The patient is generally anaesthetized.
2. The humerus is stabilized and the elbow flexed 90°.
3. The forearm is held in the ipsilateral hand of the doctor and supinated as far as possible.
4. Apply pressure on the anterolateral aspect of the head of the radius.
5. Carefully rotate the forearm to a neutral position and then into full pronation.
6. The displaced and tilted radial head is rotated under pressure and reduces. This is facilitated by the lax capsule of the elbow joint in elbow flexion.
7. Confirm stability and reduction radiographically.
8. Place the arm in a posterior above the elbow plaster splint and in full supination to relax the biceps brachii muscle for three weeks.

4. Materials

- Pre- and post reduction radiographs
- Radiographic screening (ideal)
- Material to apply a cast
- Plaster scissors, plaster spreader
- 2% chlorhexidine in alcohol
- 1% lidocaine without adrenaline and 10cc syringe and needle if local anesthesia is administered.

5. Anatomical pitfalls

5.1 Colles' Fracture

- Colles³³ described the fracture in 1814 as follows: "This fracture takes place at about an inch and a half above the carpal extremity of the radius". The dorsal surface of the wrist presents with a considerable deformity or swelling and a depression is seen in the forearm.
- All fractures of the distal radius spanned by the pronator quadratus with a dorsiflexion deformity are considered Colles' fractures²⁵.
- Mechanism of injury²⁷
 - It is widely accepted that distal radius fractures are caused by a fall on the outstretched arm with the hand in either dorsal flexion or volar flexion. Dorsal displacement of the distal fragment result when the hand is in dorsal flexion (Colles' fracture) and volar displacement of the distal fragment when the hand is in volar flexion (Smith's fracture) during the fall.
- The following elements characterize a Colles' fracture:
 - Impaction of the distal and proximal segments of the fracture (Shortening of the radial length). With the styloid of the radius and the ulna on the same plane.
 - The distal fragment is displaced dorsally (Dorsal displacement).
 - The distal fragment is displaced radially (Radial displacement).
 - Ulnar styloid avulsion.

5.2 Wrist²⁵

- At the wrist the radius and ulna are closely related to a concentration of tendinous, neural and vascular structures, which are situated in narrow channels. During a fracture these structures are at risk of injury. They may be excluded from the original

injury but may be included due to compression, swelling and secondary scar formation.

5.2.1 Radiocarpal joint

- The distal radius articulates with both the scaphoid and lunate bone of the proximal row of carpal bones. The distal joint surface of the radius is more curved for articulation with the scaphoid compared to the lunate³¹.

5.2.2 Radio-ulnar joint

- The distal radio-ulnar joint should always be considered with the proximal radio-ulnar joint for they form a functional unit. The distal and proximal radio-ulnar joints form the 'forearm joint', with the ulna being the stable and weight bearing part and the radius rotating in pronation and supination.
- The distal ulna has cartilage over its most dorsal, volar and radial surfaces. It articulates with the ulnar or sigmoid notch of the radius.
- The forearm rotates about 150° at the distal radio-ulnar joint. The radius and the hand rotate around the ulnar head⁷.
- The curvature of the ulnar notch has a radius, which is 4-7 mm larger than that of the ulnar head. Pronation and supination is therefore a combined rotation and sliding movement and the volar and dorsal radio-ulnar ligaments as well as the joint capsule are of great importance for the stability of the joint. The ulnar head has an inclination of 20° relative to the long axis of the ulna. This is also the case with the ulnar notch of the radius¹⁸.
- The radio-ulnar joint is stabilized by the interosseous membrane, the pronator quadratus muscle, the radio-ulnar joint capsule and the triangular fibrocartilage complex (TFC) between the distal radius and ulna, which includes the volar and dorsal radio-ulnar ligaments.
- Innervation of the radio-ulnar joint: Lourie *et al*³ demonstrated in 24 cadaver dissections, that the dorsal sensory branch of the ulnar nerve gives off a transverse branch in 80% of cases innervating the distal radio-ulnar joint and overlying skin.
- Articular disc and triangular fibrocartilage complex (TFC)
 - There is no contact between the ulna and the carpal bones. An articular disc separates the radiocarpal joint from the distal radio-ulnar joint³¹. A perforation in the articular disc joins the radiocarpal and radio-ulnar joint cavities in 25% of cases²⁷.
 - Kauer³¹ points out that the articular disc is in fact an extension of the deep layer of the antebrachial fascia. The antebrachial fascia stratifies at the level of the distal radio-ulnar joint. The fact that the articular disc and the

extensor carpi ulnaris muscle are situated within the deep layer of the antebrachial fascia provides mobility to the ulna on the radius during pronation and supination of the hand. This allows for pronation and supination in every position of the hand and forearm¹⁹.

- The articular disc has several extensions as reported by Kauer³¹: An extension to the base of the ulnar styloid process, to the ulnar styloid process, to the triquetral bone and to the hamate and base of the 5th metacarpal bone. The articular disc should be regarded as a complex fibrous system that links the radius to the ulna and the radius to the carpal joint. The complex attaches to the ulnar aspect of the lunate fossa of the radius⁷. This whole complex is therefore often referred to as the triangular fibrocartilage complex (TFC). The triangular fibrocartilage complex is contributing significantly to stabilizing the radio-ulnar joint⁷. Its anatomy allows the independent movement of the radio-ulnar and radiocarpal joints¹⁹.
 - The triangular fibrocartilage complex is a ligamentous and cartilaginous structure suspending the radius and carpal bones from the distal ulna⁷. The complex includes the dorsal and volar radio-ulnar ligaments, the meniscus homologue, the articular disc and the extensor carpi ulnaris sheath.
 - The **articular disc** plays an important stabilizing role in both the distal radio-ulnar and radiocarpal joints. It is part of both joints and allows independent movement in each joint¹⁹.
 - The disc is a fibrocartilaginous semicircular biconcave structure²⁰. The distal surface of the disc forms one quarter of the proximal articular surface of the radiocarpal joint. The radius forms the other three quarters²⁷.
 - The tendon of the extensor carpi ulnaris keeps the TFC under tension and helps with the stability of the joints¹⁹.
- **Specific tests for the distal radio-ulnar joint⁸:**
 - **A stability test:** The radius and ulna are fixed between the thumb and index finger of the examiner. The bones are moved up and down to detect joint laxity as compared to the contralateral side. The test is positive if the ulna can be subluxed.
 - **The forearm rotation test.** The patient is asked to pronate and supinate the wrist to a maximal range. The test is positive if pain is present with or without limited movement.
 - **The forearm rotation compression test:** The patient is asked to pronate and supinate the forearm while the examiner compresses the distal radio-ulnar joint. The test is positive indicating instability in the presence of pain and/or

subluxation of the ulnar head.

5.3 Distal radius²⁷

- The distal radius is formed of cancellous bone covered by a thin layer of cortical bone. It has a carpal articular surface for articulation with the lunate and scaphoid bones and an ulnar notch for articulation with the head of the ulna. Both these joints have thin capsules, which are strengthened by ligaments.

5.4 Ligaments²⁷

- There are dorsal and volar radiocarpal and ulnarcarpal ligaments. The volar ligaments are constantly found. The volar radiocarpal and ulnarcarpal ligaments combine to form the volar arcuate ligament. The dorsal ligaments are not always present. To provide for its unique range of movement, the wrist has no collateral ligaments³¹.

5.5 Movement around the wrist

- The wrist allows for dorsal and volar flexion and radio-ulnar adduction and abduction and combinations of these movements. Rotation of the hand is excluded from the wrist. To allow for this movement the wrist has no collateral ligaments, but other stabilizing factors³¹. The extensor carpi ulnaris on the ulnar side and abductor pollicis brevis and extensor pollicis brevis on the radial side are dynamic collaterals to the wrist joint³¹. The flexor carpi ulnaris, extensor carpi radialis longus and brevis, flexor carpi radialis and abductor pollicis longus also play a role in stabilizing the wrist. The important apparatus of ligaments joining the carpals and the scaphoid and lunate to the radius play an important stabilizing role.

5.6 Interosseous membrane¹⁷

- The interosseous membrane has a distal tract (8 mm wide, 31 mm long and 1 mm thick), which inserts on the dorsal capsule of the distal radio-ulnar joint and some deep fibers attach to the triangular fibrocartilage complex, which influence the joint. This tract strengthens the dorsal capsule of the distal radio-ulnar joint. The interosseous membrane joins the radius and ulna together to form a syndesmosis. A fracture of the distal radius is therefore usually associated with an ulnar fracture as well. Fractures can occur to the ulnar shaft, head and styloid process.

5.7 Distal radio-ulnar joint capsule¹⁶

- The distal radio-ulnar joint capsule is separate from the triangular fibrocartilage complex and accommodates the rotation of the distal ulna. This capsule may play an important role in the limited pronation and supination movement of patients who suffered fractures of the distal radius.

5.8 Structures in relation to the wrist joint²⁷

- **The extensor tendons** lie dorsally in their tunnels deep to the extensor retinaculum.
- **The flexor tendons** are somewhat protected from a distal radius fracture by the pronator quadratus muscle. The flexor tendons run in the carpal tunnel.
- **The median nerve** accompanies the flexor tendons in the carpal tunnel. It is prone to injury with distal radius fractures.
- **The ulnar nerve and artery** are less prone to injury since they are situated under superficial parts of the volar carpal ligament on the radial side of the flexor carpi ulnaris muscle. They may however be injured with fractures due to the insertion of the volar carpal ligament on the ulna.
- Both the ulnar and median nerves are not in contact with the volar surface of the radius and ulna²⁹.

5.9 Surface anatomy of the distal wrist crease³²:

- The distal wrist crease is situated over the proximal row of carpal bones. The radiocarpal joint is on average 13.5 mm proximal to the distal wrist crease, and the center of the radio-ulnar joint is on average 21.1 mm proximal to the distal wrist crease. The base of the ulnar styloid is on average 11.7 mm proximal to the distal wrist crease. Bugbee *et al*³² found the lunate consistently proximal from the distal wrist crease.

5.10 Anatomical classification of distal radius fractures

5.10.1 Frykman classification²⁷:

- Type 1 – extra-articular radius fracture
- Type 2 – extra-articular radius fracture plus an ulnar fracture
- Type 3 – fracture into the radiocarpal joint
- Type 4 - fracture into the radiocarpal joint plus an ulnar fracture
- Type 5 – fracture into the radio-ulnar joint
- Type 6 – fracture into the radio-ulnar joint plus an ulnar fracture
- Type 7 – Fracture of both joints without an ulnar fracture
- Type 8 – Fracture of both joints with an ulnar fracture

5.10.2 Universal classification system²⁵:

<i>Type</i>	<i>Fracture</i>	<i>Management</i>
Type I	Nonarticular, undisplaced	Cast or splint support
Type IIA	Nonarticular, displaced, stable	Closed reduction and cast
Type IIB	Nonarticular displaced, unstable	Closed reduction and percutaneous pins, external fixation
Type III	Intra-articular, undisplaced	Closed reduction and cast
Type IVA	Intra-articular, displaced, reducible	Closed reduction and percutaneous pins, external fixation, intramedullary rods
Type IVB	Intra-articular, displaced, not reducible	Open reduction (limited), external fixation, internal fixation, bone graft (unusual)
Type IVC	Complex	Open reduction (adequate), external fixation, internal fixation, bone graft (usual)

Type I and IIA are regarded as uncomplicated.

5.11 Anatomical measurements of reduction of a Colles' fracture^{5, 23}

5.11.1 Dorsal displacement:

- Dorsal angle (Lateral radiograph)**
 The dorsal angle is the angle between a line perpendicular to the long axis and the articular surface. The first line is drawn in the long axis of the radius and the second is a line joining the volar and dorsal margins of the articular surface. The dorsal angle is illustrated in Fig 1.

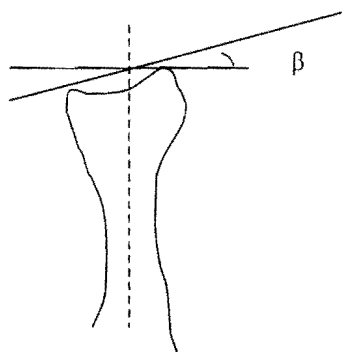


Fig 1. Dorsal angle (β)

- **Dorsal shift (Lateral radiograph)**

Dorsal shift is the difference in the distance from the long axis to the most dorsal point of the distal end of the bone. Dorsal shift is illustrated in fig 2.

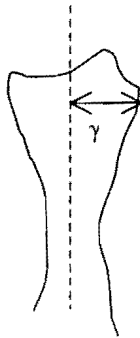


Fig 2. Dorsal shift (γ)

5.11.2 Radial displacement:

- **Radial angle (Antero-posterior radiograph)**

The antero-posterior view is used to determine the radial angle. The radial angle is between a line perpendicular to the long axis of the distal third of the radius and a line through the tip of the radial styloid process and the most distal part of the radius at the radio-ulnar joint. The radial angle is illustrated in fig 3.

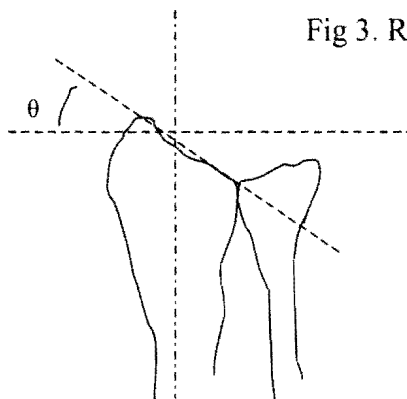


Fig 3. Radial angle (θ)

- **Radial length (Antero-posterior radiograph)**

Radial length is defined as the projected distance between the radial styloid process and the distal articular surface of the ulna on an antero-posterior radiograph. Measurement of the radial length is illustrated in fig 4.

A wrist with a small dorsal angle tends to show considerable shortening.

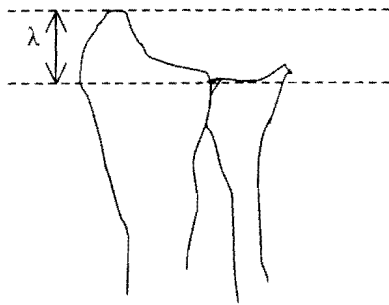


Fig 4. Radial length (λ)

- **Radial shift (Antero-posterior radiograph)**

Radial shift is the increase in distance from the long axis to the most radial point of the styloid process. Radial shift is illustrated in fig 5.

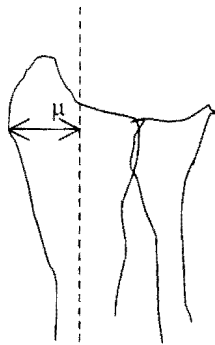


Fig 5. Radial shift (μ)

- Displacement according to Van der Linden *et al*²³, can be adequately described by two measurements, one for **dorsal displacement** and one for **radial displacement**. He also showed that restoration of the dorsal angle result in the diminishing or disappearance of radial shortening.
- The dorsal and radial angles are independent from each other. Therefore during reduction, both these angles need to be reduced. The distal fragment needs to be pushed dorsalward and ulnarward. If both angles are restored, the radial length will also be restored. Radial length is however also restored by the initial disimpaction of the fracture.
- Reduction is the key to a good outcome. According to Van der Linden *et al*²³, the technique of immobilization plays a less important roll in the final outcome.

5.11.3 Successful anatomical reduction.

- Reduction is considered satisfactory when the position on the post-reduction radiograph meets the criteria for an excellent anatomical grade⁵.
- The criteria for an excellent, good, fair and poor anatomical grade are illustrated in the following table by Stewart et al⁵:

Dorsal angle	Neutral	1-10	11-14	15+
Loss of radial length	0-3	3-6	7-11	12+
Loss of radial angle	0-4	5-9	10-14	15+
Score	0	1	2	4

An excellent grade = 0, good = 1-3, fair = 4-6 and poor = 7-12

- A **severely displaced fracture** is classified as follows:
 - Dorsal angle of more than 40°.
 - Radial shortening of 10 mm or more.
 - Loss of the radial angle of 15° or more when compared to the normal side.
- Boszotta *et al*¹⁰ states the following indications for surgical repair of Colles' fractures:
 - Radial shortening of over 3mm
 - A dorsal angle of more than 10°
 - Presence of a dorsal debris zone and avulsion of the distal radio-ulnar joint.

5.12 Brachioradialis muscle

- The brachioradialis muscle tends to deform the Colles' fracture, however this is least likely in supination. The brachioradialis muscle is the only muscle attached to the distal fragment of the fracture²⁶. Sarmiento *et al*⁶ find an increased number of unsatisfactory anatomic results in fractures that were immobilized in pronation, due to the muscle-deforming force of brachioradialis when the arm is in a pronated position.

6. Complications (anatomically relevant)

- Cooney *et al*⁴ reports on the complications seen in 565 patients with Colles' fractures. Complications are usually due to repeated attempts for reduction, incorrect application of the cast, poor mobilization of the joint and fingers and inadequate

rehabilitation.

- Cooney *et al*⁴ reports a 31% complication rate with the following distribution:
 - Persistent neuropathies of the median, ulnar or radial nerves (45 cases)
 - Radiocarpal or radio-ulnar arthrosis (37 cases)
 - Malposition and malunion (30 cases)
 - Pain dysfunction syndrome (20 cases)
 - Unrecognized associated fractures (12 cases)
 - Finger stiffness (9 cases)
 - Tendon rupture (7 cases)
 - Volkmann's ischemia (4 cases)

6.1 Inadequate reduction

- Anatomical reduction is usually possible to obtain even in elderly people if the bone is of good quality and if there is no excessive comminution. Reduction is difficult in the presence of osteoporosis and severe comminution.
- Linscheid *et al*²⁵ reports that an operative approach is seldom needed and the best possible reduction should be sought. The degree of anatomical reduction significantly affects the final result.
- Insufficient traction is the most common problem associated with inadequate reduction. This may be due to soft tissue being entrapped, making reduction impossible. Muscle relaxation greatly assists in reducing a fracture.
- If reduction cannot be maintained, percutaneous Kirschner wire fixation or open reduction and internal fixation are necessary.
- Loss of reduction leads to shortening of the radius, an abnormal radial angle and dorsal displacement and incongruence of the distal radio-ulnar joint. Various functional complications may be the result. Functional complaints include loss of wrist and forearm motion, weakness of the wrist, finger stiffness and possible loss of dexterity.
- A bad result due to fixation in an abnormal position (wrist flexion, pronation and ulnar deviation) is the stiff claw hand, extension contracture of the metacarpophalangeal joints, flexion contractures of the PIP joints and flexion contracture of the wrist joint.
- Inadequate reduction can be changed by closed methods up to 3 weeks after the injury and open methods up till 6 weeks after the injury.
- Stoffelen *et al*⁸ concludes that a dorsal angle of more than 5°, a radial shortening of 4 mm or more and a lateral shift of 2 mm or more, contribute to a poorer result with restriction in supination.

- Associated styloid fractures result in poorer functional results due to the involvement of the distal radio-ulnar joint.
- Dorsal angle of more than 20° result in poor functional outcome.
- There is a rough correlation between the anatomy of the fracture at 6 weeks and the function at three months^{5,6}.
- Loss of reduction means the fracture is unstable and should be referred. This is usually the case in great comminution, marked displacement of fragments and interposition of soft tissue.
- Adequate reduction means that the full dorsal length of the radius is restored. Full and adequate reduction has been shown to benefit the outcome of Colles' fractures⁵. These benefits are good early function and, less risk of developing carpal tunnel syndrome.
- Dias *et al*³⁵ has shown in a prospective radiographic assessment of patients above 55 years that during a 13-week period following the injury and reduction, the deformity progressively recurred, even after the plaster cast had been removed. Radial length and angle disturbance return to their position before reduction. They conclude that the initial injury determines the radiological and therefore anatomical result. This view is challenged by Stewart *et al*¹⁴ and Van der Linden *et al*²³ by pointing to the definite correlation between the completeness of the reduction and the final anatomical result also in the elderly.

6.2 Nerve injuries²⁵

- Frykman²⁷ reports an incidence of 3.2% of nerve injuries in a series of 430 patients with Colles' fracture. The median nerve was involved in 2.3% of all the cases and the ulnar nerve in 0.9% of cases. The most frequent clinical symptom was numbness in the field of innervation of the nerve. Only exceptionally, numbness was experienced in the entire field of innervation.
- Frykman²⁷ reports that the involvement of an intra-articular fracture was a common etiological factor in all the cases he studied with nerve injuries. Intra-articular fractures and peri-articular hematoma and swelling lead to increased pressure in the carpal tunnel.
- Volar fracture segments, excessive callus formation, persistent hematoma and localized swelling may compress on both the ulnar and median nerve.
- Force of reduction, positioning of immobilization contribute to neuropathies.
- Aro *et al*¹² reported a 12% rate of late compression neuropathies after conservative management of 166 Colles' fractures. The incidence of median nerve compression

was 8% and that of ulnar nerve compression 4%. Median nerve compression was associated with malunion with radius collapse and dorsal angle deformities. Ulnar nerve compression was associated with malunion with radius collapse or volar subluxation of the ulnar head.

Anatomical malalignment of Colles' fractures therefore play an important role in late compression neuropathies.

- The symptoms of nerve compression usually diminish after reduction of the fracture. Persistent symptoms can be treated with median nerve decompression²⁷.
- The nerves can also be injured by the bony fragments. This is best treated by reduction and immobilization of the fracture. If the nerve irritation is persistent, an exploration needs to be done.
- Nerve injuries may involve the roots of the nerves of the brachial plexus up to the digital nerves. This is due to possible associated fractures.
- The most common nerve injured is the median nerve at the site of the injury. Ulnar nerve injuries and injury to the branches of the radial nerve occur, but are less common.
- Simultaneous injuries to both the median and ulnar nerves are rare²⁷.
- Median nerve compression is usually easily recognized, but radial and ulnar nerve compression may be difficult to diagnose if not specifically looked for⁴.

6.2.1 Median nerve

- The median nerve is usually entrapped in the carpal tunnel and the ulnar nerve in Guyon's canal due to bleeding in the region and swelling after the injury. Entrapment of the median nerve is much more common than that of the ulnar nerve due to the intimate relation of the median nerve to the distal radius²⁷.
- Progressive edema and hematoma formation in the carpal tunnel after the initial injury and fracture reduction are responsible for acute median nerve compression.
- The wrist should not be immobilized in the flexed position, for this position can produce nerve irritation²⁵.
- Lynch *et al*²⁸ report 3.3% incidence of median nerve compression in 600 cases.
- The use of local anesthesia for reduction of the fracture may be associated with median nerve compression⁴.
- Abbot *et al*²⁹ classified median nerve injuries in the following categories: 1) Primary injury after fracture (very rare), 2) Secondary injury after fracture due to the bony

fragment, bleeding or callus formation, 3) late or delayed involvement and 4) injuries associated with immobilization in palmar flexion.

- Primary injury necessitates immediate exploration. Atrophy of the thenar muscles is an absolute indication for surgery.
- There may be two reasons why the median nerve is prone to injury during immobilization of the wrist in flexion²⁹. 1) The median nerve runs from deep to superficial just proximal to the wrist and is therefore not amenable to displacement with flexion, and 2) the transverse carpal ligament has a sharp proximal edge close to the anterior border of the radius. In palmar flexion, impingement may occur on this edge.
- Robbins³⁰ pointed out that with acute volar flexion of the wrist, the anterior part of the lunate bone rotates to point volarwards. This reduces the volume of the carpal tunnel especially in the presence of displaced bony fragments and bleeding.
- Median neuropathy is associated with reduction of the fracture under local anesthesia, where the local anesthetic solution is injected into the fracture hematoma. This increases the pressure as well as scar and fibrosis formation, which are responsible for nerve compression^{4, 13}.
- Callus formation may compress the median nerve proximal to the carpal tunnel.
- Elderly patients and patients where reduction has a poor anatomical result are more likely to develop carpal tunnel syndrome. This is especially true if there is dorsal angle disturbance at the fracture site. Carpal tunnel syndrome carries the highest morbidity in Colles' fracture⁵.
Stewart *et al*¹¹ studied 209 patients with Colles' fractures for six months and reported a 17% incidence of carpal tunnel syndrome after three months and 12% after six months. Older patients and those with higher degrees of dorsal angle disturbance were most at risk.

6.2.2 Ulnar nerve

- Ulnar nerve injuries are less common due to the anatomical relation of the ulnar nerve which is on the ulnar side of and superficial to the carpal tunnel. Dislocation of the ulnar head is known to cause ulnar nerve injuries. The diagnosis may be difficult if only the deep motor branch of the ulnar nerve is involved and the patient is not presenting with radiating pain to the 4th and 5th digits.
- Aro *et al*¹² reports that CT examination may demonstrate volar dislocation of the ulnar head in patients with symptoms of ulnar nerve compression.
- Entrapment of the ulnar nerve between a dislocated ulna facing to the palm and fragments of the radius requires immediate treatment. Sensory function of the ulnar

nerve and the motor function to the intrinsic hand muscles deteriorate quickly.

- Ulnar neuropathy may also occur due to cast compression, especially at the elbow.
- Clarke *et al*¹⁵ reports three cases of ulnar nerve palsies following distal radius fractures. All three cases had dense scar tissue around the nerve, with one ulnar nerve being displaced dorsally due to a dislocated radio-ulnar joint. Clarke also performed an anatomical study to try to explain the lower incidence of ulnar nerve compression compared to median nerve compression. Anatomically, this may be due to the greater excursion and mobility of the ulnar nerve compared to the median nerve, which runs through a confined space in the carpal tunnel. He made a transverse incision over the radio-carpal joint through all the structures in six cadaver wrists. The proximal stumps of the median and ulnar nerves were then assessed regarding their mobility in three directions: longitudinal traction, radial displacement and ulnar displacement. The ulnar nerve had greater mobility and therefore escapes injury in most cases.

6.2.3 Radial nerve

- Radial neuropathy can occur with improper cast immobilization. It is usually due to direct pressure on the radial styloid region, dorsum of the thumb and metacarpal region of the index finger compressing the superficial branch of the radial nerve on the bony structures.
- If an above-elbow cast is used, the cast should extend up to the axilla or it may compress the radial nerve in the radial groove of the humerus.

6.3 Missing the diagnosis²⁵

- Falls on the outstretched hand are common and fractures can easily be missed. The diagnosis should be made in the presence of a history and tenderness over the bone. The fracture line may only become apparent days after the injury. Although not displaced these fractures can result in complications, due to radius shortening and consequent radio-ulnar joint involvement.

6.4 Associated skeletal injuries²⁵

- Due to the mechanism of injury, the entire upper limb is involved. Associated injuries at the elbow, humerus and clavicle are therefore not uncommon. These regions should be examined and if necessary also radiologically evaluated. Due to the syndesmosis between the radius and ulna, the ulna is usually involved as well.
- The proximal row of carpal bones can also be involved as well as the triangular fibrocartilage complex. Scaphoid fracture, radial head fracture, Bennett's fracture and intercarpal ligament injury can occur simultaneously with the Colles' fracture due to the same mechanism of injury. These injuries may not be obvious just after

the injury.

- A fracture of one bone with appreciable shortening is usually accompanied by dislocation of one end of the other bone. It is therefore important to always check the elbow and wrist radiologically.

6.5 Vascular injuries²⁵

- Vascular injuries may occur during unusual displacement of a distal radius fracture. Exploration is necessary if a vascular injury is suspected.

Volkmann's ischemia

- This may be due to an undiagnosed constricting cast.
- Compartment syndrome is also seen in the forearm. Pain especially on stretching the muscles and swelling are reliable signs. The flexor compartment of the forearm is most frequently involved. Decompression of the cast, skin and fascial layers is necessary. Monitoring of the arterial blood flow is important.

6.6 Radio-ulnar dissociation

- Knowledge of the anatomy and biomechanics of the joint is very important in the treatment of distal radius fractures¹⁸. With a distal radius fracture, the distal segment of the radius angulates dorsally or radially and therefore the ulnar notch of the radius is no longer congruent with the ulnar head. The radio-ulnar ligaments, which are part of the triangular fibrocartilage complex, may tear.
- Wrist disabilities after distal radius fractures are most commonly caused by injury to the distal radio-ulnar joint²¹. Early recognition of injury to the joint may allow proper anatomical reconstruction of the bony components, joint surfaces and ligaments of the distal radio-ulnar joint. Some instability of the radio-ulnar joint is present in every displaced distal radius fracture.
- Ekenstam¹⁸ reports on three important anatomical aspects of the distal radio-ulnar joint. He found that 10° of radial compression and a dorsal angle of 40° is enough to cause subluxation of the distal radio-ulnar joint. A fractured styloid process seen on X-Ray reveals a disrupted TFC. Restoring stability to the distal radio-ulnar joint is crucial for normal function of the forearm and wrist. Because radius compression due to a Colles' fracture has such an important impact on the TFC, it is crucial to disimpact the fracture during closed reduction.
- Altered anatomy of the distal radius and ulnar styloid fractures lead to dysfunction of the distal radio-ulnar joint⁸. Stoffelen *et al*⁸ evaluated the involvement of the distal radio-ulnar joint in 272 distal radius fractures. At one-year follow-up, 13 patients had instability of the joint, nine had pain with simple forearm rotation, 51 had instability

during compression and 130 had loss of strength in forearm rotation. He concludes that impaired function due to altered anatomy in distal radius fractures can be explained by distal radio-ulnar joint dysfunction.

- Injury to the lateral aspect of the elbow is associated with instability of the distal radio-ulnar joint².
Various fractures of the elbow and wrist are associated with radio-ulnar dissociation. A disrupted interosseous membrane is presumably the cause for this problem. Both the interosseous membrane and the triangular fibrocartilage complex stabilize the radio-ulnar joint. Imaging of the interosseous membrane is unhelpful in the difficult diagnosis of radio-ulnar dissociation. MRI may be promising.

6.7 Mal-union

- Mal-union usually occurs due to inadequate reduction seen in unstable and comminuted fractures. If reduction cannot be obtained by closed manipulation, patients should be referred for surgical reduction.
- McQueen *et al*³⁶ has shown that mal-united Colles' fractures have significant functional deficits. The wrist is weak, deformed, stiff and sometimes a painful joint. The author concludes that it is essential to strive for an anatomically accurate result to ensure minimal functional deficit.

6.8 Radiocarpal or radio-ulnar arthrosis

- Arthrosis is diagnosed in the presence of any painful motion of the wrist and forearm or mechanical obstruction of motion.
- This complication is more often seen in Frykman²⁷ VI, VII and VIII, where the articular surfaces are also involved and where either an internal or external pin-fixation was used.
- Radiocarpal arthrosis usually develops if an adequate anatomical reduction cannot be obtained. Two common problems with reduction are:
 - Radial deviation with dorsal angle disturbance of the distal radial component.
 - Poor restoration of radial length to maintain the distal radio-ulnar joint.

6.9 Pain dysfunction syndrome²⁵ (Shoulder-hand-finger syndrome, Sudek's atrophy)

- The characteristic of this syndrome is the inhibition of function due to pain. It is exacerbated by caution, panic, anxiety and other psychological attitudes. As active movement is inhibited, swelling occurs which limits even passive movement. The skin is very sensitive and typically has a shiny appearance.
- This syndrome may be secondary to median nerve neuropathy^{4, 28}.

- Shoulder pain is commonly associated and the syndrome is therefore sometimes referred to as shoulder-hand-finger syndrome.
- Inactive patients are more prone to the syndrome²⁷. Active exercise of both the shoulder and fingers should immediately commence to prevent contracture formation and the circulation.
- The condition should be identified early and appropriate measures initiated. A range of six exercises are described:
 - **Claw flexion** is where the interphalangeal joints are flexed and the metacarpophalangeal joints extended.
 - **Tabletop flexion** is where the interphalangeal joints are extended and the metacarpophalangeal joints are flexed.
 - **Fist flexion** is where the wrist, metacarpophalangeal joints and interphalangeal joints are flexed.
 - Full extension **of all the digital joints**.
 - **Abduction and adduction** of the fingers.
 - **Opposition** of the thumb tip to each fingertip.
- Elevation of the hand and forearm helps avoiding edema.

6.10 Tendon rupture

- Rupture of the extensor pollicis longus, index flexor digitorum profundus or flexor pollicis longus has been reported⁴. Tendon rupture occurs due to displaced bony fragments that wear through the tendon during the subsequent weeks and months.
- The extensor pollicis longus tendon is at greatest risk from initial injury at the dorsal fracture edge. It may also be due to cramping of the tendon in its fibro-osseous tunnel due to callus formation around the fracture site with devascularization and eventual rupture of the tendon.
- Frykman²⁷ reports 3 cases with rupture of the extensor pollicis longus tendon in a series of 430 patients with Colles' fracture.
- The extensor digiti minimi and extensor digitorum to the little and ring finger can rupture through rubbing over a subluxated ulnar head.

6.11 Subluxation of the ulna

- Colles³³ first described ulnar subluxation which is evident if the surgeon finds that the end of the ulna may be moved readily forwards and backwards.

- The ulna often subluxates in a dorsal direction and sometimes in a palmar direction. The ulnar nerve may as a result be injured. A high index of suspicion should be maintained for this injury which may become apparent with clinical examination and radiographic observation. The ulna must be reduced into the ulnar notch of the radius.

6.12 Immobilizing the hand in palmar flexion (Cotton-Lodor position)

- Immobilizing the hand in the so-called Cotton-Lodor position where the hand is immobilized in palmar flexion, is very undesirable. In the palmar flexion position, the hand is in a position of nonfunction. The digits cannot be flexed properly, especially in the presence of swelling. The tension in the extensor tendons created by a palmar flexion position, results in compression of the dorsal surface of the articular fragments and acts adversely on maintaining reduction. Dorsal angle disturbance is the primary displacement.
- The palmar flexion position also increases the risk of entrapment of the median and ulnar nerves²⁵.

6.13 Immobilizing the wrist in ulnar deviation

- According to Linscheid²⁵, ulnar deviation increases the compressive stresses and radius shift of the radiocarpal articulation, which may aggravate radius translocation. He prefers the wrist to be in a neutral position with slight ulnar deviation and moderate supination.
- The hand should not be immobilized in pronation, for this increases the already unstable distal radio-ulnar joint.
- The forearm should be immobilized in moderate supination and if the length of the radius cannot be maintained, the patient should be transferred for fixation.

6.14 Uncoordinated function

- Loss of coordination and strength occur in all patients in the early months after the fracture.

6.15 Cast related complications²⁴

- Pressure necrosis. This can result from localized pressure on bony prominences. The sequence of events is often as follows: The patient complains of persistent discomfort which is ignored. The pain disappears and sloughing occurs with staining of the overlying cast. A window should be cut at the suspected site. When ulceration is present a dressing should be applied.

- Edema distal to the plaster cast. Edema usually disappears after 2-3 days with elevation of the limb. If the edema does not disappear, the cast is too tight and should be split along its full length.
- Skin blistering and dermatitis.
The skin becomes scaly and the epithelial layer is discarded. Dermatitis may develop especially in hot weather.
- Loss of vascular function.
This is usually due to injury to the vascular supply during the initial injury. Capillary circulation should be checked both before and after the application of the cast. This will avoid gangrene or Volkmann's contracture.
- Compartment syndrome.
Compartment syndrome may develop especially in the flexor compartment. If a compartment syndrome is suspected the cast should be removed immediately.
- Neuropathy of the superficial sensory branches of the radial, ulnar, median and musculocutaneous nerves are frequent complications of pressure within or at the edges of the cast. Release of pressure is necessary²⁵.

6.16 Triangular fibrocartilage complex (TFC) tears²⁵

- The TFC is usually injured with marked displacement of the ulnar head. The TFC may be torn from its medial attachment, from its insertion on the base of the styloid process and/or from its foveal insertion. Avulsion of the ulnar styloid process result in tearing of the TFC.
- Tearing of the TFC is found clinically by localized pain in the ulnocarpal sulcus. Depression of the ulnar head and forced ulnar deviation accentuate the pain.

6.17 Mechanical constraint of finger movement

- The metacarpophalangeal joints, proximal and distal interphalangeal joints should be free of mechanical constraints. It is important that the metacarpophalangeal joints are free to move since they are most prone to stiffness. The little and ring fingers are most at risk of an extension contracture. Care should be taken that the cast does not immobilize the metacarpophalangeal joints. These joints should be frequently flexed past 60° to prevent contracture formation of the collateral ligaments.
- This may be a severe complication with considerable pain particularly of the proximal interphalangeal joint. This is commonly associated with incorrect application of the cast. Early finger motion after cast application is essential to prevent stiff fingers.

6.18 Poor movement ability

- Hove *et al*⁹ showed in a prospective study of 26 patients with Colles' fractures with secondary displacement after immobilization and subsequent remanipulation that the total pronation and supination movement five years after the Colles' fracture correlated with the initial radial length and dorsal angle disturbance. Total movement in all directions correlated well with the initial radial length. Initial radial shortening is therefore an important factor in a Colles' fracture and needs to be corrected for a good functional result.

6.19 Hand complications

- Stewart *et al*¹⁴ studied the hand complications of Colles' fracture in 230 patients. He found an incidence of 17% of carpal tunnel syndrome after three months and 12% at six months. These patients were significantly older and the amount of dorsal angle disturbance of their fractures was significantly greater. The nerve tissue of older patients tolerates pressure relatively poorly. It is accepted that the final anatomical result is related to the completeness of the reduction. This is especially true for proper reduction of the dorsal angle with regards to hand complications.
- The incidence of Dupuytren's disease was 11%. These patients were also significantly older.

6.20 Pathological fracture

- With a pathological fracture the preexisting lesion should be established. Biopsy of the lesion may be necessary.

6.21 Pain

- Subluxation of the radio-ulnar joint is a common cause of residual pain after a Colles' fracture.
- Frykman²⁷ reports that at least 25% of patients with a distal radius fracture have some complaints one year after the injury. Most of these complaints are referred to the distal radio-ulnar joint¹⁸.

6.22 Infection²⁵

- Infection and gangrene are uncommon complications. If present, thorough surgical debridement is of great importance as well as aggressive antibiotic treatment.

7. References

- ¹ Kaufman B, Rinott MG, Tanzman M. Closed reduction of the proximal radius in children. *J Bone Joint Surg* 1989; 71-B: 66-67
- ² Trousdale RT, Amadio PC, Cooney WP, Morrey BF. Radio-ulnar dissociation. *J Bone Joint Surg* 1992;74-A; 1486-1497
- ³ Lourie GM, King J, Kleinman WB. The transverse radio-ulnar branch from the dorsal sensory ulnar nerve: Its clinical and anatomical significance further defined. *J Hand Surg* 1994; 19A: 241-245
- ⁴ Cooney WP, Dobyns JH, Linscheid RL. Complications of Colles' Fractures. *J Bone Joint Surg* 1980; 62-A: 613-619
- ⁵ Stewart HD, Innes AR, Burke FD. Factors affecting the outcome of Colles' fracture: an anatomical and functional study. *Injury* 1985;16:289-295
- ⁶ Sarmiento A, Zagorski JB, Sinclair WF. Functional bracing of Colles' fracture: a prospective study of immobilization in supination versus pronation. *Clin Orthop* 1980; 146:175
- ⁷ Palmer AK, Werner FW, Eng MM. Biomechanics of the distal radio-ulnar joint. *Clin Orthop and Related Research* 1984; 187: 26-35
- ⁸ Stoffelen D, De Smet L, Broos P. The importance of the distal radio-ulnar joint in distal radial fractures. *J Hand Surgery Br Vol* 1998; 23(4):507-11
- ⁹ Hove LM, Fjeldsgaard K, Skjeie R, Solheim E. Anatomical and functional results five years after remanipulated Colles' fractures. *Scandinavian Journal of Plastic & Reconstructive surgery & Hand Surgery* 1995; 29(4):349-55
- ¹⁰ Boszotta H, Helperstorfer W, Sauer G. Indications for surgery in distal radius fractures. *Unfallchirurg* 1991; 94(8): 417-23
- ¹¹ Stewart HD, Innes AR, Burke FD. The hand complications of Colles' fractures. *J Hand Surg Br Vol* 1985; 10(1):103-6
- ¹² Aro H, Koivunen T, Katevuo K, Nieminen S, Aho AJ. Late compression neuropathies after Colles' fractures. *Clin Orthop & Related Research* 1988; 233: 217-25
- ¹³ Kongsholm J, Olerud C. Neurological complications of dynamic reduction of Colles' fractures without anesthesia compared with traditional manipulation after local infiltration anesthesia. *J Orthop Trauma* 1987; 1(1):43-7
- ¹⁴ Stewart HD, Innes AR, Burke FD. The hand complications of Colles' fractures. *J Hand Surg* 1985; 10B: 103-106
- ¹⁵ Clarke AC, Spencer RF. Ulnar nerve palsy following fractures of the distal radius: clinical and anatomical studies. *J Hand Surg Br Vol* 1991; 16(4):438-40
- ¹⁶ Kleinman WB, Graham TJ. The distal radio-ulnar joint capsule: clinical anatomy and role in posttraumatic limitation of forearm rotation. *J Hand Surg Am Vol* 1998; 23(4):588-99
- ¹⁷ Gabl M, Zimmermann R, Angermann P, Sekora P, Maurer H, Steinlechner M, Pechlaner S. The interosseous membrane and its influence on the distal radio-ulnar joint. An anatomical investigation of the distal tract. *J Hand Surg Br Vol* 1998; 23(2):179-82
- ¹⁸ Ekenstam AF. Anatomy of the distal radio-ulnar joint. *Clin Orthop & Related Research* 1992;275:14-8
- ¹⁹ Kauer JM. The distal radio-ulnar joint. Anatomic and functional considerations. *Clin Orthop & Related Research* 1992; 275: 37-45

- ²⁰ Mikic ZD. Detailed anatomy of the articular disc of the distal radio-ulnar joint. *Clin Orthop & Related Research* 1989; 245:123-32
- ²¹ Geissler WB, Fernandez DL, Lamey DM. Distal radio-ulnar joint injuries associated with fractures of the distal radius. *Clin Orthop* 1996; 327:135-46
- ²² Dinley RJ, Michelinakis E. Local anaesthesia in the reduction of Colles' fracture. *Injury* 1972, 4: 345-346
- ²³ Van der Linden W, Ericson R. Colles' fracture. How should its displacement be measured and how should it be mobilized? *J Bone Joint Surg* 1981; 63-A, 1285
- ²⁴ Cook J, Sankaran B, Wasunna AEO. Surgery at the district hospital: Obstetrics, gynaecology, orthopaedics, and traumatology. Geneva: WHO, 1991: 89-91
- ²⁵ Linscheid RL, Dobyns JH. Complications of fractures and dislocations of the wrist. In: Epps CH Ed. *Complications in Orthopaedic Surgery Vol I*. Philadelphia: JB Lippincott Company, 1994: 321-387
- ²⁶ Sarmiento A. The brachioradialis as a deforming force in Colles' fractures. *Clin Orthop* 1965; 38: 86
- ²⁷ Frykman G. Fracture of the distal radius including sequelae – shoulder-hand-finger syndrome, disturbance of the distal radio-ulnar joint and impairment of nerve function. A clinical and experimental study. *Acta Orthop Scandinavica* 1967; Suppl 108 : 7-153
- ²⁸ Lynch AC, Lipscomb PR. The carpal tunnel syndrome and Colles' fracture. *JAMA* 1963; 185: 363
- ²⁹ Abbot LC, Saunders JB de CM. Injuries of the median nerve in fractures of the lower end of the radius. *Surg Gynec Obstet* 1933; 57: 507
- ³⁰ Robbins H. Anatomical study of the median nerve in the carpal tunnel and etiologies of the carpal tunnel syndrome. *J Bone J Surg* 1963; 45A: 953
- ³¹ Kauer JMG Functional anatomy of the wrist. *Clin Orthop Related Research* 1980: 149: 9- 20
- ³² Bugbee WD, Botte MJ. Surface anatomy of the hand. The relationships between palmar skin creases and osseous anatomy. *Clin Orthop Related Research* 1993; 296: 122-126
- ³³ Colles A. On the fracture of the carpal extremity of the radius. *Edinburgh Med Surg J* 1814; 10:182-186
- ³⁴ Sarmiento A, Pratt GW, Berry NC et al. Colles' fractures- functional bracing in supination. *J Bone Joint Surg* 1975; 57-A:311
- ³⁵ Dias JJ, Wray CC, Jones JM. The radiological deformity of Colles' fractures. *Injury* 1987; 18: 304-308
- ³⁶ McQueen M, Caspers J. Colles fracture: Does the anatomical result affect final function? *J Bone J Surg* 1988; 70B: 649-651

4.4.4 Imaging Procedures

4.4.4.1 Obstetric ultrasound examination

1. Indications	349
2. Contraindications	350
3. Step by step procedure	350
4. Materials	351
5. Anatomical pitfalls	351
6. Complications (anatomically relevant)	360
7. References	360

1. Indications⁶

Antenatal screening

- Estimation of fetal age
- Earlier detection of twins
- Amniocentesis for lung maturation evaluation

16-20 weeks

- fetal age: Uncertain clinical dates
 - Indicated induction of labor
 - Repeat elective cesarean section
- Significant discrepancy between uterine size and clinical dates
- Detect multiple gestation
- Suspected fetal death
- Follow-up examination of placental position
- Suspected placenta previa or abruptio placentae
- Determination of presenting fetal part
- Estimation of fetal weight in premature rupture of membranes, premature labor, and a fetus that is large for gestational age
- To assist amniocentesis
- History of congenital abnormalities
- Review maternal and fetal anatomy
- Confirming a breech presentation at 36 weeks by physical examination.
- Ultrasound guided amniocentesis for fetal lung maturity testing.
- Vaginal bleeding of undetermined cause during pregnancy
- Suspected ectopic pregnancy
- Suspected polyhydramnios and oligohydramnios
- Evaluation of fetal condition in late registrants
- Evaluation of a pelvic mass
- Suspected uterine abnormality

- Suspected hydatiform mole

Serial examinations in the second and third trimester can be used to screen for intrauterine growth retardation.

2. Contraindications

No contra-indications are reported except for inappropriate use which are listed under complications.

3. Step by step procedure⁵

Step 1. Meet patient and establishes rapport.

Step 2. Perform an abdominal examination and the fundal height should be measured.

Step 3. Use a mechanical sector transducer for visualization. This transducer scans in an arc and produces a pie-shaped image. First obtain an orientation of the transverse and longitudinal views.

Step 4. The following are easy guidelines for obstetric ultrasound^{7, 8}:

First trimester

- Location of the gestational sac
- Identify the embryo and record the crown-rump length
- Report on the presence or absence of fetal life
- Record the fetal number
- Evaluate the uterus and cervix and adnexal structures

Second and third trimester

- Record the presence or absence of fetal life
- Record the fetal number
- Document the fetal presentation
- Give an estimate of the amniotic fluid (normal, increased or decreased)
- Record the placental position and its relation to the internal os of the cervix
- Assessment of gestational age: Biparietal diameter
Femur length
- Fetal growth assessment: Abdominal circumference
- Fetal anatomy:
 - cerebral ventricles,
 - four chambers of the heart and the heart's position in the thorax,
 - spine,

- stomach,
- urinary bladder,
- umbilical cord insertion on the anterior abdominal wall and
- renal region

Step 5. Compare these findings with possible previous scans

The following need to be mastered: assessment of gestational age and fetal growth, survey of fetal anatomical structures to detect abnormalities and examination of the placenta, amniotic fluid, uterus and adnexal structures⁶.

Anatomy not seen with the one mode, can often be seen more clearly with the other.

4. Materials⁶

Ultrasound machine

- Screen – video monitor
- Hardware and software
- Transducers – Mechanical sector – scans in an arc and produces a pie-shaped image
 - Linear array – produces a rectangular shaped image

5. Anatomical pitfalls

5.1 Embryology

The ovum starts dividing after fertilization into the morula and blastocyst which implants in the endometrium at about one week after ovulation.

The gestational sac is surrounded by the trophoblast which is seen as a hyperechoic rim and will develop into the placenta.

At 6 weeks the fetal pole can first be seen, however the anatomy only becomes visible after the second gestational month¹⁰.

Fetal heart activity can be seen after 5 weeks gestation.

5.2 Gestational age determination⁶

Gestational age is measured in weeks and days from the onset of the normal menstrual period (conception date plus 15 days)¹⁰. Others refer to the term gestational age extending from fertilization to birth²⁰. Sometimes it is then referred to as fertilization age. The first mentioned calculation is usually used in obstetric ultrasound measurements, but does not solve the problem mentioned by O’Rahilly²⁰, that the word gestational used in two different meanings, has lost scientific value.

All measurements done to determine gestational age are done in millimeters.

This determination becomes less accurate later in pregnancy with as much as a 3-week deviation in either direction at 30 weeks gestation.

The most accurate time to determine gestational age is between 10 and 12 weeks. During this period the fetus is experiencing linear growth and the crown-rump length estimation at 6-12 weeks is very accurate.

Anatomical landmarks are best found from 17-23 weeks gestation.

Crown-rump length at 6-12 weeks and biparietal diameter at 17-23 weeks have a 95% confidence interval of being close to 10 days of conception.

After 23 weeks there is more variation in growth.

Croft *et al*²² has shown very little difference in ultrasound measurements in a study comparing aging in preserved fetuses and live fetuses. There was also no significant difference between manual and ultrasonographical measurements.

5.3 Anatomy visualized in the first trimester

- **Gestational sac**

The embryo is seen within the amniotic cavity. The yolk sac is still present. The trophoblast can be seen as a hyperechoic rim. The extra-embryonic coelom is directly external to the amniotic sac. The amniotic membrane can also be seen.

- **Crown-rump length (CRL)**

This is the longest length of the embryo, excluding the limbs and the yolk sac¹¹. CRL gives an excellent correlation between length and age at a phase where the embryo is rapidly growing and minimally affected by pathology. A longitudinal view of the embryo should be obtained. The measurement is done from the outer edge of the cephalic pole and the outer edge of the fetal rump. The average of three measurements is used. This measurement at 7 to 10 weeks is predictive of the menstrual age with an error of three days. The error increases to 5 days between 10 and 14 weeks gestation. The range of error is dependent on the biological variation in fetal size, variation in maturity and therefore fetal size, individual differences in the timing of ovulation and fertilization as well as errors made concerning measurement technique.

The CRL is related to tables based on reliable menstrual data²¹.

As pregnancy advances, most measurements are subject to increased biological variation.

- **Cardiac activity** – presence or absence of fetal life
- **Somatic activity**
- **Placental location**
- **Pelvic anatomy**

- **Fetal number**

5.4 Anatomy visualized in the second and third trimester

5.4.1 Estimation of gestational age

- **Biparietal diameter (BPD)⁴**

The BPD's accuracy is best between 17-23 weeks but can be done between 12 and 28 weeks gestation. The BPD as measured before 28 weeks forms a standard method of ultrasound dating¹⁷.

The BPD should be measured by standard consensus at the level of the thalami. Measurements rostral to the thalami, result in underestimation of the BPD and therefore of the gestational age.

The BPD measurement is done at a standard reference level, which includes the cavum septum pellucidum and both thalami. Head circumference is measured at the same level as the BPD.

The measurement is done from the outer table of the proximal skull to the inner table of the distal skull (as seen on the ultrasound screen)^{12,13}. The same landmarks should be used throughout pregnancy.

Some fetal heads are elongated and flattened giving an artificially decreased BPD. This condition is called dolichocephaly and is especially the case in fetuses that have premature rupture of membranes¹⁵.

In the presence of premature rupture of membranes in the third trimester, the BPD measurement is smaller than expected and consequently the gestational age of the fetus is underestimated¹⁵. This may be due to distortion of the fetal skull due to decreased amniotic fluid. To verify this the cephalic index should be determined. The cephalic index is the ratio of the BPD divided by the occipitofrontal diameter. The normal range of the cephalic index is 0.75 to 0.85¹⁴. If the cephalic index is close to either limit, the BPD should not be used for gestational age determination.

Due to growth disturbances and individual variation, which affect the size of the head, the BPD should not be used after 28 weeks gestation¹⁶.

The following should be seen on the plane where the BPD is measured:

The paired thalami are seen posterior to the cavum septum pellucidum. Anterior to the cavum septum pellucidum the falx cerebri can be seen. Laterally a curvilinear structure can be seen representing the insula. The frontal and occipital lobes as well as the choroid plexus in the anterior horn of the lateral ventricle can also be seen.

The coronal suture and lambdoid suture of the calvarium can sometimes be seen at this level. The posterior fossa with vermis and lateral lobes of the cerebellum can be seen, with the cisterna magna posterior to the cerebellum.

- **Head circumference**

Head circumference is less influenced by growth disorders than the BPD. It is not influenced by dolicocephaly or brachycephaly¹⁷. The head circumference is measured at the same plane as the BPD. The longest anteroposterior length (occipitofrontal diameter, OFD) is obtained and the head circumference determined according to the following formula:

$$\text{Head circumference} = (\text{BPD} + \text{OFD}) * 1.62$$

Ott¹⁷ has shown that the head circumference may more accurately predict gestational age when compared to BPD. Head circumference has a distinct advantage over BPD where the head shape is altered as in breech presentation or transverse lie.

- **Femur length¹⁸**

The femur length can be measured from 10 weeks onward. The measurement is done from the most proximal portion to the distal end of the shaft. The femoral head and the distal epiphysis are not included in the measurement.

Acoustical shadowing from other bones or the other femur can decrease the visible length of the femur.

Technique²⁵: The long axis of the fetus is first identified. The transducer is then turned 90° to produce a cross-sectional image of the trunk. The transducer is now moved downward to the fetal pelvis. The femur is usually flexed. Therefore the transducer must be rotated 30° - 45° toward the abdomen of the fetus to visualize the femur.

Tangential sections should be avoided for it will result in a too short measurement.

The ilium, ischium and distal femoral epiphyses should be avoided for they artificially increase the measurement.

Measurements are easy to perform. O'Brien²⁶ was unable to perform the measurements of 18 fetal femur lengths in more than 1000 examinations. These were breech presentations, where the fetal lower limbs were positioned deep in the pelvis. The pelvic bones obscured the visualization of the fetal femurs.

Fetal femur length accurately portrays gestational age up to 24 weeks.

- **Abdominal circumference²⁴**

The BPD (biparietal diameter) is sometimes difficult to obtain due to head position.

Abdominal circumference can easily be performed in the third trimester. The measurement is done on the level of the umbilical vein - ductus venosum complex and/or the fetal stomach as anatomical landmarks.

The measurement should not be performed on an oblique image of the abdomen for it will reflect a larger measurement than the actual circumference.

This measurement is used for fetal weight determination as well as to rule out intrauterine growth retardation by using the head circumference: abdominal circumference ratio. The ratio can distinguish asymmetrical intrauterine growth retardation from symmetrical

growth retardation¹⁹.

This measurement is very sensitive to variations in fetal growth.

5.4.2 Fetal anatomy

- Visualization of fetal anatomy improves with increasing gestational age. The need for transvaginal ultrasound, steadily decreases with increasing gestational age. The optimal gestational age to examine fetal anatomy in the first trimester is at 13 weeks².
- The following fetal organs can be visualized by means of a transabdominal and transvaginal ultrasound. Fetal organs are better visualized by transvaginal sonar compared to transabdominal ultrasound, and even better with both transabdominal and transvaginal ultrasound¹.

The following are stated as criteria for adequate visualization in a study done by Braithwaite *et al*¹ at 12 to 13 weeks of gestation:

Head: Complete cranium, septum pellucidum, thalami, choroid plexi, cerebellum and ventricles

Face:

The face starts developing in the second month.

Correct position of the mandibles, maxillae and orbits, lenses, nostrils, filtrum and ears.

Heart: Four-chamber view, symmetrical ventricles and atria

Diaphragm: Hypoechoic interface between abdomen and thoracic cavities

Stomach: Single hypoechoic structure in the left upper abdomen

Abdominal wall: Normal cord insertion and abdominal wall

Kidneys: Visualisation of cortex and pelvis of both kidneys

Bladder: Hypoechoic structure anteriorly in the midline of the pelvis

Spine: Complete vertebrae seen in both transverse and coronal planes with normal overlying skin

Extremities: visualization of long bones, correct posture of hands and feet.

- **Spine**

The spine starts to ossify at the tenth week of gestation. Three different ossification

centers form each vertebra, one central and two posterolateral ossification centers. The central ossification center forms the vertebral body and the two posterolateral centers the spinous process, laminae, pedicles, transverse processes and articular processes. Spina bifida can be evaluated between 16 to 20 weeks gestation with splaying of the paired posterolateral elements.

A coronal image demonstrates the developing vertebrae.

The vertebral bodies of the lumbar spine can be seen as unpaired hyperechoic blocks along the midline with paired hyperechoic segmental blocks representing the developing posterior laminae, which will develop into the pedicles and laminae. The distance between the paired posterior laminae should be relatively constant throughout the thoracolumbar spine. A widening between the paired posterior laminae may be due to a posterior fusion defect. A slight widening can be due to the ultrasound image passing through on this level. In the thoracolumbar region, the iliac wings can also be seen. There is a normal widening of the posterior elements in the cervical region. A sagittal section shows the hyperechoic vertebral bodies with between them the developing intervertebral discs.

- **Heart – chamber size and number, rate and rhythm, aortic arch and descending aorta as well as valves**

The anatomy of the heart and the kidneys are difficult to visualize in the first trimester. The four-chamber view is best seen at 13 weeks gestation, and at earlier gestations, there is an increasing incidence of artifacts, which may give a false impression of a ventriculoseptal defect².

At four weeks gestation, the two-chambered heart divides into the four-chambered configuration. This happens as a result of the formation of the endocardial cushions and the septum primum. The interventricular septum forms from the apex of the heart. The interatrial septum forms after the formation of the septum primum, ostium secundum, septum secundum and foramen ovale. The interatrial septum separates the atria except for the foramen ovale which close postnatally.

The normal right ventricle is more anteriorly situated and trabeculated. It also contains the visible moderator band extending from the interventricular septum to the apex of the heart.

The left ventricle is thick-walled and is associated with the apex. The interventricular septum can be seen. The echogenic fullness extending from the interventricular septum to the right ventricle is the moderator band. The posterior part of the septum is very thin and represents the membranous part of the septum.

The atrioventricular canals can be seen at the membranous part of the septum, with the mitral and tricuspid valves. The left and right atrium can be seen on the other side of the atrioventricular canals.

The interatrial septum can be seen with the patent part which represents the foramen ovale.

The descending aorta can be seen posterior to the left atrium.

- **Abdomen**

The gastrointestinal tract is formed from an endodermal midline tube. The abdominal cavity can not contain the developing gastrointestinal tract with its organs and is therefore located extra-abdominally, forming a normal physiological umbilical hernia which can be seen sonographically at 10 to 11 weeks. After the 11th week, the midgut returns to the abdominal cavity for further development.

The kidneys start functioning at the second month of gestation and a fluid –filled bladder can be seen between 11 and 14 weeks gestation.

A transverse section of the upper abdomen may illustrate the insertion of the umbilical cord to the anterior abdominal wall. Two linear hypoechoic structures represent the paired umbilical arteries. There are various normal cross-connections between the two umbilical arteries²³. These connections are called Hyrtl anastomosis after Hyrtl who described them in 1870. They occur in 96% of placentas and are usually found near the cord's insertion to the placenta. The anastomosis secures an even blood distribution over the surface of the placenta. There are normally two arteries and one vein in the umbilical cord. The umbilical vein can also be seen in the three-vessel cord.

The length of the cord varies greatly with a mean length of 59 cm. Excessively long cords are associated with fetal death due to entangling or twisting. Extremely short cords are associated with certain fetal anomalies like osteogenesis imperfecta.

The liver can be seen as an inhomogeneous structure occupying the ventral portion of the abdominal cavity. A cross sectional view of the fetal abdomen shows the stomach as well as the kidneys.

Care should also be taken not to confuse the adrenals in the first trimester with the kidneys. The adrenals have a dense medulla in contrast to the kidneys².

- **Central nervous system**

Most structures of the central nervous system are visible at 12 to 13 weeks gestation. The corpus callosum is completely formed at 3½ months gestation. The septum pellucidum and the cavum septum pellucidum are now also visible. The biparietal diameter (BPD) can be measured at this stage. The BPD should include the cavum septum pellucidum.

The cerebellum starts developing in week 11 to 12. Posterior to the cerebellum , the cisterna magna is found, which contains cerebrospinal fluid. Absence of this cistern, is indicative of Arnold-Chiari malformation.

5.4.3 Nonfetal anatomy

- Maternal bladder and cervix. Filling of the maternal bladder is not necessary from 12 to 13 weeks gestation onwards where adequate visualization is possible¹.
- Placenta – position and grade
- Amniotic fluid volume
- Uterus and adnexae
- Maternal gallbladder if visible

5.5 Time of appearance of various anatomical structures⁶ (Transabdominal ultrasound)

Gestational sac	5 weeks
Crown rump length	6-12 weeks
Fetal movement	7 weeks
Cardiac activity	7 weeks
Placenta	8 weeks
Yolk sac	7-11 weeks
Embryological period ends	10 weeks
Heart is fluid filled	12-13 weeks
Biparietal diameter	12-13 weeks
Abdominal circumference	12-13 weeks
Femur	12-13 weeks
Stomach	20 weeks
Lateral ventricles appear	12 weeks, characteristic appearance at 20 weeks
Choroid	20-24 weeks
Kidneys	17-22 weeks
Bladder	20 weeks
Heart valve motion	20 weeks
Majority of neurologic abnormalities present	24 weeks
Genitalia	25 weeks

Many of these structures can be visualized with a transvaginal ultrasound at an earlier gestational age.

5.6 Placenta

The position of the placenta before the third trimester may differ considerably from that at birth. This is due to the enlarging lower segment of the uterus, with resultant change in the placental position.

5.7 Position of the uterus.

Reichler *et al*³ showed in a study that uterine fundal pressure in a bimanual fashion, significantly enhanced the visualization of lower limbs, head, upper limbs, kidneys, spine, gender, face and four chamber view of the heart in transvaginal ultrasounds. By applying fundal pressure, the fetus is more closely approximated to the transvaginal transducer. As the maternal weight increases, fundal pressure becomes more ineffective.

5.8 Amniotic fluid

Ultrasound guided late pregnancy amniocentesis to determine lung maturity is done by identifying pockets of amniotic fluid which are not covered by the placenta, are free of

the umbilical cord and away from the fetal face. Sometimes it is impossible to get a pocket. In such cases an assistant can elevate the fetal head abdominally and then perform the tap suprapubically. The needle is then inserted between the fetal head and the endocervix.

5.9 Fetal biophysical profile⁶

This is an objective scoring system to evaluate fetal wellbeing. It includes breathing movements, muscle tone, placental grade, amniotic fluid volume and heart rate activity. This data can be captured while doing the biometry and fetal anatomy survey.

5.10 Vaginal ultrasound⁶

This route places the tranvaginal transducer closer to the pelvic anatomy and will display fetal anatomy about 1 week earlier than the abdominal route.

5.11 Umbilical versus paraumbilical window

Davidoff *et al*²⁷ demonstrated in a study of 68 patients that the umbilical window to visualize the gravid uterus is better than the paraumbilical window. He compared the two windows regarding the thickness of the tissue to the amniotic cavity, clarity of the imaged part and noise produced.

The paraumbilical tissue had a mean thickness of 18 mm, whereas the umbilical tissue thickness had a mean measurement of 11 mm. Improvement of the image clarity was not statistically different when the umbilical and paraumbilical window were compared. The clarity was however improved by 60% in patients where there was a difference in tissue thickness of more than 6 mm between the umbilical and paraumbilical tissue thickness. In a small number of patients the clarity of the image was worse through the umbilical window. This may be due to dense fibrous tissue within the umbilicus.

There was relatively less noise through the umbilical window.

The umbilical window is therefore particularly useful in obese patients.

The umbilicus consist of skin, fibrous tissue and no fat.

The paraumbilical window consist of skin, subcutaneous fat of variable thickness, fibrous tissue and rectus abdominis muscle of variable thickness. The difference between the two windows can clearly be seen on a CT scan of the abdomen.

Histologically the umbilicus consists of epidermis, dermis and connective tissue. The paraumbilical window consists of epidermis, dermis, hypodermis, a variable amount of fat and muscle.

The rectus abdominis muscle also contains connective fibrous tissue and three pairs of tendinous intersections. The tendinous intersections are situated at the xiphoid level, umbilical level and midway between those levels.

The signal returning to the transducer is dependent on the transmission of the ultrasonic waves. Various tissues in the path of the ultrasonic beam affect the strength of the signal.

In the first trimester, bowel may intervene with the ultrasonic beam when the umbilical window is used due to the relative small size of the uterus.

Another limitation of the umbilical window is the relatively small size of the umbilicus compared to the relatively large transducer.

6. Complications (anatomically relevant)

6.1 Poor visualization

Poor visualization¹ for transabdominal ultrasound in women with a high body mass index (BMI) and retroverted uterus. A transvaginal ultrasound is indicated in these patients.

6.2 Inappropriate use⁶

- It is inappropriate to do an obstetric ultrasound examination for gestational age before 10 weeks or after 20 weeks. Morphometric features are not clearly visible before 10 weeks, and after 20 weeks gestational age determination by dates is as accurate⁹.
- Routine screening of all pregnancies.
- Determination of fetal sex unless sex-linked abnormalities are suspected.
- Casual non systematic evaluation.

6.3 Incomplete anatomical survey⁶

Due to factors as fetal position, maternal factors and gestational age, the anatomical survey may be incomplete. The average success rate for visualization of individual organs range from 70% to 90%.

Only 1% to 2% of fetuses have an anatomical anomaly.

7. References

¹ Braithwaite JM, Armstrong MA, Economides DL. Assessment of fetal anatomy at 12 to 13 weeks of gestation by transabdominal and transvaginal sonography. *Br J Obstet Gynaecol* 1996, 103: 82-85

² Whitlow BJ, Economides DL. The optimal gestational age to examine fetal anatomy and measure nuchal translucency in the first trimester. *Ultrasound Obstet Gynecol* 1998; 11:258-261

³ Reichler AVI, Sherer DM, Divon MY. Transvaginal sonographic imaging of early second trimester fetal anatomy assisted by uterine fundal pressure. *Obstetrics and Gynecology* 1997, 89:949-952

⁴ Deter RL, Harrist RB. Growth standards for anatomic measurements and growth rates derived from longitudinal studies of normal fetal growth. *J Clin Ultrasound* 1992, 20:381-388

⁵ Smith CB, Sakornbut EL, Dickinson LC, Bullock GL. Quantification of training in obstetrical ultrasound: a study of family practice residents. *J Clin Ultrasound* 1991; 91:479-483

⁶ Rodney WM, Deutchman ME, Hartman KJ, Hahn RG. Obstetric ultrasound by family physicians. *J Fam Pract* 1992; 34: 186-200

⁷ Leopold GR. Antepartum obstetrical ultrasound examination guidelines. *J Ultrasound*

Med 1986;5: 241-2

⁸ Guidelines for performance of the antepartum obstetrical ultrasound examination (AIUM). *J Ultrasound Med* 1991; 10:10

⁹ Campbell S, Warsof SL, Little D, Cooper DJ. Routine ultrasound screening for the prediction of gestational age. *Obstet Gynecol* 1985; 65:613-20

¹⁰ Rieck RW, Crum P, Jeanty P. Fetal Anatomy. In: Fleischer AC, Manning FA, Jeanty P, Romero R. *Sonography in Obstetrics and Gynecology. Principles and Practice*. 5th Ed. Stamford: Appleton & Lange, 1996: 109-147

¹¹ Robinson HP, Fleming JEE. A critical evaluation of sonar crown-rump length measurements. *Br J Obstet Gynecol* 1975; 82: 702-710

¹² Hadlock FP, Deter RL, Harrist RB et al. Fetal biparietal diameter: a critical re-evaluation of the relation to menstrual age by means of realtime ultrasound. *J Ultrasound Med* 1982; 1:97-104

¹³ Shepard M, Filly RA. A standardized plane for biparietal diameter measurement. *J Ultrasound Med* 1982; 1:145-150

¹⁴ Jeanty P. Fetal biometry. In: Fleischer AC, Manning FA, Jeanty P, Romero R. *Sonography in Obstetrics and Gynecology. Principles and Practice*. 5th Ed. Stamford: Appleton & Lange, 1996: 131- 147

¹⁵ Wolfson RN, Zador IE, Halvorsen P et al. Biparietal diameter in premature rupture of membranes: Errors in estimating gestational age. *J Clin Ultrasound* 1983; 11:371-374

¹⁶ Selbing A, Kjessler B. Conceptual dating by ultrasonic measurement of the fetal biparietal diameter in early pregnancy. *Acta Obstet Gynecol Scand* 1985; 64: 593-597

¹⁷ Ott WJ. The use of ultrasonic fetal head circumference for predicting expected date of confinement. *J Clin Ultrasound* 1984; 12: 411-415

¹⁸ Hadlock FP, Harrist RB, Deter RL, et al. Fetal femur length as a predictor of menstrual age: Sonographically measured. *AJR* 1982; 138: 875-878

¹⁹ Deter RL, Harrist RB, Hadlock FP et al. Fetal head and abdominal circumferences. II: A critical evaluation of the relationship to menstrual age. *J Clin Ultrasound*. 1982; 10: 365-372

²⁰ O'Rahilly R. Gestational Age? *Clin Anat* 1997; 10: 367

²¹ Drumm JE, Clinch J, MacKenzie G. The ultrasonic measurement of fetal crown-rump length as a method of assessing gestational age. *Br J Obstet Gynaecol* 1976; 83: 417-421

²² Croft MS, Desal G, Seed PT, Pollard JI, Perry ME. Application of obstetric ultrasound to determine the most suitable parameters for the aging of formalin-fixed human fetuses using manual measurements. *Clin Anat* 1999; 12: 84-93

²³ Benirschke K. Remarkable placenta. *Clin Anat* 1998; 11: 194-205

²⁴ Hadlock FP, Deter RL, Harrist RB, Park SB. Fetal abdominal circumference as a predictor of menstrual age. *AJR* 1982; 139: 367-370

²⁵ O'Brien GD, Queenan JT, Campbell S. Assessment of gestational age in the second trimester by real-time ultrasound measurement of the femur length. *Am J Obstet Gynecol* 1981; 139: 540

²⁶ O'Brien GD, Queenan JT. Growth of the ultrasound fetal femur length during normal pregnancy. *Am J Obstet Gynecol* 141:833-837, 1981

²⁷ Davidoff A, Reuter K, Karellas A, Baker S, Raptopoulos V. Maternal umbilicus: Ultrasound window to the gravid uterus. *J Clin Ultrasound* 1994; 22:263-7

4. Results (Cont.)

4.5 Development of a clinical anatomy training program

A multimedia CD-ROM based on a PowerPoint® platform was developed for the reasons mentioned earlier in 3.4. This provides a stimulating environment for study with an innovative combination of learning resources regarding clinical anatomy for procedures relevant to general practitioners in South Africa. Appropriate use was made of new learning technologies to facilitate teaching and learning.

The emergency procedures and two office procedures were chosen as a realistic starting point illustrating the principles and philosophy of designing a novel self directed teaching aid for practical procedures. The aim is to progress in incorporating all 15 selected procedures, but for the sake of the PhD it was decided to limit these to 8.

The program was developed in what is called a Virtual Procedures Clinic (**Attached as CD-ROM**). This virtual clinic environment introduces the student to various rooms in a virtual clinic.

The following rooms are accessible in a non-linear format:

Orientation room

This room provides a quick overview of all the procedures that are covered in the program.

Clinical anatomy laboratory

This room provides the visual representation of the anatomical pitfalls and complications of all the procedures. These sections can be accessed in a non-linear way for every procedure.

Simulation room

A simulation of all the procedures can be visualized in this room. They are represented as animations on prosections. All the simulations can be accessed in a non-linear way.

Clinical background room

This room provides background information for every procedure regarding the following aspects: Indications, contraindications, materials necessary for the performance and a step by step way to perform the procedure.

Library

The library contains the full text papers of all the procedures as well as all the references

used to compile this clinical anatomy knowledge base.

The following media were used in an interactive manner:

- Text with hypertext where relevant.
- High resolution images of dissections of relevant anatomy.
- Animations on the prosections created in PowerPoint®.
- Audio clips.
- Simulations of the performance of the procedure was done on prosections and created in PowerPoint®.
- Short video clips.

All these media were hyperlinked where relevant to ensure the creation of clinical anatomy correlations as well as a non-linear way of accessing the data.

The CD-Rom is available on the front page of this document and can be loaded in the following way:

System requirements: Powerpoint 2000
100 MHz Computer 32MB
CD-ROM drive facility

Loading instructions:

Turn the computer on and go to the “My Computer” selection.
Select the CD-ROM drive.
Select the Virtual Procedures Clinic file.
This will open the Virtual Procedures Clinic in PowerPoint®.

5. Discussion

5.1 Development and conduction of survey

The questionnaire used in this study was developed like the list of Heikes²⁷ on Spivey's⁶³ method to determine curriculum content. This technique consists of analyzing and delineating potential performances from various sources and then presenting this to the appropriate group of respondents. For the present study this involved the compilation of a list of clinical procedures important for general practitioners in South Africa. The list was compiled by an extensive literature research study, personal experience and discussions with general practitioners and faculty. A list of 57 procedures was compiled and a questionnaire developed to assess various aspects of procedures performed including the role of the underlying anatomy.

Of the 102 questionnaires obtained, 5 were not fully completed and were therefore not included in the study. A total of 97 questionnaires were therefore analyzed. All the questionnaires were filled out by general practitioners in the various hospital practices. Hospitals in three provinces were selected and all the general practitioners present at a random date filled out the questionnaire voluntarily and anonymously. Although 3 provinces in South Africa were included in the study, the scenario for clinical procedures in other parts of South Africa may be somewhat different. This study may therefore have limited geographic generalizability. It is thought however, that the data presented reflect a general picture due to the representative number of general practitioners that took part in the study in Gauteng, Northern Province and Mpumalanga. A limitation of the study is the fact that the different hospitals were not randomly selected in the sense that each hospital had an equal chance to be selected. The aim was however to obtain two groups of hospital practices where at least 40 different respondees could be obtained.

This study embarked on an evidence-based medicine approach for procedural training for general practitioners. It may serve as a basis on which procedures should be taught in residency programs to prepare general practitioners for their future practice as well as for continued medical education courses. There is a need for assessing real, perceived and expressed educational needs in South Africa as pointed out by De Villiers⁵⁰. This study addresses the educational needs of general practitioners regarding procedural competence. Similar studies have been conducted in Australia⁶⁴ and The Netherlands⁶⁵. Data from these studies proved relevant to health care planning and education regarding the demand on doctors to perform clinical procedures.

Abrahams⁶⁶ performed a similar study in 1985, which did not focus specifically on the clinical anatomy of procedures, but a broad evaluation of the applications of anatomy in general practice. In his study, three levels of anatomical knowledge were considered which were 1) no anatomy needed during the consultation, 2) routine physical examination and 3) surface anatomy and detailed specific anatomical knowledge required for specific diagnosis and clinical reasoning. It was found that especially in the second group, anatomy was essential in 62.5% of 4131 consultations. The evidence base that this study revealed has great implications for clinical training of general practitioners. There

is however a need to extent this evidence base to unique circumstances in developing countries also with regard to procedural training of doctors.

The demographic characteristics reveal important information, which is necessary to have when developing any procedural training program. It is of great importance to know the target audience in order to focus on their specific characteristics and therefore not over- or underestimate their competence³¹.

Concerning the age of general practitioners, the rural doctors group in hospital practice are notably younger than the urban doctors group with 55% of rural doctors in the age group 23-30 years compared to 39% of the urban doctors. Regarding sex, it was found that more doctors in rural hospitals are male (73%) compared to urban doctors (60%). This is similar to findings in Australia⁶⁴. This may be explained by the fact that young doctors are more likely to work in rural hospital practices because of the opportunity to gain hands on experience and the possible absence of family commitments which are better met in urban areas.

Overall urban doctors seem more experienced regarding their years in hospital practice, although both groups consist of doctors with no more than 5 years in practice since graduation, 42% for the urban doctors and 62% for the rural doctors.

It is not surprising that urban doctors overall have more postgraduate training, due to both the fact that they are older and therefore have more years in practice and the fact that more opportunities exist in urban hospitals regarding postgraduate medical training. This also explains the higher competency levels found in the study. It is encouraging to note that nearly a third (30%) of the urban doctors have done or are busy with the postgraduate masters training in Family Medicine (MMedFam Med) and a fifth (21%) of the rural doctors.

5.1.1 Incidence of performance

Various bodies have compiled lists for what is regarded as core procedures in family practice. The National Health Services (NHS) in the UK has compiled such a list of procedures³⁷.

It is clear from our data that this list is very different from the procedures that general practitioners perform in South African hospital practices. General practitioners perform a wide range of procedures, which include procedures that are usually performed by specialists in developed countries. The number of the procedures varies with the nature of the practice situation, whether urban or rural, which confirms data presented by other studies^{44,45,46,47}.

Our study shows that general practitioners in hospital practices perform a wide variety of procedures, ranging from non-invasive procedures such as interpretation of radiographic images to invasive surgical procedures like cesarean sections and appendectomies.

Various other procedures were listed by the responding doctors for both urban and rural practices. They are listed in section 4.1.1 and were listed by individual doctors and were

not by any means noted by the majority of practitioners. These procedures should also be evaluated in future studies for most of them are not only invasive, but rely strongly on a sound anatomical understanding.

- **Emergency procedures**

Regarding emergency procedures, it is striking that almost all procedures evaluated are performed by more than 50% of the doctors. Exceptions are cricothyroidotomy (26.32%), pericardiocentesis (23.16%), pretibial intraosseous puncture/infusion (41.05%) and internal jugular vein catheterization (45.26%). These procedures either have alternatives which scored highly or have a lower incidence because they are less often needed.

Procedures with an extremely high incidence include oro/nasotracheal intubation (95.79%), intercostal drain insertion (90.53%), lumbar puncture (90.53%), eye injury examination (89.47%) and suprapubic puncture and catheterization (75.79%). It is clear that the demand for competency in emergency procedures is very high.

- **Surgical procedures**

Regarding surgical procedures, although less often performed when compared to emergency procedures, a substantial number are very often performed. They include dilatation and curettage (80.00%), normal vaginal delivery (78.95%), cesarean section (74.74%), episiotomies (73.68%), circumcision (72.63%), sterilization (70.53%) and reduction of uncomplicated forearm fractures (69.47%).

These are almost all highly invasive procedures, which are almost certainly performed by specialists like obstetricians and gynecologists, general surgeons or orthopedic surgeons in developed countries. The importance of sound surgical procedural training is underscored by these figures.

Procedures that are seldomly performed include pudendal nerve block (15.79%) and brachial plexus block (16.84%). Surprisingly sigmoidoscopy and proctoscopy are seldomly performed (29.47%). This may be due to the fact that the procedures were not separated in the questionnaire for there may be more doctors who perform a proctoscopy compared to a sigmoidoscopy.

- **Office procedures**

Concerning office procedures, rectal examination (97.89%) and vaginal examination (98.95%) are performed extremely often as would be expected.

Others like the management of epistaxis (95.79%), aspiration of pleural effusions (85.26%), reduction of shoulder dislocation (81.05%), knee joint aspiration (78.95%) are very often performed.

Surprisingly, injection of the shoulder joint (29.47%), indirect laryngoscopy (30.53%)

and nasopharyngoscopy (10.53%) are not often performed. These procedures are very effective and not invasive. There may be a lack of understanding of the value of these procedures.

Upper gastrointestinal endoscopy (9.47%), colposcopy (14.74%) and slit lamp examination (13.68%) are seldomly performed as was expected. Lack of specialized equipment may be one reason.

- **Imaging procedures**

Concerning imaging procedures, the following are performed extremely often as is expected: abdominal X-ray (93.68%), chest X-ray (92.63%), pelvic X-ray (92.63) and neck X-ray (91.58%).

Very surprisingly is the fact that an obstetric ultrasound is performed very often (82.11%) and an abdominal ultrasound by nearly two thirds of doctors (58.95%). Residency programs rarely offer training programs in these imaging procedures and training is often done by courses in a continued medical education environment.

Musculoskeletal ultrasound is very seldomly performed (9.47%). These doctors are thought to have a special interest in Sports Medicine.

Although there are regional differences regarding which procedures are performed, we agree with Wigton⁶⁷, who did similar work regarding procedures relevant to internal medicine, that there should be a core of procedural skills that family physician residents require. Wigton⁶⁷ defined this core to be those procedures, which are performed by over 90% of general practitioners.

If we apply this rule to our study, the following procedures may be considered as core procedures: oro/nasotracheal intubation, vascular access: peripheral arm veins, intercostal drain insertion, lumbar puncture, epistaxis and nasal packing, rectal examination, vaginal examination, chest X-Ray, abdominal X-Ray, pelvic X-Ray and neck X-Ray.

It is however important that more factors need to be considered regarding selecting a core set of procedures. These include the apparent life saving nature of the procedure, the complications and difficulties involved, the essentiality of the procedure in the practice situation as well as the comfortability of the family physician performing the procedure. The high number of procedures performed as revealed by the present study, reflect an enormous continuing educational challenge for family practice as a profession.

5.1.2 Frequency of performance

Procedures with a high frequency of performance (> 20 per annum) include:

- **Emergency procedures:** Vascular access via peripheral arm veins (91.58%)
Oro/nasotracheal intubation (52.63%)
Lumbar puncture (42.11%)
Eye injury examination (42.11%)
- **Surgical procedures:** Dilatation and curettage (49.47%)
Cesarian section (41.05%)
Normal vaginal delivery (35.79%)
Reduction of uncomplicated forearm fractures (29.47%)
Circumcision (25.26%)
- **Office procedures:** Vaginal examination (95.79%)
Rectal examination (82.11%)
Aspiration of pleural effusion (31.58%)
- **Imaging procedures:** Chest X-ray (86.32%)
Abdominal X-ray (75.79%)
Pelvic X-ray (68.42%)
Neck X-ray (65.26%)
Obstetric ultrasound (44.21%)

One expects general practitioners to be reasonably proficient in the performance of these procedures. This may however not be the case with all these procedures for the following were actually selected as problem procedures: oro/nasotracheal intubation, lumbar puncture, cesarian section, reduction of uncomplicated forearm fractures, rectal examination and obstetric ultrasound. The frequency of performance is therefore not an indication of the proficiency with a certain procedure.

Procedures with a lower frequency of performance (< 5 per annum) include (percentage represents the doctors performing this procedure not more than 5 times per annum):

- **Emergency procedures:** Vascular access via the great saphenous vein (74.07%)
Cricothyroidotomy (23.16%)
Subclavian vein catheterization (32.63%)
Internal jugular vein catheterization (29.47%)
Pretibial intraosseus puncture/infusion (27.37%)
Suprapubic puncture and catheterization (29.47%)
Umbilical line placement (26.32%)
- **Surgical procedures:** Appendectomy (21.05%)
Ectopic pregnancy surgery (26.32%)
- **Office procedures:** Reduction of shoulder dislocation (32.63%)
Epistaxis and nasal packing (29.47%)
Reduction of elbow dislocation (27.37%)

Paronychia incision and drainage (23.16%)

- **Imaging procedures:** Nil

These procedures are therefore performed by most doctors but not more than five times a year. This may be a compromising factor in competency. However, Wigton⁶⁸ states that the number of procedures done per annum does not reflect proficiency in performing the procedure.

This notion is underscored by our data for a number of procedures with a high frequency of performance where selected as problem procedures as some with a lower frequency of performance where not selected as problem procedures. Usually the number of procedures that need to be done before attaining competency, is higher than the recommendations of expert panels. Few studies have attempted to determine how many supervised performances of a procedure are necessary to provide competence. It is difficult to know for any procedure what amount of experience and supervision is needed to attain competency⁴¹. The old saying of “see one, do one, teach one”, is simply not good enough for competency.

In a study by Hawes *et al*⁶⁹, it was found that for acquiring competency in flexible sigmoidoscopy, 24-30 procedures are required. Competency in their study included correct insertion distance, number of lesions correctly identified and number of correct diagnoses and management scores.

5.1.3 Importance rating

- **Emergency procedures**

Procedures that were rated as essential by more than 60% of general practitioners were in order:

- Vascular access via the peripheral arm veins (98%)
- Intercostal drain insertion (86%)
- Oro/nasotracheal intubation (85%)
- Eye injury examination (80%)
- Lumbar puncture (77%)
- Suprapubic puncture and catheterization (66%)
- Arterial puncture (62%)

Alarming is that less than 50% thought that a life saving procedure such as cricothyroidotomy (47%) was essential and nearly 10% thought it was not necessary.

Although less than 50% thought that vascular access via the great saphenous vein (37%) was an essential procedure, nearly 30% thought the procedure is useful and 24% thought the procedure is desirable. This reflects the fact that alternative vascular approaches like peripheral arm veins and the femoral vein is attempted before the great saphenous vein.

The insertion of a pretibial interosseous infusion was regarded by 51% to be an essential procedure. This certainly reflects the importance of this procedure regarding the rehydration of dehydrated children in hospital practice in the three studied provinces of South Africa and is a very specific finding as this procedure is rarely, if ever, performed outside a pediatric specialist unit in the United Kingdom or United States of America.

The high rating of the importance of emergency procedures by general practitioners reflects their important role in emergency care in hospital practices in the three studied provinces in South Africa. One reason for this certainly is the important role of the family physician's responsibility as the primary health worker of the unselected patient. Another reason for this may be due to amongst other factors, the high emergency patient load seen at hospital practices that has recently been reported⁷⁰.

- **Surgical procedures**

Surgical procedures that were rated as essential by more than 60% of general practitioners were in order:

- Dilatation and curettage (76%)
- Normal vaginal delivery (71%)
- Reduction of uncomplicated forearm fractures (70%)
- Cesarian section (67%)
- Episiotomy (67%)
- Ectopic pregnancy surgery (65%)

Sigmoidoscopy and proctoscopy was rated as essential by only 30% of general practitioners. This may be due to the fact that these procedures were not separated in the questionnaire, for more general practitioners may possibly rate a proctoscopy as more essential when compared to a sigmoidoscopy.

Although only 39% of general practitioners reported to perform an appendectomy, nearly 50% thought it is an essential procedure to perform. This reflects the need to perform this procedure although it is not as often performed. It may be explained by the fact that only 30% feel comfortable with performing an appendectomy, as well as 23% reporting difficulties due a lack of practical skills. A percentage of 51 thought that improving anatomy knowledge necessary to perform an appendectomy will increase their confidence in performing the procedure and 50% thought that it will reduce difficulties and complications. There does therefore exist a great educational challenge regarding the performance of an appendectomy.

Regarding invasive regional anesthetic procedures, both pudendal nerve block (19%) and brachial plexus block (20%) seem not to be regarded as essential by most general practitioners.

- **Office procedures**

Office procedures that were rated as essential by more than 60% of general practitioners

were in order:

- Rectal examination (96%)
- Vaginal examination (95%)
- Epistaxis and nasal packing (82%)
- Reduction of shoulder dislocation (67%)
- Knee joint aspiration (60%)

Only 23% regarded shoulder joint injection to be essential, although 25% regarded the procedure as useful. This is not surprising, for injection of the shoulder joint is an important part of the treatment and diagnosis of shoulder joint problems, but certainly not essential.

The same is true for upper gastrointestinal endoscopy, liver biopsy, bone marrow aspiration and slit lamp examination, where only 20%, 18%, 30% and 18% respectively thought the procedure to be essential, but 30%, 26%, 18% and 25% respectively regarded the procedure as useful.

Surprisingly only 27% of general practitioners regarded an indirect laryngoscopy and only 24% a nasopharyngoscopy as essential. These procedures are important in the primary diagnostic investigation of suspected vocal cord and nasopharynx pathology respectively. It seems that the role of these procedures need more emphasis in teaching programs.

Wrist and digital nerve block was rated by nearly half (48%) of doctors to be essential and only by 8% as not necessary. This reflects the high expectation of general practitioners to manage hand injuries.

- **Imaging procedures**

Imaging procedures that were rated as essential by more than 60% of general practitioners were in order:

- Chest X-ray (88%)
- Neck X-ray (88%)
- Abdominal X-ray (86%)
- Pelvic X-ray (82%)

Obstetric ultrasound was regarded by 58% as essential and 26% as desirable which with the high performance rate (82%) of the procedure, illustrates the fact that this procedure is regarded as an important one in hospital practice in the studied three provinces in South Africa, an issue that is often debated⁷¹.

5.1.4 Measure of comfort rating

Although it may be argued that a score that rates how comfortable a family physician is with his own performance of a procedure may be seen as very subjective, it does provide important information on self assessment of proficiency and identifying what may be

called problem procedures. This rating does not point to where the exact problem is, whether there is a deficiency regarding knowledge or skills, but it does provide a global self-assessment. The results of this study compares well with a Canadian study⁷² where Canadian general practitioners reported not to feel comfortable in performing procedures such as simple fracture reduction, intravenous access, lumbar puncture and endotracheal intubation.

- **Emergency procedures**

Although 96% of family physician perform oro/nasotracheal intubation, only 51% regard themselves as being very comfortable with the procedure.

This is even more striking for cricothyroidotomy, where 26% reported to perform the procedure, but only 1% regard themselves as very comfortable with this life saving procedure and 32% as uncomfortable and very uncomfortable.

The same is true for pericardiocentesis and vascular access via the great saphenous vein, where 23% and 57% respectively report to perform the procedure, but only 3% and 12% respectively regard themselves to be very comfortable with the procedure and 32% and 22% as uncomfortable and very uncomfortable respectively.

Similar results were observed for subclavian vein catheterization, internal jugular vein catheterization and pretibial interosseous puncture/infusion where 57%, 45% and 41% perform the procedure respectively, but only 12%, 8% and 12% regard themselves to be very comfortable with the procedures and 27%, 30% and 20% as uncomfortable and very uncomfortable with the respective procedures.

These figures reflect a high incidence of performance, but not necessarily a high comfortability score, which amongst other reasons may reflect on the underlying anatomy necessary to perform a safe and successful procedure. They should be regarded as problem procedures and therefore receive priority in continued educational procedural training.

The incidence of vascular access via the peripheral arm veins is very high (100%). A Measure of comfort rating of only 2% being uncomfortable with the procedure correlates well with the high incidence.

The same can be said for intercostal drain insertion and lumbar puncture, where 91% report to perform both procedures and only 3% and 4% respectively report to be uncomfortable and very uncomfortable with the procedure.

Regarding eye injury examination, most general practitioners report to be fairly comfortable (56%).

Procedures where more general practitioners felt uncomfortable (score of uncomfortable plus very uncomfortable) than comfortable (score of comfortable plus very comfortable)

were: cricothyroidotomy, pericardiocentesis and internal jugular vein catheterization. These procedures are indeed of a life saving nature and also carry high-risk anatomically related complications if performed incorrectly.

- **Surgical procedures**

Although 69% of general practitioners perform reduction of uncomplicated forearm fractures, only 30% report to be very comfortable with the procedure.

Similar findings were true for the performance of a normal vaginal delivery, cesarian section, ectopic pregnancy surgery and appendectomy, where 79%, 75%, 55% and 39% of general practitioners respectively reported to perform the procedures and only 47%, 42%, 28% and 12% of general practitioners respectively, report to be very comfortable with the procedures.

These figures reflect a relatively high incidence of performance, but not necessarily a high comfortability score, which amongst other reasons may reflect on the underlying anatomy necessary to perform a safe and successful procedure. They should be regarded as problem procedures and therefore receive priority in continued educational procedural training.

The high rate of no response to this assessment found for especially pudendal nerve block (68%), brachial plexus block (59%) and tonsillectomy and adenoidectomy (58%) correlates well with the low performance rate of these procedures, 16%, 17% and 27% respectively.

Procedures where more general practitioners felt uncomfortable (score of uncomfortable plus very uncomfortable) than comfortable (score of comfortable plus very comfortable) were: sigmoidoscopy and proctoscopy, appendectomy, pudendal nerve block and brachial plexus block.

- **Office procedures**

The performance rate of both rectal and vaginal examination was extremely high as expected, 98% and 99% respectively. A Measure of comfort rating of 0% and 2% respectively as being very uncomfortable correlates well with the high incidence. There seems however to be more doctors to be very comfortable with vaginal examination (90%) compared to rectal examination (86%).

Although 79% of general practitioners perform knee joint aspiration, only 48% report to be very comfortable with the procedure.

The same is true for the performance of wrist and digital nerve block, shoulder joint injection, epistaxis and nasal packing, aspiration of pleural effusion, reduction of shoulder dislocation, reduction of elbow dislocation, reduction of interphalangeal joint dislocation and reduction of hip joint dislocation. Table 31 illustrates the figures.

Procedure	Performance rate	Comfortable (very comfortable and fairly comfortable)
Wrist and digital nerve block	58%	52%
Shoulder joint injection	29%	23%
Epistaxis and nasal packing	96%	85%
Aspiration of pleural effusion	85%	85%
Reduction of shoulder dislocation	81%	68%
Reduction of elbow dislocation	54%	44%
Reduction of interphalangeal joint dislocation	65%	60%
Hip joint dislocation	28%	20%

Table 31. Office procedures with a high incidence of performance but significantly lower measure of comfort rating.

These figures reflect a relatively high incidence of performance, but not necessarily a high comfortability score, which amongst other reasons may reflect on the underlying anatomy necessary to perform a safe and successful procedure. They should therefore be regarded as problem procedures and receive priority in continued educational procedural training.

Procedures where more general practitioners felt uncomfortable (score of uncomfortable plus very uncomfortable) than comfortable (score of comfortable plus very comfortable) were: colposcopy, upper gastrointestinal endoscopy, liver biopsy, reduction of hip joint dislocation, nasopharyngoscopy and slit lamp examination.

- **Imaging procedures**

Although a high performance rate is reported for a number of imaging procedures, a significantly lower number of doctors report to be very comfortable with the procedures. This is illustrated in Table 32.

Procedure	Performance rate		Comfortable (very comfortable and fairly comfortable)
Chest X-ray	93%	} Interpretation	89%
Abdominal X-ray	94%		86%
Pelvic X-ray	93%		82%
Neck X-ray	92%		78%
Obstetric ultrasound	82%	} Performance and interpretation	67%
Abdominal ultrasound	59%		37%

Table 32. Imaging procedures with a high incidence of performance but significantly lower measure of comfort rating.

Especially regarding obstetric ultrasound and abdominal ultrasound these figures does raise concern regarding the very high performance rate, but relative uncomfotability with which these procedures are performed, with 19% and 28% reporting to be uncomfortable and very uncomfortable respectively for these two procedures.

These figures reflect a very high incidence of performance, but not necessarily a high comfortability score, which amongst other reasons may reflect on the underlying anatomy necessary to perform a safe and successful procedure. They should also be regarded as problem procedures and therefore receive priority in continued educational procedural training.

The low rate of interpretation of both abdominal and brain CT scans by general practitioners, correlates well with the high assessment of doctors being uncomfortable and very uncomfortable with interpreting these scans, 24% and 28% respectively. This is not surprising, as these imaging procedures are usually interpreted by specialists in hospital practices where CT scanners are available, which in our study is limited to the Kalafong and Pretoria Academic Hospitals.

Procedures where more general practitioners felt uncomfortable (score of uncomfortable plus very uncomfortable) than comfortable (score of comfortable plus very comfortable) were: musculoskeletal ultrasound, abdominal CT scan and brain CT scan.

5.1.5 Difficulties of performance

Four categories of difficulties were defined and assessed for all the procedures. They are i) knowledge of the procedure, ii) practical skills, iii) equipment necessary and iv) regional anatomy knowledge. Especially knowledge of the procedure, practical skills and regional anatomy knowledge are interrelated, as anatomical knowledge is a key feature to

the procedural skill exercised. Clinically relevant anatomy related to the specific procedure cannot be separated from practical skills with which a procedure is performed²¹.

The no response option was rated relatively high in most procedures. This could be interpreted in several ways. The most likely explanation is that it represents the fact that no difficulty mentioned was experienced concerning the specific procedure. It may however also reflect a degree of uncertainty in what is actually meant by the difficulties mentioned. Although the options “equipment necessary” and “regional anatomy knowledge” seem straight forward, the options “knowledge of the procedure” and “practical skills” may be widely interpreted. Thirdly non-respondents may think they have no difficulty with the procedure, but may actually have some difficulties after being specifically alluded to it. An example is for instance the no response reported for injury of the saphenous nerve related to a venous cutdown of the great saphenous vein. It can be argued that few respondents actually are aware of this nerve and therefore are unaware of its possible injury when performing a cutdown.

- **Emergency procedures**

Practical skills were reported in most procedures and by most doctors as the greatest difficulty. These included the following procedures: oro/nasotracheal intubation (23%), cricothyroidotomy (23%), vascular access via the femoral vein (22%), subclavian vein catheterization (30%), intercostal drain insertion (20%), lumbar puncture (16%), arterial puncture (20%), pericardiocentesis (20%) and umbilical line placement (21%).

Knowledge of the procedure was reported to be the greatest difficulty in vascular access via the great saphenous vein (20%).

Equipment necessary to perform the procedure, was regarded as the greatest difficulty in pretibial interosseous puncture, suprapubic puncture and catheterization and eye injury examination. This is most probably due to the unavailability of specialized needles for the performance of pretibial interosseous punctures and suprapubic catheterization, as well as the availability of a good light source for eye examination.

Regional anatomy knowledge was regarded as a difficulty in especially the following procedures: eye injury examination (20%), subclavian vein catheterization (16%), vascular access via the great saphenous vein (13%), lumbar puncture (12%) and internal jugular vein catheterization (13%).

This should however be placed in the perspective of the very strong indication given by the vast majority of doctors that improvement in the critical anatomy knowledge necessary to perform the procedures will reduce difficulties and complications and will increase confidence in performing the procedure (Tables 20 and 24).

- **Surgical procedures**

Practical skills were reported in most procedures and by most doctors as the greatest

difficulty: reduction of uncomplicated forearm fractures (29%), sigmoidoscopy and proctoscopy (28%), cesarean section (28%), sterilization (20%), ectopic pregnancy surgery (22%), excision of external hemorrhoids (25%), appendectomy (29%), tonsillectomy and adenoidectomy (22%), pudendal nerve block (16%) and brachial plexus block (20%).

This may reflect an underlying knowledge framework weakness which is integrally related to these skills amongst which anatomy is crucial.

Knowledge of the procedure was regarded to be the greatest difficulty in dilatation and curettage (13%) as well as circumcision (17%).

Equipment necessary to perform the procedure was not regarded as a major difficulty in any of the surgical procedures.

Regional anatomy knowledge was regarded as a difficulty in especially the following procedures: brachial plexus block (16%), cesarean section (12%), reduction of uncomplicated forearm fractures (10%), pudendal nerve block (10%) and excision of external thrombosed hemorrhoids and injection or ligation of internal hemorrhoids (10%).

These figures appear to be low, but should however be placed in the perspective of the very strong indication given by the vast majority of doctors that improvement in the critical anatomy knowledge necessary to perform the procedures will reduce difficulties and complications and will increase confidence in performing the procedure (Table 21 and 25).

- **Office procedures**

Practical skills were reported in most procedures and by most doctors as the greatest difficulty: wrist and digital nerve block (24%), injection of shoulder joint (16%), colposcopy (17%), paronychia incision and drainage (13%), upper gastrointestinal endoscopy (14%), knee joint aspiration (18%), liver biopsy (21%), bone marrow aspiration (23%), aspiration of pleural effusion (15%), reduction of shoulder dislocation (26%), reduction of elbow dislocation (17%), reduction of interphalangeal joint dislocation (17%), reduction of hip dislocation (21%), nasopharyngoscopy (16%) and slit lamp examination (15%).

This lack of practical skills may not only reflect a manual skills deficiency to perform the procedure, but as important may reflect an underlying knowledge framework weakness, which is integrally related to these skills amongst which anatomy is crucial. The hands naturally do what the brain thinks³¹.

Knowledge of the procedure was regarded to be the greatest difficulty in epistaxis and nasal packing (17%), rectal examination (12%) and vaginal examination (14%). This is not surprising, for the manual skills to perform these procedures is relatively straight forward, but the correct performance of these procedures, heavily depends on a sound knowledge base. The hands that are actually performing the procedures are entirely dependent on a spatial understanding of the relevant anatomy⁷³.

Equipment necessary to perform the procedure was regarded to be a problem in especially the following procedures: indirect laryngoscopy (16%), bone marrow aspiration (22%), nasopharyngoscopy (15%) and slit lamp examination (13%). This is most probably due to the unavailability of specialized instruments like a bone marrow aspiration needle, dental mirrors and a slit lamp.

Regional anatomy knowledge was regarded as a difficulty in especially the following procedures: wrist and digital nerve block (13%), knee joint aspiration (14%), epistaxis and nasal packing (12%) and rectal examination (12%). These figures appear to be low, but should be placed in the perspective of the very strong indication given by the vast majority of doctors that improvement in the critical anatomy knowledge necessary to perform the procedures will reduce difficulties and complications and will increase confidence in performing the procedure (Table 22 and 26).

- **Imaging procedures**

Practical skills were reported in most procedures and by most doctors as the greatest difficulty: abdominal X-ray (13%), pelvic X-ray (16%), neck X-ray (16%), obstetric ultrasound (23%) and abdominal ultrasound (30%). Concerning the latter two, this lack of practical skills may not only reflect a manual skills deficiency to perform the procedure, but as important may reflect an underlying knowledge framework weakness, which is integrally related to these skills amongst which anatomy is crucial. Regarding the interpretation of the X-rays, the lack of practical skills does reflect an underlying knowledge deficiency.

Equipment necessary to perform the procedure was regarded to be a problem in especially the following procedures: musculoskeletal ultrasound (17%), abdominal CT scan (20%), brain CT scan (18%). This is not surprising for these images are usually performed and interpreted by specialists in tertiary medical care centers.

Regional anatomy knowledge was regarded as a difficulty in especially the following procedures: brain CT scan (13%), chest X-ray (16%), pelvic X-ray (15%), neck X-ray (17%) and obstetric ultrasound (14%). These figures should be evaluated together with the very strong indication given by the vast majority of doctors that improvement in the critical anatomy knowledge necessary to perform the procedures will reduce difficulties and complications and will increase confidence in performing the procedure (Table 23 and 27).

5.1.6 Complications of performance (Table 20)

Due to the individual specificity of the complications of every single procedure, the most relevant and anatomically important complications were rated for every specific procedure (Table 20). Both the complication and the percentage of occurrence of the complication by all respondents are provided. Only the most striking results for every procedure are discussed here.

- **Emergency procedures**

Nearly half (47.4%) of general practitioners are not able to visualize the vocal cords relevant to *oro/nasotracheal intubation*. This is a complication based on pure anatomical grounds, whether the vocal cords are not correctly identified or whether the skill to slide the laryngoscope blade into the correct position is the problem. It is therefore not surprising that esophageal intubation is also a highly rated complication (36.8%).

It is alarming that the most common complication found in *cricothyroidotomy* is the inability to find the correct entry site for the needle (8.4%). This may be regarded as basic surface anatomy of the midline structures of the neck, applied to the skill to find the cricothyroid membrane on a patient.

Brachial artery puncture (10.5%) remains an important complication regarding *vascular access of peripheral arm veins* due to its close relation to the cubital fossa veins deep to the bicipital aponeurosis. The high percentage of inability to locate a suitable vein (47.4%) is not surprising, as these veins are difficult to find in obese and hypovolemic patients. Other vascular access routes should therefore be explored.

Inability to locate the femoral vein during *vascular access of the femoral vein* is rated very high (33.7%). It is therefore not surprising that femoral artery puncture is also rated high (28.4%), as the femoral artery lies directly lateral to the femoral vein just below the inguinal ligament and the palpable pulse of the femoral artery forms the important landmark to find the femoral vein medial to it for successful cannulation.

Inability to locate the *great saphenous vein for vascular access* is rated high (32.6%). This skill is solidly based on an understanding of the surface anatomy of the vein anterior to the medial malleolus.

Regarding *subclavian vein catheterization*, inability to locate the vein was regarded as the most common complication (45.3%), followed by subclavian artery puncture (12.6%) and a hemopneumothorax (9.5%). The surface anatomy of the vein and the correct direction of the needle is obviously the main concern. Inability to perform this correctly, will surely result in the complications listed. Failure to locate the vein at first, will therefore result in puncturing the subclavian artery posterolateral to the subclavian vein and the pleura posteroinferior to the subclavian vein.

Inability to locate the internal jugular vein was also regarded as the most common complication of *catheterization of the internal jugular vein* (37.9%). Correct location of the vein is based on a sound surface anatomical knowledge of the vein. It is therefore not surprising that due to incorrect location of the vein, related structures like the common carotid artery and pleura are injured, causing puncture of the artery (7.4%) and a pneumothorax (5.3%) respectively.

Inability to find the correct site of placement was rated to be a problem by 14.7% of general practitioners during *pretibial intraosseous puncture/infusion*, with possible

resultant physal plate injury (3.2%). Correct placement is based on the surface anatomy of the insertion site of the intraosseous needle and the relations of structures to the inserted needle. Subcutaneous or subperiosteal infiltration reported by 15.8% is based on an understanding of where the needle actually goes and therefore a cross sectional anatomical understanding at the site of needle entry.

For the placement of an *intercostal drain*, the inability to find the correct site of placement of the tube was reported by 16.8% of general practitioners. This explains the bleeding from intercostal vessels (17.9%), injury to the intercostal nerves (2.11%) and puncture of the intrathoracic and /or abdominal organs (5.3%). This is due to the fact that the correct identification of the site of insertion of the intercostal tube by means of surface anatomy knowledge can prevent injury to intercostal arteries, nerves and intrathoracic and/or intra-abdominal organs. A sound knowledge of the position of the neurovascular bundle on the inferior surface of the ribs avoids placing the tube over the inferior surface of the rib instead of its superior surface.

Inability to find the correct entry site for placement of the needle during *lumbar puncture* (33.7%), is the result of a lack of understanding of the surface anatomy of the spinal cord and insertion site. Unawareness of the structures in relation to the advancing needle and therefore the cross sectional anatomy of the lumbar spine, explains the inability to appreciate the position of the advancing needle (15.8%) and the common complication of a bloody tap (45.3%) if the needle is placed too lateral with injury to the posterior external vertebral venous plexus in the epidural space.

Unawareness of the surface anatomy of both the radial and femoral arteries, explains the inability to locate the radial artery (26%) and femoral artery (6.3%) during an *arterial puncture for arterial blood sampling*. Lack of knowledge explains the uncertainty on which artery to use in pediatric patients (22.1%) as it is absolutely contraindicated to use the femoral artery in children due to the risk of thromboembolism and causing a septic hip arthritis due to the posterior relation of the hip joint to the femoral artery at the entry site of the needle⁷⁴.

Lack of surface anatomy and cross sectional anatomical understanding at the plane of needle entry, explains the inability to find the correct site of placement (10.5%) and inability to appreciate the position of the advancing needle (18.9%) respectively, during the performance of a *pericardiocentesis*.

Unawareness of the cross sectional anatomy of the umbilical cord explains the 21.1% of general practitioners unable to find the umbilical vein during an *umbilical line placement*.

Lack of understanding of abdominal surface anatomy as well as the extent and reflection of the peritoneal layers, explains the uncertainty about the site of placement of a suprapubic needle (17.9%) and intra-abdominal placement (10.5%) during *suprapubic puncture and catheterization*.

Uncertainty on the functional anatomy of the eye explains the inability to examine the eye properly by visualizing the retina and optic disc (37.9%), during **examination of the injured eye**.

- **Surgical procedures**

Uncertainty on the osteology and radiographic anatomy of the wrist before and after reduction explains why 39% of doctors are unsure about correct reduction during **reduction of uncomplicated forearm fractures**.

Lack of endoscopic anatomical knowledge of the sigmoid colon, rectum and anus is the reason why 10.5% are unsure of the differences between these structures and 7.4% are unsure of the anatomy of the bowel mucosa, during the performance of a **sigmoidoscopy and proctoscopy**.

Uncertainty about the anatomy of the uterus leads to the unawareness of 15.8% of general practitioners about the extent of the uterus in a non pregnant female during the performance of **dilatation and curettage**. This explains why 19% of doctors experience uterus perforations.

Uncertainty about the perineal layers when suturing an **episiotomy** by 16.8% of doctors is based on a lack of understanding of the perineal anatomy.

Lack of knowledge of the basic pelvic anatomy as applied to obstetrics, explains the uncertainty about anatomical landmarks during vaginal examination, reported by 9.5% of doctors during **normal vaginal delivery**. This will naturally explain the uncertainty about determining the position of the fetal head in 13.7%. Although vaginal tears are a recognized complication of normal vaginal delivery, the reported 28.4% second or third degree tears is high, possibly reflecting lack of practical skills to support the perineum during fetal head delivery.

Uncertainty of the anterior abdominal layers as seen during a Pfannenstiel incision may explain the 27.8% of doctors having difficulty to perform this incision for access during the performance of a **cesarean section**. This also explains the uncertainty about the anatomy of the abdominal wall when suturing in 7.4%. Lack of understanding of the relational anatomy of the pregnant uterus explains the difficulty to determine the site of uterine incision by 9.5% and injury to the ureter by fortunately a relatively low 4.2% of doctors.

Difficulty to understand the pelvic anatomy as seen from the pelvic inlet and undamaged peritoneum as well as blood supply to the uterine tubes, explains the problem to locate the uterine tubes experienced by 36.8% of doctors and bleeding by 13.7% respectively during the performance of a **sterilization**.

Uncertainty about the blood supply of the uterine tubes and anastomosis between the

ovarian and uterine arteries may in part explain the high incidence of bleeding experienced by 29.5% doctors during the performance of *ectopic pregnancy surgery*.

Lack of knowledge of both the arterial supply and venous drainage of the foreskin as well as the blood vessels associated to the frenulum of the foreskin, explains the bleeding reported at the high rate of 33.7% of doctors during a *circumcision*.

Uncertainty about what hemorrhoids actually are as well as their normal anatomical location, explains the difficulty 7.4% of doctors have to distinguish between hemorrhoids as well as the 17.9% who are unsure of the site of incision during the excision of *external thrombosed hemorrhoids and injection or ligation of internal hemorrhoids*.

Unawareness of the different possible positions of the appendix and uncertainty of the surface anatomy of this structure explains why 23.3% of doctors are unable to locate the appendix and 7.4% are unsure of the site of incision during the performance of an *appendectomy*.

Uncertainty on the tonsillar and peritonsillar vessels as well as the fascial planes around the palatine tonsil, explains partly why 27.4% of doctors experience bleeding and why 8.4% are unable to remove the tonsil in the fascial plane respectively during a *tonsillectomy and adenoidectomy*.

Lack of knowledge of the position and surface anatomical landmarks to advance a needle towards the pudendal nerve during a *pudendal nerve block* is the reason why 20% of doctors are uncertain how to find the nerve.

Lack of knowledge of the position of the brachial plexus and the surface anatomical landmarks to locate different parts of the brachial plexus during *regional brachial plexus blockade*, explains the uncertainty about the site of entrance and direction of the needle experienced by 16.8% of doctors. Due to the uncertainty of the direction of the needle, it is actually surprising that only 3.16% of doctors report a pneumothorax and phrenic nerve paralysis, due to the relational anatomy of the pleura and phrenic nerve to the brachial plexus. The latter is more prone to injury during interscalene blockade, where the C5,6 roots of the brachial plexus are anesthetized.

- **Office procedures**

Failure to appreciate the relational anatomy of the nerves around the wrist and digits, explains the inability to locate the nerves in relation to the wrist and digits by 15.8% and 14.7% of doctors respectively during *wrist and digital nerve blockade*.

Uncertainty of the surface anatomy of the shoulder and extent of the shoulder joint explains the problem of finding the site of entrance and direction of the needle by 20% of doctors during *injection of the shoulder joint*.

Uncertainty about the anatomical landmarks was reported by 9.8% doctors during the

performance of a **colposcopy**, which relates to the anatomy of the cervix as seen through a speculum.

Uncertainty about the surgical anatomy involved during **paronychia incision and drainage** explains the uncertainty about the site of incision by 19% of doctors.

A percentage of 8.42 of doctors who perform **upper gastrointestinal endoscopy** report to be unsure about anatomical landmarks of the mucosal anatomy and reveals a lack of understanding of the endoscopic anatomy of the gastrointestinal tract.

Inability to appreciate the surface anatomy of the knee and the underlying structures, explains the inability to locate the site of entry by 13.7% and injury to the articular cartilage by 9.5% of doctors respectively during a **knee joint aspiration**.

Failure to appreciate the surface anatomy of the liver, especially as seen on the midaxillary line, explains the uncertainty of 15.8% of doctors to locate the site of entrance needed during performance of a **liver biopsy**.

Uncertainty on the endoscopic anatomy of the laryngopharynx and larynx, explains the uncertainty about anatomical landmarks by 10.5% of those who perform an **indirect laryngoscopy**.

Inability to control bleeding by 47.4% of doctors during **epistaxis and nasal packing** may be due to a lack of practical skills and therapeutic knowledge of which both are supported by a sound understanding of the blood supply of the nasal septum and lateral walls of the nose.

Uncertainty on the surface anatomy of the bony points where a **bone marrow aspiration** can be performed explains the 20% of doctors who are not sure about the site of needle entry.

Lack of knowledge of the surface anatomy of the lung and pleural reflections result in uncertainty about the site of needle entrance reported by 14.7% of doctors during **aspiration of a pleural effusion**.

Uncertainty of the functional anatomy of the shoulder joint and biomechanics of a shoulder dislocation as well as relational anatomy of a dislocated humerus head to the brachial plexus, explains the uncertainty about the technique and its rationale during **reduction of shoulder joint dislocation** by 21.1% of doctors and brachial plexus injuries by 7.4% of doctors respectively.

The same functional anatomical uncertainty on the elbow joint, interphalangeal joints and hip joint regarding the biomechanics of dislocation of these joints explains the uncertainty about the technique to relocate these joints by 16.8% of doctors regarding the **reduction of elbow dislocation**, 10.5% regarding the **reduction of interphalangeal joint dislocation** and 17.9% regarding the **reduction of hip joint dislocation**.

Failure to appreciate the endoscopic anatomy of the nasopharynx was reported by 12.6% of doctors performing a *nasopharyngoscopy*. This is due to a lack of understanding of the different normal mucosal folds in the nasopharynx and what they represent.

Uncertainty about the anatomy of eye structures was reported by 13.7% of doctors performing a *slit lamp examination*. This is due to unfamiliarity with the anatomy of the eye as seen via this technique.

Inability to appreciate the spatial anatomy of the rectum as applied to *rectal examination* explains the 30.5% of doctors who are unable to locate the seminal vesicles, the alarming 9.5% who are unable to locate the prostate gland and the 5.3% who are unable to locate the cervix and uterus in a female patient. It may indeed be difficult to palpate the seminal vesicles as is reflected by the high reported figure, but inability to palpate the prostate is alarming.

Likewise, inability to appreciate the spatial anatomy of the vagina as applied to a *vaginal examination*, explains the 7.4% of doctors who are unable to locate the bladder, the 5.3% who are unable to locate the adnexal structures, the 6.3% unable to locate the recto-uterine pouch and the 21.1% unable to appreciate the position of the ureters. Although the position of the ureters as appreciated by a vaginal examination is difficult, the location of the bladder, adnexal structures and recto-uterine pouch is vitally important during a vaginal examination.

- **Imaging procedures**

Failure to appreciate the ultrasonographic anatomy of specific muscles and bony structures, explains the inability to locate them by 12.6% of doctors performing a *musculoskeletal ultrasound*.

Inability to appreciate cross sectional anatomy of the abdomen and skull, explains the reported inability to read an *abdominal and brain CT scan* by 13.7% of doctors who interpret these scans.

Failure to appreciate the radiographic anatomy of the thorax explains why 3.2% of doctors are unable to locate the borders of the heart, 4.2% to count the ribs and 19% to visualize the pulmonary vasculature on a *chest X-ray*. Although these figures are not extremely high, it shows how problematic can be the simple interpretation of normal anatomy on an X-ray.

Failure to appreciate the radiographic anatomy of the abdomen explains why 10.5% of doctors are unable to differentiate small bowel from large bowel, 7.4% are unsure about the soft tissues and 22% are unable to visualize the psoas line on an *abdominal X-ray*. These figures are actually quite high, keeping in mind that these elements are key features in interpreting an abdominal X-ray.

Inability to locate the bony landmarks by 11.6% and evaluate the pelvic brim by 7.4% of

doctors on a *pelvic X-ray*, shows that there are conceptual deficiencies in the simple interpretation of the radiographic anatomy on a pelvic X-ray.

Failure to assess the soft tissue spaces by 21.1% and the bony landmarks by 19% of doctors on a *neck X-ray*, is extremely alarming and shows great incompetence to read the radiographic anatomy on a neck X-ray. The great importance of being able to interpret a neck X-ray properly is of life-saving nature as is underscored by the American College of Surgeons⁷⁵.

The inability to locate anatomical structures by 34.7% of doctors and to understand how obstetric measurements are done by 16.8% during the performance of an *obstetric ultrasound* is alarming in the light of the fact that 82% of doctors report to perform this procedure. This is explained by a basic lack of understanding of the ultrasonographic anatomy of pregnancy.

The failure to locate anatomical structures by 34.7% of doctors during the performance of an *abdominal ultrasound* is problematic, especially because of the fact that 59% of doctors report performing this procedure.

For both the obstetric and abdominal ultrasound it in effect means that a third of doctors performing these procedures are unable to identify with certainty the structures they are looking at. This raises serious doubts about the reliability and validity of these procedures in family physician's hands.

It is clear that nearly all complications mentioned above arise from a lack of understanding of basic surface, surgical, functional, radiographic, cross sectional, relational and endoscopic anatomy.

5.1.7 The role of clinical anatomy in reducing difficulties and complications

Previous studies have ranked the importance of anatomy with regard to common health problems. Adeyemi-Doro⁷⁶ did a study amongst doctors, rating the relevance of anatomy to the diagnosis and treatment of 40 listed health problems. No study has however been undertaken to rate the assessment of general practitioners on the influence of clinical anatomy on the safe and successful performance of procedures in hospital practice and whether the improvement of clinical anatomy knowledge may actually reduce difficulties and complications.

- **Emergency procedures**

Regarding emergency procedures (Table 21), more than 80% of doctors agreed (strongly agree + agree) in *all* procedures that the improvement of critical anatomy knowledge necessary to perform this procedure will reduce difficulties and complications.

The three procedures where the strongest agreement with the statement was reported were: subclavian vein catheterization (63% strongly agree), eye injury examination (60% strongly agree) and cricothyroidotomy (57% strongly agree).

Regarding vascular access of peripheral arm veins, 15% of doctors disagreed (strongly disagree plus disagree) with the statement. This reflected the strongest disagreement with the statement of all the emergency procedures and is not surprising considering that the procedure is performed by 100% of the general practitioners and usually has few complications.

These figures reflect not only a great need for postgraduate clinical anatomy teaching but also more importantly the possible influence of improvement of relevant anatomy regarding specific procedures in reducing difficulties and complications and therefore have an enormous influence on patient care.

Although these figures represent a subjective self-assessment, it does reflect the notion and strong message of practitioners in the field. This is an important first step on the road of illustrating the key significance of anatomy on patient care regarding clinical procedures.

This has to be followed up by assessment on the influence of anatomy on patient care on higher levels of the assessment pyramid of Miller⁵⁴ by means of content based written and performance based assessment.

- **Surgical procedures**

Regarding surgical procedures (Table 22) more than 85% of all doctors agreed and strongly agreed in *all* procedures that the improvement of critical anatomy knowledge necessary to perform this procedure will reduce difficulties and complications.

This is an extremely strong message regarding their perception of the influence of anatomy knowledge on competent performance of surgical procedures.

The three procedures where the strongest agreement with the statement was reported, were (strongly agree plus agree): cesarean section (94%), appendectomy (94%) and pudendal nerve block (94%). Especially the first two procedures are highly invasive and certainly need a very competent level of anatomical knowledge.

- **Office procedures**

Regarding office procedures (Table 23), more than 80% of all doctors agreed and strongly agreed in *all* procedures that the improvement of critical anatomy knowledge necessary to perform this procedure will reduce difficulties and complications.

This is a very strong message to underscore the notion that competency in anatomy is also of great importance in the safe performance of less invasive office procedures.

The four procedures where the strongest agreement with the statement was reported, were (strongly agree plus agree): reduction of shoulder joint dislocation (96%), reduction of elbow joint dislocation (95%), wrist and digital nerve block (95%) and knee joint aspiration (94%).

These procedures are indeed associated with complications which are anatomically related, and therefore require a higher anatomical competency to perform safely.

- **Imaging procedures**

Regarding imaging procedures (Table 24), more than 79% of all doctors agreed and strongly agreed in *all* procedures that the improvement of critical anatomy knowledge necessary to perform this procedure will reduce difficulties and complications.

The three procedures where the strongest agreement with the statement was reported, were (strongly agree plus agree): abdominal ultrasound (95%), obstetric ultrasound (91%) and neck X-ray (91%).

Interpreting these image procedures without difficulty does indeed need a high competency level of radiographic and ultrasonographic anatomy.

5.1.8 The role of clinical anatomy to increase the confidence of general practitioners in performing procedures

It is widely recognized that the degree of confidence to perform a procedure is reflected amongst others by competency in the anatomy relevant to the specific procedure. Ger¹¹ has pointed out that prolongation of surgical procedures is partly but most importantly due to the incompetent anatomical knowledge of the surgeon which is reflected in a lack of confidence. This may have detrimental consequences to the patient.

This present study proves beyond any doubt that doctors agree with this notion.

For emergency procedures (Table 25), more than 80% of doctors agreed and strongly agreed that improvement of anatomical knowledge relevant to the procedure will increase confidence in performing the procedure. This was also true for surgical procedures (Table 26), office procedures (Table 27) and imaging procedures (Table 28).

The notion was most strongly supported regarding eye injury examination (93%), cricothyroidotomy (88%) and both subclavian and internal jugular vein catheterization (88%) for emergency procedures. For surgical procedures, the notion was most strongly supported regarding pudendal nerve block (95%), brachial plexus block (94%), appendectomy (92%) and cesarian section (91%). The notion was most strongly supported for office procedures regarding reduction of elbow joint dislocation (95%), reduction of shoulder joint dislocation (94%), knee joint aspiration (94%) and wrist and digital nerve block (94%).

For imaging procedures, the notion was most strongly supported regarding abdominal ultrasound (95%), obstetric ultrasound (94%) and neck X-ray (88%).

All these figures correlate very strongly with the notion that improvement of anatomy knowledge necessary for a specific procedure will reduce difficulties and complications.

5.2 Selection of problem procedures and criteria for selection

A total of 15 problem procedures were selected (Table 29) according to scoring option C to obtain a representative number of procedures in every category (emergency, surgical, office and imaging procedures) where clinical anatomy competence is the most obvious problem in dealing with difficulties and complications and where improvement of this competence will result in improved patient care.

Six procedures were selected under the category of emergency procedures. Due to the anatomical overlap involved during subclavian vein and internal jugular vein catheterization, they were grouped together under one as central venous catheterization.

For the categories surgical and office procedures, four procedures were selected for each category. Similarly due to the anatomical similarities involved during rectal examination and proctoscopy and sigmoidoscopy, these procedures were grouped together. Both obtained high scores during the selection process.

One procedure was selected for the category imaging procedures.

Determining the scope of different clinical procedures done by family practitioners is significant. Not only the teachers of a discipline should be consulted to determine content, but also those who practice the discipline. Spivey⁶³ has developed a method to use a formal survey to determine content. Spivey's method has also been successfully applied in determining which procedural skills should be learned by internal medicine residents⁷⁷. The data presented in this study may be of significance in determining which procedures need to be included not only in postgraduate anatomical education, but also in family practice residency programs in South Africa.

Most clinical anatomy training programs for residents of any specialty are usually based on a regional anatomy approach of the relevant area. Most programs usually do not focus on the specific needs of the specialty involved. This is certainly true for the postgraduate clinical anatomy training program of general practitioners¹³.

It is thought that in the 'age of evidence based medical education', it is vitally important to focus clinical anatomy training programs on actual data from clinical practices. The anatomy general practitioners need to practice at the bedside is often determined by what clinical anatomists think general practitioners need to know. There is often an assumption of what anatomy is needed by general practitioners to perform clinical procedures. However, the evidence base of what we are teaching is usually absent. There is therefore a need to support our teaching programs with hard data from the field in order to contribute to patient care. South African medical schools are challenged in the training of general practitioners to cater for both first and third world patient populations. The crucial challenge is to succeed in directing the medical education obligation to the entire population⁷⁸.

Boon *et al*¹⁶ demonstrated that clinical anatomy training programs should focus on four

basic elements of clinical practice in order to equip physicians with a sound anatomical base for safe clinical practice. These are the clinical examination, radiographic interpretation, clinical procedures and clinical reasoning skills. These elements are core to medical practice and anatomy training programs should always keep these elements in mind. This study focuses on one element, namely the clinical procedures.

Certainly in the South African context, an evidence base for the procedures done in hospital practice is not available. This study addresses this question and also studies the difficulties and complications experienced during performance of various clinical procedures. These are usually greatly dependent on a sound anatomical understanding. It seems this is a first study determining the evidence base for a clinical anatomy procedures training program for general practitioners in hospital practice in a developing country. The procedures performed were systematically determined, difficulties and complications related to the anatomy were identified. This formed the basis to develop a clinical anatomy knowledge base for problem practical procedures and a training program for general practitioners.

5.3 Comparison between urban and rural hospital practices

There is a need to identify the educational needs of general practitioners working not only in urban practices but also in rural practices. Similar studies have been performed in Australia⁶⁴ to identify the educational needs of so-called country doctors. Significant differences were found regarding the amount of procedural work that was undertaken by country doctors compared to metropolitan doctors.

For rural doctors, the findings of this study provide an affirmation of their wide range of clinical practice particularly concerning the performance of procedures. It is generally excepted that rural general practitioners have to perform more procedures than their urban counterparts^{64,79}.

- **Oro/nasotracheal intubation (Table 30)**

No statistically significant difference was found regarding the incidence of performance of oro/nasotracheal intubation between rural and urban practices, although the procedure is more frequently performed per year in rural hospital practices ($p=0.015$). No significant difference was found regarding the rating of essentiality, comfortability, difficulties and complications. Rural doctors however rated the influence of clinical anatomy on reduction of difficulties and complications ($p=0.001$) as well as the increase in confidence ($p=0.0236$), as significantly higher.

This may be explained by the fact that rural doctors perform the procedure more often per annum, possibly due to the fact that general anesthesia is usually performed by them. They therefore have a greater sensitivity for difficult intubations, which can be identified by careful anatomical assessment prior to intubation. It is however not surprising that doctors from both practice situations regard the procedure as essential, given the demand on emergency care provision by general practitioners in both practice situations.

- **Cricothyroidotomy (Table 30)**

A significantly higher incidence ($p=0.026$) and frequency rate ($p=0.0001$) was found amongst doctors in urban hospital practices compared to rural practices. This may be due to the fact that general practitioners are responsible for the emergency room in all the urban hospitals included in the study as well as the higher incidence of trauma draining to these centers for instance motor vehicle accidents.

The fact that urban doctors have more difficulties with the procedure ($p=0.0013$) can be explained by the fact that they perform the procedure significantly more often and are therefore more alert to difficulties that may occur.

Both groups have an equal assessment of the essentiality of the procedure, complications as well as the assessment of the influence of clinical anatomy on reducing difficulties and complications and increasing confidence to perform the procedure.

- **Vascular access via the great saphenous vein (Table 30)**

There was no significant difference on the incidence of the performance of great saphenous vein cannulation between the urban and rural doctors group ($p=0.51$), however urban doctors perform the procedure more often per year than the rural doctors do ($p=0.04$). Although the significance is not strong, urban doctors may have been more exposed to the value of this procedure than their rural counterparts due to the fact that they are closer to tertiary academic institutions.

This with the fact that the performance of this procedure heavily depends on the position and relations of the great saphenous vein, may also explain why significantly more rural doctors regard the influence of clinical anatomy on reducing difficulties and complications ($p=0.006$) and increasing confidence to perform the procedure ($p=0.003$) as important. An educational challenge therefore exists in rural hospital practices regarding this procedure.

- **Lumbar puncture (Table 30)**

A great significant difference is seen regarding the incidence ($p=0.0002$) and essentiality ($p=0.0001$) of the performance of lumbar puncture in rural and urban hospital practices. Significantly more rural doctors perform the procedure and regard the procedure as essential. This may be explained by the fact that rural doctors are much more so than their urban counterparts required to perform spinal anesthesia for various surgical procedures (like cesarean section) as well as lumbar punctures on pediatric patients due to the absence of full time pediatricians in rural hospital practices.

Significantly more doctors regard the influence of clinical anatomy in reducing difficulties and complications ($p=0.01$) as important. This may be explained by the possible greater awareness or rural doctors of difficulties and complications which are anatomically related, because their performance rate of the procedure is higher.

- **Pericardiocentesis (Table 30)**

There was no significant difference on the incidence of the performance of pericardiocentesis between the urban and rural doctors ($p=0.367$), however urban doctors perform the procedure more frequently per year than their rural counterparts ($p=0.028$). Although the significance is not very strong, this may be explained by the fact that priority one trauma cases are more commonly seen in urban hospital practices and the fact that cardiothoracic surgical expertise is present in most urban hospitals which form an important backup for this procedure.

Both rural and urban doctors regard the procedure as essential and there was no statistically significant difference between difficulties ($p=0.632$) and complications ($p=0.074$) experienced by rural and urban doctors.

Rural doctors regarded the influence of anatomy to reduce difficulties and complications ($p=0.012$) and to increase confidence to perform the procedure ($p=0.027$) as more important than the urban doctors, possibly due to less expertise around them.

- **Subclavian vein catheterization (Table 30)**

Significantly more urban doctors not only perform ($p=0.002$) but also more frequently perform ($p=0.0002$) subclavian vein catheterization compared to doctors in rural hospitals. This may be due to the availability of radiological expertise in urban hospitals compared to rural hospitals where radiological services are often only available for a limited time during the day. After performing a subclavian vein catheterization, a chest X-ray needs to be done to rule out the possibility of a pneumothorax. Another reason might be the availability of doctors to supervise the procedure in urban hospitals as well as the access to postgraduate training programs in urban hospitals.

For the same reasons, rural doctors are significantly more uncomfortable ($p=0.0005$) compared to the urban doctors group. It also explains why rural doctors regard the influence of clinical anatomy to reduce difficulties and complications ($p=0.0066$) and to increase confidence in the performance of the procedure ($p=0.005$) as significantly more important.

Both doctors equally thought that the performance of the procedure is essential.

Urban doctors experience significantly more difficulties ($p=0.004$) and complications ($p=0.0008$) compared to rural doctors, most likely because they perform the procedure significantly more often.

- **Internal jugular vein catheterization (Table 30)**

No significant difference was found regarding the incidence of performance of internal jugular vein catheterization between urban and rural doctors ($p=0.082$). Urban doctors do however perform the procedure significantly more frequently per year ($p=0.004$).

Urban doctors regard themselves as more uncomfortable with the procedure ($p=0.002$) and experience significantly more difficulties ($p=0.0001$) and complications ($p=0.0009$) than rural doctors.

This route of internal jugular venous catheterization seems to be more widely practiced in rural hospitals, rather than the subclavian vein route. This is not surprising for it is well documented that complications are generally lower when the internal jugular vein access route is used⁸⁰.

Rural doctors regarded the influence of clinical anatomy to increase confidence to perform this procedure as significantly more important ($p=0.035$).

- **Cesarean section (Table 30)**

Significantly more rural doctors perform cesarean sections ($p=0.0001$) and also regard the procedure as significantly more essential in their practice situation ($p=0.0001$). This is not surprising as rural general practitioners are usually running obstetric services in rural hospitals in South Africa and therefore need to be competent to perform this procedure.

Rural doctors experience significantly more complications ($p=0.0009$), most likely due to the fact that their performance rate is much higher.

Both doctors groups regard the influence of anatomy to reduce difficulties and complications and increase confidence of performance as very important, which is understandable due to the invasive nature of this surgical procedure.

- **Reduction of uncomplicated forearm fractures (Table 30)**

Rural doctors have a significantly higher performance rate ($p=0.0001$) concerning the reduction of uncomplicated forearm fractures and regard the procedure as significantly more essential ($p=0.0001$) in their practice situation.

Due to this fact, one would expect them to experience significantly more complications, which is indeed the case ($p=0.045$).

These differences as well as the importance of anatomy and biomechanics on correct reduction of forearm fractures, explains why rural doctors regard the influence of clinical anatomy relevant to this specific procedure to reduce difficulties and complications as significantly more important ($p=0.022$).

- **Ectopic pregnancy surgery (Table 30)**

Due to the fact that general practitioners in rural hospitals in South Africa run the obstetric services as well as the emergency surgical theatre, especially after hours, it is not surprising that the performance rate ($p=0.0002$) as well as the frequency rate per annum ($p=0.034$) of ectopic pregnancy surgery is significantly higher for rural general

practitioners.

Due to the necessity to perform this procedure in rural hospitals, it is no surprise that rural doctors regard this procedure as significantly more essential in their practice situation ($p=0.0001$). Ectopic pregnancy surgery is usually performed by the Obstetrics and Gynecology department in urban hospitals.

- **Appendectomy (Table 30)**

There was no significant difference observed regarding the performance rate of appendectomy between rural and urban general practitioners ($p=0.855$). This may be explained by the fact that the urban doctors were older and more experienced and the rural doctors younger and less experienced. Rural doctors do however regard the procedure as significantly more essential ($p=0.0001$). This is a very strong significance which reveals the demand on rural doctors to be able to perform the procedure.

The influence of anatomy on reducing difficulties and complications, is regarded as significantly more important by rural doctors ($p=0.017$). This with the equal performance rate between urban and rural general practitioners may be explained by the fact that urban general practitioners usually have greater access to supervised instruction of the procedures by a member of the Surgery Department. Rural doctors with limited supervised opportunities have therefore a greater sense of dependence on their anatomical foundation underlying this invasive procedure.

- **Wrist and digital nerve block (Table 30)**

Both urban and rural general practitioners reported a high performance rate on wrist and digital nerve block, although significantly more rural doctors regard the procedure as essential ($p=0.021$) in their practice situation. This may be due to the fact that access to general anesthesia is more limited in rural hospitals and the role of regional anesthetic techniques is therefore of great importance.

Both groups regard the influence of anatomy on reducing difficulties and complications and to increase confidence of performance as equally important. This is encouraging for the reliance on the exact anatomy of the nerves in relation to the wrist and digits is very important.

- **Knee joint aspiration (Table 30)**

Significantly more rural general practitioners perform knee joint aspirations ($p=0.006$) and they also regard the procedure as significantly more essential in their practice situation ($p=0.0001$). This may be explained by the fact that due to the availability of orthopedic services in urban hospitals, urban general practitioners are less likely to perform knee joint aspirations.

Due to the higher performance rate of this procedure in rural hospitals and the fact that several anatomical key points are crucial for successful performance, it is not surprising that rural general practitioners regard the importance of anatomy on reducing difficulties and complications as significantly more important ($p=0.023$).

- **Epistaxis and nasal packing (Table 30)**

No significant difference was found regarding the management of epistaxis and nasal packing between urban and rural general practitioners regarding all aspects investigated. This is not surprising due to the very common nature of epistaxis in both practice situations, which has traditionally been the responsibility of the family physician to manage.

- **Rectal examination (Table 30)**

No significant difference was observed regarding the performance rate ($p=0.796$) and the essentiality grading ($p=0.560$) of rectal examination between rural and urban general practitioners. This does reflect the importance of this procedure in both practice situations.

Rural doctors did however regard the influence of anatomy on reducing difficulties and complications ($p=0.013$) and on increasing confidence to perform the procedure ($p=0.027$) as significantly more important.

The following is clear from the comparison of all 15 selected problem procedures regarding several aspects of competence as perceived by urban and rural doctors:

- a) The central role of clinical anatomy in the reduction of difficulties and complications. This role is recognized to be significantly higher by rural general practitioners in the following procedure in order of strength of significance: oro/nasotracheal intubation ($p=0.001$), great saphenous vein cannulation ($p=0.006$), subclavian vein catheterization ($p=0.0066$), lumbar puncture ($p=0.010$), pericardiocentesis ($p=0.012$), rectal examination ($p=0.013$), appendectomy ($p=0.017$), reduction of uncomplicated forearm fractures ($p=0.022$) and knee joint aspiration ($p=0.023$).

No urban doctors regarded the influence of anatomy to reduce difficulties and complications for any procedure as more important compared to rural doctors. It is therefore of crucial importance to conduct training programs in the relevant anatomy necessary to perform these procedures safely especially in rural hospital practices.

- b) Rural general practitioners regard the following procedures to be significantly more essential in their practice situation compared to urban general practitioners in order of strength of significance: knee joint aspiration ($p=0.0001$), appendectomy ($p=0.0001$), ectopic pregnancy surgery ($p=0.0001$), cesarean

section ($p=0.0001$), reduction of uncomplicated forearm fractures ($p=0.0001$), lumbar puncture ($p=0.0001$), internal jugular vein catheterization ($p=0.0008$) and wrist and digital nerve block ($p=0.021$).

No procedures were regarded as significantly more essential in urban practices. This is of great importance and illustrates the crucial challenge of addressing the unique demands and needs of rural general practitioners, concerning the above mentioned procedures. More work needs to be done regarding the continued medical education of the procedures in rural hospitals. This notion is underscored by rural family practice in Canada. Hamilton⁷⁹ states that rural general practitioners need more academic knowledge and skills than their urban colleagues. There is a tendency to train residents in postgraduate Family Medicine programs for urban practice only⁷⁹.

Practicing as a family physician in a rural hospital practice may draw one out of an area of expertise into diverse procedural challenges¹¹.

Wigton⁴¹ reports that internists practicing in smaller hospitals and communities perform more procedures. This is in line with the results presented in this study for general practitioners in rural hospital practice. In this practice setting, physicians may have to depend solely on their own skills in performing procedures that might be referred elsewhere. Another complicating factor is that the resources for performance of the procedure may be unavailable.

- c) A significantly higher performance rate or frequency of performance per annum was reported by rural general practitioners for the following procedures (in order of strength of significance): cesarean section ($p=0.0001$), reduction of uncomplicated forearm fractures ($p=0.0001$), ectopic pregnancy surgery ($p=0.0002$), lumbar puncture ($p=0.0002$), knee joint aspiration ($p=0.006$) and oro/nasotracheal intubation ($p=0.015$).

A significantly higher performance rate or frequency of performance per annum was reported by urban general practitioners for the following procedures (in order of strength of significance): cricothyroidotomy ($p=0.0001$), subclavian vein catheterization ($p=0.0002$), internal jugular vein catheterization ($p=0.004$), pericardiocentesis ($p=0.028$) and great saphenous vein cannulation ($p=0.044$).

- d) It seems that generally the performance rate of most emergency procedures are higher by urban general practitioners and that the performance rate of most surgical procedures generally have a higher performance rate amongst rural general practitioners.

One should however be careful to make deductions regarding the educational needs of both these practice situations for although the performance rate is for example higher, the continued medical educational needs may not subsequently be lower and vice versa. This notion is underscored by Wigton³⁰ when saying that performance rate and training needs are not indirectly related.

- e) Being younger, male and practicing in rural hospital practice reflects the performance of a greater number of procedures (Table 5). This correlates well with a study done by Eliason⁸¹ in the USA. Young doctors may not be as experienced as older doctors, but due to the hospital practice profile where they work, a high demand is laid upon them to perform procedures.

5.4 Development of a clinical anatomy knowledge base for each selected problem procedure

According to the key features approach as described by Page *et al*⁵², there are unique key features to every clinical problem. This model can be translated to procedural skills training and assessment regarding the role of clinical anatomy in the safe and successful performance of procedures.

For all the selected procedures, clinical anatomical key features unique to the procedure were developed. This was done by studying the literature extensively of both the basic and clinical sciences regarding the key clinical anatomical features of the selected procedures and was further enriched by personal communication with content experts in the field of clinical anatomy and procedural skills training¹.

5.5 Development of a clinical anatomy training program

Developing and teaching an educational program, involves several key elements as defined by Kennedy⁸²: i) it should effectively communicate content, ii) it should coach for skills improvement and iii) it should be a thoughtful guide to analytical thought. Due to the various duties of tertiary education institutions of which the responsibility to students is the core of its mission, emphasis should not only be on research, but also on the core business of educational innovation⁸². This also involves the duty of continued educational programs in the community, and *for* the community.

Creating medical educational programs which contribute to patient care by improving the

¹ The following content experts are named:

Prof PH Abrahams, Kigezi International School of Medicine, Girton College, Cambridge, UK

Prof JH Meiring, Department of Anatomy, University of Pretoria, South Africa

Mr T Welsh, Queens College, Cambridge, UK

Dr IG Parkin, Department of Anatomy, University of Cambridge, UK

Mr RH Whitaker, Department of Anatomy, University of Cambridge, UK

Mr B Logan, Department of Anatomy, University of Cambridge, UK

Prof T Olson, Albert Einstein School of Medicine, New York, USA

Dr Helen Bloch, Long Island Jewish Medical Centre, New York, USA

Dr W Rennie, Long Island Jewish Medical Centre, New York, USA

Dr R Kneebone, St Mary's Hospital, London and Bath University, UK

Dr T Silver, St Georges Hospital Medical School, London, UK

Mr V Mahadevan, Royal College of Surgeons of England, London, UK

Prof J Kauer, Katholieke Universiteit Nijmegen, The Netherlands

proficiency of practitioners in their community is a responsibility at the core of any medical faculty.

This study focuses on an important element of proficiency regarding procedures done in hospital practices in South Africa. The anatomy underlying this competency is often neglected and this fact has been linked to the increased incidence of complications and difficulties^{7,9,11}.

There is therefore a need to develop clinical anatomy programs, which presents the anatomy in relevant clinical context. Anatomy courses which are grossly overcrowded with factual information not relevant to the clinical world inhibits students from developing creative critical thinking. The application of anatomical principles to procedural skills will strengthen the student's motivation for learning anatomy. Cahill *et al*⁸³ stressed the link between a basic science such as anatomy to clinical performance and introduced the concept of anatomic incompetence where the link is failed to be acknowledged. Teichgräber *et al*⁸⁴ has well illustrated the recognition of students regarding the importance of anatomy for diagnostic and therapeutic procedures.

Beahrs *et al*⁹, a noted American surgeon pointed out that the surgical resident learns anatomy at the operating table. There is great truth in this notion, however it is often impossible to have supervision available during the performance of all surgical procedures. This is certainly true for developing countries. It is therefore necessary to study innovative solutions in procedural training.

With modern information technology it is now possible to create a virtual procedures clinic to teach clinical anatomy as an adjunct to the formal procedural training programs in various residencies. Within the clinical context of the procedures, anatomical pitfalls and complications can be demonstrated in an interactive way. In this way the principle of Bearhs *et al*⁹, namely teaching at the operating table, can be practiced by way of simulation.

The nature of clinical procedures training, is that often there is no time to explain slowly and methodically how procedures are performed. A patient with an acute upper airway obstruction, cannot wait for a methodical teaching session, but needs a cricothyroidotomy immediately.

Teaching models³⁸ are therefore often an excellent substitute for teaching procedures. These models include animal models, plastic models, volunteers and cadavers for selected procedures⁸⁵. The key question in assessing procedural skills is whether the skills learned on a model or prosection can be transferred to real patients³¹.

Animal models are currently less used due to ethical issues regarding animal usage in research and teaching³⁸. Also, the anatomy is different and these models are therefore not useful to focus on clinical anatomy competency regarding a procedure performed on patients.

Plastic models are ideal for teaching certain procedures where the focus is on teaching a

certain algorithm like in CPR (cardiopulmonary resuscitation) or where specific skills are taught. Plastic models however never reflect the true human anatomy where specific detail of relationships of structures are of great importance for safe and successful performance of the procedure. A good example of this is a model which is used for learning how to introduce a central venous catheter via the subclavian vein. Injury to the brachial plexus, subclavian artery or phrenic nerve cannot be demonstrated at all with this model. It has therefore serious limitations.

Using volunteers is often difficult if not impossible concerning the invasive nature of certain procedures. They are however of great value in the teaching of non-invasive examination procedures and skills.

Cadavers, whether fresh or preserved can be used with great success in the teaching of clinical procedures. Fresh cadavers however present the risk of transmission of infectious diseases like HIV or Hepatitis B and is not an option in the South African context. Embalmed cadavers, although less realistic, can still be successfully used as a teaching model of various clinical procedures.

Nelson³⁸ mentions the following procedures for which the cadaver is an excellent teaching model:

Airway management: Endotracheal intubation (oral and nasal), placement of naso- and oropharyngeal airways, cricothyroidotomy, chin lift and jaw-thrust maneuver.

Wound care: Suturing, local anesthesia, nerve blocks.

Chest procedures: Needle thoracostomy, thoracostomy, thoracotomy, pericardiocentesis (with a pericardial sac filled beforehand).

Abdominal procedures: Nasogastric tubes, peritoneal lavage.

Neurologic or neurosurgical procedures: Gardner-Wells tongs, burr holes.

Miscellaneous: Urinary catheter insertion, arthrocentesis, cut downs, nasal packs, nail removal.

Rennie *et al*⁸⁵ have used embalmed cadavers in an extensive training program on the clinical anatomy of emergency procedures in New York. The following procedures appear in their practical anatomy course, which has been conducted with great success over the past 10 years in New York⁸⁶:

Hand: wrist block, digital nerve block, drainage of paronychia and felon, extensor tendon repair.

Forearm: fasciotomy.

Neck: subclavian and internal jugular central venous lines.

Airway: cricothyroidotomy (needle and surgical).

Face: supraorbital, infraorbital and mental nerve blocks, anesthesia for ear lacerations.

Neurosurgery: burr holes, cervical tongs.

Shoulder: shoulder relocation techniques, radiographic interpretation, arthrocentesis.

Arm and elbow: relocation techniques, radiographic interpretation, arthrocentesis.

Knee: maneuvers for knee examination, radiographic interpretation, arthrocentesis.

Ankle: radiographic interpretation, posterior tibial and sural nerve blocks, arthrocentesis.

Vascular: venous cutdowns at cephalic, basilic and great saphenous veins.

Chest: needle thoracocentesis, chest tube placement, pericardiocentesis, open thoracotomy, cross clamping of the aorta, repair of a cardiac lesion.

Abdomen: diagnostic peritoneal lavage.

Nelson³⁸ mentions a few procedures that do not work well to perform on cadavers, eg: central venous lines, lumbar puncture, ophthalmologic procedures, arterial blood gas sampling and the insertion of peripheral intravenous lines. Although they may be difficult to perform on a cadaver, these procedures may well be simulated on the cadaver or prosected specimen with or without the aid of computer technology in order to teach the clinical anatomy background of the procedure. There are limitations on how many times a procedure can be performed on a cadaver. However, for simulating a procedure on a prosected regional dissection by means of information technology does not have this limitation.

Using cadavers and specifically prosections to teach the clinical anatomy background of procedures is ideal. Focussed regional prosections relevant to the specific procedure were used in this study to demonstrate the clinical anatomy pitfalls and complications by means of multimedia computer technology. There are several advantages to simulated procedural training by means of regional dissections and computer technology:

- i) It is always available and teaching can therefore be better structured and is less opportunistic.
- ii) Repetitive teaching and interactive self-learning as well as self-pacing is possible, which is not possible on real patients.
- iii) Staff and students can discuss problems freely.
- iv) Anxiety during performance is reduced.

Simulated situations form an important part of medical education programs. One of its important benefits is their value in allowing practice of difficult, painful or embarrassing procedures⁸⁷. This ensures that doctors do not need to perform a procedure for the first time in the middle of the night without supervision and on a desperately ill patient⁹¹.

5.5.1 The use of computer technology in procedural skills training (Virtual Procedures Clinic)

Different opinions are expressed in the literature concerning the influence of instructional media on the learning process. Clark⁸⁹ argues that instructional media are merely vehicles used to deliver instruction and do not affect the learning process. Cobb⁹⁰ on the other hand argues that different media have an impact on cognitive learning but do not necessarily produce different learning outcomes. Jonassen⁹¹ suggested that media and

technologies are not merely a vehicle of content delivery, but are part of the context. Teachers therefore need to consider the instructional design, learning environment and context in delivery systems. Maddux *et al*⁹² points out that high interactivity is the most important factor which differentiates computers from other educational delivery modes.

Information and communication technology offers universities the opportunity to develop effective flexible learning environments. The barriers of distance and time are being broken down by new opportunities for optimizing interaction¹³. This is true for postgraduate and undergraduate students. Boon *et al*¹³ has shown that a CD-ROM can effectively be used by general practitioners in a postgraduate anatomy course in South Africa, and Levine *et al*⁹³ has demonstrated the efficient and flexible way in which educational technology can be utilized in undergraduate teaching in the dissection laboratory.

Tavares *et al*⁹⁴ has also shown in a study where computer based sessions were used for the teaching of radiological anatomy, that students strongly approve the use of instructional tools in the educational process. It is therefore important to translate this concept of computer-assisted environments to the teaching of procedural skills. Wigton³⁰ points out that training of the cognitive aspects of procedural skills lends itself to training through self-contained educational programs such as computer based education. Computers can be used to assist the learning of both knowledge and skills of clinical procedures.

Anatomy is one of the biomedical disciplines that has benefited most from development in computer technology, mainly due to visualization and representation of knowledge⁹⁵. The integration of resources on a CD-ROM platform can advance well beyond the limitations of a book. Learning is not only dependent on the didactic skills of a program or teacher, but also on the environment where learning takes place. The closer the learning environment comes to the environment where the knowledge base is applied, the better. Ideally both environments should be the same. This is however not always possible. According to Daetwyler⁹⁶, computer based learning environments can serve as a good platform to introduce the knowledge base to a virtual clinical environment. This principle is introduced into the virtual procedures clinic. I believe that the computer can effectively mediate the knowledge base of a procedure.

Computerized simulations on prosected anatomical dissections to illustrate the clinical anatomy pitfalls and complications, followed by actual performance of the procedure on the cadaver, seems to be a very effective teaching methodology. Kneebone³¹ described a five-stage approach to learn a surgical procedure using a multimedia CD-ROM in combination with simulated tissue as an educational framework. These stages include (1) watching of an animated graphic, (2) watching a clinical video-clip, (3) watching a demonstration on a simulated tissue model, (4) performing the procedure on a model and (5) performing the procedure on a patient under supervision.

During the present study Kneebone's³¹ approach was modified to the following relevant to clinical anatomy training of procedures by using a CD-ROM platform: (1) Studying

the clinical background (cognitive framework) to the procedure which involves indications, contraindications, a step by step outline and materials needed for the procedure, (2) studying the anatomical pitfalls and complications on animated prosections, (3) watching a simulated procedure on a prosection and (4) performing the procedure on a prosection.

There are several reasons for the choice of a CD-ROM as platform in our situation¹³. Firstly, CD-ROM is characterized by a large storage capacity for interactive media. It therefore overcomes the problem of low bandwidth currently experienced in South Africa in online course delivery. For example, images, video and animated graphics need much more bandwidth capacity than text. Secondly, CD-ROM can offer simultaneous combinations of different media formats such as text, images, graphics, sound, video and animation, with hyperlinks between them. Thirdly, general practitioners are not solely dependant on online environments and can study the content at their own work stations by using CD-ROM. Fourthly, general practitioners can access the Virtual Procedures Room in a flexible non-linear way according to their specific needs.

The CD-ROM's developed by Primal Pictures^{97,98,99} are an excellent example of how high quality media can be presented in an interactive way complementing each other as an educational package. Their programs are also available via a www platform¹⁰⁰. Treadwill *et al*¹⁰¹ has also developed CD-ROM courseware along the lines of integrating various resources on different skills in an educational program. Alexander¹⁰² has developed a radiology survival manual (webtextbook) which integrates text, radiological and superimposed anatomical images as well as patient case studies. It is created as a syllabus for a course and serves as a worldwide resource as it is freely accessible via the www. Gordon *et al*¹⁰³ has showed the efficacy of teaching procedures with a combination of computerized multimedia programs with simulations. Kneebone³¹ stresses the point that any simulation in medical practice is a prelude to real patient performance. Abrahams *et al*^{97,104} argues that computer learning reinforces the clinical understanding of the human body. This can be done by the interactive use of CD-ROM in an integrative course assisted with the use of the www and multimedia demonstrations. Abrahams *et al*⁹⁷ has developed a CD-ROM on interactive clinical anatomy and has illustrated how various media like cadaver prosections, cross sectional anatomy, skeletal anatomy, radiographic anatomy, histology and clinical correlations are interlinked with relevant text, video and audio clips, that covers the topics recommended by the Clinical Anatomy Curriculum for the 21st century by the American Association of Clinical Anatomists¹⁰⁵. These resources are accessible in a non-linear way by means of seamless navigation and a search facility across resources.

The Virtual Procedures Clinic was developed with the same philosophy of easy access to relevant information linked to various resources regarding clinical procedures. **The Virtual Procedures Clinic that was developed is attached as a CD-ROM.** The teaching program assumes a set of basic surgical skills to perform a procedure. For conduction of the workshop, it is suggested to place the computer close to the prosections on which the procedure is to be performed, with the necessary instruments for every procedure. The multimedia program serves as the knowledge base and the simulation of

the procedure on the prosection as the skills base. The student can then compare the performance of the procedure on the prosection with the simulated procedure on the screen.

The CD-ROM allows access to a wealth of clinical background information as well as clinical anatomy information linked to animated prosection images. The CD-ROM allows for self-directed learning. Extensive hyperlinks allow for easy and non-linear navigation within the program.

A non-linear access has been developed to various rooms in a Virtual Procedures Clinic. This virtual clinic environment introduces the student to various rooms in a virtual clinic. The first impression in a learning program is often very important⁹⁶. The first screen which maps out the virtual procedures clinic, communicates the “reality” of the environment in which the student is going to learn. A similar platform was used by Henderson *et al*¹⁰⁶ in his Primary Care of the HIV/AIDS patient: A Virtual Clinic.

The internet based Virtual Hospital of the University of Iowa Health Care in the USA¹⁰⁷, uses a similar platform. This Virtual Hospital allows access in a non-linear way to the following for both health care workers and patients: A welcome area to the Virtual Hospital, an environment for health care providers, for patients, a room where common problems are dealt with as well as an area beyond the Virtual Hospital. These topics are all hyperlinked to various resources by means of hypertext. These are examples environments providing functional access to medical information which is relevant to medical practice¹⁰⁸.

The same principle of a virtual environment has been used in the Virtual Procedure Clinic.

There is an increasing demand for instantly accessible information to aid general practitioners in the performance of procedures. This demand can be met by developing an electronic knowledge reference, which allows a non-linear way to access knowledge.

Several software packages can be used to accomplish this. PowerPoint® for example provides the possibility of hypertext links and hypermedia to facilitate instruction. General practitioners can therefore decide on their own route through the content by means of hypertext, linking a node of content, whether text, image, animation, audio or video to another node.

PowerPoint® was used in the development of the training program for the following reasons:

- i) The program is widely available on standard computer software packages in South Africa.
- ii) It allows for immediate use in a continued educational environment for both self-directed learning methods and lecture based teaching.
- iii) It allows for user friendly programming by the simple creation and handling of text, images, animations, video, audio, hyperlinks and hypertext as well as a non-linear mode of access. Similar to what

Carmichael *et al*¹⁰⁹ has done concerning image processing, images are easy to import into PowerPoint® after which labeling and enhancement can be done.

- iv) It allows for dynamic learning of clinical anatomy and not from a static slide, which is usually overwhelmed by information. With PowerPoint® a concept can be explained by starting with a simple image which sequentially grows in detail¹⁰⁹ with labeling and animations. This is done in an educationally sound way as relevant to the specific topic.
- v) It allows to save the file in HTML format after which it can be uploaded to a website.

The rooms in the Virtual Procedure Clinic include an orientation room, library, clinical anatomy laboratory, clinical background room and simulation room. The goal of this virtual environment was to use computer-based technology to overcome a number of obstacles in the teaching process and to integrate resources that are usually not found in one environment. The program is based on the so-called constructivist school of thought in medical education, where a student is immersed in a multimedia environment where he/she can construct their own knowledge from a variety of options⁹¹.

Simulation Room

The goal of this room is not to provide an exact simulation of the procedure, but to simulate key important points from an anatomical perspective by using computer technology and real dissections. The simulations are done in a step by step approach assisted by text, images, audio clips and animations. A similar methodical approach is followed by Kneebone¹¹⁰, pioneer of national training courses in minor surgery in the UK, in his gold standard CD-ROM on teaching surgical skills relevant to minor surgical procedures.

Chapman⁶⁰ has showed that computer simulation using complex visual anatomical images and sequential ordering of procedural steps show promise for teaching and assessing skills which are fundamental for procedural competency.

Clinical Anatomy Laboratory

Wherever possible a key anatomical pitfall or complication was illustrated on one page in the PowerPoint® environment, which is accessible in a non-linear way. High resolution images of prosections were selected to match the anatomical pitfalls and complications of the specific procedure. The images were carefully annotated by means of the functions in PowerPoint®. Similar work to annotate images in a digital way was done by Hejle¹¹¹ in Denmark on prosected material as well as by Abrahams⁹⁷ in the UK.

Further ideas regarding the lay-out and organization of the images was obtained from the program Anatomy Revealed¹¹², an award winning integrative multimedia CD-ROM program.

Audio clips were used to illustrate key points regarding anatomical pitfalls and complications. This ensures that relevant information is available to assist a graphic animation of a key point illustrated on a prosection in a way as if the professor is giving advice and comments over the shoulder of the operator. Daetwyler¹¹³ has used audio and video clips successfully in this way in his program *Headache Interaktiv*, where background information is given by a content expert.

Clinical Background Room

Wigton⁶⁸ stressed the importance of a sound background knowledge base for safe performance of procedures. We have developed this room along these lines by including information on indications, contra-indications, materials necessary and a step by step approach to perform the procedure. The CD-ROM's developed by Wigton^{114,115} are all based on a sound clinical background knowledge base which are presented by various media on a CD-ROM platform with internet linkage for updates.

Animations

Various animations were created to illustrate the position of for example the needle in a specific procedure or to illustrate a specific complication linked to a particular anatomical concept. Animations make an illustration dynamic or put the illustration into motion and can easily be used to illustrate clinical procedures. Several principles govern the use of animations as discussed by Guttman¹¹⁶. One of these is timing. It is important that the user can follow the animation and not lose interest because it moves too fast or too slow. We used the 'crawl' function in PowerPoint® to accomplish this. Another principle is anticipation where a device is created to catch the attention of the user before the action takes place. This was done by introducing an interactive icon stating what is to follow by clicking on it.

Animations in the Virtual Procedure Clinic were done in PowerPoint®, but more sophisticated animated movies require more advanced digital movie-making programs such as Macromedia Flash®.

Uses

The CD-ROM can be used in several environments. First, the busy family physician performing various procedures requires immediate access to information on pitfalls and complications and therefore use the program in his practice from his/her own desk computer station. The program can also be used for patient explanation of a proposed procedure. Secondly, the CD-ROM provides a learning tool for continued medical education on clinical procedures either individually or in small groups like a journal club in a hospital or group practice. Thirdly, the CD-ROM can be ideally used for training purposes, not only at academic institutions during residency or undergraduate medical courses, but also by hospital practices for the training of current and new intake doctors. Ideally the program should be made available during residency training of general practitioners and for learning and review near patient care areas. It can be used for

undergraduate teaching illustrating basic clinical anatomical concepts.

5.6 Limitations of the study

There are some limitations to this study:

1. Although 3 provinces in South Africa were included in the study, the scenario for clinical procedures in other parts of South Africa may be somewhat different. This study may therefore have limited geographical generalizability. It is thought however, that the data presented reflect a general picture due to the representative number of general practitioners in hospital practice that took part in the study in Gauteng, Mpumalanga and the Northern province.
2. The study has a subjective element due to the fact that perceptions were measured. Conclusions are based on self report from the survey and not on actual objective observations. It is however regarded that perceptions are important and that essential data can flow from it. Subjective perceptions form an important part of the attitude, integrally part of procedural skills. Doctors filled out the questionnaire voluntarily and anonymously.
3. No cognitive assessment of knowledge of the procedures was used. Those procedures were identified which most general practitioners rated as essential, where most difficulties and complications were met and where clinical anatomy understanding was problematic.
A next phase would be to conduct the training program that has been developed as well as cognitive assessment methods of clinical anatomy knowledge necessary for the procedure before and after the training program.
4. There may be inaccuracies on the data reflected by the survey. Terms like comfortable, difficulties and complications were not specifically defined. Some respondents may therefore have stricter or looser definitions than others.
5. A possible limitation may be the fact that an initial pilot study was not performed, which could possibly have lead to the inclusion of more procedures. Procedures that were added to the list by practitioners were done by individuals and were not by any means noted by the majority of practitioners. It is admitted that those procedures can be studied in a follow-up study, which is not considered to be part of this study.
6. Limitations exist in doing the survey. These include as mentioned earlier:
 - a. The way that the hospitals were selected were not truly in a randomized way in the sense that each hospital had an equal chance to be selected and has an influence on the data. This should be seen in the light of the fact that an equal amount of responders were from both urban and rural hospital practices coming from three different provinces in South Africa. The aim was to obtain two groups of hospital practices where at least 40 different respondees could be obtained. The fact that every hospital did not

have an equal chance to be selected may be regarded as a drawback of the survey.

- b. Some responders from the different hospital practices may have been absent on the day of the conduction of the survey or may have been busy in casualty or the operating theatre. This may have an influence on the data. The amount of responders where however more than 80% of general practitioners working in the specific hospital practices and where not previewed on the conduction of the survey. Everybody therefore had a fair chance to be included in the survey and it was attempted to include all general practitioners in the individual hospitals by conducting the survey on their weekly meeting.
- c. Anonymity may be jeopardized by the fact that the researcher was present when the questionnaires were collected in a box, for they may have felt to be identified. There was therefore a slight theoretical chance for the researcher to identify a specific respondees completed questionnaire and therefore abridge anonymity, although the respondee was assured of staying anonymous due to above mentioned measures. The researcher however protected anonymity at all times and refrained from transgressing good ethical conduct.

5.7 Recommendations

1. General practitioners should be trained to perform competently those procedures relevant to their practice situation. This includes competency in clinical anatomy underlying the safe and successful performance of procedures. Regarding hospital practice, a core set of procedures should be included in residency programs. They should at least include those 15 procedures where difficulties and complications were highly rated. The remaining procedures could form an elective group of procedures which a resident might choose from to learn when the procedure is essential to his/her present or future practice situation.
2. Clinical anatomy programs for procedural competency should be included in all Family Practice residency programs in South Africa. These should at least include the 15 problem procedures that were identified in this study.
3. A log book for procedures performed should be kept in all hospital practices. Residents should note all procedures performed as well as difficulties and complications encountered. Periodic assessment of outcomes and complications can in this way be facilitated.
4. Training programs in Family Practice should ensure that their residents acquire sufficient clinical anatomy competency in each procedure included in the program.
5. This study provides data to help define standards for procedural training. It suggests that training in procedural skills in family practice residencies should be

reexamined. Standards need to be proposed for accreditation. Procedural training of general practitioners is not only a responsibility of specialists but lies primarily with Family Medicine⁴³. It should not be assumed that because specialists usually take up this responsibility, there is no need to train general practitioners in procedural skills. This applies to both rural and urban hospital practices. The fact that the environment of family medicine training programs are often located in large urban hospitals with specialities, may provide false reassurance that general practitioners will not need procedural skills training.

6. Training of procedural skills are more important than ever. The current situation of inadequate procedural skills training programs is not acceptable. General practitioners completing the residency program need to be competent to perform the procedures relevant to their practice situation. This process actually already starts during undergraduate anatomy training.
7. We need more information on which procedures are taught in family practice residency programs as well as the competency of those completing the program.
8. We have developed a training program on a PowerPoint® platform, a widely available Microsoft package. Various more advanced modalities of simulation, video streaming and interactivity can be created in authoring environments like Macromedia. It is intended to continue this program by upgrading it in these environments. Modes of interactivity including the facility to assess clinical competence should be incorporated in the training program. These activities can be performed from a computerized platform as has been successfully done by Myers¹¹⁷ in his web-based DxR Clinician program where a clinical competency exam is conducted to assess clinical reasoning skills.
9. Health care data such as is presented in this study needs to be recognized when policy decisions regarding funding and development of health care facilities are planned as well as educational design of undergraduate and postgraduate education.
10. A pre- and post course assessment is necessary to form an audit trial which is important for future refinements of the program.

6. References

References studied for all the selected procedures are listed at the end of every specific procedure.

- ¹ American Association of Clinical Anatomists, Educational Affairs Committee. A clinical anatomy curriculum for the medical student of the 21st century: Gross anatomy. *Clin Anat* 1999; 9:71-99
- ² Cahill DR. Lachman's case studies in anatomy. New York: Oxford University Press, 1997
- ³ Bates B. A Guide to Physical Examination. Philadelphia: Lippincott, 1983
- ⁴ Willms JL, Schneiderman H, Algranati PS. Physical Diagnosis: Bedside Evaluation of Diagnosis and Function. Baltimore, MD: Williams and Wilkins, 1994
- ⁵ Coupland RE, Tresidder GC, Green NA. The teaching of anatomy. *Annals of the Royal College of Surgeons of England* 1976; 58: 434-439
- ⁶ Cottam WW. Adequacy of Medical School Gross Anatomy Education as Perceived by Certain Postgraduate Residency Programs and Anatomy Course Directors. *Clin Anat* 1999;12:55-65
- ⁷ Graney DO. Letter to the editor. *Clin Anat* 1996;9:61
- ⁸ Dando P. Medico-legal aspects of minor surgery. London: The Medical Defense Union, 1993: 4
- ⁹ Beahrs OH, Chase RA, Ger R. Gross anatomy in medical education. *The American Surgeon* 1986 May; 52(5):227-232
- ¹⁰ American Association of Clinical Anatomists, Educational Affairs Committee. The Clinical Anatomy of Several Invasive Procedures. *Clin Anat* 1999; 12:43-54
- ¹¹ Ger R. Basic Surgical Training 4: American and British scenes compared. *Clin Anat* 1996; 9: 175-182
- ¹² Grossman JA. Minor injuries and repairs. New York, London: Gower Medical, 1993
- ¹³ Boon JM, Meiring JH, Scheepers MD, Smith M, Loots M, Wolmarans H, Boon JA. Clinical anatomy – Reaching family physicians with CD-ROM and electronic communication. In: Multimedia in Health Sciences Education, Stanssaas SS et al. Logos Verlag Berlin 2001: 47-60
- ¹⁴ Hamilton G, Nagy F. A course in anatomy for emergency medicine residents. *Journal of Emergency Medicine* 1985; 3: 71-74
- ¹⁵ Rennie E. The way we teach topographical anatomy. *Medical Teacher* 1987; 9(3)
- ¹⁶ Boon JM, Meiring JH, Richards PA, Jacobs CJ Evaluation of clinical relevance of problem-oriented teaching in undergraduate anatomy at the University of Pretoria. *Surg Radiol Anat* 2001; 23:1-4
- ¹⁷ Crisp AH. The relevance of anatomy and morbid anatomy for medical practice and hence postgraduate and continuing medical education of doctors. *Postgraduate Medical Journal* 1989; 65:221-223
- ¹⁸ Phillips LG. Anatomy: How much or how little and taught by whom? *The American Surgeon* 1987 Sept; 53(9): 540-542
- ¹⁹ McMinn RMH, Hutchings RT, Logan BM. A colour atlas of Applied Anatomy. London: Wolfe Medical Publications, 1984

- ²⁰ Miller M. Education, Training, and Proficiency of Procedural Skills. *Primary Care* 1997 June; 24:231-240
- ²¹ Boon JM, Meiring JH, Richards PA. Clinical anatomy as the basis for clinical examination – development and evaluation of an introduction to clinical examination in a problem-oriented medical curriculum. *Clin Anat* 2002;15: 45-50
- ²² Peuker ET, Filler TJ, Berns T, Marschall B, Pera F, Senninger N. Klinische Anatomie als integrierendes Element in der Lehre der operativen Fächer. *Chirurg* 1998; 69: 1324-1328
- ²³ Hubbell DS, Byers PH, McKeown PP. Clinical anatomy instruction in the operating room. *Clin Anat* 1996; 9: 405-407
- ²⁴ Barrows HS, Tamblyn RM. *Problem-based learning: an approach to medical education*. New York: Springer. 1980: 9-10
- ²⁵ Nasmith L, Franco ED. Minor surgical procedures. Faculty development workshop. *Can Fam Physician* 1997; 43:715-718
- ²⁶ Rethans JJ, Sturmans F, Drop R, Van der Vleuten C, Hobus P. Does competence of general practitioners predict their performance? Comparison between examination setting and actual practice. *BMJ* 1991; 303: 1377-1380
- ²⁷ Heikes LG, Gjerde CL. Office procedural Skills in Family Medicine. *J Med Educ* 1985;60:444-53
- ²⁸ O'Connor HM, Davidson JR. Emergency Medicine Skills. Are primary care physicians adequately prepared? *Can Fam Phys* 1992;38:1789-1793
- ²⁹ Royal College of General Practitioners. *Clinical management manuals*. London: The Royal College 1989: 1
- ³⁰ Wigton RS. Training internists in procedural skills. *Annals of Internal Medicine* 1992; 116(12 pt 2): 1091-1093
- ³¹ Kneebone RL. Twelve tips on teaching basic surgical skills using simulation and multimedia. *Medical Teacher* 1999; 21: 571-575
- ³² Brown JS. Minor operations in general practice. *BMJ* 1979;1:1609-1610
- ³³ Morrison JM, Murray TS. Survey of minor surgery in general practice in the West of Scotland. *Br J Surg* 1993 Febr; 80:202-204
- ³⁴ Norris TE, Felmar E, Tolleson G. Which Procedures Should Be Taught in Family Practice Residency Programs? *Fam Med* 1997; 29:99-104
- ³⁵ De Witt DE. Skills training in primary care residency. Problems and solutions from the family practice perspective. *Postgraduate Medicine* 1987; 81: 155-162
- ³⁶ Howard B, Alexander GP. Family physicians as proceduralists: Striking a balance. *The Journal of the American Board of Family Practice* 1995; 8: 58-61
- ³⁷ National Health Services, General medical services. *Minor surgical procedures*. Dept of Health UK, 1996
- ³⁸ Nelson MS. Models for teaching emergency medicine skills. *Annals of Emerg Med* 1990; 19: 333-335
- ³⁹ Pisacano NJ. *Procedures and Skills Relating to Family Practice Residencies*. Editor, 1982 June 11;2:1
- ⁴⁰ Panting G. Caution in minor surgery. *Fam Med* 1999 March:11-13
- ⁴¹ Wigton RS, Nicolas JA, Blank LL. Procedural skills of the General Internist. A survey of 2500 physicians. *Ann Int Med* 1989; 111: 1023-1034

- ⁴² Education Committee of the General Medical Council. Recommendations on undergraduate medical education. 1993 Dec: 9
- ⁴³ Association of American Medical Colleges. Learning objectives for medical student education. Guidelines for medical schools. Washington, 1998 Jan: 5-6
- ⁴⁴ Al-Turk M, Susman J. Perceived core procedural skills for Nebraska family physicians. *Fam Pract Res J* 1992;12:297-303
- ⁴⁵ Britt H, Miles DA, Bridges-Webb C, Neary S, Charles J, Traynor V. A comparison of country and metropolitan general practice. *Med J Aust* 1993;159 Suppl:13-63
- ⁴⁶ Hamilton J. Organization for rural MDs focuses "on problems that separate us from our urban counterparts." *Can Med Assoc J* 1995; 153(2):197-200
- ⁴⁷ Eliason BC, Lofton SA, Mark DH. Influence of demographics and profitability on physician selection of family practice procedures. *J Fam Pract* 1994;39:341-7
- ⁴⁸ Wetmore SJ. Procedures in ambulatory care. Which family physicians do what in southwestern Ontario? *Can Fam Phys.* 1998;44:521-529
- ⁴⁹ Menon NK. Minor surgery in general practice. *Practitioner* 1986;230:917-919
- ⁵⁰ De Villiers MR. The availability, utilization and needs for continuing professional development of rural general practitioners in the Western and Northern Cape. *SA Fam Pract* 2000; 22(2): 11-16
- ⁵¹ Jansen JJM, Tan LHC, Van der Vleuten CPM, Van Luijk SJ, Rethans JJ, Grol RPTM. Assessment of competence in technical skills of general practitioners. *Med Educ* 1995; 29:247-253
- ⁵² Page G, Bordage G, Allen T. Developing key feature problems and examinations to assess clinical decision-making skills. *Academic Medicine* 1995; 70: 194-201
- ⁵³ Van der Vleuten CPM. The assessment of professional competence: Developments, research and practical implications. *Advances in Health Sciences Education* 1996; 1(1): 41-67
- ⁵⁴ Miller GE. The assessment of clinical skills/ competence/performance. *Academic Medicine* 1990; 65: 63-S7
- ⁵⁵ Harden R, Stevenson M, Downie W, Wilson G. Assessment of clinical competence using objective structured examinations. *BMJ* 1975; 1: 447-51
- ⁵⁶ Van der Vleuten CPM, Swanson DB. Assessment of clinical skills with standardized patients: state of the art. *Teaching and Learning in Medicine* 1990; 2:58-76
- ⁵⁷ Van der Vleuten CPM, Van Luijk SJ, Beckers HJM. A written test as an alternative to performance testing. *Medical Education* 1989; 23:97-107
- ⁵⁸ Hager P, Gonczi A, Athanasou J. General issues about assessment of competence. *Assessment and Evaluation in Higher Education* 1994; 19(1): 3-16
- ⁵⁹ Martin JA, Regehr G, Reznick R, Macrae H, Murnaghau J, Hutchison C, Brown M. Objective structured assessment of technical skill (OSATS) for surgical residents. *British J of Surg* 1997; 84:273-278
- ⁶⁰ Chapman DM, Rhee KJ, Marx JA. Open thoracotomy procedural competency: validity study of teaching and assessment modalities. *Ann Emerg Med* 1996; 28:641-647
- ⁶¹ < URL: <http://home.global.co.za> > [accessed 2 October 2001]
- ⁶² < URL: <http://www.sa-venues.com/maps> > [accessed 2 October 2001]
- ⁶³ Spivey BE. A Technique to Determine Curriculum Content. *J Med Educ* 1971; 46:269-274
- ⁶⁴ Britt H, Miles DA, Bridges-Webb C, Neary S, Charles J, Traynor V. A comparison of

- country and metropolitan general practice. *The Med J Australia* 1993; 159 Suppl: S9-S63
- ⁶⁵ Bensing JM, Foets M, Van der Velden J, Van der Zee J. De Nationale studie van ziekten en verrichtingen in de huisartspraktijk. *Huisarts en Wetenschap* 1991; 34(2): 51-61
- ⁶⁶ Abrahams PH. *The applications of Anatomy in General Practice*. Royal Society of Medicine, General Practice Section, 1985
- ⁶⁷ Wigton RS, Steinmann WC. Procedural skills training in the internal medicine residency. *J Med Education* 1984; 59: 392-400
- ⁶⁸ Wigton RS. Measuring procedural skills. *Ann Intern Med* 1996 125(12): 1003-1004
- ⁶⁹ Hawes R, Lehman GA, Hast J, O'Connor KW, Crabb DW, Lui A et al. Training resident physicians in fiberoptic sigmoidoscopy. How many supervised examinations are required to achieve competence? *Am J Med* 1986; 80: 465-70
- ⁷⁰ Boon JM, Asobayire WM. Gun shot injuries – an analysis of an epidemic in a South African secondary level public sector hospital. *The Medicine Journal*, 2001 June: 16-19
- ⁷¹ Rodney WM, Deutchman ME, Hartman KJ, Hahn RG. Obstetric ultrasound by family physicians. *J Fam Pract* 1992; 34: 186-200
- ⁷² Van der Goes T, Grzybowski SC, Thommasen H. Procedural skills training. Canadian family practice residency programs. *Can Fam Physician* 1999; 45: 78-85
- ⁷³ Heikes LG, Gjerde CL. Office procedural Skills in Family Medicine. *J Med Educ* 1985;60:444-453
- ⁷⁴ Meiring JH, Boon JM, Scheepers MD. *Clinical Anatomy, CD-ROM*. Pretoria: University of Pretoria, 2000.
- ⁷⁵ American College of Surgeons, Committee on Trauma. *Advanced Trauma Life Support Course for Physicians Student Manual*. Chicago: American College of Surgeons, 1993
- ⁷⁶ Adeyemi-Doro HO, Ojeifo J. What anatomy shall we teach medical and dental students in a primary health care curriculum? *Medical Education* 1988; 22: 407-411
- ⁷⁷ Wigton RSA. Method for Selecting which Procedural Skills should be learned by Internal Medicine Residents. *J Med Educ* 1981; 56:512-517
- ⁷⁸ Department of Education Green paper on Higher Education Transformation. Department of Education, Pretoria, South Africa, 1996: 3-9
- ⁷⁹ Hamilton J. Organization for rural MDs focuses “on problems that separate us from our urban counterparts”. *Can Med Assoc J* 1995; 153(2): 197-200
- ⁸⁰ Dronen SC, Younger JG. Central catheterization and central venous pressure monitoring. In: *Procedures for primary care physicians*. Pfenninger JL, Grant CF. St Louis London: Mosby, 1994: 270
- ⁸¹ Eliason BC, Lofton SA, Mark DH. Influence of demographics and profitability on physician selection of Family Practice Procedures. *The J of Fam Pract* 1994; 39: 341-347
- ⁸² Kennedy D. *Academic Duty*. Cambridge: Harvard University Press, 1997: 60
- ⁸³ Cahill DR, Leonard RJ, Marks Jr SC. A comment on recent teaching of human anatomy in the United States. *Surg Radiol Anat* 2000; 22:69-71
- ⁸⁴ Teichgräber UKM et al. Teaching applied anatomy to senior medical students with an emphasis on surgery and radiology. *Surg Radiol Anat* 1996;18:141-142
- ⁸⁵ Rennie W, Bloch H, Olson T. *Practical Anatomy syllabus*. Long Island Jewish Medical Center, New York, 1993
- ⁸⁶ Rennie W, Bloch H, Olson T. *Practical Anatomy*. Long Island Jewish Medical Center,

- New York: CME Conference Video, 1993
- ⁸⁷ Dacre J, Nicol M, Holroyd D. The development of a clinical skills center. *J R Coll Physicians Lond* 1996; 30(4): 318-24
- ⁸⁸ Lowry S. *Medical Education*. London: BMJ Publishing Group, 1993: 70
- ⁸⁹ Clark RE. Reconsidering research on learning from media. *Review of Educational Research* 1983; 53(4): 445-459
- ⁹⁰ Cobb T. Cognitive efficiency: Toward a revised theory of media. *Educational Technology Research and Development* 1997; 45(4):21-35
- ⁹¹ Jonassen DH, Campbell JP, Davidson ME. Learning with media: Restructuring the debate. *Educational Technology Research and Development* 1994; 42(3): 31-39
- ⁹² Maddux CD, Johnson DL, Willis JW. *Educational Computing: Learning with tomorrow's technologies*. 2nd ed. Needham Heights, MA: Allyn & Bacon, 1997
- ⁹³ Levine MG, Stempak J, Conyers G, Walters JA. Implementing and integrating computer-based activities into a problem-based gross anatomy curriculum. *Clin Anat* 1999; 12:191-198
- ⁹⁴ Tavares MA, Dinis-Machado J, Silva MC. Computer-based sessions in radiological anatomy: one year's experience in clinical anatomy. *Surg Radiol Anat* 2000; 22: 29-34
- ⁹⁵ Rosse C. The potential of computerized presentations of anatomy in the training of health care providers. *Acad Med* 1995; 70: 499-505
- ⁹⁶ Daetwyler C. How can computers assist students in the learning of clinical medicine? Wie können Computer den Studenten in seinem Bestreben unterstützen, klinische Medizin zu lernen? In: *Multimedia in Health Sciences Education*. Berlin: Logos Verlag, 2001: 71-96
- ⁹⁷ Abrahams PH. *McMinn's Interactive Clinical Anatomy*. Mosby multimedia, Harcourt Brace, St Louis, CD-ROM, version 2, 2001
- ⁹⁸ Aichroth PM, Mahadevan V, Harris JM, Stoller DW. *Interactive Knee*. CD-ROM, version 1.1. Primal Pictures: London, 1999
- ⁹⁹ Abrahams PH, Anderson J, Field D. *Interactive Skeleton, Sports and Kinetic Edition*. CD-ROM, London: Primal Pictures
- ¹⁰⁰ Primal Pictures. <URL: <http://www.anatomy.tv>> [accessed 8 October 2001]
- ¹⁰¹ Treadwill I, Makin J. *Obstetrical skills*. CD-ROM, Skills Laboratory, Pretoria: University of Pretoria, 2000
- ¹⁰² Alexander SG. A webtextbook for the teaching of radiology, concepts and interpretation to senior medical students and interns. Indiana: Indiana University School of Medicine, 2000
<URL:<http://www.indyrad.iupui.edu/public/alexanders/rsm/home.html>> [accessed 8 October 2001]
- ¹⁰³ Gordon MS, Issenberg SB, Mayer JW, Felner JM. Developments in the use of simulators and multimedia computer systems in medical education. *Medical Teacher* 1999; 21: 32-36
- ¹⁰⁴ Abrahams PH, Jordan R, Rao CV, Ambrose R. Integrating multimedia CD-Roms into the teaching of clinical anatomy. <URL: <http://www.slice.gsm.com/2000/index.html>> [accessed 5 October 2001]
- ¹⁰⁵ Educational Affairs Committee, American Association of Clinical Anatomists. A clinical anatomy curriculum for the clinical student of the 21st century: gross anatomy. *Clin Anat* 1996; 9: 71-99

-
- ¹⁰⁶ Henderson JV, Bartlett JG, Anastasi J, Dobkin J. Primary Care of the HIV/AIDS patient: A virtual Clinic. Dartmouth Medical School, Appleton and Lange New Media, CD-ROM, 1997
- ¹⁰⁷ Virtual Hospital. University of Iowa Health Care. <URL: <http://www.vh.org>> [Accessed 9 October 2001]
- ¹⁰⁸ Kiley R. Medical information on the internet. 2nd ed. Edinburgh: Churchill Livingstone, 2000: 1-6
- ¹⁰⁹ Carmichael SW, Pawlina W. Animated PowerPoint as a tool to teach anatomy. The Anatomical Record 2000; 261:83-88
- ¹¹⁰ Kneebone R, Schofield J. Minor surgery & skin lesions, diagnosis and management on CD-ROM, London: Primal Pictures, Limbs and Things, CD-ROM, 1998
- ¹¹¹ Hejle J, Peterson JK, Kneebone R, Apsimon D. <URL: <http://www.anatomi.dk/>> [accessed 5 October 2001]
- ¹¹² Schneider R, Morse D. Anatomy Revealed. Medical College of Ohio. <URL: <http://www.mco.edu/cci/anatomy/>> [accessed 5 October 2001]
- ¹¹³ Daetwyler C, Mumenthaler M. Kopfschmerz Interaktiv. AUM: Bern 2000. <URL: <http://medweb.unibe.ch/kopfschmerz/>> [accessed 5 October 2001]
- ¹¹⁴ Wigton RS, Tape TG. Mosby's Primary care procedures: Arthrocentesis. CD-ROM, University of Nebraska Medical Centre
- ¹¹⁵ Wigton RS, Tape TG. Mosby's Primary care procedures: Gynecological procedures and women's health. CD-ROM, University of Nebraska Medical Centre
- ¹¹⁶ Guttman GD. Animating functional anatomy for the web. The Anatomical Record 2000; 261: 57-63
- ¹¹⁷ Myers H. DxR Clinician web-based problem-based learning software, CD ROM. Illinois: DxR Development Group, 2001

7. Addendum 1. Questionnaire

Clinical procedures in family practice in South Africa


Dear Dr

This study is done to determine the scope of procedures done by general practitioners. Your contribution is very much appreciated and will help to focus on the important role of general practitioners in the performance of clinical procedures, which forms an important part of effective health care in South Africa.


Your questionnaire will be kept confidential. No information by which you can be identified will be released or published. The first part is on demographic data, and the second on specific procedures. You need only to tick your answer in the appropriate box. Every procedure has 8 questions to answer. The questions are repeated on every page.

A word of special thanks for your time and cooperation in completing this questionnaire.

Kind regards



Dr JM Boon
MBChB, MMed(Family Medicine)(Pret)
Senior Lecturer: Dept of Anatomy
Faculty of Medicine
University of Pretoria



Prof JH Meiring
MBChB, MpraxMed(Pret) LAKad(SA)
HEAD : Department of Anatomy
Faculty of Medicine
University of Pretoria

Demographic data:

Indicate your answer by ticking in the appropriate box:

Age	23-30	30-35	35-40	40-50	>50
Sex	Male	Female			
Date of graduation	<1970	1970-1980	1981-1990	1991-1995	1996-1999
Years in practice	< 5	6-10	11-20	21-30	> 30
Practice profile	urban private practice	urban hospital practice	rural private practice	rural hospital practice	Academic position with practice
Postgraduate training	Masters in Family Medicine	Diploma in: Family Medicine Obstetrics and Gynaecology Anaesthesia Other:		MSc (Sports Medicine)	Other:

1. I perform this procedure in my practice.
2. How many times did you perform this procedure in the past year?
3. The performance of this procedure is important in my practice situation.
4. I feel comfortable to perform this procedure.
5. I find difficulty to perform this procedure due to the following reason/s: (order in level of importance)
6. I met the following complication/s and have the following difficulties when performing this procedure
7. The improvement of critical anatomy knowledge necessary to perform this procedure will reduce difficulties and complications.
8. Improvement of anatomy knowledge necessary for the procedure will increase my confidence in performing the procedure.

Emergency procedures	1	2	3	4	5	6	7	8
Oro/naso-tracheal intubation 1	Yes	More than 20	Essential	Very comfortable	Knowledge of the procedure itself	Esophageal intubation	Strongly agree	Strongly agree
		10-20	Desirable but not essential	Fairly comfortable	Equipment necessary for the procedure	laryngospasm	Agree	Agree
	No	5-10	Useful	Uncomfortable	Practical skills to perform the procedure	Not able to visualize vocal cords	Disagree	Disagree
		Less than 5	Not necessary	Very uncomfortable	Regional anatomy knowledge		Strongly disagree	Strongly disagree
	1	2	3	4	5	6	7	8
Cricothyroidotomy 2	Yes	More than 20	Essential	Very comfortable	Knowledge of the procedure itself	Unable to find entry site for needle	Strongly agree	Strongly agree
		10-20	Desirable but not essential	Fairly comfortable	Equipment necessary for the procedure	Vocal cord paralysis	Agree	Agree
	No	5-10	Useful	Uncomfortable	Practical skills to perform the procedure	Esophageal perforation	Disagree	Disagree
		Less than 5	Not necessary	Very uncomfortable	Regional anatomy knowledge	Thyroid perforation	Strongly disagree	Strongly disagree
	1	2	3	4	5	6	7	8
Vascular access: peripheral arm veins 3	Yes	More than 20	Essential	Very comfortable	Knowledge of the procedure itself	Brachial artery puncture	Strongly agree	Strongly agree
		10-20	Desirable but not essential	Fairly comfortable	Equipment necessary for the procedure	Median nerve damage	Agree	Agree
	No	5-10	Useful	Uncomfortable	Practical skills to perform the procedure	Inability to locate vein	Disagree	Disagree
		Less than 5	Not necessary	Very uncomfortable	Regional anatomy knowledge		Strongly disagree	Strongly disagree

1. I perform this procedure in my practice.
2. How many times did you perform this procedure in the past year?
3. The performance of this procedure is important in my practice situation.
4. I feel comfortable to perform this procedure.
5. I find difficulty to perform this procedure due to the following reason/s: (order in level of importance)
6. I met the following complication/s and have the following difficulties when performing this procedure
7. The improvement of critical anatomy knowledge necessary to perform this procedure will reduce difficulties and complications.
8. Improvement of anatomy knowledge necessary for the procedure will increase my confidence in performing the procedure.

Emergency Procedures	1	2	3	4	5	6	7	8
Vascular access: femoral vein 4	Yes	More than 20	Essential	Very comfortable	Knowledge of the procedure itself	Femoral artery puncture	Strongly agree	Strongly agree
		10-20	Desirable but not essential	Fairly comfortable	Equipment necessary for the procedure	Femoral nerve transection and/or puncture	Agree	Agree
	No	5-10	Useful	Uncomfortable	Practical skills to perform the procedure	Inability to locate vein	Disagree	Disagree
		Less than 5	Not necessary	Very uncomfortable	Regional anatomy knowledge	Hip joint sepsis	Strongly disagree	Strongly disagree
	1	2	3	4	5	6	7	8
Vascular access: greater saphenous vein on the foot (1 finger breadth medially to the medial malleolus) 5	Yes	More than 20	Essential	Very comfortable	Knowledge of the procedure itself	Inability to locate vein	Strongly agree	Strongly agree
		10-20	Desirable but not essential	Fairly comfortable	Equipment necessary for the procedure	Saphenous nerve damage	Agree	Agree
	No	5-10	Useful	Uncomfortable	Practical skills to perform the procedure	Arterial transection	Disagree	Disagree
		Less than 5	Not necessary	Very uncomfortable	Regional anatomy knowledge		Strongly disagree	Strongly disagree
	1	2	3	4	5	6	7	8
Subclavian vein catheterization 6	Yes	More than 20	Essential	Very comfortable	Knowledge of the procedure itself	Inability to locate vein	Strongly agree	Strongly agree
		10-20	Desirable but not essential	Fairly comfortable	Equipment necessary for the procedure	Subclavian artery puncture	Agree	Agree
	No	5-10	Useful	Uncomfortable	Practical skills to perform the procedure	hemopneumothorax	Disagree	Disagree
		Less than 5	Not necessary	Very uncomfortable	Regional anatomy knowledge	Brachial plexus puncture	Strongly disagree	Strongly disagree

1. I perform this procedure in my practice.
2. How many times did you perform this procedure in the past year?
3. The performance of this procedure is important in my practice situation.
4. I feel comfortable to perform this procedure.
5. I find difficulty to perform this procedure due to the following reason/s: (order in level of importance)
6. I met the following complication/s and have the following difficulties when performing this procedure
7. The improvement of critical anatomy knowledge necessary to perform this procedure will reduce difficulties and complications.
8. Improvement of anatomy knowledge necessary for the procedure will increase my confidence in performing the procedure.

Emergency procedures	1	2	3	4	5	6	7	8
Internal jugular vein catheterization 7	Yes	More than 20	Essential	Very comfortable	Knowledge of the procedure itself	Inability to locate the vein	Strongly agree	Strongly agree
		10-20	Desirable but not essential	Fairly comfortable	Equipment necessary for the procedure	pneumothorax	Agree	Agree
	No	5-10	Useful	Uncomfortable	Practical skills to perform the procedure	Internal carotid artery puncture	Disagree	Disagree
		Less than 5	Not necessary	Very uncomfortable	Regional anatomy knowledge	chylothorax	Strongly disagree	Strongly disagree
	1	2	3	4	5	6	7	8
Pretibial intraosseous puncture/infusion in paediatric patients 8	Yes	More than 20	Essential	Very comfortable	Knowledge of the procedure itself	Inability to find the correct site of placement	Strongly agree	Strongly agree
		10-20	Desirable but not essential	Fairly comfortable	Equipment necessary for the procedure	Physal plate injury	Agree	Agree
	No	5-10	Useful	Uncomfortable	Practical skills to perform the procedure	osteomyelitis	Disagree	Disagree
		Less than 5	Not necessary	Very uncomfortable	Regional anatomy knowledge	Subcutaneous or subperiosteal infiltration	Strongly disagree	Strongly disagree
	1	2	3	4	5	6	7	8
Intercostal drain insertion 9	Yes	More than 20	Essential	Very comfortable	Knowledge of the procedure itself	Inability to find the correct site of placement	Strongly agree	Strongly agree
		10-20	Desirable but not essential	Fairly comfortable	Equipment necessary for the procedure	Bleeding from the intercostal vessels	Agree	Agree
	No	5-10	Useful	Uncomfortable	Practical skills to perform the procedure	Damage to the intercostal nerves	Disagree	Disagree
		Less than 5	Not necessary	Very uncomfortable	Regional anatomy knowledge	Puncture of intrathoracic and/or abdominal organs	Strongly disagree	Strongly disagree

1. I perform this procedure in my practice.
2. How many times did you perform this procedure in the past year?
3. The performance of this procedure is important in my practice situation.
4. I feel comfortable to perform this procedure.
5. I find difficulty to perform this procedure due to the following reason/s: (order in level of importance)
6. I met the following complication/s and have the following difficulties when performing this procedure
7. The improvement of critical anatomy knowledge necessary to perform this procedure will reduce difficulties and complications.
8. Improvement of anatomy knowledge necessary for the procedure will increase my confidence in performing the procedure.

Emergency Procedures	1	2	3	4	5	6	7	8
Lumbar puncture 10	Yes	More than 20	Essential	Very comfortable	Knowledge of the procedure itself	Inability to find the correct placement of the needle	Strongly agree	Strongly agree
		10-20	Desirable but not essential	Fairly comfortable	Equipment necessary for the procedure	Inability to appreciate the position of the needle while proceeding the needle	Agree	Agree
	No	5-10	Useful	Uncomfortable	Practical skills to perform the procedure	Bloody tap	Disagree	Disagree
		Less than 5	Not necessary	Very uncomfortable	Regional anatomy knowledge		Strongly disagree	Strongly disagree
	1	2	3	4	5	6	7	8
Arterial puncture for blood sampling • Radial artery • Femoral artery • Paediatric patients 11	Yes	More than 20	Essential	Very comfortable	Knowledge of the procedure itself	Inability to perform a radial artery puncture	Strongly agree	Strongly agree
		10-20	Desirable but not essential	Fairly comfortable	Equipment necessary for the procedure	Inability to locate the femoral artery	Agree	Agree
	No	5-10	Useful	Uncomfortable	Practical skills to perform the procedure	Uncertain on which artery to use in paediatric patients	Disagree	Disagree
		Less than 5	Not necessary	Very uncomfortable	Regional anatomy knowledge		Strongly disagree	Strongly disagree
	1	2	3	4	5	6	7	8
Pericardiocentesis 12	Yes	More than 20	Essential	Very comfortable	Knowledge of the procedure itself	Inability to find the correct site of placement	Strongly agree	Strongly agree
		10-20	Desirable but not essential	Fairly comfortable	Equipment necessary for the procedure	Inability to appreciate the position of the needle while placing	Agree	Agree
	No	5-10	Useful	Uncomfortable	Practical skills to perform the procedure	Injury to a coronary vessel, inferior vena cava, aorta, esophagus	Disagree	Disagree
		Less than 5	Not necessary	Very uncomfortable	Regional anatomy knowledge	Aspiration of ventricular blood	Strongly disagree	Strongly disagree

1. I perform this procedure in my practice.
2. How many times did you perform this procedure in the past year?
3. The performance of this procedure is important in my practice situation.
4. I feel comfortable to perform this procedure.
5. I find difficulty to perform this procedure due to the following reason/s: (order in level of importance)
6. I met the following complication/s and have the following difficulties when performing this procedure
7. The improvement of critical anatomy knowledge necessary to perform this procedure will reduce difficulties and complications.
8. Improvement of anatomy knowledge necessary for the procedure will increase my confidence in performing the procedure.

Emergency Procedures	1	2	3	4	5	6	7	8
Umbilical line placement 13	Yes	More than 20	Essential	Very comfortable	Knowledge of the procedure itself	Inability to find the umbilical artery	Strongly agree	Strongly agree
		10-20	Desirable but not essential	Fairly comfortable	Equipment necessary for the procedure		Agree	Agree
	No	5-10	Useful	Uncomfortable	Practical skills to perform the procedure		Disagree	Disagree
		Less than 5	Not necessary	Very uncomfortable	Regional anatomy knowledge		Strongly disagree	Strongly disagree
	1	2	3	4	5	6	7	8
Suprapubic catheterization and puncture 14	Yes	More than 20	Essential	Very comfortable	Knowledge of the procedure itself	Unsure about the site of placement of the puncture	Strongly agree	Strongly agree
		10-20	Desirable but not essential	Fairly comfortable	Equipment necessary for the procedure	Intra-abdominal placement	Agree	Agree
	No	5-10	Useful	Uncomfortable	Practical skills to perform the procedure		Disagree	Disagree
		Less than 5	Not necessary	Very uncomfortable	Regional anatomy knowledge		Strongly disagree	Strongly disagree
	1	2	3	4	5	6	7	8
Eye injury Examination 15	Yes	More than 20	Essential	Very comfortable	Knowledge of the procedure itself	Unsure about anatomical structures	Strongly agree	Strongly agree
		10-20	Desirable but not essential	Fairly comfortable	Equipment necessary for the procedure	Inability to visualize the retina and optic disc	Agree	Agree
	No	5-10	Useful	Uncomfortable	Practical skills to perform the procedure	Unsure of innervation of the eye musculature	Disagree	Disagree
		Less than 5	Not necessary	Very uncomfortable	Regional anatomy knowledge		Strongly disagree	Strongly disagree

1. I perform this procedure in my practice.
2. How many times did you perform this procedure in the past year?
3. The performance of this procedure is important in my practice situation.
4. I feel comfortable to perform this procedure.
5. I find difficulty to perform this procedure due to the following reason/s: (order in level of importance)
6. I met the following complication/s and have the following difficulties when performing this procedure
7. The improvement of critical anatomy knowledge necessary to perform this procedure will reduce difficulties and complications.
8. Improvement of anatomy knowledge necessary for the procedure will increase my confidence in performing the procedure.

Minor Surgery	1	2	3	4	5	6	7	8
Reduction of uncomplicated forearm fractures 16	Yes	More than 20	Essential	Very comfortable	Knowledge of the procedure itself	Unsure about correction of rotation	Strongly agree	Strongly agree
		10-20	Desirable but not essential	Fairly comfortable	Equipment necessary for the procedure		Agree	Agree
	No	5-10	Useful	Uncomfortable	Practical skills to perform the procedure		Disagree	Disagree
		Less than 5	Not necessary	Very uncomfortable	Regional anatomy knowledge		Strongly disagree	Strongly disagree
	1	2	3	4	5	6	7	8
Sigmoidoscopy and proctoscopy 17	Yes	More than 20	Essential	Very comfortable	Knowledge of the procedure itself	Unsure of the anatomy of the bowel mucosa	Strongly agree	Strongly agree
		10-20	Desirable but not essential	Fairly comfortable	Equipment necessary for the procedure	Unsure about the difference between sigmoid colon, rectum and anus	Agree	Agree
	No	5-10	Useful	Uncomfortable	Practical skills to perform the procedure	Bowel perforation	Disagree	Disagree
		Less than 5	Not necessary	Very uncomfortable	Regional anatomy knowledge		Strongly disagree	Strongly disagree
	1	2	3	4	5	6	7	8
D+C 18	Yes	More than 20	Essential	Very comfortable	Knowledge of the procedure itself	Unsure about the extent of the uterus in a non pregnant women	Strongly agree	Strongly agree
		10-20	Desirable but not essential	Fairly comfortable	Equipment necessary for the procedure	Uterus perforation	Agree	Agree
	No	5-10	Useful	Uncomfortable	Practical skills to perform the procedure		Disagree	Disagree
		Less than 5	Not necessary	Very uncomfortable	Regional anatomy knowledge		Strongly disagree	Strongly disagree

1. I perform this procedure in my practice.
2. How many times did you perform this procedure in the past year?
3. The performance of this procedure is important in my practice situation.
4. I feel comfortable to perform this procedure.
5. I find difficulty to perform this procedure due to the following reason/s: (order in level of importance)
6. I met the following complication/s and have the following difficulties when performing this procedure
7. The improvement of critical anatomy knowledge necessary to perform this procedure will reduce difficulties and complications.
8. Improvement of anatomy knowledge necessary for the procedure will increase my confidence in performing the procedure.

Minor surgery	1	2	3	4	5	6	7	8
Episiotomy 19	Yes	More than 20	Essential	Very comfortable	Knowledge of the procedure itself	Unsure about site of incision	Strongly agree	Strongly agree
		10-20	Desirable but not essential	Fairly comfortable	Equipment necessary for the procedure	Unsure about perineal layers when suturing	Agree	Agree
	No	5-10	Useful	Uncomfortable	Practical skills to perform the procedure		Disagree	Disagree
		Less than 5	Not necessary	Very uncomfortable	Regional anatomy knowledge		Strongly disagree	Strongly disagree
	1	2	3	4	5	6	7	8
Normal vaginal delivery 20	Yes	More than 20	Essential	Very comfortable	Knowledge of the procedure itself	Second or third degree tear	Strongly agree	Strongly agree
		10-20	Desirable but not essential	Fairly comfortable	Equipment necessary for the procedure	Unsure about determining the position of the fetal head	Agree	Agree
	No	5-10	Useful	Uncomfortable	Practical skills to perform the procedure	Unsure about anatomical landmarks during vaginal examination	Disagree	Disagree
		Less than 5	Not necessary	Very uncomfortable	Regional anatomy knowledge		Strongly disagree	Strongly disagree
	1	2	3	4	5	6	7	8
Caecarian section 21	Yes	More than 20	Essential	Very comfortable	Knowledge of the procedure itself	Unsure about anatomy of the abdominal wall when suturing	Strongly agree	Strongly agree
		10-20	Desirable but not essential	Fairly comfortable	Equipment necessary for the procedure	Difficulty to determine the site of uterine incision	Agree	Agree
	No	5-10	Useful	Uncomfortable	Practical skills to perform the procedure	Damage to the ureter	Disagree	Disagree
		Less than 5	Not necessary	Very uncomfortable	Regional anatomy knowledge	Difficulty to perform a Phannstiel incision	Strongly disagree	Strongly disagree

1. I perform this procedure in my practice.
2. How many times did you perform this procedure in the past year?
3. The performance of this procedure is important in my practice situation.
4. I feel comfortable to perform this procedure.
5. I find difficulty to perform this procedure due to the following reason/s: (order in level of importance)
6. I met the following complication/s and have the following difficulties when performing this procedure
7. The improvement of critical anatomy knowledge necessary to perform this procedure will reduce difficulties and complications.
8. Improvement of anatomy knowledge necessary for the procedure will increase my confidence in performing the procedure.

Minor surgery	1	2	3	4	5	6	7	8
Sterilization 22	Yes	More than 20	Essential	Very comfortable	Knowledge of the procedure itself	Bleeding	Strongly agree	Strongly agree
		10-20	Desirable but not essential	Fairly comfortable	Equipment necessary for the procedure	Difficulty to locate the uterine tubes	Agree	Agree
	No	5-10	Useful	Uncomfortable	Practical skills to perform the procedure		Disagree	Disagree
		Less than 5	Not necessary	Very uncomfortable	Regional anatomy knowledge		Strongly disagree	Strongly disagree
	1	2	3	4	5	6	7	8
Ectopic pregnancy 23	Yes	More than 20	Essential	Very comfortable	Knowledge of the procedure itself	Bleeding	Strongly agree	Strongly agree
		10-20	Desirable but not essential	Fairly comfortable	Equipment necessary for the procedure	Unsure about anatomy of the abdominal wall when suturing	Agree	Agree
	No	5-10	Useful	Uncomfortable	Practical skills to perform the procedure		Disagree	Disagree
		Less than 5	Not necessary	Very uncomfortable	Regional anatomy knowledge		Strongly disagree	Strongly disagree
	1	2	3	4	5	6	7	8
Circumcision 24	Yes	More than 20	Essential	Very comfortable	Knowledge of the procedure itself	bleeding	Strongly agree	Strongly agree
		10-20	Desirable but not essential	Fairly comfortable	Equipment necessary for the procedure	Difficulty to find site for incision	Agree	Agree
	No	5-10	Useful	Uncomfortable	Practical skills to perform the procedure		Disagree	Disagree
		Less than 5	Not necessary	Very uncomfortable	Regional anatomy knowledge		Strongly disagree	Strongly disagree

1. I perform this procedure in my practice.
2. How many times did you perform this procedure in the past year?
3. The performance of this procedure is important in my practice situation.
4. I feel comfortable to perform this procedure.
5. I find difficulty to perform this procedure due to the following reason/s: (order in level of importance)
6. I met the following complication/s and have the following difficulties when performing this procedure
7. The improvement of critical anatomy knowledge necessary to perform this procedure will reduce difficulties and complications.
8. Improvement of anatomy knowledge necessary for the procedure will increase my confidence in performing the procedure.

Minor surgery	1	2	3	4	5	6	7	8
Excision of external thrombosed hemorrhoids and Injection or ligation of internal hemorrhoids 25	Yes	More than 20	Essential	Very comfortable	Knowledge of the procedure itself	Difficulty to find and distinguish between hemorrhoids	Strongly agree	Strongly agree
		10-20	Desirable but not essential	Fairly comfortable	Equipment necessary for the procedure	Unsure about possible site of incision	Agree	Agree
	No	5-10	Useful	Uncomfortable	Practical skills to perform the procedure		Disagree	Disagree
		Less than 5	Not necessary	Very uncomfortable	Regional anatomy knowledge		Strongly disagree	Strongly disagree
	1	2	3	4	5	6	7	8
Appendectomy 26	Yes	More than 20	Essential	Very comfortable	Knowledge of the procedure itself	Unsure about site of incision	Strongly agree	Strongly agree
		10-20	Desirable but not essential	Fairly comfortable	Equipment necessary for the procedure	bleeding	Agree	Agree
	No	5-10	Useful	Uncomfortable	Practical skills to perform the procedure	Unable to locate appendix	Disagree	Disagree
		Less than 5	Not necessary	Very uncomfortable	Regional anatomy knowledge	Damage to cutaneous nerves	Strongly disagree	Strongly disagree
	1	2	3	4	5	6	7	8
Tonsillectomy and adenoidectomy 27	Yes	More than 20	Essential	Very comfortable	Knowledge of the procedure itself	bleeding	Strongly agree	Strongly agree
		10-20	Desirable but not essential	Fairly comfortable	Equipment necessary for the procedure	Unable to remove tonsil in fascia plane	Agree	Agree
	No	5-10	Useful	Uncomfortable	Practical skills to perform the procedure	Nerve damage	Disagree	Disagree
		Less than 5	Not necessary	Very uncomfortable	Regional anatomy knowledge	Unsure about the location of the adenoids	Strongly disagree	Strongly disagree

1. I perform this procedure in my practice.
2. How many times did you perform this procedure in the past year?
3. The performance of this procedure is important in my practice situation.
4. I feel comfortable to perform this procedure.
5. I find difficulty to perform this procedure due to the following reason/s: (order in level of importance)
6. I met the following complication/s and have the following difficulties when performing this procedure
7. The improvement of critical anatomy knowledge necessary to perform this procedure will reduce difficulties and complications.
8. Improvement of anatomy knowledge necessary for the procedure will increase my confidence in performing the procedure.

Minor surgery	1	2	3	4	5	6	7	8
Wrist block and digital nerve block 28	Yes	More than 20	Essential	Very comfortable	Knowledge of the procedure itself	Unable to locate nerves in relation to the wrist	Strongly agree	Strongly agree
		10-20	Desirable but not essential	Fairly comfortable	Equipment necessary for the procedure	Unable to locate nerves in relation to the digits	Agree	Agree
	No	5-10	Useful	Uncomfortable	Practical skills to perform the procedure		Disagree	Disagree
		Less than 5	Not necessary	Very uncomfortable	Regional anatomy knowledge		Strongly disagree	Strongly disagree
	1	2	3	4	5	6	7	8
Pudendal nerve block 29	Yes	More than 20	Essential	Very comfortable	Knowledge of the procedure itself	Unsure about anatomical landmarks to find the nerve	Strongly agree	Strongly agree
		10-20	Desirable but not essential	Fairly comfortable	Equipment necessary for the procedure		Agree	Agree
	No	5-10	Useful	Uncomfortable	Practical skills to perform the procedure		Disagree	Disagree
		Less than 5	Not necessary	Very uncomfortable	Regional anatomy knowledge		Strongly disagree	Strongly disagree
	1	2	3	4	5	6	7	8
Brachial plexus block • Scale- nus block • Supra- clavicular block • Axillary block 30	Yes	More than 20	Essential	Very comfortable	Knowledge of the procedure itself	Pneumothorax	Strongly agree	Strongly agree
		10-20	Desirable but not essential	Fairly comfortable	Equipment necessary for the procedure	Phrenic nerve paralysis	Agree	Agree
	No	5-10	Useful	Uncomfortable	Practical skills to perform the procedure	Unsure about site of entrance and direction of the needle	Disagree	Disagree
		Less than 5	Not necessary	Very uncomfortable	Regional anatomy knowledge		Strongly disagree	Strongly disagree

1. I perform this procedure in my practice.
2. How many times did you perform this procedure in the past year?
3. The performance of this procedure is important in my practice situation.
4. I feel comfortable to perform this procedure.
5. I find difficulty to perform this procedure due to the following reason/s: (order in level of importance)
6. I met the following complication/s and have the following difficulties when performing this procedure
7. The improvement of critical anatomy knowledge necessary to perform this procedure will reduce difficulties and complications.
8. Improvement of anatomy knowledge necessary for the procedure will increase my confidence in performing the procedure.

Office procedures	1	2	3	4	5	6	7	8
Injection of shoulder joint 31	Yes	More than 20	Essential	Very comfortable	Knowledge of the procedure itself	Unsure of site of entrance and direction of needle	Strongly agree	Strongly agree
		10-20	Desirable but not essential	Fairly comfortable	Equipment necessary for the procedure		Agree	Agree
	No	5-10	Useful	Uncomfortable	Practical skills to perform the procedure		Disagree	Disagree
		Less than 5	Not necessary	Very uncomfortable	Regional anatomy knowledge		Strongly disagree	Strongly disagree
	1	2	3	4	5	6	7	8
Colposcopy 32	Yes	More than 20	Essential	Very comfortable	Knowledge of the procedure itself	Unsure about anatomical landmarks	Strongly agree	Strongly agree
		10-20	Desirable but not essential	Fairly comfortable	Equipment necessary for the procedure		Agree	Agree
	No	5-10	Useful	Uncomfortable	Practical skills to perform the procedure		Disagree	Disagree
		Less than 5	Not necessary	Very uncomfortable	Regional anatomy knowledge		Strongly disagree	Strongly disagree
	1	2	3	4	5	6	7	8
Paronychia incision and drainage 33	Yes	More than 20	Essential	Very comfortable	Knowledge of the procedure itself	Unsure about site of incision	Strongly agree	Strongly agree
		10-20	Desirable but not essential	Fairly comfortable	Equipment necessary for the procedure	Unable to locate root of the nail	Agree	Agree
	No	5-10	Useful	Uncomfortable	Practical skills to perform the procedure		Disagree	Disagree
		Less than 5	Not necessary	Very uncomfortable	Regional anatomy knowledge		Strongly disagree	Strongly disagree

1. I perform this procedure in my practice.
2. How many times did you perform this procedure in the past year?
3. The performance of this procedure is important in my practice situation.
4. I feel comfortable to perform this procedure.
5. I find difficulty to perform this procedure due to the following reason/s: (order in level of importance)
6. I met the following complication/s and have the following difficulties when performing this procedure
7. The improvement of critical anatomy knowledge necessary to perform this procedure will reduce difficulties and complications.
8. Improvement of anatomy knowledge necessary for the procedure will increase my confidence in performing the procedure.

Office procedures	1	2	3	4	5	6	7	8
Upper gastrointestinal endoscopy 34	Yes	More than 20	Essential	Very comfortable	Knowledge of the procedure itself	Unsure about anatomical landmarks of the mucosal anatomy	Strongly agree	Strongly agree
		10-20	Desirable but not essential	Fairly comfortable	Equipment necessary for the procedure		Agree	Agree
	No	5-10	Useful	Uncomfortable	Practical skills to perform the procedure		Disagree	Disagree
		Less than 5	Not necessary	Very uncomfortable	Regional anatomy knowledge		Strongly disagree	Strongly disagree
	1	2	3	4	5	6	7	8
Knee joint aspiration 35	Yes	More than 20	Essential	Very comfortable	Knowledge of the procedure itself	Unable to locate the site of entry	Strongly agree	Strongly agree
		10-20	Desirable but not essential	Fairly comfortable	Equipment necessary for the procedure	Damage to coetaneous nerves of the knee joint	Agree	Agree
	No	5-10	Useful	Uncomfortable	Practical skills to perform the procedure	Damage to articular cartilage	Disagree	Disagree
		Less than 5	Not necessary	Very uncomfortable	Regional anatomy knowledge		Strongly disagree	Strongly disagree
	1	2	3	4	5	6	7	8
Liver biopsy 36	Yes	More than 20	Essential	Very comfortable	Knowledge of the procedure itself	Unsure about site of entrance	Strongly agree	Strongly agree
		10-20	Desirable but not essential	Fairly comfortable	Equipment necessary for the procedure	bleeding	Agree	Agree
	No	5-10	Useful	Uncomfortable	Practical skills to perform the procedure	pneumothorax	Disagree	Disagree
		Less than 5	Not necessary	Very uncomfortable	Regional anatomy knowledge	pneumoperitoneum	Strongly disagree	Strongly disagree

1. I perform this procedure in my practice.
2. How many times did you perform this procedure in the past year?
3. The performance of this procedure is important in my practice situation.
4. I feel comfortable to perform this procedure.
5. I find difficulty to perform this procedure due to the following reason/s: (order in level of importance)
6. I met the following complication/s and have the following difficulties when performing this procedure.
7. The improvement of critical anatomy knowledge necessary to perform this procedure will reduce difficulties and complications.
8. Improvement of anatomy knowledge necessary for the procedure will increase my confidence in performing the procedure.

Office procedures	1	2	3	4	5	6	7	8
Indirect laryngoscopy 37	Yes	More than 20	Essential	Very comfortable	Knowledge of the procedure itself	Unsure about anatomical landmarks in the larynx	Strongly agree	Strongly agree
		10-20	Desirable but not essential	Fairly comfortable	Equipment necessary for the procedure		Agree	Agree
	No	5-10	Useful	Uncomfortable	Practical skills to perform the procedure		Disagree	Disagree
		Less than 5	Not necessary	Very uncomfortable	Regional anatomy knowledge		Strongly disagree	Strongly disagree
	1	2	3	4	5	6	7	8
Epistaxis and nasal packing 38	Yes	More than 20	Essential	Very comfortable	Knowledge of the procedure itself	Unable to control bleeding	Strongly agree	Strongly agree
		10-20	Desirable but not essential	Fairly comfortable	Equipment necessary for the procedure		Agree	Agree
	No	5-10	Useful	Uncomfortable	Practical skills to perform the procedure		Disagree	Disagree
		Less than 5	Not necessary	Very uncomfortable	Regional anatomy knowledge		Strongly disagree	Strongly disagree
	1	2	3	4	5	6	7	8
Bone marrow aspiration • Sternal • Crista illaca 39	Yes	More than 20	Essential	Very comfortable	Knowledge of the procedure itself	Unsure about site of entry	Strongly agree	Strongly agree
		10-20	Desirable but not essential	Fairly comfortable	Equipment necessary for the procedure		Agree	Agree
	No	5-10	Useful	Uncomfortable	Practical skills to perform the procedure		Disagree	Disagree
		Less than 5	Not necessary	Very uncomfortable	Regional anatomy knowledge		Strongly disagree	Strongly disagree

1. I perform this procedure in my practice.
2. How many times did you perform this procedure in the past year?
3. The performance of this procedure is important in my practice situation.
4. I feel comfortable to perform this procedure.
5. I find difficulty to perform this procedure due to the following reason/s: (order in level of importance)
6. I met the following complication/s and have the following difficulties when performing this procedure
7. The improvement of critical anatomy knowledge necessary to perform this procedure will reduce difficulties and complications.
8. Improvement of anatomy knowledge necessary for the procedure will increase my confidence in performing the procedure.

Office procedures	1	2	3	4	5	6	7	8
Aspiration of pleural effusion 40	Yes	More than 20	Essential	Very comfortable	Knowledge of the procedure itself	Unsure about site of needle entrance	Strongly agree	Strongly agree
		10-20	Desirable but not essential	Fairly comfortable	Equipment necessary for the procedure		Agree	Agree
	No	5-10	Useful	Uncomfortable	Practical skills to perform the procedure		Disagree	Disagree
		Less than 5	Not necessary	Very uncomfortable	Regional anatomy knowledge		Strongly disagree	Strongly disagree
	1	2	3	4	5	6	7	8
Reduction of shoulder dislocation 41	Yes	More than 20	Essential	Very comfortable	Knowledge of the procedure itself	Unsure about technique and its rationale	Strongly agree	Strongly agree
		10-20	Desirable but not essential	Fairly comfortable	Equipment necessary for the procedure	Brachial plexus injury	Agree	Agree
	No	5-10	Useful	Uncomfortable	Practical skills to perform the procedure		Disagree	Disagree
		Less than 5	Not necessary	Very uncomfortable	Regional anatomy knowledge		Strongly disagree	Strongly disagree
	1	2	3	4	5	6	7	8
Reduction of elbow dislocation 42	Yes	More than 20	Essential	Very comfortable	Knowledge of the procedure itself	Brachial artery injury	Strongly agree	Strongly agree
		10-20	Desirable but not essential	Fairly comfortable	Equipment necessary for the procedure	Median nerve injury	Agree	Agree
	No	5-10	Useful	Uncomfortable	Practical skills to perform the procedure	Unsure about the technique and its rationale	Disagree	Disagree
		Less than 5	Not necessary	Very uncomfortable	Regional anatomy knowledge		Strongly disagree	Strongly disagree

1. I perform this procedure in my practice.
2. How many times did you perform this procedure in the past year?
3. The performance of this procedure is important in my practice situation.
4. I feel comfortable to perform this procedure.
5. I find difficulty to perform this procedure due to the following reason/s: (order in level of importance)
6. I met the following complication/s and have the following difficulties when performing this procedure
7. The improvement of critical anatomy knowledge necessary to perform this procedure will reduce difficulties and complications.
8. Improvement of anatomy knowledge necessary for the procedure will increase my confidence in performing the procedure.

Office procedures	1	2	3	4	5	6	7	8
Reduction of inter-Phalangeal joint dislocation 43	Yes	More than 20	Essential	Very comfortable	Knowledge of the procedure itself	Collateral ligament injury	Strongly agree	Strongly agree
		10-20	Desirable but not essential	Fairly comfortable	Equipment necessary for the procedure	Unsure about technique and its rationale	Agree	Agree
	No	5-10	Useful	Uncomfortable	Practical skills to perform the procedure		Disagree	Disagree
		Less than 5	Not necessary	Very uncomfortable	Regional anatomy knowledge		Strongly disagree	Strongly disagree
	1	2	3	4	5	6	7	8
Reduction of hip dislocation 44	Yes	More than 20	Essential	Very comfortable	Knowledge of the procedure itself	Unsure about technique and its rationale	Strongly agree	Strongly agree
		10-20	Desirable but not essential	Fairly comfortable	Equipment necessary for the procedure		Agree	Agree
	No	5-10	Useful	Uncomfortable	Practical skills to perform the procedure		Disagree	Disagree
		Less than 5	Not necessary	Very uncomfortable	Regional anatomy knowledge		Strongly disagree	Strongly disagree
	1	2	3	4	5	6	7	8
Naso-Pharyngoscopy 45	Yes	More than 20	Essential	Very comfortable	Knowledge of the procedure itself	Unsure about the anatomy of the nasopharynx	Strongly agree	Strongly agree
		10-20	Desirable but not essential	Fairly comfortable	Equipment necessary for the procedure		Agree	Agree
	No	5-10	Useful	Uncomfortable	Practical skills to perform the procedure		Disagree	Disagree
		Less than 5	Not necessary	Very uncomfortable	Regional anatomy knowledge		Strongly disagree	Strongly disagree

1. I perform this procedure in my practice.
2. How many times did you perform this procedure in the past year?
3. The performance of this procedure is important in my practice situation.
4. I feel comfortable to perform this procedure.
5. I find difficulty to perform this procedure due to the following reason/s: (order in level of importance)
6. I met the following complication/s and have the following difficulties when performing this procedure
7. The improvement of critical anatomy knowledge necessary to perform this procedure will reduce difficulties and complications.
8. Improvement of anatomy knowledge necessary for the procedure will increase my confidence in performing the procedure.

Office procedures	1	2	3	4	5	6	7	8
Slit lamp examination 46	Yes	More than 20	Essential	Very comfortable	Knowledge of the procedure itself	Unsure about anatomy of structures in the eye	Strongly agree	Strongly agree
		10-20	Desirable but not essential	Fairly comfortable	Equipment necessary for the procedure		Agree	Agree
	No	5-10	Useful	Uncomfortable	Practical skills to perform the procedure		Disagree	Disagree
		Less than 5	Not necessary	Very uncomfortable	Regional anatomy knowledge		Strongly disagree	Strongly disagree
	1	2	3	4	5	6	7	8
Rectal examination 47	Yes	More than 20	Essential	Very comfortable	Knowledge of the procedure itself	Unable to locate the prostate gland	Strongly agree	Strongly agree
		10-20	Desirable but not essential	Fairly comfortable	Equipment necessary for the procedure	Unable to locate the seminal vesicles	Agree	Agree
	No	5-10	Useful	Uncomfortable	Practical skills to perform the procedure	Unable to locate the cervix and uterus in a female patient	Disagree	Disagree
		Less than 5	Not necessary	Very uncomfortable	Regional anatomy knowledge		Strongly disagree	Strongly disagree
	1	2	3	4	5	6	7	8
Vaginal examination 48	Yes	More than 20	Essential	Very comfortable	Knowledge of the procedure itself	Unable to locate the bladder	Strongly agree	Strongly agree
		10-20	Desirable but not essential	Fairly comfortable	Equipment necessary for the procedure	Unable to locate the adnexae	Agree	Agree
	No	5-10	Useful	Uncomfortable	Practical skills to perform the procedure	Unable to locate the recto-uterine pouch	Disagree	Disagree
		Less than 5	Not necessary	Very uncomfortable	Regional anatomy knowledge	Unable to appreciate the position of the ureters	Strongly disagree	Strongly disagree

1. I perform this procedure in my practice.
2. How many times did you perform this procedure in the past year?
3. The performance of this procedure is important in my practice situation.
4. I feel comfortable to perform this procedure.
5. I find difficulty to perform this procedure due to the following reason/s: (order in level of importance)
6. I met the following complication/s and have the following difficulties when performing this procedure
7. The improvement of critical anatomy knowledge necessary to perform this procedure will reduce difficulties and complications.
8. Improvement of anatomy knowledge necessary for the procedure will increase my confidence in performing the procedure.

Imaging procedure	1	2	3	4	5	6	7	8
Musculo skeletal ultrasound 49	Yes	More than 20	Essential	Very comfortable	Knowledge of the procedure itself	Unable to locate anatomical structures	Strongly agree	Strongly agree
		10-20	Desirable but not essential	Fairly comfortable	Equipment necessary for the procedure		Agree	Agree
	No	5-10	Useful	Uncomfortable	Practical skills to perform the procedure		Disagree	Disagree
		Less than 5	Not necessary	Very uncomfortable	Regional anatomy knowledge		Strongly disagree	Strongly disagree
	1	2	3	4	5	6	7	8
Abdominal CT scan 50	Yes	More than 20	Essential	Very comfortable	Knowledge of the procedure itself	Unable to locate abdominal structures	Strongly agree	Strongly agree
		10-20	Desirable but not essential	Fairly comfortable	Equipment necessary for the procedure		Agree	Agree
	No	5-10	Useful	Uncomfortable	Practical skills to perform the procedure		Disagree	Disagree
		Less than 5	Not necessary	Very uncomfortable	Regional anatomy knowledge		Strongly disagree	Strongly disagree
	1	2	3	4	5	6	7	8
Brain CT scan 51	Yes	More than 20	Essential	Very comfortable	Knowledge of the procedure itself	Unable to locate abdominal structures	Strongly agree	Strongly agree
		10-20	Desirable but not essential	Fairly comfortable	Equipment necessary for the procedure		Agree	Agree
	No	5-10	Useful	Uncomfortable	Practical skills to perform the procedure		Disagree	Disagree
		Less than 5	Not necessary	Very uncomfortable	Regional anatomy knowledge		Strongly disagree	Strongly disagree

1. I perform this procedure in my practice.
2. How many times did you perform this procedure in the past year?
3. The performance of this procedure is important in my practice situation.
4. I feel comfortable to perform this procedure.
5. I find difficulty to perform this procedure due to the following reason/s: (order in level of importance)
6. I met the following complication/s and have the following difficulties when performing this procedure
7. The improvement of critical anatomy knowledge necessary to perform this procedure will reduce difficulties and complications.
8. Improvement of anatomy knowledge necessary for the procedure will increase my confidence in performing the procedure.

Imaging procedure	1	2	3	4	5	6	7	8
Chest X ray 52	Yes	More than 20	Essential	Very comfortable	Knowledge of the procedure itself	Unable to locate the borders of the heart	Strongly agree	Strongly agree
		10-20	Desirable but not essential	Fairly comfortable	Equipment necessary for the procedure	Unable to count the ribs on X-Ray	Agree	Agree
	No	5-10	Useful	Uncomfortable	Practical skills to perform the procedure	Unable to visualize pulmonary vasculature	Disagree	Disagree
		Less than 5	Not necessary	Very uncomfortable	Regional anatomy knowledge		Strongly disagree	Strongly disagree
	1	2	3	4	5	6	7	8
Abdominal X-ray 53	Yes	More than 20	Essential	Very comfortable	Knowledge of the procedure itself	Unable to differentiate small bowel from large bowel	Strongly agree	Strongly agree
		10-20	Desirable but not essential	Fairly comfortable	Equipment necessary for the procedure	Unable to visualize soft tissue	Agree	Agree
	No	5-10	Useful	Uncomfortable	Practical skills to perform the procedure	Unable to visualize the psoas line	Disagree	Disagree
		Less than 5	Not necessary	Very uncomfortable	Regional anatomy knowledge		Strongly disagree	Strongly disagree
	1	2	3	4	5	6	7	8
Pelvic X-ray 54	Yes	More than 20	Essential	Very comfortable	Knowledge of the procedure itself	Unable to locate bony landmarks	Strongly agree	Strongly agree
		10-20	Desirable but not essential	Fairly comfortable	Equipment necessary for the procedure	Unable to evaluate the pelvic brim	Agree	Agree
	No	5-10	Useful	Uncomfortable	Practical skills to perform the procedure		Disagree	Disagree
		Less than 5	Not necessary	Very uncomfortable	Regional anatomy knowledge		Strongly disagree	Strongly disagree

1. I perform this procedure in my practice.
2. How many times did you perform this procedure in the past year?
3. The performance of this procedure is important in my practice situation.
4. I feel comfortable to perform this procedure.
5. I find difficulty to perform this procedure due to the following reason/s: (order in level of importance)
6. I met the following complication/s and have the following difficulties when performing this procedure
7. The improvement of critical anatomy knowledge necessary to perform this procedure will reduce difficulties and complications.
8. Improvement of anatomy knowledge necessary for the procedure will increase my confidence in performing the procedure.

	1	2	3	4	5	6	7	8
Neck X-ray 55	Yes	More than 20	Essential	Very comfortable	Knowledge of the procedure itself	Unsure about assessment of soft tissue spaces	Strongly agree	Strongly agree
		10-20	Desirable but not essential	Fairly comfortable	Equipment necessary for the procedure	Unsure about assessment of bony landmarks	Agree	Agree
	No	5-10	Useful	Uncomfortable	Practical skills to perform the procedure	Unsure about assessment of cartilage	Disagree	Disagree
		Less than 5	Not necessary	Very uncomfortable	Regional anatomy knowledge		Strongly disagree	Strongly disagree
	1	2	3	4	5	6	7	8
Obstetric ultrasound 56	Yes	More than 20	Essential	Very comfortable	Knowledge of the procedure itself	Unable to locate anatomical structures	Strongly agree	Strongly agree
		10-20	Desirable but not essential	Fairly comfortable	Equipment necessary for the procedure	Unable to do standard obstetric measurements	Agree	Agree
	No	5-10	Useful	Uncomfortable	Practical skills to perform the procedure		Disagree	Disagree
		Less than 5	Not necessary	Very uncomfortable	Regional anatomy knowledge		Strongly disagree	Strongly disagree
	1	2	3	4	5	6	7	8
Abdominal ultrasound 57	Yes	More than 20	Essential	Very comfortable	Knowledge of the procedure itself	Unable to locate anatomical structures	Strongly agree	Strongly agree
		10-20	Desirable but not essential	Fairly comfortable	Equipment necessary for the procedure	Unable to do standard obstetric measurements	Agree	Agree
	No	5-10	Useful	Uncomfortable	Practical skills to perform the procedure		Disagree	Disagree
		Less than 5	Not necessary	Very uncomfortable	Regional anatomy knowledge		Strongly disagree	Strongly disagree

1. I perform this procedure in my practice.
2. How many times did you perform this procedure in the past year?
3. The performance of this procedure is important in my practice situation.
4. I feel comfortable to perform this procedure.
5. I find difficulty to perform this procedure due to the following reason/s: (order in level of importance)
6. I met the following complication/s and have the following difficulties when performing this procedure
7. The improvement of critical anatomy knowledge necessary to perform this procedure will reduce difficulties and complications.
8. Improvement of anatomy knowledge necessary for the procedure will increase my confidence in performing the procedure.

	1	2	3	4	5	6	7	8
Other:	Yes	More than 20	Essential	Very comfortable	Knowledge of the procedure itself		Strongly agree	Strongly agree
		10-20	Desirable but not essential	Fairly comfortable	Equipment necessary for the procedure		Agree	Agree
	No	5-10	Useful	Uncomfortable	Practical skills to perform the procedure		Disagree	Disagree
		Less than 5	Not necessary	Very uncomfortable	Regional anatomy knowledge		Strongly disagree	Strongly disagree
	1	2	3	4	5	6	7	8
Other:	Yes	More than 20	Essential	Very comfortable	Knowledge of the procedure itself		Strongly agree	Strongly agree
		10-20	Desirable but not essential	Fairly comfortable	Equipment necessary for the procedure		Agree	Agree
	No	5-10	Useful	Uncomfortable	Practical skills to perform the procedure		Disagree	Disagree
		Less than 5	Not necessary	Very uncomfortable	Regional anatomy knowledge		Strongly disagree	Strongly disagree
	1	2	3	4	5	6	7	8
Other:	Yes	More than 20	Essential	Very comfortable	Knowledge of the procedure itself		Strongly agree	Strongly agree
		10-20	Desirable but not essential	Fairly comfortable	Equipment necessary for the procedure		Agree	Agree
	No	5-10	Useful	Uncomfortable	Practical skills to perform the procedure		Disagree	Disagree
		Less than 5	Not necessary	Very uncomfortable	Regional anatomy knowledge		Strongly disagree	Strongly disagree

8. Addendum 2. Scoring options

Scoring option A

Scoring system

1. Incidence of performance	50%-74%	1 point
	75%-100%	2 points
2. Essentiality	50-75%	1 point
	76-100%	2 point
3. Comfortability	uncomfortable > 30%	3 points
	uncomfortable > 20%	2 points
	uncomfortable > 10%	1 point
4. Difficulty or complication related to anatomy experienced by	25-34%	1 point
	35-50%	2 points
5. More than 80% thought that improvement of critical anatomy knowledge necessary to perform the procedure will reduce difficulties and complications.	80-90%	1 point
	91-100%	2 points
6. More than 80% thought that improvement of anatomy knowledge necessary for the procedure will increase confidence in performing the procedure.	80-90%	1 point
	91-100%	2 points

Total: 13 points

Emergency procedures:

1. Eye injury examination
2. Reduction of shoulder dislocation
3. Vascular access: Greater saphenous vein
4. Oro/nasotracheal intubation
5. Subclavian vein catheterization
6. Lumbar puncture

Surgical procedures:

1. Caesarian section
2. Reduction of uncomplicated forearm fractures
3. Wrist and digital nerve block
4. Appendectomy

Office procedures:

1. Epistaxis and nasal packing
2. Knee joint aspiration
3. Rectal examination
4. Aspiration of pleural effusion

Imaging procedures:

1. Obstetric ultrasound
2. Abdominal ultrasound

Scoring option B

Scoring system

1. Incidence of performance	50%-74%	1 point
	75%-100%	2 point
2. Essentiality	60-79%	1 point
	80-100%	2 point
3. Comfortability	uncomfortable > comfortable	2 points
	uncomfortable > 10%	1 point
4. Difficulty or complication related to anatomy experienced by	25-34%	1 point
	35-50%	2 point
5. More than 80% thought that improvement of critical anatomy knowledge necessary to perform the procedure will reduce difficulties and complications.	80-90%	1 point
	91-100%	2 points
6. More than 80% thought that improvement of anatomy knowledge necessary for the procedure will increase confidence in performing the procedure.	80-90%	1 point
	91-100%	2 points

Total: 12 points

Emergency procedures:

1. Eye injury examination
2. Reduction of shoulder dislocation
3. Oro/nasotracheal intubation
7. Vascular access: Greater saphenous vein
5. Subclavian vein catheterization
6. Lumbar Puncture

Surgical procedures:

1. Caesarian section
2. Reduction of uncomplicated forearm fractures
3. Wrist and digital nerve block
4. Choice of 2 that need to be further selected

Office procedures:

1. Epistaxis and nasal packing
2. Rectal examination
3. Knee joint aspiration
4. Choice of 3 that need to be further selected

Imaging procedures:

1. Obstetric ultrasound
2. Abdominal ultrasound

Scoring option C

Scoring system

- | | |
|--------------------------------------------------------------------------------------------------------------------------------------------------------|---------|
| 1. Incidence of performance (>50%) | 1 point |
| 2. Essentiality (>60%) | 1 point |
| 3. Comfortability (more are uncomfortable than comfortable) | 1 point |
| 4. Difficulty or complication related to anatomy experienced by more than 25% of doctors | 1 point |
| 5. More than 80% thought that improvement of critical anatomy knowledge necessary to perform the procedure will reduce difficulties and complications. | 1 point |
| 6. More than 80% thought that improvement of anatomy knowledge necessary for the procedure will increase confidence in performing the procedure. | 1 point |

Total: 6 points

Procedures that scored highest in every section (emergency procedures, surgical procedures, office procedures and imaging procedures) were subjected to the following to select the number (emergency procedures = 6, surgical procedures = 4, office procedures = 4, imaging procedures = 2) in every category: Sum of following categories: Uncomfortable + very uncomfortable + the single highest difficulty or complication.

Emergency procedures:

1. Central venous catheterization – (subclavian and internal jugular vein catheterization)
2. Cricothyroidotomy
3. Pericardiocentesis
4. Vascular access: Greater saphenous vein
5. Oro/nasotracheal intubation
6. Lumbar puncture

Surgical procedures:

1. Appendectomy
2. Caecarian Section
3. Reduction of uncomplicated forearm fractures
4. Ectopic pregnancy surgery

Office procedures:

1. Epistaxis and nasal packing
2. Rectal examination, proctoscopy and sigmoidoscopy
3. Knee joint aspiration
4. Wrist block and digital nerve block

Imaging procedures:

1. Obstetric ultrasound

Scoring option D

Scoring system

- | | |
|--------------------------------------------------------------------------------------------------------------------------------------------------------|---------|
| 1. Incidence of performance (>50%) | 1 point |
| 2. Essentiality (>60%) | 1 point |
| 3. Comfortability (more are uncomfortable than comfortable) | 2 point |
| 4. Difficulty or complication related to anatomy experienced by more than 25% of doctors | 2 point |
| 5. More than 80% thought that improvement of critical anatomy knowledge necessary to perform the procedure will reduce difficulties and complications. | 1 point |
| 6. More than 80% thought that improvement of anatomy knowledge necessary for the procedure will increase confidence in performing the procedure. | 1 point |

Total: 8 points

Emergency procedures:

1. Cricothyroidotomy
2. Internal jugular vein catheterization
3. Pericardiocentesis
4. A choice of 5 with score of 6 that need to be further selected

Surgical procedures:

A choice of 5 that need to be further selected

Office procedures:

1. Epistaxis and nasal packing
2. Rectal examination
3. A choice of 4 that need to be selected)

Imaging procedures

1. Obstetric ultrasound
2. Abdominal ultrasound

9. Acknowledgements

Prof PH Abrahams, Kigezi International School of Medicine, Girton College, Cambridge, a special word of thanks for his untiring methodical supervision, assistance, advice and unrivalled content expertise and his introductions to experts in the academic world. A special word of thanks for the Friday lunch time hours, where the length and depth of clinical anatomy was discussed over a grand Girton College lunch treat. We will also never forget the weekend outings in the Cambridgeshire countryside.

Prof JH Meiring, Department of Anatomy, University of Pretoria, a special word of thanks for his supervision, vision and ability to create and manage opportunities in an outstanding way.

Mr T Welch, Queens College, Cambridge, a kind word of thanks for his systematic review of the content of the PhD with regard to the English language and content drawn from his expertise as traumatologist and surgeon. Many thanks for his friendship and discussions in our flat in Cranmer Road Cambridge.

Dr IG Parkin, Department of Anatomy, Cambridge, for his assistance in the Department of Anatomy in Cambridge and the opportunity to take part in the undergraduate clinical anatomy training program in Cambridge, demonstration sessions 2001 and MRCS review courses at the Department of Anatomy, University of Cambridge.

Mr RH Whitaker, Department of Anatomy, Cambridge, for his wealth of anatomical knowledge, demonstration sessions 2001 and MRCS review courses at the Department of Anatomy, University of Cambridge.

Prof T Olson, Albert Einstein School of Medicine, New York, for his advice on the anatomy of practical procedures as reflected in their postgraduate training course for emergency physicians, his hospitality in New York and willingness to introduce me to colleagues in New York in the field of clinical anatomy, 26- 30 March 2001.

Dr H Bloch, Long Island Jewish Medical Centre, New York, for her hospitality and rich experience in the training of emergency procedures from a clinical anatomical point of view. "Practical Anatomy for Emergency Medicine procedures", held on 28,29 March 2001 at the Albert Einstein College of Medicine, NY.

Dr W Rennie, Long Island Jewish Medical Centre, New York, for his wealth of knowledge in clinical anatomy, as reflected in the course presented in New York: "Practical Anatomy for Emergency Medicine procedures", held on 28,29 March 2001 at the Albert Einstein College of Medicine, NY.

Dr R Kneebone, St Mary's Hospital, London and Bath University, for his willingness to share his experience in the training of minor surgical procedures assisted with the latest

computer technology available. Minor Surgery Course, 4-5 April 2001, Bath, United Kingdom.

Mr B Logan, Department of Anatomy, University of Cambridge, for his advice on technical aspects of photography of prosections and his willingness to allow me to photograph and study his outstanding prosections in the Department of Anatomy.

Prof S Stensaas, University of Utah, Salt Lake City, for her time and advice on the development of multimedia in the field of Medical Education. Slice of Life Computers in Health Care Education Conference, Munchen, 1-4 Aug 2001.

Prof J Dacre, Professor of Medical Education, University College London Medical School, Whittington Hospital, London, for her time to observe one of her state of the art Objective Structured Clinical Assessments and her insights in medical education and student assessment. UCL Medical School, Whittington Hospital London OSCE examination, 17 July 2001.

Mr T Silver, London, for his knowledge in the field of joint injections and his willingness to let me take part in one of his well-known training sessions on joint injections. Minor Surgery Course, 4-5 April 2001, Bath, United Kingdom.

Mr V Mahadevan, Royal College of Surgeons, London, for allowing me to participate in a master class on the training of vascular surgical procedures from a clinical anatomical perspective at the Royal College of Surgeons of England, FRCS Master Class on Vascular surgical procedures, 10 September 2001, London.

Mr L Wiseman, Primal Pictures, London, for his advice on the development of Multimedia Educational software, 10 May 2001.

Prof C Van der Vleuten, University of Maastricht, The Netherlands, for his recommendations on assessment methodology on competency in clinical medicine. Advanced topics in Problem Based Learning, Maastricht, The Netherlands, 26-30 June 2000.

Dr C Daetwyler, Switzerland, for his advice on the clinical integration of multimedia software development during the Slice of Life Computers in Health Care Education Conference in Munchen, 1-4 August 2001.

Prof E April, Columbia University, New York, for his time and advice on the teaching of clinical anatomy, 28 March 2001.

Prof B Bogart, New York University, New York, for his advice on postgraduate training of clinical anatomy skills, 30 March 2001.

Dr C Goodmurphy, University of Grenada, West Indies for his sharing of knowledge in computer technology during the Slice of Life Computers in Health Care Education

Conference in Munchen, 1-4 August 2001.

Dr R Gabriel, Bath University, UK, for his willingness to allow me to take part in the Minor Surgery course for GP's. Minor Surgery Course, 4-5 April 2001, Bath, United Kingdom.

Dr E Mtui, Cornell University, New York, for the discussion we had on problem based methodologies in clinical anatomy, 28 March 2001.

Dr M Levine, Downstate Brooklyn Hospital, New York, for the time spent on discussing matters concerning the teaching of clinical anatomy, 29 March 2001.

Dr P Gobbee, Leiden University, The Netherlands, for the discussion we had on multimedia development and to share in his computer skills relevant to the teaching of clinical anatomy during the: Slice of Life Computers in Health Care Education Conference, Munchen, 1-4 Aug 2001.

Dr S Sambandan, Norwich Hospital, NHS, UK for allowing me to take part in his postgraduate course on minor surgery presented in Norwich. Norfolk and Norwich Hospital, 3 March 2001.

Prof J Biggs, Dean of Medical Education, NHS, Cambridge, for creating opportunities to meet key people in the field of postgraduate education of surgical skills.

Prof J Kauer and Dr J Bulte, Katholieke Universiteit Nijmegen, The Netherlands, for their insights in principles of medical education as reflected by the problem oriented approach followed in Nijmegen, Advanced topics in Problem Based Learning, Nijmegen, The Netherlands, 29 June 2000.

Prof I Treadwill, Skills Laboratory, University of Pretoria, for her advice on developing multimedia for skills training during the conference: Slice of Life Computers in Health Care Education Conference, Munchen, 1-4 Aug 2001.

Prof JA Boon and his team, Dept of Telematic Learning and Education Innovation, University of Pretoria, for advice on educational principles in education innovation and multimedia development.

Association of Commonwealth Universities for their excellent administration and funding of the Cambridge period of my PhD study. (2 Jan – 5 Dec 2001) Commonwealth travel grant for postgraduate studies in Cambridge.

Medical Research Council South Africa for the travel grant, which was extensively used to meet content experts around the world especially in the United Kingdom, USA, The Netherlands and Germany.

The University of Pretoria, South Africa, especially the Dean of the Faculty of Health

Sciences, Prof DJ Du Plessis, Vice Principal Prof T Erasmus and Principal Prof J van Zyl, for their support during the period of study leave in Cambridge.

The Master of Corpus Christi College, University of Cambridge and especially his secretary Margaret Cathie for all her assistance during the period 2 Jan – 5 Dec 2001.

John Bashford and his team at the Audiovisual Department in the Department of Anatomy, University of Cambridge for their advice on photography and information technology assistance.

The librarians of both the Anatomy Library at the University of Cambridge and the Academic Information Services at the University of Pretoria for their assistance in performing various literature searches.

My wife Sietske and two daughters Germien and Julia-Marie for their untiring and sustained support through late nights and early mornings.

Above all, Almighty God for His sustaining and loving grace and the privilege to work, search, investigate, dissect and describe His perfect creation to the benefit and service of patients. All the glory and honor be to Him.

10. List of Figures

Fig 1. Miller's⁵⁴ assessment pyramid correlated with assessment methods as described by Van der Vleuten⁵³

Fig 2. Map of South Africa⁶¹. The survey was performed in the provinces Gauteng, Northern Province and Mpumalanga.

Fig 3. Gauteng⁶² with the following hospitals indicated: Kalafong Hospital, Pretoria Academic Hospital and Mamelodi Hospital

Fig 4. Northern Province⁶² with the following hospitals indicated: Warmbaths Hospital, Elim Hospital, Tshilidzini Hospital and Donald Fraser Hospital.

Fig 5. Mpumalanga⁶² with the following hospitals indicated: Themba Hospital and Rob Ferreira Hospital

11. List of Tables

- Table 1. Utility of both the key features approach and OSCE.
- Table 2. List of procedures
- Table 3. Questionnaire development of aims, statements/questions and responses for every procedure
- Table 4. Questionnaires obtained from different hospitals
- Table 5. Demographic data for both urban and rural hospital groups.
- Table 6. Incidence of performance
- Table 7. Frequency of performance
- Table 8. Importance rating of emergency procedures
- Table 9. Importance rating of surgical procedures
- Table 10. Importance rating of office procedures
- Table 11. Importance rating of imaging procedures
- Table 12. Comfort with which emergency procedures are performed
- Table 13. Comfort with which surgical procedures are performed.
- Table 14. Comfort with which office procedures are performed
- Table 15. Comfort with which imaging procedures are performed.
- Table 16. Difficulties with emergency procedures
- Table 17. Difficulties with surgical procedures
- Table 18. Difficulties with office procedures
- Table 19. Difficulties with imaging procedures
- Table 20. Complications reported for all the procedures
- Table 21. Evaluation of statement: "The improvement of critical anatomy knowledge necessary to perform this procedure will reduce difficulties and complications", for emergency procedures.
- Table 22. Evaluation of statement: "The improvement of critical anatomy knowledge necessary to perform this procedure will reduce difficulties and complications", for surgical procedures.
- Table 23. Evaluation of statement: "The improvement of critical anatomy knowledge necessary to perform this procedure will reduce difficulties and complications", for office procedures.
- Table 24. Evaluation of statement: "The improvement of critical anatomy knowledge necessary to perform this procedure will reduce difficulties and complications", for imaging procedures.
- Table 25. Evaluation of statement: "Improvement of anatomy knowledge necessary for the procedure will increase my confidence in performing the procedure", for emergency procedures.
- Table 26. Evaluation of statement: "Improvement of anatomy knowledge necessary for the procedure will increase my confidence in performing the procedure", for surgical procedures.
- Table 27. Evaluation of statement: "Improvement of anatomy knowledge necessary for the procedure will increase my confidence in performing the procedure", for office procedures.
- Table 28. Evaluation of statement: "Improvement of anatomy knowledge necessary for the procedure will increase my confidence in performing the procedure", for imaging



procedures.

Table 29. List of selected problem procedures by means of Scoring option C

Table 30.. Comparison between urban and rural hospital practices regarding the selected 15 problem procedures.

Table 31. Office procedures with a high incidence of performance but significantly lower measure of comfort rating.

Table 32. Imaging procedures with a high incidence of performance but significantly lower measure of comfort rating.

(The following table content is extremely faint and illegible due to low contrast and blurring in the original image. It appears to be a list of tables or a detailed index, but the text cannot be transcribed accurately.)