

CHAPTER ONE

General introduction

1.1 Overview and historical background

Ostriches are the largest living birds, measuring up to 2.7m in height and 150 kg in weight (Deeming, 1999). These birds are considered to be seasonal breeders. Reproductive activity seems to be synchronized photoperiodically in wild ostriches and normally coincides with increasing daylength (Hicks, 1992; Mellett, 1993). Ostriches prefer to live in open, short grass plains or semi-desert areas avoiding places with long grass and dense woodland. Large populations of these birds are found in South and East Africa.

In South Africa, ostrich farming started in the 1880s in the Cape Province where the birds were taken into captivity for the production of feathers for the fashion market (Deeming and Angel, 1996). This market encouraged the development of ostrich farming in other regions of South Africa, as well as in the USA and Australia (Deeming and Angel, 1996). The market for feathers collapsed at the onset of World War I and the number of birds slumped from 250,000 in 1913 to 32,000 in 1930 (Smit, 1963). However, ostrich farming survived in South Africa and in the early 1950s there was a resurgence of the market based on the sale of ostrich skins for leather production (Deeming and Angel, 1996). Now ostrich meat has also become an important product with at least 150,000 birds being slaughtered per year in South Africa (Smith *et al.*, 1995).

In other parts of Africa, ostrich farming has developed in countries such as Namibia and Zimbabwe. Namibian farmers rear hybrid birds originating from Oudtshoorn, while Zimbabwean farmers rear an indigenous ostrich sub-species (Foggin, 1995).

Other countries involved in ostrich farming include Israel, which started production in the early 1980s (Deeming and Angel, 1996). The slaughter operation in Israel is the second largest after that in South Africa (Deeming and Angel, 1996). In the USA and Canada, the interest in ostrich farming has increased and currently the USA is estimated to have over 500,000 birds (American Ostrich Association, 1995 as cited by Deeming and Angel, 1996). In addition, many member countries of the European Union started ostrich farming in the 1990s while various countries in the Far East are also exploring the feasibility of ostrich farming (Deeming and Angel, 1996).

Ostriches seem to have been useful to humans from 5,000 to 10,000 years B.C. as evidenced by images seen in paintings and carvings found in the Sahara (Bertram, 1992; Kreibich and Sommer, 1995). In more recent times, the San have hunted these birds for meat. In addition, ostrich eggshells are used as storage and drinking vessels in Africa and Arabia, with the skin being used in protective jackets in the Arab world (Bertram, 1992). Although the skin and meat are the most economically important products today, the entire bird is utilized. For example, the feathers are used for dusters and decorations. In addition, tourism on a few ostrich farms contributes substantially to the economy (Bertram, 1992).

In view of the increasing economic importance of this bird, ostrich farming should be strengthened to improve the productivity and quality of its products. In addition, having a better knowledge of the reproductive system of ostriches will improve artificial insemination, which is an alternative breeding strategy. Extensive studies have been done on the domestic fowl, but there is a knowledge gap concerning the morphology of the female reproductive system of the sexually immature ostrich, largely due to the assumption that it conforms to the general avian pattern. This could be proved wrong since substantial variations have been reported amongst different species of birds.

As reported by Soley and Groenewald (1999), there is no information on the formation of follicles, or on the development of oocytes in the ostrich. Furthermore, although the study by Soley and Groenewald (1999) demonstrated the gross structure of the ovary in the sexually mature ostrich, it did not mention the possibility that the ovary of the sexually immature bird may change structurally during different seasons of the year. This is not surprising, as according to Kern (1972), few studies on morphological changes in the ovary associated with the seasonal reproductive cycle have been carried out. Indeed, much of the information about ovarian structure and function has been restricted to the domestic fowl (*Gallus domesticus*). However, changes in season do not appear to significantly influence the reproductive cycle in the domestic fowl (Guraya, 1989). In light of the lack of information on the ovary of the sexually immature ostrich the main objective of Chapter Two and Chapter Three was to investigate the histological structure, as well as the ultrastructure of this organ.

It is well accepted that intermediate filaments play an important role in the differentiation and structural support of the cell (Galou *et al.*, 1997; Goldman *et al.*, 1996). Intermediate filaments are abundant in epithelial cells, muscle cells and peripheral nerve fibres. In addition, immunoreactivity to the intermediate filaments desmin, vimentin and smooth muscle actin has been localized in various ovarian cells in mammals (Marettova and Marettova, 2002; Khan-Dawood *et al.*, 1996). Currently there is no information available on the presence of these intermediate filaments in the sexually immature ostrich. Thus, the distribution of the intermediate filaments: desmin, vimentin and smooth muscle actin in the ovarian tissue of the sexually immature ostrich is detailed in Chapter Four.

It has been shown in the domestic fowl that the destruction of the germinal disc region in pre-ovulatory follicles causes follicular atresia, blocks ovulation and induces apoptosis (Humphrey *et al.*, 1998). In addition, adenohipophysectomy also results in atresia suggesting that gonadotropins regulate and maintain follicular growth (Yoshimura *et al.*, 1993). This is only possible if there are hormone receptors in the target tissues or cells, which in this case would be the ovarian follicles. In addition to gonadotropins it is known that gonadal hormones control ovarian functions. However, there are no reports on the presence or distribution of steroid hormone receptors in the ostrich ovary. Thus, in Chapter Five the immunolocalization of steroid hormone receptors in the ovary of the immature ostrich was described. At present, the only information available about steroid hormone receptors in the reproductive system of the ostrich is a study by Madekurozwa (2004) in which

progesterone and oestrogen receptors were localized in the surface epithelium and tubular glands of the shell gland in immature ostriches with active ovaries.

Traditionally, it is well accepted that the innervation of any autonomous organ is important in controlling its function. The ovary, being the primary gonadal organ of the female reproductive system, is exclusively innervated by cholinergic and adrenergic nerve fibres of the autonomic nervous system (Gilbert, 1979). This fact has been reported in mammals, as well as in birds. Gilbert (1969) has studied in detail the distribution of nerve fibres in the ovary of the domestic fowl. However, there are no reports concerning the distribution of nerve fibres in the ovary of the sexually immature ostrich. Therefore, the objective of Chapter Six was to investigate the ovarian innervation in the sexually immature ostrich utilizing antibodies against neurofilament protein, protein gene product 9.5, as well as neuron specific enolase.

1.2 Justification of the study

The ostrich, being the largest of the ratites is currently an extremely valuable farm animal due to the quality of its meat and skin. As mentioned earlier, at least 150,000 birds are slaughtered per year for the meat and skin market in South Africa (Smith *et al.*, 1995).

It has been found that in the prepubertal male ostrich, testicular morphology and spermatogenic activity change throughout the year. A report by Madekurozwa *et al.* (2002) showed that spermatogenesis progressed to the stage of spermatozoa during the active stage of the testicular cycle or breeding season; that is the testes contained the full complement of spermatogenic cells from spermatogonia, spermatocytes, spermatids to spermatozoa. It is not known if the same seasonal changes occur in the sexually immature female. Therefore, the results of this study will fill an important gap in our knowledge of the morphology of the ovary in the immature ostrich. This knowledge should contribute much to our understanding of the morphophysiology of reproduction in the ostrich, with possible influences on husbandry practices in commercial ostrich farming.

1.3 General methodology

A total of 26 sexually immature (12 - 14 months old) female ostriches were used in this study. The birds were 90 – 100 kg in weight. The ostrich gearboxes (carcass without the skin, head and limbs- essentially the thoracoabdomen) were purchased from commercial ostrich abattoirs. The ovaries were removed at the abattoir to reduce further the length of time between the death of the birds and the collection of tissue samples. Tissue samples were then processed in the histopathology laboratory and Electron Microscopy Unit of the Faculty of Veterinary Science, University of Pretoria.

1.3.1 Experimental design

Specimens were collected for a period of twelve months to cover all seasons of the year. The twelve-month period was divided into three phases based on climatic conditions in South Africa (Fig.1.1). The three phases were the breeding or active reproductive phase (August to February), the regressive reproductive phase (March to early May) and inactive reproductive phase (Late May to July).

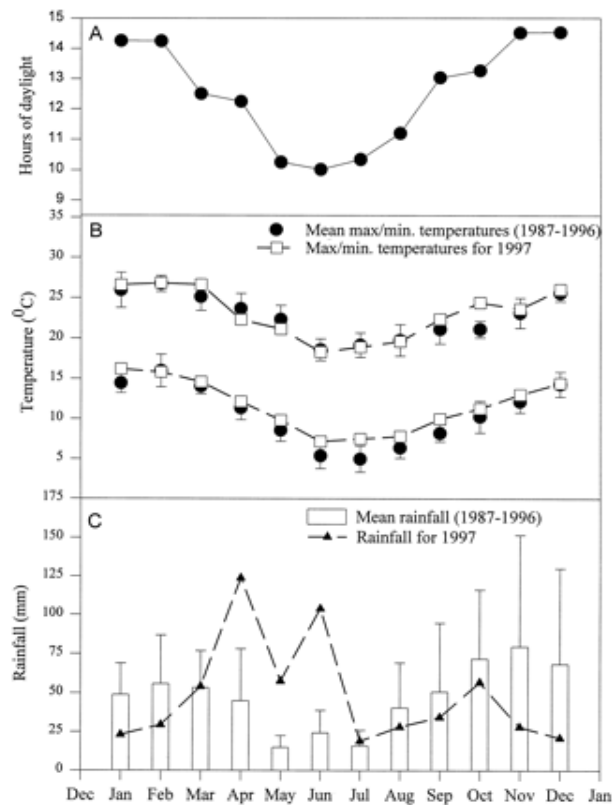


Fig. 1.1. Hours of daylight (A) and a comparison of temperature (B) and rainfall (C) patterns for 1997 with mean values for the last 10 yr (1987–1996) in South Africa.

Source: Jackson and Bernard (1999). *Biology of Reproduction* 60, 1320-1323

1.4 References

- BERTRAM, B.C.R. 1992. *The ostrich communal nesting system*. Princeton New jersey: Princeton University Press. Pp. 7-11.
- DEEMING, D.C. 1999. *The ostrich Biology, Production and Health*. USA and UK: CAB Publishing. Pp. 1-9.
- DEEMING, D.C. & ANGEL, C.R. 1996. Introduction to the ratites and farming operations around the world, in: *Improving our understanding of ratites in a farming environment. Proceedings of the International Ratite Conference*. March 1996, University of Manchester.
- FOGGIN, C.M. 1995. The ostrich industry in Zimbabwe, in: *Improving our understanding of ratites in a farming environment. Proceedings of the International Ratite Conference*. March 1996, University of Manchester.
- GALOU, M., GAO, J., HUMBERT, J., MERICKSKAY, M., LI, Z., PAULIN, D. & VICART, P. 1997. The importance of intermediate filaments in the adaptation of tissues to mechanical stress: evidence from gene knockout studies. *Biology of the Cell*, 89:85-97.
- GILBERT, A.B. 1969. Innervation of the ovary of the domestic hen. *Quarterly Journal of Experimental Physiology*, 54:409-411.

GILBERT, A.B., 1979. Female genital organs, in: *Form and Function in Birds*, edited by A. S. King & J. McLelland. London: Academic Press. pp. 237 – 360.

GOLDMAN, R.D., KHUON, S., CHOU, Y.H., OPAL, P. & STEINERT, P.M. 1996. The function of intermediate filaments in cell shape and cytoskeletal integrity. *The Journal of Cell Biology*, 134:971-983.

GURAYA, S.S. 1989. Ovarian follicles in reptiles and birds, in: *Zoophysiology*, Vol. 24, edited by W. Burggren. Berlin: Springer-Verlag. Pp. 212-221.

HICKS, K.D. 1992. *Ratite reproduction. Proceedings of the Association of Avian Veterinarian*. Pp. 318-324.

HUMPHREY, H.Y., KENDRA, K.V. & JANICE, M. B. 1998. Destruction of the germinal disc region of an immature preovulatory chicken follicle induces atresia and apoptosis. *Biology of Reproduction*, 59:516-521.

KERN, M.D. 1972. Seasonal changes in the reproductive system of the female white crowned sparrow (*Zonotrichia leucophrys gambelii*) in captivity and in the field. The Ovary. *Zeitschrift fur Zellforschung*, 126:297–319.

- KHAN-DAWOOD, F.S., DAWOOD, M.Y. & TABIBZADEH, S. 1996. Immunohistochemical analysis of the microanatomy of primate ovary. *Biology of Reproduction*, 54:734-742.
- KREIBICH, A. & SOMMER, M. 1995. *Ostrich Farm Management*. Germany: Landwirtschaftsverlag GmbH. Pp. 7-20.
- MADEKUROZWA, M.C. 2004. Immunohistochemical localization of the progesterone and oestrogen receptors in the shell gland of sexually immature ostriches (*Struthio camelus*) with active or inactive ovaries. *Research in Veterinary Science*, 76:63-68.
- MADEKUROZWA, M-C., CHABVEPI, T.S., MATEMA, S. & TEERDS, K.J. 2002. Relationship between seasonal changes in spermatogenesis in the juvenile ostrich (*Struthio camelus*) and the presence of the LH receptor and 3 β -hydroxysteroid dehydrogenase. *Reproduction*, 123:735-742.
- MARETTOVA, E. & MARETTA, M. 2002. Demonstration of intermediate filaments in sheep ovary. *Acta Histochemica*, 104:431-434.
- MELLETT, F.D. 1993. Ostrich production and products, in: *Livestock Production Systems, Principles and Practice*, edited by C. Maree & N.H. Casey. Pretoria: Agri Development foundation. Pp. 187-194.

SMIT, D.J. 1963. REPUBLIC OF SOUTH AFRICA. Department of Agriculture and Technical services. 1963. *Ostrich farming in the little Karoo*. Bulletin 358.

SMITH, W. A., CILLIERS, S.C., MELLETT, F.D. & VAN SCHALKWYK, S.J. 1995. Ostrich production - a South African perspective, in: *Biotechnology in the Feed Industry*, edited by T.P. Lyons & K.A. Jaques. Nottingham: Nottingham University Press. Pp. 175-195.

SOLEY, J.T. & GROENEWALD, H.B. 1999. Anatomy of the female reproductive system, in: *The Ostrich Biology, Production and Health*, edited by D.E. Deeming. USA and UK: CABI publishing. Pp. 144-147.

YOSHIMURA, Y., CHANG, C., OKAMOTO, T. & TAMURA, T. 1993. Immunolocalization of androgen receptor in the small, preovulatory, and postovulatory follicles of laying hens. *General and Comparative Endocrinology*, 91:81-9.

CHAPTER TWO

The gross anatomical and histological structure of the ovary in the sexually immature ostrich

2.1 Introduction

Duerden (1912) and Cho *et al.* (1984) described the ovary of the sexually immature ostrich as a single, thin, flattened elliptical to rectangular structure. In addition, the ovary in the young chick was described as being pale in colour and measuring about 12mm in length. According to Soley and Groenewald (1999) the ovary in the sexually mature ostrich resembles a bunch of grapes and consists of a stroma, which contains follicles of different sizes. Although the gross structure of the ovary in the ostrich has been studied extensively, relatively little is known about the histological structure of the ovary in this species.

It is a well-established fact that ovarian follicles undergo a cycle of growth and degeneration (Gilbert *et al.*, 1983). Furthermore, it is known that only a small fraction (<1%) of the follicles that begin development ovulate, with the majority undergoing atresia (Vickers *et al.*, 2000). In the domestic fowl, it has been estimated that, for every twenty ovarian follicles that grow to a size of 6 to 8mm in diameter, only one will remain viable long enough to be selected into the preovulatory hierarchy; the remainder undergo atresia and become resorbed (Gilbert *et al.*, 1983). This observation reveals a high incidence of atresia before maturity.

Between two to five different types of atresia have been reported in various species of birds, including the white-crowned sparrow (Kern 1972), the pied myna (Gupta and Maiti, 1986) and the domestic fowl (Gupta *et al.*, 1988). The different forms of atresia described include liquefaction (Kern, 1972), invasion (Guraya, 1976a; Gupta and Maiti, 1986), lipoidal (Marshall and Coombs, 1957), as well as glandular and lipoglandular (Guraya, 1976a). Significantly, all the types of atresia mentioned show large discrepancies in morphology, which is thought to be due to problems related to the processing techniques employed (Gilbert, 1979). To overcome these problems, Gupta *et al.* (1988) carried out a detailed investigation of the ovary in the domestic fowl and characterized all types of atresia into two groups: non-bursting (type 1) and bursting (type 2). Gupta and Maiti (1986) pointed out that the most common type of atresia in birds is bursting atresia. Bursting atresia is characterized by a rupture of the follicular wall and the subsequent escape of yolk contents into either the ovarian stroma (Gupta and Maiti, 1986) or the peritoneal cavity (Dominic, 1961).

Follicular atresia occurs by apoptosis and the large majority of cells undergoing this process appear to be of granulosa cell origin (Johnson *et al.*, 1996). It has been suggested that follicular apoptosis is driven by the status of the Bcl-2:Bax rheostat and cysteine proteases (CPP32), which are key effectors of granulosa cell death (Van Nassauw and Harrisson, 1999). Bcl-2, which is an oncogene associated with human B cell lymphoma, has a role in the prevention of apoptotic cell death in a variety of cell types including mammalian lymphocytes (Korsmeyer, 1992; Boise *et al.*, 1993; Reed, 1994),

neurons (Garcia *et al.*, 1992; Allsopp *et al.*, 1993) and haematopoietic cell lineages (Tushinski *et al.*, 1982; Lotem and Sachs, 1989; Williams *et al.*, 1990). Research on non-gonadal tissues has centred on the function of protooncogene and tumor suppressor gene products as mediators of cell survival. Two members of the Bcl-2 gene (Bcl-x long and Bcl-x short) have been found in the domestic fowl (Johnson *et al.*, 1999). Bcl-x long protein products show similar activities to Bcl-2 and prevent apoptosis. Bcl-x short, in contrast to Bcl-2, counteracts the activity of Bcl-2 by promoting cell death.

The apoptotic process could also be induced by the withdrawal of survival factors such as gonadotrophin and growth hormone (Uilenbroek *et al.*, 1980; Chun *et al.*, 1994). Likewise, cytotoxic factors within the follicle or the activation of one or more cysteine proteases (caspases 3 and 6) could also induce apoptosis (Johnson and Bridgham, 2000). Although it is now known that apoptotic cell death occurs, at least initially, within the granulosa cell layer (Johnson and Bridgham, 2000), it is still not well-established whether the signals for the apoptotic process originate from within granulosa cells or are initiated by germ cells or extracellular signals, such as cytokines and hormones (Gupta and Maiti, 1986).

The susceptibility of the avian ovarian follicle to apoptosis varies with the stage of development (Johnson *et al.*, 1996). In slow growing, prehierarchal follicles (6-8mm diameter), the granulosa cells are more susceptible to apoptosis than cells of the pre-ovulatory follicles (Johnson *et al.*, 1996). In contrast to apoptosis-sensitive granulosa cells, granulosa cells that are

resistant to apoptosis contain significantly higher levels of mRNA encoded for the death-suppressing gene, Bcl-x long (Johnson, *et al.*, 1996).

Despite the fact that various forms of atresia have been observed in a wide range of bird species, no information is available on this process in the sexually immature ostrich. Therefore, in this Chapter the morphology of healthy and atretic ovarian follicles in the sexually immature ostrich is described.

2.2 *Materials and methods*

The ovary was exposed *in-situ* by removing the intestines. The location of the left ovary was noted. The ovary was then removed by cutting through its stalk, after which any fat and connective tissue were removed. 1cm³ pieces of ovary were then fixed in Bouin's fluid for 12 hours. Intact yolk-filled follicles were placed in Bouin's fluid and were cut after 12 hours to avoid the escape of the yolk. Thereafter, the tissue samples were washed in several changes of 70% alcohol to remove most of the picric acid from the tissue and stored in the same concentration of alcohol pending further histological processing.

2.2.1 Light microscopic study

Tissue samples fixed in Bouin's fluid were processed for histology using an automated tissue processor. The tissues were then embedded in paraffin wax. 5µm - thick sections were cut with a microtome. The sections were then

stained with Haematoxylin and Eosin (H&E). The sections were studied under a light microscope (Olympus BH 2) at magnifications of x100 to x400.

2.3 Results

2.3.1 Gross anatomy

Only the left ovary was present in the sexually immature ostrich. The ovary lay in the cranial part of the body cavity, ventral to the aorta and the caudal vena cava. Caudally it was related to the cranial extremity of the left kidney. In addition, the caudal part of the left lung made contact with the cranial part of the ovary. Ventrally the ovary was covered by the abdominal air sac. The ovary was a pink-brown, elongated structure with two major extremities: a broad base cranially, and a narrow apex, directed caudally (fig. 2.1). In addition, the ovary had a short stalk, which was located ventral to the abdominal aorta and the caudal vena cava. An oval-shaped, convoluted germinal region was located ventral to the ovarian stalk.

The active ovary was approximately 5 to 7cm in length and contained between 25 to 30 follicles; with the diameters of the largest follicle ranging from 11 to 19mm. In addition, both healthy and atretic follicles were observed. White and yellow-yolk healthy follicles were observed, with the latter being more predominant. Each follicle possessed an individual stalk. Follicles were classified as atretic based on criteria detailed by Gilbert *et al.* (1983). In

contrast to healthy follicles, atretic follicles were deformed and flaccid (fig. 2.2). In addition, haemorrhagic areas were observed on the follicular surface.

In contrast to the active ovary, the ovarian surface of the inactive ovary was flat, with a granular appearance due to the presence of numerous follicles, which were less than 2mm in diameter (fig. 2.3).

2.3.2 Light microscopy (H&E staining)

2.3.2.i General overview of cortex and medulla

The ovarian surface was lined by a germinal epithelium, which consisted of a single layer of cuboidal cells. The ovary had an outer cortex and an inner medulla. The cortex (*zonae parenchymatosae*) contained numerous follicles at different stages of development (fig. 2.4). The medulla (*zonae vasculosae*) contained connective tissue, blood vessels, and nerves (fig. 2.4).

2.3.2.ii Healthy follicles

The cortex of the ovary contained primordial (100 -110µm in diameter), previtellogenic (111- 449µm in diameter), as well as vitellogenic follicles (\geq 450µm in diameter).

2.3.2.ii.a. Primordial follicles

Primordial follicles were distributed singly within the cortex. The follicles were composed of an oocyte surrounded by a layer of flat to cuboidal granulosa

cells. In these follicles, a crescent-shaped Balbiani's vitelline body was evident close to the nuclear membrane (fig. 2.5). The oocyte nucleus generally contained darkly stained chromosomes. Nuclear bodies, attached to chromosomes, were also observed. A single layer of fibrocytes enclosed the follicle.

2.3.2.iib. Previtellogenic follicles

Nuclear bodies were not observed in early previtellogenic follicles. However, condensed chromosomes were observed in the central regions of the nucleus. A spherical or oval-shaped Balbiani's vitelline body was evident adjacent to the nuclear membrane (fig. 2.6). An oval-shaped, pale-staining yolk nucleus was located in the peripheral regions of Balbiani's vitelline body (fig. 2.7).

In the early previtellogenic phase, the granulosa cell layer was generally simple columnar, although pseudostratified columnar epithelium was occasionally evident. The granulosa cell layer was demarcated from the thecal layer by a thin basement membrane. However, at this stage the thecal layer did not appear to be differentiated into theca interna and externa (fig. 2.6).

In the late previtellogenic phase, Balbiani's vitelline body was typically indistinct. However, in a few follicles a fragmented Balbiani's vitelline body was observed in the peripheral regions of the ooplasm (fig. 2.8). The granulosa cell layer in these follicles was generally pseudostratified columnar.

The thecal layer, which appeared to be thicker than that of early previtellogenic follicles, had differentiated into a theca interna and theca externa (fig. 2.8). The theca interna contained predominantly fibroblasts and a few undifferentiated thecal gland cells. The theca externa consisted of fibroblasts, undifferentiated and differentiated thecal gland cells. Undifferentiated thecal gland cells contained oval nuclei surrounded by scant cytoplasm. Differentiated thecal gland cells possessed abundant clear cytoplasm which enclosed a centrally-located round nucleus. The theca externa appeared to contain more undifferentiated thecal gland cells than differentiated thecal gland cells. Although most of the thecal gland cells were distributed singly, groups of two to three cells were occasionally identified (fig. 2.9).

2.3.2.iic. Vitellogenic follicles

The oocytes in vitellogenic follicles were generally filled with yolk granules and vesicles (fig. 2.10 & 2.11). Membrane-bound yolk vesicles were predominant and occupied most of the oocyte. The yolk vesicles were typically round to oval in shape. Small dark yolk granules were observed in the yolk vesicles. Darkly-stained lipid droplets were located in the peripheral regions of the oocyte. No Balbiani's vitelline bodies were observed in vitellogenic follicles.

In vitellogenic follicles, the granulosa cell layer was composed of a simple cuboidal or columnar epithelium. As in the case of previtellogenic follicles, the

thecal layer in vitellogenic follicles was clearly differentiated into theca interna and theca externa, with the latter being of a greater thickness (fig. 2.12).

2.3.2.iii Atretic follicles

2.3.2.iiia. Primordial follicles in atresia

Atresia of the primordial follicles (100 -110 μm in diameter) was common. The atretic primordial follicles underwent shrinkage and eventually blended with the stroma (fig. 2.13).

2.3.2.iiib. Previtellogenic follicles in atresia

Atresia in previtellogenic follicles (111 - 449 μm in diameter) was marked by the presence of a shrunken oocyte (fig. 2.14). Occasional atretic follicles exhibited large vacuoles of various sizes within the oocyte (fig. 2.15). In the majority of atretic previtellogenic follicles, the granulosa cell layer was multilayered, scalloped and detached from the theca interna (fig. 2.16). In addition, the granulosa cells in some follicles contained pyknotic nuclei. There appeared to be an increased density of connective tissue fibres in the theca externa of atretic previtellogenic follicles (fig. 2.15). Thecal gland cells were observed in the theca externa of these follicles.

2.3.2.iiic. Vitellogenic follicles in atresia

Vitellogenic follicles displayed two forms of atresia, which are designated as type I and type II in this study. In the early stages of type I atresia, the granulosa cell layer was discontinuous and scalloped. In these follicles the

theca interna contained vacuolated cells, whilst the theca externa was hyalinized. Later, the granulosa cell layer dispersed resulting in the invasion of the oocyte by the vacuolated thecal cells (fig. 2.17). Fibroblast-like cells were observed in the central regions of the follicle along the inner edge of the vacuolated cell layer. In the advanced stages of type I atresia the entire follicle was filled with hyalinized connective tissue, which contained numerous blood vessels (fig. 2.18).

The early stages of type II atresia were characterized by the proliferation of granulosa and theca interna cells. The theca externa in these follicles was composed of loose connective tissue, rather than the hyalinized connective tissue present in type I atresia. Fibroblast-like cells were also observed in the central regions of the follicle. In the later stages of type II atresia the granulosa and theca interna cells differentiated into interstitial gland cells, which eventually occupied the entire follicle (fig. 2.19). Several blood vessels were observed within the interstitial gland mass. In the advanced stages of atresia, cords of connective tissue, originating from the stroma, invaded the glandular mass resulting in the fragmentation of the interstitial gland mass and the dispersal of clusters of gland cells in the stroma (fig. 2.20). Numerous blood vessels were located between the groups of stromal interstitial gland cells.

2.3.2.iv Stroma

The ovarian stroma was composed of cellular and connective tissue elements, which occupied the areas between the follicles. The cells within the stroma included stromal cells and sparsely distributed fibrocytes. The stromal cells contained dark, round nuclei, which were placed at the centre of a clear cytoplasm. Connective tissue cords, which contained numerous fibrocytes, extended from the tunica albuginea into the medulla. Stromal interstitial glands occupied a large part of the stroma, especially in ovaries that contained atretic follicles (fig. 2.20). Several blood vessels and nerves were present in the stroma.

2.4 Discussion

The present study has demonstrated the gross anatomical and histological structure of the ovary in the sexually immature ostrich. In addition, the morphological changes occurring in the ovarian follicles during folliculogenesis and atresia have also been highlighted. Based on the fact that female ostriches attain sexual maturity between 2 and 4 years (Hicks-Allredge, 1998), the precocious ovarian activity reported in this study could be as a result of juvenile photorefractoriness. In birds exhibiting juvenile photorefractoriness gonadal development is stimulated by increasing daylength after an exposure to short daylength (Williams *et al.*, 1987; Dawson and Goldsmith, 1989; McNaughton *et al.*, 1992).

The results of the present study suggest that the histological morphology of healthy follicles in the sexually immature ostrich is similar to that of other avian species (Guraya, 1976b; Perry *et al.*, 1978; Gilbert, 1979). As in other species of birds, the ovary of the sexually immature ostrich is composed of primordial, previtellogenic, and vitellogenic follicles. In the present study primordial follicles were distributed singly in the ovarian cortex. This pattern of distribution is similar to that observed in the common myna, *Acridotherens tristis* (Chalana and Guraya, 1979a). In contrast to these findings, primordial follicles in the crow, *Corvus splendens* are organized in clusters (Chalana and Guraya, 1979b).

In the primordial and early previtellogenic follicles of the sexually immature ostrich, Balbiani's vitelline body was a notable feature. The occurrence of a distinct Balbiani's vitelline body, in primordial follicles, has also been reported in the pigeon, *Columba livia*, the brown dove, *Streptopelia senegalensis*, the ring dove, *Streptopelia dacocto*, the domestic fowl, *Gallus domesticus* and the Japanese quail, *Cortunix cortunix japonica* (Guraya, 1976b). Balbiani's vitelline body consists of a yolk nucleus, mitochondria, Golgi complex and lipid droplets (Guraya, 1976b). Balbiani's vitelline body is thought to be the centre for the initial multiplication and differentiation of cytoplasmic organelles (Guraya, 1976b).

The yolk nucleus has been shown to form an integral part of Balbiani's vitelline body in the domestic fowl (Guraya, 1976b). Likewise, in the immature ostrich, a yolk nucleus was observed associated with Balbiani's vitelline body.

According to a report by Guraya (1976b), the yolk nucleus controls the multiplication and aggregation of mitochondria and endoplasmic reticulum cisternae, which form Balbiani's vitelline body.

In the current study, gland cells were observed in the thecal layer of previtellogenic and vitellogenic follicles, as well as in the ovarian stroma. Although most of the gland cells were distributed singly, groups of two to three gland cells were occasionally observed. In birds thecal gland cells are a common feature of the thecal layer in healthy follicles (Guraya and Chalana, 1976). The origin, ultrastructure and functional importance of these gland cells is discussed in Chapter Three.

Based on the classification of atretic follicles by Gupta *et al.* (1988), only the non-bursting form of atresia was observed in the present study. This could be due to the fact that, the ovarian follicles in the sexually immature ostrich were small, immature follicles. As reported by Gupta *et al.* (1988), in the domestic fowl, the non-bursting form of atresia generally affects small follicles less than 1mm in diameter. Similar observations have also been reported in the pied myna (Gupta and Maiti, 1986). In non-bursting atresia the yolk is resorbed *in-situ* whereas in bursting atresia the yolk is released through a ruptured follicular wall. In the current study, atretic follicles were identified based on their characteristic features, which included a shrunken oocyte, a multilayered granulosa cell layer, a vacuolated oocyte, as well as degenerated granulosa cells. In the domestic fowl the presence of a shrunken oocyte is one of the characteristic features of cystic atresia (Gupta and Maiti, 1986). In follicles

displaying cystic atresia the oocyte is separated from the granulosa cell layer by a wide space. The description of cystic atresia in the domestic fowl concurred with observations made in the present study, except that the shrunken oocytes in the sexually immature ostrich occasionally contained large vacuoles.

As stated in the results, vitellogenic follicles expressed two forms of atresia. Type I atresia was marked by an invasion of the oocyte by vacuolated theca interna cells, as well as fibroblast-like cells, which were presumed to be of thecal origin. In contrast to type I atresia, vacuolated granulosa and theca interna cells infiltrated the oocyte in type II atresia. The vacuolated cells subsequently differentiated into interstitial gland cells. This observation was similar to findings made in the domestic goose where theca interna cells of atretic follicles transformed into glandular cells (Forgo *et al.*, 1988). The report further showed that the glandular cells contained lipid droplets, which suggested the accumulation of cholesterol esters, which are known to be steroid precursors. In support of this finding, Guraya, (1989) reported the ability of interstitial gland cells to synthesize steroid hormones. To date, it is not known whether steroidogenesis occurs in the interstitial gland cells of the sexually immature ostrich. Therefore, further studies need to be carried out to establish the steroidocompetence of interstitial gland cells in the sexually immature ostrich.

The results of the current study have indicated that the later stages of type II atresia, observed in the sexually immature ostrich, resembled the advanced

stages of atresia in the domestic fowl (Gupta and Maiti, 1986), the white crowned sparrow (Kern, 1972) and the house sparrow (Guraya and Chalana, 1976). The appearance of atretic follicles in the sexually immature ostrich could be significant in the control of the number of follicles destined for ovulation after puberty. Yoshimura and Nishikori (2004) observed changes in the population of apoptotic oocytes in the ovary of Japanese quail embryos during development. The report showed that the apoptotic process starts in the embryonic stage and reaches its climax at hatching, after which it declines. Furthermore, follicular atresia could be considered as a stimulus for the recruitment of new follicles in the establishment of a follicular hierarchy. This has been revealed in research conducted by Kumagai and Homma (1974) where the removal of yolky follicles from the ovary of the Japanese quail led to the recruitment of smaller follicles.

In conclusion, the results of the present study indicate that the structure of healthy follicles in sexually immature ostriches is similar to that of the pigeon (Guraya, 1976b), the Japanese quail (Guraya, 1976b), the domestic fowl (Perry *et al.*, 1978; Gilbert, 1979) and the common myna (Chalana and Guraya, 1979a). In addition, the ovarian follicles in the immature ostrich undergo a period of regression which is similar to that reported in other avian species (Forgo *et al.*, 1988; Gupta and Maiti, 1986; Gupta *et al.*, 1988; Guraya, 1976a; Kern, 1972).

2.5 References

- ALLSOPP, T.E., WYATT, S., PATERSON, H.F. & DAVIES, A.M. 1993. The proto-oncogene bcl-2 can selectively rescue neurotrophic factor-dependent neurons from apoptosis. *Cell*, 73:295-307.
- BOISE, L. H., GONZALEZ-GARCIA, M., POSTEMA, C. E., DING, L., LINDSTEN, T., TURKA, L. A., MAO, X., NUNEZ, G. & THOMSON, C.B. 1993. Bcl-x, a bcl-2 related gene that functions as a dominant regulator of apoptotic cell death. *Cell*, 74:597-608.
- CHALANA, R.K. & GURAYA, S.S. 1979a. Correlative morphological and cytochemical observations on the nucleoli and nuclear bodies during avian oogenesis. *Zeitschrift fur Mikroskopisch-Anatomische Forschung*, 93:449-457.
- CHALANA, R.K. & GURAYA, S.S. 1979b. Morphological and histochemical observations on the primordial and early growing oocytes of crow (*Corvus splendens*) and myna (*Acridotheres tristis*). *Poultry Science*, 58:225-231.
- CHO, P., BROWN, R. & ANDERSON, M. 1984. Comparative gross anatomy of ratites. *Zoo Biology*, 3:133-144.
- CHUN, S.Y., BILLIG, H., TILLY, J.L., FURUTA, I., TSAFRIRI, A. & HSUEH, A.J.W. 1994. Gonadotropin suppression of apoptosis in cultured

preovulatory follicles: mediatory role of endogenous insulin-like growth factor I. *Endocrinology*, 135:1845-1853.

DAWSON, A. & GOLDSMITH, A.R. 1989. Sexual maturation in starlings raised on long and short days: changes in hypothalamic gonadotrophin-releasing hormone and plasma LH concentration. *Journal of Endocrinology*, 123:189-196.

DOMINIC, C.J. 1961. A study of the atretic follicles in the ovary of the domestic pigeon. *Proceedings of the National Academy of Sciences of India*. 31:273 – 286.

DUERDEN, J.E. 1912. Experiments with ostriches. XX. The Anatomy and physiology of the ostrich. C. The internal organs. *South African Agriculture Journal*, April/May 1-27.

FORGO, V., SASS, M. & PECZELY, P. 1988. Light microscopic, enzyme biochemical and steroid analytical investigations of follicular atresia in the ovary of the domestic goose. *Acta Biologica Hungarica*, 39:377-401.

GARCIA, I., MARTINOU, I., TSUJIMOTO, Y. & MARTINOU, J.-C. 1992. Prevention of programmed cell death of sympathetic neurons by the bcl-2 proto-oncogene. *Science*, 258:302-304.

GILBERT, A.B. 1979. Female genital organs, in: *Form and Function in Birds*, Vol. 1, edited by A. S. King & J. McLelland. London: Academic Press. Pp. 237-360.

GILBERT, A.B., PERRY, M.M., WADDINGTON, D. & HARDIE, M.A. 1983. Role of atresia in establishing the follicular hierarchy in the ovary of the domestic hen (*Galus domesticus*). *Journal of Reproduction and Fertility*, 69:221-227.

GUPTA, S.K. & MAITI, B.R. 1986. Study of atresia in the ovary during annual reproductive cycle and nesting cycle of the pied myna. *Journal of Morphology*, 190:285-296.

GUPTA, S.K., GILBERT, A.B. & WALKER, M.A. 1988. Histological study of follicular atresia in the ovary of the domestic hen (*Gallus domesticus*). *Journal of Reproduction and Fertility*, 82:219-225.

GURAYA, S.S. 1976a. Morphological and histological observations on follicular atresia and interstitial gland tissue in columbid ovary. *General Endocrinology*, 30:534-538.

GURAYA, S.S. 1976b. Correlative cytological and histochemical studies on the avian oogenesis. *Zeitschrift fur Mikroskopisch-Anatomische Forschung Leipzig*, 90:91-150.

- GURAYA, S.S. 1989. Ovarian follicles in reptiles and birds, in: *Zoophysiology*, volume 24, edited by W. Buttgren. Berlin: Springer-Verlag. Pp. 212-221; 226-235.
- GURAYA, S.S. & CHALANA, R.K. 1976. Histochemical observations on the seasonal fluctuations of the follicular atresia and intersitial gland tissue in the house sparrow ovary. *Poultry Science*, 55:1881-1885.
- HICKS-ALLDREDGE, K. 1998. Ratite reproduction. *Veterinary Clinics in North America Food Animal Practice*, 14:437-453.
- JOHNSON, A.L., BRIDGHAM, J.T., WITTY, J.P. & TILLY, J.L. 1996. Susceptibility of avian ovarian granulosa cells to apoptosis is dependent upon stage of follicle development and is related to endogenous levels of *bcl-xlong* gene expression. *Endocrinology*, 137:2059-2066.
- JOHNSON, A.L., BRIDGHAM, J.T. & JENSEN, T. 1999. Bcl-xlong protein expression and phosphorylation in granulosa cells. *Endocrinology*, 140:4521-4529.
- JOHNSON, A.L. & BRIDGHAM, J.T. 2000. Caspase-3 and -6 expression and enzyme activity in hen granulosa cells. *Biology of Reproduction*, 62:589-598.

KERN, M.D. (1972). Seasonal changes in the reproductive system of the female white crowned sparrow (*Zonotrichia leucophrys gambelii*) in captivity and in the field. *Zeitschrift fur Zellforschung* , 126:297–319.

KORSMEYER, S. J. 1992. Bcl-2 initiates a new category of oncogenes: regulators of cell death. *Blood*, 80:879-886.

KUMAGAI, S. & HOMMA, K. 1974. High estrogen production of the medium-sized follicles during follicular growth and ovulation in laying quail. *Endocrinology*, 21:349-354.

LOTEM, J. & SACHS, L. 1989. Induction of dependence on haematopoietic proteins for viability and receptor up-regulation in differentiating myeloid leukemic cells. *Blood*, 74:579-585.

MARSHALL, A.J & COOMBS, C.J.F. 1957. The interaction of environmental, internal and behavioural factors in the rook. *Corvus f. frugilegus linnaeus*. *Proceedings of Zoological Society of London*. 128:545-589.

McNAUGHTON, F.J., DAWSON, A. & GOLDSMITH, A.R. 1992. Puberty in birds: the reproductive system of starlings does not respond to short days until birds are fully grown. *Journal of Endocrinology*, 132:411-417.

PERRY M.M., GILBERT, A.B. & EVANS, A.J. 1978. Electron microscope observations on the ovarian follicle of the domestic fowl during the rapid growth phase. *Journal of Anatomy*, 125:481-497.

REED, J. C. 1994. Bcl-2 and the regulation of programmed cell death. *Journal of Cell Biology*, 124:1-6.

SOLEY, J.T. & GROENEWALD, H.B. 1999. Anatomy of the female reproductive system, in: *The Ostrich Biology, Production and Health*, edited by D.E. Deeming. USA and UK: CABI publishing. Pp. 144-147.

TUSHINSKI, R.J., OLIVER, I.T., GUILBERT, L.J., TYNAN, P.W., WARNER, J.R. & STANLEY, E.R. 1982. Survival of mononuclear phagocytes depends on a lineage-specific growth factor that differentiated cells specifically destroy. *Cell*, 28:71-76.

UILENBROEK, J.T.J., WOUTERSEN, P.J. & VAN DER SCHOOT, P. 1980. Atresia of preovulatory follicles: gonadotropin binding and steroidogenic activity. *Biology of Reproduction*, 23:219-229.

VAN NASSAUW, L.T. & HARRISSON, F. 1999. Distribution of apoptosis-related proteins in the quail ovary during folliculogenesis: bcl-2, bax and cpp32. *Acta Histochemica*, 101:103-112.

VICKERS, S.L., COWAN, R. G., HARMAN, R. M., PORTER, D. A. & QUIRK, S. M. 2000. Expression and activity of the Fas antigen in bovine ovarian follicle cells. *Biology of Reproduction*, 62:54-61.

WILLIAMS, T.D., DAWSON, A., NICHOLLS, T.J. & GOLDSMITH, A.R. 1987. Short days induce premature reproductive maturation in juvenile starlings, *Sturnus vulgaris*. *Journal of Reproduction and Fertility*, 80:327-333.

WILLIAMS, G.T., SMITH, C.A., SPOONCER, E., DEXTER, T.M. & TYLOR, D.R. 1990. Haemopoietic colony stimulating factors promote cell survival by suppressing apoptosis. *Nature*, 343:76-79.

YOSHIMURA, Y. & NISHIKORI, M. 2004. Identification of apoptotic oocytes in the developing ovary of embryonic and post-hatched chicks in Japanese quail (*Coturnix japonica*). *Journal of Poultry Science*, 41:64-68.

2.6 List of figures

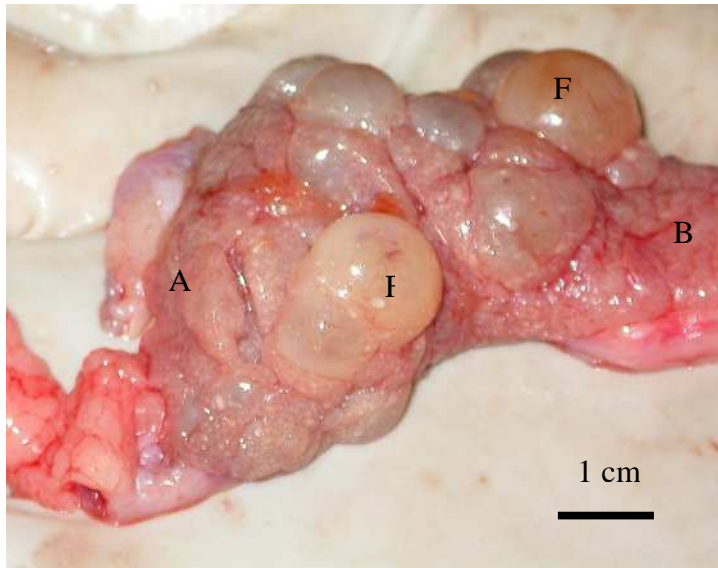


Fig. 2.1. Active ovary of an immature ostrich. The cranial extremity (A) is broad, whilst the caudal extremity (B) is narrow. Note the presence of yolk-filled follicles (F).

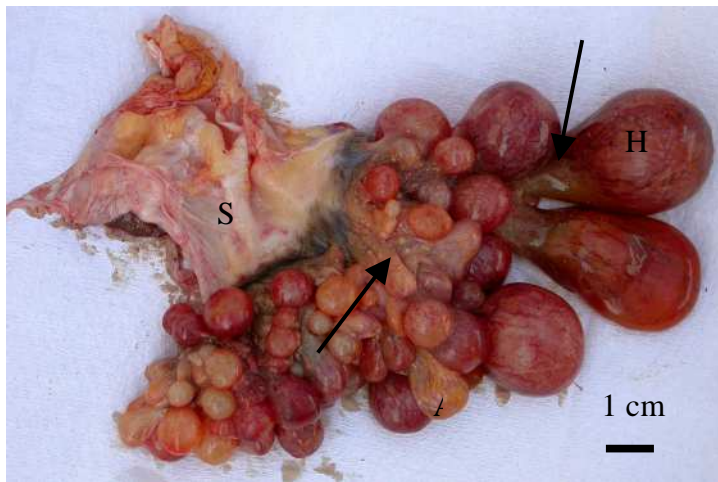


Fig. 2.2. Active ovary showing healthy (H) and atretic (A) follicles. Note that each follicle is suspended by an individual stalk (arrows). S: ovarian stalk

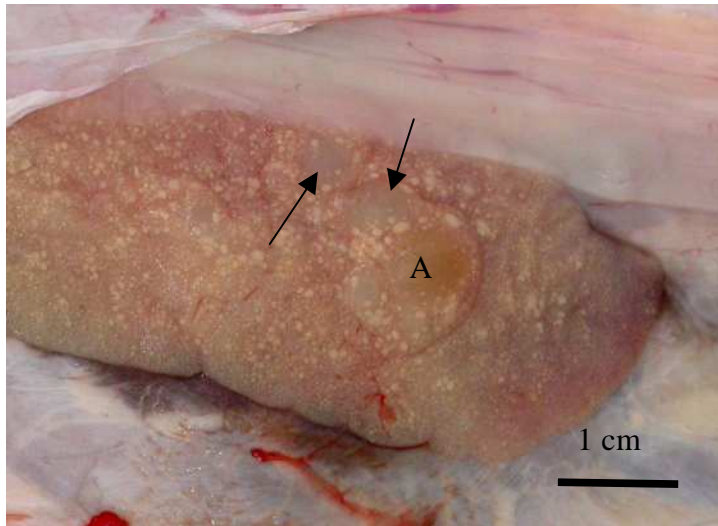


Fig. 2.3. Inactive ovary showing a granular surface due to the presence of small follicles (arrows). An atretic follicle (A) is also seen on the surface.

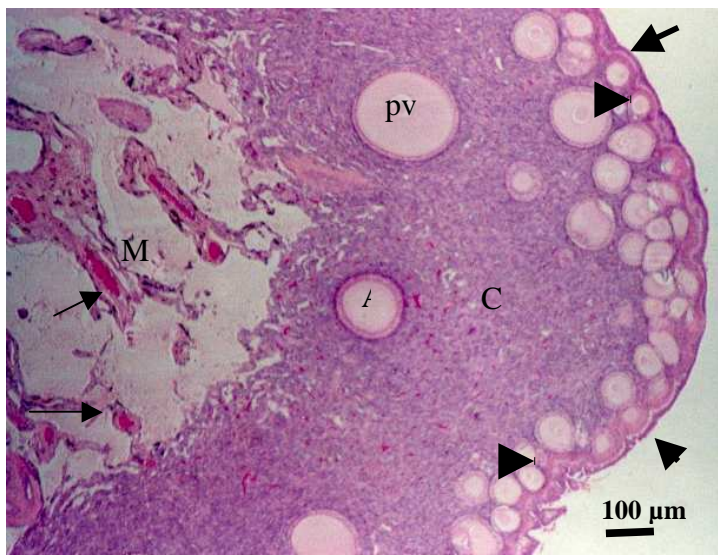


Fig. 2.4. Portion of the ovary showing the cortex (C) and medulla (M). A germinal epithelium (thick arrows) covers the ovary. Several blood vessels (thin arrows) are observed in the medulla. Pv: previtellogenic follicle. Arrow heads: primordial follicles. Note the presence of a previtellogenic follicle (A) in the early stages of atresia.

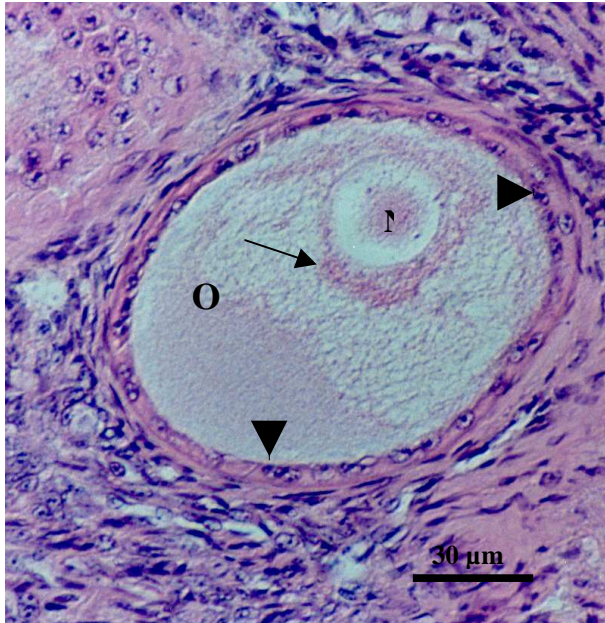


Fig. 2.5. Primordial follicle composed of an oocyte (O) and a layer of flattened granulosa cells (arrow heads). A crescent-shaped Balbiani's vitelline body (arrow) caps the nucleus (N).

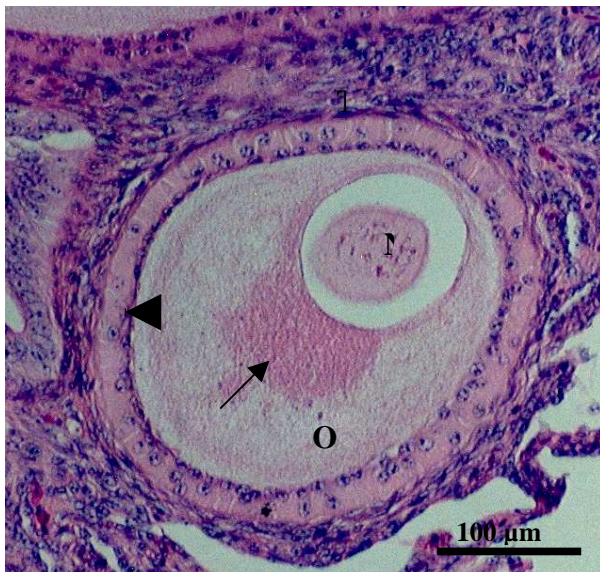


Fig. 2.6. Early previtellogenic follicle. A simple to pseudostratified columnar granulosa cell layer (arrow head) surrounds the oocyte (O). A spherical Balbiani's vitelline body (arrow) is observed adjacent to the nucleus (N). At this stage, the thecal layer (T) is not clearly differentiated into externa and interna.

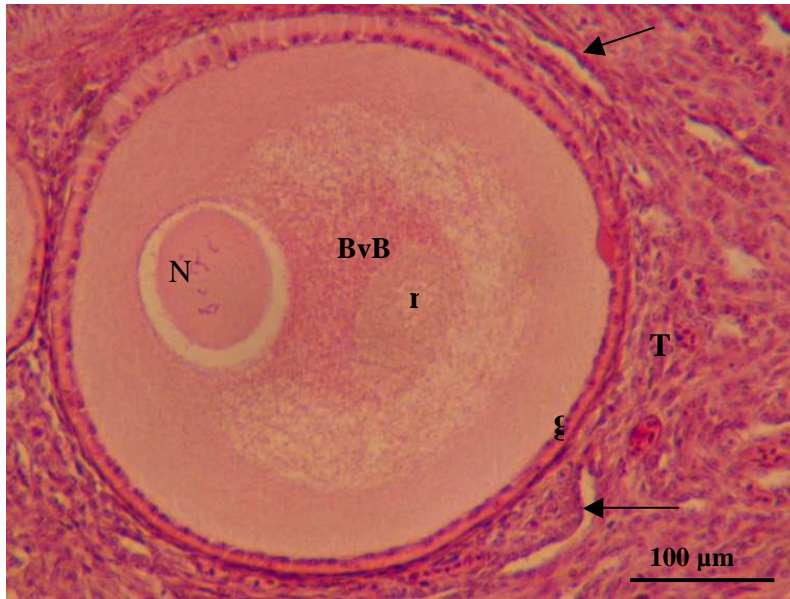


Fig. 2.7. Early previtellogenic follicle. A few blood vessels (arrows) are observed in the thecal layer (T). A yolk nucleus (n) is located in Balbiani's vitelline body (BvB). N: Nucleus of the oocyte. G: granulosa cell layer

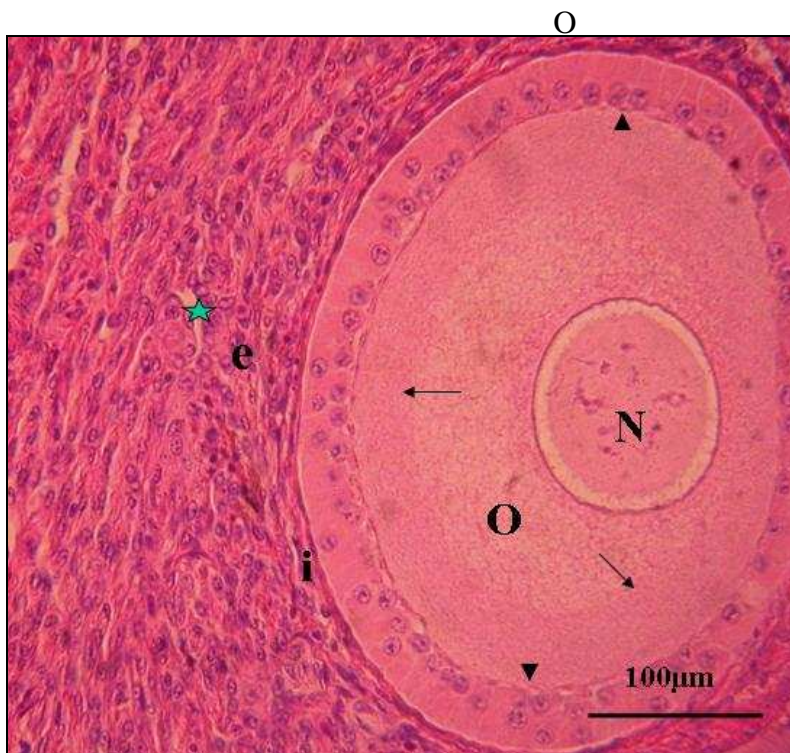


Fig. 2.8. Late previtellogenic follicle. The oocyte (O) is surrounded by a pseudostratified columnar granulosa cell layer (arrow heads). Note the fragments of Balbiani's vitelline body (arrows). The thecal layer is clearly differentiated into theca interna (i) and theca externa (e). Small capillaries (star) are observed in the theca externa. N: oocyte nucleus.

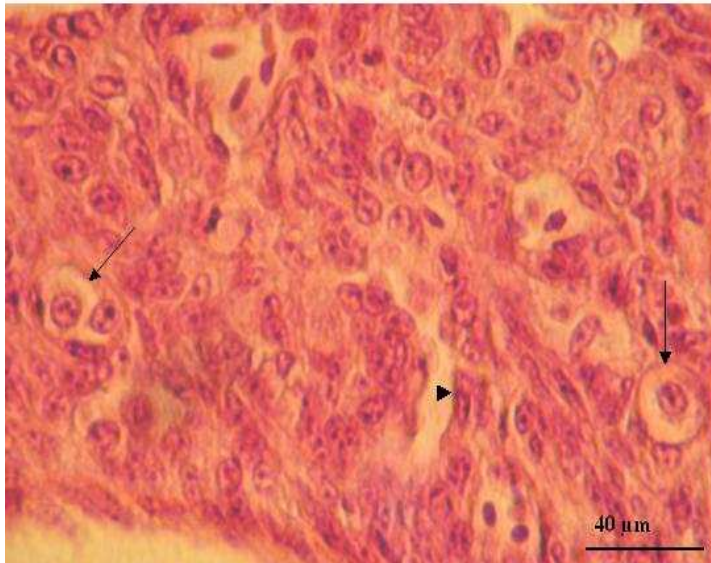


Fig. 2.9. Late previtellogenic follicle showing differentiated thecal gland cells (arrows) in the thecal layer. A blood vessel (arrow head) is also evident.

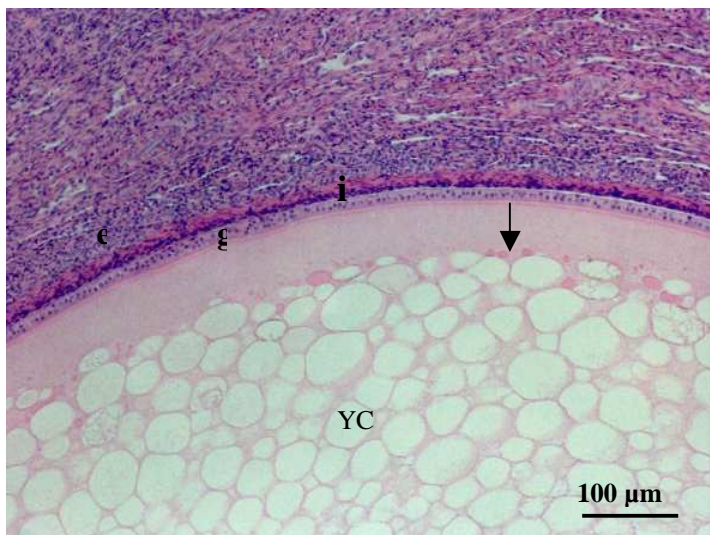


Fig. 2.10. Vitellogenic follicle. The oocyte is occupied by yolk vesicles (YC). A few yolk granules are observed in the yolk vesicles. Lipid droplets (arrows) are displaced towards the periphery of the oocyte. The theca interna (i) is clearly differentiated from the theca externa (e). g: granulosa cell layer.

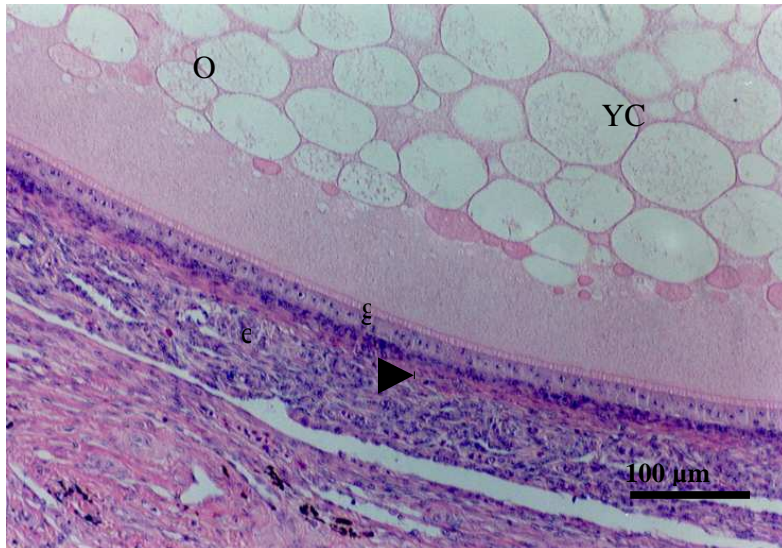


Fig. 2.11. Higher magnification of a vitellogenic follicle demonstrating yolk vesicles (YC) in the oocyte (O). The theca interna (i) is more cellular than the theca externa (e), which contains more connective tissue fibres (arrow head). g: granulosa cell layer

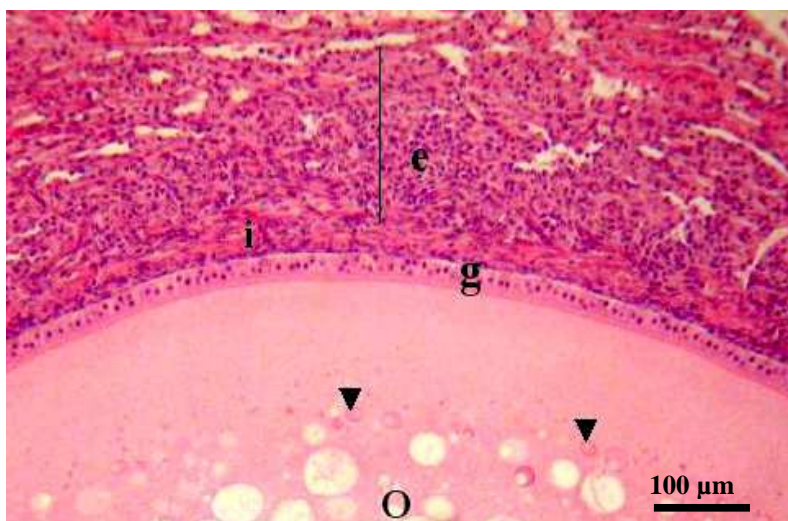


Fig. 2.12. Vitellogenic follicle demonstrating a well-differentiated theca interna (i) and theca externa (e). The theca externa (line) is thicker than the theca interna. The oocyte (O) is surrounded by a simple cuboidal granulosa cell layer (g). A few lipid droplets are observed in the peripheral regions of the oocyte (arrow heads).

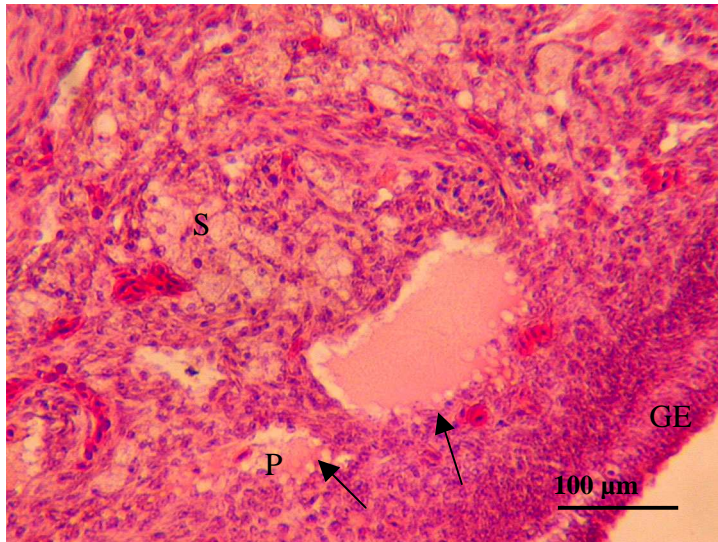


Fig. 2.13. Portion of the cortex demonstrating atretic primordial follicles (arrows). The resorption of one of the primordial follicles (P) is almost complete. S: stroma. GE = Germinal epithelium.

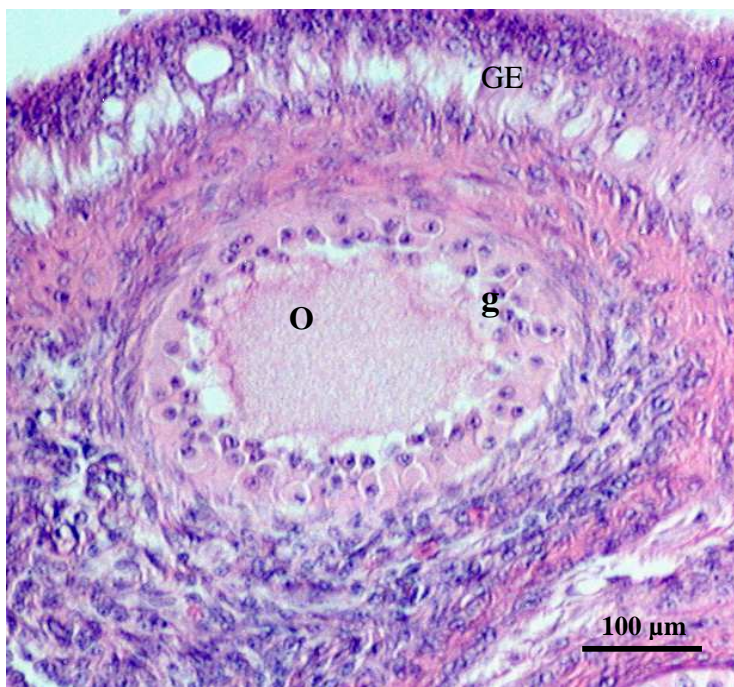


Fig. 2.14. Atretic previtellogenic follicle composed of a shrunken oocyte (O) and a multilayered granulosa cell layer (g). GE: germinal epithelium.

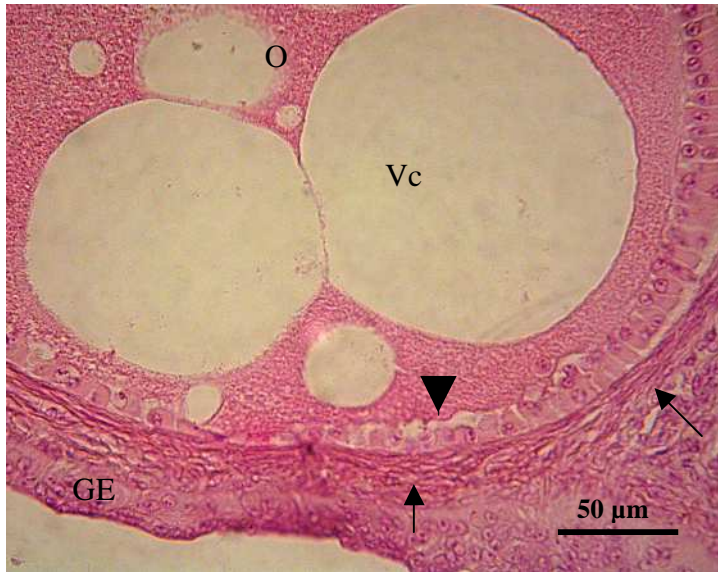


Fig. 2.15. Atretic previtellogenic follicle demonstrating vacuoles (Vc) of various sizes in the oocyte (O). Observe that the granulosa cell layer (arrow head) is not multilayered at this stage of atresia. There appears to be an increased density of connective tissue fibres in the theca externa (arrows).

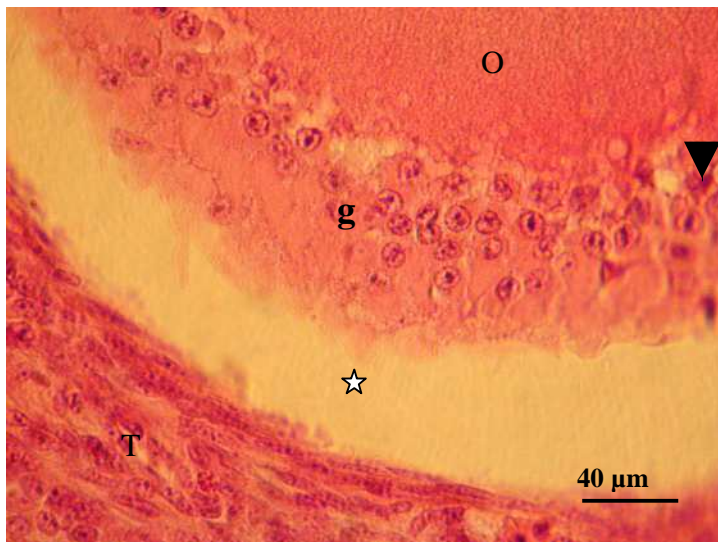


Fig. 2.16. Portion of an atretic previtellogenic follicle showing a multilayered granulosa cell layer (g), which is separated from the theca layer (T) by a clear space (star). Some granulosa cells contain pyknotic nuclei (arrow head). O: oocyte.

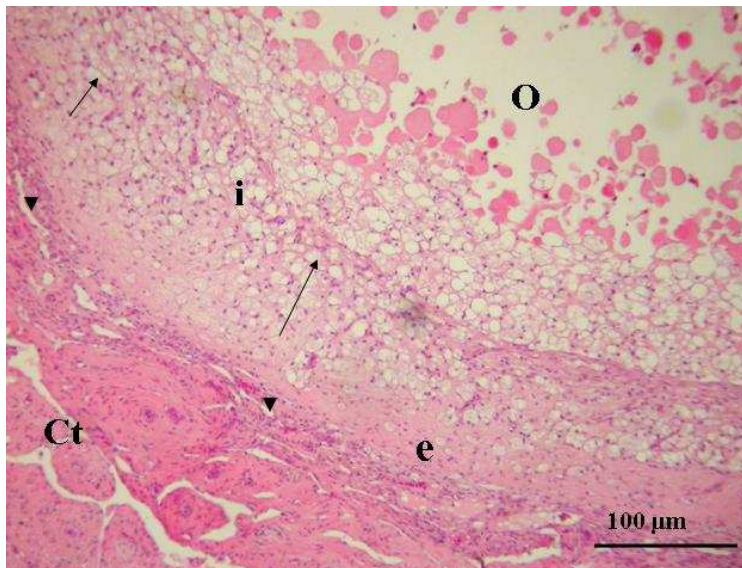


Fig. 2.17. Vitellogenic follicle (type I atresia) showing vacuolated cells (arrows) in the theca interna (i). Blood vessels (arrow heads) are observed in the hyalinized theca externa (e). Note the increased density of connective tissue fibres in the theca interna. O: oocyte. Ct: connective tissue layer

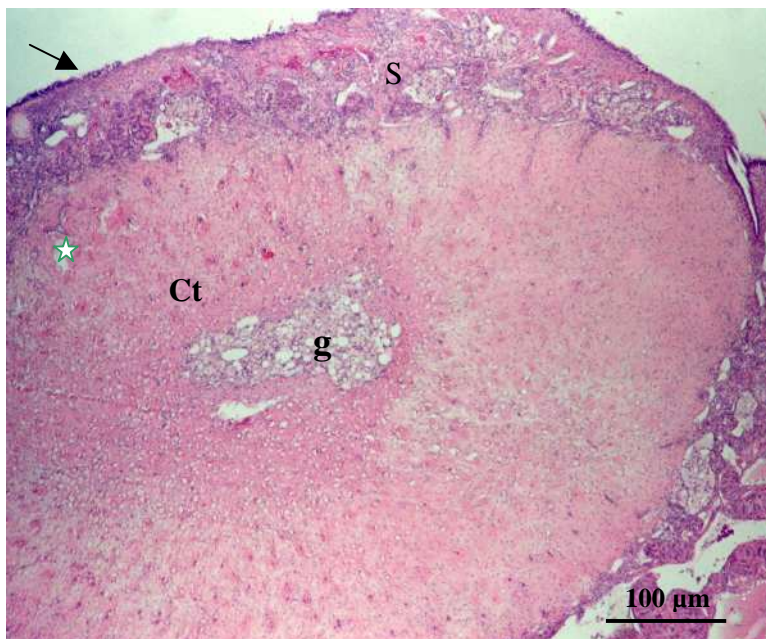


Fig. 2.18. Vitellogenic follicle (advanced stages of type I atresia). Most of the follicle is occupied by hyalinized connective tissue (Ct.), which contains blood vessels (asterisk). Note that a small area in the central region of the follicle contains vacuolated cells (g). Arrow: germinal epithelium; S: stroma.

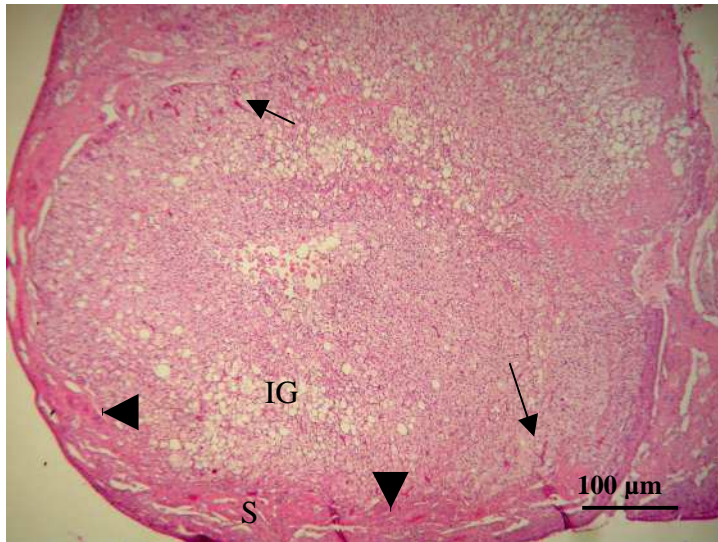


Fig. 2.19. Atretic vitellogenic follicle (type II). Vacuolated granulosa and theca interna cells have differentiated into interstitial gland cells (IG). Note the presence of numerous blood capillaries (arrows) originating from the stroma (S), which have invaded the glandular mass. Arrow heads: connective tissue fibres surrounding the glandular mass.

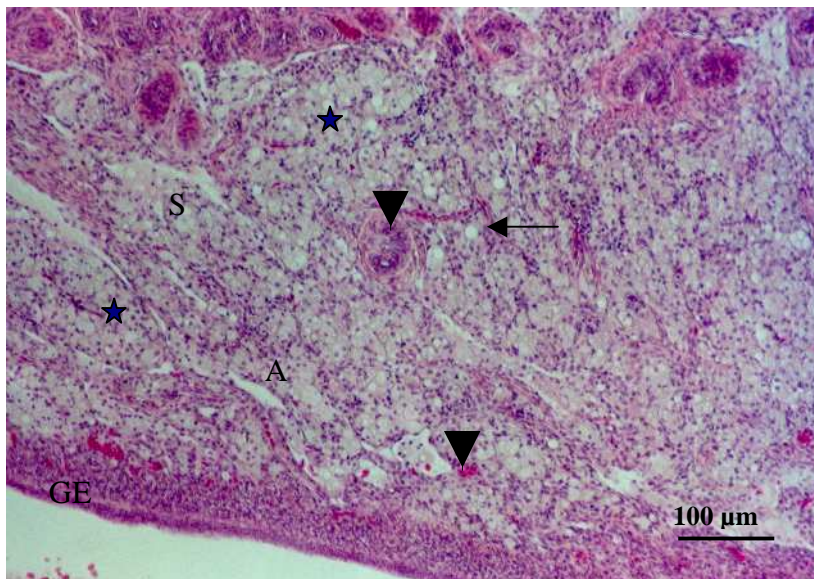


Fig. 2.20. Portion of the stroma (S) occupied by stromal interstitial gland cells (asterisks). Note the numerous blood vessels (arrow heads) between the clusters of gland cells. GE: Germinal epithelium. Arrow: connective tissue trabeculae.

CHAPTER THREE

Ultrastructural features of healthy and atretic ovarian follicles in the sexually immature ostrich

3.1 Introduction

The ultrastructure of the wall of avian ovarian follicles has been extensively studied in the domestic fowl (Perry *et al.*, 1978a, 1978b; Rothwell and Solomon, 1977; Bellairs, 1965; Wyburn *et al.*, 1965) and the domestic goose (Kovacs *et al.*, 1992). In these birds, seven regions or layers cover the oocyte of the mature follicle. From within outwards the layers are: the *Zona radiata*; *lamina perivitellina*; *stratum granulosum*; *lamina basalis folliculi*; *theca folliculi* (*theca folliculi interna* and *theca folliculi externa*); connective tissue layer and superficial epithelium (Rothwell and Solomon, 1977).

It is well accepted that, the growth and degeneration of ovarian follicles is associated with structural and biochemical changes of the cells forming the follicular wall. This has been reported in the domestic fowl (Wyburn *et al.*, 1965; Hernandez-Vertiz *et al.*, 1993; Yoshimura and Bahr, 1995), the domestic goose (Forgo *et al.*, 1988; Kovacs *et al.*, 1992) and the Japanese quail (Yoshimura and Nishikori, 2004). Guraya (1989) reported that the shape, number and cytochemical properties of cells forming the follicular wall change with the initiation of oocyte growth. Another structural change associated with the growth of follicles is the accumulation of electron dense fibres in the perivitelline layer (Wyburn *et al.*, 1965). Research carried out on the domestic

goose (Kovacs *et al.*, 1992) and the domestic fowl (Schjeide *et al.* 1974; Gilbert *et al.*, 1980) has shown that the disappearance of ribosome-coated vesicles, known as transosomes, is one of the structural changes, which occurs in the follicle as it undergoes regression. A further morphological change associated with regression is the appearance of granular cells in the thecal layer of atretic follicles (Dahl, 1970).

The ostrich, which is the largest ratite, is currently an extremely valuable farm animal in several parts of the world (Deeming and Angel, 1996). However, no information appears to be available on the ultrastructure of ovarian follicles in this species. Therefore, in this chapter the morphology of healthy and atretic ovarian follicles was investigated using the transmission electron microscope. In addition, cellular changes occurring during follicular growth and atresia were highlighted.

3.2 *Materials and methods*

A total of 26 sexually immature female ostriches aged between 12 and 14 months were used in the present study. The birds were stunned and exsanguinated by decapitation at a commercial ostrich abattoir in the Republic of South Africa. Ovarian tissue samples were collected as soon as possible following the death of the birds. The tissue samples were fixed by immersion in 2.5% glutaraldehyde in 0.1M cacodylate buffer. Thereafter, the tissue blocks were post-fixed with osmium tetroxide (OsO_4) for 1-2 hours and then rinsed with cacodylate buffer for 10 minutes, and distilled water for a further 10 minutes. Thereafter, the tissue samples were dehydrated using a graded

series of alcohol (50% - 100% ethanol). After been infiltrated for 1 hour with a propylene: epoxy resin mixture at a ratio of 2:1, followed by a 1:1 propylene: epoxy resin mixture for 1 hour, samples were embedded in a 100% epoxy resin overnight. Thereafter, the tissue blocks were sectioned, stained with lead citrate and uranyl acetate and viewed with a transmission electron microscope (Philips CM10).

3.3 Results

3.3.1 Healthy follicles

3.3.1a. Primordial follicles

Primordial follicles were composed of an oocyte, which was surrounded by a single layer of granulosa cells. The oocyte in these follicles contained several small lipid droplets inter-mixed with mitochondria, rough endoplasmic reticulum (RER), smooth (SER) endoplasmic reticulum, as well as a Golgi complex (fig. 3.1). Balbiani's vitelline body, which was observed close to the nucleus of the oocyte, was composed of a dense accumulation of organelles, which included mitochondria, lipid droplets, RER, SER, as well as a Golgi complex (fig. 3.2 & 3.3). The mitochondria in Balbiani's vitelline body tended to be peripherally-located. In primordial follicles the plasma membrane of the oocyte and the apical membrane of the granulosa cells formed interdigitated undulations. In addition, desmosomes were occasionally formed between the granulosa cells and the oocyte.

The granulosa cell layer consisted of flat to cuboidal cells with apically-located nuclei (fig. 3.1). The nucleus of a typical granulosa cell was oval in shape and contained a prominent nucleolus (fig. 3.4). The cell contained several mitochondria, lysosomes, SER, RER, as well as a Golgi complex. The mitochondria were elongated or round depending on the plane of sectioning and were concentrated adjacent to the lateral aspects of the nucleus (fig. 3.4). SER and RER were evenly distributed throughout the cell with the latter being more predominant. Tight junctions, as well as interdigitations of the lateral plasma membranes linked the granulosa cells (fig. 3.4). The apical regions of the granulosa cells displayed regular undulations, which interdigitated with the plasma membrane of the oocyte. In this follicular size, transosomes were occasionally seen as cytoplasmic evaginations on the apical aspect of the granulosa cells (fig. 3.4). The transosomes were oval in shape with inner granular and outer smooth membranes.

Beneath the granulosa cell layer was a basal lamina. At a low magnification, the basal lamina appeared to be a homogeneous, granular layer. However, at a higher magnification, it became evident that the region of the basal lamina closest to the granulosa cell layer was more electron dense than that adjacent to the thecal layer (fig. 3.5).

An undifferentiated thecal layer composed of approximately 2 to 3 layers of fibroblasts, was present (fig. 3.1). A few connective tissue fibres (collagen fibres) were seen between the fibroblasts.

3.3.1b. Previtellogenic follicles

The oocyte of previtellogenic follicles contained a large number of lipid droplets and yolk granules (fig. 3.6). Cytoplasmic organelles, which included mitochondria, cisternae of RER and a Golgi complex were present in the oocyte. In late previtellogenic follicles, Balbiani's vitelline body was indistinct. The perivitelline layer consisted of an electron dense amorphous material, which was deposited between the granulosa cell layer and the oocyte. The *zona radiata* was formed by interdigitating cytoplasmic extensions from the granulosa cell layer and the oocyte (fig. 3.7). The cytoplasmic processes were held together by tight junctions and desmosomes (fig. 3.8).

In early previtellogenic follicles, the granulosa cell layer was formed by a simple columnar or pseudostratified columnar epithelium (fig. 3.9). In late previtellogenic follicles, the granulosa cell layer was pseudostratified columnar (fig. 3.10). Light (type I) and dark (type II) granulosa cells were observed, with the former being more predominant (fig. 3.11). Type I granulosa cells contained apically-located round nuclei, which generally contained one or two prominent nucleoli (fig. 3.9). In addition, clumps of heterochromatin were observed in the nucleus. Mitochondria, SER, RER and a Golgi complex were distributed throughout the cell. In addition, the cytoplasm in the central regions of the cells contained several microfilaments (fig. 3.12).

Dark (type II) granulosa cells contained an ovoid nucleus which was located either centrally or apically (fig. 3.11). The cytoplasm contained numerous electron dense bodies (fig. 3.13). Mitochondria were more concentrated in the

apical regions of these granulosa cells (fig. 3.13). A few lipid droplets were observed in type II granulosa cells. Although RER, SER and a Golgi complex were observed in the cytoplasm, microfilaments were not clearly identifiable in these cells.

Despite the fact that light and dark granulosa cells showed clear differences in their cytoplasmic contents, both cell types possessed longer cytoplasmic extensions than the granulosa cells of primordial follicles (fig. 3.14). Transosomes were observed at the apical regions of the cytoplasmic processes (fig. 3.15) as well as, along the lateral plasma membranes (fig. 3.16). Depending on the plane of sectioning transosomes appeared to be either round or oval in shape (fig. 3.17). The transosomes were composed of an inner granular membrane and an outer smooth membrane. Electron dense ribosome-like granules were attached to the inner membrane (fig. 3.17). An electronlucent area separated the inner and outer membranes. The inner membrane of the transosomes was curved towards the cytoplasm of the granulosa cell.

Gap junctions, as well as desmosomes were identified between adjacent granulosa cells (fig. 3.16). In some instances tight junctions were also observed.

The thecal layer was demarcated from the granulosa cell layer by a relatively homogeneous granular basal lamina (fig. 3.18). The theca interna and externa were clearly differentiated in late previtellogenic follicles. Fibroblasts, which

were arranged in strata, as well as undifferentiated thecal gland cells, were the main features of the theca interna (fig. 3.19). The fibroblasts were spindle-shaped with elongated nuclei. The cytoplasm of these cells contained several electron dense bodies which were either round or irregular in shape (fig. 3.20). In addition, the cells contained a few mitochondria, RER profiles as well as, a Golgi complex (fig. 3.20 & 3.21). Although connective tissue fibres occupied most of the intercellular space, desmosomes and tight junctions between adjacent fibroblasts were occasionally present (fig. 3.22a&b).

Undifferentiated thecal gland cells were either round or oval in shape. The gland cells were usually distributed singly in the outer regions of the theca interna. Pairs of thecal gland cells were typically united by tight junctions (fig. 3.23). The oval-shaped nucleus of the undifferentiated thecal gland cell contained one or two nucleoli and was surrounded by a small amount of cytoplasm (fig. 3.24). Several cytoplasmic organelles, which included mitochondria, Golgi complexes and SER, were observed. In addition, these cells displayed bundles of microfilaments (fig. 3.23).

The theca externa consisted of fibroblasts, a few capillaries, as well as, undifferentiated and differentiated thecal gland cells. The fibroblasts and undifferentiated thecal gland cells in the theca externa appeared to be morphologically identical to those observed in the theca interna. The differentiated thecal gland cells were generally distributed singly (fig. 3.24). However, in some cases groups of differentiated thecal gland cells were observed. The differentiated theca gland cells contained a large amount of

cytoplasm, which enclosed a round, centrally-located nucleus. Lipid droplets, electron dense bodies and ill-defined cisternae of RER and SER were observed in the cytoplasm (fig. 3.24). In the theca externa, as in the theca interna collagen fibres were observed between the fibroblasts and thecal gland cells.

3.3.1c Vitellogenic follicles

Yolk granules were evident in the oocytes of vitellogenic follicles. In contrast to the previtellogenic follicles, the oocytes in vitellogenic follicles contained numerous yolk vesicles, which occupied most of the ooplasm. In addition, groups of peripherally located mitochondria, profiles of SER and a Golgi complex were observed.

As in previtellogenic follicles, the *zona radiata* was formed by cytoplasmic extensions from the oocyte and the granulosa cells. However, in this follicular size, cytoplasmic extensions from the granulosa cells appeared shorter than in the previtellogenic follicles and restricted to the lateral or peripheral aspects of the cells (fig. 3.25). In addition, the cytoplasmic processes displayed very few transosomes. Unlike in previtellogenic follicles, transosomes in vitellogenic follicles were uncommon along the lateral plasma membranes of the granulosa cells. Interestingly, the formation of the perivitelline layer was still in the initial stages observed in previtellogenic follicles.

The granulosa cell layer was composed of a simple cuboidal or columnar epithelium (fig. 3.26). The cells possessed either centrally or apically-located

nuclei (fig. 3.26 & 3.27). Mitochondria were concentrated basally in cells with apically located nuclei (fig. 3.27). In contrast, cells with centrally-located nuclei contained groups of apically-located mitochondria (fig. 3.26). In cells with apically located nuclei lipid droplets and vacuoles were observed below the nucleus (fig. 3.27). In addition, SER, as well as RER were present with the latter being more predominant. The granulosa cells were linked by desmosomes.

A basal lamina separated the granulosa cell layer from the theca interna. The ultrastructure of the basal lamina appeared to be similar to that of previtellogenic follicles. The theca interna was composed of fibroblasts and both undifferentiated and differentiated thecal gland cells (fig. 3.28). In some cases cells with vacuolated cytoplasm were observed in the theca interna as well as in the theca externa (fig. 3.28). In general the fibroblasts of vitellogenic follicles resembled those of previtellogenic follicles. Collagen fibres were evident between the fibroblasts.

The theca externa was composed of both undifferentiated and differentiated thecal gland cells, as well as fibroblasts (fig. 3.29). Connective tissue fibres were identified between the cells forming the theca externa. Blood vessels were also a common feature. In addition, occasional unmyelinated nerve fibres were observed in close association to either thecal gland cells or fibroblasts (fig. 3.30a&b).

3.3.2 Atretic follicles

3.3.2a Primordial follicles

Major ultrastructural changes were observed in the cytoplasmic organelles of both the oocyte and the surrounding follicular wall. In the oocyte, mitochondria were concentrated around the nucleus and close to the granulosa cells (fig. 3.31). In addition, Balbiani's vitelline body did not appear to be present. In these follicles vacuoles, lipid droplets and electron dense bodies were observed in the oocytes.

A single layer of granulosa cells surrounded the oocyte. The cytoplasm of the granulosa cells varied in electron density. Electron dense bodies, lipid droplets, SER and RER were observed in the cytoplasm. The ultrastructure of the basal lamina and thecal layer appeared similar to that observed in healthy follicles.

3.3.2b Previtellogenic follicles

The oocyte in atretic previtellogenic follicles contained clusters of mitochondria intermixed with lipid droplets and electron dense bodies (fig. 3.32). The mitochondria were swollen and contained tubular cristae. In addition, dilated profiles of SER were observed throughout the ooplasm. In some follicles, an amorphous layer was observed between the oocyte and granulosa cell layer (fig. 3.33).

The multilayered granulosa cells displayed apical cytoplasmic processes, which appeared to be shorter and fewer than in the healthy previtellogenic follicles. Likewise, fewer transosomes were observed in the atretic

previtellogenic follicles. Although RER and SER were intact, a Golgi complex could not be identified. In addition, in the more advanced stages of atresia lipid droplets and swollen mitochondria were distributed throughout the cell (fig. 3.34).

The thecal layer in atretic previtellogenic follicles appeared to contain a greater mass of connective tissue fibres than in the healthy previtellogenic follicles (fig. 3.35). The fibroblasts and undifferentiated thecal gland cells contained several lipid droplets and swollen mitochondria.

3.3.2c Vitellogenic follicles

In the early stages of atresia in vitellogenic follicles, the granulosa cells contained several electron dense bodies. Other cytoplasmic organelles displayed normal features. However, major atretic changes were seen in the thecal layer where granulosa and theca interna cells differentiated into interstitial gland cells (fig. 3.36). In the initial stages of differentiation, numerous lipid droplets filled the cytoplasm of the interstitial gland cells. Scant cytoplasm was observed between the lipid droplets. At this stage the gland cells contained a round, centrally-located nucleus.

In the advanced stages of atresia, the gland cells contained irregular shaped nuclei, which were peripherally-located (fig. 3.36). These interstitial gland cells appeared to be undergoing degeneration. In addition, cellular debris and macrophages were observed in the areas between the degenerating gland cells. At this stage interstitial gland cells occupied a large part of the oocyte.

Dense accumulations of collagen fibres were present between the fibroblasts in the theca externa. However, lipid droplets as well as swollen mitochondria were the notable feature in some fibroblasts (fig. 3.37).

3.4 Discussion

This appears to be the first documentation of the ultrastructural morphology of healthy and atretic ovarian follicles in the sexually immature ostrich. The nomenclature of the ovarian follicular layers adopted in this study is in accordance with the description used by Gilbert (1979) in the domestic fowl. In general, the results of the present study correlated well with earlier research findings made in the domestic fowl (Wyburn *et al.*, 1966; Dahl, 1971; Rothwell and Solomon, 1977; Perry *et al.*, 1978a), the domestic duck (Deray, 1979), the Japanese quail (Kudryavstev *et al.*, 1982), the domestic goose (Kovacs *et al.*, 1992) and the pigeon (Guraya, 1976).

As in other avian species, the oocyte in the sexually immature ostrich was surrounded by a *zona radiata*, *perivitelline* layer, granulosa cell layer, basal lamina, as well as thecal layers. The *zona radiata*, which was formed by interdigitations of cytoplasmic processes from the oocyte and the granulosa cells, was observed in previtellogenic and vitellogenic follicles. Similar observations were made in the domestic fowl where the *zona radiata* was present in follicles larger than 5mm in diameter (Rothwell and Solomon, 1977). In contrast to the domestic fowl (Perry *et al.*, 1978a) and the domestic goose (Kovacs *et al.*, 1992), the perivitelline layer in the sexually immature

ostrich was still in the initial stages of development. This might suggest that the differentiation of the perivitelline layer is restricted to large follicles in the sexually mature ostrich.

The results of this Chapter complement the observations made in the light microscopic study (Chapter Two) on the components of Balbiani's vitelline body. At the electron microscope level, Balbiani's vitelline body was composed of aggregations of mitochondria, SER, RER and Golgi complexes. This distribution pattern is in agreement with the research findings of Guraya (1976b) on the ovary of the pigeon, the brown dove, the ring dove, the domestic fowl and the Japanese quail.

In the current study it was shown that as the follicle grows the structure of granulosa cells, as well as the thickness of the granulosa cell layer changes. This is in agreement with an observation made by Gilbert (1980) where the shape and number of granulosa cells in the domestic fowl varied as the follicle developed. In the sexually immature ostrich, granulosa cells accumulated lipid droplets during the vitellogenic phase. Studies in the domestic fowl and the rat (Dahl, 1971; Wyburn *et al.*, 1966) have also demonstrated the presence of lipid droplets in the granulosa cells. The reports pointed out that the presence of lipid droplets in the granulosa cells might be due to the accumulation of neutral fats from fatty degeneration. However, histochemical tests carried out in the domestic fowl have shown that lipid droplets in the granulosa cells consisted of phospholipids and triglycerides (Guraya, 1989). Phospholipids and triglycerides are cholesterol esters, which are known to be utilized in the

synthesis of steroid hormones. Therefore, it may be possible that granulosa cells of vitellogenic and atretic follicles in the sexually immature ostrich play an important role in steroid synthesis.

In the current investigation a study of the apical and lateral granulosa cell membranes revealed the presence of transosomes, which are membranous structures found only in avian ovarian follicles. The different names, which have been used to describe these structures include: unique organelles (Schjeide *et al.*, 1966; 1974; 1975); lining bodies (Bellairs, 1965; 1967); macrobodies (Greenfield, 1966); terminal membranes (Wyburn *et al.*, 1965) and vesicular bodies (Bellairs, 1967). However, according to Guraya (1989) the basic structure of the organelles described by these researchers appears to be similar. Guraya (1976) and Schjeide *et al.* (1966) suggested that the importance of transosomes lay in the growth of ovarian follicles. It is thought that transosomes play an important role in the initial formation of yolk material.

According to Schjeide *et al.* (1974) transosomes contain ribosomes (rRNA) which participate in the growth of the oocyte. In addition, Paulson and Rosenberg (1974) reported the ability of transosomes to form yolk vesicles after detaching from the granulosa cell membrane. Therefore, it may be assumed that the presence of transosomes in the ovarian follicles of the sexually immature ostrich is important for the growth of the follicle and the initial formation of yolk material as has been suggested by earlier researchers. However, further studies need to be carried out to ascertain the physiological function of these organelles in the immature ostrich.

As stated in the results, the number of transosomes appeared to decrease as the follicle matured and regressed. A similar occurrence has been reported in the domestic goose (Kovacs *et al.*, 1992) and the domestic fowl (Paulson and Rosenberg, 1974). According to Kovacs *et al.* (1992), the number of transosomes was reduced in follicles larger than 8mm in diameter, as well as in atretic follicles. The report suggested that apoptosis of granulosa cells is heralded by the disappearance of transosomes. Other ultrastructural changes that characterized regression in the previtellogenic follicles on the sexually immature ostrich included the accumulation of electron dense bodies and lipid droplets in the granulosa cells, as well as the presence of swollen mitochondria.

The present study supports and complements the results of the light microscopic study in Chapter Two, which showed that interstitial gland cells are formed from degenerating granulosa and theca interna cells. This observation is in agreement with the report by Guraya and Chalana (1976) and Chalana and Guraya (1979) who observed the formation of interstitial gland cells in the ovary of the house sparrow (*Passer domesticus*), the crow (*Corvus splendens*) and the myna (*Acridotherens splendens*). However, Erpino (1973) reported that interstitial glands in the scrub jay (*Aphelocoma coerulescens*) are formed from thecal gland cells of atretic follicles, as well as from stromal fibroblasts.

In the ovary of the house sparrow, the crow and the myna interstitial gland cells were distributed either in groups or singly in the ovarian stroma (Guraya

and Chalana, 1976). In the sexually immature ostrich interstitial gland cells occurred in well-vascularized clusters, which were separated by connective tissue fibres. Research conducted by Chalana and Guraya (1976) has shown that the avian ovary contains more interstitial gland cells prior to breeding season. The report concluded that the accumulation of interstitial glands is correlated to the steroidogenic function of these glands during the breeding season. The functional importance of interstitial gland cells in the ovary of the sexually immature ostrich is not known for certain. However, the presence of lipid droplets in these cells suggests that interstitial gland cells may play an important role in steroid hormone synthesis as reported in other avian species.

In addition to interstitial gland cells, thecal gland cells were a common feature in the ovary of the sexually immature ostrich. Dahl (1970) described thecal gland cells as being composed of groups of steroid producing cells surrounded by a layer of enclosing cells. Interestingly, thecal gland cells in the sexually immature ostrich were enclosed by a basal lamina, and not by enclosing cells as described in the domestic fowl (Dahl, 1970). Differentiated and undifferentiated thecal gland cells were observed in the sexually immature ostrich. In addition, a few vacuolated thecal cells were occasionally observed in the thecal layer of vitellogenic follicles. These vacuolated cells were termed "theca lutein cells" in the domestic fowl (Rothwell and Solomon, 1977). However, there is no evidence that these vacuolated cells have a steroidogenic function.

Hernandez-Vertiz *et al.* (1993) described the structure of steroidogenic cells in the theca layer of follicles in the domestic fowl. The report showed that a typical steroidogenic cell is characterized by the presence of numerous lipid droplets in the cytoplasm. A similar observation was also made in the current study in which the thecal gland cells contained numerous lipid droplets. This observation supports the possibility that thecal gland cells in the sexually immature ostrich could be involved in the production of steroid hormones. Although a study by Huang and Nalbandov (1979) and Marone and Hertelendy (1985) has shown that oestrogen and androgen are synthesized by cells of the theca layer, further immunohistochemical studies need to be carried out to provide more evidence on the steroidocompetence of these cells in the ovary of the sexually immature ostrich.

In conclusion, the results of this study indicate that the structure of the follicular wall in the sexually immature ostrich is similar to that of other avian species.

3.5 References

BELLAIRS, R. 1965. The relationship between oocyte and follicle in hen's ovary, as shown by electron microscopy. *Journal of Embryology and Experimental Morphology*, 13:215-233.

- BELLAIRS, R. 1967. Aspects of the development of yolk spheres in the hen's oocyte, studied by electron microscopy. *Journal of Embryology and Experimental Morphology*, 17:267-281.
- CHALANA, R.K. & GURAYA, S.S. 1979. Morphological and histochemical observations on the primordial and early growing oocytes of crow (*Corvus splendens*) and myna (*Acridotheres tristis*). *Poultry Science*, 58:225-231.
- DAHL, E. 1970. Studies on the fine structure of ovarian interstitial tissue. 2. The ultrastructure of the thecal gland of the domestic fowl. *Zeitschrift fur Mikroskopisch-Anatomische Forschung*, 109:195-211.
- DAHL, E. 1971. The fine structure of the granulosa cells in the domestic fowl and rat. *Zeitschrift fur Zellforschung*, 119:58-67.
- DEEMING, D.C. & ANGEL, C.R. 1996. Introduction to the ratites and farming operations around the world, in: *Improving our understanding of ratites in a farming environment. Proceedings of International Ratite Conference*. March 1996, University of Manchester.
- DERAY, A. 1979. Cells of the granulosa of small ovarian follicles of ducks: Peking duck (*Anas platyrhynchos*). *Journal of Ultrastructural Research*, 68:118-135.

- ERPINO, M.J. 1973. Histogenesis of atretic follicles in a seasonally breeding birds. *Journal of Morphology*, 139:239-250.
- FORGO, V., AFANASIEV, G.D. & PECZELY, P. 1988. Structural and hormonal changes during follicular maturation in the ovary of the domestic goose. *Acta Biologica Hungarica*, 39:403-417.
- GILBERT, A.B. 1979. Female genital organs, in: *Form and Function in Birds*, Vol.1, edited by A. S. King & J. McLelland. London: Academic Press. pp. 237-360
- GILBERT, A.B., HARDIE, M.A., PERRY, M.M., DICK, H.R. & WELLS, J.W. 1980. Cellular changes in the granulosa layer of the maturing ovarian follicle of the domestic fowl. *British Poultry Science*, 21:256-263.
- GREENFIELD, M. 1966. The oocyte of the domestic chicken shortly after hatching, studied by electron microscopy. *Journal of Embryology and Experimental Morphology*, 15:297-316.
- GURAYA, S.S. 1976. Morphological and histological observations on follicular atresia and interstitial gland tissue in columbid ovary. *General Endocrinology*, 30:534-538.

- GURAYA, S.S. (1989). Ovarian follicles in reptiles and birds, in: *Zoophysiology, Vol. 24*, edited by W. Burggren. Berlin: Springer-Verlag. Pp. 226-235.
- GURAYA, S.S. & CHALANA, R.K. 1976. Histochemical observations on the seasonal fluctuations of the follicular atresia and interstitial gland tissue in the house sparrow ovary. *Poultry Science*, 55:1881-1885.
- HERNANDEZ-VERTIZ, A., GONZALEZ DEL PLIEGO, M., VELAZQUEZ, P. & PEDERNERA, E. 1993. Morphological changes in the thecal layer during the maturation of the preovulatory ovarian follicle of the domestic fowl (*Gallus domesticus*). *General and Comparative Endocrinology*, 92:80-87.
- HUANG, E.S. & NALBANDOV, A.V. 1979. Steroidogenesis of chicken granulosa and theca cells: in vitro incubation system. *Biology of Reproduction*, 20:442-453.
- KOVACS, J., FORGO, V. & PECZELY, P. 1992. The fine structure of the follicular cells in growing and atretic ovarian follicles of the domestic goose. *Cell Tissue Research*, 267:561-569.
- KUDRYAVSTEV, I.V., SHEINA, N.I. & VASIN, V.I. 1982. A comparative electron microscopic study of chicken and quail oocytes. *Zhurnal Obshchei Biologii*, 43:394-398.

- MARSHALL, A.J. & COOMBS, C.J.F. 1957. The interaction between environmental, internal and behavioral factors in the Rook, *Corvus f. frugilegus* Linnaeus. *Proceedings of Zoological Society of London*, 128:545-587.
- MARONE, B.L. & HERTELENDY, F. 1985. Decreased androstenedione production with increased follicular maturation in the theca cells from the domestic hen (*Gallus domesticus*). *Journal of Reproduction and Fertility*, 74:543-550.
- PAULSON, J.L. & ROSENBERG, M.D. 1974. Formation of lining bodies and oocyte bodies during avian oogenesis. *Developmental Biology*, 40:366-371.
- PERRY M.M., GILBERT, A.B. & EVANS, A.J. 1978a. Electron microscope observations on the ovarian follicle of the domestic fowl during the rapid growth phase. *Journal of Anatomy*, 125:481-497.
- PERRY M.M., GILBERT, A.B. & EVANS, A.J. 1978b. The structure of the germinal disc region of the hen's ovarian follicle during the rapid growth phase. *Journal of Anatomy*, 127:379-392.
- ROTHWELL, B. & SOLOMON, S.E. 1977. The ultrastructure of the follicle wall of the domestic fowl during the phase of rapid growth. *British Poultry Science*, 18:605-610.

SCHJEIDE, O.A., MUNN, R.J., MCCANDLESS, R.G. & EDWARDS, R. 1966.

Unique organelles of avian oocytes. *Growth*, 30:471-489.

SCHJEIDE, O.A., HANZLEY, L., HOLSHOUSER, S.J. & BRILES, W.E. 1974.

Production and fates of unique organelles (transosomes) in ovarian follicles of *Gallus domesticus* under various conditions. *Cell Tissue Research*, 156:47-59.

SCHJEIDE, O.A., KANCHEVA, L., HANZLEY, L. & BRILES, W.E. 1975.

Production and fates of unique organelles (transosomes) in ovarian follicles of *Gallus domesticus* under various conditions, II. *Cell Tissue Research*, 163:63-79.

WYBURN, G.M., AITKEN, R.N.C. & JOHNSTON, H.S. 1965. The

ultrastructure of the zona radiata of the ovarian follicle of the domestic fowl. *Journal of Anatomy*, 99:469-484.

WYBURN, G.M., JOHNSTON, H.S. & AITKEN, R.N.C. 1966. Fate of the

granulosa cells in the hen's follicle. *Zeitschrift fur Zellforschung*, 72:53-65.

YOSHIMURA, Y. & BAHR, J.M. 1995. Atretic changes of follicular wall caused

by destruction of the germinal disc region of an immature preovulatory follicle in the chicken: an electron microscope study. *Journal of Reproduction and Fertility*, 105:147-151.

YOSHIMURA, Y. & NISHIKORI, M. 2004. Identification of apoptotic oocytes in the developing ovary of embryonic and post-hatched chicks in Japanese quail (*Coturnix japonica*). *Journal of Poultry Science*, 41:64-68.

3.6 List of figures

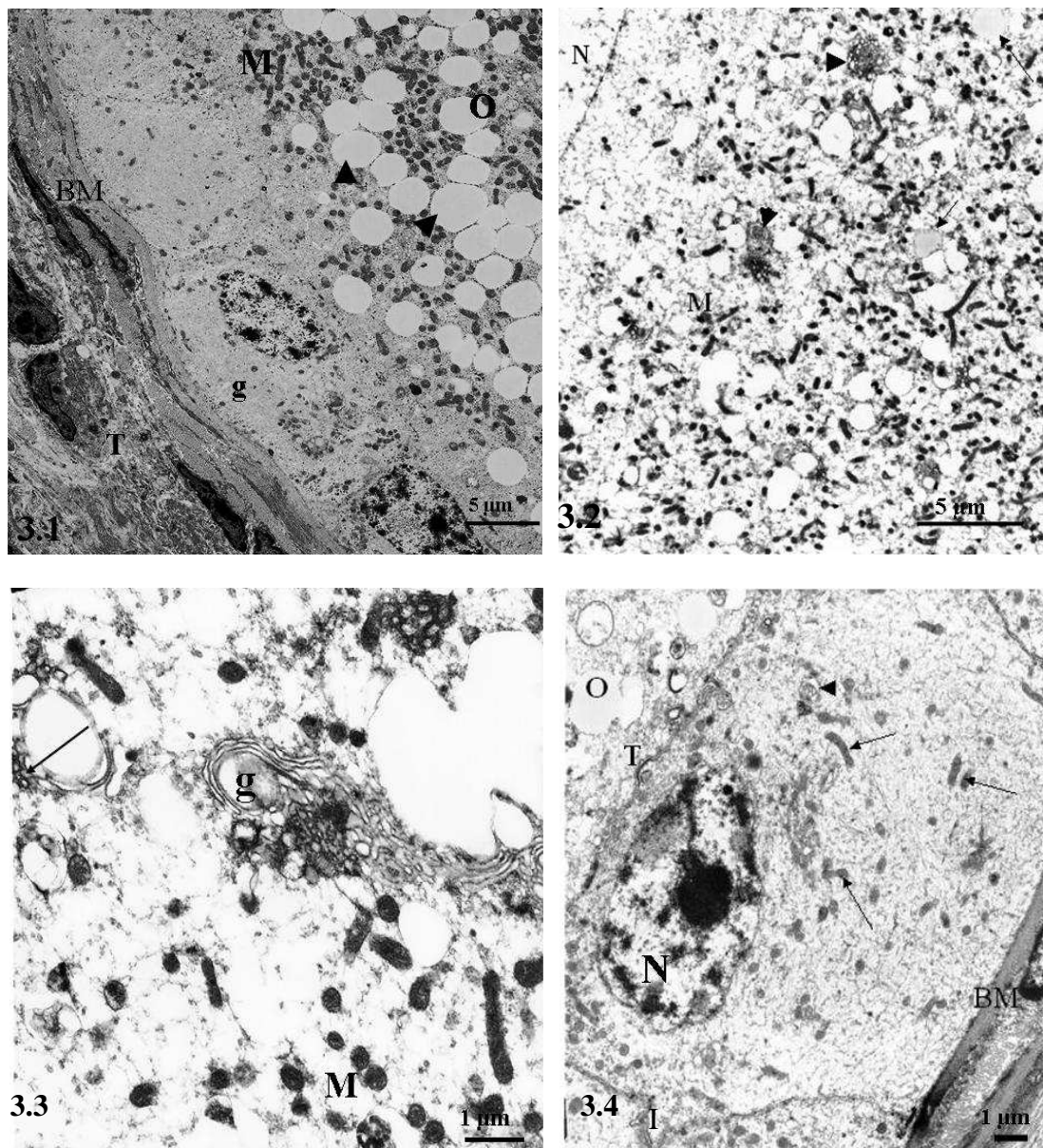


Fig. 3.1. Healthy primordial follicle. Flat granulosa cells (g) surround the oocyte (O). Groups of mitochondria (M) are observed intermixed with lipid droplets (arrow heads) in the oocyte. BM: basal lamina. T: thecal layer.

Fig. 3.2. Healthy primordial follicle. An electron micrograph of Balbiani's vitelline body, which is formed by a high concentration of mitochondria (M) and RER (arrow heads). A few lipid droplets (arrows) are also present. N: nucleus.

Fig. 3.3. A high magnification electron micrograph of Balbiani's vitelline body shows a Golgi complex (g), RER (arrow) and mitochondria (M).

Fig. 3.4. Healthy primordial follicle. Cuboidal granulosa cell rests on the basal lamina (BM). Several mitochondria (arrows) and a few cisternae of RER (arrow head) are present. The oval-shaped nucleus (N) contains a prominent nucleolus. Note the early formation of transosomes (T) on the apical aspect of the granulosa cell adjacent to the oocyte (o). I: Folding of the lateral plasma membranes.

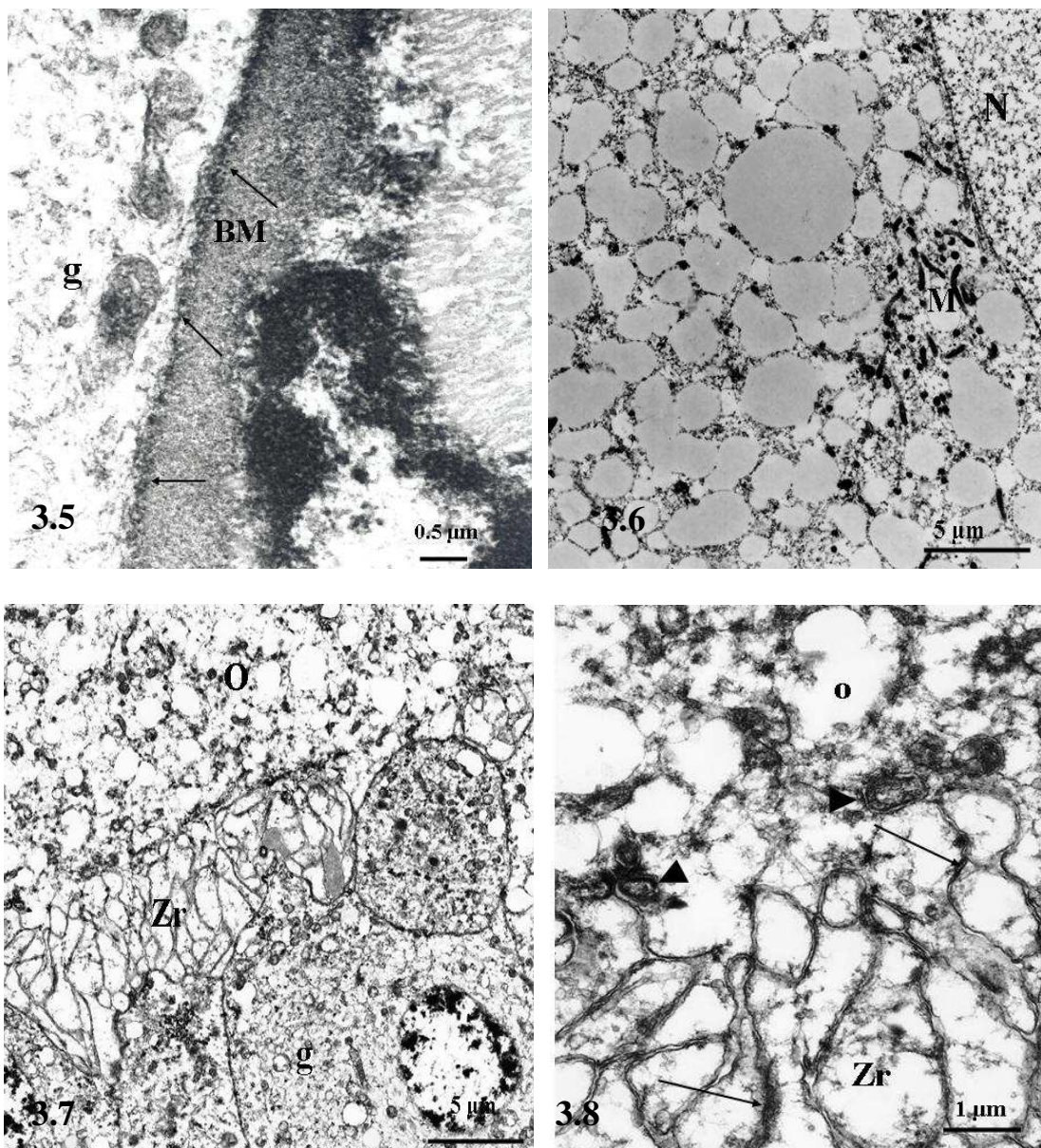


Fig. 3.5. Granular basal lamina (BM). Note the presence of electron dense granules (arrows) adjacent to the granulosa cell (g).

Fig. 3.6. Healthy previtellogenic follicle. Small to large lipid droplets are present in the oocyte. Groups of mitochondria (M) are observed close to the nucleus (N).

Fig. 3.7. Late healthy previtellogenic follicle. Part of the oocyte (O) and the apical portions of granulosa cells (g) are shown. The *zona radiata* (Zr) is formed by interdigitating processes from the granulosa cell layer and the oocyte.

Fig. 3.8. Higher magnification of the *zona radiata* (Zr) showing the presence of tight junctions (arrows). Note the presence of transosomes (arrow heads) at the tips of the cytoplasmic processes. O: oocyte

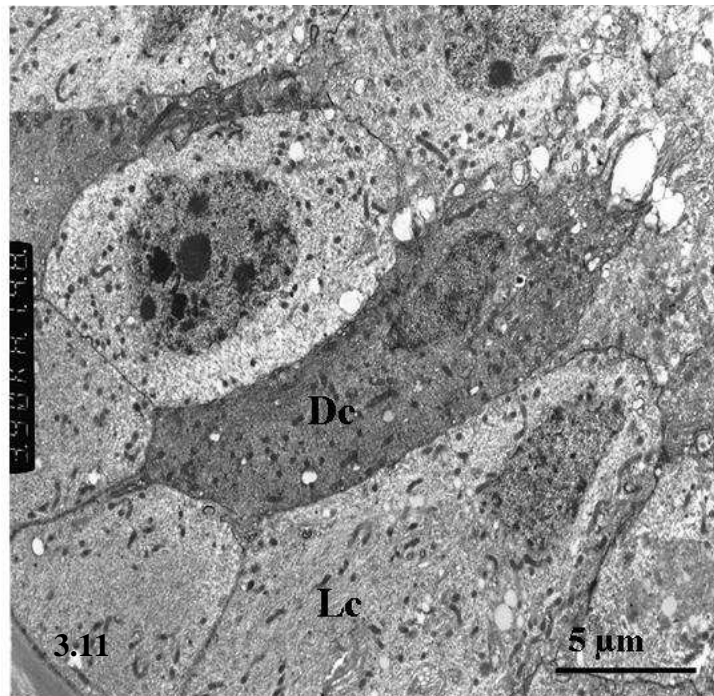
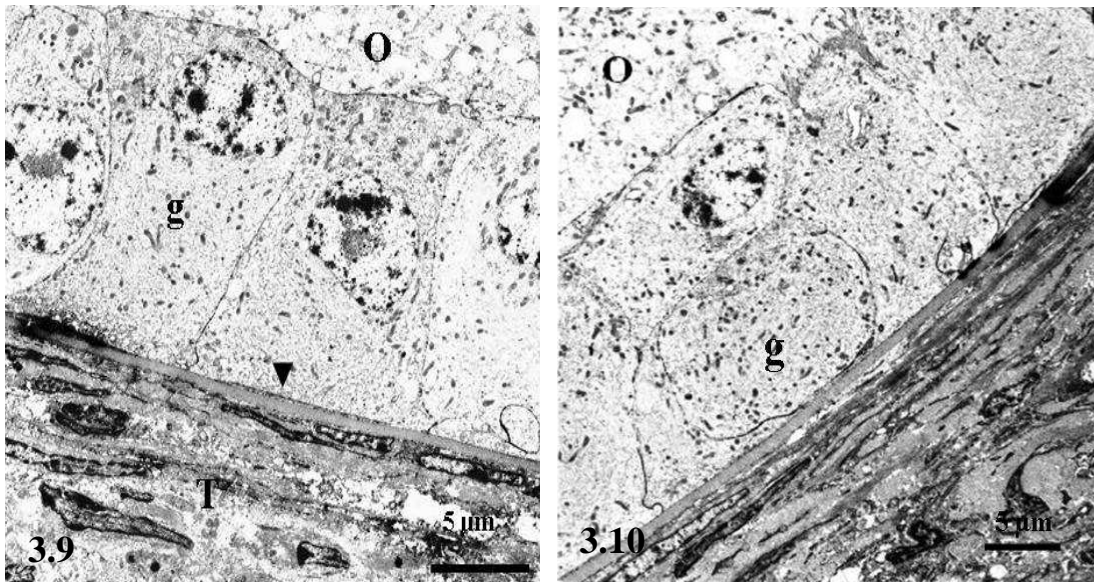


Fig. 3.9. Early healthy previtellogenic follicle. Columnar granulosa cells (g) surround the oocyte (O). Note the presence of an undifferentiated thecal layer (T) beneath the basal lamina (arrow head).

Fig. 3.10. Late healthy previtellogenic follicle. A pseudostratified columnar granulosa cell layer (g) encloses the oocyte (O).

Fig. 3.11. Late healthy previtellogenic follicle. The granulosa cell layer exhibits light (Lc) and dark (Dc) cells.

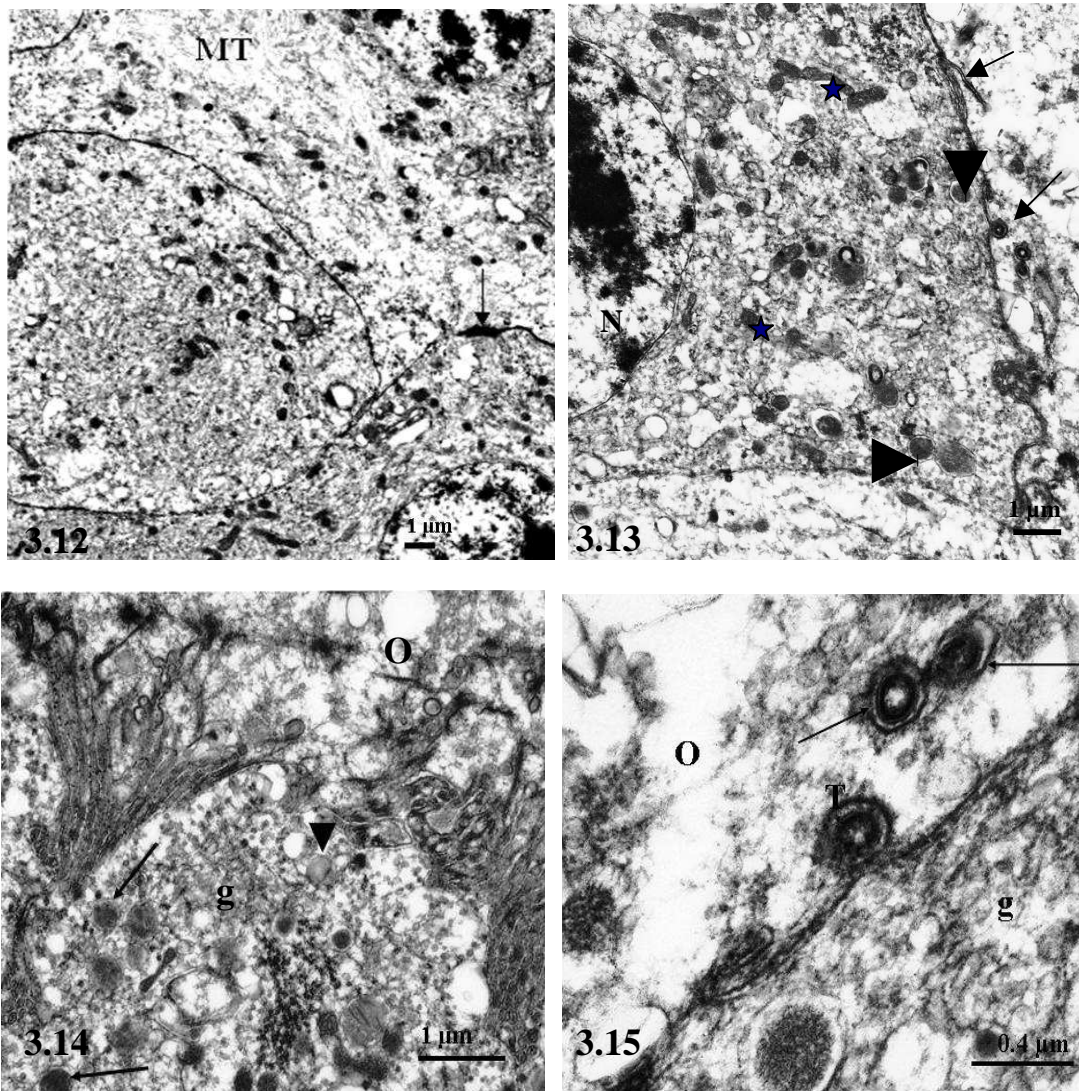


Fig. 3.12. Cytoplasm of a type I (light) granulosa cell showing microfilaments (MT) in the central regions of the cell. Tight junctions (arrow) united these cells.

Fig. 3.13. Apical portion of a type II (dark) granulosa cell showing electron dense bodies (arrow heads). Mitochondria (asterisks) are more concentrated in this apical area. The plasma membrane adjacent to the oocyte (o) displays several transosomes (arrows). N: nucleus

Fig. 3.14. Healthy previtellogenic follicle. Granulosa cell (g) exhibiting long cytoplasmic processes. Lysosomes (arrows) and a few lipid droplets (arrow head) are observed in the cytoplasm of the granulosa cell. O: oocyte

Fig. 3.15. Transosomes (T) in the apical region of a granulosa cell (g). Some transosomes (arrows) have detached from the granulosa cell and are within the oocyte (O).

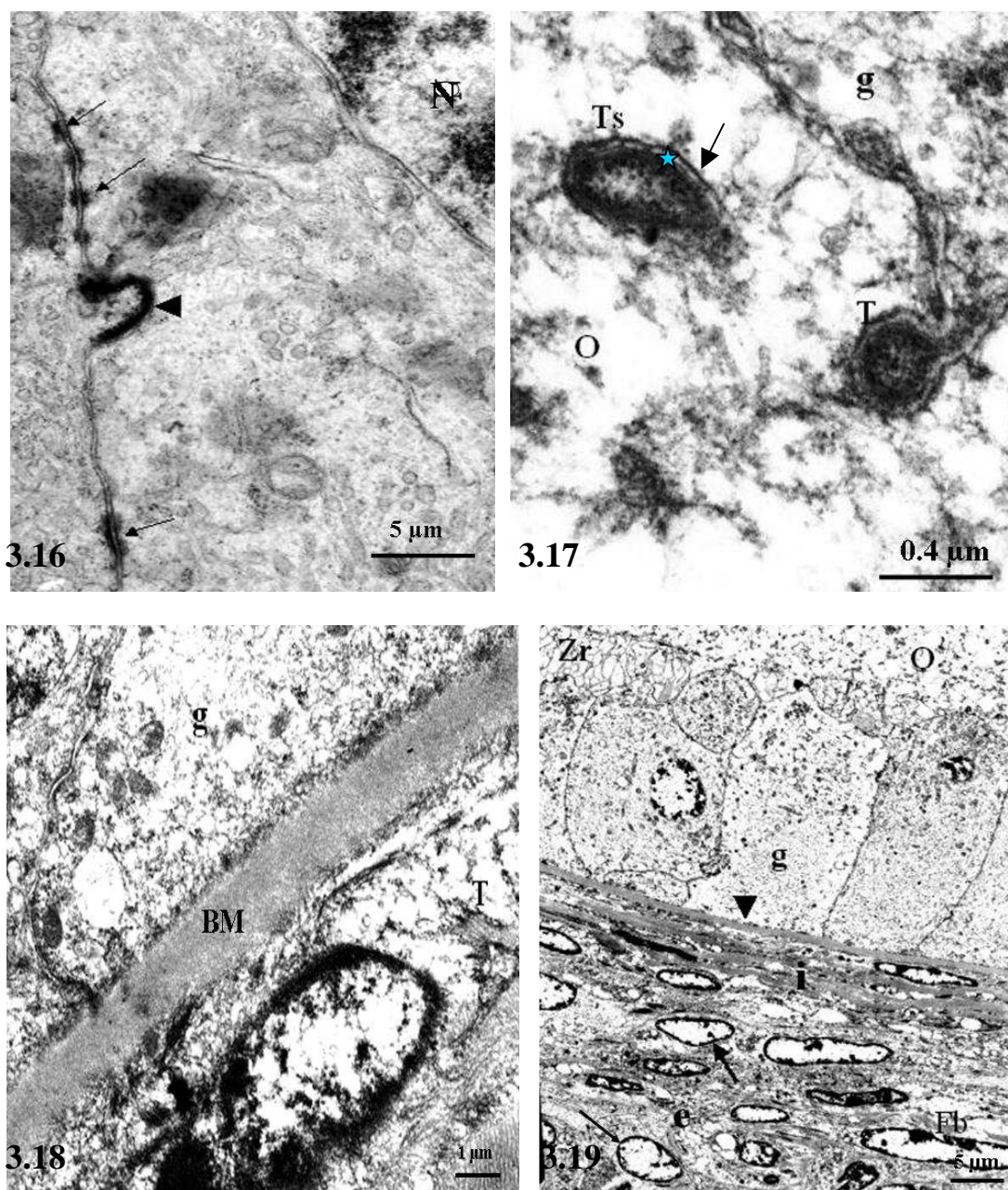


Fig. 3.16. Desmosomes (arrows) are observed between two granulosa cells. N: nucleus. Arrow head: transosome on the lateral plasma membrane.

Fig. 3.17. Round (T) and oval (Ts) shaped transosomes in a granulosa cell (g) and an oocyte (o). Note the presence of an outer smooth membrane (arrow) and an inner granular membrane separated by an electron-lucent area (star)

Fig. 3.18. Healthy previtellogenic follicle. A basal lamina (BM) separates the granulosa cell layer (g) from the theca layer (T).

Fig. 3.19. A survey electron micrograph of a late healthy previtellogenic follicle. Fibroblasts (Fb) and undifferentiated thecal gland cells (Arrow) are the main components of the theca interna (i) and theca externa (e). Granulosa cells (g) rest on the basal lamina (arrow head) and bear cytoplasmic processes, which contribute to the formation of *zona radiata* (Zr). O: oocyte.

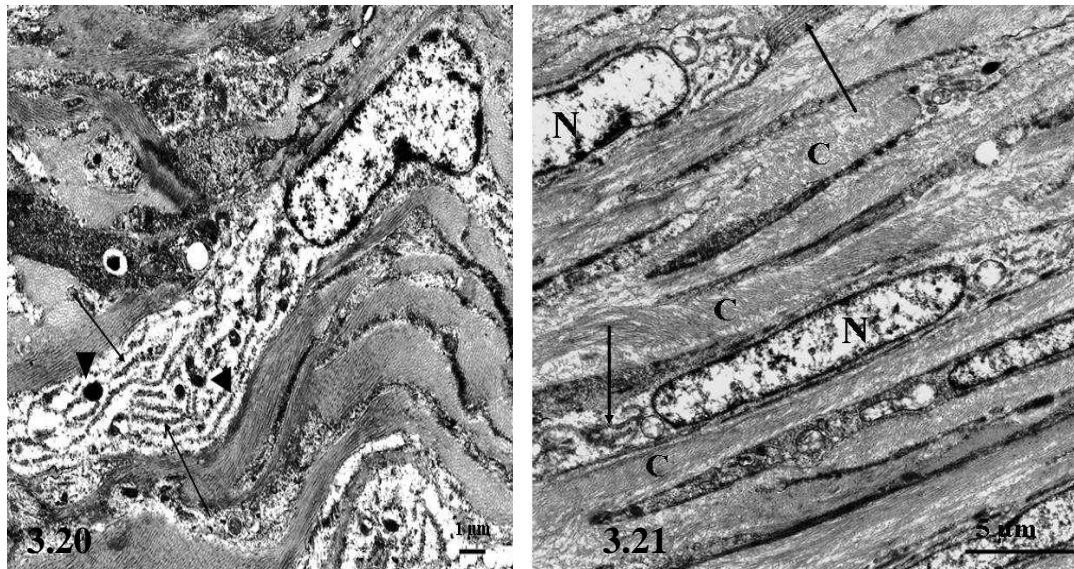


Fig. 3.20. Higher magnification electron micrograph of fibroblasts showing a parallel array of RER cisternae (arrows) and electron dense bodies (arrow heads) within the cytoplasm.

Fig. 3.21. Electron micrograph of a portion of the thecal layer showing spindle shaped fibroblasts with elongated nuclei (N). Parallel cisternae of RER are observed adjacent to the nucleus (arrows). Collagen fibres (C) occupy the intercellular spaces.

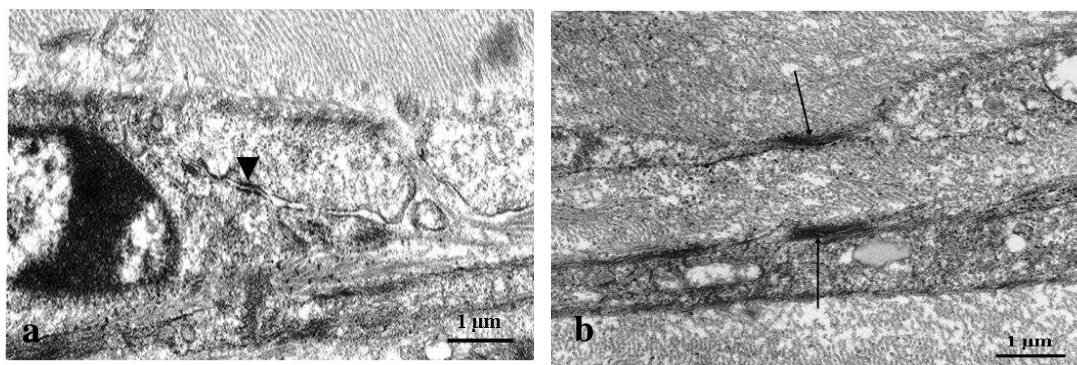


Fig. 3.22. Cellular junctions between fibroblasts in the thecal layer. Desmosomes (arrow head) and tight junctions (arrows) are clearly seen in figures a & b respectively.

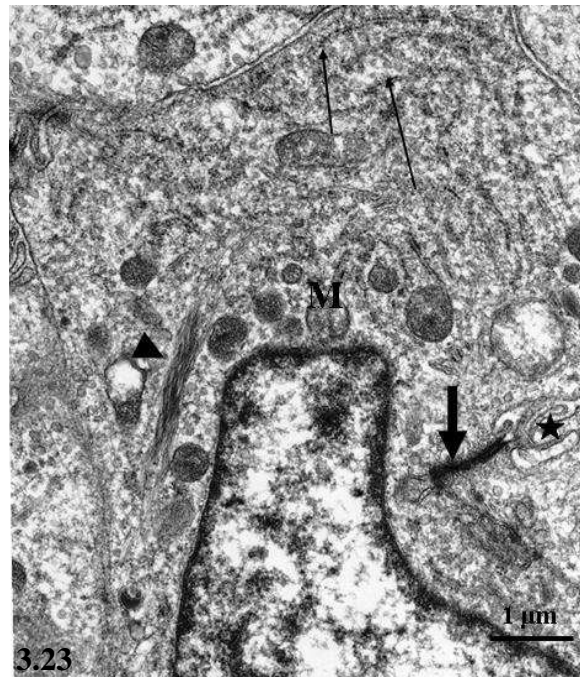


Fig. 3.23. Undifferentiated thecal gland cell. A bundle of microfilaments (arrow head), mitochondria (M) and arrays of RER (arrows) are observed in the cytoplasm. Tight junctions (thick arrow), as well as folding of the lateral plasma membranes (asterisk) unite the adjacent cells.

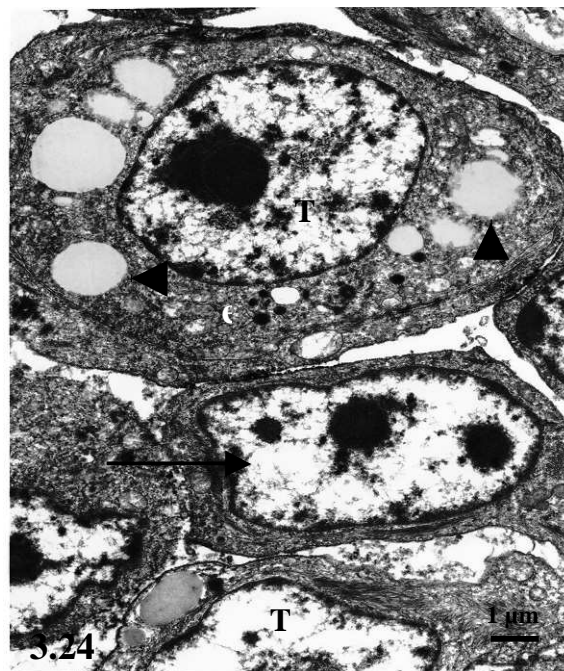


Fig. 3.24. Portion of the theca externa showing differentiated (T) and undifferentiated (arrow) thecal gland cells. Note the presence of lipid droplets (arrow heads) and electron dense bodies (e) in the cytoplasm of the differentiated thecal gland cell (T). The cell demonstrates a round nucleus, which is centrally located. The ovoid nucleus of the undifferentiated thecal gland cell possesses two nucleoli.

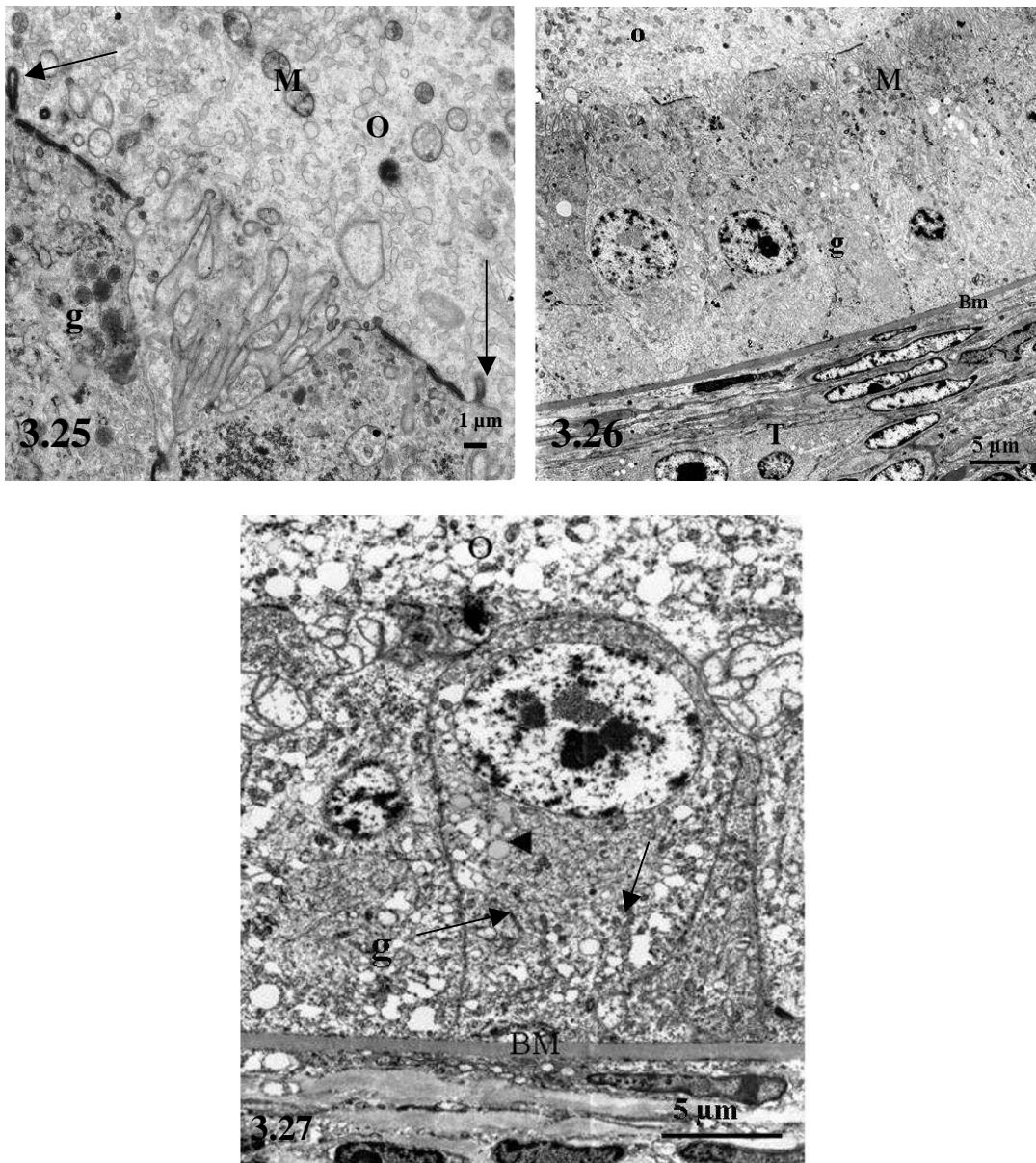


Fig. 3.25. Healthy vitellogenic follicle. A high magnification electron micrograph showing part of the oocyte (o) and the apical region of a granulosa cell (g). Only the peripheral regions of the granulosa cells are involved in the formation of the zona radiata (Zr). Note the presence of a few transosomes (arrows).

Fig. 3.26. A survey electron photomicrograph of an healthy vitellogenic follicle showing the oocyte (o) and follicular wall. The granulosa cell layer (g) is composed of a simple columnar epithelium, which is separated from the thecal layer (T) by a basal lamina (Bm). Mitochondria (M) are concentrated in the apical regions of the cells.

Fig. 3.27. Healthy vitellogenic follicle. The granulosa cells (g) contain apically-located nuclei. Note the accumulation of lipid droplets (arrow head) and mitochondria (arrows) below the nucleus. The basal lamina (BM) appears to be homogeneous.

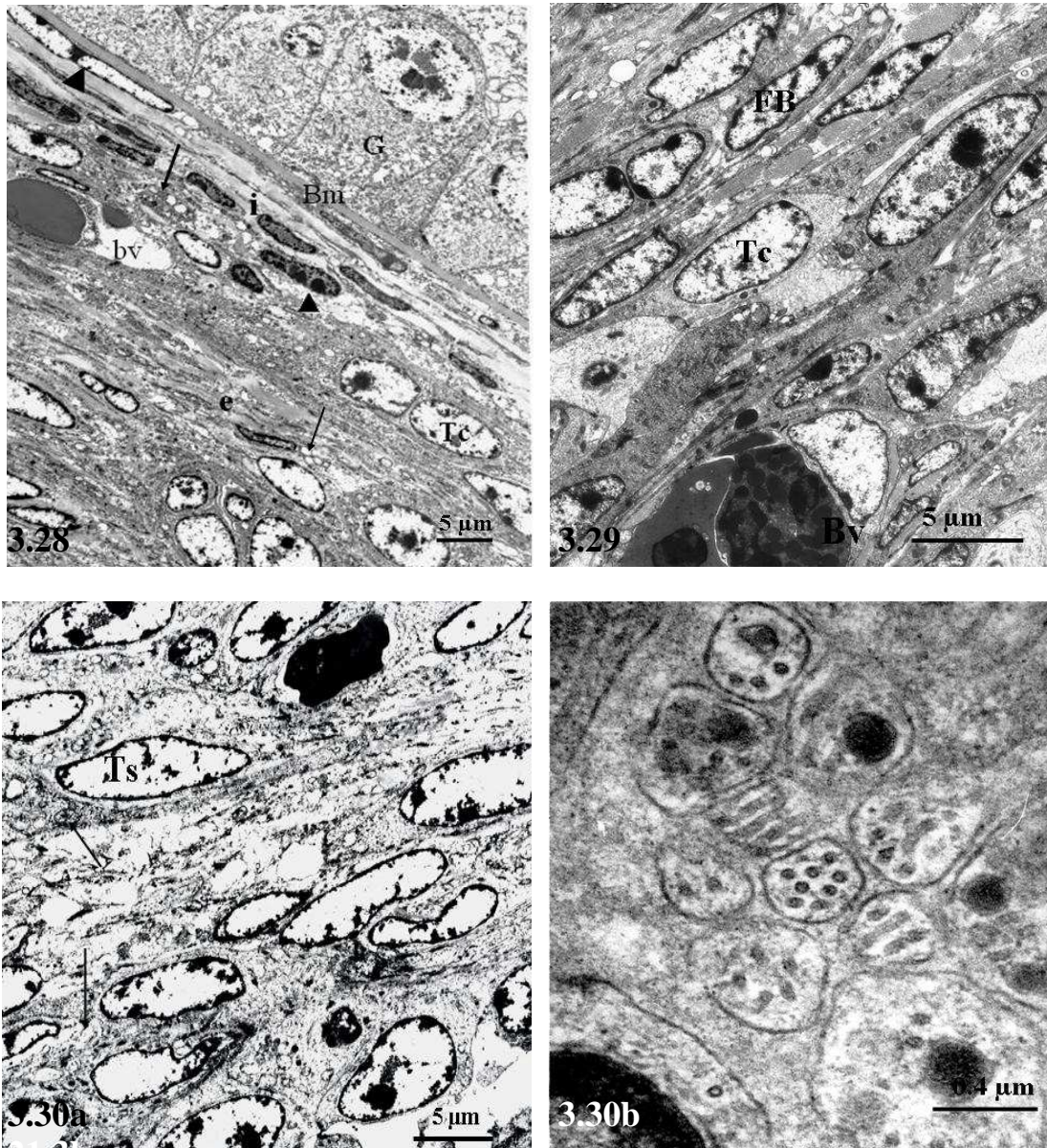


Fig. 3.28. Healthy vitellogenic follicle showing a distinct theca interna (i) and theca externa (e). The theca interna has a high concentration of fibroblasts (arrow heads). Note the presence of cells with vacuolated cytoplasm (arrows) in both the theca interna and theca externa. G: granulosa cell layer separated from the theca interna by the basal lamina (Bm). Tc: undifferentiated thecal gland cells. bv: blood vessel.

Fig. 3.29. Portion of an healthy vitellogenic follicle demonstrating fibroblasts (FB) and undifferentiated thecal gland cells (Tc) arranged in strata. Bv: blood vessel.

Fig. 3.30a. A survey electron micrograph of the thecal layer showing nerve fibres (arrows). Ts: undifferentiated thecal gland cells. b. A higher magnification electron micrograph of unmyelinated nerve fibres in the theca externa.

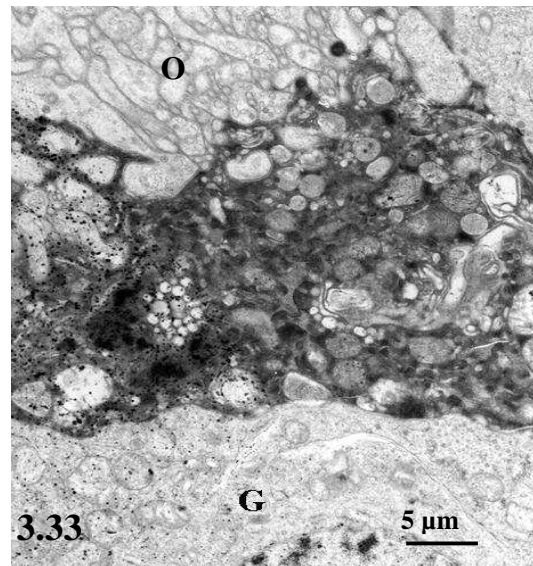
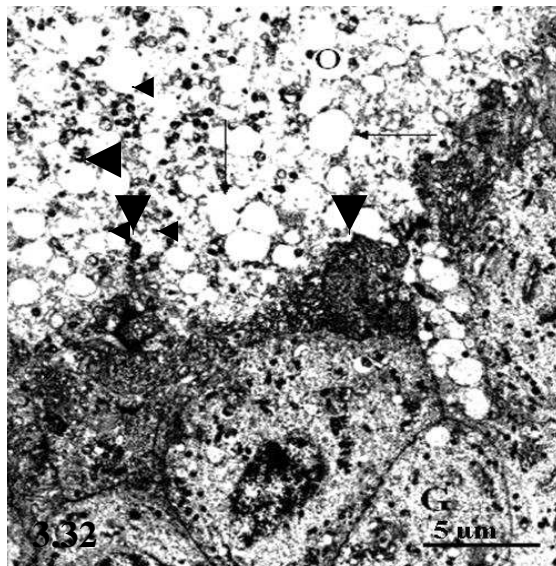
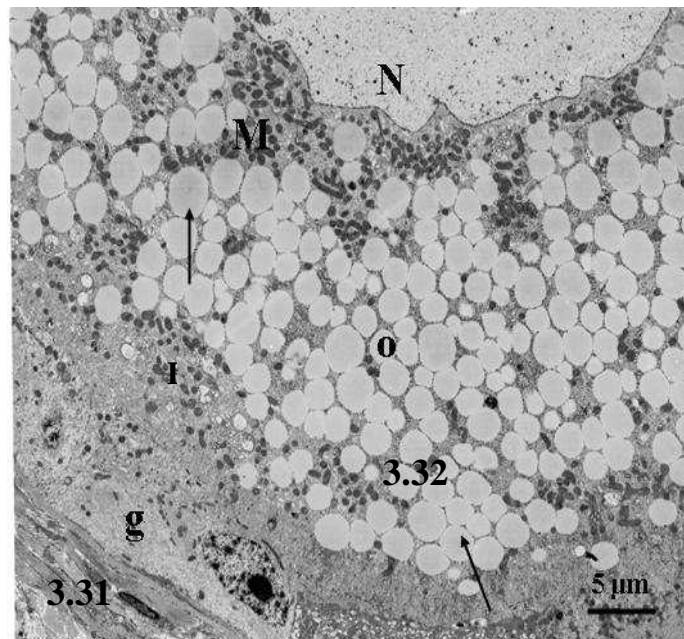


Fig. 3.31. A survey electron micrograph of an atretic primordial follicle showing lipid droplets (arrows) in the oocyte (o). Groups of mitochondria (M) are evident close to the nucleus (N), as well as in the peripheral regions (P) of the oocyte.

Fig. 3.32. Atretic previtellogenic follicle. The oocyte (o) contains a large number of lipid droplets (arrows). Several electron dense bodies (arrow heads) are observed in the oocyte and in the zona radiata.

Fig. 3.33. Atretic previtellogenic follicle. An electron dense amorphous layer is present between the oocyte (O) and granulosa cell layer (g).

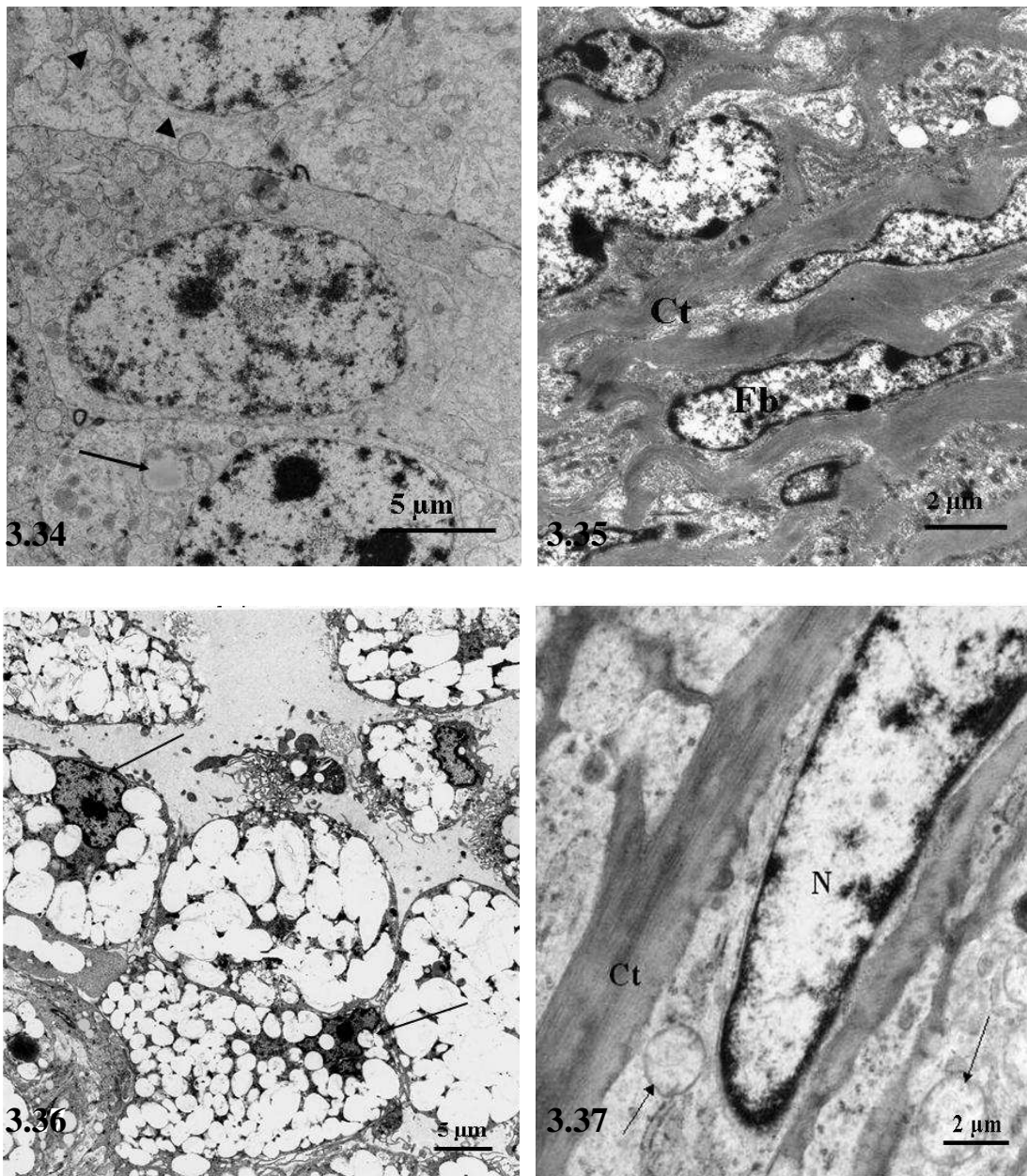


Fig. 3.34. Atretic previtellogenic follicle. Swollen mitochondria (arrow heads) in the granulosa cells. Some cells contained lipid droplets (arrow).

Fig. 3.35. Atretic previtellogenic follicle. There appears to be a greater concentration of connective tissue fibres (Ct) between the fibroblasts (Fb) in the theca externa.

Fig. 3.36. Interstitial gland cells in an atretic vitellogenic follicle. The gland cells contain irregular, peripherally-located nuclei (arrows).

Fig. 3.37. Atretic vitellogenic follicle. Thick collagen bundles (Ct) are present between fibroblasts in the theca externa. Note the presence of swollen mitochondria (arrows) in the fibroblast. N: nucleus.

CHAPTER FOUR

An immunohistochemical localization of intermediate filament proteins in the ovary of the sexually immature ostrich

4.1 Introduction

Studies on the ovaries of various species have shown marked differences in the distribution of intermediate filament proteins in healthy follicles, as well as in the different forms of atretic follicles (Marettova and Marettova, 2002; Van den Hurk *et al.*, 1995, Khan-Dawood *et al.*, 1996). Intermediate filaments are fibrous proteins, measuring approximately 8-10 nm in diameter. On the basis of chemical composition, function and distribution, six major types of intermediate filaments have been reported (Banks, 1993). The identified types include: keratin filaments (tonofilaments) found in epidermal cells; desmin filaments found in muscle cells; vimentin filaments found in cells of mesenchymal origin; neurofilaments located in axons; glial filaments found in glial cells and nuclear lamins located in the nucleus (Banks, 1993).

Intermediate filaments form an essential component of the cytoskeleton. In addition, intermediate filaments are also known to participate in various cellular activities, such as, differentiation, proliferation and cell-to-cell binding (Helfand *et al.*, 2003). A report by Galou *et al.* (1997) has shown that mutations in intermediate filament genes decrease cell and tissue resistance to mechanical stress, resulting in several abnormalities, such as fragile skin syndromes and myopathies. Furthermore, an abnormal intermediate filament aggregation pattern is known to occur in giant axonal neuropathy (Durham *et al.*, 1983).

As in mammals, ovarian tissue in the avian consists of various cell types. A report by Galou *et al.* (1997) has shown that the presence of certain intermediate filaments can be used to identify different cell types. Despite the usefulness of intermediate filaments in cell identification, few studies have been conducted on the occurrence of intermediate filament proteins in the avian ovary. Furthermore, there does not appear to be any information available on the occurrence and distribution of intermediate filament proteins in the sexually immature ostrich. Therefore, in this Chapter, an immunohistochemical study was carried out to investigate the distribution of desmin filaments, vimentin filaments, as well as smooth muscle actin filaments in the ovary of sexually immature ostrich.

4.2 Materials and methods

A total of 26 sexually immature female ostriches were used in this study. Sample collection was carried out as detailed in Chapter Two. The immunostaining technique was performed on 5µm-thick sections, using a LSAB-plus kit (Dakocytomation, Denmark). Sections were deparaffinized and endogenous peroxidase activity was blocked, using 3% (v/v) hydrogen peroxide solution in water for 5 minutes. The slides were then rinsed in a 0.01M phosphate buffer saline solution 1^{-1} (PBS, pH 7.4) for 5 minutes. Thereafter, the slides were microwaved at 750 W for three cycles of 5 minutes each. After being allowed to cool for 20 minutes the sections were rinsed with PBS. The sections were then incubated for 30 minutes at room temperature with monoclonal antibodies against vimentin, desmin and smooth muscle actin at dilutions of 1:100, 1:300 and 1:50 respectively. After this incubation the slides were rinsed with PBS and then incubated for 15 minutes with a ready-to-use

biotinylated secondary antibody (LSAB-plus kit, Dakocytomation, Denmark). Thereafter, the slides were rinsed in PBS and subsequently incubated for 15 minutes with the streptavidin component of the LSAB-plus staining kit. Slides were then rinsed in PBS and bound antibody was visualized after the addition of a 3,3' -diaminobenzidine tetrachloride solution (LSAB-plus kit, Dakocytomation, Denmark).

In the negative controls the primary antibodies were replaced with normal mouse serum. Smooth muscle was used as a positive control for both desmin and smooth muscle actin, whilst tonsillar tissue was used as a positive control for vimentin.

4.3 Results

Variations in the immunostaining of the sections used in this study were minor. No background staining was detected in the negative control sections, whilst positive immunostaining for vimentin, desmin and smooth muscle actin was observed in the tonsil and smooth muscle sections.

On the basis of visual examination, the relative intensities of vimentin, desmin and smooth muscle actin immunostaining were designated as absent (-), weak (+), moderate (++) and strong (+++). The immunostaining intensities are summarized in Tables 1 and 2.

4.3.1. Healthy follicles

The granulosa cells of primordial follicles showed weak immunostaining for desmin whilst moderate desmin immunostaining was observed in the granulosa cells of previtellogenic follicles (Fig. 4.1). In the vitellogenic follicles, no immunoreactivity for desmin was observed in the granulosa cell layer. However, in these follicles moderate immunostaining for desmin was seen in the fibroblasts of the theca interna (Fig. 4.2).

Strong vimentin immunostaining was observed in the granulosa cells of primordial and previtellogenic follicles (Fig. 4.3). However, granulosa cells of vitellogenic follicles showed weak immunoreactivity for vimentin. Thecal fibroblasts in early previtellogenic follicles were immunonegative for vimentin. Weak immunostaining for vimentin was observed in the fibroblasts of the theca interna and theca externa of vitellogenic follicles.

Smooth muscle actin immunoreactivity was restricted to fibroblasts in the thecal layer of vitellogenic follicles (Fig. 4.4). However, most of the theca interna cells closest to the granulosa cell layer were immunonegative for smooth muscle actin (Fig. 4.4)

4.3.2. Atretic follicles

Atretic primordial and previtellogenic follicles were desmin immunonegative. Desmin immunostaining was observed in fibroblast-like cells, which infiltrated the oocytes of atretic vitellogenic follicles (fig. 4.5 & 4.6). In the advanced stages of type I atresia, desmin immunoreactivity was restricted to the blood vessel walls and stroma (fig. 4.7).

The granulosa cell layer of primordial and previtellogenic atretic follicles was moderately immunopositive for vimentin (fig. 4.8). In addition, fibroblast-like cells in the oocytes of atretic vitellogenic follicles displayed a positive immunostaining for vimentin (fig. 4.9). Weak immunostaining for vimentin was observed in the interstitial glands cells of atretic type II vitellogenic follicles (fig. 4.10).

Positive immunostaining for smooth muscle actin was observed in fibroblast-like cells in the theca interna of type I atretic vitellogenic follicles (Fig. 4.11). In addition, smooth muscle actin immunoreactivity was also demonstrated in fibroblast-like cells, which infiltrated the central regions of the type II atretic vitellogenic follicles (Fig. 4.12).

4.3.3. Stroma

Fibrocytes in the stromal connective tissue cords, as well as in the fibrous capsule of the ovary were immunopositive for smooth muscle actin. Weak vimentin immunostaining was observed in the stromal fibroblasts (fig. 4.3). Positive vimentin immunostaining was demonstrated in the endothelial cells of stromal blood vessels. In addition, strong immunostaining for desmin and smooth muscle actin was localized in the tunica media of these blood vessels (fig. 4.2 & 4.4). Fibroblasts in the stroma showed positive immunoreactivity for desmin.

4.4 Discussion

In the present study, immunoreactivity for the intermediate filament proteins desmin, vimentin and smooth muscle actin was demonstrated in the ovary of the sexually immature ostrich. In addition, differences in the immunoreactivity of intermediate filament proteins, in healthy and atretic follicles, were revealed. The presence of desmin immunoreactivity in the granulosa cells of the immature ostrich correlated well with results of desmin immunostaining in the ovary of the rat (Albertini and Kravit, 1981). However, contrary to findings in the sheep (Marettova and Mareta, 2002) granulosa cells in healthy previtellogenic follicles of the sexually immature ostrich showed a moderate immunostaining for desmin. In the ovary of the sheep, desmin immunostaining was limited to a few cells in the granulosa layer, with a more pronounced immunoreactivity being observed in stromal fibroblasts and smooth muscle cells of blood vessels (Marettova and Mareta, 2002). Research on the primate ovary has shown the localization of desmin immunoreactivity in luteinized granulosa cells (Khan-Dawood *et al.*, 1996). Likewise, in the current study desmin immunoreactivity was observed in the interstitial gland cells of atretic follicles. In the present investigation interstitial glands cells were formed from granulosa and theca interna cells.

Desmin was originally believed to be a muscle-specific protein occurring in skeletal, smooth and cardiac muscle. However, desmin immunoreactivity has been observed in several cell types, including fat storing cells (Ito cells) in the liver (Yokoi *et al.*, 1984). Furthermore, desmin is also synthesized in endothelial cells. Although a report by Schroeder *et al.* (1985) has shown that granulosa

cells detach from thecal cells two hours before ovulation, more research is needed to ascertain the physiological function of desmin during ovulation.

In addition to providing structural integrity to cells vimentin filaments are important during cellular morphogenesis (Helfand *et al.*, 2003). In the present study vimentin filaments were localized in the granulosa cells and thecal fibroblasts of healthy late previtellogenic and vitellogenic follicles. However, immunostaining for vimentin in atretic follicles was weak to moderate. This observation suggests that as follicles undergo atresia vimentin filaments are dismantled.

In the current study, smooth muscle actin immunoreactivity was consistently demonstrated in the theca externa fibroblasts of healthy vitellogenic follicles, as well as in the fibroblasts of connective tissue cords in the stroma. In addition, smooth muscle actin immunoreactivity was observed in the smooth muscle cells of blood vessels. These findings correlated well with observations made in the Japanese quail in which smooth muscle actin immunoreactivity was observed in the cells of theca interna and theca externa, as well as in vascular smooth muscle cells (Van Nassauw *et al.*, 1989; Van Nassauw and Callebaut, 1991). Van Nassauw *et al.* (1992) have reported that thecal cells in the Japanese quail possess ultrastructural characteristics of smooth muscle cells. However, in the current study the cells exhibiting smooth muscle actin immunoreactivity appeared to be fibroblasts. Thecal fibroblasts have been shown to possess a contractile ability which is thought to be important during ovulation (Yoshimura *et al.*, 1983). Further studies need to be conducted to ascertain the possible role

of smooth muscle actin filaments in the development of ovarian follicles in the sexually immature ostrich.

In conclusion, the results of the present study have shown the occurrence of the intermediate filament proteins desmin, vimentin and smooth muscle actin in the ovarian tissue of the sexually immature ostrich. In addition, the results show that the distribution and immunostaining of the intermediate filaments changes during follicular growth and degeneration.

4.5 References

- ALBERTINI, D.F. & KRAVIT, N.G. 1981. Isolation and biochemical characterization of ten-nanometer filaments from cultured ovarian granulosa cells. *Journal of Biological Chemistry*, 256:2484-2492.
- BANKS, W.J. 1993. Cells- structure and function, in: *Applied Veterinary Histology, 3rd edition*, edited by R.W. Reinhardt. Mosby. Pg. 41.
- DURHAM, H.D., PENA, S.D. & CARPENTER, S. 1983. The neurotoxins 2,5-hexanedione and acrylamide promote aggregation of intermediate filaments in cultured fibroblasts. *Muscle and Nerve*, 6:631-637.
- GALOU, M., GAO, J., HUMBERT, J., MERICKSKAY, M., LI, Z., PAULIN, D. & VICART, P. 1997. The importance of intermediate filaments in the adaptation of tissues to mechanical stress: evidence from gene knockout studies. *Biology of Cell*, 89:85-97.

- HELFAND, B. T., CHANG, L. & GOLDMAN, R.D. 2003. The dynamic and motile properties of intermediate filaments. *Annual Review of Cell Developmental Biology*, 19:445-467.
- KHAN-DAWOOD, F.S., DAWOOD, M.Y. & TABIBZADEH, S. 1996. Immunohistochemical analysis of the microanatomy of primate ovary. *Biology of Reproduction*, 54:734-742.
- MARETTOVA, E. & MARETTA, M. 2002. Demonstration of intermediate filaments in sheep ovary. *Acta Histochemica*, 104:431-434.
- SCHROEDER, P.C & TALBOT, P. 1985. Ovulation in the animal kingdom. A review with an emphasis on the role of contractile processes. *Gamete Research*, 11:191-221.
- VAN DEN HURK, R., DIJKSTRA, G., VAN MIL, F.N., HULSHOF, S.C. & VAN DEN INGH, T.S. 1995. Distribution of the intermediate filament proteins vimentin, keratin and desmin in the bovine ovary. *Molecular Reproduction and Development*, 41:459-467.
- VAN NASSAUW, L., CALLEBAUT, M., HARRISSON, F., DANEELS, G. & MOEREMANS, M. 1989. Immunohistochemical localization of desmin in the quail ovary, demonstration of a suspensory apparatus. *Histochemistry*, 90:371-377.

VAN NASSAUW, L. & CALLEBAUT, M. 1991. Structural and immunohistochemical aspects of the postovulatory follicle in Japanese quail. *Anatomical Records*, 229:27-30.

VAN NASSAUW, L., HARRISSON, F. & CALLEBAUT, M. 1992. Immunolocalization of smooth muscle-like cells in the quail ovary. *European Journal of Morphology*, 30:275-288.

YOKOI, Y., NAMIHISA, T., KURODA, H., KOMATSU, I., MIYAZAKI, A., WATANABE, S. & USUI, K. 1984. Immunocytochemical detection of desmin in fat-storing cells (Ito cells). *Hepatology*, 4:709-714.

YOSHIMURA, Y., TANAKA, K. & KOGA, O. 1983. Studies on the contractility of follicular wall with special reference to the mechanism of ovulation in hens. *British Poultry Science*, 24:213-218.

Table 4.1

Summary of the immunohistochemical localization of vimentin, desmin and smooth muscle actin (SMA) in healthy ovarian follicles of the immature ostrich

Follicle type	Follicular region	Desmin	Vimentin	SMA
Primordial	granulosa cell layer	+	+++	-
Early previtellogenic	granulosa cell layer	++	+++	-
	Thecal fibroblasts	+++	-	-
Late previtellogenic	granulosa cell layer	++	+++	-
	Thecal fibroblasts	+++	++	-
Vitellogenic	granulosa cell layer	-	+	-
	Fibroblasts (t.interna)	++	+	<u>±</u>
	Fibroblasts (t.externa)	-	+	++

Intensities of immunostaining : -, absent; +, weak; ++, moderate; +++, strong

Table 4.2

Summary of the immunohistochemical localization of the vimentin, desmin and smooth muscle actin (SMA) in atretic ovarian follicles of the immature ostrich.

Follicle type	Follicular region	Desmin	Vimentin	SMA
Primordial	granulosa cell layer	-	++	-
Previtellogenic	granulosa cell layer	-	++	-
	Thecal fibroblasts	-	-	-
Vitellogenic (Type I)	granulosa cell layer	-	-	-
	Fibroblasts (t.interna)	-	-	-
	Fibroblasts (t.externa)	-	-	-
	Fibroblast-like cells in oocyte	++	++	+++
Vitellogenic (Type II)	Interstitial gland cells	+	+	-
	Fibroblast-like cells in oocyte	++	++	+++

Intensities of immunostaining : -, absent; +, weak; ++, moderate; +++, strong

4.6 List of figures

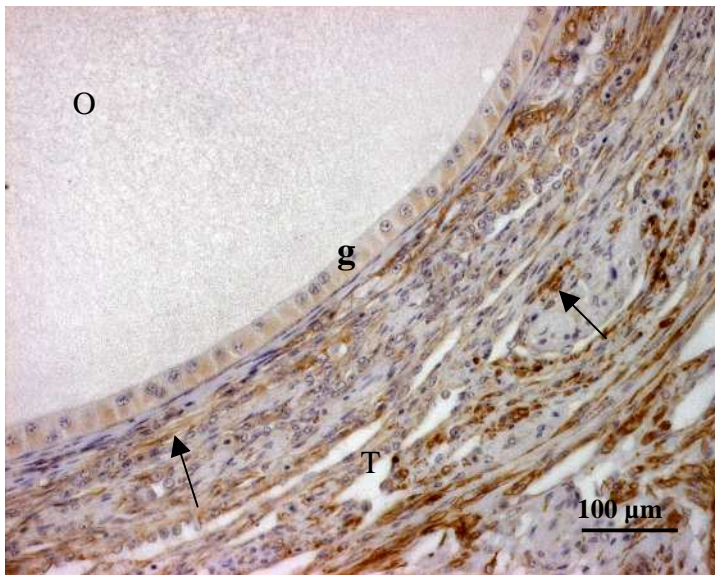


Fig. 4.1. Healthy previtellogenic follicle showing a moderate immunostaining for desmin in the granulosa cells (g). Strong immunostaining is observed in the thecal fibroblasts (arrows). O: Oocyte. T: Thecal layer.

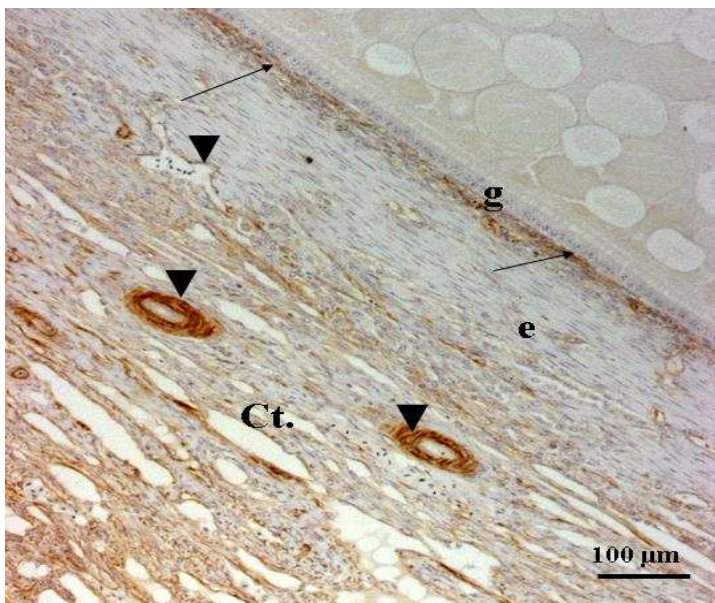


Fig. 4.2. Healthy vitellogenic follicle. A moderate immunoreactivity for desmin is exhibited in fibroblasts (arrows) in the theca interna. In addition, desmin immunoreactivity is also observed in blood vessel walls (arrow heads) in the theca interna (i), theca externa (e) and connective tissue layer (Ct). Granulosa cells (g) were immunonegative for desmin.

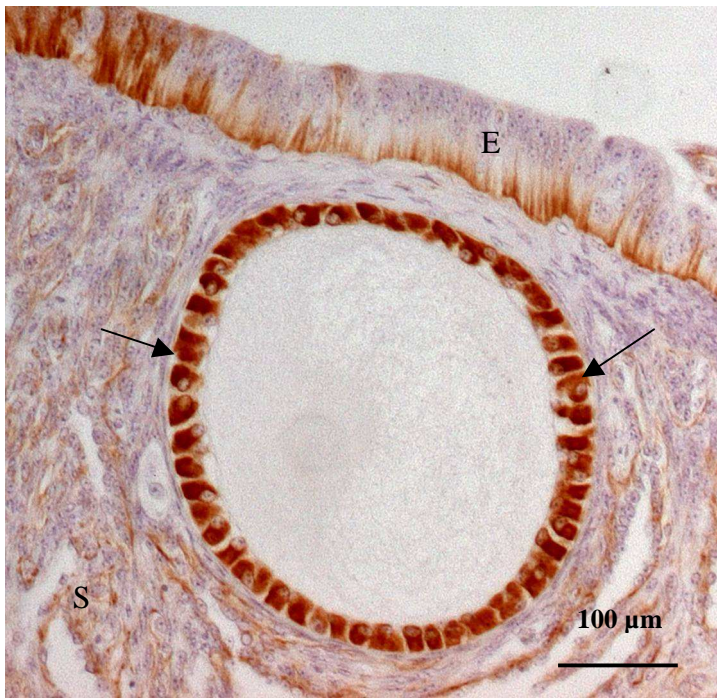


Fig. 4.3. Early previtellogenic follicle (healthy). Strong immunoreactivity for vimentin is seen in the granulosa cells (arrows). Cells in the stoma (S) and germinal epithelium (E) show weak immunostaining.

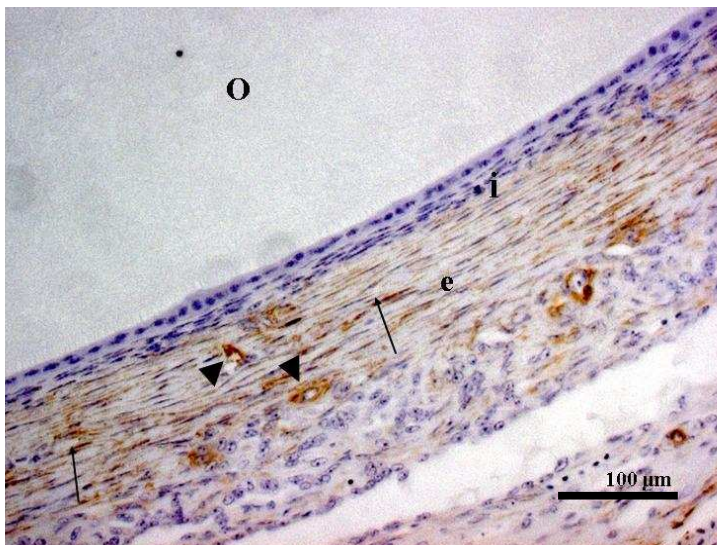


Fig. 4.4. Healthy vitellogenic follicle. Fibroblasts (arrows) and blood vessels (arrow heads) in the theca externa (e) show positive immunostaining for smooth muscle actin. Fibroblasts adjacent to the basal lamina of the follicle were generally immunonegative for smooth muscle actin. O: oocyte.

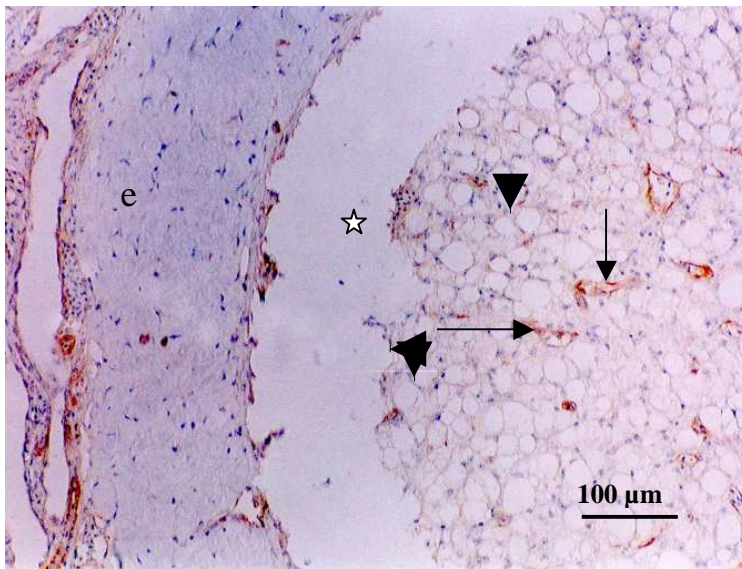


Fig. 4.5. Atretic vitellogenic follicle. Fibroblast-like cells (arrows) demonstrate positive immunoreactivity for desmin. Note the presence of vacuolated theca interna cells (arrow heads) and a hyalinized theca externa (e). Asterisk: artifact

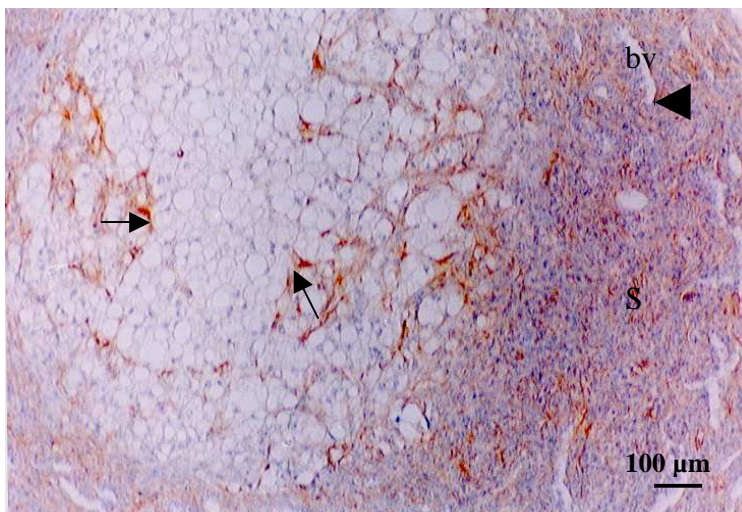


Fig. 4.6. Vitellogenic follicle (advanced stage of type II atresia). Positive immunostaining for desmin is seen in fibroblast-like cells, which have infiltrated the oocyte (arrows). Moderate desmin immunostaining is also observed in the stroma (S), as well as in endothelial cells (arrow head) of the blood vessel (bv) shown.

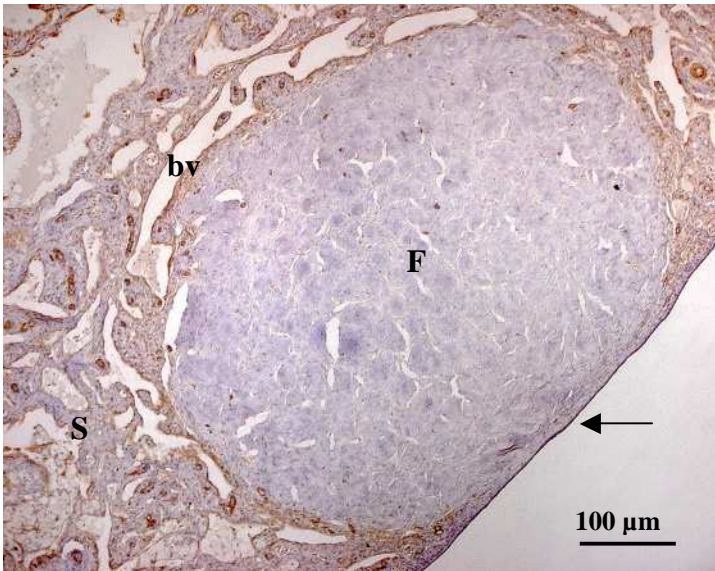


Fig. 4.7. Atretic vitellogenic follicle (type I). Desmin immunoreactivity is present in the stroma (s) and in the blood vessel walls (bv). Arrow: germinal epithelium. Note that the entire follicle (F) is occupied by hyalinized connective tissue.

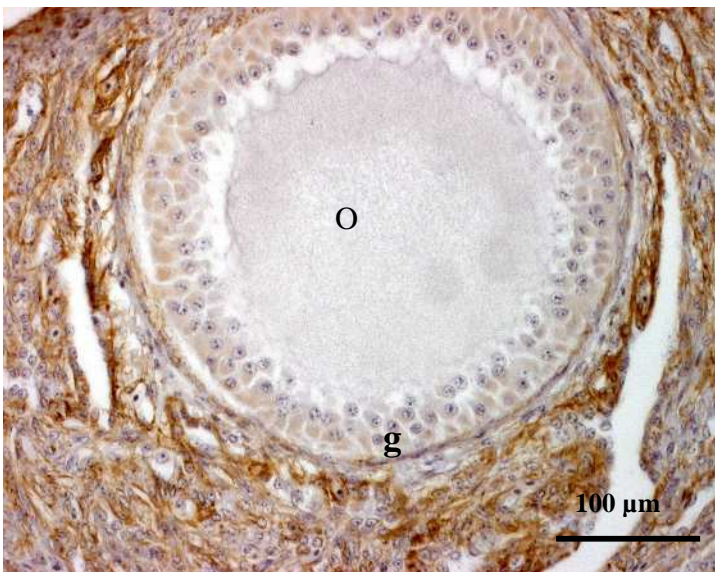


Fig. 4.8. Atretic previtellogenic follicle. Multilayered granulosa cell layer (g) showing a moderate immunostaining for vimentin. Note the presence of strong immunostaining in the stroma (s).

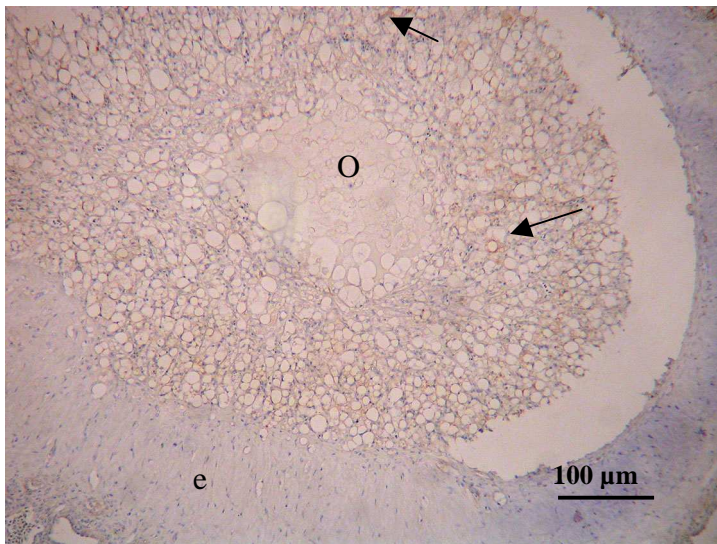


Fig. 4.9. Atretic vitellogenic follicle (type I) displaying a hyalinized theca externa (e) and a shrunken oocyte (o). Positive immunoreactivity for vimentin is seen in fibroblast-like cells (arrows) within the oocyte (o).

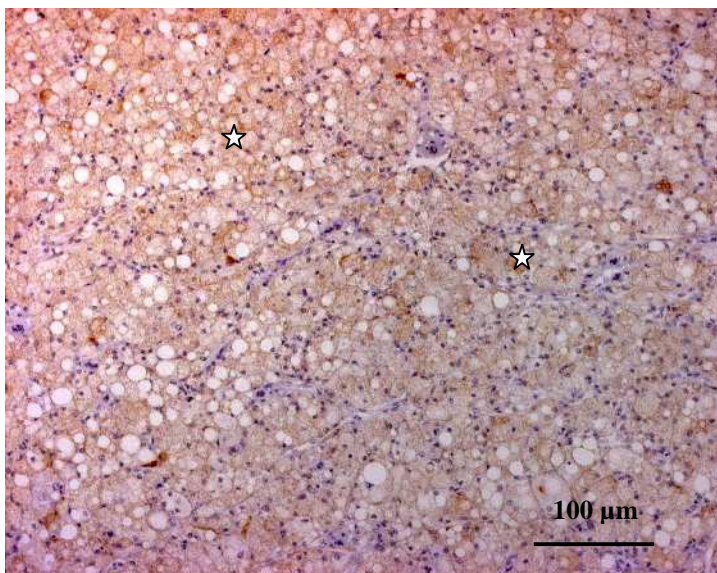


Fig. 4.10. Atretic vitellogenic follicle (type II). Vimentin immunoreactivity is seen in the interstitial gland cells (asterisks).

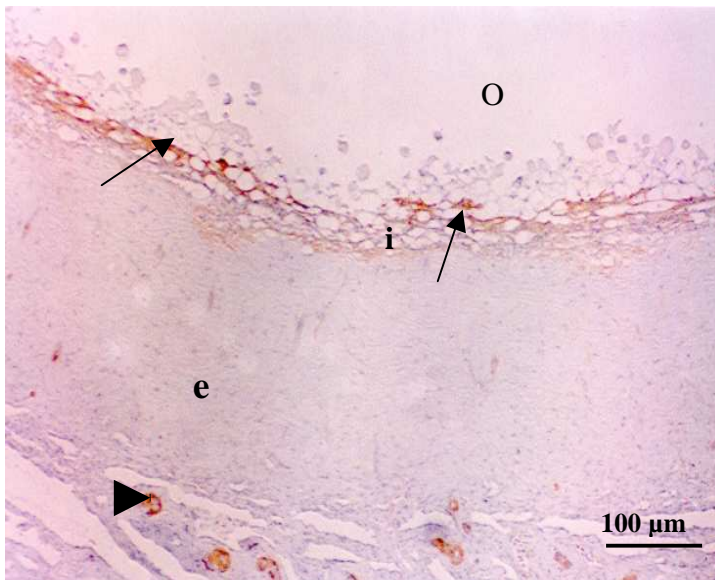


Fig. 4.11. Atretic vitellogenic follicle (type I). Smooth muscle actin immunoreactivity is observed in fibroblast-like cells (arrows) and smooth muscle cells of blood vessels (arrow head). Note the vacuolated theca interna cells (i) infiltrating the oocyte (O). e: hyalinized theca externa.

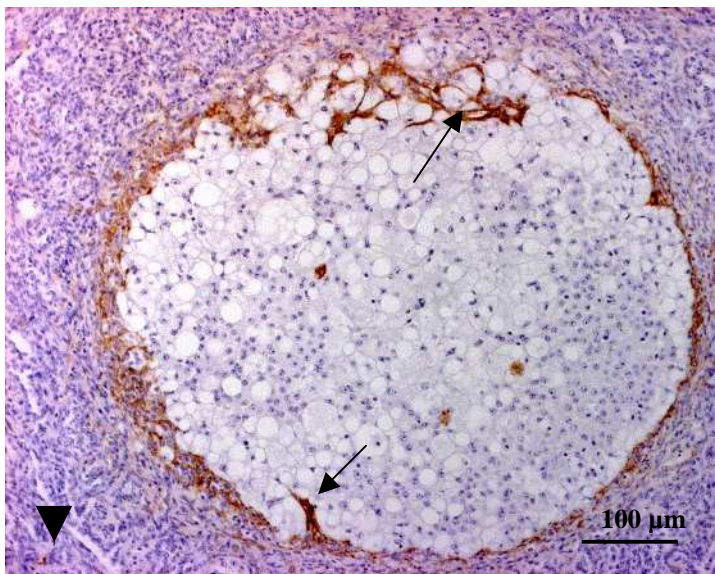


Fig. 4.12. Atretic vitellogenic follicle (type II). The entire follicle has been transformed into an interstitial gland mass. Note the presence of smooth muscle actin immunoreactive fibroblasts (arrows) infiltrating the mass. Blood vessels (arrow head) exhibiting weak smooth muscle actin immunoreactivity are observed in the stroma (S).

CHAPTER FIVE

The distribution of progesterone, oestrogen and androgen receptors in the ovary of the sexually immature ostrich

5.1 Introduction

Several studies have indicated that gonadotropins are the primary regulators of ovarian function (Ritzhaupt and Bahr, 1987; Yoshimura *et al.*, 1995a). During folliculogenesis, the gonadotropins, luteinizing hormone (LH) and follicle stimulating hormone (FSH), are essential for the completion of follicular development. In addition, gonadotropins are known to have stimulatory effects on the cells of the theca interna and thecal glands (Dahl, 1971) cited by Guraya (1989).

It is known that steroid hormones are also involved in the control of ovarian function. Research conducted by Yoshimura and Tamura (1986) and Yoshimura *et al.* (1993) has shown that progesterone and oestrogen suppress follicular atresia in hypophysectomized chickens. In addition, the paracrine action of oestrogen on oestrogen receptors (OR) in the ovarian stroma has been documented (Bigsby *et al.*, 2004). In the domestic fowl, OR have been localized in white-yolk, preovulatory and postovulatory follicles (Yoshimura *et al.*, 1995b). In addition, OR were demonstrated in thecal gland cells in the outer regions of the theca externa of white yolk follicles (Yoshimura *et al.*, 1995b). Based on these findings it was suggested that the activation of OR may influence follicular growth and regulate steroid hormone production in follicles (Yoshimura *et al.*, 1995b).

Progesterone plays a major role in the regulation of follicular maturation and ovulation through receptor-mediated pathways (Yoshimura and Bahr, 1991). In birds, it has been shown that progesterone induces the LH surge, 4 to 6 hours before ovulation (Wilson and Sharp, 1973; Johnson *et al.*, 1985). Furthermore, it is thought that progesterone acts directly on the follicular wall to induce structural and biochemical changes associated with ovulation (Tanaka *et al.*, 1987; Isola *et al.*, 1987). Progesterone acts via the progesterone receptor (PR), which has been demonstrated in both preovulatory and postovulatory follicles in the domestic fowl (Yoshimura *et al.*, 1995a; Yoshimura and Bahr, 1991).

Androgen, in a similar manner to progesterone and oestrogen, has also been found to act directly on the ovarian follicle to regulate its function (Yoshimura *et al.*, 1993). In addition, androgens are known to have an effect on steroidogenesis. Lee and Bahr (1989) have shown that androgens suppress progesterone production by granulosa cells in a dose-related manner. Another effect of androgens on ovarian tissue is the inhibition of plasminogen activator activity of granulosa cells, which is assumed to play a major role in cellular differentiation and follicular maturation (Tilly and Johnson, 1987). Yoshimura *et al.* (1993) localized androgen receptors (AR) in various cells of the ovary in the domestic fowl. The report showed that strong AR immunoreactivity is demonstrated in the granulosa cells and thecal gland cells of small white-yolk follicles, preovulatory and postovulatory follicles. Furthermore, AR were also localized in thecal fibroblasts of small white-yolk follicles, and preovulatory follicles. Weak immunostaining was demonstrated in the fibroblasts of postovulatory follicles.

Huang and Nalbandov (1979) proposed a model for steroidogenesis within the avian ovarian follicle, in which progesterone is the precursor for the synthesis of androgens and oestrogens. However, Guraya (1985) later showed that thecal gland cells produce androgens, which then potentiate the synthesis of oestrogen. Therefore, the cascade of the reaction could flow from progesterone to testosterone, which then acts as a precursor for oestrogen. The conversion of testosterone to oestrogen is catalyzed by the enzyme 17 β -hydroxysteroid dehydrogenase (HSDH) under the influence of LH (Davis and Burger, 2003).

Although several studies have documented the occurrence of steroid hormone receptors in the avian ovary, no information is available on the localization of these receptors in the sexually immature ostrich. Therefore, in this Chapter the occurrence and distribution of the oestrogen, progesterone and androgen receptors are investigated.

5.1 *Materials and methods*

A total of 26 sexually immature female ostriches aged between 12 and 14 months and weighing 90 – 100 kg, were used in the present study. Tissue samples were collected as soon as possible following the death of the bird. The tissues were embedded in OCT compound (Sakura, CA, USA) and snap-frozen in an isopentane slurry. Thereafter, the tissue samples were stored at -80°C.

The immunostaining technique was performed on 10 μ m-thick frozen sections, using a LSAB-plus kit (Dakocytomation, Denmark). Sections were air-dried for 60 min and endogenous peroxidase activity was blocked, using a 3% (v/v)

hydrogen peroxide solution in water for 5 minutes. The slides were then rinsed in a 0.01M phosphate buffered saline solution 1⁻¹ (PBS, pH 7.4) for 5 minutes. Thereafter, the sections were incubated at room temperature with monoclonal antibodies against the progesterone receptor (PR), oestrogen receptor α (OR) and androgen receptor (AR) at concentrations of 1:100, 1:35 and 1:50 respectively. The incubation time was 1 hour for the PR, and 2 hours for the OR and AR. After this incubation the slides were rinsed with PBS and then incubated for 30 minutes with a ready-to-use biotinylated secondary antibody (LSAB-plus kit, Dakocytomation, Denmark). Thereafter, the slides were rinsed in PBS and subsequently incubated for 30 minutes with the streptavidin component of the LSAB-plus staining kit. Slides were then rinsed in PBS and bound antibody was visualized after the addition of a 3,3' -diaminobenzidine tetrachloride solution (LSAB-plus kit, Dakocytomation, Denmark). In the negative controls the primary antibodies were replaced with mouse serum. Ostrich shell gland was used as a positive control for both OR and PR, whilst testis was used as a positive control for AR.

5.3 Results

The distribution of immunoreactivity to OR, PR and AR in the ovary was visualized under the light microscope at a magnification of X400. The relative intensities of immunoreaction for OR, PR and AR were designated as absent, weak, moderate or strong. No background staining was observed in the negative control sections. Positive immunoreactivity for OR and PR was observed in shell gland, whilst AR immunostaining was observed in the testis.

5.3.1 Oestrogen receptor (OR)

Positive immunostaining for OR was observed in the nuclei of the germinal epithelium (fig. 5.1), as well as in a few fibroblasts in the stroma. In addition, a few fibroblasts and thecal gland cells in the theca externa of previtellogenic and vitellogenic follicles showed weak immunoreactivity for OR (fig. 5.2). However, fibroblasts in the theca interna of these follicles were generally immunonegative. No OR immunoreactivity was observed in the granulosa cell layer.

5.3.2 Progesterone receptor (PR)

Immunostaining for PR was observed in the nuclei of the germinal epithelium, stromal fibroblasts, as well as in granulosa cells of previtellogenic and vitellogenic follicles. PR immunostaining in the germinal epithelium nuclei was strong, whilst staining in the granulosa cells was weak to moderate (fig. 5.3). It appeared that the proportion of PR immunoreactive granulosa cells increased with follicular development. Strong immunoreactivity for PR was observed in the tunica media of blood vessels and in smooth muscle cells located in the cortex and medulla (fig. 5.4). Weak to moderate immunoreactivity for PR was identified in stromal fibroblasts, as well as in the thecal layer of previtellogenic and vitellogenic follicles (fig. 5.5). Interstitial gland cells in these follicular sizes were generally immunonegative for PR.

5.3.3 Androgen receptor (AR)

Immunostaining for AR was observed in germinal epithelium nuclei and in a few fibroblasts in the ovarian stroma. AR immunostaining in the nuclei of the germinal epithelium was strong (fig. 5.6). Fibroblasts in the stroma of the ovary stained moderately with AR. Occasional immunoreactivity for AR was observed

in fibroblasts in the theca externa and in granulosa cells of previtellogenic and vitellogenic follicles (fig. 5.7).

5.4 Discussion

The distribution of the OR, PR and AR in the ovary of the sexually immature ostrich was investigated in the current study. This appears to be the first description of the presence and distribution of these steroid receptors in the ovary of the sexually immature ostrich. In the reproductive system oestrogen is known to mediate several important physiological processes. A report by Delville *et al.*, (1986) has shown that sexual receptivity in the Japanese quail coincides with high plasma levels of estradiol and progesterone. In mammals oestrogen causes endometrial hyperplasia and hypertrophy (Bigsby *et al.*, 2004). In addition, oestrogen is known to cause proliferative effects on target epithelial cells in the uterus (Bensley, 1951 cited by Hild-Petito *et al.*, 1988). Although the role of oestrogen in the sexually immature ostrich was not determined in this study, one could speculate that oestrogen might be involved in the growth of ovarian follicles. A report by Gonzalez-Moran (2005) has shown the abundance of ORs in the growing ovaries of newly hatched chicks. The report suggested that the oestrogen-OR interaction might play an important role in the regulation of ovarian and follicular development.

It is a well-established fact that the effect of oestrogen on ovarian tissue is mediated via specific ORs (Bigsby *et al.*, 2004). Two forms of the OR (OR α and OR β) have been documented (Green *et al.*, 1986). In addition, two forms of

OR α (OR α I and OR α II) have been isolated in the liver, ovary and oviduct of the domestic fowl (Griffin *et al.*, 1999).

The presence of the OR in the ovary has been demonstrated in several species, including the monkey (Hild-Petito *et al.*, 1988), the domestic fowl (Yoshimura *et al.*, 1995b; Gonzalez-Moran, 2005), the rat (Sakaguchi *et al.*, 2005) and the human (Vaskivuo *et al.*, 2005). In the sexually immature ostrich, the OR was localized in the nuclei of the germinal epithelium, thecal gland cells, as well as in a few fibroblasts in the ovarian stroma. In the domestic fowl, the OR was localized in the germinal epithelium, thecal gland cells, as well as in granulosa cells of vitellogenic follicles. Contrary to the observation made in the domestic fowl (Yoshimura *et al.*, 1995b), no immunoreaction for the OR was observed in granulosa cells of the sexually immature ostrich. According to Guraya (1989) granulosa cells are the source of progesterone in the avian ovary. Thus, the absence of the OR in granulosa cells of the sexually immature ostrich suggests that oestrogen does not regulate the production of progesterone in the sexually immature bird. The presence of the OR in thecal gland cells suggests that steroid synthesis by these gland cells is regulated by oestrogen via the OR.

Several studies have described the functional importance of progesterone in the female reproductive system (Fortune and Vincent, 1983; Johnson *et al.*, 1985; Yoshimura *et al.*, 1993). The reports suggest that progesterone regulates the growth and differentiation of ovarian follicles. Furthermore, Yoshimura and Bahr (1991) have demonstrated the regulatory role of progesterone on follicular maturation and ovulation. In addition, progesterone is known to exert structural

and biochemical changes on the wall of the follicle, which lead to ovulation (Tanaka *et al.*, 1987).

As shown in the results, the PR was observed in the nuclei of the germinal epithelium, granulosa cells, and stromal fibroblasts. Similar observations were made in the domestic fowl, where PR was localized in the germinal epithelium cells, thecal and granulosa cells (Isola *et al.*, 1987; Yoshimura and Bahr, 1991). It is known that the effect of progesterone on ovarian tissue is mediated through a specific PR interaction. However, the presence of the PR in the germinal epithelium, granulosa cells and fibroblasts of the sexually immature ostrich does not necessarily indicate that these cells are target sites solely for progesterone, as it is known that oestrogen also activates the PR (Kawashima, *et al.*, 1996; Yoshimura *et al.*, 2000).

In the current study, PR was also observed in the tunica media of blood vessels, as well as in smooth muscle cells in the cortex and medulla. The expression of PR in vascular smooth muscle cells has also been reported in the domestic fowl (Pasanen *et al.*, 1997), the rabbit (Perrot-Applanat *et al.*, 1988) and the human (Ingegno *et al.*, 1988; Perrot-Applanat *et al.*, 1988). The occurrence of PR in the tunica media of blood vessels suggests that the blood flow within the ovary might be influenced by the plasma concentrations of progesterone.

Androgens, which are commonly referred to as male hormones, have been found in large quantities in the ovaries of both mammals and birds (Okada *et al.*, 2003; Taber, 1951). In a similar manner to oestrogen and progesterone,

androgens have also been found to act directly on the ovarian follicle (Yoshimura *et al.*, 1993). Beato (1989) and Miesfeld (1989) reported that the activation of the human AR modulates gene expression, which regulates the synthesis of proteins involved in cell proliferation and differentiation. In the ovary of the monkey the AR was localized in the granulosa cell layer, thecal layer, stroma and germinal epithelium (Hild-Petito *et al.*, 1991). In addition, Slomczynska and Tabarowski (2001) reported the presence of AR in the granulosa and thecal cells of preantral and growing antral follicles in the ovary of the pig. Likewise, Yoshimura *et al.* (1993) localized the AR in the granulosa cells, thecal gland cells and thecal fibroblasts of the domestic fowl. In the current investigation, the AR was demonstrated in the nuclei of germinal epithelium, stromal fibroblasts and in a few granulosa cells in previtellogenic and vitellogenic follicles. Thus, it would appear that the results of the current study are in general agreement with the observations made in the domestic fowl (Yoshimura *et al.*, 1993), the monkey (Hild-Petito *et al.*, 1991) and the porcine (Slomczynska and Tabarowski, 2001).

The results of the current study are in agreement with research findings, which have described steroid receptors as being specifically localized in the nucleus (Perrot-Appianat, 1985; Hild-Petito *et al.*, 1988; Yoshimura *et al.*, 1995b). Significantly, the nuclei of the germinal epithelium showed immunoreactivity for all the antibodies used in the current study. Several studies have described the functional aspects of the germinal epithelium (Duke, 1978). The reports show that germinal epithelium cells contain dense bodies, which are rich in lysosomal enzymes (Bjersing and Cajender, 1974). It is thought that the activation of steroid receptors results in the release of the lysosomal enzymes, which

weakens the follicular wall at the onset of ovulation (Bjersing and Cajender, 1974). Although it is clear that ovulation does not occur in the sexually immature ostrich, the presence of PR and AR in the germinal epithelium supports the idea that these cells could be involved in the ovulatory process in the ostrich. A report by Tanaka and Inoue (1990) has shown that the administration of progesterone and testosterone induces ovulation within 3 to 6 hours in the domestic fowl. Further studies need to be carried out to investigate the role of steroid receptors in the ovulatory process of the ostrich.

In conclusion, the distribution of the steroid receptors highlighted in the present study appears to be similar to that described in the domestic fowl (Yoshimura *et al.*, 1993; 1995a; 1995b; Yoshimura and Bahr, 1991; Isola *et al.*, 1987). Further studies on the molecular characterization of these receptors will provide valuable comparative information.

5.5 References

BEATO, M. 1989. Gene regulation by steroid hormones. *Cell*, 56:335-344.

BIGSBY, R.M., CAPERELL-GRANT, A., BERRY, N., NEPHEW, K. & LUBAHN, D. 2004. Estrogen induces a systemic growth factor through an estrogen receptor-alpha-dependent mechanism. *Biology of Reproduction*, 70:178-183.

- BJERSING, L. & CAJENDER, S. 1974. Ovulation and the mechanism of follicle rupture. I. Light microscopic changes in rabbit ovarian follicles prior to induced ovulation. *Cell Tissue Research*, 148:287-300.
- DAVIS, S.R. & BURGER, H.G. 2003. The role of androgen therapy. *Best Practice and Research Clinical Endocrinology and Metabolism*, 17:165-175.
- DELVILLE, Y., SULON, J. & BALTHAZART, J. 1986. Diurnal variations of sexual receptivity in the female Japanese quail (*Coturnix Coturnix japonica*). *Hormones and Behaviour*, 20:13-33.
- DUKE, K.L. 1978. Non-follicular ovarian components, in: *The Vertebrate Ovary*, edited by R.E. Jones. New York and London: Plenum Press. Pp. 563-582.
- FORTUNE, J.E. & VINCENT, S.E. 1983. Progesterone inhibits the induction of aromatase activity in rat granulosa cells *in vitro*. *Biology of Reproduction*, 27:1078-1089.
- GONZALEZ-MORAN, M.G. 2005. Immunohistochemical detection of estrogen receptor alpha in the growing and regressing ovaries of newly hatched chicks. *Journal of Molecular Histology*, 36:147-155.
- GREEN, S., WALTER, P., KUMAR, V., KRUST, A., BORNERT, J.M., ARGOS, P. & CHAMBON, P. 1986. Human oestrogen receptor cDNA: sequence, expression and homology to v-erb-A. *Nature*, 320:134-139.

GRIFFIN, C., FLOURIOT, G., SONNTAG-BACK, V. & GANNON, F. 1999. Two functionally different protein isoforms are produced from the chicken receptor-gene. *Molecular Endocrinology*, 13:1571-1587.

GURAYA, S.S. 1985. *Biology of ovarian follicles in mammals*. Berlin: Springer-Verlag. Pp. 221-226.

GURAYA, S.S. 1989. Ovarian follicles in reptiles and birds, in: *Zoophysiology*, Vol. 24, edited by W. Buttgren. Berlin: Springer-Verlag. Pp. 232-235.

HILD-PETITO, S., STOUFFER, R.L. & BRENNER, R.M. 1988. Immunohistochemical localization of estradiol and progesterone receptors in the monkey ovary throughout the menstrual cycle. *Endocrinology*, 123:2896-2905.

HILD-PETITO, S., WEST, N.B., BRENNER, R.M. & STOUFFER, R.L. 1991. Localization of androgen receptor in the follicle and corpus luteum of the primate ovary during menstrual cycle. *Biology of Reproduction*, 44:561-568.

HUANG, E.S. & NALBANDOV, A.V. 1979. Steroidogenesis of chicken granulosa and theca cells: in vitro incubation system. *Biology of Reproduction*, 20:442-453.

INGEGNO, M.D., MONEY, S.R. & THELMO, W. 1988. Progesterone receptors in the human heart and great vessels. *Laboratory Investigations*, 59:353-356.

- ISOLA, J., KORTE, J. & TUOHIMAA, P. 1987. Immunocytochemical localization of progesterone receptor in the chick ovary. *Endocrinology*, 121:1034-1040.
- JOHNSON, P.A., JOHNSON, A.L. & VAN TIENHOVEN, A. 1985. Evidence for a positive feedback interaction between progesterone and luteinizing hormone in the induction of ovulation in the hen, *Gallus domesticus*. *General and Comparative Endocrinology*, 58:478-485.
- KAWASHIMA, M., TAKAHASHI, T., KAMIYOSHI, M. & TANAKA, K. 1996. Effects of progesterone, oestrogen and androgen on progesterone receptor binding in hen oviduct and uterus (shell gland). *Poultry Science*, 75:257-260.
- LEE, H.T. & BAHR, J.M. 1989. Inhibitory sites of androgens and estradiol-17 β -hydroxysteroid dehydrogenase and the amount of P450 cholesterol side-chain cleavage by testosterone and estradiol-17 β in hen granulosa cells. *Endocrinology*, 101:623-626.
- MIESFELD, R.L. 1989. The structure and function of steroid receptor proteins. *Critical Reviews in Biochemistry and Molecular Biology*, 24:101-117.
- OKADA, A., OHTA, Y., INOUE, S., HIROI, H., MURAMATSU, M. & IGUCHI, T. 2003. Expression of estrogen, progesterone and androgen receptors in the oviduct of developing, cycling and pre-implantation rats. *Journal of Molecular Endocrinology*, 30:301-315.

- PASANEN, S., YLIKOMI, T., SYVALA, H. & TUOHIMAA, P. 1997. Distribution of progesterone receptor in chicken: novel target organs for progesterone and estrogen action. *Molecular and Cellular Endocrinology*, 135:79-91.
- PERROT-APPLANAT, M., LOGEAT, F., GROYER-PICARD, M.T. & MILGROM, E. 1985. Immunohistochemical study of mammalian progesterone receptor using monoclonal antibodies. *Endocrinology*, 116:1473-1478.
- PERROT-APPLANAT, M., GROYER-PICARD, M.T., GARCIA, E., LORENZO, F. & MILGROM, E. 1988. Immunocytochemical demonstration of estrogen and progesterone receptors in muscle cells of uterine arteries in rabbit and humans. *Endocrinology*, 123:1511-1519.
- RITZHAUPT, L. & BAHR, J.M. 1987. A decrease in FSH receptors of granulosa cells during follicular maturation in the domestic hen. *Journal of Endocrinology*, 115:303-310.
- SAKAGUCHI, H., FUJIMOTO, J., HONG, B.L. & TAMAYA, T. 2005. Quantitative analysis of estrogen receptor proteins in rat ovary. *Journal of Steroid Biochemistry and Molecular Biology*, 94:83-91.
- SLOMCZYNSKA, M. & TABAROWSKI, Z. 2001. Localization of androgen receptor and cytochrome p450 aromatase in the follicle and corpus luteum of the porcine ovary. *Animal Reproduction Science*, 65:127-134.
- TABER, E. 1951. Androgen secretion in the fowl. *Endocrinology*, 48:6-16.

TANAKA, K. & INOUE, T. 1990. Role of steroid hormones and catecholamines in the process of ovulation in the domestic fowl, in: *Endocrinology of Birds: Molecular and behavioural*, edited by M. Wada, S. Ishii & C.G. Scanes. Springer-Verlag. Pp. 59-68.

TANAKA, K., LI, Z.D. & ATAKA, Y. 1987. Studies of ovulation in the perfused ovary of the fowl (*Gallus domesticus*). *Journal of Reproduction and Fertility*, 80:411-416.

TILLY, J.L. & JOHNSON, A.L. 1987. Presence and hormonal control of plasminogen activator in granulosa cells of the domestic hen. *Biology of Reproduction*, 37:1156-1164.

VASKIVUO, T.E., MAENTAUSTA, M., TORN, S., ODUWOLE, O., LONNBERG, A., HERVA, R., ISOMAA, V. & TAPANAINEN, J.S. 2005. Estrogen receptors and estrogen-metabolizing enzymes in human ovaries during fetal development. *Journal of Clinical Endocrinology and Metabolism*, 90:3752-3756.

WILSON, S.C. & SHARP, P.J. 1973. Variation in plasma LH levels during the ovulatory cycle of the hen *Gallus domesticus*. *Journal of Reproduction and Fertility*, 35:561-564.

YOSHIMURA, Y. & BAHR, J.M. 1991. Localization of progesterone receptors in pre- and post-ovulatory follicles of the domestic hen. *Endocrinology*, 128:323-330.

- YOSHIMURA, Y. & TAMURA, T. 1986. Effects of estradiol administration on the follicular tissue of hypophysectomized hens. *Poultry Science*, 65:1808-1810.
- YOSHIMURA, Y., CHANG, C., OKAMOTO, T. & TAMURA, T. 1993. Immunolocalization of androgen receptor in the small, preovulatory, and postovulatory follicles of laying hens. *General and Comparative Endocrinology*, 91:81-89.
- YOSHIMURA, Y., OKAMOTO, T. & TAMURA, T. 1995a. Effects of luteinizing hormone and follicle-stimulating hormone on the progesterone receptor induction in chicken granulosa cells *in vivo*. *Poultry Science*, 74:147-151.
- YOSHIMURA, Y., OKAMOTO, T. & TAMURA, T. 1995b. Changes in localization of ovarian immunoreactive estrogen receptor during follicular development in hens. *General and Comparative Endocrinology*, 100:368-371.
- YOSHIMURA, Y., KOIKE, K. & OKAMOTO, T. 2000. Immunolocalization of progesterone and oestrogen receptors in the sperm storage tubules of laying and diethylstilbestrol-injected immature hens. *Poultry Science*, 79:94-98.

5.6 List of figures

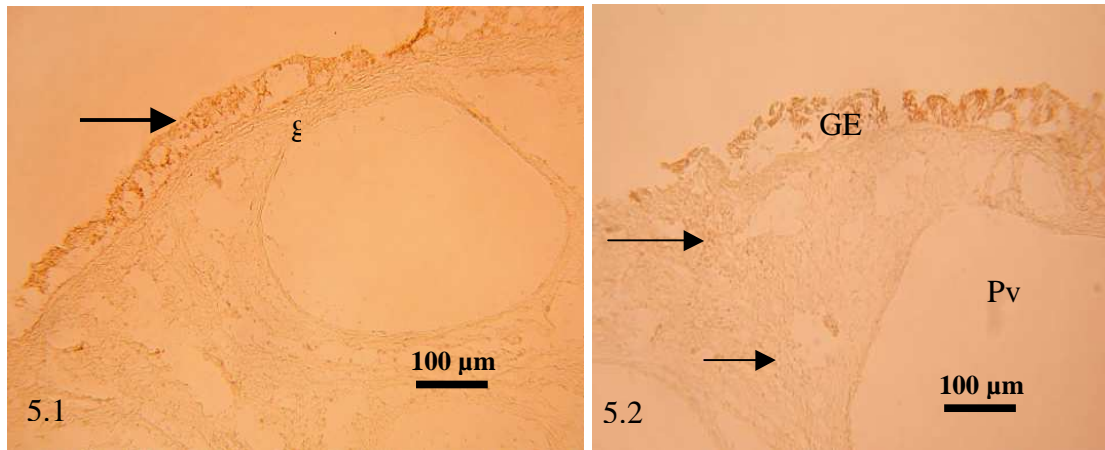


Fig. 5.1. A portion of cortex showing OR immunoreactivity in the nuclei of the germinal epithelium (arrow). No OR immunostaining is observed in granulosa cells (g).

Fig. 5.2. Part of previtellogenic follicle (Pv). Immunoreaction for OR is observed in the nuclei of thecal gland cells (arrows). GE: germinal epithelium.

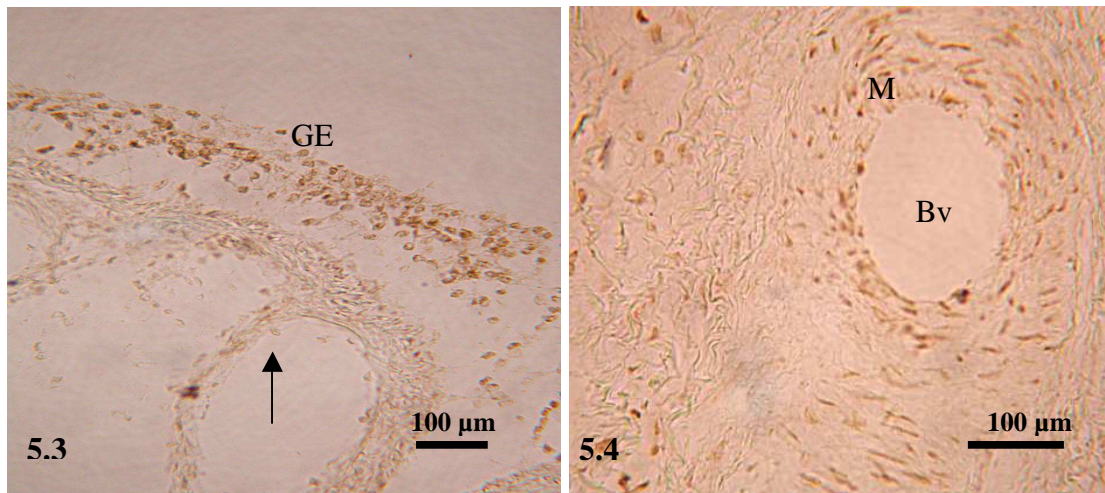


Fig. 5.3. Strong immunoreactivity for PR is observed in the nuclei of the germinal epithelium (GE). Granulosa cells (arrow) show moderate immunostaining for PR.

Fig. 5.4. PR immunoreactive smooth muscle cells are observed in the tunica media (M) of a blood vessel (Bv) in the medulla.

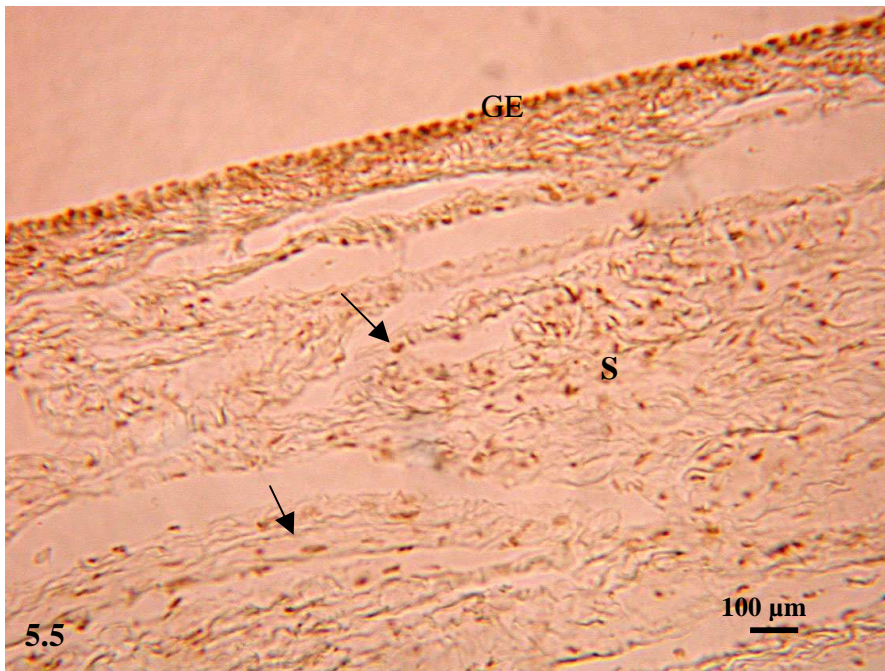


Fig. 5.5. A survey micrograph showing part of the stroma (S). A moderate immunoreaction for PR is observed in fibroblasts (arrows). Note the strong immunostaining for PR in the germinal epithelium (GE).

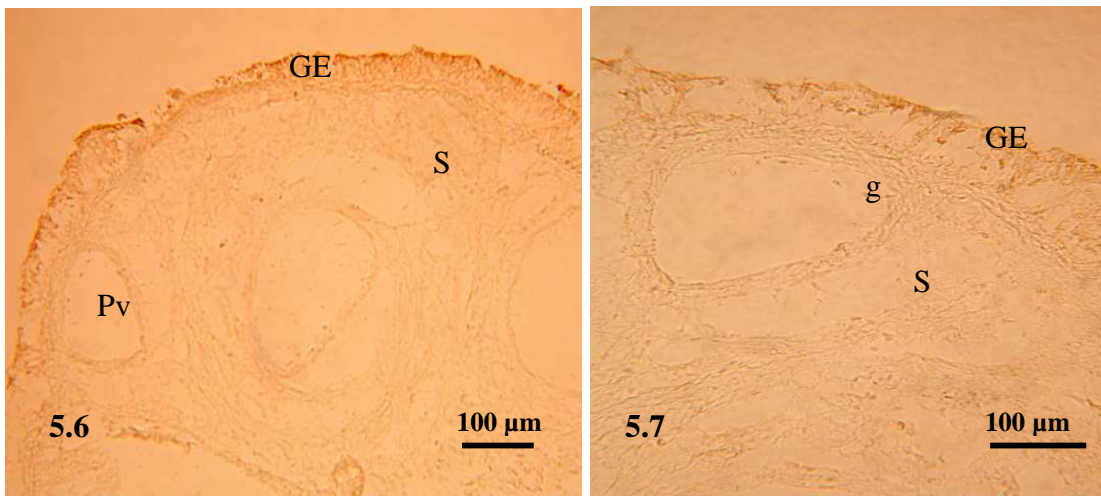


Fig. 5.6. Ovarian cortex showing strong immunoreactivity for AR in the nuclei of the germinal epithelium (GE). A moderate immunostaining for AR is observed in stromal fibroblasts in the stroma (S). Pv: previtellogenic follicle.

Fig. 5.7. Positive immunostaining for AR is observed in a few granulosa cells (g) in a previtellogenic follicle. S: Stroma. GE: germinal epithelium.

CHAPTER SIX

Immunoreactivities to protein gene product 9.5, neurofilament protein and neuron specific enolase in the ovary of the sexually immature ostrich

6.1 Introduction

The innervation of the ovary has been studied in several species of birds and mammals using immunohistochemical and ultrastructural techniques (Gilbert, 1969; 1979; Perry *et al.*, 1978; Mayerhofer and Fritz, 2002). Gilbert (1979) reported that the ovary of the domestic fowl receives both cholinergic and adrenergic nerve fibres. In birds, these nerve fibres occur within the *tunica media* of blood vessels, as well as between interstitial gland cells (Perry *et al.*, 1978). Similar observations have also been reported in the ovaries of mammals (Stefenson *et al.*, 1981; Lakomy *et al.*, 1983; and Sporrang *et al.*, 1985).

It is a well-established fact that ovarian nerves are sympathetic in nature (Stjernquist, 1996). Catecholamines and acetylcholines, which are the possible neurotransmitters, have been reported to control a variety of cellular functions within the ovary, including mitosis, differentiation and secretion (Fritz *et al.*, 2001; Kornya *et al.*, 2001; Bodis *et al.*, 1993; 2002). Furthermore, a report by Gilbert (1979) in the domestic fowl has shown a high density of nerve fibres in the wall of mature follicles, thus suggesting that the innervation plays a role in follicular growth.

Despite the fact that the innervation of any autonomous organ is an essential factor in controlling its growth and function, no information is available on the

distribution of nerve fibres in the ovary of the sexually immature ostrich. Therefore, in this Chapter the distribution of nerve fibres in the ovary of the sexually immature ostrich was investigated using antibodies against neurofilament protein (NP), protein gene product 9.5 (PGP 9.5) and neuron specific enolase (NSE).

6.2 *Materials and methods*

A total of 26 sexually immature female ostriches were used in the present study. The birds were aged between 12 and 14 months, with bodyweights of 90 – 100 kg. Fourteen of the birds, which had active ovaries, were sampled between December and February, a period of long daylight. The other twelve birds, which contained predominantly atretic follicles, were sampled in May and June.

At a commercial ostrich abattoir in South Africa, the ostriches were electrically stunned and exsanguinated. Ovarian tissue samples were obtained from the birds 10 -15 minutes after slaughter. The tissue samples were then immersion-fixed in either 4% paraformaldehyde (pH 7.2) or Bouin's fluid for 12 hours. Some of the samples were fixed in Bouin's fluid due to the fact that the antibody against PGP 9.5 is only suitable for paraffin sections.

The samples fixed in paraformaldehyde were then placed, for 24 hours at 4°C, in a 30% sucrose solution made up in 0.01 phosphate buffered saline solution 1⁻¹ (PBS, pH 7.4). Thereafter, the tissue samples were snap-frozen in OCT compound (Sakura, CA, USA) in an isopentane slurry. The samples were then

stored at -80°C. Tissue samples fixed in Bouin's fluid were processed routinely for histology and embedded in paraffin wax.

The immunostaining technique was performed on 10µm-thick cryostat sections and 5µm-thick paraffin sections, using a LSAB-plus kit (Dakocytomation, Denmark). The cryostat sections were air-dried for 60 minutes at room temperature after which they were rinsed in PBS. Endogenous peroxidase activity in both cryostat and paraffin sections was blocked, using a 3% (v/v) hydrogen peroxide solution in water for 5 minutes. Thereafter, the paraffin sections were microwaved at 750 W for two cycles of 7 minutes each. After being allowed to cool for 20 minutes the sections were rinsed with PBS. The paraffin sections were then incubated for 60 minutes at room temperature with a polyclonal antibody against PGP 9.5, at a dilution of 1:50. The cryostat sections were incubated for 30 minutes with monoclonal antibodies against NP, at a dilution of 1:25, and a ready-to-use solution of antibodies against NSE, for 60 minutes. After this incubation all slides were rinsed with PBS and then incubated for 15 minutes with a biotinylated secondary antibody (LSAB-plus kit, Dakocytomation, Denmark). Thereafter, the slides were rinsed in PBS and subsequently incubated for 15 min with the streptavidin peroxidase component of the LSAB-plus kit. Slides were then rinsed in PBS and bound antibody was visualized after the addition of a 3,3' -diaminobenzidine tetrachloride solution (LSAB-plus kit, Dakocytomation, Denmark). Slides were counterstained with Mayer's haematoxylin for 20 seconds before being dehydrated in graded concentrations of ethanol.

In the negative controls the primary antibodies were replaced with either normal mouse or rabbit serum. An histological section of nerve was used as a positive control. No background staining was detected in the negative control sections, whilst nerve fibres immunoreactive for PGP 9.5, NP and NSE were observed in the positive control sections.

6.3 Results

A subjective assessment of the density and distribution of immunoreactive nerves (Bae *et al.*, 2001a,b) in the ovary was performed under the x 40 objective of the light microscope and was graded semiquantitatively as: - = no nerve fibres observed; \pm = very few nerve fibres observed; + = a small number of nerve fibres observed; ++ = a moderate number of nerve fibres observed and +++ = a large number of nerve fibres observed. The relative density of immunoreactive nerves is summarized in Tables 6.1 and 6.2.

6.3.1 Neurofilament protein (NP)

Strong immunostaining for NP was observed in nerve bundles throughout the ovary. The nerves bundles originated from the ovarian stalk and extended through the medulla to the ovarian cortex. Numerous nerve bundles were seen in the ovarian stalk (fig. 6.1) and medulla (fig. 6.2). Some of these nerve bundles were associated with blood vessels (fig. 6.3). In contrast to the high nerve density in the ovarian stalk and medulla, fewer nerve bundles were observed in the cortex. Nerve bundles in the cortex branched into nerve fibres, which in previtellogenic follicles, appeared to terminate in the theca interna (fig. 6.4). In addition, a few nerve fibres were observed below the germinal

epithelium, as well as in close association with interstitial gland cells (fig. 6.5). In healthy vitellogenic follicles, NP immunoreactive nerve fibres appeared to terminate in theca externa. No nerve fibres immunoreactive for neurofilament protein, were observed in the theca interna layer of healthy vitellogenic follicles (fig. 6.6). However, in atretic vitellogenic follicles, a few nerve fibres were seen in the hyalinized thecal layer (fig. 6.7 & 6.8).

6.3.2 Neuron specific enolase (NSE)

Immunostaining for NSE was observed in neuron cell bodies, nerve bundles, as well as in interstitial gland cells. NSE immunoreactive neuron cell bodies were identified in the medulla and the ovarian stalk. These nerve cell bodies were generally distributed singly. Furthermore, in some cases the nerve cell bodies were incorporated into nerve bundles (fig. 6.9). The nerve cell bodies were characterized by the presence of a large, round nucleus with a prominent nucleolus. In addition, strong NSE immunostaining was evident in the cytoplasm (fig. 6.10).

Strong NSE immunoreactivity was seen in nerve bundles, which coursed from the ovarian stalk into the medulla. In a similar manner to the NP immunoreactive nerve bundles, nerve bundles displaying immunoreactivity to NSE were most numerous in the ovarian stalk and medulla. In contrast, a few immunoreactive nerve fibres were observed in the cortex. NSE immunoreactive nerve fibres were demonstrated in the thecal layer of previtellogenic and vitellogenic follicles. However, no nerve fibres were observed in the granulosa cell layer.

Several NSE immunoreactive nerve fibres were associated with interstitial gland cells. In addition, strong NSE immunostaining was observed in the cytoplasm of interstitial gland cells, as well as in differentiated thecal gland cells which were associated with previtellogenic follicles (fig. 6.11). Few NSE immunopositive thecal gland cells were observed in vitellogenic follicles (fig. 6.12). In contrast to healthy follicles, interstitial gland cells in atretic follicles showed weak to moderate immunostaining for NSE.

6.3.3 Protein gene product 9.5 (PGP 9.5)

In all the tissue samples studied, strong immunoreactivity for PGP 9.5 was observed in nerve bundles, interstitial gland cells, as well as in endothelial cells (fig. 6.13). In addition, weak non-specific PGP 9.5 immunoreactivity was observed in the granulosa cells and ooplasm of ovarian follicles. Numerous nerve bundles, which were immunopositive for PGP 9.5, were concentrated in the medulla (fig. 6.14), with fewer nerve bundles observed in the cortex. Some of the nerve bundles within the medulla were associated with blood vessels (fig. 6.15). Numerous immunostained nerve fibres were observed in the thecal layer of previtellogenic follicles (fig. 6.16). A few PGP 9.5 immunoreactive nerve fibres were observed in close association with stromal interstitial gland cells. In addition, in atretic follicles, weak to moderate PGP 9.5 immunoreactivity was seen in interstitial glands cells of granulosa and thecal origin.

Table 6.1.

Summary of the relative density and distribution of nerve fibres immunoreactive for neurofilament protein, neuron specific enolase and protein gene product 9.5 in the active ovary of the sexually immature ostrich.

Ovarian section	Neurofilament protein	Neuron specific enolase	Protein gene product
Ovarian stalk	+++	+++	+++
Medulla	+++	+++	+++
Cortical stroma	++	++	++
Primordial follicles			
Granulosa cell layer	-	-	-
Connective tissue layer	+	+	+
Early previtellogenic follicles			
Granulosa cell layer	-	-	-
Thecal layer	+	++	++
Connective tissue layer	++	++	++
Late previtellogenic follicles			
Granulosa cell layer	-	-	-
Theca interna	±	+	++
Theca externa	+	++	++
Connective tissue layer	++	+++	++
Vitellogenic follicle			
Granulosa cell layer	-	-	-
Theca interna	-	+	+
Theca externa	+	++	++
Connective tissue layer	++	+++	+++

Table 6.2.

Summary of the relative density and distribution of nerve fibres immunoreactive for neurofilament protein, neuron specific enolase and protein gene product 9.5 in the regressive ovary of the sexually immature ostrich.

Ovarian section	Neurofilament protein	Neuron specific enolase	Protein gene product
-----------------	-----------------------	-------------------------	----------------------

Ovarian stalk	+++	+++	+++
Medulla	+++	+++	+++
Cortical stroma	++	++	++
Atretic primordial follicles			
Granulosa cell layer	-	-	-
Connective tissue layer	+	+	+
Atretic early previtellogenic follicles			
Granulosa cell layer	-	-	-
Thecal layer	+	++	++
Connective tissue layer	++	++	++
Atretic late previtellogenic follicles			
Granulosa cell layer	-	-	-
Theca interna	±	+	±
Theca externa	+	++	+
Connective tissue layer	++	+++	++
Atretic vitellogenic follicle			
Granulosa cell layer	-	-	-
Theca interna	++	+	+
Theca externa (hyalinized)	+	++	++
Connective tissue layer	++	+++	+++

6. 4 Discussion

The present study has demonstrated immunoreactivity to NP, PGP 9.5 and NSE in the ovary of the sexually immature ostrich. The use of these neuronal markers in the current study has clearly exhibited the intrinsic innervation of the ovary in the immature ostrich. Based on the results of this study it is evident that the distribution pattern of these neuronal markers in the ovary of the ostrich is similar, but not identical. This could be attributed to the specific nature of protein immunoreactivity. As reported by Ohara *et al.*, (1993), NP is expressed specifically in neurons. In contrast, PGP 9.5, as well as NSE are cytoplasmic

markers of both neuronal and neuroendocrine cells (Thompson *et al.*, 1981). Although nerve fibres in the ovary have been reported to be cholinergic and/ or adrenergic in nature (Stefenson *et al.*, 1981; Unsicker *et al.*, 1983; Kannisto *et al.*, 1984; Sporrang *et al.*, 1985) the neuronal markers utilized in the present study did not differentiate between the different nerve types. To date no cholinergic or adrenergic markers have been found to label nerves in the ostrich.

In the present study, nerve fibres and bundles immunoreactive for NP, NSE and PGP 9.5 were distributed in the ovarian stalk, medulla, cortex and follicular layers. In addition, the density of nerve fibres was higher in medulla and ovarian stalk. A similar observation was made in the domestic fowl in which nerve fibres were more concentrated in the medulla and ovarian stalk (Gilbert, 1968; 1969).

In the immature ostrich nerve fibres immunoreactive for NP, NSE and PGP 9.5 were closely associated with blood vessels and interstitial gland cells. This finding correlates well with reports by Dahl (1970), as well as Amanuma and Yamada (1979), which described the innervation of interstitial gland cells in the domestic fowl. In addition, Avila *et al.* (1991) has shown the close association between interstitial gland cells and nerve endings in the 11-day old chick embryo. Such an extensive nerve supply to the interstitial gland cells suggests that innervation has a regulatory role in hormonal secretion from the interstitial gland cells. Furthermore, the rate of hormonal supply to the ovary through blood vessels might be controlled by nerve fibres innervating the blood vessels in the ovary.

Neurofilaments are a type of intermediate filament that constitutes a major element of the axon cytoskeleton. A report by Weber *et al.* (1983) shows that neurofilaments occur in triplet proteins which include NF-L (68/70 kD), NF-M (160 kD) and NF-H (200kD). In the current study NF-M was used. The presence of NF-M in the ovary of the sexually immature ostrich is in agreement with the research findings in the ovary of rat (D'Albora *et al.*, 2000) and human (Anesetti *et al.*, 2001). In these species, immunoreactive nerve fibers were observed in the ovarian medulla and cortex.

Based on the results of the current study it is clear that neuron specific enolase is an excellent marker of neuronal and endocrine structures in the ovary of the immature ostrich. *Alpha*, *beta* and *gamma* forms of NSE occur in mammalian tissue (Schmechel *et al.*, 1978; Jackson *et al.*, 1985). The *Alpha* form has been localized in the liver, whereas the *beta* form is found in skeletal muscle (Marangos *et al.*, 1978). The *gamma* form, which was previously known as 14-3-2 neurone specific protein, is normally demonstrated in neurons and cells of the neuroendocrine system. Ovarian follicles contain various cell types, which demonstrate marked differences in NSE immunostaining. In the present study, thecal gland cells, in both healthy and atretic follicles, were immunopositive for NSE, but not for NP or PGP 9.5. NSE immunoreactivity in the thecal gland cells suggests that these gland cells are steroidocompetent even in the sexually immature ostrich. The ability of NSE to label hormone-secreting cells has been reported by Schmechel *et al.* (1978) who demonstrated NSE immunoreactivity in cells of the neuroendocrine system. Further immunohistochemical studies need to be carried out on the thecal gland cells of the ostrich to ascertain their exact function.

As shown in the results, NSE immunoreactive neuron cell bodies were identified in the medulla and the ovarian stalk. This is in agreement with research conducted on the domestic fowl in which upto 100 nerve cell bodies were reported in the ovarian stalk (Gilbert, 1969). However, contrary to the observations of the present study, no nerve cell bodies were present in the medulla in the domestic fowl. In the present study nerve cell bodies, which were generally distributed singly, were in some cases observed in nerve bundles. In the domestic fowl, numerous nerve cells were observed in association with blood vessels and smooth muscle cells rather than with nerve bundles.

In addition to domestic fowl, neuronal cell bodies have been reported in the ovary of the human (Anesetti *et al.*, 2001), the rat (D'Albora and Barcia, 1996) and the monkey (Dess *et al.*, 1995). In the rat ovary, neuron cell bodies were detected in the rat strains which had a long reproductive life span (D'Albora and Barcia, 1996). It was assumed that neuron cell bodies play an important role in the regulation of ovarian function.

The greatest concentration of the neuron-specific cytoplasmic marker, protein gene product 9.5, has been shown to be in the central nervous system (Doran *et al.*, 1983). The presence of this protein in the ovary of the sexually immature ostrich is not surprising, as PGP 9.5 protein has also been found to be expressed in the ova, theca interna and theca externa of the human, the rat and the guinea pig (Wilson *et al.*, 1988). At the moment the function of this protein is not well stated, however it would appear that PGP 9.5 protein could serve as a marker in studies on ovarian innervation. In addition, the immunolocalization of

this protein is increasingly becoming an important diagnostic method for different forms of tumours including carcinoids (Rode *et al.*, 1985)

In conclusion, the current study has highlighted the distribution of nerve fibres in the ovary of the sexually immature ostrich. This immunohistochemical study appears to be the first report on the intrinsic innervation of the ovary in the ostrich. Based on the results of studies on the innervation of the avian ovary, which have been carried out using light microscopy, electron microscopy, as well as histofluorescence (Gilbert, 1968; 1969; Dahl, 1970; Amanuma and Yamada, 1979; Muller-Marschhausen, *et al.*, 1988), it would appear that the distribution of nerve fibres in the sexually immature ostrich resembles that of the domestic fowl.

6.5 References

- AMANUMA, A. & YAMADA, K. 1979. Innervation of the ovarian interstitial cell of the chick embryo. *Experimentia*, 35:403-404.
- ANESETTI, G., LOMBIDE, P., D'ALBORA, H. & OJEDA, S.R. 2001. Intrinsic neurons in the human ovary. *Cell Tissue Research*, 306:231-237.
- AVILA, R.E., SAMAR, M.E. & DE FABRO, S.P. 1991. Interstitial cells of the ovaries of the chick embryo: ultrastructural aspects of their innervation. *Revista de la Facultad de Ciencias Medicas de la Universidad Nacional de Cordoba*, 49:13-17.

- BAE, S.-E., CORCORAN, B.M. & WATSON, E.D. 2001a. Organisation of uterine innervation in the mare: distribution of immunoreactivities for the general neuronal markers protein gene product 9.5 and PAN-N. *Equine Veterinary Journal*, 33:323-325.
- BAE, S.-E. CORCORAN, B.M. & WATSON, E.D. 2001b. Immunohistochemical study of the distribution of adrenergic and peptidergic innervation in the equine uterus and cervix. *Reproduction*, 122:275-282.
- BODIS, J., TINNEBERG, H.R., TOROK, A., CLEDON, P., HANF, V. & PAPENFUSS, F. 1993. Effect of noradrenaline and dopamine on progesterone and estradiol secretion of human granulosa cells. *Acta Endocrinologica (Copenhagen)*, 129:165-168.
- BODIS, J., KOPPAN, M., KORNIA, L., TINNEBERG, H.R. & TOROK, A. 2002. The effect of catecholamines, acetylcholine and histamine on progesterone release by human granulosa cells in a granulosa cell superfusion system. *Gynecologic Endocrinology*, 16:259-264.
- DAHL, E. 1970. Studies of the fine structure of ovarian interstitial tissue. 3. The innervation of the thecal gland of the domestic fowl. *Zeitschrift fur Zellforschung*, 109:212-226.
- D'ALBORA, H. & BARCIA, J.J. 1996. Intrinsic neuronal cell bodies in the rat ovary. *Neuroscience Letters*, 205:65-67.

- D'ALBORA, H., LOMBIDE, P. & OJEDA, S.R. 2000. Intrinsic neurons in the rat ovary: an immunohistochemical study. *Cell Tissue Research*, 300:47-56.
- DEES, W.L., HINEY, J.K., SCHULTEA, T.D., MAYERHOFER, A., DANILCHIK, M., DISSEN, G.A. & OJEDA, S.R. 1995. The primate ovary contains a population of catecholaminergic neuron-like cells expressing nerve growth factor receptors. *Endocrinology*, 136:5760-5768.
- DORAN, J.F., JACKSON, P., KYNOCH, P.A.M. & THOMPSON, R.J. 1983. Isolation of PGP 9.5, a new human neurone-specific protein detected by high-resolution two-dimensional electrophoresis. *Journal of Neurochemistry*, 40:1542-1547.
- FRITZ, S., WESSLER, I., BREITLING, R., ROSSMANITH, W., OJEDA, S.R., DISSEN, G.A., AMSTERDAM, A. & MAYERHOFER, A. 2001. Expression of muscarinic receptor types in the primate ovary and evidence for nonneuronal acetylcholine synthesis. *Journal of Clinical Endocrinology and Metabolism*, 86:349-354.
- GILBERT, A.B. 1968. Innervation of the avian ovary, in: *Proceedings of the Physiological Society, Royal Veterinary College meeting*. Pp. 4p-5p.
- GILBERT, A.B. 1969. Innervation of the ovary of the domestic hen. *Quarterly Journal of Experimental Physiology*, 54:404-411.

- GILBERT, A.B. 1979. Female genital organs, in: *Form and Function in Birds*, Vol. 1, edited by A. S. King & J. McLelland. London: Academic Press. Pp. 237-360.
- JACKSON, P., THOMSON, V.M. & THOMPSON, R.J. 1985. A comparison of the evolutionary distribution of the two neuroendocrine markers, neuron-specific enolase and protein gene product 9.5. *Journal of Neurochemistry*, 45:185-190.
- KANNISTO, P., OWMAN, C., ROSENGREN, E. & WALLEES, B. 1984. Intraovarian adrenergic nerves in the guinea-pig: development from fetal life to sexual maturity. *Cell Tissue Research*, 238:235-240.
- KORNYA, L., BODIS, J., KOPPAN, M., TINNEBERG, H.R. & TOROK, A. 2001. Modulatory effect of acetylcholine on gonadotropin-stimulated human granulosa cell steroid secretion. *Gynecologic and Obstetrics Investigation*, 52:104-107.
- LAKOMY, M., DOBOSZYNSKA, T. & SZTEYN, S. 1983. Adrenergic nerves in organs of the reproductive system of sexually immature pigs. *Anatomischer Anzeiger*, 154:149-159.
- MARANGOS, P.J., ZIS, A.P., CLARK, R.L. & GOODWIN, F.K. 1978. Neuronal, non-neuronal and hybrid forms of enolase in brain: structural, immunological and functional comparisons. *Brain Research*, 150:117-133.

- MAYERHOFER, A. & FRITZ, S. 2002. Ovarian acetylcholine and muscarinic receptors: hints of a novel intrinsic ovarian regulatory system. *Microscopy Research and Technique*, 59:503-508.
- MULLER-MARSCHHAUSEN, U., GROTHE, C., KAVERI, S., STROBERG, A.D., VERHOFSTAD, A.A. & UNSICKER, K. 1988. Catecholaminergic nerves in the embryonic chick ovary: co-localization with beta 2-adrenoceptor-bearing steroidogenic cells. *Cell Tissue Research*, 254: 1-9.
- OHARA, O., GAHARA, Y., MIYAKE, T., TERAOKA, H. & KITAMURA, T. 1993. Neurofilament deficiency in quail caused by nonsense mutation in neurofilament-L gene. *Journal of Cell Biology*, 121:387-395.
- PERRY, M.M., GILBERT, A.B. & EVANS, A.J. 1978. Electron microscope observations on the ovarian follicle of the domestic fowl during the rapid growth phase. *Journal of Anatomy*, 125:481-497.
- RODE, J., DHILLON, A.P., DORAN, J.F., JACKSON, P. & THOMPSON, R.J. 1985. PGP 9.5, a new marker for human neuroendocrine tumors. *Histopathology*, 9:147-158.
- SCHMECHEL, D., MARANGOS, P.J. & BRIGHTMAN, M. 1978. Neuron-specific enolase is a molecular marker for peripheral and central neuroendocrine cells. *Nature*, 276:834-836.

SPORRONG, B., KANNISTO, P., OWMAN, C., SJOBERG, N.-O. & WALLEES, B. 1985. Histochemistry and ultrastructure of adrenergic and acetylcholinesterase-containing nerves supplying follicles and endocrine cells in the guinea-pig ovary. *Cell Tissue Research*, 240:505-511.

STEFENSON, A., OWMAN, C., SJOBERG, N.-O., SPORRONG, B. & WALLEES, B. 1981. Comparative study of the autonomic innervation of the mammalian ovary, with particular regard to the follicular system. *Cell Tissue Research*, 215:47-62.

STJERNQUIST, M. 1996. Innervation of ovarian and testicular cells, in: *Autonomic-endocrine interactions*, edited by K. Unsicker. Amsterdam: Harwood. Pp. 231-256.

THOMPSON, R.J., KYNOCH, P.A.M. & SARJANT, J. 1981. Immunohistochemical localization of creatine kinase-BB isoenzyme to astrocytes in human brain. *Brain Research*, 201:423-426.

UNSICKER, K., SEIDEL, F., HOFMANN, H.D., MULLER, T.H., SCHMIDT, R. & WILSON, A. 1983. Catecholaminergic innervation of the chicken ovary. With special reference to the follicular wall. *Cell Tissue Research*, 230:431-450.

WEBER, K., SHAW, G., OSBORN, M., DEBUS, E. & GEISLER, N. 1983. Neurofilaments, a subclass of intermediated filaments; structure and expression. *Cold Spring Harbour Symposium on Quantitative Biology*, 47:717-729.

WILSON, P.O.G., BARBER, P.C., HAMID, Q.A., POWER, B.F., DHILLON, A.P.,
RODE, J., DAYS, I.N.M., THOMPSON, R.J. & POLAK, J.M. 1988. The
immunolocalization of protein gene product 9.5 using rabbit polyclonal and
mouse monoclonal antibodies. *British Journal of Experimental Pathology*,
69:91-104.

6.5 List of figures

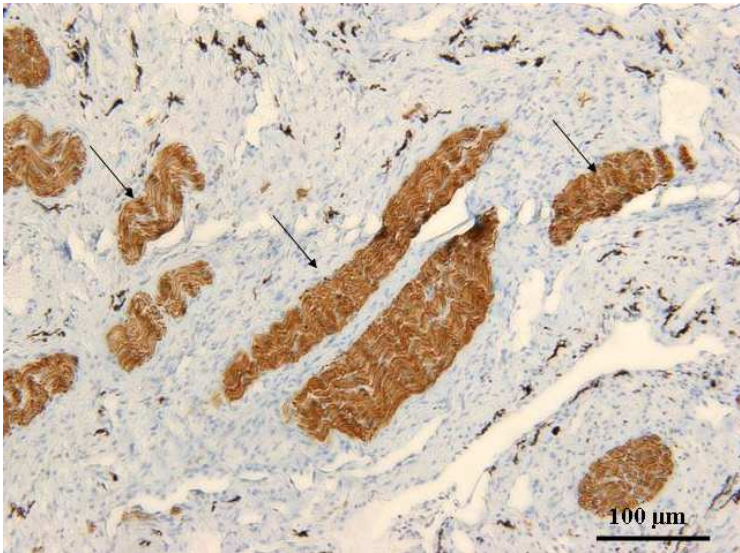


Fig. 6.1. Neurofilament protein immunoreactive nerve bundles (arrows) in the ovarian stalk.

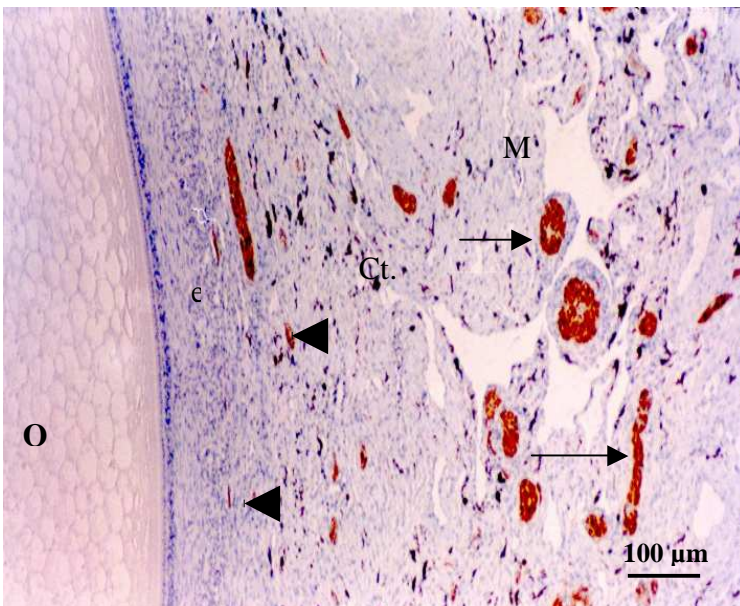


Fig. 6.2. Numerous nerve bundles (arrows) in the medulla (M) of the ovary. Note that only a few nerve fibres (arrow heads) are observed in the connective tissue layer (Ct.) and theca externa (e) of the adjacent ovarian follicle. O: oocyte

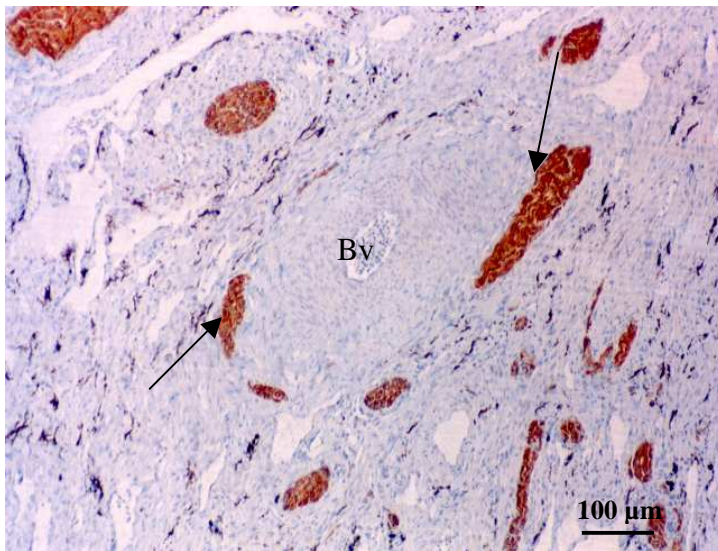


Fig. 6.3. Neurofilament protein immunoreactive nerve bundles (arrows) were occasionally associated with blood vessels (Bv) in the medulla region of the ovary.

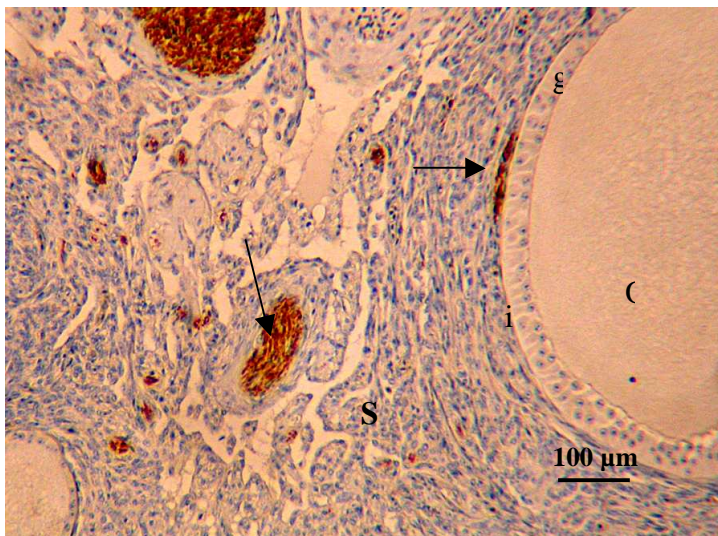


Fig. 6.4. Healthy previtellogenic follicle. Neurofilament protein immunoreactive nerve fibres (arrows) are observed in the theca interna (i) and cortical stroma (S). g: granulosa cell layer. O: Oocyte.

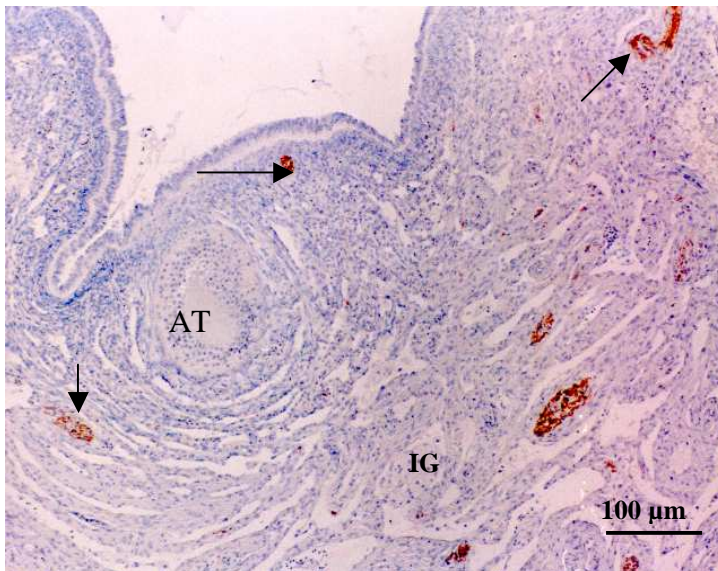


Fig. 6.5. Distribution of neurofilament protein immunoreactive nerve fibres (arrows) in the cortex of the ovary. Nerve fibres are seen in the vicinity of interstitial glands (IG). AT: atretic previtellogenic follicle.

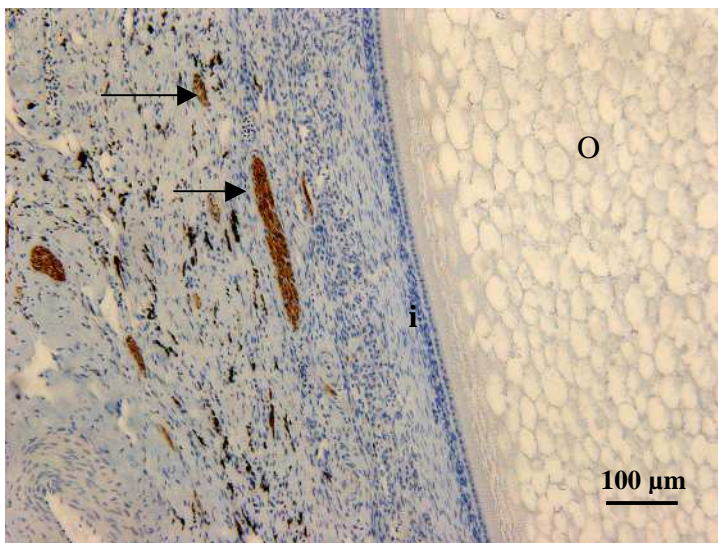


Fig. 6.6. Portion of a vitellogenic follicle showing neurofilament protein immunoreactive nerve fibres (arrows) in the connective tissue layer. No nerve fibres were observed in the theca interna (i). O: oocyte

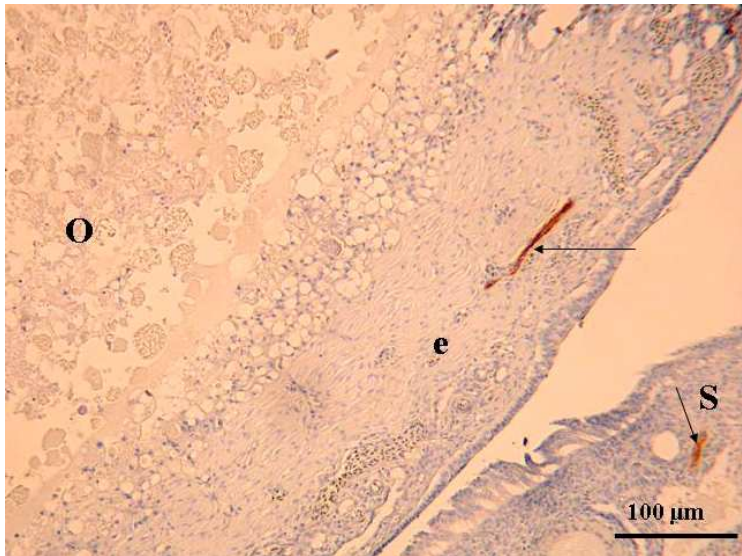


Fig. 6.7. Type 1 atretic vitellogenic follicle (left) and a portion of the cortex (right). Nerve fibres (arrows) are observed in the hyalinized theca externa (e), as well as, in the cortical stroma (S). O: oocyte

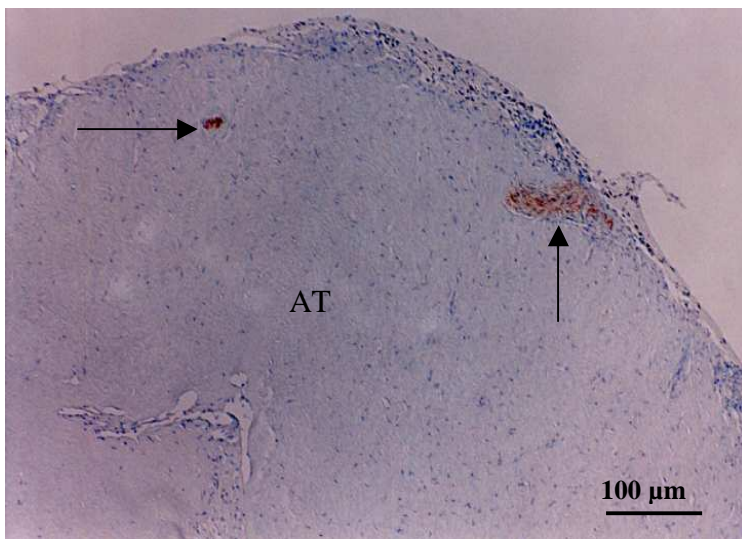


Fig. 6.8. Type 1 atretic vitellogenic follicle. Nerve fibres (arrows) are observed within the hyalinized connective tissue mass (AT).

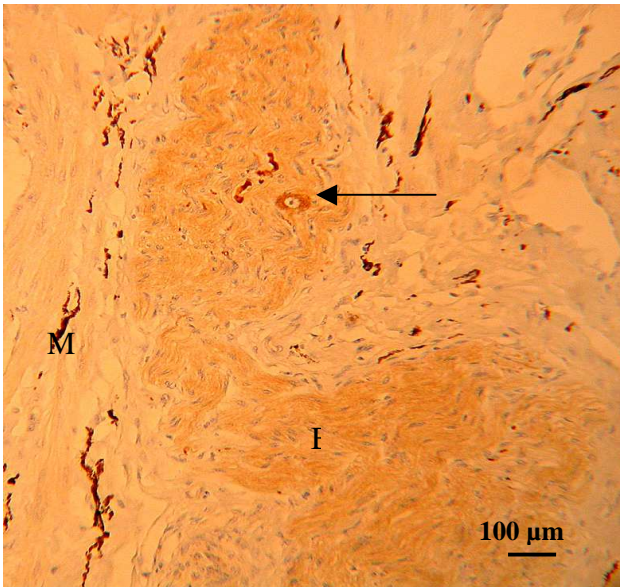


Fig. 6.9. Large NSE-immunoreactive nerve bundle (B) in the medulla (M). A nerve cell body (arrow) is observed within the nerve bundle (B).

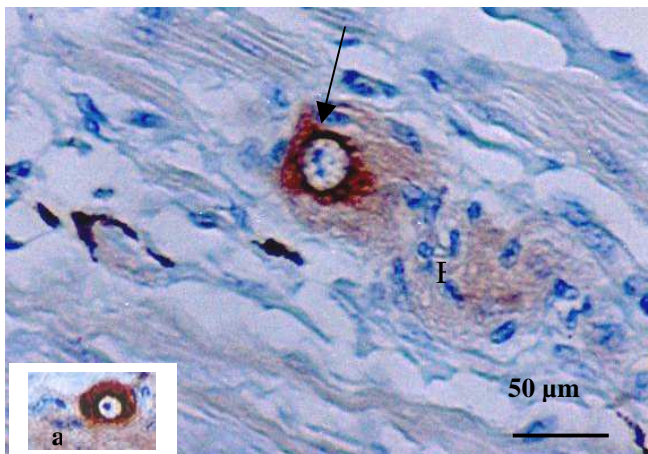


Fig. 6.10. A solitary nerve cell body in the medulla. NSE immunoreactivity is observed in the cytoplasm of the nerve cell body (arrow), as well as in the nerve bundle (B). The insert (a) shows a neuron cell body with a prominent nucleolus.

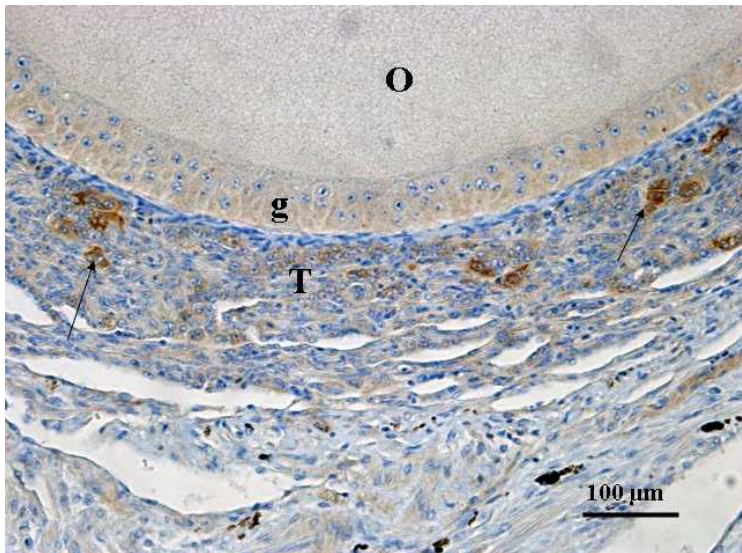


Fig. 6.11. Portion of a late previtellogenic follicle. Immunostaining for NSE is observed in differentiated thecal gland cells (arrows). O: oocyte. g: granulosa cell layer. T: thecal layer.

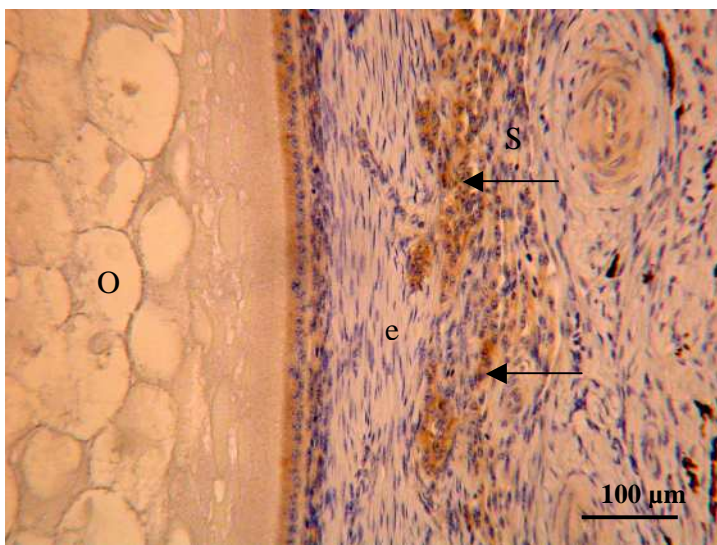


Fig. 6.12. Portion of a vitellogenic follicle demonstrating NSE immunoreactive thecal gland cells (arrows) in the stroma (S). In this follicular size, the theca externa (e) contains very few NSE immunopositive thecal gland cells. O: oocyte.

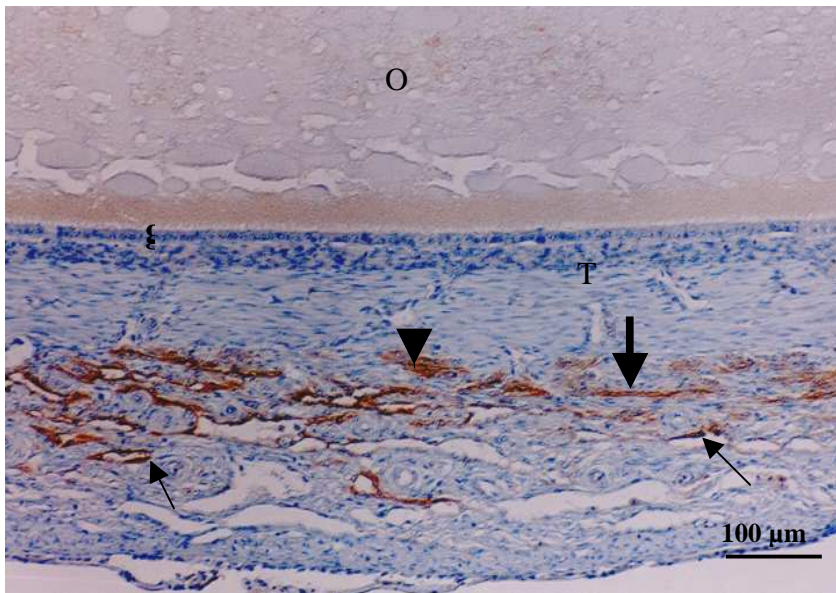


Fig. 6.13. A portion of the cortex showing PGP 9.5 immunoreactivity in endothelial cells (arrows) and gland cells (arrow head). A few immunoreactive nerve fibres (thick arrow) are evident in the thecal layer (T). g: granulosa cell layer. O: oocyte.

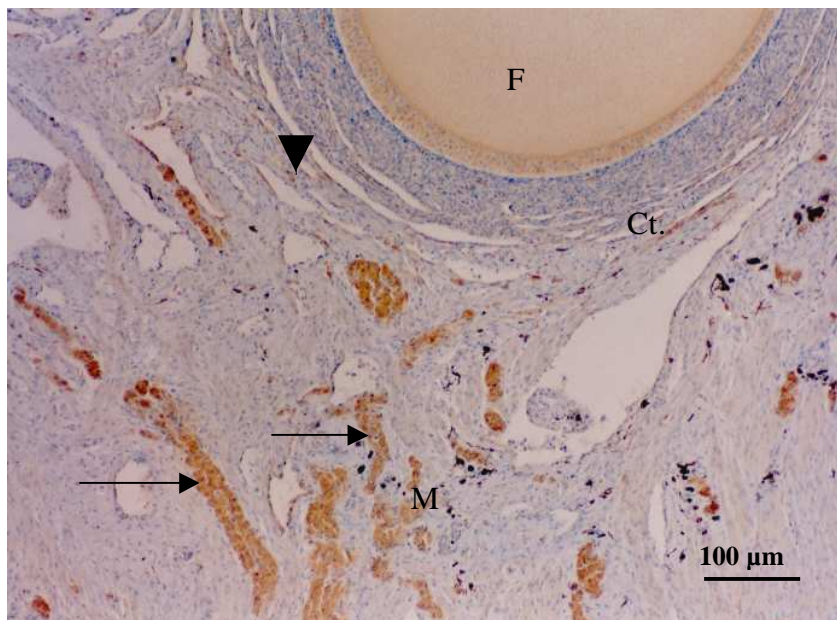


Fig. 6.14. Large PGP 9.5 immunoreactive nerve bundles (arrows), which originated from ovarian stalk are observed in medulla (M). Nerve fibres (arrow head) are evident in the connective tissue layer (Ct) adjacent to the follicle (F).

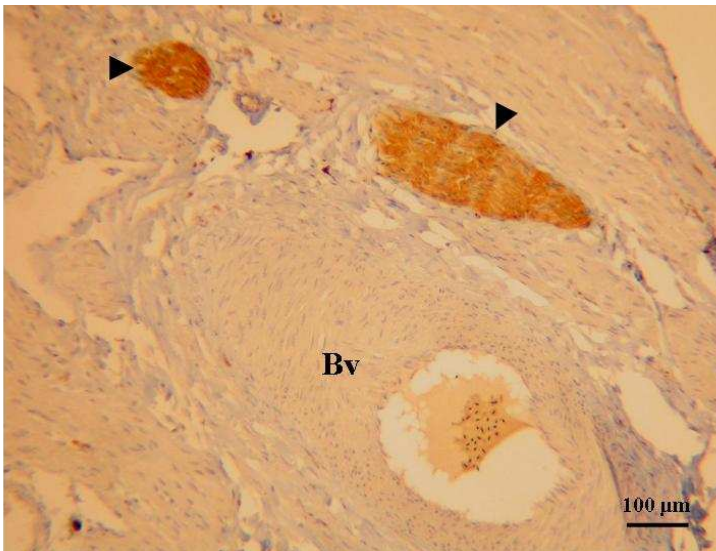


Fig. 6.15. PGP 9.5 immunoreactive nerve bundle (arrow heads) associated with a blood vessel (Bv) in the medulla.

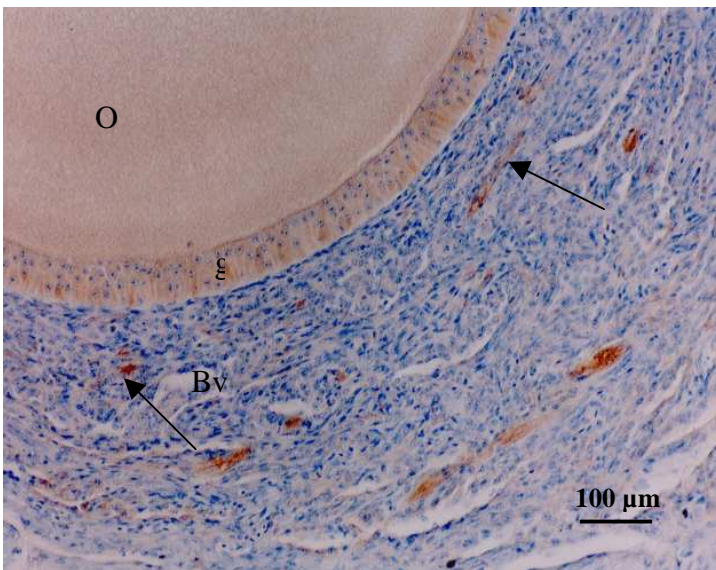


Fig. 6.16. A portion of the wall of a late previtellogenic follicle. Numerous PGP 9.5 immunopositive nerve fibres (arrows) are observed in the thecal layer. Non-specific immunostaining is also observed in the granulosa cells (g) and oocyte (O). Bv: blood vessel.

Appendix I

Manuscripts accepted for publication

Madekurozwa, M-C. and Kimaro, W.H. "A morphological and immunohistochemical study of the ovary of the sexually immature ostrich, *Struthio camelus*". Anatomia Embryologia Histologia, *Journal of Veterinary Medicine series C. In press.*

Appendix II

II.a. Local conferences

II.a.i. W.H. Kimaro and M-C. Madekurozwa (2004). Distribution of intermediate filament proteins in healthy and atretic ovarian follicles in the immature ostrich, *Struthio camelus*. Microscopic Society of Southern Africa, December, 2004.

II.a.ii. W.H. Kimaro and M-C. Madekurozwa: An immunohistochemical study of the innervation of the ovary in the sexually immature ostrich. Microscopic Society of Southern Africa, December, 2005.

II.a.iii. W.H. Kimaro and M-C. Madekurozwa: Ultrastructural features of healthy and atretic ovarian follicles in the sexually immature ostrich. Microscopic Society of Southern Africa, December, 2005.

II.a.iv. W.H. Kimaro and M-C. Madekurozwa: The ultrastructure of gland cells in the ovary of the sexually immature ostrich. Microscopic Society of Southern Africa, December, 2005.

II.b. International conferences

II.b.i. M-C. Madekurozwa and W.H. Kimaro (2005). A morphological and immunohistochemical study of developing and atretic follicles in the ovary of the sexually immature ostrich, *Struthio camelus*. 3rd International Ratite Science Symposium. Madrid, Spain, October 2005.

II.b.ii. W.H. Kimaro and M-C. Madekurozwa: Immunoreactivity of protein gene product 9.5, neurofilament protein and neuron specific enolase in the ovary of the sexually immature ostrich (*struthio camelus*). International Neuroscience Conference, Al Ain, United Arab Emirates, November, 2005.