

**The detection of lumpy skin disease virus in samples of experimentally infected cattle using different diagnostic techniques**



**Eeva S.M. Tuppurainen**

**The detection of lumpy skin disease virus in samples of  
experimentally infected cattle using different diagnostic  
techniques**

**by**

**Eeva S.M. Tuppurainen**

**Submitted in partial fulfilment of the requirements**

**for the degree of**

**Magister of Scientiae (Veterinary Sciences)**

**in the**

**Department of Veterinary Tropical Diseases**

**Faculty of Veterinary Science**

**University of Pretoria**

**August 2004**

## DECLARATION

I declare that this dissertation is my own work. It has been submitted for the Degree Magister of Scientiae (Veterinary Sciences) at the University of Pretoria. It has not been submitted before for any degree or examination in any other university.

I further declare that the work presented was approved by the Animal Use and Care Committee for research of the University of Pretoria, South Africa.

---

Signature of candidate

Day of 2004/ /

## **ACKNOWLEDGEMENTS**

I would like to express my sincere gratitude to the following people and institutions:

Prof. E.H. Venter, Department of Veterinary Tropical Diseases, supervisor of this project, for the guidance, support and encouragement throughout this research period. Thank you for your warm and caring friendship!

Prof. J.A.W. Coetzer, Head of the Department of Veterinary Tropical Diseases, co-supervisor of this project, for assistance in histopathology and in the interpretation of the results of immunoperoxidase staining of tissue sections, as well as for his determination, persistence and constructive criticism of the thesis.

Prof. P.G. Howell, for his valuable advice and constant support during this project.

Dr P. Irons, for co-operation and collection of the semen samples.

Prof. R.C. Tustin, for editing the thesis.

Ms A-M. Bosman, for assistance in molecular biology.

Ms D. Nel and Ms A. Durand, for assistance in serology.

The personnel of the Department of Anatomy and Physiology, Electron Microscopy Unit for assistance in transmission electron microscopy examination of skin lesions.

The personnel of the Department of Paraclinical Sciences, Section of Pathology for assistance in processing skin biopsies for histopathological examination and in immunoperoxidase staining of tissue sections.

The personnel of the Department of Veterinary Tropical Diseases for being so wonderful and kind to me.

My family and parents for love, patience and support. I couldn't have done this without you!

Finally, I would like to thank the following institutes for financially supporting the study: Research and Science Foundation of Farnos Finland, Finnish Veterinary Foundation and Department of Veterinary Tropical Diseases, Faculty of Veterinary Science, University of Pretoria, and Orion Pharma Finland for donating Domosedan sedative for the project.

## ABSTRACT

Lumpy skin disease (LSD), affecting cattle in Africa, Madagascar and the Middle East, is caused by a capripox virus that belongs to the family *Poxviridae*. The disease is of economical importance in endemic areas and the Office International des Epizooties classifies it as a "List A"- disease.

Effective control of LSD requires accurate and rapid laboratory techniques to confirm a tentative clinical diagnosis. Comparative studies on different diagnostic tests used at different stages of the disease have not been done. The aim of this study was to compare the different tests that are available and to provide data to assist in the selection of a rapid and sensitive laboratory test for the diagnosis of LSD.

Six seronegative, prepubertal bulls were infected via the intravenous route and kept in an insect-free facility. The course of infection was monitored. During a three months' period blood and semen samples were collected for virus isolation and polymerase chain reaction (PCR), and skin biopsies for the PCR, virus isolation, transmission electron microscopy (TEM), histopathological examination and immunoperoxidase staining of tissue sections. Antibody titres were assessed using the serum virus neutralization test (SNT) and indirect immunofluorescence test (IFAT).

The incubation period in infected animals varied from 4 to 5 days. The length of viraemia did not correlate with the severity of clinical disease. By using virus isolation the duration of viraemia was determined to be from 1 to 12 days and by PCR from 4 to 11 days, which is longer than has previously been stated. Virus was isolated from semen until day 43 post-infection (p.i.) whereas the PCR could detect LSD virus nucleic acid until day 161 p.i. Virus was isolated from skin biopsies until day 39 p.i. and PCR could demonstrate viral DNA in them until day 92 p.i.

The PCR was a fast and sensitive method to demonstrate viral DNA in blood, skin and semen samples. It could detect viral nucleic acid for significantly longer periods than any of the conventional methods. Virus isolation from blood, skin and semen samples was sensitive and reliable, but as a single test it may be too time-consuming although this depends how rapidly the diagnosis must be confirmed.

The IFAT can be used for rapid confirmation of a clinical diagnosis but it needs careful standardization due to non-specific staining. The SNT showed positive results later in the course of the clinical disease than IFAT but it was however, sensitive and reliable in detecting antibodies from all the animals in this experiment.

Transmission electron microscopy of skin biopsies detected LSD virus only in one of the four bulls that developed skin lesions. This indicated that even though TEM is usually considered to be a fast and reliable method, a negative result must still be confirmed using another method.

Histopathological changes of the skin lesions in sections stained with haematoxylin and eosin were typical for the disease. It was not possible to make a reliable diagnosis of LSD based only on immunoperoxidase staining of tissue sections.

In conclusion, this study indicated the PCR to be superior in detecting LSD virus from blood, skin and semen samples. However, virus isolation is still required when the infectivity of the LSD virus is to be investigated. Even though the IFAT has been used for several decades, it is still a valuable tool in detecting antibodies against LSD virus. Both the SNT and IFAT are useful and reliable in retrospective, epidemiological studies.

## LIST OF ABBREVIATIONS

AGID	Agar-gel immunodiffusion test
AHS	African horsesickness
AVK 58	Adult vervet monkey kidney cell line
BDC	Bovine dermis cells
BHK	Baby hamster kidney cells
BVD	Bovine viral diarrhoea
CPE	Cytopathic effect
DNA	Deoxiribonucleic acid
dsDNA	Double stranded deoxiribonucleic acid
DVTD	Department of Veterinary Tropical Diseases
EDTA	Ethylenediaminetetraacetic acid
ELISA	Enzyme-linked immunosorbent assay
FAT	Fluorescent antibody test
IFAT	Indirect fluorescent antibody test
IV	Intravenous
IM	Intramuscular
LSD	Lumpy skin disease
MEM	Minimum essential medium
ND	Not done
OIE	Office International des Epizooties
PBS	Phosphate buffered saline
PBS+	Phosphate buffered saline containing Mg <sup>2+</sup> and Ca <sup>2+</sup>
PBS-T	Phosphate buffered saline containing 0,05% Tween 20
PCR	Polymerase chain reaction
p.i.	Post-infection
PTA	Phosphotungstic acid
SGPV	Sheep and goat pox virus
SNT	Serum virus neutralization test
SOP	Standard operative procedure
TCID <sub>50</sub>	Tissue culture infected dose 50
TEM	Transmission electron microscopy
VI	Virus isolation



## TABLE OF CONTENTS

### CHAPTER 1

INTRODUCTION	1
LITERATURE REVIEW	2
History	2
Aetiology	3
Epidemiology	6
Economic importance	9
Clinical signs	9
Diagnosis	11
Differential diagnosis	14
Pathology	15
Immunity	15
Control	18
OBJECTIVES OF THE STUDY	19
OBSERVATIONS MADE IN THE STUDY	19

### CHAPTER 2

MATERIALS AND METHODS	20
Experimental animals	20
Preparation of virus suspension and animal inoculation	20
Clinical observations, sample collection and processing	21
Diagnostic methods	23
<i>Transmission electron microscopy</i>	23
<i>Virus isolation</i>	23
<i>Indirect fluorescent antibody test</i>	25
<i>Serum virus neutralization test</i>	27
<i>Histopathology</i>	28

<i>Polymerase chain reaction</i>	28
----------------------------------	----

### CHAPTER 3

RESULTS	31
Clinical signs	31
Virus isolation	35
<i>Heparinized blood samples</i>	35
<i>Skin biopsies</i>	37
<i>Semen samples</i>	37
Polymerase chain reaction	37
<i>EDTA blood samples</i>	37
<i>Skin biopsies</i>	38
<i>Semen samples</i>	39
Indirect fluorescent antibody test	40
Serum virus neutralization test	41
Transmission electron microscopy	44
Histopathology	45
<i>Haematoxylin and eosin-stained sections</i>	45
<i>Immunoperoxidase staining</i>	45

### CHAPTER 4

DISCUSSION	47
Clinical signs	47
Viraemia	49
Serological results	53
Skin lesions	56
Semen	59

**LIST OF FIGURES**

Figure 1: Temperature reaction in the bulls.....33

Figure 2: Generalized skin lesions.....33

Figure 3: Ulcerative lesions on the muzzle and nostrils.....34

Figure 4: Lesions on the skin of the scrotum.....34

Figure 5: Subcutaneous oedema between the tarsal joint and fetlock of the right hind leg in Bull no. 1.....35

Figure 6: Virus isolations on bovine dermis cell cultures from blood samples collected in heparin.....36

Figure 7: LSD virus isolation from a heparinized blood sample on bovine dermis cell culture showing typical CPE.....36

Figure 8: PCR results from EDTA blood samples .....38

Figure 9: End point IFAT titres of the bulls.....41

Figure 10: Serum virus neutralization titres of the bulls.....43

Figure 11: Comparison of the SNT antibody titres of experimentally infected bulls.....54

**LIST OF TABLES**

Table 1: Genera within the *Poxviridae* family ..... 4

Table 2: Grouping of animals according to the severity of clinical signs .....31

Table 3: Indirect fluorescent test results .....41

Table 4: Transmission electron microscopy results of the skin biopsies of the bulls.....44

Table 5: Temperature reaction related to the development of skin lesions ...48

Table 6: The temperature reaction and the appearance of skin lesions related to virus isolation and PCR results of blood samples. The numbers in brackets indicate the number of positive test results during the time period .....53

Table 7: The appearance of fever and skin lesions related to SNT and IFAT titres .....56

Table 8: Detection of LSD virus / nucleic acid in skin lesions using TEM, VI and PCR. The numbers in brackets indicate the number of positive test results during the time period.....58

Table 9: The PCR and VI results of semen samples compared with the onset of the fever reaction and skin lesions. The numbers in brackets indicate positive test results during the time period .....60

## CHAPTER 1

### INTRODUCTION

Lumpy skin disease (LSD) in cattle is caused by a capripoxvirus. It is characterized by fever, enlarged lymph nodes, firm, circumscribed nodules in the skin and ulcerative lesions particularly of the mucous membrane of the mouth. The disease is of economic importance because of decreased milk yield, weight gain, infertility, and permanent damage to hides.

Lumpy skin disease is an Office International des Epizooties "List A"-disease because of the potential for its rapid spread and ability to cause serious losses. In 1989 the European Economic Co-operation (EEC) / European Union added LSD to the Council Directive 82/894/EEC on the notification of animal diseases within the community, and therefore it must be reported to all other member states and the commission within 24 hours of an outbreak.

Lumpy skin disease may occur in different ecological and climatic zones and has the potential to extend its boundaries (Davies, 1991). It is endemic in most parts of sub-Saharan Africa and Madagascar and has isolated outbreaks in the Middle East.

Vaccination is the only effective method to control the disease in endemic countries. In LSD free countries the rapid confirmation of a clinical diagnosis is essential so that eradication measures, such as quarantine, slaughter-out of affected and in-contact animals and ring vaccinations can be implemented as soon as possible (Carn, 1993).

The aim of this study was to monitor the clinical signs of the bulls infected experimentally with LSD virus and to determine virus persistence in blood, semen and skin lesions using different diagnostic assays.

## LITERATURE REVIEW

### History

A new skin disease of cattle was identified in northern Zambia in 1929. Because the aetiology of the disease was not known it was thought to be caused by either an allergic reaction to insect bites (MacDonald, 1931; Morris, 1931 cited by Weiss, 1968) or a plant poisoning (Le Roux, 1945 cited by Weiss, 1968). At first the disease was referred to as "pseudo-urticaria" or "lumpy disease". In October 1943 another outbreak of the disease occurred in Ngamiland, Bechuanaland Protectorate (Botswana) where it had not previously been described and was provisionally called "Ngamiland cattle disease" (Von Backstrom, 1945).

In 1945 the disease spread to southern Rhodesia (Zimbabwe) (Houston, 1945) and to South Africa where it first appeared in the Transvaal. The disease was named knopvelsiekte or lumpy skin disease (Thomas and Maré, 1945). Thomas and co-workers (1945) were the first to demonstrate the transmission of the infectious agent by the inoculation of cattle with a suspension of skin nodules.

Lumpy skin disease was diagnosed in East Africa in Kenya in 1957 (MacOwan, 1959), Sudan in 1971 (Ali and Obeid, 1977), Chad and Niger in 1973, Nigeria in 1974 (Nawathe *et al.*, 1978) and Somalia in 1983. In May 1988 the first outbreak occurred in Egypt in Ismailia and despite all the control and eradication measures taken the disease has become endemic there (Ali *et al.*, 1990).

The outbreak of LSD in Israel occurred in 1989. It was suggested that the disease spread from the Egyptian outbreak via insect vectors carried on the wind or inside the vehicles of cattle merchants (Yeruham *et al.*, 1995). Ring vaccination programme in a radius of 50 km of the outbreak, the slaughtering

of all infected and in-contact cattle, sheep and goats, together with the restriction of cattle movements eradicated the disease from Israel.

According to the annual information of animal health situation worldwide, collected by the OIE, outbreaks or isolated cases of LSD have occurred in Bahrain in 1993, 1994 and 2002, Iran in 1996 and 2001, United Arab Emirates in 2000, Kuwait in 1991 and Oman in 1984 (OIE web page). Lumpy skin disease occurs at regular intervals in most parts of South Africa.

### **Aetiology**

Although Thomas and Maré (1945) and Von Bacstrom (1945) demonstrated the infective nature of LSD, Alexander *et al.*, (1957) were the first to isolate the Neethling type virus in tissue culture. These results were confirmed two years later by Prydie and Coackley (1959).

Lumpy skin disease virus belongs to the family *Poxviridae* which is divided into two subfamilies: *Entomopoxvirinae* (poxviruses of insects) and *Chordopoxvirinae* (poxviruses of vertebrates) and several genera (Table 1). The vertebrate poxviruses share a group-specific antigen (NP antigen) (Woodroffe and Fenner, 1962).

Table 1: Genera within the *Poxviridae* family

Genus	Viruses
<i>Capripoxvirus</i>	Sheeppox, goatpox, lumpy skin disease viruses
<i>Orthopoxvirus</i>	Buffalopox, camelpox, cowpox, vaccinia, ectromelia, monkeypox, rabbitpox, raccoonpox, taterapox, variola and volepox viruses
<i>Parapoxvirus</i>	Pseudocowpox, bovine papular stomatitis, contagious pustular dermatitis (orf), squirrel parapox viruses and parapoxvirus of red deer
<i>Suipoxvirus</i>	Swinepox virus
<i>Avipoxvirus</i>	Fowlpox, canarypox, juncopox, pigeonpox, quailpox, sparrowpox, starlingpox, turkeypox, mynahpox and pcittacinepox viruses
<i>Leporipoxvirus</i>	Hare fibroma, myxoma, rabbit (Shope) fibroma, and squirrel fibroma viruses
<i>Molluscipoxvirus</i>	<i>Molluscum contagiosum</i> virus
<i>Yatapoxvirus</i>	Yaba and tanapox viruses

Poxviruses are the largest of all animal viruses. The average size of capripoxviruses is 320-260 nm. The morphology of the viruses of the genera of the chordopoxviruses are similar with the exception of the parapoxviruses. Poxvirions are brick- or oval-shaped. Within the virion there are over 100 polypeptides, which are arranged in a core, two lateral bodies, a membrane and an envelope. The membrane and envelope are important structures for the interaction with the host cell. Mature virions that are released from the cell without cell disruption, are enveloped. The envelope contains two layers of cellular lipids and several virus-specific polypeptides. Most of the virions released by the rupture of the host cell are therefore not enveloped. Both enveloped and non-enveloped virions are infectious (Fenner *et al.*, 1987). The outer membrane is a lipoprotein bilayer that protects the core and lateral bodies. It has irregular arrangements of tubular protein called "filaments". The core is dumbbell-shaped and there are two lateral bodies of unknown



nature. The core of the viruses contains proteins that include a transcriptase and several other enzymes (Fenner *et al.*, 1987).

The virion contains numerous antigens most of which are shared by all the members of the same genus even though every species have their own specific polypeptides (Fenner *et al.*, 1987). DNA analysis using restriction endonucleases on both field samples and vaccine strains showed 80 % homology between strains of capripoxviruses (Black *et al.*, 1986). The nucleic acid is a double stranded DNA.

The characteristics of the LSD virus and its effects are mainly:

- The development of cytopathic changes and intracytoplasmic inclusion bodies in cell cultures (Alexander *et al.*, 1957; Prydie and Coackley, 1959; Munz and Owen, 1966).
- The development of macroscopic lesions (pocks) in the chorioallantoic membranes of embryonated chicken eggs (Alexander *et al.*, 1957; Van Rooyen *et al.*, 1969).
- Production of generalized skin lesions in rabbits (Alexander *et al.*, 1957).
- Morphological and antigenic similarities with sheep and goat pox viruses (Kitching and Smale, 1986).
- The presence of dsDNA (Weiss, 1968).

Lumpy skin disease virus is stable between pH 6,6 and 8,6. It is readily inactivated by the detergent sodium dodecyl-sulphate and it is chloroform and ether sensitive (Weiss, 1968; Plowright and Ferris, 1959).

The replication of the LSD virus is accompanied by the formation of intracytoplasmic inclusion bodies (Alexander *et al.*, 1957; Prydie and Coackley, 1959; Prozesky and Barnard, 1982). The virion enters host cell by fusion with the plasma membrane or by endocytosis. The transcriptase

released from the core of the virion starts the formation of the mRNA within minutes after infection. The first polypeptides complete the uncoating of the core before the actual viral DNA synthesis begins 1,5 to 6 hours after infection (Fenner *et al.*, 1987). Virion formation occurs in the cytoplasm in microscopic inclusion bodies. Microscopic examination of haematoxylin and eosin stained tissue culture monolayer cells infected with LSD virus will reveal the presence of eosinophilic intracytoplasmic inclusion bodies. The inclusion bodies are round or irregularly shaped. There may be one or several inclusion bodies within one cell (Weiss, 1968).

The virus persists for at least 33 days in the skin lesions of infected animals. It remains viable for 18 days in the skin lesions and superficial epidermal scrapings of a hide, which is air-dried and kept at room temperature. The virus was recovered from intact skin nodules kept at  $-80^{\circ}\text{C}$  for 10 years and from infected tissue culture fluid kept at  $4^{\circ}\text{C}$  for 6 months. In tissue culture fluid stored in dry-ice, virus remains viable for at least 10 years (Weiss, 1968).

## **Epidemiology**

Lumpy skin disease usually occurs at regular intervals in endemic areas or it may cause epidemics, which spread fairly rapidly throughout a region or country (Davies, 1991).

Field and experimental evidence have proved that LSD is not highly contagious. The morbidity rates in natural outbreaks vary from 3 to 85 %. In experimentally produced infections only 40 to 50 % of inoculated animals showed clinical signs. The mortality rate is usually low less than 10 % (Thomas and Maré, 1945).

Although no differences were found among strains of capripoxviruses collected over 20 years (Kitching *et al.*, 1989), it was suggested that the

variation in mortality and morbidity rates could be due to the involvement of strains of different pathogenicity, efficiency of the transmission of the disease by the vector, and route of infection (Carn and Kitching, 1995b). Experimentally it has been demonstrated that intradermal inoculation of LSD virus predominately produces localized lesion at the site of inoculation whereas intravenous inoculation results in generalized lesions and more severe disease (Carn and Kitching, 1995a).

In cattle affected with the disease virus is present in skin nodules, the crusts of skin lesions, blood, saliva, nasal discharge, semen and milk (Weiss, 1968). In experimentally infected animals it is present in blood for a period of 4 days following the appearance of fever and generalized skin lesions, in saliva for 11 days, in semen for 22 days and in the skin nodules for a period of 33 days following the first appearance of these lesions (Weiss, 1968). Because of their resistant nature poxviruses may remain viable in scab or tissue fragments for several months and therefore can be source of infection for biting insects for a prolonged period (Davies, 1991).

Transmission is believed to be mainly mechanical by biting insects (Haig, 1957; Weiss, 1968; Carn and Kitching, 1995a). It has been suggested that transmission may occur following ingesting of contaminated food, sharing the same water trough (Haig, 1957), or by blood-contaminated needles. Suckling calves may become infected through infected milk (Weiss, 1968; Henning, 1956). The transmission of sheep pox virus was demonstrated using an aerosol suspension (Kitching and Taylor, 1985). In the same study it was shown that sheep with well developed clinical signs transmitted the disease more rapidly than animals which died of peracute disease or that had suffered from mild clinical disease.

Transmission by contact with infected cattle does not readily occur in insect-proof cattle pens (Weiss, 1968; Carn and Kitching, 1995a). Outbreaks of the

disease are much more common during wet seasons and along watercourses where the insect population is high (Haig, 1957; Woods, 1988).

Lumpy skin disease virus was isolated from *Stomoxys calcitrans* and *Biomyia fasciata* caught after they had been fed on infected cattle (Weiss, 1968). The transmission of capripoxvirus was demonstrated between sheep using *Stomoxys calcitrans* (Kitching and Mellor, 1986) and between cattle using the mosquito, *Aedes aegypti* (Chihota *et al.*, 2001) as a vector. Field reports confirm that outbreaks in the absence of a significant population of biting flies decrease (Yeruham *et al.*, 1995) and that the disease diminishes with the onset of the dry season and the reduction in the number of biting flies (Nawathe *et al.*, 1978).

Carn and Kitching (1995b) concluded that the low titre of LSD virus present in blood of animals during the viraemic stage is not sufficient for mechanical transmission to occur by biting flies feeding on blood alone and that they must feed on skin lesions to obtain sufficient amount of virus for transmission to take place. Acute skin lesions contain high titres of virus that are sufficient to contaminate the mouthparts of biting insects (Carn and Kitching, 1995b).

All cattle breeds, both sexes and all ages are susceptible. Young calves are frequently more severely affected. Sheep and goats can be infected experimentally with LSD virus (Weiss, 1986). The lesions produced by capripoxvirus in sheep and in cattle following experimental infection are similar (Burdin, 1959). The skin lesions of cattle experimentally infected with sheep pox virus (Isiolo strain) using the intradermal route were clinically identical to those produced by LSD (Neethling) virus (Capstick, 1959).

The reservoir of the disease between epidemics is not known. Wildlife and small ruminants have been suspected but so far nothing has been confirmed. Climatic conditions, such as heavy rainfalls, humid and warm weather, and

drought periods affect the insect populations and will support or suppress the spread of the disease.

Natural infection has not been reported in any other ruminant species with the exception of a report of five cases in Asian water buffalo (*Bubalus bubalis*) in Egypt (Ali *et al.*, 1990) and Arabian Oryx (*Oryx leucoryx*) in Saudi Arabia (Greth *et al.*, 1992). Impala (*Aepyceros melampus*) and giraffe (*Giraffa camelopardalis*) have been successfully infected experimentally (Young *et al.*, 1970). Antibodies against LSD virus have been found in blue wildebeest (*Connochaetes taurinus*), black wildebeest (*Connochaetes gnou*), springbok (*Antidorcas marsupialis*) and eland (*Taurotragus oryx*) (Barnard, 1997). According to Hedger and Hamblin (1983) wildlife do not play significant role in the epidemiology of the disease.

### **Economic importance**

Even though the morbidity and mortality rates of LSD are usually low, it is an economically important disease of cattle in Africa because of the prolonged loss of productivity of dairy and beef cattle, decrease in body weight, mastitis, severe orchitis, which may result in temporary infertility and sometimes permanent sterility. Pregnant cows may abort and infertility of cows can last for several months (Weiss, 1968). In severely affected animals damage to hides is permanent and the value of these for leather industry is greatly reduced (Green, 1959).

### **Clinical signs**

The clinical signs of natural and experimentally produced LSD have been well described (Thomas and Maré, 1945; Haig, 1957; Alexander *et al.*, 1957; Capstick, 1959; Weiss, 1968; Prozesky and Barnard, 1982; Davies, 1991; Barnard *et al.*, 1994; Carn and Kitching, 1995b). The course of the disease may be acute, subacute or chronic. Only 40 to 50 % of experimentally

infected animals develop generalized skin lesions; many cases are subclinical (Weiss, 1968). The incubation period of LSD under field condition is 2-4 weeks (Haig, 1957) while in the experimentally induced disease it is between 4 and 14 days (Prozesky and Barnard, 1982; Carn and Kitching, 1995b).

In animals that develop clinical disease there is a biphasic febrile reaction that may exceed 41 °C. They remain febrile for 4 to 14 days. This is accompanied by depression, disinclination to move, inappetence, salivation, lachrymation and a nasal discharge, which may be mucoid or mucopurulent. Lachrymation may be followed by conjunctivitis and, in some cases, by corneal opacity and blindness. The superficial lymph nodes, especially prescapular, precrural and subparotid are usually markedly enlarged (Thomas and Maré, 1945; Haig, 1957; Alexander *et al.*, 1957; Capstick, 1959; Weiss, 1968; Prozesky and Barnard, 1982; Davies, 1991; Barnard *et al.*, 1994; Carn and Kitching, 1995b).

The eruption of nodular skin lesions usually appears within 48 hours of onset of the febrile reaction. They may be very numerous and cover the entire body or there may be only a few of them. Predilection sites are the skin of the head, neck, perineum, genitalia, udder and limbs. Nodules are 5 to 50 mm in diameter, circumscribed, firm, round and raised, and involve the skin, subcutaneous tissue and sometimes even the underlying muscles. Ulcerative lesions may appear on the conjunctiva, muzzle, nostrils, on the mucous membrane of the mouth, larynx, trachea, oesophagus and abomasum. Small nodules may resolve spontaneously, without any consequences or may become ulcerated and sequestered. Secondary bacterial infection or infestation by fly larvae may occur. Large nodules may become fibrotic and persist for several months; these are referred to as "sit fasts" (Thomas and Maré, 1945; Haig, 1957; Alexander *et al.*, 1957; Capstick, 1959; Weiss, 1968; Prozesky and Barnard, 1982; Davies, 1991; Barnard *et al.*, 1994; Carn and Kitching, 1995b). The scars may remain indefinitely thus rendering the hide worthless (Green, 1959).

Some acutely affected animals may develop severe subcutaneous oedema of the ventral parts of the body such as the dewlap, brisket, limbs, udder, scrotum and vulva. The skin of the oedematous limbs may become necrotic and slough off leaving deep ulcers, which may become secondarily infected with bacteria. Oedematous and necrotic lesions in the udder may result in mastitis. In some animals necrotic lesions in the trachea and lungs may lead to pneumonia. Contraction of connective tissue in healed tracheal lesions may result in a localized collapse of the trachea and subsequent suffocation. Bulls usually become temporarily infertile but sometimes because of severe orchitis they may become permanently sterile. Pregnant cows may abort and be in anoestrus for several months (Thomas and Maré, 1945; Haig, 1957; Alexander *et al.*, 1957; Capstick, 1959; Weiss, 1968; Prozesky and Barnard, 1982; Davies, 1991; Barnard *et al.*, 1994; Carn and Kitching, 1995b).

## **Diagnosis**

A presumptive diagnosis of the disease can be made based on clinical signs. However, mild and inapparent disease may be difficult to diagnose and rapid laboratory methods are needed to confirm the diagnosis.

Laboratory diagnosis of LSD can be done either by identification of the agent using transmission electron microscopy (TEM), by its isolation in cell cultures, by direct fluorescent antibody test (FAT) or by detection of antibody using conventional serological tests such as the serum virus neutralization test (SNT), indirect fluorescent antibody test (IFAT) and agar-gel immunodiffusion test (AGID). Routine histopathology and immunohistological staining provide a relatively inexpensive tool to diagnose the disease. Indirect and antigen trapping ELISA as well as polymerase chain reaction (PCR) have been developed more recently for detecting LSD antibodies and antigen (Carn *et al.*, 1994; Carn, 1995; Ireland and Binepal, 1998; Heine *et al.*, 1999).

Transmission electron microscopy is a rapid method of detecting LSD virus both in fresh and formalin-fixed biopsy material but may not always be available. Lumpy skin disease virus was detected in skin lesions using TEM from day 9 to day 21 p.i., the same time period as the virus was isolated in cell cultures (Davies *et al.*, 1971).

Lumpy skin disease virus can be cultured in a large variety of tissue cultures: lamb and calf kidney cells, lamb and calf testis cells, sheep kidney cells, lamb and calf adrenal and thyroid cultures, foetal lamb and calf muscle cells, sheep embryonic kidney and lung cells, rabbit foetal kidney and skin cells, chicken embryo fibroblasts, adult vervet monkey kidney cell line (AVK 58) and in baby hamster kidney cells (BHK/21) (Alexander *et al.*, 1957; Prydie and Coackley, 1959; Weiss, 1968). The virus can also be cultured in primary cell cultures of bovine dermis and equine lung cells [Standard Operative Procedure, Department of Veterinary Tropical Diseases (DVTD)]. The development of cytopathic effects (CPE) may take up to 14 days during primary isolation (Alexander *et al.*, 1957; Prydie and Coackley, 1959).

Capripoxvirus grows slowly in tissue cultures and may require several passages (Alexander *et al.*, 1957; Prydie and Coackley, 1959). Bacterial and fungal contaminations are frequently encountered in biopsy samples and these may infect cell cultures, particularly those ones that require prolonged incubation. The virus also multiplies in chicken embryos and on the chorio-allantoic membrane of embryonated hens' eggs (Van Rooyen *et al.*, 1969).

Fluorescent antibody staining of frozen sections shows brilliant, stippled cytoplasmic staining of virus-infected cells with large intracytoplasmic inclusion bodies. Examinations using FAT may indicate the presence of LSD virus antigens especially in the early stages of the disease, but later non-specific fluorescence may cause problems (Davies *et al.*, 1971). However, it is not possible to differentiate the different members of the capripoxvirus group with the direct or indirect FAT (Davies and Otema, 1981).



Serological methods are useful for confirming retrospectively LSD but are too time consuming to be used as primary diagnostic methods (Davies, 1991). The interpretation of SNT and IFAT for antibodies to capripoxviruses may sometimes be difficult due to cross-reactions with other poxviruses as well as to the low antibody titres in some animals following mild infection or vaccination (Kitching and Hammond, 1992). The SNT is considered to be a reliable test for evaluating antibodies to capripoxviruses.

Capripoxviruses are not readily neutralized and neutralization studies cannot differentiate LSD virus from sheep and goat pox virus (SGPV) (Davies and Otema, 1981). Cattle in contact with sheep or goats infected with SGPV usually do not develop antibodies to capripoxviruses. However, cattle that have been vaccinated with SGPV will develop neutralizing antibodies to LSD virus (Capstick and Coackley, 1961).

Histopathology of skin lesions provides a method to recognize the intracytoplasmic inclusion bodies of LSD virus-infected cells by using haematoxylin and eosin staining. Immunohistochemical methods e.g. immunoperoxidase staining can be used to identify the antigen in skin lesions (Haines and Chelack, 1991; Haines and Clark, 1991).

The shortcomings of the conventional serological tests have been overcome by the recent development of an indirect enzyme-linked immunosorbent assay (ELISA) for the detection of antibodies to capripoxviruses (Carn *et al.*, 1994). An antigen-trapping ELISA (Carn, 1995) and a PCR (Ireland and Binopal, 1998; Heine *et al.*, 1999) have been developed for the detection of capripoxviruses.

Due to variable results obtained by crude or purified native antigen, the gene encoding the major structural protein P32 was cloned and used in an indirect ELISA (Carn *et al.*, 1994). The results indicated that the indirect ELISA detected antibodies earlier post-infection than the SNT. The ELISA was easier

to interpret than the SNT, as tissue cultures were not used as they are in the SNT and there was no cross-reaction with antibodies to orthopox- or parapoxviruses.

An antigen trapping ELISA was developed using quinea pig polyclonal detector antiserum produced against a recombinant capripoxvirus specific antigen expressed in *Escherichia coli* using the plasmid vector pGEX-2T (Carn, 1995). The ELISA detected antigen at a titre of 2,8 tissue culture infected dose 50 (TCID<sub>50</sub>). The test was developed to detect the virus in biopsy samples or tissue cultures. The benefits of the assay are that it gives rapid results, is of low cost, is easy to perform and it utilizes stable reagents.

The diagnosis of LSD can be confirmed rapidly by performing the PCR on suitable specimens. It is also suitable for use in those countries in which the disease is not endemic and a live virus is not available (Heine *et al.*, 1999). The PCR is more sensitive and specific compared to the antigen trapping ELISA (Ireland and Binopal, 1998). False-negative results are seldom a problem. However, great care must be taken to avoid contamination of samples with extraneous nucleic acids, which may lead to false-positive results. One of the benefits of the PCR is that the reagents are commercially available.

### **Differential diagnosis**

The skin lesions of pseudo lumpy skin disease (caused by bovine herpesvirus-2), insect bites, Demodex infection, onchocerciosis, besnoitiosis and dermatophilosis can be confused with LSD (Barnard *et al.*, 1994).

Diseases causing mucosal lesions, which can be confused with LSD are rinderpest, bovine viral diarrhoea/mucosal disease and bovine malignant catarrhal fever (Barnard *et al.*, 1994).

## **Pathology**

The pathology of LSD has been well described (Thomas and Maré, 1945; Prozesky and Barnard, 1982; Barnard *et al.*, 1994). Firm, well-circumscribed nodules, 5-50 mm in diameter, develop in the skin. There may be a few of them in mild cases or many in severe cases. The entire thickness of the skin, and underlying subcutaneous tissues and, occasionally, the skeletal muscles are involved. Soft yellowish-grey nodules or ulcerative lesions may also appear on the muzzle, nostrils, mucous membrane of the mouth, digestive and respiratory tract, vulva, and prepuce. Skin nodules have a firm and whitish-grey appearance on cut section. Eventually the central necrotic plug may slough off to leave a raw granulating ulcer. Subcutaneous oedema of the limbs and ventral parts of the body and generalized lymphadenopathy are characteristics of the acute disease (Thomas and Maré, 1945; Prozesky and Barnard, 1982; Barnard *et al.*, 1994).

The histopathological changes of the skin lesions in the acute stage are characterized by vasculitis, perivasculitis, lymphangitis, thrombosis, oedema, necrosis and infarction. Necrotic areas are infiltrated with neutrophils, macrophages and sometimes eosinophils, which are later replaced by lymphoblasts, lymphocytes, plasma cells, macrophages and fibroblasts. Eosinophilic intracytoplasmic inclusion bodies surrounded by a halo are seen mainly in macrophages, endothelial cells, pericytes and keratinocytes in the skin but also occur in epithelial cells associated with hair follicles, skin glands and in smooth muscle cells (Thomas and Maré, 1945; Prozesky and Barnard, 1982, Barnard *et al.*, 1994).

## **Immunity**

Immunity to capripoxvirus infections is predominantly cell-mediated and therefore requires a replicating agent to be effectively stimulated (Carn, 1993). Most progeny viruses remain inside infected cells with the exception of

enveloped poxviruses, which are released into the blood (Boulter and Appleyard, 1973). By spreading from cell to cell the virus is out of reach of circulating antibody. Circulating antibodies against capripox virus are able to limit the spread of the virus in experimental sheep, but do not prevent replication of the virus at the site of infection (Kitching, 1986). The immune status of a previously infected or vaccinated animal cannot therefore be related to serum levels of neutralizing antibody (Kitching, 1986).

All the viruses in the *Capripox* genus share a common major antigen for neutralizing antibodies: animals recovered from infection by one virus are protected from infection with the other. It is not possible to distinguish capripoxviruses with the SNT, FAT, IFAT or AGID (Davies and Otema, 1981; Kitching *et al.*, 1986a). Serological evidence (Davies and Otema, 1981), cross infection and cross protection experiments (Capstic, 1959; Kitching and Taylor, 1985) indicate that the viruses of the genus *Capripox* cross-react immunologically.

Animals recovered from apparent or inapparent natural infection with LSD develop antibodies capable of neutralizing up to 3 logs of the virus and are also resistant to reinfection (Weiss, 1968). Animals that have been vaccinated or showed mild disease develop low levels of neutralizing antibodies (Kitching and Hammond, 1992).

In experimentally produced LSD only 40-50 % of the infected cattle developed generalized skin lesions. The remaining animals either develop localized and circumscribed painful swelling at the inoculation site of LSD virus or show no clinical signs apart from a fever reaction (Weiss, 1968).

The attenuated Neethling strain vaccine is used to vaccinate cattle in South Africa. It is possible to use the SGPV vaccine for cattle (Capstick and Coackley, 1961) but the use of this vaccine has been restricted to those countries where sheep and goat pox are endemic. Neutralizing antibodies to

LSD virus persist for at least 2-3 years after vaccination. In some animals the antibody levels are too low to demonstrate but they, nevertheless, are still resistant to challenge (Weiss, 1968). Antibodies appear 10 days after vaccination and reach the highest level 30 days post-inoculation. Calves born to immunized cows will have passive immunity that persists for about 6 months (Weiss, 1968).

A granulomatous local skin reaction at the site of inoculation as well as fever and reduction in milk yield may follow vaccination with live, attenuated capripoxvirus. Severe, generalized reactions, typical of LSD, occurred in dairy cattle in Israel vaccinated with live attenuated virus (Kenya sheep and goat pox strain 0240) (Yeruham *et al.*, 1994). A decrease in milk production of 3,5 % over a period of 12 days was observed. Some of the animals, which had calved for the first time (3,5 %) and some older cows (0,5 %) had to be slaughtered because of the severity of the reaction. Positive virus isolations and positive TEM findings were made of the skin lesions of the animals. On the other hand, the same vaccine strain of capripoxvirus has been used effectively without any severe adverse vaccine reactions in sheep and goats in Kenya (Kitching *et al.*, 1986b). The reduction in the milk yield, the granulomatous local reaction at the vaccination site and the possibility of the generalized reaction in the vaccinated animals have made some farmers unwilling to vaccinate their cattle except if an actual threat of the disease is evident.

Recently new recombinant vaccines have been developed. Capripoxvirus has been combined, for example, with rinderpest or rabies virus (Ngichabe *et al.*, 2002; Aspden *et al.*, 2002). Capripoxvirus is an excellent vector for the recombinant vaccines because of its narrow host range (Ngichabe *et al.*, 1997) and relatively large size of its genome (Carn, 1993). The foreign genes can be attached to the non-essential sites of the genome of capripoxvirus. The combined new genome will express the antigenic protein of both viruses without interfering with the replication of the poxvirus. The recombinant

capripox-rinderpest vaccine was developed by adding the haemagglutinin or fusion gene of the rinderpest virus to the genome of LSD virus. Clinical trials showed no local reaction at the vaccination site or any other adverse reaction to vaccination. After a year the cattle were protected from severe rinderpest but some animals did, however, show mild signs of rinderpest. The animals were fully protected when challenged with LSD virus (Ngichabe *et al.*, 1997).

## **Control**

In endemic areas vaccination against LSD is the only effective method to control the disease.

In those countries where LSD is not present the most important method to control the disease is the restriction or ban on the importation of animals and those animal products that may contain live virus from endemic countries (Carn, 1993).

In order to prevent the introduction of the disease from endemic areas, LSD free countries may prohibit the importation or the transit through their territory of live domestic and wild bovine species and bovine semen. When importing from endemic countries, veterinary administrations should require a presentation of an international veterinary health certificate attesting that the animals being imported do not show clinical signs of the disease and the animals have been vaccinated against LSD more than 30 days and less than 3 months prior to shipment. They should require that the cattle must be kept in a quarantine station in the exporting country for at least 28 days prior to shipment. The requirements for the importation of bovine semen should include the presentation of an international veterinary certificate attesting that the donor animal does not show any clinical signs of LSD on the day of collection of the semen or for the following 28 days and that the donor has been kept in a quarantine station for 28 days in the exporting country. The importation of bovine products that may contain live virus should either be

banned or the importing country should require that those products must be processed before the importation in such a way, which ensures that LSD virus will be destroyed. (OIE's web page, recommendations for the importation of live bovine species and bovine semen from endemic countries to LSD free countries).

In the case of a LSD outbreak in non-endemic areas the slaughter of infected and in-contact animals, ring vaccination in a radius of 25-50 km, movement restriction of animals and destruction of contaminated hides should usually be sufficient to eradicate the disease (Carn, 1993).

### **OBJECTIVES OF THE STUDY**

- To determine the incubation period and viraemia in bulls inoculated with LSD virus.
- To monitor the clinical manifestations of LSD.
- To determine the persistence of the virus in semen and skin lesions.
- To assess the antibody response to LSD virus.
- To compare different diagnostic tests to detect LSD virus at different intervals following infection.

### **OBSERVATIONS MADE IN THE STUDY**

The following observations were made:

- The sequential development of clinical signs, e.g. rise in rectal temperature and skin lesions were observed.
- The viraemia was correlated with the fever reaction.
- The duration of virus / antigen in semen and skin lesions was determined using cell cultures, TEM, PCR and immunoperoxidase-stained tissue sections.
- Antibody titres were assessed using SNT and IFAT.

## CHAPTER 2

### MATERIALS AND METHODS

#### **Experimental animals**

Six post-pubertal, early-maturing bulls from a herd where vaccination against LSD was not practised were used as experimental animals. They were thin-skinned, European breeds: 2 Holstein-Friesians, 2 Dexters and 2 Dexter crosses. The bulls were between 11 and 20 months of age (Table 2). Before they were purchased and again before the onset of the experiment the animals were tested to be seronegative using SNT. During the experiment the animals were kept in isolation in the insect proof facility of OVARU, Faculty of Veterinary Science, University of Pretoria. Before the onset of the experiment the bulls had a period of two weeks to acclimatize into a new environment. The experimental animals were numbered with ear tags (1, 2, 3, 4, 7 and 8). The latter two bulls were not numbered as 5 and 6 because they already had ear-tag numbers 7 and 8 before their purchase and these were not changed.

#### **Preparation of virus suspension and animal inoculation**

A virulent, South African, 3 times-passaged, field isolate strain V248/93 of LSD virus was used to infect the animals.

Bovine dermis cells prepared from foetal calf's ear were cultured in 75 cm<sup>2</sup> tissue culture flasks in Minimum Essential Medium (MEM) with L-glutamine (Highveld Biological), 0,2 % Sodium Bicarbona (Highveld Biological), 5 % foetal calf serum (Adcock Ingram) and gentamycin 0,05 mg / ml (Genta 50 Phenix, 50 mg / ml).



To ensure that virus was present in actively dividing cells 0,5 ml of virus suspension was inoculated 2 hours after preparation of the cells into the 75 cm<sup>2</sup> flasks containing bovine dermis cell monolayer in a growth medium. Virus was harvested when 90 - 100 % of the cell monolayer was infected and showed typical CPE. Culture flasks were briefly frozen at -70 °C and then thawed. They were shaken gently to break up the cell material and to release the cell-associated virus. The cell material was centrifuged for 3 min at 2000 rpm, the supernatant removed and aliquoted in 1,8 ml or 3,5 ml volumes in cryotubes and stored as reference stock virus at -70 °C until used.

The reference stock virus was titrated on bovine dermis cells using 96 well microtitre plates. Cells were observed daily for CPE and TCID<sub>50</sub> of the virus was calculated using the method of Reed and Muench (1938).

The bulls were inoculated intravenously (IV) with 2 ml of the virus suspension at a titre of 5,4 log TCID<sub>50</sub>.

### **Clinical observations, sample collection and processing**

The bulls were clinically examined daily and their rectal temperatures were measured twice a day. Blood, semen and skin biopsy samples were collected at different intervals.

After inoculation blood samples in EDTA and in heparin were collected daily for 30 days post-inoculation (p.i.) and then at 3-day intervals up to day 40. After collection heparinized and EDTA blood samples were aliquoted in 1,8 ml volumes in cryotubes. Heparinized blood was stored at -70 °C and EDTA blood at -20 °C.

For the assessment of antibody response serum was collected at 3-day intervals from day 3 to day 90 p.i. The serum was aliquoted in 3,5 ml volumes in cryotubes and stored at  $-20\text{ }^{\circ}\text{C}$ .

After the appearance of the skin lesions, biopsies comprising epidermis, dermis and subcutis of the nodules were collected for virus isolation, virus detection by means of PCR, TEM, and light microscopy in tissue sections stained with haematoxylin and eosin and with immunoperoxidase. Samples were collected at weekly intervals for up to 3 months. During biopsy sampling the skin area was anaesthetised locally using 2 % Lignocaine<sup>®</sup> (lignocaine HCL, Bayer AH). In case the animal showed any signs of discomfort during the procedure Domosedan<sup>®</sup> (detomidine, Novartis / Orion Pharma) sedative was administrated. Biopsy samples were taken aseptically and the incisions were sutured with 2-0 Ethicon Vicryl (Johnson & Johnson Intl). Samples were divided into 3 pieces, one of which was placed in 10 % buffered formalin and the others in 1,8 ml cryotubes, which were stored either at  $-20\text{ }^{\circ}\text{C}$  for PCR or at  $-70\text{ }^{\circ}\text{C}$  for virus isolation. The biopsy samples in 10 % formalin were submitted to the Section of Pathology, Faculty of Veterinary Science where tissue sections were prepared for microscopy. These were stained with haematoxylin and eosin and with immunoperoxidase. Samples for TEM were examined on the day of collection and submitted to the Electron Microscopy Unit of the Faculty.

After the animals were infected semen samples for PCR and virus isolation were collected every second day until day 18, then twice a week until day 64. In the bulls, in which the virus in the semen persisted when tested by PCR, the collection of semen samples was continued twice a month until three consecutive results were negative. Semen was collected in graduated sample tubes after the bulls had been stimulated to ejaculate by electrical stimulation. The samples were delivered immediately to the laboratory where they were aliquoted in 1,8 ml volumes in cryotubes and stored at  $-20\text{ }^{\circ}\text{C}$  for PCR and at  $-70\text{ }^{\circ}\text{C}$  for virus isolation.

The presence of virus and antibodies was determined in the samples using several laboratory assays. The laboratory procedures were done according to the standard operating procedures (SOPs) of the different laboratories in the Department of Veterinary Tropical Diseases (DVTD) or using other published procedures as described below.

## **Diagnostic methods**

### ***Transmission electron microscopy***

Negative staining of biopsy material for TEM was done according to the SOP of the Electron Microscopy Unit at the Faculty of Veterinary Science.

For TEM skin specimen was minced using a sterile, disposable blade and forceps and then ground in a sterile mortar with a pestle. A small volume of distilled water was added and the aqueous material was collected into 1,5 ml Eppendorf tubes and centrifuged for 15 min at 5000 rpm. The supernatant was collected and centrifuged again for 45 min at 13 000 rpm. After discarding the supernatant the pellet was rinsed carefully with distilled water and the pellet was then diluted into one droplet of water. A droplet of 3 % phosphotungstic acid (PTA) was mixed with a droplet of the sample and the copper grid was dipped into the mixture. After drying the grid was examined using a Philips CM 10 transmission electron microscope.

### ***Virus isolation***

Heparinized blood samples

Bovine dermis cells at  $\pm$  50 % confluency were infected with 0,5 ml heparinized blood. After 24 hours the medium was removed and the cells were washed twice with phosphate buffered saline containing  $Mg^{2+}$  and

Ca<sup>2+</sup> (PBS+) and gentamycin (0,05 mg / ml). The medium was replaced with MEM containing 5 % foetal calf serum and gentamycin (0,05 mg / ml). The cell cultures were observed daily for CPE. After 14 days negative cultures were frozen briefly at -70 °C and thawed. The flasks were shaken gently to break up the cell material and to release the cell-bound virus. A second passage was done and observed for 14 days. Isolates were stored at -70 °C.

### Skin biopsies

For virus isolation, biopsy tissue was minced using sterile scissors and forceps and then using sterile techniques ground in a mortar containing sterile sand with a pestle. A volume of 10 ml PBS+ containing gentamycin (0,1 mg / ml), ampicillin (0,05 mg / ml) (Intramed Ampicillin Inj. 500 mg) and amphotericin B (5 µg / ml) (inj. Fungizone, Bristol-Myers Squibb) were added. The suspension was left to stand overnight at 4 °C. The samples were partially clarified by centrifugation at 2000 rpm for 3-5 min to remove gross particles and the supernatant was collected and used to inoculate cell cultures or was stored at -70 °C until used. A 25 cm<sup>2</sup> flask of a monolayer of bovine dermis cells was inoculated using 0,5 ml of the supernatant. Cultures were observed daily for CPE.

### Semen samples

After fast thawing at 37 °C using a waterbath, semen samples were diluted 1:10 in MEM containing 5 % foetal calf serum and amoxicillin (0,2 mg / ml) (inj. Amoxil 500 I<sup>®</sup>, Smith Kline Beecham Pharmaceuticals Ltd.), penicillin (200 IU / ml) streptomycin (200 µg / ml) (inj. PenicillinStreptomycin, Invitrogen), gentamycin (0,2 mg / ml) and amphotericin B (5 µg / ml). To inhibit bacterial and fungal contamination the diluted samples were left for 24 - 48 h at 4 °C before 0,5 ml of each sample was inoculated onto a bovine dermis cell monolayer in 25 cm<sup>2</sup> tissue culture flasks. The cell cultures were

inoculated at 100 % confluency and were examined 1-2 h after inoculation and those which showed any evidence of toxicity were washed and fresh medium was added. Otherwise the medium was removed about 6 h later and the cells were washed twice with PBS+ containing amoxicillin (0,05 mg / ml). The medium was replaced with MEM containing 5 % foetal calf serum and amoxicillin (0,05 mg / ml), penicillin (50 IU / ml) and streptomycin (50 µg / ml), gentamycin (0,1 mg / ml) and amphotericin B (5 µg / ml).

The cell cultures were examined daily for 14 days for the CPE typical for LSD virus infection. The growth medium was replaced if it appeared cloudy due to bacterial or fungal contamination. After 14 days the negative cell cultures were blind-passaged onto a fresh cell culture monolayer and observed until typical CPE changes occurred or for another 14 days.

A negative control for the virus isolation consisted of a bovine dermis cell monolayer and a positive control consisted of a bovine dermis cell monolayer inoculated with a volume of 0,2 – 0,5 ml LSD virus (V 248/93) suspension.

### ***Indirect fluorescent antibody test***

The IFAT was carried out according to the SOP of the DVTD.

Bovine dermis cells were cultured in two 75 cm<sup>2</sup> tissue culture flasks in MEM containing 5 % foetal calf serum (Adcock Ingram) and gentamycin 0,05 mg / ml (Genta 50 Phenix, 50 mg / ml). Two days after splitting the cells 0,25 ml LSD virus suspension was inoculated into one flask. The other flask contained only the cells. After CPE was observed the cells of these two flasks were mixed and the cells were counted. A volume of 10 µl of LSD virus-infected bovine dermis cell culture at a concentration of 10<sup>6</sup> cells / ml was spotted onto 12 wells teflon-coated slides and fixed in cold acetone at –20 °C for 10 min. The slides were dried and stored at –20 °C until used.

A series of two-fold dilutions of test sera were made in 0,15 M phosphate buffered saline containing 0,05 % Tween 20 (polyoxyethylene sorbitan monolaureate) (PBS-T) and 10 µl was added to the wells on top of the fixed virus. Antibodies were allowed to bind to antigens by incubating the slides at 37 °C for 30 min in a humid chamber to avoid desiccation. After incubation, the slides were washed with PBS-T for 5 min, followed by washing with distilled water for 5 min. Finally anti-bovine gamma globulin conjugated with fluoresceine isothiocyanate (Antibovine Ig G, H+L, FITC, The Binding Site) was added at a predetermined working dilution of 1:80 in Evans' blue counterstain (Sigma) and incubated in a moist chamber at 37 °C for 30 min. The slides were again washed for 5 min with PBS-T and for 5 min in distilled water and dried. Mounting fluid [NaHCO<sub>3</sub> (0,715 g), Na<sub>2</sub>CO<sub>3</sub> (0,16 g), distilled water 10 ml, mixed up to 100 ml glyserol] was added and the slides were examined using a microscope with an UV-light of wave length 436 nm as a light source.

Two known positive serum samples were tested to be used as positive control. Positive sera had been collected in 1991 from a herd in which a natural outbreak of LSD had occurred. Two bovine serum samples and foetal calf serum (Adcock Ingram) were tested to be used as negative control sera. The former being collected from clinically healthy animals in the vicinity of Pretoria. These animals were previously tested to have no antibodies against LSD virus using the SNT. Serial two-fold dilutions of all the sera (1:10, 1:20, 1:40, 1:80 and 1:160) were made using PBS-T. A volume of 10 µl of each dilution was spotted onto the wells. The slides were processed and examined as described above.

To determine the best working dilution of fluorescein iso-thiocyanate-labelled antibovine antibody, it was diluted in 1:40, 1:80 and 1:160 in 0,05% Evans' blue and added to the wells. The slides were processed and examined as described above.

The sera used as positive controls gave the optimum results at a 1:40 dilution. Even though both negative samples were previously tested to be LSD-negative using the SNT, they still showed too much non-specific fluorescence in the cytoplasm of the cells. For this reason it was decided to use foetal calf serum as a negative control at a 1:10 dilution. The conjugate gave the best result at a dilution of 1:80.

Pre-infection sera of the experimental bulls gave too much non-specific fluorescence at a titre of 1:40 and it was therefore decided to use a dilution of 1:80 as a starting dilution.

### ***Serum virus neutralization test***

The SNT was carried out according to the SOP of the DVTD.

A 96-well, flat-bottomed cell culture microtitre plate was used. Test sera were diluted 1:5 in MEM containing 5 % foetal calf serum and gentamycin (0,05 mg / ml) and inactivated at 56 °C for 30 min. A series of two-fold dilutions of the inactivated test serum was prepared and 100 µl of sera were added to the wells. The titre of the LSD virus to be used was determined and 100 µl of a 100 TCID<sub>50</sub> were added to each well.

For the cell control, 200 µl of MEM was added to 12 wells. For the antigen control, three ten-fold dilutions of antigen (100 TCID<sub>50</sub>) were made and 100 µl of each dilution were added to 100 µl of MEM in each well. The microtitre plate was incubated at 37 °C for 1 hour. Following incubation, 80 µl of bovine dermis cells at a concentration of 480 000 cells / ml were added to the wells.

The microtitre plates were then incubated at 37 °C in an incubator containing 5 % CO<sub>2</sub>. Using an inverted microscope, the monolayers were examined daily for evidence of CPE. The cell control indicated how long the

cells remained viable and for how long it was possible to read the test before cell degeneration. The results were interpreted accordingly.

### ***Histopathology***

The preparation of tissue sections for haematoxylin and eosin, and immunoperoxidase staining were performed according to the SOPs of the Section of Pathology, Faculty of Veterinary Science.

### ***Polymerase chain reaction***

The extraction method used was a modification from the method described by Gubbels *et al.*, (1999) and Schwarts *et al.*, (1997). A volume of 200 µl semen or blood specimen in EDTA was frozen at –70 °C and thawed. The samples were suspended in 100 µl lysis buffer containing 0,378 g KCl, 1 ml Tris (1,0 M, pH 8), 0,5 ml Tween 20 and 60 % guanidine thiocyanate (Roche Diagnostics). Protein bands were digested by adding 1 µl of Proteinase K (20 mg / ml Invitrogen, Laboratory Specialist Services Ltd) to each sample. The portions of the skin biopsies to be used in this test were first cut into fine pieces using sterile scissors and forceps and ground in a mortar with a pestle. The samples were suspended in 1 ml lysis buffer containing 60 % guanidine. A volume of 10 µl Proteinase K was added. All the samples were incubated at 56 °C overnight and the next day the samples were heated for 10 min at 100 °C to denature the enzyme.

A Phenol:Chloroform:Isoamylalcohol (25:24:1, v/v, Invitrogen) solution was added to each sample at a 1:1 volume and the samples were mixed while incubating at room temperature for 10 min. After centrifugation (13 000 rpm for 15 min) the upper, aqueous phase was collected and two volumes of ice cold, 100 % ethanol was added. The samples were placed at –20 °C for 1 h, centrifuged at 13 000 rpm for 15 min and the pellets washed with 70-75 % ethanol. After centrifugation at 13 000 rpm for 1 min, supernatants were



discarded and pellets were dried thoroughly. The pellets were suspended in 30 µl of distilled water.

The PCR primers were developed from the gene for viral attachment protein and have the following sequences (Ireland and Binopal, 1998).

forward primer: 5'-d TTCCTGATTTTCTTACTAT3'

reverse primer: 5'-d AAATTATATACGTAAATAAC 3'

The size of the amplicon was 192 bp (Ireland and Binopal, 1998).

A Platinum<sup>®</sup> Quantitative PCR SuperMix-UDG (2X) reaction mixture (Invitrogen, Life Technologies) was used for amplification of nucleic acid templates. The mixture contains deoxiribonucleotide triphosphates with dUTP, Platinum<sup>®</sup> *Tag* DNA polymerase for DNA amplification, urasil DNA glycosylase (UDG) for preventing reamplification of PCR carryover products.

DNA amplification was carried out in final volume of 25 µl containing:

12,5 µl Platinum<sup>®</sup> Quantitative PCR SuperMix-UDG

1 µl 0,20 mM each primer

9,5 µl distilled water

1 µl DNA sample

The reaction was carried out in a Perkin-Elmer Gen Amp 9600 PCR system. The PCR started with one cycle of 42 °C for 2 min and 94 °C for 10 min. This step allows the UDG component of Platinum<sup>®</sup> Quantitative PCR SuperMix-UDG to remove any urasil residues from the PCR mixture. The initial cycle was 94 °C for 1 min, 50 °C for 30 s and 72 °C for 1 min. This was followed by 40 cycles of 94 °C for 1 min, 50 °C for 30 s, and 72 °C for 1 min, and a final elongation step of 72 °C for 1 min to complete the extension of the primers (Ireland and Binopal, 1998).

Always when samples were tested using the PCR a positive, negative and water control were included. Amplified products were analysed using a 100 bp DNA ladder (Whitehead Scientific Ltd) as a molecular marker on 1,5 % agarose gels. A volume of 2  $\mu$ l ethidium bromide (a stock concentration of 10 mg / ml) in TrisEDTA (TE) was added to the gel. Amplicons were visualized using an UV transilluminator at a wave length of 590 nm and positive reactions were confirmed according to size.

## CHAPTER 3

### RESULTS

#### Clinical signs

The experimental animals were divided into three groups according to the severity of the clinical signs after inoculation as shown in Table 2. Two bulls developed severe, generalized disease (group 1), two manifested a mild disease with fever and a few skin lesions on the neck and back (group 2), and two had only transient fever but no other signs (group 3).

Before the onset of the experiment Bulls no. 1 and 2 were the smallest but were otherwise in good condition. Bulls no. 3 and 4 were in good physical condition with shiny haircoats. Bulls no. 7 and 8 were very thin.

Table 2: Grouping of animals according to the severity of clinical signs

Group no.	Clinical signs	Animal no.	Age (months)	Weight (kg)	Breed
1	severe	1	11	232	Dexter
		2	15	250	Dexter
2	mild	7	17	236	Friesian
		8	20	310	Friesian
3	inapparent	3	16	295	Dexter cross
		4	14	321	Dexter cross

In this study the day of inoculation was counted as day 1 p.i.

An increase in rectal temperature, which lasted for 3 to 14 days, was observed in all the animals 5 to 6 days p.i. (Figure 1).

Group 1: In Bulls no. 1 and 2 the fever lasted 10 to 14 days and in Bull no. 1, at the height of the reaction, it exceeded 41 °C (41,5 °C) for three days (Figure 1). After the main fever reaction Bull no. 1 had a rise in temperature (39,2 °C) for one day on day 22 p.i. Bull no. 2 also had a rise in temperature (39,4° C) on day 24 p.i. Both animals developed ulcerative lesions on the muzzle and nostrils (Figure 3) and numerous skin nodules over the entire body (Figure 2, Figure 4). They showed salivation, lachrymation and a mucopurulent nasal discharge. The superficial lymph nodes were slightly enlarged. Bull no. 1 had a subcutaneous oedema between the tarsal joint and fetlock of the right hind leg (Figure 5). Because of respiratory distress, high fever and inappetence it was treated with 12 ml of sulfatrimetoprim / day administrated either IV or IM (Sulfatrim 240<sup>®</sup>, Phenix, Virbac) for 10 days and 4 ml of phenylbutazone / every second day IV twice (Phenylarthrite<sup>®</sup>, 200 mg / ml, Centaur, Bayer). These treatments were started on day 10 p.i.

Group 2: Bulls no. 7 and 8 had elevated rectal temperatures for 5 to 7 days which did not exceed 40,5 °C. A small number of skin lesions developed mainly on their necks, backs and perineal areas but they showed no other clinical signs. Both animals developed a ringworm infection 30 to 34 days p.i.

Group 3: In Bulls no. 3 and 4, the fever lasted 3 to 6 days and only on one day did it exceed 40 °C in Bull no. 4. Bull no. 3 had a slight rise (39,3 °C) in rectal temperature on day 18 p.i. No other clinical signs were observed.

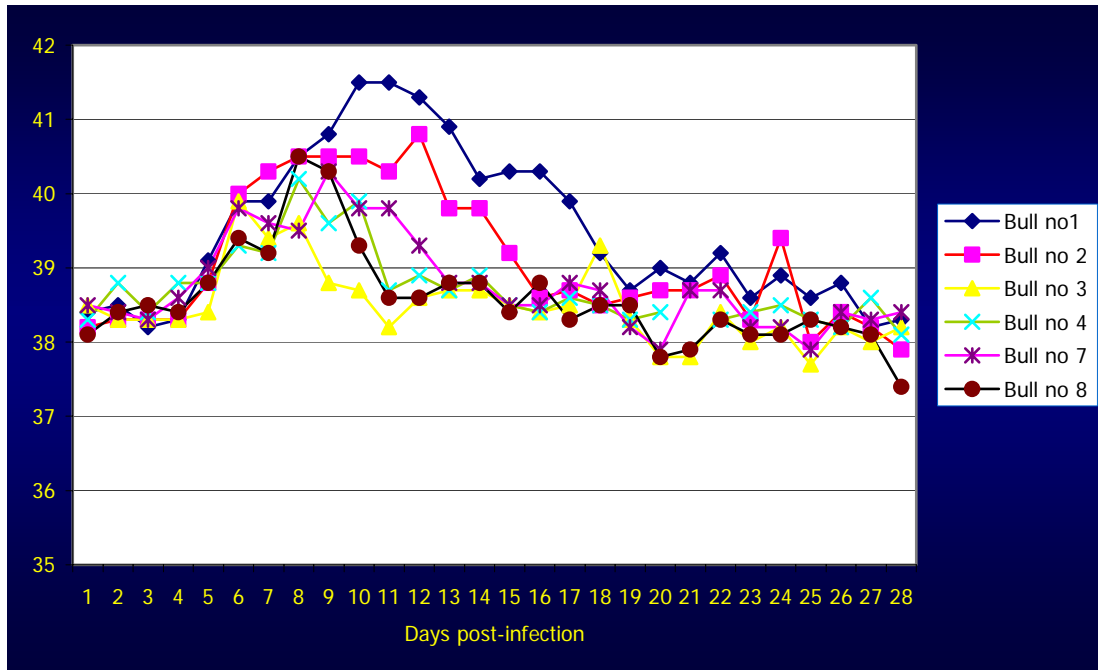


Figure 1: Temperature reaction in the bulls



Figure 2: Generalized skin lesions

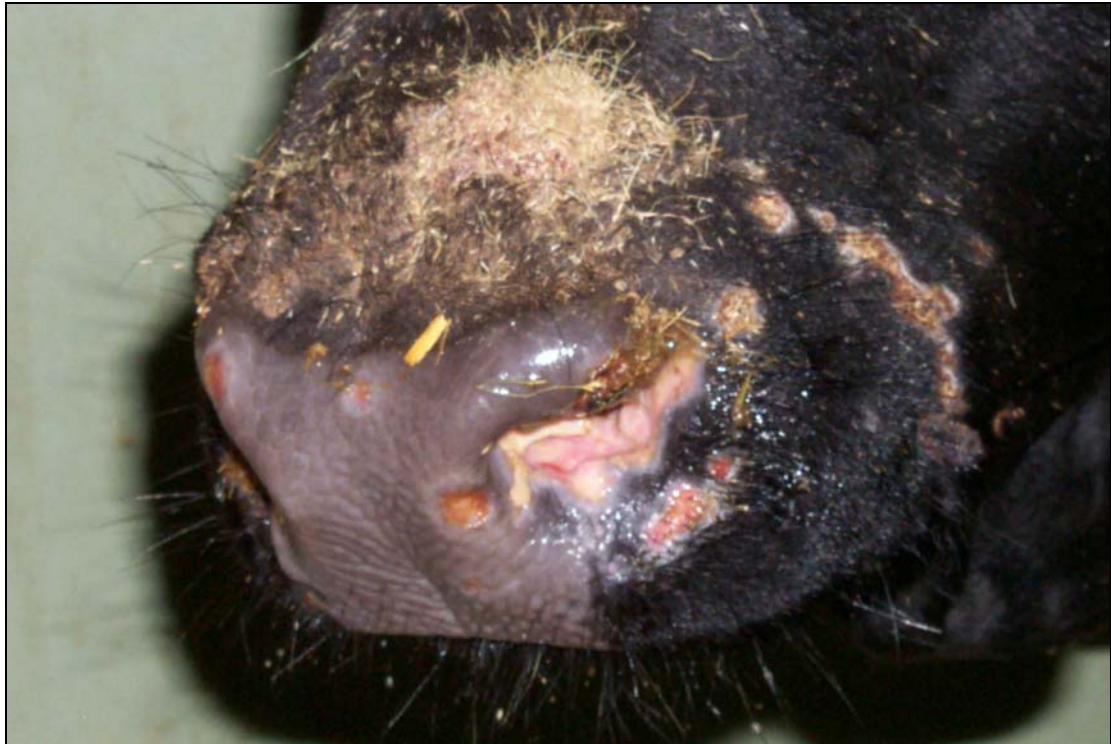

Figure 3: Ulcerative lesions on the muzzle and nostrils

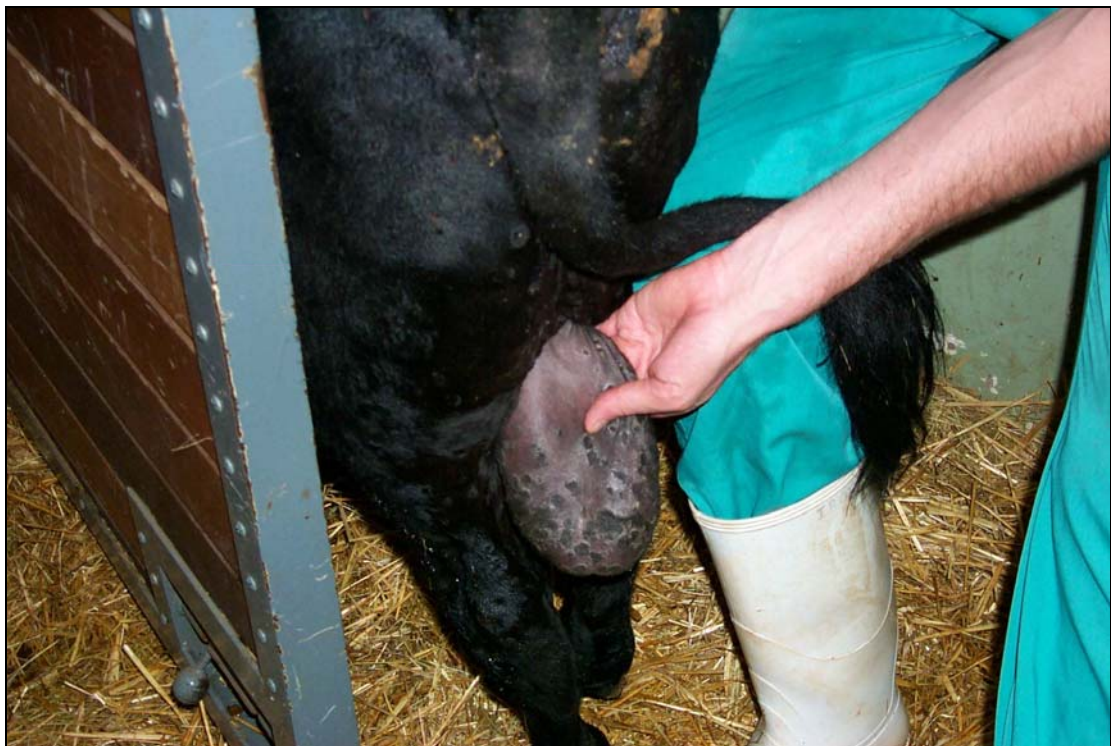


Figure 4: Lesions on the skin of the scrotum

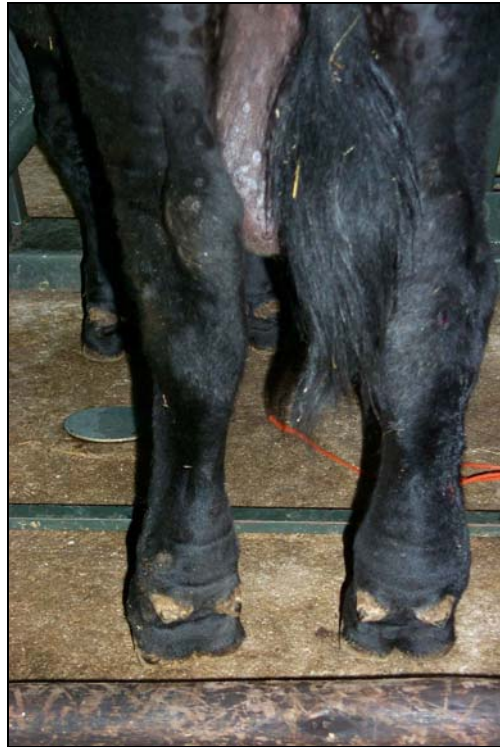

Figure 5: Subcutaneous oedema between the tarsal joint and fetlock of the right hind leg in Bull no. 1

## **Virus isolation**

### ***Heparinized blood samples***

Group 1: Virus was isolated from Bull no. 1 for 11 days from days 6 to 16 p.i. Fever started on day 5 p.i. and virus was isolated from the blood sample collected on the following day (day 6 p.i.). The rectal temperature of Bull no. 2 started to rise on day 6 p.i. and virus was isolated from its blood for 11 days between days 6 and 16 p.i.

Group 2: Virus was isolated from Bull no. 7 only once (on day 16 p.i.), 10 days after the fever had commenced (day 6 p.i.). From Bull no. 8 virus was isolated 4 times between days 5 and 16 p.i. (on days 5, 8, 10 and 16 p.i.). In Bull no. 8 virus was isolated one day (day 5 p.i.) before the rectal temperature started to rise (day 6 p.i.).

Group 3: From Bull no. 3 virus was isolated 3 times between days 11 and 16 (on days 11, 12 and 16 p.i.). Virus was isolated for the first time 5 days after the onset of fever (day 6 p.i.). From Bull no. 4 virus was isolated 7 times between days 5 (i.e. at the same day that the fever started) and 16 p.i. (on days 5, 6, 9, 10, 12, 14 and 16 p.i.).

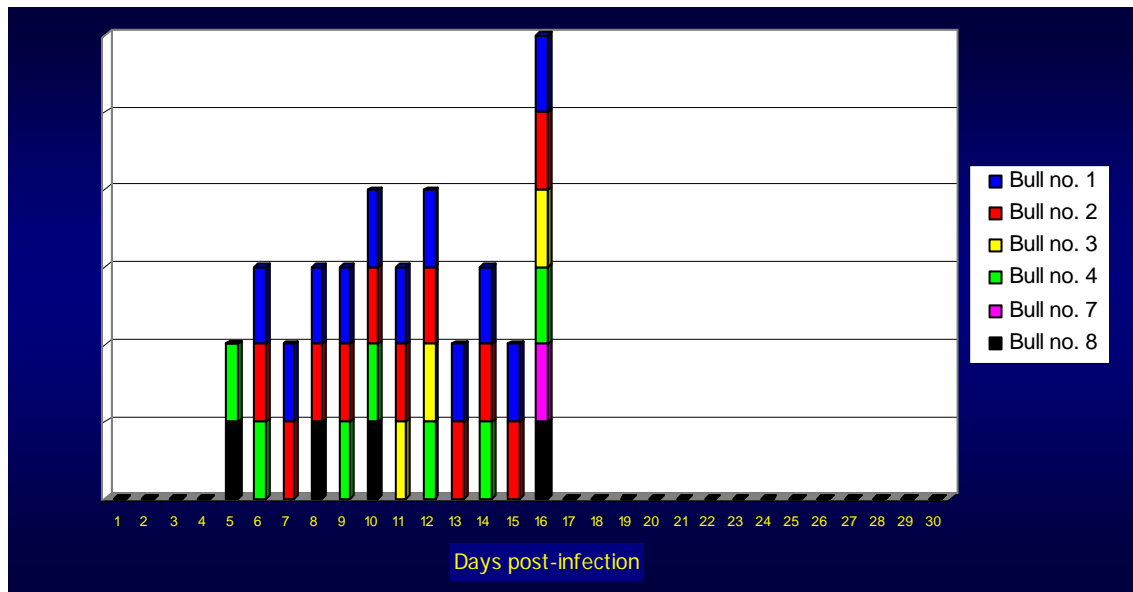


Figure 6: Virus isolations on bovine dermis cell cultures from blood samples collected in heparin

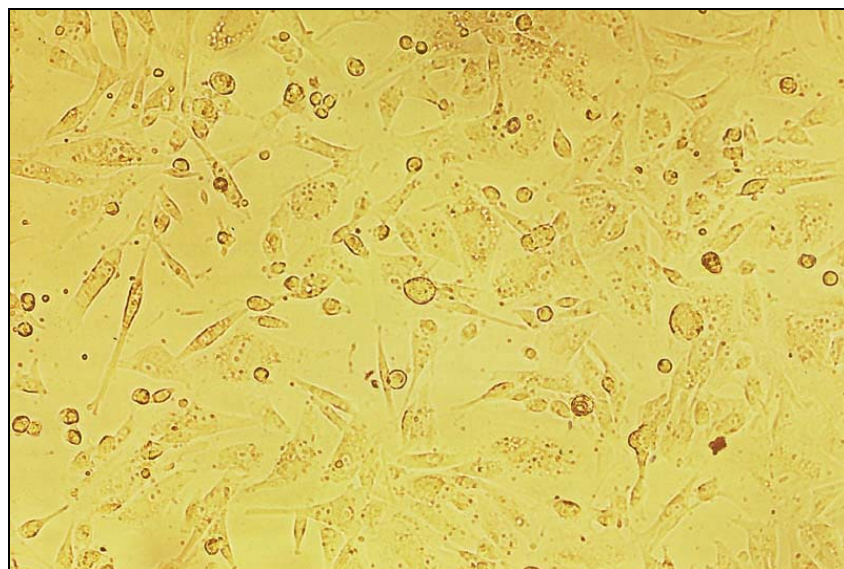


Figure 7: LSD virus isolation from a heparinized blood sample on bovine dermis cell culture showing typical CPE



### ***Skin biopsies***

Group 1: Virus was isolated from Bull no. 1 on day 10 p.i. when the first skin sample was collected and for the last time on day 39 p.i. From Bull no. 2 virus was isolated once, 26 days after the first skin lesions appeared; this was on day 33 p.i.

Group 2: No virus was isolated from skin biopsies collected from Bull no. 7. From the skin lesion of Bull no. 8 virus was isolated on day 10 p.i.

Group 3: The bulls of group 3 did not develop any skin lesions.

### ***Semen samples***

Group 1: Virus was isolated from semen samples of Bull no. 1 on days 9 and 11 p.i. All the other semen samples from this animal were negative. From the semen of Bull no. 2 virus was isolated 5 times on days 11, 15, 17, 19 and 43 p.i.

Group 2 and 3: No virus was isolated from semen samples collected from Bulls no. 3, 4, 7 and 8.

### **Polymerase chain reaction**

#### ***EDTA blood samples***

Group 1: Both Bulls no. 1 and 2 gave positive PCR results on days 2 and 3 p.i. Bull no. 1 was positive 7 times between days 8 and 14 p.i. (on days 8, 9, 10, 11, 12, 13 and 14). On day 24 p.i. it became positive again but only for one day. Bull no. 2 gave positive PCR results 7 times between days 5 and 15 p.i. (on days 5, 7, 9, 10, 12, 13 and 15). After the main viraemic period Bull no. 2 showed positive PCR results again on days 19, 25, 26 and 28 p.i.

Group 2: Bull no. 7 gave one positive PCR result on day 3 p.i. Then Bull no. 7 had PCR positive samples on days 5, 11 and 13 p.i. after which it remained negative. Bull no. 8 had positive results on days 9, 11 and 12 p.i. and one positive result on day 26 p.i.

Group 3: Bull no. 3 gave its first positive PCR result on day 4 p.i. Between days 10 and 13 p.i. it was PCR positive 3 times on days 10, 12 and 13 p.i. After 8 negative days it became positive again on days 22, 25 and 27 p.i. Bull no. 4 gave its first positive PCR result on day 3 p.i. Between days 9 and 15 p.i. it became positive again on days 9, 12, 14 and 15 p.i. and on days 19, 25 and 26 p.i.

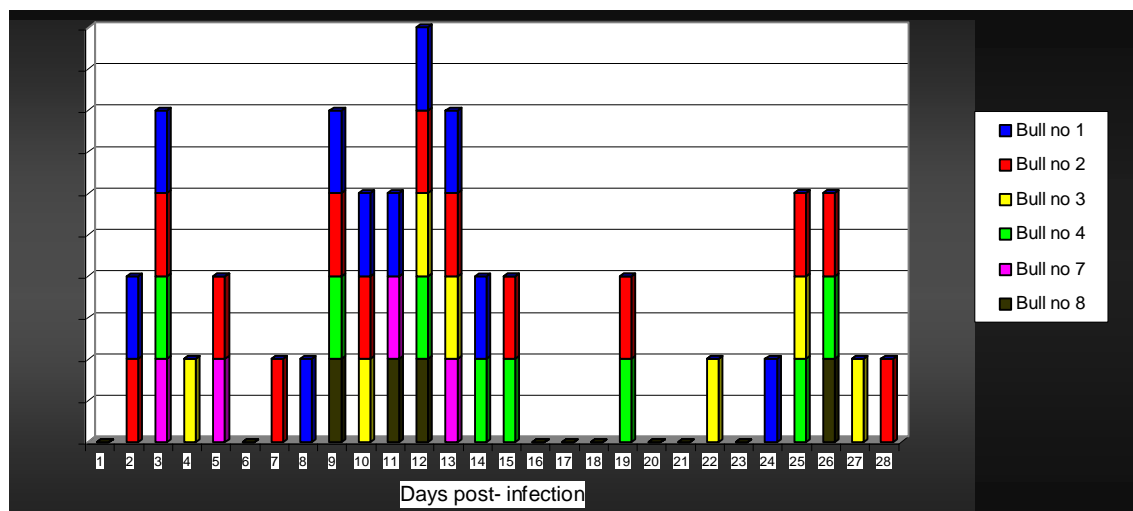


Figure 8: PCR results from EDTA blood samples

### *Skin biopsies*

Group 1: The first skin lesions appeared in Bull no. 1 on day 6 p.i. and Bull no. 2 on day 7 p.i. The PCR failed to detect viral DNA from the skin biopsy of Bull no. 1 collected on day 10 p.i. even though LSD virus was isolated in cell culture and it was demonstrated using TEM. From Bull no. 1, 17 samples were collected, mainly skin biopsies, but also some scabs. The first positive skin nodule was collected on day 18 p.i. and the skin biopsies of this bull

remained positive until day 92 p.i. However, skin biopsies collected from Bull no. 1 on days 25, 47, 75 and 81 p.i. were negative.

The first two skin samples collected on days 11 and 18 p.i. from Bull no. 2 were negative. It started to show positive PCR results on day 25 p.i. and, apart from a biopsy collected on day 81 p.i., it remained positive until day 85 p.i.

Group 2: Bulls no. 7 and 8 had very few skin lesions which occurred mainly in the area of the neck and back. Some nodules occurred on the perineal area. The first lesions in Bull no. 7 developed on day 10 p.i. and skin biopsies from it were positive on days 12 and 25 p.i. The skin nodule collected on day 18 p.i. was PCR negative. No skin lesions were observed after day 25 p.i. Skin lesions appeared in Bull no. 8 on day 8 p.i. The PCR demonstrated viral DNA from skin biopsies only 2 days after the appearance of the first skin lesion on day 10 p.i. This animal remained positive until day 18 p.i. The last skin nodule collected on day 25 p.i. was negative.

Group 3: These bulls did not have any skin lesions.

### ***Semen samples***

Group 1: Bull no. 1 showed positive PCR results in the semen sample collected on day 11 p.i. and the semen remained positive until day 161 p.i. Four out of 23 samples collected during this time period (on days 46, 98, 118 and 146 p.i.) were negative. The semen of Bull no. 2 tested positive between days 9 and 133 p.i. Seven out of 22 samples collected during this time period were negative (on days 13, 15, 19, 39, 46, 57 and 118). The semen samples collected from Bulls no. 1 and 2 on day 181 p.i. and 1 year and 1 month p.i. were negative.

Group 2: The PCR demonstrated only one positive sample on day 19 p.i. from Bull no. 7. Bull no. 8 was positive on day 11 p.i. and it remained positive until day 22 p.i.

Group 3: The semen samples collected from Bulls no. 3 and 4 were PCR positive on day 7 p.i. All the other samples from these animals were negative.

### **Indirect fluorescent antibody test**

Group 1: Serum samples collected from Bull no. 1 on days 1 and 7 p.i. were negative. Sera of Bull no. 1 became positive on day 10 p.i. and the end point titre of the serum collected from this bull on day 31 p.i. was 1:10240. Serum samples of Bull no. 1 collected on days 13, 16 and 34 p.i. were positive. The first serum samples of Bull no. 2 collected on days 1, 7 and 10 p.i. were negative when tested using the IFAT. The serum of Bull no. 2 showed positive fluorescence on day 13 p.i. No end point titre was determined. Serum samples from Bull no. 2 collected on days 16 and 34 p.i. were positive.

Group 2: The first serum samples collected from Bulls no. 7 and 8 on day 1 p.i. were negative. Serum samples of Bulls no. 7 and 8 showed positive fluorescence on day 7 p.i. The serum samples collected from these bulls on days 10, 13 and 16 p.i. were positive. The end point titre of serum collected from Bull no. 7 on day 31 p.i. was 1:2560. The end point titre of serum from Bull no. 8 was not determined.

Group 3: Bull no. 3 had the first positive titre on day 7 p.i. The end point titre of the serum sample collected from this animal on day 31 p.i. was 1:5120. Bull no. 4 became positive on day 10 p.i. The end point titre was not determined from Bull no. 4. All the other serum samples collected from Bull no. 3 after day 7 p.i. (on days 10, 13 and 16 p.i.) and from Bull no. 4 collected after day 10 p.i. (on days 13 and 16 p.i.) tested positive.

The results of end point titration of one representative of each group are shown in Table 3 and Figure 9.

Table 3: Indirect fluorescent test results

GROUP NO.	ANIMAL NO.	FIRST POSITIVE IFAT TITRE (DAY P.I.)	END POINT TITRE (31 DAYS P.I.)
1	1	10	1:10240
	2	13	ND
2	7	7	1:2560
	8	7	ND
3	3	7	1:5120
	4	10	ND

ND= not done

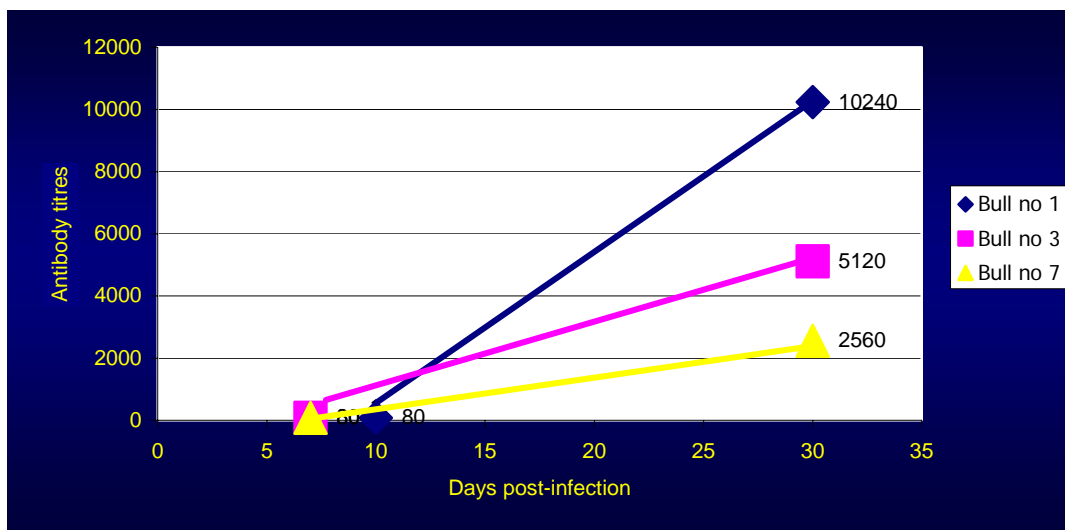


Figure 9: End point IFAT titres of the bulls

### Serum virus neutralization test

Group 1: In Bull no. 1 an increase in neutralizing antibody titres was detected on day 13 p.i. (8 days after the onset of fever and 7 days after the appearance skin lesions). On day 19 p.i. the antibody titre reached the

highest level and remained high for the duration of the trial (until day 99 p.i.). In Bull no. 2 a significant rise in antibody titres was detected between days 16 and 22 p.i. Antibodies were detectable 10 days after the onset of fever and 9 days after the appearance of skin lesions in Bull no. 2. The titre remained high at 1:160 until day 67 p.i. Thereafter the titres decreased slightly but remained between 1:40 and 1:112 until the last serum sample was collected on day 99 p.i.

Group 2: In Bull no. 7 an increase in antibody titre was detectable on day 16 p.i. (10 days after the onset of fever and 6 days after the appearance of skin lesions). The rise was slow and the titres remained low (between 1:20 and 1:40) until day 40 p.i. when the titre reached 1:80. On day 47 p.i. the peak titre of 1:160 was reached. Thereafter the titres decreased slowly until the end of the experiment but stayed between 1:40 and 1:80. In Bull no. 8 an increase in antibody titre was first detected on day 16 p.i. (10 days after the rise of fever and 8 days after the appearance of the skin lesions). Between days 19 and 34 p.i. the titres remained low (1:20 to 1:40). On day 43 p.i. the titre rose to 1:80 and on day 47 p.i. the titre reached a peak, which was between 1:80 and 1:160. Antibody levels remained between 1:40 and 1:80 for the rest of the trial.

Group 3: A significant rise in antibody titres in Bull no. 3 was detected on day 16 p.i. (10 days after the onset of fever). Between days 19 and 28 p.i. antibody titres increased to 1:80 and on day 31 p.i. the titre reached the peak level of 1:160 where they remained until day 67 p.i. The last serum sample from this animal was collected on day 71 p.i. and in this sample it had a significantly lower antibody titre of 1:40. In Bull no. 4 an increase in neutralizing antibody titres was observed on day 19 p.i. (14 days after the onset of the fever). The peak antibody titre, 1:160, was reached on day 31 p.i. The antibodies remained high until day 67 p.i. and then decreased to between 1:40 and 1:80 on day 71 p.i. when the last serum sample was collected.

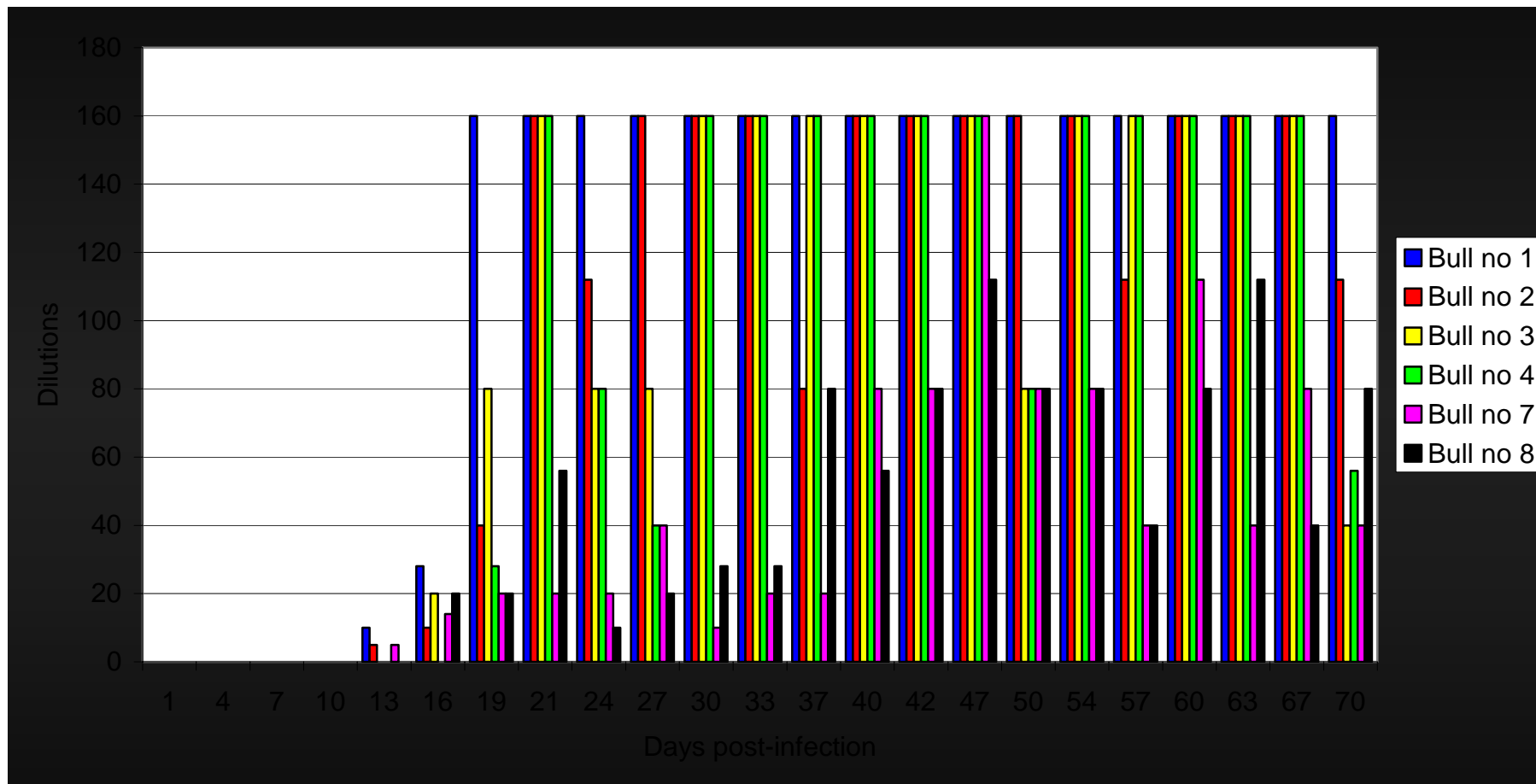


Figure 10: Serum virus neutralization titres of the bulls

## Transmission electron microscopy

The results of the TEM examinations are given in Table 4.

Group 1: Lumpy skin disease virus was detected in the first skin biopsy collected on day 10 p.i. from Bull no. 1, which was 4 days after the appearance of skin lesions. In biopsies collected on days 18 and 25 p.i. the virus was suspected but not confirmed. Virus was again detected from a specimen collected on day 33 p.i. No virus was detected in 10 biopsy specimens collected from Bull no. 1 between days 39 and 106 p.i. or from the skin specimens of Bull no. 2 collected between days 11 and 106 p.i. Virus was suspected in one skin nodule of Bull no. 2 collected on day 33 p.i.

Group 2: Bull no. 7 did not have any positive or suspected samples. Skin biopsies were collected from Bull no. 7 on days 12, 18 and 25 p.i. Only 3 skin samples were collected from Bull no. 8 on days 10, 18 and 25 p.i. Virus was suspected to be present in the skin lesion collected on day 25 p.i.

Table 4: Transmission electron microscopy results of the skin biopsies of the bulls

Days p.i.	Bull no. 1	Bull no. 2	Bull no. 7	Bull no. 8
10	Pos	ND	ND	Neg
11	ND	Neg	ND	ND
12	ND	ND	Neg	ND
18	Suspect	Neg	Neg	Neg
25	Suspect	Neg	Neg	Suspect
33	Pos	Suspect	ND	ND
39	Neg	Neg	ND	ND
47	Neg	Neg	ND	ND
54	Neg	ND	ND	ND
60	Neg	ND	ND	ND
67	Neg	ND	ND	ND
75	Neg	ND	ND	ND
81	Neg	ND	ND	ND
92	Neg	ND	ND	ND
99	Neg	Neg	ND	ND
106	Neg	Neg	ND	ND
113	Neg	ND	ND	ND

ND= not done



## **Histopathology**

### ***Haematoxylin and eosin-stained sections***

Group 1 and 2: The acute nodular skin lesions collected between days 10 and 25 p.i. were similar to those previously described (Prozesky and Barnard, 1982) and were characterized by multifocal necrosis of the epidermis and/or dermis. In some animals the necrosis and inflammatory response were limited to the dermis while the overlying epidermis was largely intact and only revealed necrosis of individual or small groups of keratinocytes in the *Stratum basale* and *Stratum germinativum*. The necrotic areas in the dermis were oedematous and infiltrated by inflammatory cells (moderate numbers of lymphocytes, macrophages and a few eosinophils and mast cells). These cells were particularly prominent around blood vessels in the dermis and subcutis adjoining the necrotic lesions. A few blood vessels in the dermis showed evidence of vasculitis.

In subacute and chronic skin lesions, collected between days 33 and 106 p.i. the inflammatory reaction in the dermis comprised moderate numbers of lymphocytes, macrophages, eosinophils and mast cells in and around the multifocal areas that showed evidence of fibroplasia. The latter reached an advanced stage of maturity in the lesions collected between days 54 and 106 p.i. Small pockets of inflammatory cells were still present in these fibrotic areas.

Group 3: Bulls no. 3 and 4 did not have any skin lesions.

### ***Immunoperoxidase staining***

Group 1 and 2: In acute skin lesions collected between days 10 and 25 p.i. the cytoplasm of individual or small groups of necrotic keratinocytes in the *Stratum basale* and *Stratum germinativum* as well as individual necrotic cells

(it was not possible to determine their identity) in the dermis stained reddish-dark brown. The cytoplasm of the mast cells in the dermis stained dark brown and many of the macrophages contained a yellowish-brown pigment (lipofuscin).

In subacute and chronic skin lesions, collected between days 33 and 106 p.i the cytoplasm of cells (probably mast cells) in the dermis in close proximity to the areas of fibrosis as well as in the fibrotic areas stained dark brown. Yellowish-brown pigment was present in many of the macrophages in the dermis.

Group 3: Bulls no. 3 and 4 did not have any skin lesions.

## CHAPTER 4

### DISCUSSION

The effective control and eradication of LSD in endemic and non-endemic areas requires rapid and accurate diagnostic methods to confirm a presumptive diagnosis. Recent research has focused mainly on transmission of the disease (Kitching and Taylor, 1985; Kitching and Mellor, 1986; Carn and Kitching, 1995a; Chihota *et al.*, 2001) and development of recombinant vaccines (Ngichabe *et al.*, 1997; Ngichabe *et al.*, 2002; Aspden *et al.*, 2002). No data of comparative studies of different diagnostic methods of LSD have been published. The use of the PCR for the detection of LSD virus nucleic acid from skin biopsies and tissue culture supernatant has been published (Ireland and Binopal, 1998; Markoulatos *et al.*, 2000) but no studies have been undertaken on the persistence of the virus in blood, skin and semen using the PCR.

A virulent, South African field isolate of LSD virus was used to infect six bulls experimentally. The intravenous route of infection was selected because previous data indicate this route to be the most effective way to produce severe generalized disease in experimentally infected cattle (Carn and Kitching, 1995a). The same volume and titre of virus suspension were used for all the animals.

#### **Clinical signs**

The incubation period of 4 to 5 days in the bulls in this study is in agreement with that reported in earlier publications, in which the incubation period after experimental infection was 4 to 14 days (Haig, 1957; Capstick, 1959; Prozesky and Barnard, 1982; Carn and Kitching, 1995b). All the bulls became infected and developed fever and viraemia. However, the severity of clinical manifestations varied in the bulls (Table 2). This correlates well

with earlier observations that less than half of cattle infected experimentally with LSD virus or naturally exposed during an outbreak will develop generalized disease (Weiss, 1968; Prozesky and Barnard, 1982; Carn and Kitching, 1995b). In our study two bulls developed severe disease (Table 2), two bulls showed mild disease and two bulls showed no clinical disease apart from a fever. The fever reaction correlated well with the development of clinical signs. Fever persisted for the longest period (12 days on average) in animals of group 1 that showed the most severe disease (Table 5). The mean duration of fever in mildly affected animals (group 2) was 6 days. The two animals that developed no clinical signs (group 3) had the shortest febrile reaction (4,5 days on average). No clear biphasic fever response as has been reported in previous publications (Barnard *et al.*, 1994) was detected. Slightly elevated rectal temperatures (39,2 - 39,4 °C) were observed between days 18 and 24 p.i. in Bulls no. 1 (day 22 p.i.), 2 (day 24 p.i.) and 3 (day 18 p.i.) (Figure 1).

Table 5: Temperature reaction related to the development of skin lesions

GROUP NO.	ANIMAL NO.	ONSET OF FEVER (DAY P.I.)	DURATION OF FEVER (DAYS)	AVERAGE DURATION OF FEVER (DAYS)	APPEARANCE OF SKIN LESIONS (DAY P.I.)
1	1	5	14	12	6
	2	6	10		7
2	7	6	7	6	10
	8	6	5		8
3	3	6	3	4,5	No skin lesions
	4	5	6		No skin lesions

Bulls no. 1, 2 and 8 developed skin lesions 1 to 2 days after the onset of fever. Bull no. 7 developed skin lesions 4 days after the rectal temperature started to rise. This finding correlates well with the observation that skin lesions appear within 48 hours of the first rise in temperature (Weiss, 1968)

or within 4 to 7 days of subcutaneous inoculation of the virus (Prozesky and Barnard, 1982).

### **Viraemia**

In this experiment bovine dermis cells (BDC) were chosen to be used in virus isolation because they are susceptible to LSD virus infection and show typical CPE. Although BDC are primary cells, they live long enough to ensure the isolation of the virus. In the present study the appearance of CPE took sometimes only 4 days but usually CPE was apparent between 7 to 10 days. On one occasion the appearance of CPE took as long as 12 days. Negative cell cultures were blind-passaged once or twice, to ensure that the results were negative.

The severity of clinical signs did not correlate with the length of viraemia in the infected bulls. Virus was isolated for the longest period of time (12 days) from the blood of Bull no. 4, which developed no clinical signs and Bull no. 8, which was only mildly affected. However, viraemic period in these bulls was only one day longer than in Bulls no. 1 and 2 that both showed severe disease (11 days). The mean length of viraemia detected by virus isolation in the animals of Group 2 and Group 3 was 6,5 days and 9 days respectively (Table 6). The viraemia in the bulls that developed no clinical signs persisted for a longer period on average than that in the bulls that showed mild disease.

No virus could be isolated from the blood samples of the bulls after day 16 p.i., which is similar to the observations of Carn and Kitching (1995b). The bulls remained viraemic for a longer period than has previously been determined. Weiss (1968) demonstrated virus in the blood of experimentally infected cattle for a period of 4 days following the appearance of fever and generalized skin lesions. In a more recent study LSD virus was isolated on lamb testis cells from blood samples of experimentally infected cattle for a

period of 9 days, from day 3 to day 11 p.i. (Carn and Kitching, 1995b). In the present study LSD virus was isolated from the blood of all the bulls for 1 to 12 days between days 5 and 16 p.i. When seven cattle were infected with LSD virus using the intradermal and subcutaneous routes at multiple sites on the side of the neck, viraemia was detected only from two animals using virus isolation technique (Prozesky and Barnard, 1982). The total volume of the virus suspension used in their study to infect each animal was 2 ml and the titres varied between 4,5 and 6,0 log TCID<sub>50</sub>.

In an experiment to determine the effect of the infecting dose and the route of infection, Carn and Kitching (1995b) used different titres of a virus suspension (2 to 6,5 log TCID<sub>50</sub>) to infect cattle by different routes. The volume of the inoculum was not mentioned. Friesian crosses (40 animals) were infected by placing LSD virus onto the conjunctiva (2 animals) or using the intranasal (2 animals), the intradermal (25 animals) and the intravenous (11 animals) routes. Eleven out of 25 animals infected intradermally developed only a local reaction at the inoculation site and a viraemia could be detected in two of them. Only five of all the 40 infected animals showed both severe generalized disease and a viraemia, which persisted for up to 9 days. Of these five animals, three were infected via the intravenous route, one intranasally and one via the intradermal route.

Virus was isolated from blood samples of 4 animals collected one day before (Bull no. 8), the same day (Bulls no. 2 and 4) or one day after (Bull no. 1) the onset of fever. However, from Bull no. 7, that showed mild disease, virus was isolated only 10 days after the onset of fever and from Bull no. 3 that did not develop clinical signs, virus was isolated 5 days after the onset of fever.

Depending how rapidly the confirmation the presumptive diagnosis is required the virus isolation technique may be too time-consuming because the members of the genus *Capripoxvirus* grow very slowly in cell cultures, the development of CPE may take up to 14 days during primary isolation

(Alexander *et al.*, 1957; Prydie and Coackley, 1959) and because several passages may be required before virus becomes adapted and will grow on cells. The results of this study indicated that in animals showing mild or inapparent disease it took 5 to 10 days after the onset of the febrile reaction before LSD virus was isolated from blood samples (Table 6), which may delay the confirmation of the diagnosis even more.

A tentative diagnosis of LSD is usually based on clinical signs. The disease in animals that develop only a few skin lesions and / or transient fever may therefore be difficult to diagnose and may be confused with pseudo-lumpy skin disease (Barnard *et al.*, 1994). The present study indicates that virus isolation on BDC cultures is a useful method but it may be too time-consuming to be used as a first diagnostic method. It is nevertheless a valuable tool to detect the viability of the virus but should be used in combination with other tests.

There are no published reports on the persistence of LSD virus in the blood of experimentally infected cattle using the PCR. In this study five of the bulls (no. 1-4 and 7) were found to be PCR-positive on days 2 to 4 p.i (Figure 8), the virus in the blood was probably the virus that was inoculated. The blood samples of all the animals were negative on day 6 p.i. The blood samples of all the experimental animals became PCR positive within 4 days after the onset of fever (mean 2 days) and skin lesions appeared approximately 1 to 4 days (mean 2 days) after the onset of the fever reaction (Table 6). In conclusion the results of this experiment indicated that the PCR was able to detect the nucleic acid of the LSD virus from the blood samples of the experimental bulls on the same day that the skin nodules appeared.

Bull no. 2 remained PCR positive for the longest period (11 days). The mean duration of the viraemic period in all the bulls determined using the PCR was 7 days and it was 8,8 days using virus isolation. The PCR could detect virus from animals that showed severe, mild and inapparent disease. The blood

samples of all the animals were PCR negative after day 15 p.i., which correlated well with virus isolation results (virus was isolated up to day 16 p.i.) (Table 6).

The blood samples of all the bulls except Bull no. 7 were PCR positive for 1 to 4 days between days 19 and 28 p.i. As discussed above Bulls no. 1 - 3 showed slightly elevated rectal temperatures between days 18 and 24. No virus could be isolated during this time period from the blood samples from any of the bulls. During this time Bulls no. 1 and 2 manifested severe skin lesions all over the entire body, Bull no. 8 showed very few lesions but Bulls no. 3 and 4 did not have any lesions. Virus was isolated from skin biopsies of Bull no. 1 between days 10 and 39 p.i. and from those of Bull no. 2 only on day 33 p.i. This finding indicates that the skin lesions contained viable virus between days 19 and 28 p.i. Semen samples from Bulls no. 1 and 2 were also PCR positive during this above mentioned time period (19 - 28 days p.i.). Semen samples of Bull no. 8 remained PCR positive only until day 22 p.i., whereas the blood sample of this animal was PCR positive on day 26 p.i. Virus was isolated from semen of Bull no. 2 on day 19 and even on day 42 p.i.

This study indicates the PCR to be a fast and sensitive diagnostic technique to detect LSD virus nucleic acid from blood samples.



Table 6: The temperature reaction and the appearance of skin lesions related to virus isolation and PCR results of blood samples. The numbers in brackets indicate the number of positive test results during the time period

GROUP NO.	ANIMAL NO.	ONSET OF FEVER (DAY P.I.)	APPEARANCE OF SKIN LESIONS (DAY P.I.)	POSITIVE VIRUS ISOLATION (DAYS P.I.)	VIRAEMIC PERIOD (DAYS)	POSITIVE PCR (DAYS P.I.)	VIRAEMIC PERIOD (DAYS)
1	1	5	6	6-16 (11x)	11	8-14 (7x)	7
	2	6	7	6-16 (11x)	11	5-15 (7x)	11
2	7	6	10	16 (1x)	1	5-13 (3x)	9
	8	6	8	5-16 (4x)	12	9-12 (3x)	4
3	3	6	no skin lesions	11-16 (3x)	6	10-13 (3x)	4
	4	5	no skin lesions	5-16 (7x)	12	9-15 (4x)	7

### Serological results

In this study the antibody response of the infected animals was assessed by SNT and IFAT. The results of the SNT were compared to those of the IFAT.

The SNT started to detected increased antibody titres in all the bulls between days 13 and 19 p.i., which was 8 to 14 days (mean 10,3 days) after the onset of fever and 6 to 9 days (mean 7,5) after the appearance of skin lesions (Table 7). In Bull no. 1 the titres remained high until day 99 p.i. when the last serum sample was collected. In Bulls no. 2, 3 and 4 the titres started to decrease between days 67 and 71 p.i. and in Bulls no. 7 and 8 after day 50 p.i. However, in all the bulls the titres remained clearly detectable (between 1:40 and 1:112) until the end of the trial (Figure 11).

The bulls with inapparent disease had only slightly lower antibody titres than those bulls that showed severe disease. Antibody titres of the bulls that showed mild disease were lower than in the other animals (Figure 11). This observation supports the finding that animals that have been vaccinated or showed mild disease develop low levels of neutralizing antibodies (Kitching and Hammond, 1992).

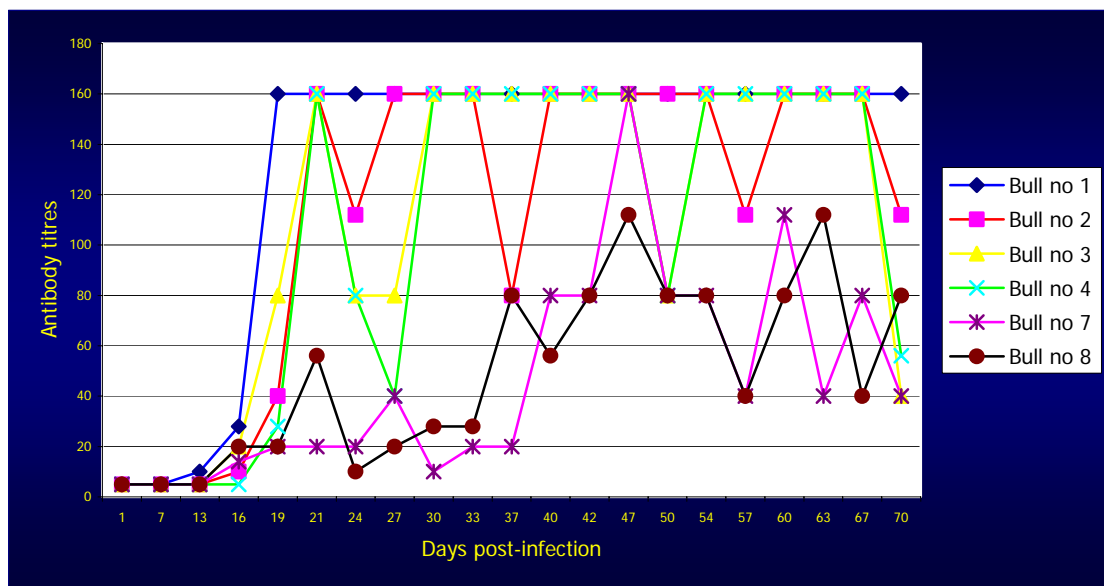


Figure 11: Comparison of the SNT antibody titres of experimentally infected bulls

This study indicated that the SNT is a reliable test for assessing antibodies against LSD virus. Because, the SNT started to detect increased antibody titres only 13 to 19 days p.i., an average of 10,3 days after the onset of fever and 7,5 days after the appearance of skin lesions, the SNT may not be able to detect increased antibody titres if a serum sample is collected less than a week after appearance of skin lesions.

The IFAT demonstrated a rise in antibody titres in 3 bulls as early as on day 7 p.i. The first increases in antibody titres were detected in Bulls no. 7 and 8 which developed mild disease and in Bull no. 3 that showed no clinical signs. The IFAT showed positive titres 1 to 7 days (mean 3,3 days) after the onset

of fever and either 1 to 3 days before or 4 to 6 days after (mean 1,5 days after) the skin lesions appeared (Table 7).

The animals reached high antibody titres (between 1:2560 and 1:10240) 31 days p.i., which is in agreement with earlier experiments with sheep pox where antibody titres of 1:5120 and 1:10240 were detected one month p.i. (Davies *et al.*, 1976). The highest antibody titre (1:10240) was detected in Bull no. 1 that showed severe disease. Bull no. 3 that did not develop any clinical signs had a titre of 1:5120. The lowest antibody titre was detected in Bull no. 7 that had a mild disease (Figure 9). This observation supports the finding that animals that have been vaccinated or showed mild disease develop low levels of neutralizing antibodies (Kitching and Hammond, 1992).

The interpretation of IFAT results is, however, subjective due to background fluorescence and non-specific staining of the cytoplasm of the cells and needs careful standardization before the results of the test can be interpreted. This study indicated that the IFAT is a fast and sensitive screening test to confirm the diagnosis of LSD. The IFAT has previously been successfully used for the diagnosis of sheep and goat pox (Davies *et al.*, 1976; Davies and Otema, 1978) and in epidemiological studies to assess the immune status of cattle and sheep (Davies and Otema, 1981).

The IFAT showed positive titres earlier after the onset of fever (mean 3,3 days) than the SNT (mean 10,3 days) (Table 7). Positive IFAT titres were obtained on average 1,5 days after the bulls developed skin lesions, which is earlier than those determined in the SNT (mean 7,5 days) (Table 7).

Table 7: The appearance of fever and skin lesions related to SNT and IFAT titres

GROUP NO.	ANIMAL NO.	ONSET OF FEVER (DAY P.I.)	APPEARANCE OF SKIN LESIONS (DAY P.I.)	FIRST POSITIVE SNT (DAY P.I.)	FIRST POSITIVE IFAT (DAY P.I.)
1	1	5	6	13	10
	2	6	7	16	13
2	7	6	10	16	7
	8	6	8	16	7
3	3	6	No skin lesions	16	7
	4	5	No skin lesions	19	10

### Skin lesions

*Virus isolation:* The reason why LSD virus could not be isolated from the skin biopsies collected from Bull no. 7, and why it was isolated only once from those collected from Bulls no. 2 and 8, is not clear. The concentration of the virus in the skin lesions may have been too low, the size of the sample may have been too small or a failure in the techniques used in processing the samples may have occurred.

Virus was isolated from the skin lesions of Bull no. 1 on days 10, 18, 33 and 39 p.i. In this animal LSD virus remained viable for 33 days after the appearance of skin nodules. From Bull no. 2 virus was isolated once, on day 33 p.i., which was 26 days after the appearance of the skin lesions. These results are in agreement with the earlier observation of Weiss (1968) that viable LSD virus particles remain for 33 days in the skin nodules after their first appearance.

*Transmission electron microscopy:* Transmission electron microscopy demonstrated LSD virus in skin biopsies of Bull no. 1 between days 10 and 33 p.i. This correlates well with the isolation of virus in cell cultures (days 10 to

39 p.i.). This finding also corresponds with the observations of Davies *et al.*, (1971) that virus could be detected by TEM in skin specimens collected between days 9 to 21 p.i. Why the virus was detected in the skin biopsies of only one experimental animal is unclear. Incorrect procedures used in preparing the samples could be a reason or perhaps more than one grid should have been prepared from each specimen as described by Davies *et al.*, (1971). The size of the sample may also have been too small, which resulted in the virus concentration in the specimen being too low.

*Polymerase chain reaction:* In Bulls no. 7 and 8 the PCR was able to detect LSD virus nucleic acid from the skin biopsies already 2 days after the appearance of skin nodules. However, it was not able to demonstrate LSD virus DNA from the first skin biopsy collected from Bull no. 1 on day 10 p.i. even though the virus was isolated in cell culture and detected by TEM. The negative result may indicate a failure in the DNA extraction procedure or the presence of DNA amplification inhibitors. In previous experiments done with sheep pox skin lesions, a dilution of skin biopsy samples at 1:10 was needed to remove DNA amplification inhibitors (Markoulatos *et al.*, 2000).

The PCR could demonstrate viral DNA in the skin biopsies of Bull no. 1 (until day 92 p.i.) and in Bull no. 2 (until day 85 p.i.) up to three months. The skin biopsies of the Bull no. 7 remained positive until the last skin nodule was collected on day 25 p.i. and Bull no. 8 until day 18 p.i. No viral DNA was detected from biopsies collected from healthy-looking skin after all the skin lesions had disappeared. Since the PCR only detects nucleic acid, this result does not necessarily imply that LSD virus remains infective for such a long time in skin lesions.

These observations indicate that the PCR is a more sensitive test to detect LSD virus or viral nucleic acid in skin biopsies than virus isolation or TEM examination. The results of TEM, VI and PCR are compared in Table 8. In previous studies the PCR has been shown to have a greater sensitivity to

detect capripoxviruses from skin biopsies than antigen trapping ELISA (Ireland and Binopal, 1998).

Table 8: Detection of LSD virus / nucleic acid in skin lesions using TEM, VI and PCR. The numbers in brackets indicate the number of positive test results during the time period

GROUP NO.	ANIMAL NO.	APPEARANCE OF SKIN LESIONS (DAY P.I.)	POSITIVE ELECTRON MICROSCOPY RESULTS (DAYS P.I.)	POSITIVE VIRUS ISOLATION (DAYS P.I.)	POSITIVE PCR (DAYS. P.I.)
1	1	6	10-33	10-39 (4x)	18-92 (11x)
	2	7	Suspected (day 33 p.i.)	33 (1x)	25-85 (8x)
2	7	10	None	None	12-25 (2x)
	8	8	Suspected (day 25 p.i.)	10 (1x)	10-18 (2x)
3	3	No skin lesions			
	4	No skin lesions			

*Light microscopy of sections of skin lesions stained with haematoxylin and eosin and immunoperoxidase:* The histopathological examination of the acute nodular skin lesions showed that the epidermis is not invariably severely affected in all animals and that the most prominent necrotic lesions and inflammatory reaction may be limited to the dermis. As the acute lesions in the dermis progress to the subacute to chronic stages (33 – 106 days p.i.) fibroplasia becomes more severe and more eosinophils and mast cells are present in the dermis in and around the lesions.

The immunoperoxidase stain employed by the Section of Pathology, Faculty of Veterinary Science make use of polyclonal antibodies to LSD virus. The cytoplasm of necrotic cells in the epidermis and dermis of acute lesions

stained reddish-dark brown with this technique while mast cells in the dermis of acute, subacute and chronic lesions stained dark brown. These subtle staining differences make it difficult or impossible to make a reliable diagnosis of LSD based on immunoperoxidase staining of skin lesions particularly during the subacute and chronic stages of the disease when virus or virus antigen is of low concentration.

## **Semen**

*Virus isolation:* Virus isolation was performed only on the semen samples of those bulls, whose semen was positive on the PCR. Toxicity, bacterial and fungal contaminations of the semen specimens were major problems during the attempts to isolate virus from them using cell culture technique. To avoid this, each sample was diluted 1:10 before the cell cultures were inoculated, the cells thereafter being observed for the first six hours after the inoculation. If evidence of toxicity did appear in the cell cultures, they were washed and new growth medium was added (see Chapter 2, Materials and methods, Diagnostic methods, Virus isolation, Semen samples).

Since all the semen samples were found to be contaminated, a mixture of 3 antibiotics and an antifungal solution was added to the growth medium, used for diluting the samples (see Chapter 2, Materials and methods, Diagnostic methods, Virus isolation, Semen samples). In many cases by the time that the growth medium in the flasks appeared to be cloudy the cells had already been irreversibly damaged.

Virus was isolated from the semen of the bulls that showed severe disease from 4 to 5 days after the onset of fever. In the semen of Bull no. 2 virus persisted until day 43 p.i., which was 37 days after the appearance of fever. Weiss (1968) was able to isolate LSD virus for 22 days following the appearance of fever and generalized skin lesions from the semen of experimentally infected animals.

*Polymerase chain reaction:* Semen samples of all the experimental animals were PCR positive on one or more occasions. The PCR started to detect LSD virus nucleic acid 7 to 11 days p.i. in the semen of Bulls no. 1, 2, 3, 4, and 8, which correlates with the time period when virus was first isolated from them. The semen of Bull no. 7 was PCR positive only on day 19 p.i. The semen of Bull no. 1 that developed severe disease remained PCR positive until day 161 p.i. and Bull no. 2 until day 133 p.i., whereas virus was isolated from the semen of Bull no. 1 only twice, i.e. on days 9 and 11 p.i., and from Bull no. 2 between days 11 and 43 p.i. In Table 9 the results of the PCR and virus isolation tests of semen samples are compared with the time of onset of fever and of skin lesions. These results indicate that the shedding of the LSD virus in semen continued for at least 43 days p.i. but the PCR was able to detect viral nucleic acid in the semen for up to 3 to 4 months p.i.

Table 9: The PCR and VI results of semen samples compared with the onset of the fever reaction and skin lesions. The numbers in brackets indicate positive test results during the time period

GROUP NO.	ANIMAL NO.	ONSET OF FEVER (DAY P.I.)	APPEARANCE OF SKIN LESIONS (DAY P.I.)	POSITIVE PCR (DAYS P.I.)	POSITIVE VIRUS ISOLATION (DAYS P.I.)
1	1	5	6	11-161 (19x)	9-11 (2x)
	2	6	7	9-133 (15x)	11-43 (5x)
2	7	6	10	19	None
	8	6	8	11-22 (6x)	None
3	3	6	No skin lesions	7	None
	4	5	No skin lesions	7	None

According to previous work, LSD virus could be isolated from the semen of experimentally infected bulls for a period of 22 days following the appearance



of fever and generalized skin lesions (Weiss, 1968). No data have previously been published on the persistence of LSD virus in semen using the PCR.

The persistence of bovine viral diarrhoea (BVD) virus in semen was evaluated after intranasal infection of 3 postpubertal bulls (Givens *et al.*, 2003). Virus was isolated from the semen of 2 animals for less than 21 days p.i., whereas reverse transcription - nested polymerase chain reaction (RT-nPCR) detected BVD virus DNA until 7 months after inoculation. Virus was detected in testicular biopsy specimens of 2 of these bulls by immunohistochemical analysis and RT-nPCR but could only be isolated from the biopsy specimen of one bull.

The PCR demonstrated the presence of LSD virus significantly longer than virus isolation. The PCR is more sensitive in detecting lower numbers of virus or viral particles. Further work is still needed to determine how long LSD virus remains infective in semen, the possible persistence of the virus in male sex organs, and whether the disease can be transmitted by the venereal route.

In conclusion, this study revealed that the PCR and IFAT are useful methods for a rapid confirmation of the diagnosis of LSD. The PCR could demonstrate LSD virus nucleic acid in blood, skin and semen samples. Using both PCR and virus isolation techniques the persistence of the virus in blood, semen and skin of experimentally infected animals was found to be for longer than has previously been shown. The SNT was shown to be reliable to detect increased antibody titres in all the bulls in this experiment. However, it could not detect a low antibody titres in serum samples collected less than a week after appearance of fever and skin nodules. For this reason the SNT is more useful for epidemiological studies than for a rapid confirmation of a tentative diagnosis.

REFERENCES

- 1 ALEXANDER, R.A., PLOWRIGHT, W., & HAIG, D.A. (1957).  
Cytopathogenic agents associated with lumpy skin disease of cattle.  
*Bulletin of Epizootic Diseases of Africa* 5, 489-492.
- 2 ALI, B.H. & OBEID, H.M. (1977). Investigation of the first outbreaks of  
lumpy skin disease in the Sudan. *British Veterinary Journal* 133, 184-  
189.
- 3 ALI, A.A., ESMAT, M., ATTIA, H., SELIM, A. & ABDEL-HAMID, Y.M.  
(1990). Clinical and pathological studies on lumpy skin disease in  
Egypt. *The Veterinary Record* 127, 549-550.
- 4 ASPDEN, K., VAN DIJK, A.A., BINGHAM, J., COX, D., PASSMORE, J.A.  
& WILLIAMSON, A.L. (2002). Immunogenicity of a recombinant lumpy  
skin disease virus (Neethling vaccine strain) expressing the rabies virus  
glycoprotein on cattle. *Vaccine*, 20, (21-22), 2693-2701.
- 5 BARNARD, B.J.H. (1997). Antibodies against some viruses of domestic  
animals in South African wild animals. *Onderstepoort Journal of  
Veterinary Research* 64, 95-110.
- 6 BARNARD, B.H.J., MUNZ, E., DUMBELL, K. & PROZESKY, L. (1994).  
Lumpy skin disease. *In: Infectious diseases of livestock with special  
reference to Southern Africa*, Vol.1 (Coetzer, J.A.W., Thomson, G.R.,  
Tustin, R.C. & Kriek, N.P.J.), 604-612. Oxford University Press, Cape  
Town.

- 7 BLACK, D.N., HAMOND, J.M. & KITCHING, R.P. (1986). Genomic relationship between capripoxviruses. *Virus Research* 5, 277-292.
- 8 BOULTER, E.A. & APPELYARD, G. (1973). Differences between extracellular and intracellular form of poxvirus and their implications. *Prog. Med. Virol.* 16, 86-108.
- 9 BURDIN, M.L. (1959). The use of histopathological examinations of skin material for the diagnosis of lumpy skin disease in Kenya. *Bulletin of Epizootic Diseases of Africa* 7, 27.
- 10 CAPSTICK, P.B. (1959). Lumpy skin disease – experimental infection. *Bulletin of Epizootic Diseases of Africa* 7, 51-62.
- 11 CAPSTICK, P.B. & COACKLEY, W. (1961). Protection of cattle against lumpy skin disease. I. Trials with a vaccine against Neethling type infection. *Research in Veterinary Science* 2, 362-368.
- 12 CARN, V.M. (1993). Control of capripox virus infections. *Vaccine*, Vol. 11, issue 13, 1275-1579.
- 13 CARN, V.M. (1995). An antigen trapping ELISA for the detection of capripoxvirus in tissue culture supernatant and biopsy samples. *Journal of Virological Methods* 51, 95-102.
- 14 CARN, V.M. & KITCHING, R.P. (1995a). An investigation of possible routes of transmission of lumpy skin disease virus (Neethling). *Epidemiology and Infection* 114, 219-226.
- 15 CARN, V.M. & KITCHING, R.P. (1995b). The clinical response of cattle experimentally infected with lumpy skin disease (Neethling) virus. *Archive of Virology* 140, 503-513.

- 16 CARN, V.M., KITCHING, R.P., HAMMOND, J.M. & CHAND, P. (1994). Use of a recombinant antigen in an indirect ELISA for detecting bovine antibody to capripoxvirus. *Journal of Virological Methods* 49, 285-294.
- 17 CHIHOTA, C.M., RENNIE, L.F., KITCHING, R.P. & MELLOR, P.S. (2001). Mechanical transmission of lumpy skin disease virus by *Aedes aegypti* (Diptera: Culicidae). *Epidemiology and Infection*, 126, 317-321.
- 18 DAVIES, F.G. (1976). Characteristics of a virus causing a pox disease in sheep and goats in Kenya, with observations on the epidemiology and control. *Journal of Hygiene, Cambridge*, 76, 163-171.
- 19 DAVIES, F.G. (1991). Lumpy skin disease of cattle: a growing problem in Africa and the Near East. *World Animal Review* 68 (3), 37-42.
- 20 DAVIES, F.G., JESSETT, D.M. & OTIENO, S. (1976). The antibody response of sheep following infection with Nairobi sheep disease virus. *Journal of Comparative Pathology* 86, 497-502.
- 21 DAVIES, F.G., KRAUSS, H., LUND, J. & TAYLOR, M. (1971). The laboratory diagnosis of lumpy skin disease. *Research in Veterinary Science* 12, 123-127.
- 22 DAVIES, F.G. & OTEMA, C. (1978). The antibody response in sheep infected with a Kenyan sheep and goat poxvirus. *Journal of Comparative Pathology* 88, 206-210.
- 23 DAVIES, F.G. & OTEMA, C. (1981). Relationships of capripoxviruses found in Kenya with two Middle Eastern strains and some orthopoxviruses. *Research in Veterinary Science* 31, 253-255.

- 24 FENNER, F., BACHMANN, P.A., GIBBS, E.P.J., MURPHY, F.A., STUDDERT, M.J. & WHITE, D.O. (1987). Poxviridae. *Veterinary Virology*. New York, London, Sydney, Tokyo, Toronto: Academic Press, 387-405.
- 25 GIVENS, M.D., HEALTH, A.M., BROCK, K.V., BRODERSEN, B.W., CARLSON, R.L. & STRINGFELLOW, D.A. (2003). Detection of bovine viral diarrhoea virus in semen obtained after inoculation of seronegative postpubertal bulls. *American Journal of Veterinary Research* 64, 428-434.
- 26 GREEN, H.F. (1959). Lumpy skin disease: its effect on hides and leather and a comparison on this respect with some other skin diseases. *Bulletin of Epizootic Diseases of Africa* 7, 63.
- 27 GRETH, A., GOURREAU, J.M., VASSART, M., NGUYEN-BA-VY, WYERS, M. & LEFEVRE, P.C. (1992). Capripoxvirus disease in an Arabian Oryx (*Oryx leucoryx*) from Saudi Arabia. *Journal of Wildlife Diseases* 28 (2), 295-300.
- 28 GUBBELS, J.M., DE VOS, A.P., VAN DER WEIDE, M., VISERAS, J., SCHOOLS, L.M., DE VRIES, E. & JONGEJAN, F. (1999). Simultaneous detection of bovine *Theileria* and *Babesia* species by reverse line blot hybridisation. *Journal of Clinical Microbiology* 37, (6), 1782-1789.
- 29 HAIG, D.A. (1957). Lumpy skin disease. *Bulletin of Epizootic Diseases of Africa* 5, 421-430.
- 30 HAINES, D.H. & CHELACK, B.J. (1991). Technical considerations for developing enzyme immunohistochemical staining procedures on

- formalin-fixed paraffin-embedded tissues for diagnostic pathology. *Journal of Veterinary Diagnostic Investigation* 3, 101-112.
- 31 HAINES, D.H. & CLARK, E.G. (1991). Enzyme immunohistochemical staining of formalin-fixed tissues for diagnosis in veterinary pathology. *Canadian Veterinary Journal* 32, 295-302.
- 32 HENNING, M.W. (1956). Animal diseases in South Africa, 3<sup>rd</sup> edition, C.N.A., Cape Town.
- 33 HEDGER, R.S. & HAMBLIN, C. (1983). Neutralising antibodies to lumpy skin disease virus in African wildlife. *Comparative Immunology and Microbiology of Infectious Diseases* 6 (3), 209-213.
- 34 HEINE, H.G., STEVENS, M.P., FOORD, A.J. & BOYLE, D.B. (1999). A capripoxvirus detection PCR and antibody ELISA based on the major antigen P32, homologue of the vaccinia virus H3L gene. *Journal of Immunological Methods* 227, 187-196.
- 35 HOUSTON, P.D. (1945). Report of the chief veterinary surgeon, Southern Rhodesia.
- 36 IRELAND, D.C. & BINEPAL, Y.S. (1998). Improved detection of capripoxvirus in biopsy samples by PCR. *Journal of Virological Methods* 74 (1), 1-7.
- 37 KITCHING, R.P. (1986). Passive protection of sheep against capripoxvirus. *Research in Veterinary Science* 41, 247-250.
- 38 KITCHING, R.P., BHAT, P.P., BLACK, D.N. (1989). The characterization of African strains of capripoxvirus. *Epidemiology and Infection* 102, 335-343.

- 39 KITHING, R.P. & HAMMOND, J.M. (1992). Poxvirus, infection and immunity. *In: Encyclopaedia of immunology* Vol. 3 (Roitt, I. M. and Delves, P. J., 3<sup>rd</sup> edition), pp. 1261-1264. Academic press, London.
- 40 KITCHING, R.P., HAMMOND, J.M. & BLACK, D.N. (1986a). Studies on the major common precipitating antigen of capripoxvirus. *Journal of General Virology*, 67, 139-148.
- 41 KITCHING, R.P., HAMMOND, J.M. & TAYLOR, W.P. (1986b). A single vaccine for the control of capripox infection in sheep and goats. *Research in Veterinary Science*, 42, 53-60.
- 42 KITCHING, R.P. & MELLOR, P.S. (1986). Insect transmission of capripoxvirus. *Research in Veterinary Science*. 40, 255-258.
- 43 KITCHING, R.P. & SMALE, C. (1986). Comparison of external dimensions of capripoxvirus isolates. *Research in Veterinary Science* 41, 425-427.
- 44 KITCHING, R.P. & TAYLOR, W.P. (1985). Transmission of capripoxviruses. *Research in Veterinary Science* 39, 196-199.
- 45 LE ROUX, P.L. (1945). Notes on the probable cause, prevention and treatments of pseudo-urticaria and associated septic conditions in cattle. Northern Rhodesia Department of Animal Health, *Newsletter*, pp.1-4. Cited by WEISS, K.E. (1968).
- 46 MACDONALD, R.A.S. (1931). Pseudo-urticaria of cattle. Northern Rhodesia Department of Animal Health. *Annual Report*, 1930, pp. 20-21. Cited by WEISS, K.E. (1968).

- 47 MACOWAN, R.D.S. (1959). Observation on the epizootiology of lumpy skin disease during the first year of its occurrence in Kenya. *Bulletin of Epizootic Diseases of Africa* 7, 7-20.
- 48 MARKOULATOS, P., MANGANA-VOUGIOUKA, O., KOPTOPOULOS, G., NOMIKOU, K. & PAPADOPOULOS, O. (2000). Detection of sheep poxvirus in skin samples by a multiplex polymerase chain reaction. *Journal of Virological Methods* 84 (2), 161-167.
- 49 MORRIS, J.P.A. (1931). Pseudo-urticaria. Northern Rhodesia Department of Animal Health. *Annual Report*, 1930, p. 12. Cited by WEISS, K.E. (1968).
- 50 MUNZ, E.K. & OWEN, N.C. (1966). Electron microscopic studies on lumpy skin disease virus type "Neethling". *Onderstepoort Journal of Veterinary Research* 33, 3-8.
- 51 NAWATHE, D.R., GIBBS E.P.J., ASAGBA, M.O. & LAWMAN, M.J.P. (1978). Lumpy skin disease in Nigeria. *Tropical Animal Health and Production* 10, 49-54.
- 52 NGICHABE, C.K., WAMWAYI, H.M., BARRETT, T., NDUNGU, E.K., BLACK, D.N., & BOSTOCK, C.J. (1997). Trial of capripoxvirus-rinderpest recombinant vaccine in African cattle. *Epidemiology and Infection* 118, 63-70.
- 53 NGICHABE, C.K., WAMWAYI, H.M., NDUNGU, E.K., MIRANGI, P.K., BOSTOCK, C.J., BLACK, D.N. & BARRETT, T. (2002). Long term immunity in African cattle vaccinated with recombinant capripox-rinderpest virus vaccine. *Epidemiology and Infection* 128, (2), 343-349.



- 54 OIE Handistatus II, Multiannual animal disease status, computer database, <http://www.oie.int/hs2/report.asp?lang=en>
- 55 OIE's Terrestrial Animal Health Code, computer database, [http://www.oie.int./eng/normes/mcode/A\\_00036.htm](http://www.oie.int./eng/normes/mcode/A_00036.htm)
- 56 PLOWRIGHT, W. & FERRIS, R.D. (1959). Ether sensitivity of some mammalian poxviruses. *Virology* 7, 357.
- 57 PROZESKY, L. & BARNARD, B.J.H. (1982). A study of the pathology of lumpy skin disease in cattle. *Onderstepoort Journal of Veterinary Research* 49, 167-175.
- 58 PRYDIE, J. & COACKLEY, M. (1959). Lumpy skin disease: tissue culture studies. *Bulletin of Epizootic Diseases of Africa* 7, 37-50.
- 59 REED, L.J. & MUENCH, H. (1938). A simple method of estimating fifty per cent endpoints. *American Journal of Hygiene* 27, 493-497.
- 60 SCHWARTZ, I., VARDE, S., NADELMAN, R.B., WORMSEL, P. & FISH, D. (1997). Inhibition of efficient polymerase chain reaction amplification of *Borrelia burgdorferi* DNA in blood-fed ticks. *American Journal of Tropical Medicine and Hygiene* 56 (3), 339-342.
- 61 THOMAS, A.D. & MARÉ, C.v.E. (1945). Knopvelsiekte. *Journal of South African Veterinary Medical Association* 16, 36-43.
- 62 THOMAS, A.D., ROBINSON, E.M. & ALEXANDER, R.A. (1945). Lumpy skin disease-Knopvelsiekte. *Onderstepoort Division of Veterinary Services, Veterinary Newsletter* 10.
- 63 VAN ROOYEN, P.J., MUNZ E.K. & WEISS K.E. (1969). The optimal conditions for the multiplication of the Neethling-type lumpy skin

- disease virus in embryonated eggs. *Onderstepoort Journal of Veterinary Research* 36 (2), 165-174.
- 64 VON BACKSTROM, U. (1945). Ngamiland cattle disease: Preliminary report on a new disease, the etiological agent being probably of an infectious nature. *Journal of South African Veterinary Medical Association* 16, 29-35.
- 65 YERUHAM, I., PERL, S, NYSKA, A., ABRAHAM, A., DAVIDSON, M., HAYMOVITCH, M., ZAMIR, O. & GRINSTEIN, H. (1994). Adverse reactions in cattle to a capripox vaccine. *Veterinary Record*, 135, 330-332.
- 66 YERUHAM, I., NIR, O., BRAVERMAN, Y., DAVIDSON, M., GRINSTEIN, H., HAYMOVITCH, M. & ZAMIR, O. (1995). Spread of lumpy skin disease in Israel dairy herds. *The Veterinary Record* 137, 91-93.
- 67 YOUNG, E., BASSON, P.A. & WEISS, K.E. (1970). Experimental infection of game animals with lumpy skin disease virus (prototype strain Neethling). *Onderstepoort Journal of Veterinary Research* 37, 79-88.
- 68 WEISS, K.E. (1968). Lumpy skin disease virus. *Virology Monographs* 3, 111-131.
- 69 WOODROOFE, G.M. & FENNER, F. (1962). Serological relationship within the poxvirus group: an antigen common to all members of the group. *Virology* 16, 334-341.
- 70 WOODS, J.A. (1988). Lumpy skin disease-a review. *Tropical Animal Health and Production* 20, 11-17.