

**UTILISING RADIOGRAPHIC INCISOR CROWN  
MARKERS TO DETERMINE INCISOR INCLINATION  
ON LATERAL HEADFILMS – AN EXPERIMENTAL  
STUDY ON EXTRACTED TEETH**

**Dr Alfred Meyer Dippenaar**

---

**UTILISING RADIOGRAPHIC INCISOR CROWN  
MARKERS TO DETERMINE INCISOR INCLINATION  
ON LATERAL HEADFILMS – AN EXPERIMENTAL  
STUDY ON EXTRACTED TEETH**

**Dr Alfred Meyer Dippenaar**

BChD; MSc (Odont) (Pret)

**Submitted in partial fulfilment of the requirements for  
the degree:**

**MChD (Orthodontics)**

**In the Department of Orthodontics  
School of Dentistry  
Faculty of Health Sciences  
University of Pretoria  
PRETORIA**

**Supervisor: Professor S T Zietsman**

**March 2003**

---

## ACKNOWLEDGEMENTS

I would like to extend my gratitude to the following people, who have contributed significantly to the completion of this research report:

- Professor S.T. Zietsman, research leader in the Department Orthodontics, who was my study leader, for his continuous support, motivation and guidance.
- Mr. Jonathan Levin for the statistical analysis.
- Staff members of the Department of Radiography.
- Staff members of the Department of Orthodontics , for assisting me in the collection of data and moral support with special reference to Dr. Piet Botha for his continuous guidance and support.
- My co-registrars in the Department of Orthodontics, with special reference to Dr. D Mistry who can only be described as a “computer whiz!”
- My wife and three daughters – the women in my life for their patience with and support to the ever-busy student in the house!

## DECLARATION

I declare that the study: **“Utilising radiographic incisor crown markers to determine incisor inclination on lateral head films – an experimental study on extracted teeth”**

I am submitting for the MChD (Orthodontics) degree at the University of Pretoria, is my own work and has not been submitted for a degree at any other university before.

\_\_\_\_\_  
ALFRED MEYER DIPPENAAR

\_\_\_\_\_  
DATE

\_\_\_\_\_  
COMMISSIONER OF OATHS

\_\_\_\_\_  
DATE

## **ABSTRACT**

### **UTILISING RADIOGRAPHIC INCISOR CROWN MARKERS TO DETERMINE INCISOR INCLINATION ON LATERAL HEADFILMS – AN EXPERIMENTAL STUDY ON EXTRACTED TEETH.**

**ALFRED MEYER DIPPENAAR**

**Supervisor: Professor S.T Zietsman**  
**Department: Orthodontics**  
**School of Dentistry**  
**Faculty of Health Sciences**  
**University of Pretoria**

Inaccuracy in landmark identification is regarded as the most important source of error in cephalometry. Better definition of landmarks should therefore contribute to better clinical decisions and research validity.

This study primarily comprised of an ex vivo investigation on 50 extracted lower incisor teeth to determine whether radiopaque markers could be utilised to accurately assess lower incisor inclination. Fifty extracted lower incisor teeth were mounted onto a Perspex sheet. Radiopaque markers, manufactured from 1mm wide strips of lead film from used peri-apical radiographs, were attached to the crowns of the mounted teeth. A lateral cephalometric radiograph was taken in accordance to standard radiographic procedures (radiograph A). This showed the true inclination of the teeth. A second radiograph was taken with the roots obscured (radiograph B). Three observers traced the inclinations of the teeth on radiograph B (from incisor edge through the middle of the labio-lingual crown-root junction). The determination was done on two different occasions and the assessments compared with the true inclination. Comparative statistical analysis was applied to the readings and the results indicated that this method compared favourably with other methods to determine incisor inclination. In addition, clinical application of opaque markers to the teeth of patients demonstrated the following: it indicated exactly which tooth was being assessed, provided clear definition of the anatomical crown in the sagittal

plane and served as a constant reference point for clinical, study model and cephalometric measurements.

Opaque radiographic markers on teeth can contribute to more accurate cephalometric measurements in orthodontics, leading to better diagnoses, treatment planning and research validity.

---

***Key words:*** *orthodontics, lateral cephalometric radiographs, cephalometry, incisor inclination, radiographic markers, dental radiographic markers, determining incisor inclination.*

## SUMMARY

Great emphasis is placed on measurements taken from the lower incisor crown and the lower incisor inclination in clinical orthodontics as well as in orthodontic treatment comparison studies. It is however difficult to accurately define the lower incisor on lateral cephalometric radiographs, a limiting factor in cephalometry. More exact definition of the lower incisor should thus contribute to improved clinical decisions and research validity.

The main aim of this investigation was to determine whether using radiographic markers to outline the crown of the lower incisor on a lateral cephalometric radiograph could enhance accurate assessment of the lower incisor inclination.

The study consists of a theoretical as well as a empirical section. In the theoretical section literature concerning the relevance of the mandibular incisors in orthodontics, radiographic principles and sources of error in cephalometry and different methods currently used to determine lower incisor inclination are discussed. For the empirical study 50 extracted lower incisor teeth were mounted onto a Perspex sheet. Radiographic markers were manufactured by cutting approximately 1mm wide strips from the lead film of used periapical radiographs. The radiographic markers were attached to the crowns of the 50 mounted teeth and a lateral cephalometric radiograph was taken according to standard radiographic procedures (radiograph A). A second radiograph was taken with the roots obscured (radiograph B). Three observers traced the inclinations of the teeth on radiograph B on two different occasions.

Method comparison statistical analysis was applied to the readings and the results indicated that a line through the tip of the lower incisor and bisecting the crown in the sagittal dimension at the crown root junction is a valid method to establish the relevant tooth inclination (std.dev. 3.0°). The precision achieved by this method therefore compared favourably with other methods to determine incisor inclination.

From this study and the clinical examples provided, the results of this experimental study can be summarised as follows:

1. it clearly indicated which tooth was assessed on the lateral cephalometric radiograph.
2. it provided a clear indication of the anatomical crown in the sagittal dimension even when the tooth was rotated.
3. it improved accurate measurements from the incisor crown providing a constant reference point for clinical, study model and cephalometric measurements.
4. the total position of the lower incisor could be located more validly and reproducibly and thus should contribute to better diagnoses, treatment planning and exact research.
5. the inclination of the tooth was determined with as much confidence as with other existing methods.
6. it should contribute to improved computer assisted cephalometric analysis by clearly defining the specific landmark.



Radiographic markers on teeth can thus make a to more accurate measurements in clinical practice as well as in research studies in orthodontics as indicated by the in vivo examples presented.

Recommendations for further research on the use of dental radiographic markers are made, including furthering the study on skulls and in clinical practice. The possible commercial manufacturing of radiographic markers should be investigated as well.

## SAMEVATTING

In kliniese sowel as vergelykende studies met betrekking tot ortodontiese behandeling word klem gelê op metings van die mandibulêre snytand en mandibulêre snytand inklinasie. Dit is egter moeilik om die mandibulêre snytand op laterale kefalometriese radiografiese opnames akkuraat te definieer. Meer presiese definiëring van die snytand behoort dus by te dra tot 'n hoër standaard van kliniese besluitneming en geldigheid van navorsingsresultate.

Die hoofdoel van hierdie ondersoek was om te bepaal of radiografiese merkers op die kroon van die mandibulêre snytand op laterale kefalometriese radiografiese opnames tot 'n meer akkurate bepaling van mandibulêre snytand inklinasie kan lei.

Derhalwe bestaan die studie uit 'n teoretiese sowel as 'n empiriese gedeelte. In die teoretiese gedeelte word literatuur met betrekking tot die belangrikheid van die mandibulêre snytande in ortodonsie, radiografiese beginsels en oorsake van foute in kefalometrie, mandibulêre snytand anatomie en verskillende metodes wat gebruik word om mandibulêre snytand inklinasie te bepaal, bespreek. Vir die empiriese gedeelte van die studie is vyftig mandibulêre snytande op 'n Perspex blad monteer. Radiografiese merkers is vervaardig deur die lood film van gebruikte x-strale ongeveer 1mm wyd te sny. Die merkers is aan die kroon van die vyftig monterde tande geheg en 'n laterale kefalometriese radiografiese opname gedoen volgens standaard kefalometriese metodes (radiografiese opname A). 'n Tweede opname is gedoen met die wortels verskans

(radiografiese opname B). Drie waarnemers is versoek om die inklinasie van die tande op radiografiese opname B by twee verskillende geleenthede aan te dui.

Metode vergelykende statistiese analise is gedoen en die resultate het aangedui dat 'n lyn deur die mandibulêre snytand insisale rand en die middel van die kroon-wortel aansluiting in die saggitale dimensie 'n betroubare metode is om snytand inklinasie te bepaal (standaard afwyking  $3.0^\circ$ ). Die akkuraatheid wat met hierdie metode verkry is, vergelyk dus goed met ander metodes waarmee snytand inklinasie bepaal word.

Radiografiese merkers kan dus 'n bydrae tot meer akkurate radiografiese metings in kliniese praktyk sowel as navorsingstudies lewer. Kliniese voorbeelde word in die studie demonstreer.

Die resultate van die eksperimentele studie kan as volg opgesom word:

1. Dit het duidelik aangedui watter tand op die laterale kefalometriese radiografiese opname analiseer word.
2. Dit het die anatomiese kroon in die saggitale dimensie van die betrokke tand duidelik aangedui al was die tand roteer.
3. Dit het akkurate metings vanaf die snytand kroon vergemaklik deurdat 'n standaard verwysingspunt vir kliniese, studiemodel analise en kefalometriese analise beskikbaar was.
4. Die totale posisie van die mandibulêre snytand kon meer betroubaar en herhaalbaar bepaal word wat 'n bydrae kan maak tot beter diagnose, behandelingsbeplanning en akkurate navorsing.

5. Die inklinasie van die tand is met net soveel vertrouwe bepaal as met ander bestaande metodes.
6. Dit behoort by te dra tot verbeterde rekenaar baseerde kefalometriese analise deurdat die spesifieke landmerke beter omskryf word.

Aanbevelings vir verdere navorsing oor die gebruik van radiografiese merkers word gemaak, onder andere op skedels en in kliniese praktyk. Voorts kan moontlike kommersiële vervaardiging van radiografiese merkers ook moontlik ondersoek word.

## **INDEX**

<b>PREFACE</b>	<b>1</b>
----------------	----------

### **CHAPTER I**

#### **THE RELEVANCE OF THE MANDIBULAR INCISOR IN ORTHODONTICS**

1.1	INTRODUCTION	<b>4</b>
1.2	THE RELEVANCE OF MANDIBULAR INCISORS IN TREATMENT PLANNING FOR PATIENTS	<b>4</b>
1.3	THE RELEVANCE OF MANDIBULAR INCISOR POSITION IN THE SCIENTIFIC VALIDITY OF ORTHODONTIC RESEARCH	<b>8</b>

### **CHAPTER II**

#### **RADIOGRAPHIC PRINCIPLES AND CEPHALOMETRY**

2.1	INTRODUCTION	<b>10</b>
2.2	ERRORS OF PROJECTION: MAGNIFICATION AND DISTORTION	<b>12</b>
	2.2.1 Magnification	<b>12</b>
	2.2.2 Distortion	<b>15</b>
2.3	ERRORS IN LANDMARK IDENTIFICATION	<b>17</b>
	2.3.1 Validity	<b>17</b>
	2.3.2 Reproducibility	<b>19</b>
2.4	CONCLUSION	<b>21</b>

## **CHAPTER III**

### **ANATOMY OF THE LOWER INCISORS**

3.1	INTRODUCTION	22
3.2	GENERAL DIMENSIONS	24
3.3	ROOT CURVATURE	25
3.4	LABIAL SURFACE INCLINATION	25
3.5	SUMMARY	26

## **CHAPTER IV**

### **DIFFERENT METHODS CURRENTLY USED TO DETERMINE LOWER INCISOR INCLINATION**

4.1	INTRODUCTION	27
4.2	CLINICAL ASSESSMENT OF LOWER INCISOR INCLINATION	27
4.3	STUDY MODELS TO DETERMINE INCISOR INCLINATION	27
4.4	DETERMINING LOWER INCISOR INCLINATION ON LATERAL CEPHALOMETRIC RADIOGRAPHS	30
4.4.1	Tracing from incisor edge to incisor apex	33
4.4.2	Tracing from incisor edge parallel to labial surface	37
4.4.3	Tracing to the middle of the symphysis	37
4.4.4	Tracing from incisor edge through the midpoint of the crown	42
4.5	COMPUTED TOMOGRAPHY	43
4.6	CONCLUSION	44

## **CHAPTER V**

### **RESEARCH METHODOLOGY**

5.1	INTRODUCTION	<b>45</b>
5.2	MAIN AIM AND SUB-AIMS	<b>45</b>
5.3	VERIFICATION OF TEETH USED IN THE STUDY	<b>47</b>
5.3.1	Origin of teeth used in the research project	<b>47</b>
5.3.2	Comparison of teeth used in the study to normal dimensions	<b>48</b>
5.4	TEMPLATE VERIFICATION	<b>48</b>
5.5	RADIOGRAPHIC MARKERS	<b>48</b>
5.6	IN VIVO PILOT STUDY	<b>50</b>
5.7	MAIN AIM REALISATION	<b>50</b>
5.7.1	Set-up of teeth	<b>50</b>
5.7.2	Radiographs taken	<b>52</b>
5.7.3	Tracing of radiographs	<b>55</b>
5.7.4	Transfer of data for electronic processing	<b>60</b>

## **CHAPTER VI**

### **RESULTS AND DISCUSSION**

6.1	INTRODUCTION	<b>62</b>
6.2	VERIFICATION OF TEETH USED IN THE STUDY	<b>63</b>
6.3	TEMPLATE VERIFICATION	<b>65</b>
6.4	RADIO-OPAQUE DENTAL MARKERS TO DEFINE THE INCISOR CROWN ANATOMY	<b>66</b>

6.5	DETERMINING LOWER INCISOR INCLINATION UTILISING RADIOGRAPHIC MARKERS	<b>68</b>
6.5.1	Presentation of the data	<b>68</b>
6.5.1.1	Graphical presentation of data	<b>68</b>
6.5.2	Comparison of observers' tracings to the true inclination	<b>77</b>
6.5.2.1	Standard deviation and mean	<b>77</b>
6.5.2.2	Teeth estimated more than 4° off the true inclination	<b>78</b>
6.5.2.3	Verifying trends at different true inclinations	<b>80</b>
6.5.3	Method comparison	<b>81</b>
6.5.3.1	Statistical analysis	<b>81</b>
6.5.3.2	Results	<b>82</b>
6.5.3.3	Discussion	<b>82</b>
6.5.3.4	Conclusion	<b>84</b>
6.6	SUMMARY	<b>85</b>

## **CHAPTER VII**

### **CLINICAL EXAMPLES OF DENTAL RADIOGRAPHIC MARKERS**

7.1	GENERAL DISCUSSION	<b>86</b>
7.2	CONCLUSION	<b>90</b>



## **CHAPTER VIII**

### **CONCLUSION AND RECOMMENDATIONS**

8.1	INTRODUCTION	<b>92</b>
8.2	VALUE OF THIS INVESTIGATION	<b>93</b>
8.3	CRITICAL EVALUATION OF THE STUDY	<b>94</b>
8.4	COMMERCIALY AVAILABLE RADIOGRAPHIC MARKERS	<b>95</b>
8.5	FURTHER INVESTIGATION RECOMMENDED	<b>96</b>
	<b>REFERENCES</b>	<b>97</b>

## LIST OF TABLES

<b>TABLE 3.1</b>	COMMON FEATURES OF THE LOWER INCISOR TEETH	<b>22</b>
<b>TABLE 3.2</b>	A SUMMARY OF RELEVANT DIMENSIONS OF MANDIBULAR INCISORS IN MILLIMETRES.	<b>24</b>
<b>TABLES 3.3</b>	RELEVANT DIMENSIONS OF THE LOWER INCISORS.	<b>24</b>
<b>TABLE 6.1</b>	THE LENGTHS AND LABIO-LINGUAL DIMENSIONS OF TEETH USED IN THIS STUDY IN MILLIMETRES. THE TEETH WERE NOT SUB-DIVIDED INTO CENTRAL OR LATERAL LOWER INCISORS AND THE PATIENT AGES OR SEXES ARE NOT KNOWN.	<b>63</b>
<b>TABLE 6.2</b>	THE INCLINATIONS OF THE TEETH AS DETERMINED BY OBSERVER NUMBER 1 ON RADIOGRAPH B COMPARED TO THE TRUE INCLINATION AS DETERMINED ON RADIOGRAPH A.	<b>74</b>
<b>TABLE 6.3</b>	THE INCLINATIONS OF THE TEETH AS DETERMINED BY OBSERVER NUMBER 2 ON RADIOGRAPH B COMPARED TO THE TRUE INCLINATION AS DETERMINED ON RADIOGRAPH A.	<b>75</b>
<b>TABLE 6.4</b>	THE INCLINATIONS OF THE TEETH AS DETERMINED BY OBSERVER NUMBER 3 ON RADIOGRAPH B COMPARED TO THE TRUE INCLINATION AS DETERMINED ON RADIOGRAPH A.	<b>76</b>
<b>TABLE 6.5</b>	THE MEAN INCLINATION ERROR ON ALL 50 TEETH ON THE FIRST, SECOND AND THE MEAN OF THE TWO TRACINGS AS WELL AS THE STANDARD DEVIATIONS AND THE ERROR RANGE OF THE DIFFERENT OBSERVERS	<b>77</b>
<b>TABLE 6.6</b>	THE NUMBER OF TEETH ASSESSED BY THE DIFFERENT OBSERVERS WITH INCLINATIONS OF MORE THAN 4° OFF THE TRUE INCLINATION. (N=150)	<b>79</b>
<b>TABLE 6.7</b>	COMPARISON OF RELEVANT STUDIES	<b>83</b>

## LIST OF FIGURES

<b>FIGURE 1.1</b>	THE POSITION OF THE LOWER INCISORS IN HARMONY BETWEEN THE SURROUNDING SOFT TISSUES.	<b>5</b>
<b>FIGURE 1.2</b>	THE TWEED ANALYSIS.	<b>6</b>
<b>FIGURE 1.3</b>	STEINER STICKS.	<b>6</b>
<b>FIGURE 1.4</b>	PRE- AND POST- TREATMENT CEPHALOGRAMS.	<b>8</b>
<b>FIGURE 2.1</b>	A. THE SKULL	<b>10</b>
	B. LATERAL CEPHALOMETRIC RADIOGRAPH.	<b>10</b>
<b>FIGURE 2.2</b>	McNAMARA CEPHALOMETRIC ANALYSIS.	<b>11</b>
<b>FIGURE 2.3</b>	MAGNIFICATION AND TARGET-OBJECT DISTANCE.	<b>12</b>
<b>FIGURE 2.4</b>	MAGNIFICATION AND OBJECT-FILM DISTANCE.	<b>13</b>
<b>FIGURE 2.5</b>	STANDARD CEPHALOMETRIC ARRANGEMENT.	<b>14</b>
<b>FIGURE 2.6</b>	COMMON LANDMARKS USED IN CEPHALOMETRICS	<b>15</b>
<b>FIGURE 2.7</b>	DIVERSIONS OF POINTS ON A LATERAL CEPHALOMETRIC RADIOGRAPHS.	<b>16</b>
<b>FIGURE 2.8</b>	VALIDITY OF LANDMARKS ACCORDING TO TNG ET AL..	<b>18</b>
<b>FIGUER 2.9</b>	OVERLAPPING OF LOWER INCISORS.	<b>20</b>
<b>FIGURE 3.1</b>	VARIATION IN ANATOMICAL DIMENSIONS OF LOWER INCISORS.	<b>23</b>
<b>FIGURE 3.2</b>	CROWN TO ROOT RELATIONSHIP OF LOWER INCISORS.	<b>25</b>
<b>FIGURE 3.3</b>	DIFFERENCES IN LABIAL SURFACE INCLINATION OF LOWER INCISORS.	<b>26</b>
<b>FIGURE 4.1</b>	A. & B. THE EFFECT OF DIFFERENT TRIMMINGS ON STUDY MODEL BASES.	<b>28</b>
<b>FIGURE 4.2</b>	THE TOOTH INCLINATION PROTRACTOR OR “TIP” APPARATUS.	<b>29</b>

<b>FIGURE 4.3</b>	A; B. & C. COMMON CEPHALOMETRIC MEASUREMENTS USED IN RELATION TO THE LOWER INCISOR.	<b>30</b>
<b>FIGURE 4.4</b>	THE 3M-UNITEK TRACING TEMPLATE.	<b>31</b>
<b>FIGURE 4.5</b>	THE EFFECT OF DIFFERENT LANDMARK ERRORS ON INCLINATION RELIABILITY.	<b>32</b>
<b>FIGURE 4.6</b>	THE INTER-OBSERVER DIFFERENCES BETWEEN THE OBSERVERS' BEST ESTIMATES OF LOWER INCISOR APEX ACCORDING TO STABRUN ET AL.	<b>34</b>
<b>FIGURE 4.7</b>	THE INTRA OBSERVER DIFFERENCES BETWEEN THE FIRST AND SECOND RECORDING OF LOWER INCISOR APEX ACCORDING TO STABRUN ET AL.	<b>35</b>
<b>FIGURE 4.8</b>	THE EFFECT OF MISLOCATING THE APEX ON LOWER INCISOR INCLINATION.	<b>36</b>
<b>FIGURE 4.9</b>	DIFFERENT INCLINATIONS OF THE LABIAL SURFACE OF THE LOWER INCISOR MIGHT LEAD TO INVALID INCLINATION DETERMINATIONS IF THE LABIAL SURFACES ARE USED AS A REFERENCE POINT.	<b>37</b>
<b>FIGURE 4.10</b>	TRACING OF THE INCISOR INCLINATION FROM INCISOR EDGE TO THE MIDDLE OF THE SYMPHYSIS MAY BE THE METHOD OF CHOICE IN UNTREATED PATIENTS.	<b>38</b>
<b>FIGURE 4.11</b>	TYPE I SYMPHYSIS WITH THE INCISORS IN THE MIDDLE OF A RELATIVELY WIDE SYMPHYSIS.	<b>39</b>
<b>FIGURE 4.12</b>	TYPE II – THE SYMPHYSIS IS NARROWER.	<b>40</b>
<b>FIGURE 4.13</b>	TYPE III – WHERE THE CROSS-SECTION OF THE ALVEOLAR PROCESS REVEALS HARDLY ENOUGH SPACE TO CONTAIN THE INCISOR ROOTS	<b>40</b>

<b>FIGURE 4.14</b>	A. & B. THE EFFECT OF PRONOUNCED SAGITTAL INCISOR MOVEMENT.	<b>41</b>
<b>FIGURE 4.15</b>	INCLINATION OF INCISOR DETERMINED BY A LINE FROM INCISOR EDGE THROUGH THE MIDPOINT OF THE BISECTION IN THE LABIO-LINGUAL DIMENSION AT THE CROWN-ROOT JUNCTION.	<b>42</b>
<b>FIGURE 4.16</b>	COMPUTED TOMOGRAPHY CAN BE USED TO LOCATE THE APEX OF THE LOWER INCISOR EXACTLY.	<b>43</b>
<b>FIGURE 4.17</b>	EXAMPLE OF A CAT SCAN OF THE LOWER.	<b>43</b>
<b>FIGURE 5.1</b>	A. RADIOGRAPHIC MARKER IS PLACED TO DEFINE THE TOOTH CROWN IN THE SAGITTAL DIMENSION. B. THE LEAD FILM BONDED ONTO THE TOOTH CROWN THROUGH THE MIDDLE OF THE INCISAL EDGE IN A MESIO-DISTAL DIMENSION.	<b>49</b> <b>49</b>
<b>FIGURE 5.2</b>	A. SOME OF THE TEETH USED WITH RADIOGRAPHIC MARKERS IN PLACE. B. RADIOGRAPHIC MARKERS WERE CUT FROM LEAD-FILM AND FIXED TO THE TEETH WITH A WELL-KNOWN GENERAL-PURPOSE ADHESIVE.	<b>49</b> <b>49</b>
<b>FIGURE 5.3</b>	THE PERSPEX SHEET ON WHICH THE TEETH WERE MOUNTED WITH THE BASE IN WHICH THE SHEET CAN BE EXACTLY REPOSITIONED	<b>51</b>
<b>FIGURE 5.4</b>	THE TEETH MOUNTED ON THE PERSPEX SHEET.	<b>52</b>
<b>FIGURE 5.5</b>	A. THE PERSPEX SHEET POSITIONED IN THE CEPHALOSTAT. B. THE ROOTS OF THE TEETH WERE COVERED FOR RADIOGRAPH B.	<b>52</b> <b>52</b>

<b>FIGURE 5.6</b>	RADIOGRAPH A WITH THE ROOTS CLEARLY VISIBLE TO OBTAIN THE TRUE ANGULATION OF THE TEETH.	<b>53</b>
<b>FIGURE 5.7</b>	RADIOGRAPH B. THE ROOTS ARE OBSCURED AND ONLY THE CROWNS VISIBLE.	<b>54</b>
<b>FIGURE 5.8</b>	TRACING 1B1: OBSERVER NUMBER 1, RADIOGRAPH B, THE FIRST TRACING	<b>56</b>
<b>FIGURE 5.9</b>	TRACING 2B1: OBSERVER NUMBER 2, RADIOGRAPH B, AND THE FIRST TRACING	<b>57</b>
<b>FIGURE 5.10</b>	TRACING 3B1: OBSERVER NUMBER 3, RADIOGRAPH B, THE FIRST TRACING	<b>58</b>
<b>FIGURE 5.11</b>	THE TRUE ANGULATION OF THE TEETH AS DETERMINED ON RADIOGRAPH A.	<b>59</b>
<b>FIGURE 5.12</b>	EACH INCLINATION WAS MEASURED USING CORELDRAW 10 DIMENSION TOOL.	<b>60</b>
<b>FIGURE 6.1</b>	DIMENSIONS OF A TRACING OF THE TEMPLATE.	<b>65</b>
<b>FIGURE 6.2</b>	THE LAST ROW OF TEETH WAS ROTATED ON THE PERSPEX SHEET.	<b>66</b>
<b>FIGURE 6.3</b>	SIMULATION OF THE EFFECT OF A RADIOGRAPHIC MARKER ON A ROTATED TOOTH.	<b>67</b>
<b>FIGURE 6.4</b>	A COMPOSITE TRACING OF OBSERVER 1'S FIRST AND SECOND TRACINGS COMPARED TO THE TRUE INCLINATION.	<b>69</b>
<b>FIGURE 6.5</b>	A COMPOSITE TRACING OF OBSERVER 2'S FIRST AND SECOND TRACINGS COMPARED TO THE TRUE INCLINATION.	<b>70</b>
<b>FIGURE 6.6</b>	A COMPOSITE TRACING OF OBSERVER 3'S FIRST AND SECOND TRACINGS COMPARED TO THE TRUE INCLINATION.	<b>71</b>

<b>FIGURE 6.7</b>	INCLINATIONS AS DETERMINED BY THE DIFFERENT OBSERVERS ON RADIOGRAPH B AND THE TRUE INCLINATION AS DETERMINED ON RADIOGRAPH A.	<b>72</b>
<b>FIGURE 6.8</b>	MEAN ERROR VERSUS TRUE ANGLE BY DIFFERENT OBSERVERS.	<b>80</b>
<b>FIGURE 7.1</b>	A. LABIAL VIEW OF TEETH WITH THE LEAD MARKERS IN PLACE. B. OCCLUSAL PHOTO DEMONSTRATES THE MARKER ON THE LOWER INCISOR.	<b>86</b> <b>86</b>
<b>FIGURE 7.2</b>	THE UPPER INCISOR WITH THE MARKER PLACED EXACTLY AS FOR THE LOWER INCISOR.	<b>87</b>
<b>FIGURE 7.3</b>	RADIOGRAPHIC MARKER ON A MOLAR.	<b>87</b>
<b>FIGURE 7.4</b>	A. & B. COMPARISON OF LATERAL CEPHALOMETRIC RADIOGRAPHS WITH AND WITHOUT LEAD MARKERS.	<b>88</b>
<b>FIGURE 7.5</b>	ENLARGEMENT FOR BETTER VISUALISATION OF THE MARKERS.	<b>88</b>
<b>FIGURE 7.6</b>	CLINICAL EXAMPLE OF CLEAR INDICATION OF LANDMARKS UTILISING RADIOGRAPHIC MARKERS.	<b>89</b>
<b>FIGURE 7.7</b>	RADIOGRAPHIC MARKERS USED TO INDICATE FUNCTIONAL OCCLUSAL PLANE.	<b>90</b>

## PREFACE

### **ORTHODONTICS: SCIENCE, ENGINEERING OR ART?**

Orthodontics is a **science** with orthodontic tooth movement (and orthopaedic jaw adaptation) based on sound biological principles. The biological principles will be adapted as more is learned about growth and tooth movement on cellular and molecular level.

**Engineering** will always be part of orthodontics. Currently orthodontic tooth movement is principally done with mechanical forces supplied by wires ligated to brackets and enhanced by springs and elastics. The future might provide movement through electrical and magnetic forces and even growth control through genetic engineering<sup>(1)</sup>.

One of the primary objectives of orthodontics is to provide an aesthetically pleasing smile with the surrounding soft tissue and hard tissue in harmony with the rest of the face. Beauty (or “balance” or “harmony”) is subjective and “lies in the eye of the beholder” – which implies that orthodontics will always be a **form of art** as well.

The speciality orthodontics has thus been seen over the last century as “part science, part engineering and part art”, but the credo of orthodontic societies is for “evidence-based orthodontics” to make orthodontics as much a science as an art in the future<sup>(2)</sup>. The only way to provide a scientific foundation for treatment plans is with proper **quantitative measurements**<sup>(3)</sup>.



A method to accurately determine the lower incisor position on lateral cephalometric radiographs was investigated in this study in relation to the quest for “evidence based orthodontics”. May this research project contribute, in whatever small way, to realise these ambitions.

### **COMPOSITION OF THE REPORT ON THE STUDY**

This research project investigated an alternative and possibly more accurate method to **determine the central lower incisor inclination** on lateral skull radiographs by using dental radiographic markers. The investigation is reported in the following chapters:

1. The **relevance** of studying a method that will assist in more exact determination of the lower incisor position is addressed in the *first chapter*.
2. In the *second chapter* a literature review of factors influencing **landmark identification** on lateral cephalometric radiographs is presented with emphasis on the lower central incisor.
3. The *third chapter* highlights the differences in the **anatomical dimensions** of the lower incisor that may especially have an influence on tracing of the relevant tooth and thereby influencing aforementioned inclination.
4. In the *fourth chapter*, different **methods used to determine lower incisor inclination** with the pros and cons of the alternative methods, are discussed. Influences of different templates, tooth sizes and unreliable location of the lower incisor apex are mathematically demonstrated.

5. In *Chapter five* the aim of this study is defined. The **methodology of a research project** applied to investigate the use of radiographic markers on the lower central incisor to possibly provide a more detailed image on the lateral cephalometric radiograph is discussed.
6. **Research results** are presented and **discussed** in *chapter six*.
7. *Chapter seven* presents **different cases** that illustrate and compare the use of radiographic dental markers on patients.
8. **Conclusions and recommendations** regarding the literature review and research project follow in *chapter eight*.

Recent clippings from orthodontic journals voicing the current viewpoint of many well-respected orthodontists regarding more accurate data in orthodontics are blocked and marked with an asterisk (\*).

## **CHAPTER I**

### **THE RELEVANCE OF THE MANDIBULAR INCISOR IN ORTHODONTICS**

#### **1.1 INTRODUCTION**

Although great emphasis is placed on measurements taken from the lower incisor crown and the lower incisor inclination in orthodontics, it is difficult to obtain reliable reference points regarding the lower incisor on lateral cephalometric radiographs. The purpose of the study was to investigate an alternative and possibly more accurate method to determine the central lower incisor position and inclination on lateral skull radiographs. The placement of radiographic markers on the clinical crown of a lower central incisor should contribute to more exact measurements taken from the specific tooth, as it should be able to clearly distinguish the dimensions of the tooth crown in the sagittal plane.

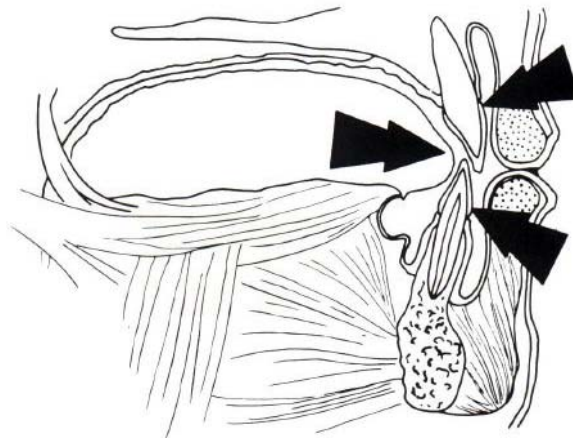
If the lower incisor position and inclination are incorrectly determined, it adversely affects the treatment planning for patients as well as the scientific validity of orthodontic research.

#### **1.2 THE RELEVANCE OF MANDIBULAR INCISORS IN TREATMENT PLANNING FOR PATIENTS**

The mandibular incisor position is of critical importance in orthodontics. The main purpose of orthodontics can usually be defined as the creation of the best balance between occlusal relationships and dental and facial aesthetics. Stability of the result as well as the long-term maintenance of the dentition are also critical <sup>(4)</sup>. The lower incisors have a central role to all these goals (Figure 1.1).

The mandibular incisors function with the maxillary incisors:

1. in the cutting of food (the moving blades)
2. in the production of distinct speech and
3. in maintenance of a good appearance by supporting the lower lip.
4. By fitting their incisal edges against the lingual surfaces of the maxillary incisors, they also help to guide the mandible posteriorly in the joint during the final phase of closing before the posterior teeth contact<sup>(5)</sup>.



*Figure 1.1: The position of the lower incisors in harmony between the surrounding soft tissue (tongue and lips), in balance with the upper incisors and within proper alveolar bone is important for optimum function, aesthetics and stability. (Acknowledgement: Moyers RE<sup>(6)</sup>)*

The mandibular incisors are, however, limited in the range that they can be moved orthodontically as their alveolar support over basal bone, especially in an antero-posterior dimension, is the least of all teeth<sup>(7)</sup>. These teeth are also found to be the most unstable after orthodontic correction and numerous studies to determine stable positions for the lower incisors have been published<sup>(8,9,10,11,12)</sup>. Different opinions regarding the optimum

position of the lower incisors are held. Tweed stresses the principle of the lower incisors being positioned over basal bone and advocates the use of a geometric balance between the lower incisor inclination, lower border of the mandible and nasion<sup>(13)</sup> (Figure 1.2). Steiner developed the so-called “Steiner Sticks” to address the different inclinations suggested in different skeletal types<sup>(14)</sup> (Figure 1.3).

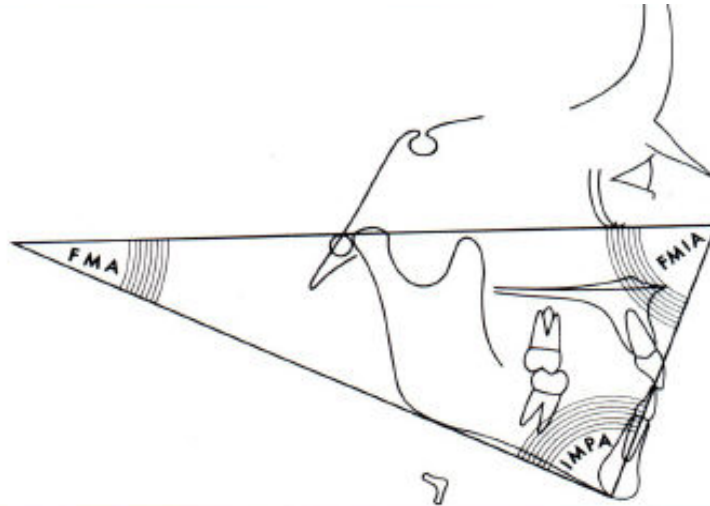


Figure 1.2: The Tweed analysis centres around two highly critical parameters: the position of the mandibular incisors (over basal bone) and the mandibular plane angle.

(Acknowledgement: Athanasiou AE<sup>(15)</sup>)

IDEAL									
-1°	0°	1°	2°	3°	4°	5°	6°	7°	8°
25° / 7	24° / 6	23° / 5	22° / 4	21° / 3	20° / 2	19° / 1	18° / 0	17° / -1	16° / -2
22° / 3.25	23° / 3.5	24° / 3.75	25° / 4	26° / 4.25	27° / 4.5	28° / 4.75	29° / 5	30° / 5.25	31° / 5.5
ACCEPTABLE ARRANGEMENTS									

Figure 1.3: Steiner developed the so-called “Steiner sticks” to provide acceptable compromises for anterior teeth positioning in different skeletal patterns.

(Acknowledgement: Jacobsen A<sup>(16)</sup>)

Another opinion is that of Alexander whose key objective is to treat a patient with the face proportionately balanced, consistent with his particular skeletal pattern. In keeping with this basic objective, Alexander makes his case diagnoses with particular emphasis on the position of the mandibular incisors in regard to the patient's profile <sup>(7)</sup>.

According to Lenz in an article *Incisal changes and orthodontic stability*, Nanda and Burstone list three concepts regarding ideal positions and angulations of the incisors for stability that differ from those traditionally accepted <sup>(17)</sup>. These three concepts are:

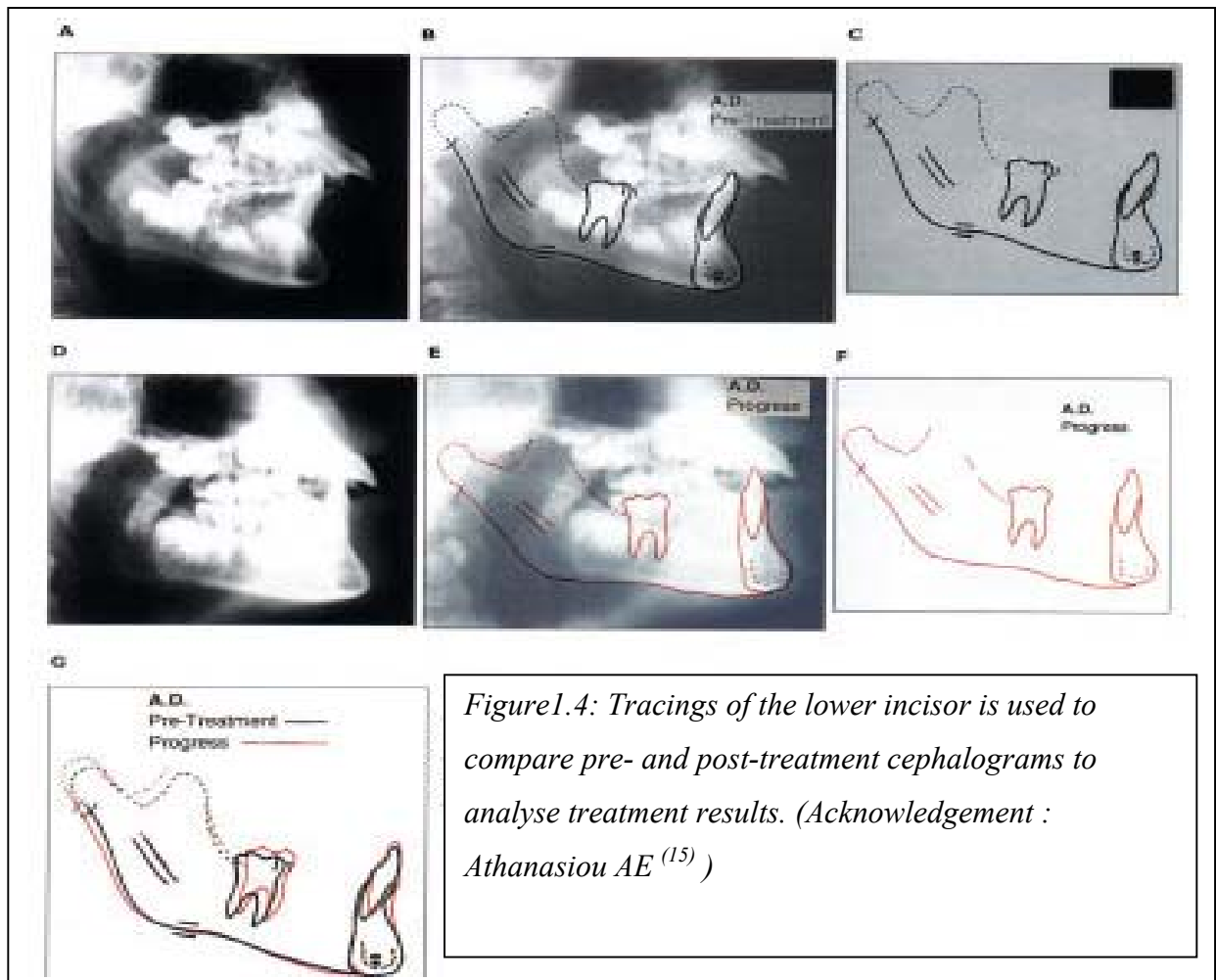
1. "the so-called cephalometric normal values for the incisors are the most stable, and yet stability can and does exist outside these norms;
2. the original positions of the mandibular incisors before treatment are the most stable positions and correcting any malocclusion may move the incisors into unstable positions;
3. there is only one stable position for the mandibular incisors."

It can be concluded that many studies have been done regarding the ideal position of the mandibular incisor teeth to provide optimum function, aesthetics and stability within the surrounding skeletal and soft tissue framework that is individually different. Positioning of these teeth (in optimum relationship to the rest of the dentition, on basal bone within the soft tissue) is thus one of the basic objectives in orthodontics and, because of the limited possible movement, often the initial starting point of treatment planning. The lower incisor position is thus critically scrutinised in relation to other structures with several linear and angular measurements to determine the existing position at the start of treatment to consider different treatment options accordingly.

The first reason then to investigate possible methods of more accurately analysing the position of the lower incisor is because inclination of the central lower incisor can play a vital role in cephalometric diagnosis and ultimately, the treatment of the patient's malocclusion.

### 1.3 THE RELEVANCE OF MANDIBULAR INCISOR POSITION IN THE SCIENTIFIC VALIDITY OF ORTHODONTIC RESEARCH.

The position of the lower incisor teeth is often analysed to compare treatment results for research and scientific studies to validate treatment protocols as illustrated in Figure 1.4.



The question however, arises: in previous studies, how accurately were the analyses of teeth positions done? Were pre- and post treatment evaluations comparing and analysing lower incisor inclinations on cephalometric radiographs valid? Furthermore, is it indeed possible to accurately assess the lower incisor position on a lateral cephalometric x-ray?

If more exact measurements regarding the position of the lower incisor can be produced, more accurate and scientifically valid conclusions will result, a second important reason to conduct this study. Although this study focused on only a small part of the dento-facial complex that can be altered with orthodontics, the principles and methods described may be applicable to other relevant components of the teeth and face as well and may contribute to improved cross-sectional and longitudinal investigations.

\* Sinclair in *Tomorrow's challenges for the science of orthodontics* calls for dedication **“to make sure that orthodontics is as much a science as and art in the future”** <sup>(2)</sup>.

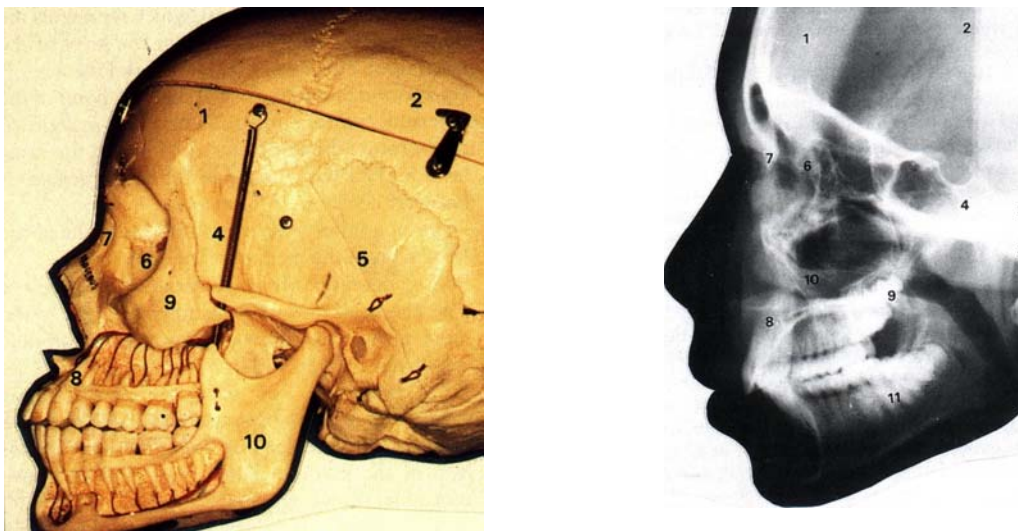


## CHAPTER II

### RADIOGRAPHIC PRINCIPLES AND CEPHALOMETRY

#### 2.1 INTRODUCTION

Cephalometry originates from craniometry where anatomists recorded various dimensions on dry skulls. In classic cephalometry measurements of the head were taken from bony landmarks as located by palpation through adjacent soft tissue. The technique to produce a lateral head film by Pacini in 1922 evoked the standardisation of cephalometric lateral radiographs of the skull for use in orthodontics by Broadbent and by Hofrath in 1931<sup>(15)</sup>. Radiographic cephalometry is thus the recording of bony landmarks (as well as dental and soft tissue landmarks) on a radiograph of the skull (Figure 2.1).



*Figure 2.1: The skull and a lateral cephalometric radiograph of the cranio-facial skeleton. (Acknowledgement: Athanasiou AE<sup>(15)</sup>)*

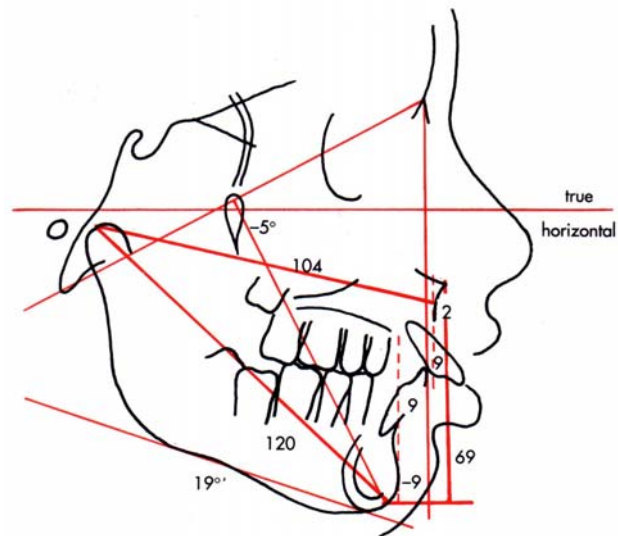
The most commonly used radiograph is a lateral head radiograph with a classical cephalometric analysis involving the construction of lines and planes on the anatomical landmarks to form a reference system. Cephalometrics is to a large degree “applied

geometry”<sup>(6)</sup>. Points are precisely located spots that relate to specific landmarks and are located on a tracing of a cephalometric radiograph. A plane is determined by joining two points with a straight line.

Analysing cephalometric head films serves as a valuable treatment planning and treatment-assessing tool. Cephalometrics is essential in the diagnoses of facial disharmony and the planning and evaluation of orthodontic treatment. The use of lateral cephalometric head films are therefore one of the routine procedures in any orthodontic practice <sup>(16)</sup>. Many different methods of cephalometric evaluation exist, for example Downs (1948); Steiner (1955); Ricketts (1960; 1981); Tweed (1962); Harvold (1974); Eastman (1982) and McNamara (1984 – Figure 2.2) are all well-known analyses.

*Figure 2.2: Analysis of a 12-year-old male, using the McNamara approach.*

*(Acknowledgement: Proffit WR <sup>(4)</sup>)*



Although cephalometric analysis “is only one of many diagnostic tools used to determine the type and focus of therapy for an individual”, it is one of the more **objective tools to compare pre- and post treatment results in a quantifiable way**. It is therefore important to be as exact as possible in cephalometrics when tracing, measuring and comparing different radiographs and landmarks<sup>(18)</sup>. Cephalometrics is unfortunately prone

to certain common errors. To accurately interpret and apply cephalometrics it is important to realise the influence and potential of different possible sources of error:

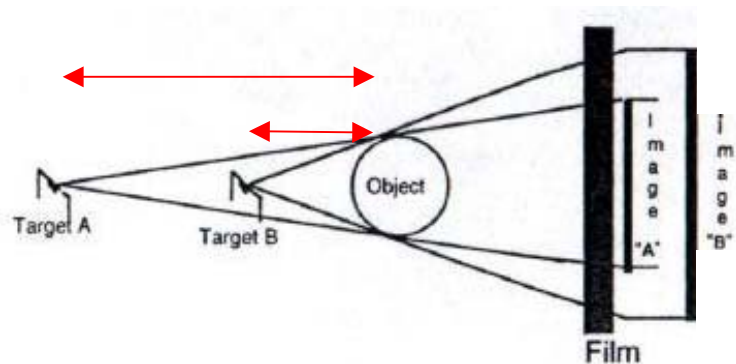
- **errors of projection** – “standard errors” of the recording procedure where the object as imaged on the radiographic film is subjected to **magnification** and **distortion**.
- **errors in landmark identification** - the **validity** and **reproducibility** of the landmark will influence the consistency of conclusions drawn from cephalometric data. (Reliability is sometimes used to encompass both validity and reproducibility.)
- measurement errors – operator mistakes while reading measurements. The influence of measurement errors of this kind is not addressed in the research project as computational methods greatly enhances accuracy in this regard.

## 2.2 ERRORS OF PROJECTION: MAGNIFICATION AND DISTORTION

### 2.2.1 Magnification:

X-ray beams are not parallel with all the points of the object to be examined with resultant magnification. The difference between image size and object size is explained in Figure 2.3 which in principle illustrates that the further the target (x-ray tube) is from the object (patient), the less will be the magnification.

*Figure 2.3: Magnification is dependant on the distance from the target (tube) to the object. (Acknowledgement: Friedland B<sup>(19)</sup>)*

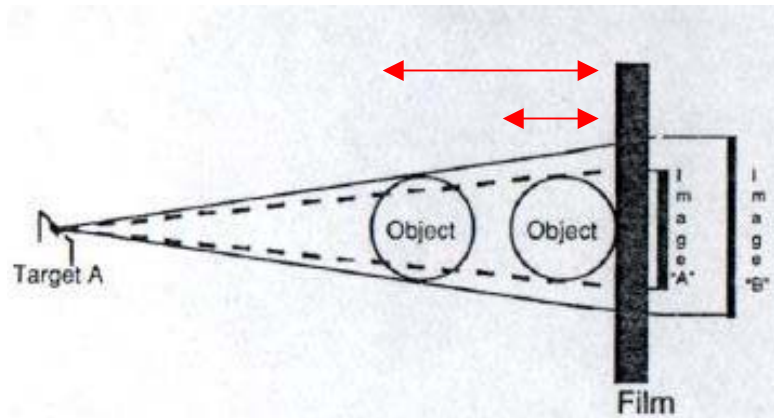


Secondly, Figure 2.4 illustrates that the closer the object is to the film (the shorter the object-film distance), the less will be the magnification.

*Figure 2.4: The object to film distance also influences magnification.*

*(Acknowledgement:*

*Friedland B<sup>(19)</sup>)*



The ideal of zero magnification is difficult to attain in practice. To minimize magnification a long target-film distance and a short object-film distance are required. The resultant standardized distances for orthodontic lateral cephalometric radiographs are: target to object distance of 150cm and the object to film distance as close as the film could be placed against the lateral of the patients head ( $\pm 9 - 15\text{cm}$ , see Figure 2.5)<sup>(4)</sup>. The latter implies that the amount of magnification might differ from patient to patient because the target-film distance may differ from  $150 + 9 = 159$  to  $150 + 15 = 165\text{cm}$ . If serial cephalograms of the same patient are to be compared it is important to keep the target film distance constant.

Orthodontists routinely perform measurements on films that are translated into clinical treatment, which may or may not accurately reflect true dimensions. Magnification of the image of the object should always be taken into consideration. Systematic error will arise if no compensation is made between measurements from models and radiographs with no allowance for the radiographic enlargement. The same invalid conclusion will be made if

measurements from two different studies are compared without knowing whether the degree of magnification was the same. As already mentioned different objects (depending on their position according to the mid-sagittal plane) will be magnified differently.

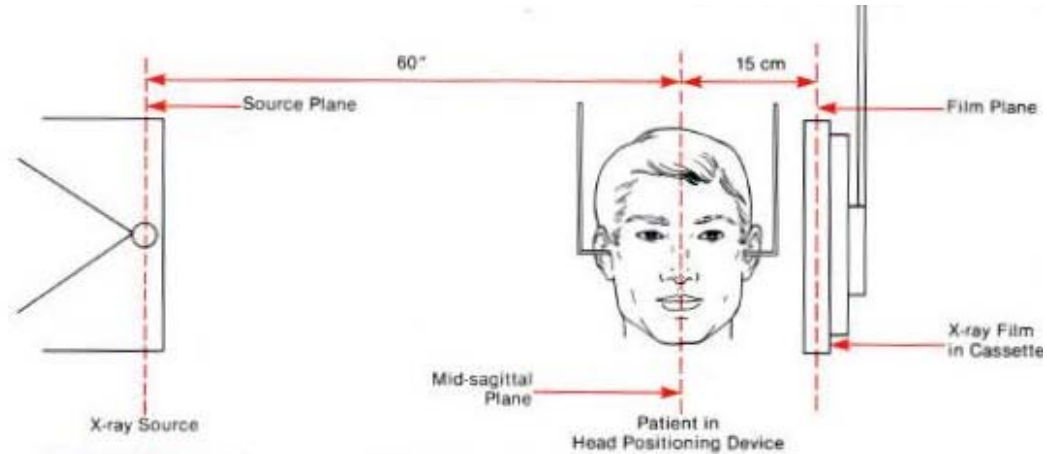


Figure 2.5: Standard cephalometric arrangement. The distance from the mid-sagittal plane to the cassette can vary in many machines but must be the same for each patient every time. (Acknowledgement: Proffit WR<sup>(4)</sup>)

An obvious clinical application is particularly in regard to treatment planning for patients in which orthognathic surgery is planned. The degree of decompensation and the surgical shift cannot be directly applied from the lateral cephalometric radiograph to the model or the patient. Measurements should always be mathematically corrected for comparison.

To ease the calculation of magnification on a lateral cephalometric radiograph a ruler is usually provided on the headholder of the cephalometric unit in the mid-sagittal plane. This ruler can be used with common mathematics to calculate the degree of magnification and is usually in the region of 8% magnification of image to object.

### 2.2.2 Distortion:

The image of the face and skull that the lateral cephalometric radiograph provides is a two-dimensional image of a 3-dimensional object.

Most landmarks used for cephalometric analysis are located in the mid-sagittal plane (Sella, Nasion, ANS, PNS, A-point, B-point, Pogonion and upper/lower incisors – see Figure 2.6) at the standardized 150cm target-object distance. The ruler that enables calculation of magnification is also in the mid-sagittal plane.

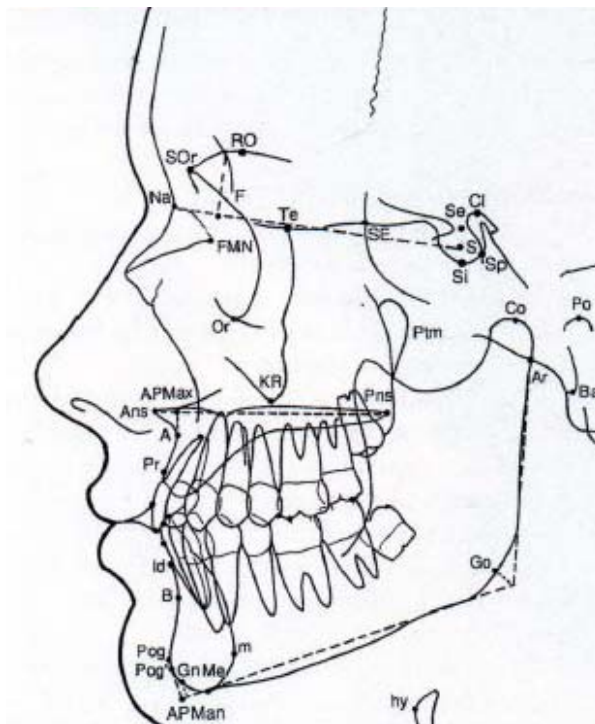


Figure 2.6: Common landmarks used in cephalometrics.

(Acknowledgement: Athanasiou AE (15))

- Na – nasion
- S – sella midpoint
- Or – orbitale lower border
- Po – external ear meatus
- Co – condylion
- Go – gonion
- Me – menton
- Gn – gnation
- Pog – pogonion
- B – B point
- A – A point
- ANS – anterior nasal spine

Other landmarks (Porion, Articulare, Condylus, Gonion and dental landmarks like molars and occlusal plane) are all located on both sides of the mid-sagittal plane (Figure 2.6). The implication is that landmarks in different sagittal planes are unevenly magnified and distorted with different degrees of magnification on either side of the mid-sagittal plane.

Linear distances will be foreshortened on the objects closer to the film and *vice versa* for objects further from the film. Furthermore, these bilateral structures on both sides of the mid-sagittal plane do not superimpose on a lateral cephalometric radiograph (Figure 2.7). The fan of the x-ray beam expands as it passes through the head, causing a divergence between the images (and different magnifications) of all bilateral structures (except those along the central beam). The greater the distance between the bilateral structures, the more the difference in magnification and divergence. That explains why the 31 and 41 will be closely superimposed and equally magnified on a lateral cephalometric radiograph, while the wisdom teeth 38 and 48 will not be superimposed exactly and will be differently magnified (although being in the same ipsi-lateral positions and of the same size).

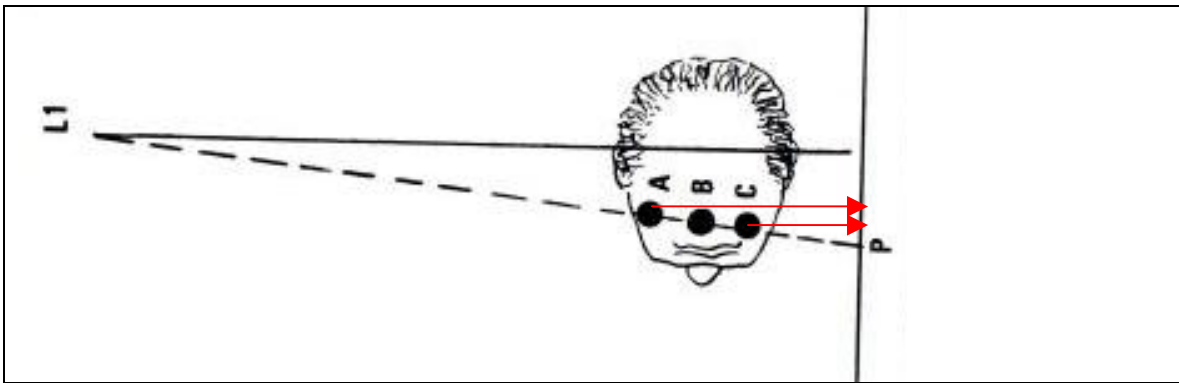


Figure 2.7: Points A, B and C will be projected on the same spot on the x-ray. The points should have been different points on the radiograph as illustrated by the arrows.

(Acknowledgement: Athanasiou AE<sup>(15)</sup>)

Phelps and Masri specifically investigated distortion in the lower incisor area on lateral cephalometric radiographs and conclude that no real distortion could be manifested in their study and that the lateral cephalometric radiograph can be used with confidence to analyse the lower incisor area<sup>(20)</sup>.

## 2.3 ERRORS IN LANDMARK IDENTIFICATION

### 2.3.1 Validity (accuracy)

Validity in epidemiological studies refers to “the accuracy with which a measurement is representative of the true value, i.e. does the value accurately reflect what it is supposed to be measuring”<sup>(21)</sup>. (The term accuracy may also be used in this sense.) In cephalometrics, for instance, are sella and nasion valid end points for the anterior cranial base? Another example: it is generally accepted that A-point is remodelled when the upper central incisors are moved. A change in ANB angle cannot therefore be taken to show that orthodontic treatment has affected jaw relationships. Is A-point a valid point to indicate the anterior border of the maxilla? Simplistic conclusions that are incorrect may be drawn if certain landmarks are interpreted without caution<sup>(22)</sup>. This unreliability leads to inaccuracy regarding cephalometric interpretation.

In a study by Tng et al. in 1994 the validity of commonly used skeletal and dental landmarks were comprehensively evaluated<sup>(23)</sup>. Steel markers were placed in the true anatomical positions on dry skulls, lateral cephalometric radiographs with and without the steel markers were taken and the true anatomical position compared to the analyser-registered landmarks. Many landmarks were found to be invalid along one or both the x- and y- axes. The landmarks estimated on the lateral cephalometric radiographs therefore differed from the true anatomical landmarks that the examiner wanted to measure and might be misleading. Some of the findings of the study by Tng et al. are presented graphically in Figure 2.8 and discussed in more detail because of the relevance to this research project.



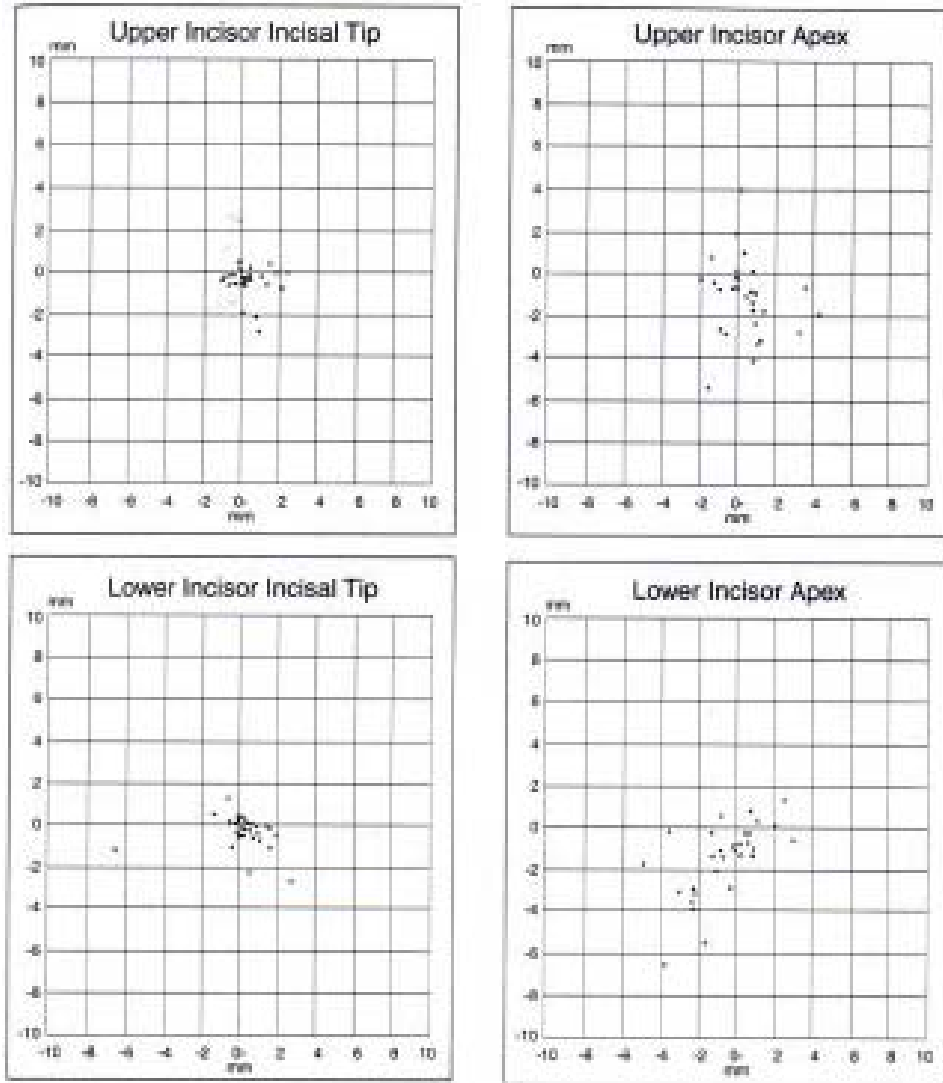


Figure 2.8: Validity of landmarks according to Tng et al. (Acknowledgement: Tng et al. (23))

In general the dental landmarks have poorer validity than the skeletal landmarks. The upper incisor edge is generally estimated forward (0.6mm) of the true landmark, thereby tending to procline the teeth. Upper incisor apex is estimated lower (-1.0mm) than the true point. The lower incisor edge is estimated forward (0.5 mm) of the true landmark and is made difficult to locate by the overlapping images of upper incisors. Lower incisor apex is

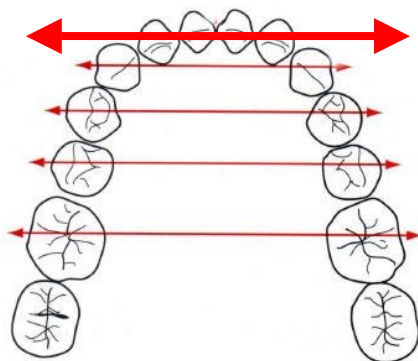
estimated backwards (-1.1 mm) of the true point. The combination of lower incisor tip estimated forward and apex more backward tends to procline the teeth and increases the lower incisor angulation. The lower incisor to mandibular plane angular differences between cephalograms with and those without the steel ball markers have a standard deviation of 4.0 degrees.

Although this study of Tng et al. refers to the “validity” of the landmarks, it should rather be the “reproducibility” as the apex of the lower incisor is a valid landmark to define the apex of the lower incisor! Houston is of opinion that “many cephalometric landmarks have been defined for convenience of identification and reproducibility, rather than on grounds of anatomic validity”<sup>(22)</sup> and justly asks in this regard whether nasion and sella are valid end points for anterior cranial base? Furthermore, point A is accepted to remodel when the upper incisors are moved, but A-point is regarded as an indicator of skeletal jaw relationship! Using the lower incisor apex to the lower incisor edge is also a valid plane to assess the long axis on a sagittal radiograph of the relevant tooth. It may, however, be very unreliably (un-reproducible) located on a lateral cephalometric radiograph. As no better alternative landmarks are available, these variables are not necessarily rejected as invalid, but it must be recognized that in certain instances they may be misleading.

### **2.3.2 Reproducibility (reliability):**

Reliability is defined in epidemiological studies as the precision with which a measurement is reproducible within the same or different observers<sup>(21)</sup>. Reproducibility is used as a synonym in cephalometrics and encompasses the precision or closeness of successive measurements of the same subject<sup>(22)</sup>. Cohen ascribes the main source of cephalometric

error to uncertainty in landmark identification<sup>(24)</sup>. This leads to an element of subjectivity in determining landmark position. Hägg et al. state that the major source of variability in landmark determination is related to the observers' opinion of the landmark location<sup>(25)</sup>. In the presence of soft tissues the standard deviations of all variables increased in a previous related study by the same authors - the distance, for instance, from the incisal tip of the lower incisor to the A-Pogonion line shows a four-fold increase in its standard deviation with the soft tissue present. This study also concludes that incisor tip for lower and upper incisors on dry skulls are about 4 times more reproducible (expressed by the 95% confidence interval) than the lower and upper incisor apices. (Illustrations of a related study by Tng et al. on previous page in Figure 2.8.)



*Figure 2.9: Although the lower incisors are in the mid-sagittal plane with little distortion, overlapping of several structures can make accurate landmark identification almost impossible.*

*(Acknowledgement: Proffit WR<sup>(4)</sup>)*

Reliability of the lower incisor may be compromised by any of the following (Figure2.9):

- superimposed images of adjacent structures are major factors in the poor reliability of landmarks such as lower incisor apices.
- the lower incisors (and even the lower canines) are sometimes basically in the same line if viewed from lateral (sagittal dimension.)

- the most prominent incisors may also be the lateral incisors rather than the central incisors and it is not possible to differentiate between them on cephalograms.

## 2.4 CONCLUSION

In relation to the lower incisor landmarks, the influence of possible cephalometric errors can be summarised as follow:

**Magnification:** the amount of magnification may differ from patient to patient, because the target-film distance may vary from  $150 + 9 = 159$  to  $150 + 15 = 165$ cm. The ruler that enables calculation of magnification is in the mid-sagittal plane as well that positively influences the estimation of the magnification effect on the incisors.

**Distortion:** Phelps and Masri conclude that no real distortion could be manifested in their study that specifically investigated distortion in the lower incisor area on lateral cephalometric radiographs and is of meaning that the lateral cephalometric radiograph can be used with confidence to analyse the lower incisor area <sup>(20)</sup>.

**Validity:** the lower incisor apex and the lower incisor edge are valid landmarks to assess the long axis of the lower incisor as they anatomically represent the true points to be considered.

**Reproducibility:** the reproducibility of the lower incisor edge is much better (4 times according to Hägg et al.) than the reproducibility of the lower incisor apex <sup>(25)</sup>. The adverse effect of this phenomenon will be discussed in more detail in Chapter 4.




\*Gianelly, in an article *Evidence-based treatment strategies: An ambition of the future* states that certain orthodontic conclusions “are **largely anecdotal reports reinforced by the evangelical fervor of the presenters**” <sup>(26)</sup>.

## CHAPTER III

### ANATOMY OF THE LOWER INCISORS

#### 3.1 INTRODUCTION

The anatomy of the lower incisors is important as a general knowledge of the usual length of a tooth and the expected rate of taper perceived from the visible portion of the crown and root are often used for projection of the apex that is obscured by superimposed surrounding structures<sup>(16)</sup>. A summary of mandibular incisor features is presented in Table 3.1.

Mandibular Incisors—Arch Traits	
1. Narrowest teeth of incisor class	
2. Lateral incisor wider than central	
3. Marginal ridges and cinguli not prominent	
4. Lingual fossa shallow	
5. Roots oval in cross-section, much wider labiolingually than mesiodistally	
6. Labial surfaces flat	
7. Crown wider labiolingually than mesiodistally	

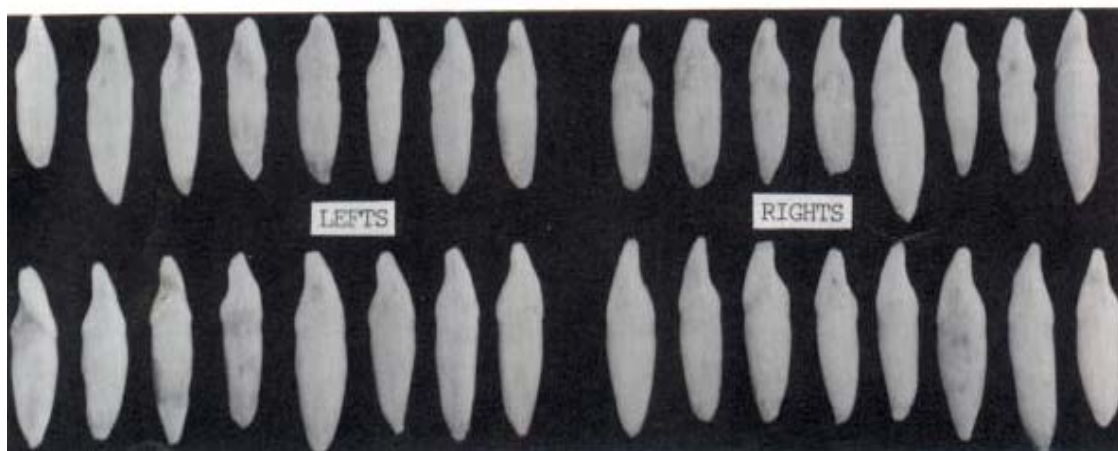
  

Mandibular Incisors—Type Traits		
	Central Incisor	Lateral Incisor
Labial aspect	Narrow mesiodistally Bilaterally symmetrical Mesial and distal mammelons equally prominent Mesioincisal and distoincisal angles sharp 90 degrees	Slightly wider than central mesiodistally Asymmetrical Distal mammelon not prominent Distoincisal angle rounded
Incisal aspect	Incisal ridge forms right angle with labiolingual bisecting line	Incisal ridge twisted on crown

Table 3.1: Common features of the lower incisor teeth are well summarised by Jordan et al.<sup>(27)</sup>.

An in-depth review of the anatomy of the lower incisors is also relevant to this study to validate templates, crown-root angulations, labial surface inclinations and labio-lingual variations in crown proportions.

Although Woelfel mentions that there is more uniformity of shape in the mandibular incisor teeth than in other teeth, it is clear from this and other studies that variation, especially in tooth length, occurs within the norm as illustrated in Figure 3.1 <sup>(5)</sup>. Taylor mentions that there is a considerable range of variation within the “lower incisor group” <sup>(28)</sup>. These include length and breadth dimensions as already mentioned, but also differences in curvature of outline and bends or curves of the roots. The relevant differences will be discussed in more detail.



*Figure 3.1: Variation in anatomical dimensions of lower incisors. (Acknowledgement: Woelfel JB<sup>(5)</sup>)*

### 3.2 GENERAL DIMENSIONS

Relevant dimensions as reported by different authors are presented in Tables 3.2 and 3.3.

	226 Centrals		234 Laterals	
<i>Dimension Measured</i>	<i>Average</i>	<i>Range</i>	<i>Average</i>	<i>Range</i>
Overall length	20.8	16.9-26.7	22.1	18.5-26.6
Crown length	8.8	6.3-11.6	9.4	7.3-12.6
Root length	12.6	7.7-17.9	13.5	9.4-18.1
Faciolingual crown size	5.7	4.8-6.8	6.1	5.2-7.4

Table 3.2: A summary of relevant dimensions of mandibular incisors in millimetres.

(Acknowledgement: Woelfel JB<sup>(5)</sup>)

	Central Incisor (mm)	Lateral Incisor (mm)
Total length	21.5	23.5
Crown length	9	9.5
Root length (calculated)	12.5	14
Labio-lingual size	6	6.5

Table 3.3: Relevant dimensions of the lower incisors. (Acknowledgement: Jordan et al.<sup>(27)</sup>)

Carlsen finds a mean length of 22mm with variations from 19 to 28mm for the lower central incisor (n=140) in a study of extracted Danish teeth and a mean of 24mm for the lower incisor laterals (n=160) with a minimum of 17mm and a maximum of 26mm. The crown-root index for both the central and lateral is 1.3 (Figure 3.2) <sup>(29)</sup>.

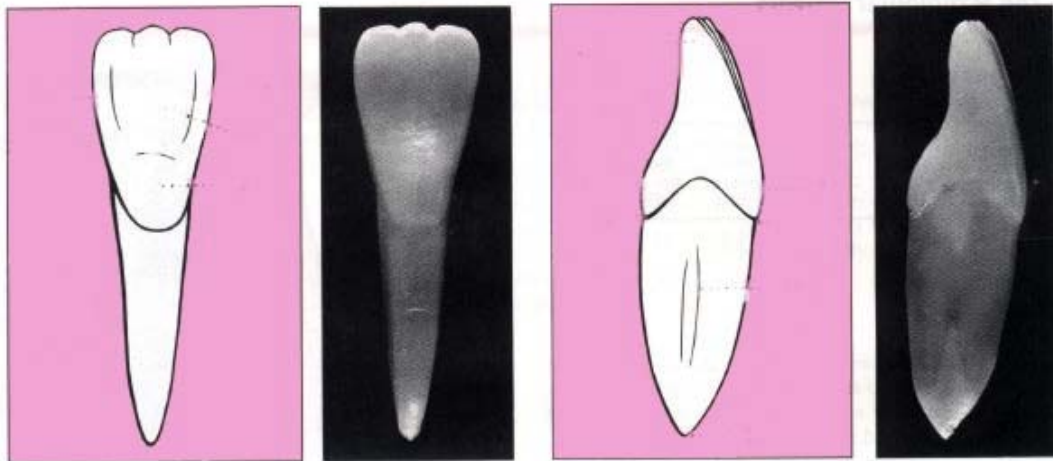


Figure 3.2: Crown to root relationship is normally 1:1.3 and the apex in line with the long axis of the tooth. (Acknowledgement: Jordan et al.<sup>(27)</sup>)

### 3.3 ROOT CURVATURE

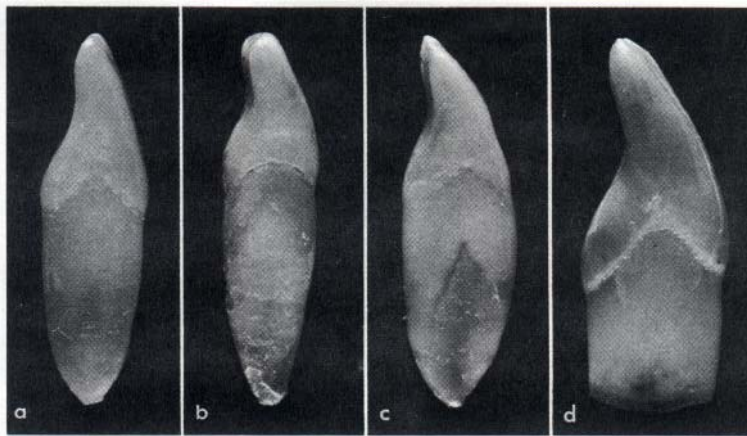
Although a slight bend of the root to the distal (when viewed from the front) is not an uncommon finding especially on the lower central incisor, bends that start abruptly are rarely encountered. (This is in contrast to the upper incisor teeth that are in close proximity to the nasal floor<sup>(30)</sup>.) Bends of apical root area to the labial or lingual are seldom encountered.

The apex of the root is thus encountered in the line of the long axis of the tooth in the sagittal dimension.

### 3.4 LABIAL SURFACE INCLINATION

Differences in inclinations of the labial surface of the crown are clearly demonstrated by the example in Figure 3.3.





*Figure 3.3: Differences in labial surface inclination of lower incisors.*

*(Acknowledgement: Jordan et al.<sup>(27)</sup>)*

### 3.5 SUMMARY

A summary of relevant anatomical features of the lower central and lateral incisors includes the following:

- mean lower incisor length:  $\pm 22$  mm, with variation from 16.9 to 28 mm.
- mean lower incisor labio-lingual dimensions:  $\pm 6$  mm, with variation from 4.8 – 7.4 mm.
- labial surface inclination varies as illustrated in Figure 2.3.
- the apex is in line of the long axis (sagittal view) of the tooth.

In Chapter VI the teeth used in this study will be compared to norms as quoted from the referred publications.

\* Proffit in *The evolution of orthodontics to a data-based Speciality* states explicitly “to prevail in a debate about the best way to do anything you need data to support your opinion.” He continues that “orthodontics has **no choice but to become a data-based speciality**”<sup>(31)</sup>.

## **CHAPTER IV**

### **DIFFERENT METHODS CURRENTLY USED TO DETERMINE LOWER INCISOR INCLINATION**

#### **4.1 INTRODUCTION**

The pros and cons of different methods to determine lower incisor inclination (for example: clinical assessment, study model analysis and analysis on lateral cephalometric radiographs) are discussed in this chapter.

#### **4.2 CLINICAL ASSESSMENT OF LOWER INCISOR INCLINATION**

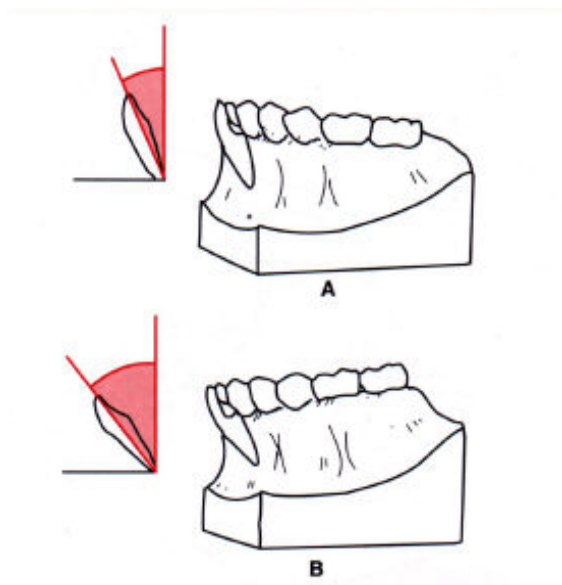
The inclination of the incisors can clinically be described as normal, proclined or retroclined. This assessment is usually done relating the incisors to the occlusal plane, profile or lower mandibular plane. These planes are not stable and can be altered with treatment.

Secondly, direct measurements are difficult clinically which implies comparison to other patients (or for the same patient pre- and post treatment) a subjective and non-scientific observation. Clinical description of inclination is, although important, subjective.

#### **4.3 STUDY MODELS TO DETERMINE INCISOR INCLINATION**

Jacobson explains why plaster casts cannot be used routinely to ascertain incisor inclination<sup>(16)</sup>. The inclination of the incisors can be very deceptive as they are related to the artistic portion of the study model base. The angle to which the plaster base is cut is not necessarily in accordance with the degree of incisor inclination in the mouth.

In the diagrammatic representations (Figure 4.1) of study models of a lower jaw, both casts could have been obtained from the same patient, thus illustrating the effect of different trimming of the plaster base. Judging the inclination of the incisors from the plaster base, those in figure A appear fairly vertical; where-as the same teeth in figure B appear labially inclined. Therefore, neither the inclination nor the extent of the antero-posterior jaw dysplasia or the degree of labial (or lingual) inclination of incisor teeth can be determined from a set of study models.




*Figure 4.1: A. Base or art position of study model cut more or less parallel to the occlusal plane. B. Base of study model cut at an angle relative to the occlusal plane of the teeth. This gives the impression of severe labial inclination of the incisor teeth.*

*(Acknowledgement: Jacobsen A<sup>(16)</sup>)*

Richmond et al. describes a method of assessing incisor inclination to overcome the above-mentioned shortcomings<sup>(32)</sup>. An instrument, the “tooth inclination protractor” (TIP) was developed to relate the incisor angulations specifically on study models (Figure 4.2). The tooth inclination protractor records the crown inclination to the occlusal plane. The authors point out that assessment of the crowns to the occlusal plane may be variable especially in the lower arch where problems may occur with a deep curve of Spee. Although the occlusal plane variability does not seem to be a factor in reliability, it may cause a problem

with validity when comparing the lower incisor to the occlusal plane and mandibular plane in pre- and post-treatment comparisons because the reference planes undergo changes during treatment.

It was found that the TIP consistently under-scores the lateral cephalometric radiographic determined maxillary incisor angulations by 10.46 degrees and consistently over-scores the lower mandibular incisor angulation by 2.57 degrees. The implication is that the study models measurements are adapted to cephalometric values (that are not perfect either!) and is therefore not ideal and rather unscientific.



*Figure 4.2: The tooth inclination protractor or "TIP" apparatus.*

*(Acknowledgement: Richmond S<sup>(32)</sup>)*

It can be concluded that determination of incisor inclination on study models is still unreliable, mainly due to the lack of a stable plane to relate to. The study model base as well as the occlusal plane is prone to undergo immeasurable and inconsistent changes.

#### 4.4 DETERMINING LOWER INCISOR INCLINATION ON LATERAL CEPHALOMETRIC RADIOGRAPHS

The most common method used to analyse the position of these teeth is by using lateral cephalometric radiographs. Common cephalometric measurements used in relation to the lower incisor are the following:

- lower incisor tip to N-B line (linear measurement - fig 4.3a )
- lower incisor tip and pogonion to N-B line (linear relationship – fig 4.3a)
- lower incisor tip to A-Po (linear measurement –fig 4.3c)
- lower incisor to N-B angulation (incisor inclination derived – fig 4.3a)
- lower incisor to mandibular plane angulation (incisor inclination derived – fig4.3a)
- lower incisor to upper incisor angulation (incisor inclination derived - fig 4.3b)

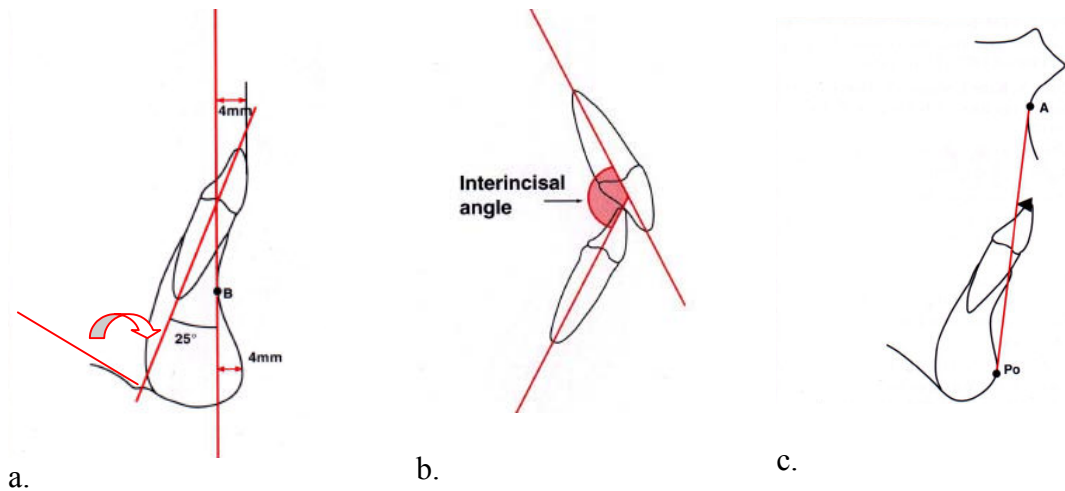
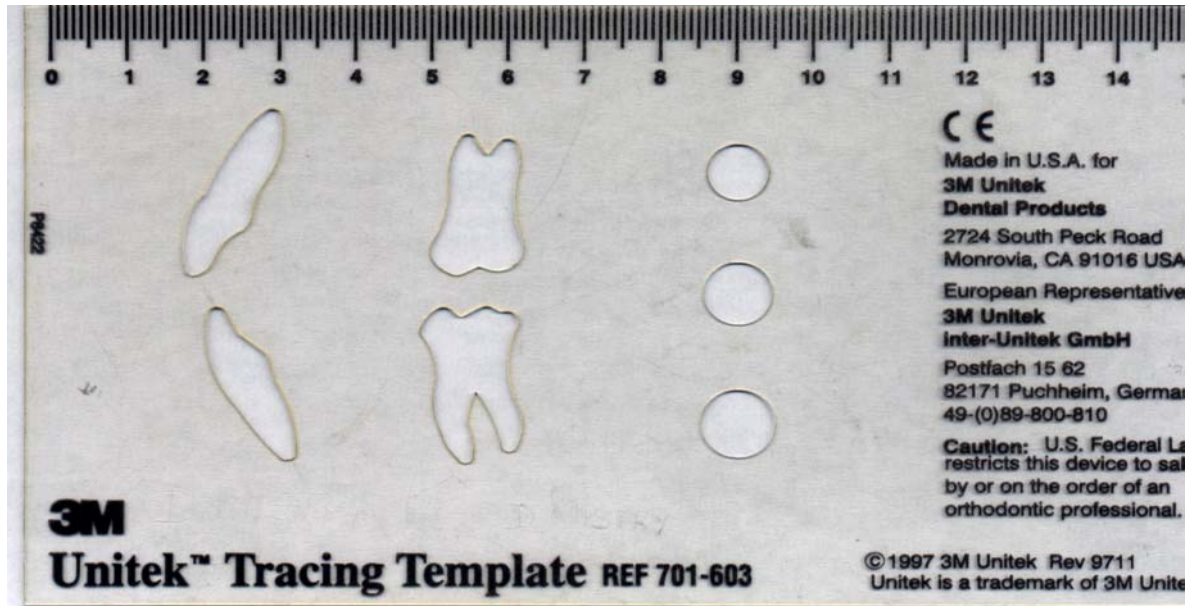


Figure 4.3: (a) Lower incisor to N-B line is 4mm; angulation to N-B line 25 degrees; angulation to mandibular plane 90 degrees and the incisor edge in a 1:1 relationship compared to pogonion to N-B line. (b) Inter-incisal angle. (c) The A-Po line of Ricketts is widely used to determine ideal incisor position. (Acknowledgement: Jacobsen A<sup>(16)</sup>)

A tracing template as illustrated in Figure 4.4 is usually implemented to produce a neat and reproducible image of the tooth.



*Figure 4.4: Steiner promulgates the use of a template to draw the outline of the lower incisor in one of his original articles on the “Steiner Analysis”<sup>(14)</sup>. The Unitek (3M) template is commonly used in South Africa. The template will be assessed in Chapter VI to confirm its relationship to the mean dimensions of the lower incisors as reported in literature.*

The lower incisor long axis is compared to another plane (e.g. mandibular plane) to obtain an angle. Two different reference planes are thus used and the angle between the two is measured to determine the inclination of the lower incisor. The inaccuracies of both planes (and the landmarks used to determine the planes) increase the margins of error. The observed error for a given measure is thus a function of:

1. the magnitudes of estimating error for the landmarks it interrelates,
2. the separation distances among those landmarks, and

- the directions from which the line segments connecting the landmarks intercept their envelopes of error<sup>(33)</sup>.

Chan et al. explain in Figure 4.5 the influences of landmark error in an article *Effects of cephalometric landmark validity on incisor angulation*, confirming that in the instance of the lower incisor inclination based on the mandibular plane as reference plane, the major contributing factors to error are the dental and not the skeletal landmarks<sup>(34)</sup>.

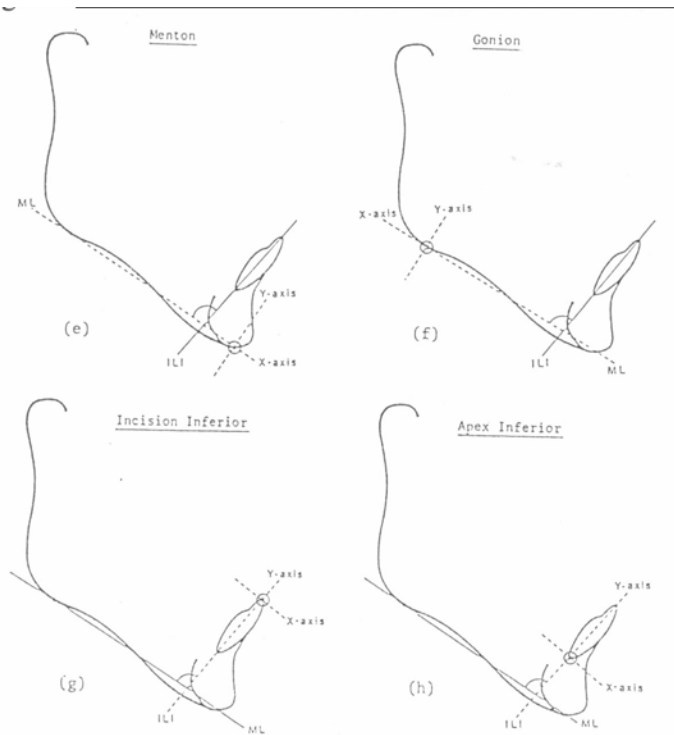


Figure 4.5: The effect of different landmark errors on inclination reliability. The error of location of a particular landmark along the true cephalometric plane will not, even if it is large, affect the inclination of the plane and the subsequent angular measure, but an error along its perpendicular will do so, even if it is comparatively small. This is especially true when the landmarks are situated close to each other as with the landmarks of the incisor<sup>(34)</sup>.

For the purpose of this study the influence of the second reference plane (mandibular plane) was excluded as the major contributing factor of error has been pointed out to be the long axis of the lower incisor.

The lower incisor is usually traced according to specific landmarks to determine the long axis of the tooth. Different landmarks to interpret the lower incisor axis are to trace from:

1. incisor edge to apex,
2. incisor edge parallel to the labial surface,
3. incisor edge to the middle of the symphysis and
4. the incisor edge through the middle of the tooth crown.

The influence of tracing the lower incisor long axis to the above mentioned different reference points will be discussed in more detail.

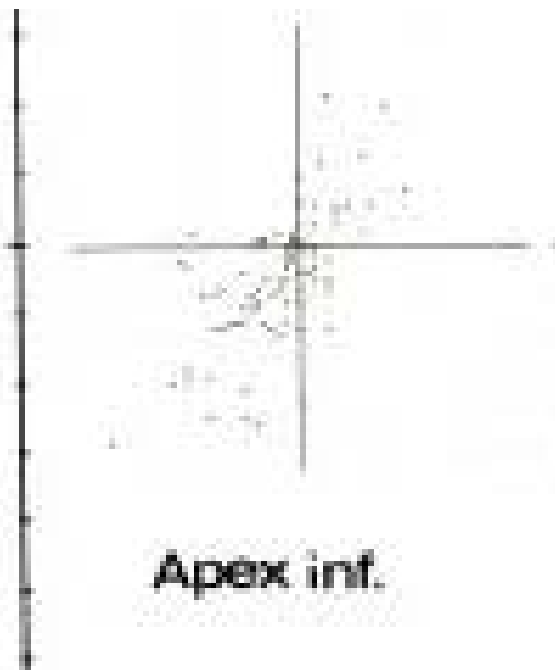
#### **4.4.1. Tracing from incisor edge to incisor apex**

When the incisor inclination is determined by locating and connecting the incisor tip and apex, the superior landmark (incisor edge or tip) is defined as the “incisal edge of the most prominent mandibular central incisor”; the inferior landmark defined as “the root apex of the most anterior mandibular central incisor”<sup>(16)</sup>. As already proved in the literature review on cephalometric landmarks, the lower incisor edge is a relatively reliable landmark. Correct location of the apex should be determined as accurately as possible if lower incisor inclination is determined from the apex as the inclination of the lower central incisor can play a vital role in cephalometric diagnosis, and ultimately, the treatment of the patient’s malocclusion. The lower incisor apex, however, is found to be unreliable with



deviations in the antero-posterior as well as the vertical dimensions. Figure 4.5 illustrates the effect of this unreliability on incisor inclination.

More evidence proving the unreliability of the lower incisor apex as cephalometric landmark is found in an article *Precision in cephalometric landmark identification* <sup>(35)</sup>. Stabrun and Danielsen find that the apex inferior was not located with confidence by the observers in 75% of the cases. Two observers recorded the relevant landmark on 100 cephalograms twice and in two categories for each observer: I - both assessments judged as uncertain; II – both assessments judged as certain. Recordings in which the two registrations differed (26 for observer A and 25 for observer B) were excluded. The observers best estimates compared to each other are illustrated below in Figure 4.6 while the intra-observer differences are presented in Figure 4.7.



*Figure 4.6: The inter-observer differences between the observers best estimates. The large variation is clearly demonstrated and a much larger variation would have resulted if all estimates were included. (Acknowledgement: Stabrun AE and Danielsen K <sup>(35)</sup>)*

The recordings of the first recording were all placed in the origin and the points represent the deviations compared with the other series. Figure 4.7 also illustrates the variability in double registrations for observer A and B of apex inferior when both the observers were judged uncertain and secondly when both registrations were judged certain.

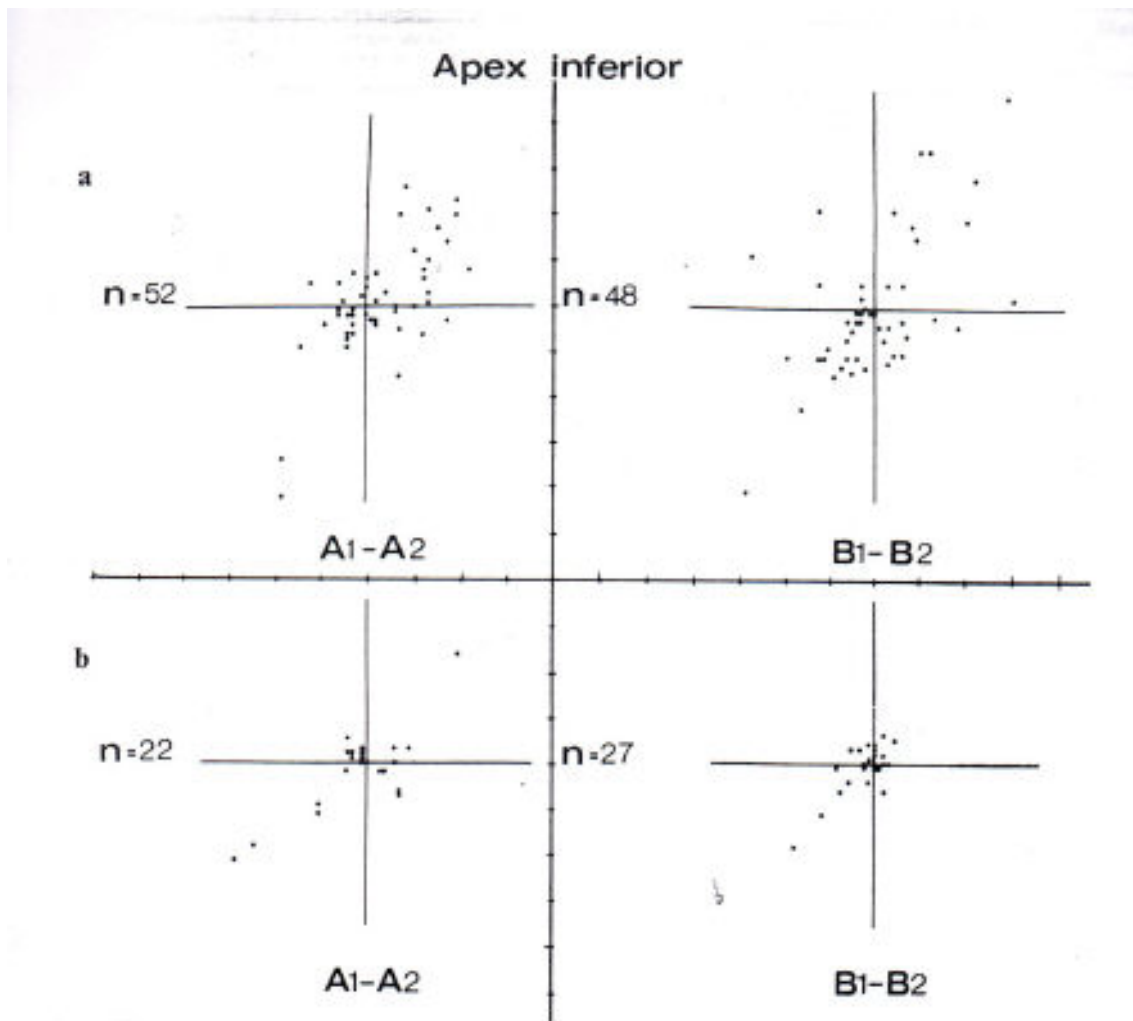
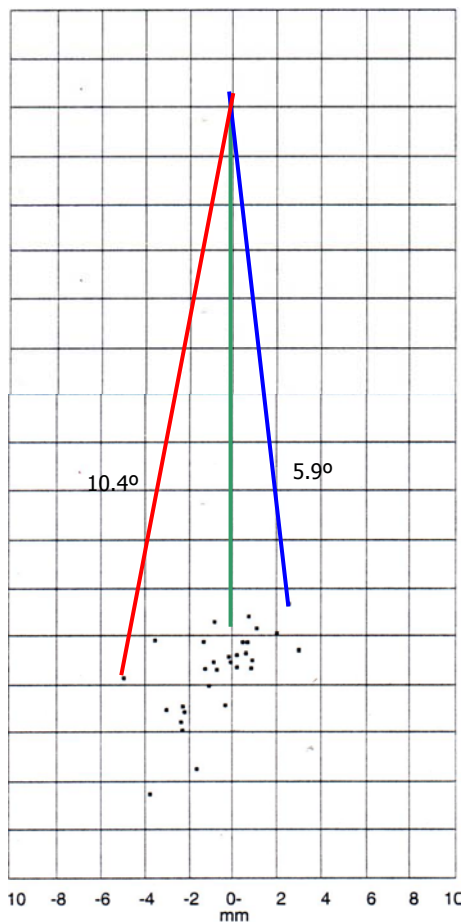


Figure 4.7: The intra-observer differences between the first and second recording of landmarks. (Acknowledgement: Stabrun AE and Danielsen K<sup>(35)</sup>)

Minor errors in incisor apex location, however have a vast adverse influence on the accuracy of the incisor inclination. If the study by Tng et al. (Figure 2.8) is used as an

example of the lower incisor apex location it would have influenced the determination of the long axis of the tooth as explained in Figure 4.8.



*Figure 4.8: If a mean length of 22 mm is assumed and the incisor edge presumed a stable reference point, the extreme possibilities of long axis determination to the different apex locations would result as illustrated. It is clear that a difference of 16 degrees is possible if the extreme anterior (blue) and posterior (red) apex locations are used. (Green line indicating the true inclination.)*

Phelps and Masri indicate that a 3mm deviation in the location of the apex buccally or lingually would cause an error of  $8^{\circ}$  <sup>(20)</sup>. This study concludes “the lack of certainty in locating apex inferior in 75% of cases should be taken into account when using the axial inclination of the lower incisor in diagnosis and treatment planning”.

**In summary, the literature overview clearly indicates the unreliability of the lower incisor apex as a landmark. That, by implication, leads to inaccurate assessment of the lower incisor inclination if the apex is used as a landmark to determine lower incisor inclination.**

#### 4.4.2 Tracing from incisor edge parallel to labial surface

The unreliability of locating the lower incisor apex led to some orthodontists overlaying the template on the labial surface of the crown to trace the relevant tooth (Figure 4.9).

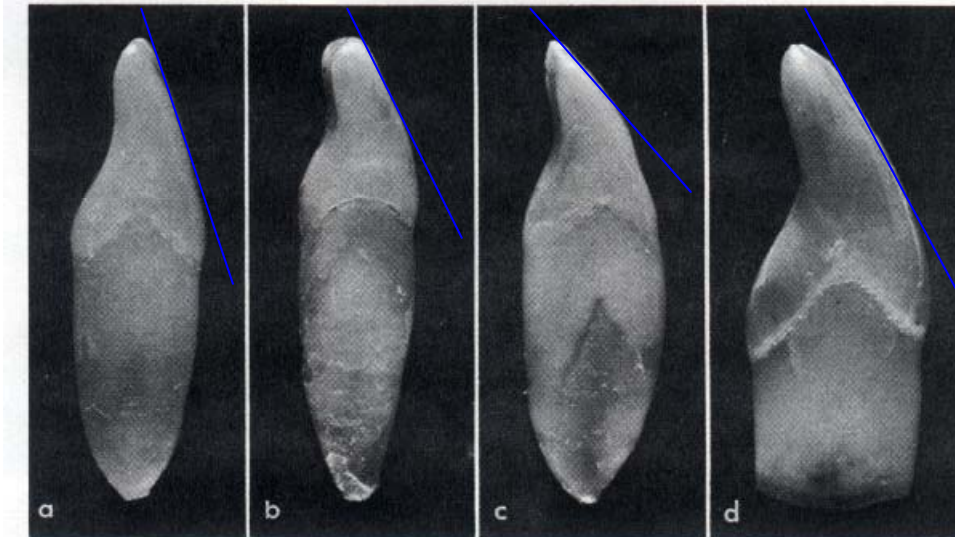


Figure 4.9: Different inclinations of the labial surface of the lower incisor might lead to invalid inclination determinations if the labial surfaces are used as a reference point. (Acknowledgement: Jordan et al. <sup>(27)</sup>)

This method is unreliable as the inclination of this surface is inconsistent and quite often poorly defined due to “noise” from adjacent superimposed structures.

#### 4.4.3 Tracing to the middle of the symphysis

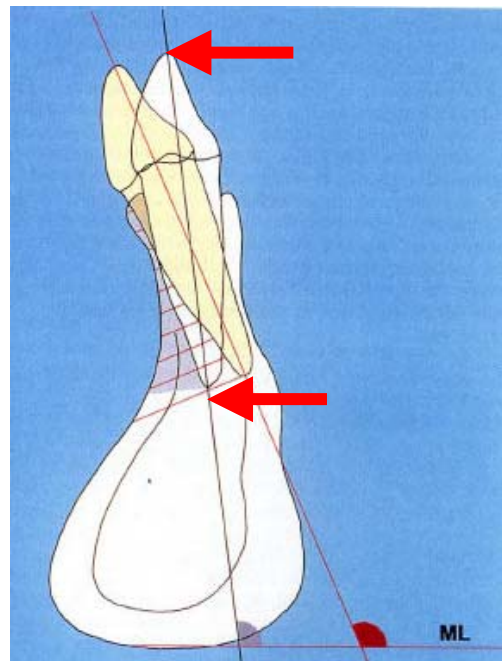
Phelps and Masri in a recent article *Location of the apex of the lower central incisor* state: “Of the common lateral cephalometric landmarks, the apex of the lower central incisor is perhaps the most difficult to accurately locate” <sup>(20)</sup>. This study used 38 complete skulls (aged 16-39 years; mean 22.8) to define the radiographic anatomy surrounding the true apex. Metallic markers were placed in the socket apex of the lower central incisor.

Measurements from the markers to the lingual and labial symphyseal borders determined that the true location of the lower central incisor apex is most often found in an approximate 60:40 ratio from the external labial outline of the symphysis at the apical level. In 9 skulls the marker ball was located lingual to the centre of the symphysis with an average deviation of 0.28 mm.

The study of Phelps and Masri concludes that the apex of the lower central incisor should be located “slightly forward of halfway from the lingual to the labial surface of the symphysis at the apical level” on a cephalometric radiograph as illustrated in Figure 4.10<sup>(20)</sup>.

*Figure 4.10: Tracing of the incisor inclination from incisor edge to the middle of the symphysis as indicated by the arrows may be the method of choice in untreated patients.*

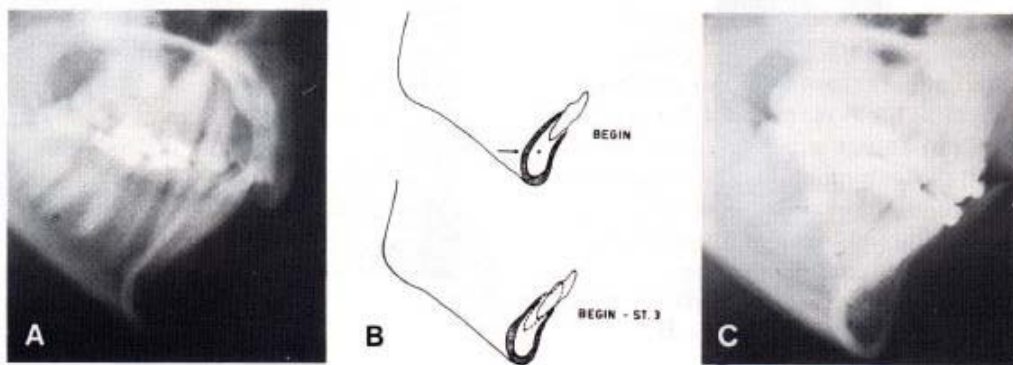
*(Acknowledgement: adapted from Nauert K and Berg R<sup>(36)</sup>)*



Chan et al., however, report in their study on cephalometric landmark validity that they found the lower incisor apex very close to the buccal plate in a few instances<sup>(34)</sup>. A point

of criticism is that although an antero-posterior estimate to locate the lower incisor apex is suggested, the length of the lower incisor varies and this influences the height at which the middle of the symphysis should be determined. It is furthermore important to keep in mind that the study by Phelps and Masri was performed on unclaimed (patients assumed never been orthodontically treated) skulls.

The effects of treatment tend to specifically move the apices while aligning the incisal edges. Fuhrmann highlights the effects of orthodontic tooth movement in the symphysis area and mentions that the loss of thin bone plates may be induced by force of orthodontic tooth movement<sup>(37,38)</sup>. Fuhrmann also mentions that the labio-lingual diameter is commonly overestimated on cephalometric radiographs in comparison to objective measurements<sup>(39)</sup>. It is critical to take this into consideration before treatment commences. The anatomy of the symphysis is classified by Mulie and Ten Hoeve in three types of symphyses as illustrated in Figures 4.11 – 4.13<sup>(40)</sup>.



*Figure 4.11: Type I symphysis with the incisors in the middle of a relatively wide symphysis.*

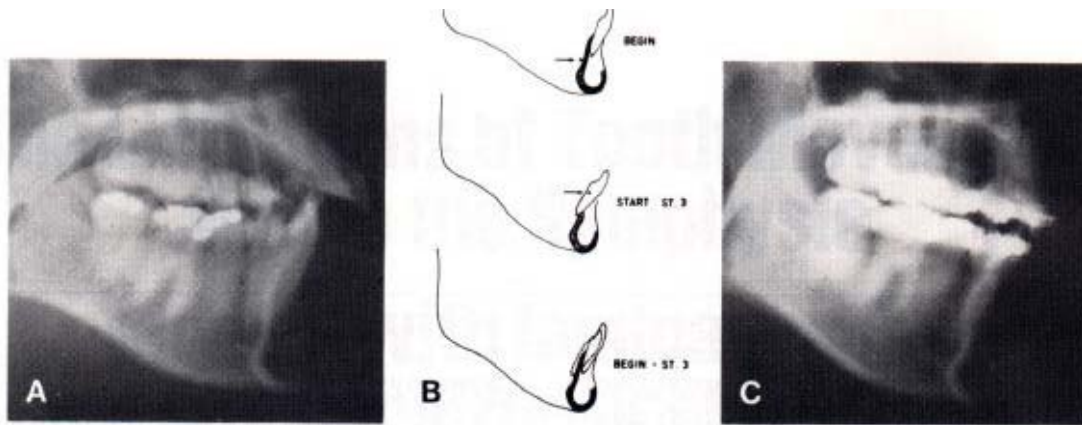


Figure 4.12: Type II symphysis – the symphysis is narrower.

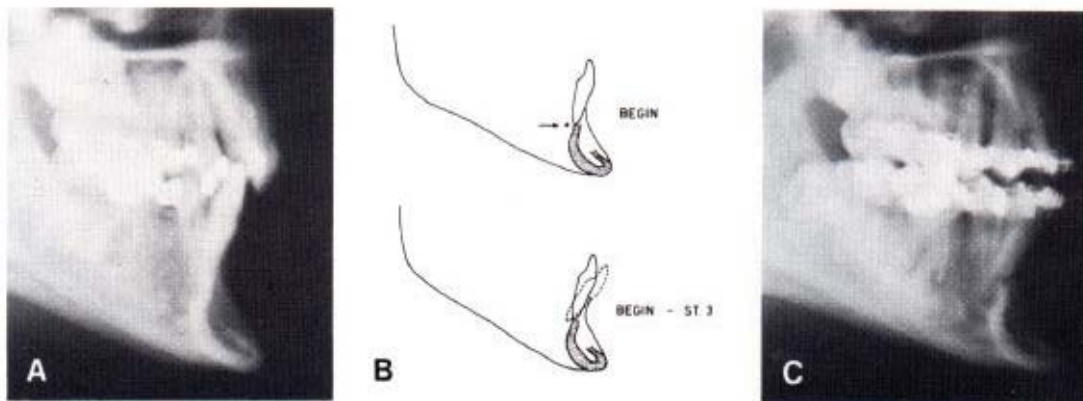


Figure 4.13: Type III symphysis – where the cross-section of the alveolar process reveals hardly enough space to contain the incisor roots. (Acknowledgement: Mulie RM and Ten Hoeve A<sup>(40)</sup>)

In the study by Mulie and Ten Hoeve it was found that the apices of the lower incisors were orthodontically moved “through the dense cortical plate and are now lingual to their bony structure” in type III symphysis<sup>(40)</sup>. An explicit example of the results in a case of a narrow and high symphysis, pronounced sagittal incisor movements and derotation during routine orthodontic treatment with a fixed appliance can lead to progressive bone loss of lingual and labial cortical plates as presented in Figure 4.14<sup>(41)</sup>.

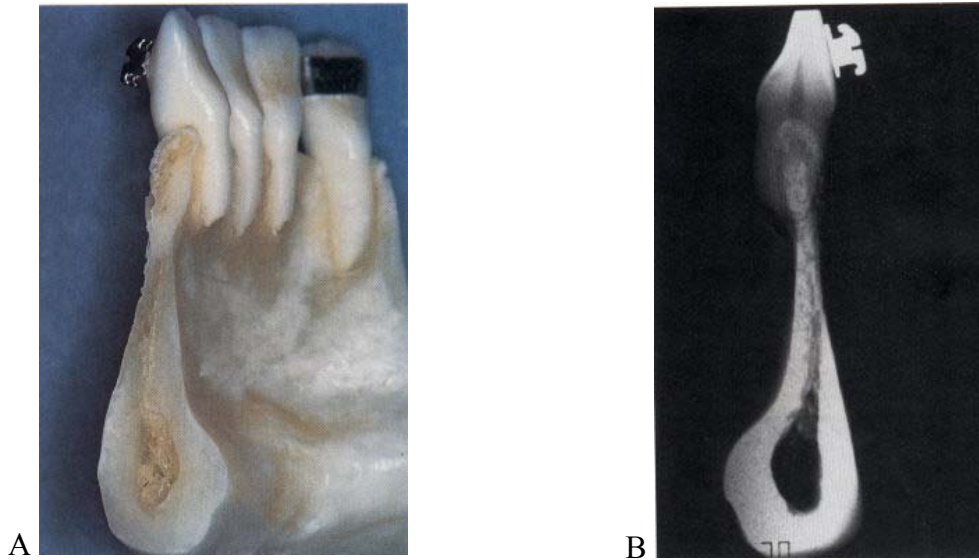


Figure 4.14: A. Anterior part of mandible from left side: lingual aspects of incisors are strongly protruded out of lingual surface of alveolar bone. B. Dental contact film of left lateral incisor/bone segment: labio-lingual diameter of incisor root is recognizably larger than both sagittal width of symphysis below apex and that of alveolar bone adjacent to tooth. (Acknowledgement: Wehrbein et al. <sup>(41)</sup>)

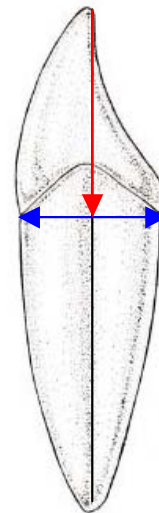
**In conclusion: locating the apex to the middle of the symphysis may be appropriate and practical for untreated patients, but not for orthodontically treated patients, which renders this method impractical for post-treatment evaluation.**



#### 4.4.4 Tracing from incisor edge through the midpoint of the crown

Athanasio states that “the midpoint on the bisection of the apical root width can be used” to determine the long axis of the tooth <sup>(15)</sup>. This method, as demonstrated in Figure 4.15, is to be researched in detail for the purpose of this study in conjunction with the use of lead markers to define reference marks.

*Figure 4.15: Inclination of incisor determined by a line from incisor edge through the midpoint of the bisection in the labio-lingual dimension at the crown-root junction.*



The routine use of this method is currently troubled by difficulty in locating the crown of a specific lower incisor because of:

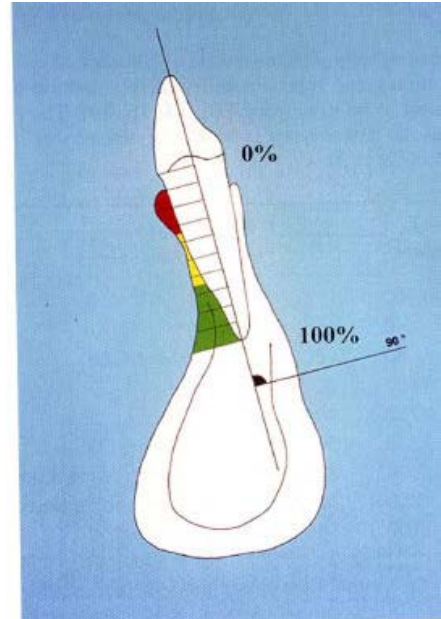
- super-imposed structures. Adjacent teeth (the lateral incisors) are in the same sagittal plane and often impossible to differentiate from the central incisors on a lateral cephalometric radiograph. In deep bite cases the upper incisors (and upper canines in extreme instances) tend to obscure lower incisors.
- if the lower incisors are rotated they will not project in a true lateral image. Measurements will also be compromised, as the measurements from lower incisor edge should be taken from the mesio-distal centre of the incisor edge.

These factors negatively influence the accuracy of this method, but the use of radiographic markers may overcome these problems and will be researched in this study.

#### 4.5 COMPUTED TOMOGRAPHY

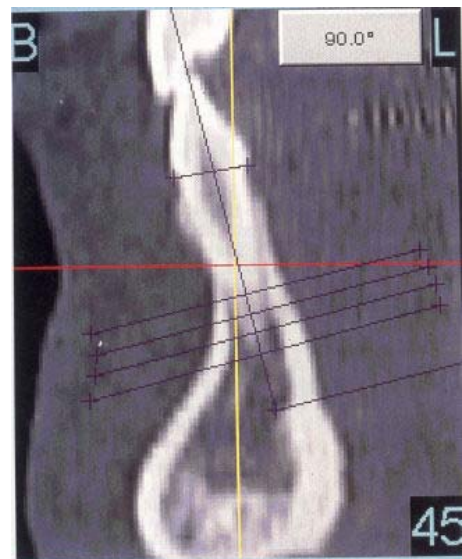
Computed tomography can be used to exactly locate the lower incisor apex, but it is impractical for day-to-day use because of the cost involved. It is however, a very accurate research tool that could be used to validate other common methods of locating cephalometric landmarks (Figure 4.16; 4.17) .

*Figure 4.16: Computed tomography is costly and the radiation exposure is higher than the exposure necessary for routine orthodontic radiographs. It is, however, the ideal method to validate incisor inclination methods in ex vivo studies for example on human skulls. (Acknowledgement: Nauert K and Berg R<sup>(36)</sup>)*



*Figure 4.17: This CAT-scan clearly reveals the exact location of the incisor apex. Note the apex in the middle of the symphysis as Phelps and Masri have concluded in another study.*

*(Acknowledgement: Nauert K and Berg R<sup>(36)</sup>)*



#### 4.6 CONCLUSION

Current methods applied to determine lower incisor inclination can be summarised as follows:

- Clinical assessment is subjective and it is impossible to describe inclination with clinical assessment in a quantified, measurable way.
- Analysing lower incisor inclination on study models is either subjective or impractical.
- The various methods of determining the inclination of the lower incisor on a lateral cephalometric radiograph have also been proofed unreliable, mainly because the lower incisor apex cannot be reliably located.
- The only method to exactly define lower incisor inclination is with CT - scans, but it is impractical for routine use.

**This study therefore suggests the use of radiographic markers on the crown of a specific lower incisor to overcome abovementioned shortcomings to determine the inclination of the lower incisor.**

\* Baumrind in *Clinical research about clinical treatment. A new agenda for a new century* summarises: “the assumptions underlying the advocacy of ‘evidence-based treatment’ are **(1) that the better the available evidence, the better our clinical judgements will be, and (2) that the better our clinical judgements, the better the outcomes of our treatments will be**”<sup>(42)</sup>.

## CHAPTER V

### RESEARCH METHODOLOGY

#### 5.1 INTRODUCTION

This study proposes a new technique with which the crown of the lower incisor can be clearly distinguished and the inclination of the tooth be derived from the radiological image on the cephalometric x-ray of the crown and not the apex. By using radiographic dental markers to indicate the crown portion of the tooth, the specific tooth and anatomical crown should be clearly defined. The use of metal markers (or other radio-opaque materials) in radiography is not new – in the well-known studies of Björk tantalum was used in growing animals and human beings for precise orientation in serial cephalometric analysis and are still the benchmark references regarding growth studies <sup>(43)</sup>. Specific reference to dental radiographic markers are, however, not found in the literature, except in one instance where Broadway et al. mention that they attempted to adapt thin lead foil to the upper and lower incisors but found no increase in accuracy of tracing the teeth and close adaptation difficult <sup>(44)</sup>.

#### 5.2 MAIN AIM AND SUB-AIMS

The main aim of the study was to determine whether a line through the tip of the tooth and bisecting the crown in the sagittal dimension at the crown-root junction is a valid method to establish the relevant tooth inclination. Most clinical measurements are not precise, either because measurements of the quantity of interest cannot be made directly or the measurement in itself is difficult to make. These uncertainties make evaluation of different methods to compare different techniques of clinical measurement difficult, as the degree of

agreement to an estimation rather than hypothesis testing are concerned. No specific hypothesis was therefore formulated for this study.

### **Statistical analysis**

Descriptive statistical analysis will be applied to scientifically interpret the data. Inter- and intra-observer comparisons will be analysed and the results discussed accordingly.

The results will also be compared to other studies regarding the accuracy and reproducibility of incisor inclination as determined and analysed by other researchers. The method suggested by Altman specifically applicable to medical method comparison studies will be applied to the results <sup>(45)</sup>. This approach regarding the “limits of agreement” implies that given a measurement, what are the limits on the error compared to the true agreement?

If this method is found to be more accurate with a smaller standard deviation than found with other methods, it could be accepted as a relevant method of determining lower incisor inclination.

### **Sub aims**

A few variables were involved when investigating the main aim of the study. The following sub aims were formulated to highlight and investigate these variables.

- **Sub aim 1:** To verify that the teeth used in the study conform to normal dimensions for lower incisors

- **Sub aim 2:** To confirm that the template dimensions used to trace the teeth are correct.
- **Sub aim 3:** To evaluate the potential of radio-opaque dental markers to exactly define the incisor crown anatomy in the sagittal dimension.
- **Sub aim 4:** If the results of the investigation were encouraging a pilot study on patients could follow.

The methodology to investigate the use of radio-opaque markers to define the incisor crown anatomy in lateral cephalometric head films and deriving a method to determine tooth inclination will be discussed in detail in the following chapter.

### **5.3 VERIFICATION OF TEETH USED IN THE STUDY (Sub aim 1)**

#### **5.3.1 Origin of teeth used in the research project**

Extracted lower incisors were obtained from the department of Maxilla-Facial and Oral Surgery, School of Dentistry, Faculty of Health Sciences of the University of Pretoria. (Patients sign a general consent form that allows the use of extracted teeth for research and teaching purposes.) The teeth obtained were extracted mainly because of advanced periodontal disease. Fifty teeth with the least amount of attrition were selected for purposes of this study as the lower incisors of orthodontic patients (that are usually of younger age) generally have limited attrition.

### **5.3.2 Comparison of teeth used in the study to normal dimensions**

The teeth were analysed to ascertain whether they conform to normal dimensions for lower incisors as indicated by a literature survey in chapter III. Length (incisal edge to apex) and labio-lingual width (at the crown-root junction) measurements were obtained to relate the teeth to the norms as provided by the literature survey.

### **5.4 TEMPLATE VERIFICATION (Sub aim 2)**

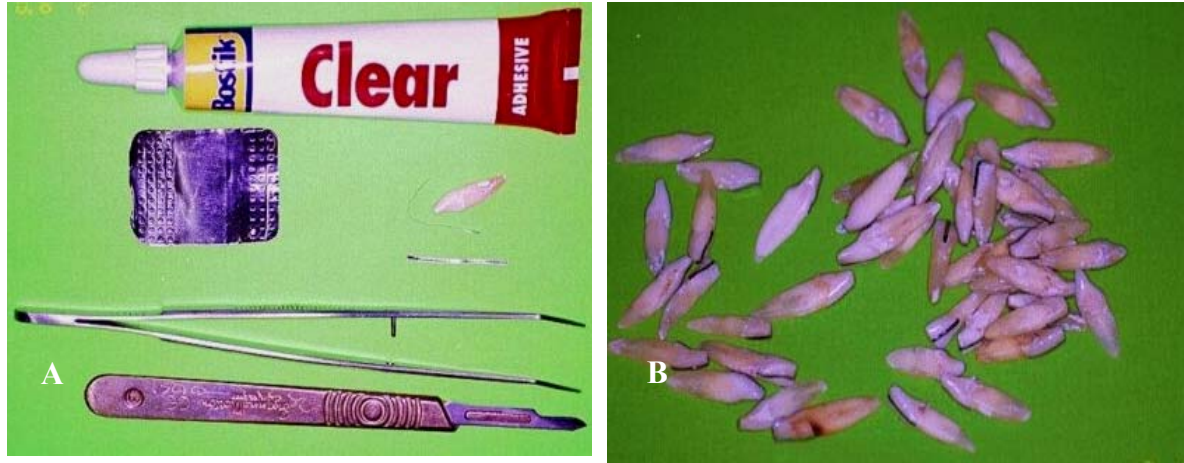The 3M-Unitek template was used in this study. A tracing from the relevant tooth was analysed to evaluate its relation to the normal anatomy of the lower central incisor regarding:

- overall length
- and labio-lingual width at crown- root junction.

These measurements were compared to the norms for lower incisors as obtained in the literature review in chapter III to ensure that the template dimensions used to trace the teeth are correct.

### **5.5 RADIOGRAPHIC MARKERS (Sub aim 3)**

As radiographic markers for use on teeth are not commercially available, radiographic markers were manufactured by cutting lead-film from used radiograph films into 1mm wide strips (Figure 5.1.A). The lead film was attached to the crowns of the teeth to create a clear image of the tooth crown on a radiograph in the required labio-lingual dimension as depicted in Figure 5.1.B. (Different alternatives like barium-sulphate, radio-opaque cement, orthodontic wire and the lead film from x-ray films were tested in a preliminary study. The lead-film strips provided the clearest image on a radiograph.)

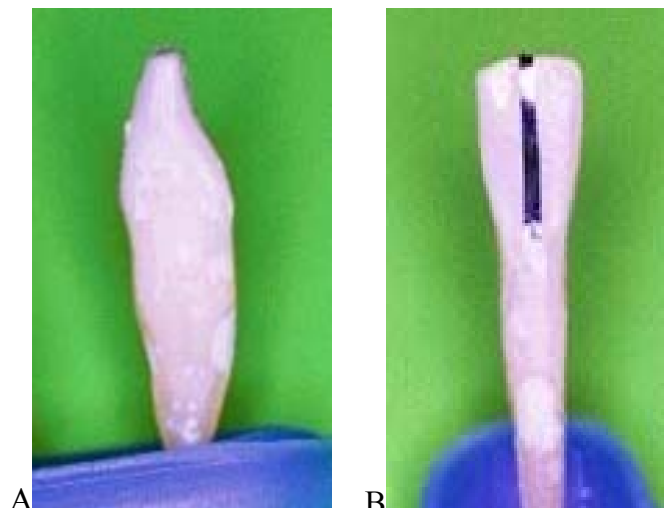


*Figure 5.1: A. Radiographic markers were cut from lead-film and fixed to the teeth with a well-known general-purpose adhesive. B. Some of the teeth used with radiographic markers in place.*

The lead-film strips were bonded from the middle (mesio-distally) of the labial crown-root junction across the middle of the incisal edge to the middle of the lingual crown-root junction to outline the crown in a sagittal dimension on a lateral radiograph (Figure 5.2).

*Figure 5.2: A. Radiographic marker is placed to define the tooth crown in the sagittal dimension.*

*B. The lead film bonded onto the tooth crown through the middle of the incisal edge in a mesio-distal dimension.*





## **5.6 PILOT STUDY (Sub aim 4)**

Utilising lead-film strips as radiographic markers would be tested by the candidate in a clinical situation. Discussion of the clinical implementation is reported in chapter VII.


## **5.7 MAIN AIM REALISATION**

The teeth were mounted on Perspex and radiographs taken with the roots visible and also with the roots obscured. Three different observers estimated the inclination of the incisors on two separate occasions on the radiograph with the roots obscured. The true inclination was determined on the radiograph where both the incisor crown and apex were visible. The tracings were then scanned into electronic format and statistically analysed. The detailed procedures regarding the methodology are discussed on the following pages.

### **5.7.1 Set up of teeth**

A Perspex sheet of 4mm thickness was cut and a base for the sheet manufactured as illustrated in Figure 5.3. The base was constructed to enable positioning (and exact repositioning) of the Perspex sheet in the sagittal plane in the centre of the ear rods of the cephalostat. These steps were taken to:


- Ensure exact repositioning of the teeth between exposures
- Obtain the same enlargement and distortion that would normally arise for lower incisors in patient lateral radiographs.



*Figure 5.3: The Perspex sheet on which the teeth were mounted with the base in which the sheet could be exactly repositioned.*

The teeth were randomly mounted at different inclinations in rows of ten on a Perspex sheet. The teeth were numbered 1-50. The first four rows (no 1-40) were mounted in the true sagittal plane, but the teeth in last row (41-50) were rotated along the incisal/apex axis to simulate rotated lower incisors (Figure 5.4).

Figure 5.4: The teeth mounted on the Perspex sheet.




### 5.7.2 Radiographs taken

The Perspex sheet was positioned in the normal mid-sagittal plane in the cephalostat as pictured in Figure 5.5.A. The roots of the teeth were covered with lead film to obscure the roots for radiograph B (Figure 5.5.B).




Figure 5.5: A. Positioning of the Perspex sheet with the teeth in the cephalostat. B. The roots of the teeth were covered with lead film when radiograph B was taken.

The first radiograph (Radiograph A- Figure 5.6) for the experiment was taken with the lead-markers in place on the crowns of the teeth and the roots uncovered.



*Figure 5.6: Radiograph A with the roots clearly visible to obtain the true angulation of the teeth.*

The Perspex sheet was removed from the base and the roots of the teeth covered with lead-film up to the crown-root junction to obscure the roots. A second radiograph (B) as presented in Figure 5.7 was taken after exact repositioning of the sheet.




*Figure 5.7: Radiograph B: the roots were obscured and only the crowns were visible. (Crown-root junctions were not always clearly visible, but judged subjectively to be clear enough not to influence the outcome of the study.)*

### 5.7.3 Tracing of the radiographs

Tracings were done on acetate sheets (Ozatex 0,5mm; Ozalid) with predetermined printed lines to standardised reference points on the radiographs.


Three independent observers (1, 2, 3) were requested to analyse the radiographs at two different times (two months apart). The observers were registrars in the Department of Orthodontics, School of Dentistry, Faculty of Health Sciences of the University of Pretoria. The observers were instructed to trace the teeth on radiograph B (crowns with lead-markers but roots obscured) using the 3M-Unitek template in a specified way. The observers had to position the template over the tooth crown with the incisal edge overlaying the relevant landmark on the radiograph and the labio-lingual crown-root junction of the template over the radiograph image in such a way that equal distances would be obtained to the labial and lingual tooth surfaces. The last row of teeth were mounted in such a way on the Perspex that it would mimic rotated anterior lower incisors. Observers were instructed to trace these teeth with the middle of the lead-marker line equal distance to the template dimensions at the crown-root junction. Observers were requested to indicate the inclination of all teeth with a line from the incisal edge to the apex of each tooth.

The tracings were repeated two months later. Tracings for radiograph B were numbered 1B1, 2B1, 3B1, 1B2, 2B2 and 3B2 indicating the observer number, radiograph B and tracing number 1 or 2. Only the first tracings of the observers are presented on the following pages in Figures 5.8 –5.10.




*Figure 5.8: Tracing 1B1: observer number 1, radiograph B, the first tracing.*

- The tracings were repeated two months later.



*Figure 5.9: Tracing 2B1: observer number 2, radiograph B, the first tracing.*





*Figure 5.10: Tracing 3B1: observer number 3, radiograph B, the first tracing.*

After the tracings by the observers the true angulations of the teeth (as taken from the middle of the incisal edge to the true apex) were drawn on radiograph A with the roots uncovered and apex clearly visible (Figure 5.11). Determining the true inclination was done on consensus basis by the three observers and the researcher. If any doubt existed the teeth on the Perspex sheet were analysed as well.



Figure 5.11: The true angulation of the teeth as determined on radiograph A.

### 5.7.4 Transfer of data for electronic processing

The tracings were scanned using Genius Colour Page HR5 Pro Scanner into electronic format at 600 dpi. These scanned images were then imported into CorelDraw 10 onto separate pages at the same x and y co-ordinates that each tracing could be overlaid onto each other to form composite tracings. Each reference line with the inclinations as determined by the observers was translated into CorelDraw 10. The inclination as determined by the observer on the tracing was copied in electronic format and afterwards measured as illustrated in Figure 5.12.

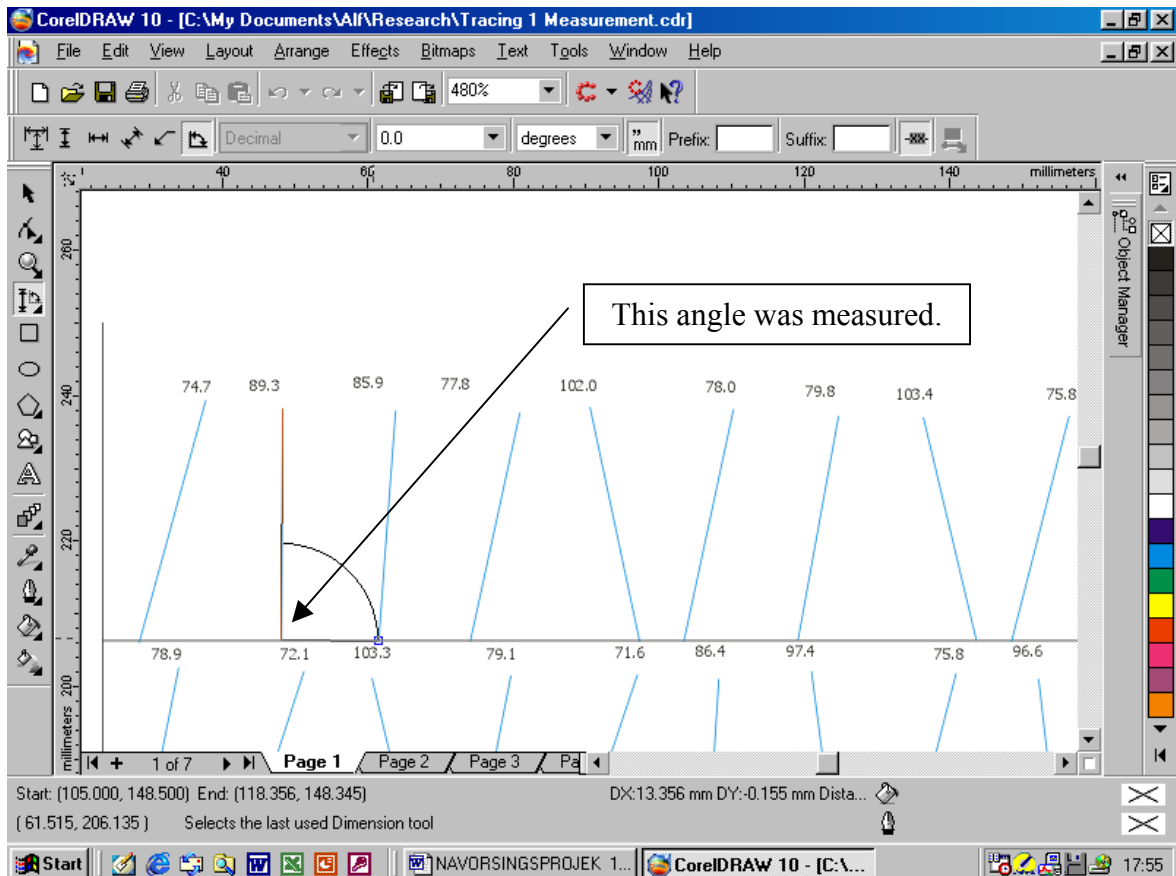


Figure 5.12: Each inclination was measured using CorelDraw 10 dimension tool.

The same procedure was followed for all the tracings. By applying this method the inclinations could be superimposed to supply a graphical overview to compare the tracings both intra- and inter-observer.

The differences between inclinations of the teeth as determined by the various observers and the true inclination could then be measured in comparison with a reference line to enable scientific interpretation. Different colours were allocated to different observers: Observer 1: blue, Observer 2 : red, Observer 3 : green and the True inclination black.

\* Hans is of meaning that it is likely that our profession will be challenged in the near future to “produce data, to support some of our long-held clinical beliefs”. He continues with the following statement: “Science by its nature demands quantitative methods. Therefore one question that must be answered is, ‘**what are the measurable outcomes of orthodontic treatment?**’ A ‘healthy smile at any age,’ a functional occlusion, success in the job market, increased self-esteem? Although they may be difficult to develop, **quantitative measures are needed to provide a scientific foundation for our treatment plans**”<sup>(3)</sup>.

## CHAPTER VI

### RESULTS AND DISCUSSION

#### 6.1 INTRODUCTION

The results of the study and discussion of the results are presented in accordance with the sub aims and main aim formulated in the previous chapter. Sub aims 1, 2 and 3 were prerequisites for investigating the main aim. Therefore the results and discussion of the investigations regarding these sub aims are presented before the report of the results of the main aim. Sub aim 4 implies clinical implication of the results of the main aim and is reported separately with clinical photos in chapter VII. The sequence of this chapter is thus:

**Sub aim 1:**

To verify that the teeth used in the study conform to normal dimensions for lower incisors.

**Sub aim 2:**

To confirm that the template dimensions used to trace the teeth were correct.

**Sub aim 3:**

To evaluate the potential of radio-opaque dental markers to exactly define the incisor crown anatomy in the sagittal dimension.

**Main aim:**

The main aim of the study was to determine whether a line through the tip of the tooth and bisecting the crown in the sagittal dimension at the crown-root junction is a valid method to establish the relevant tooth inclination.

**6.2 VERIFICATION OF TEETH USED IN THE STUDY (Sub aim 1)**

**Results**

The lengths and labio-lingual dimensions of teeth used in this study appear in Table 6.1. The teeth were not sub-divided into central or lateral lower incisors and the patient ages or sexes were not known.

<i>Tooth number</i>	<i>Incisor edge to Apex</i>	<i>Labio-lingual dimension</i>	<i>Tooth number</i>	<i>Incisor edge to Apex</i>	<i>Labio-lingual dimension</i>
1	22.8	6.0	26	17.8	6.1
2	19.0	5.6	27	21.3	6.1
3	19.5	5.8	28	21.8	6.6
4	20.0	6.2	29	21.0	6.3
5	22.8	6.5	30	19.6	5.7
6	18.7	6.3	31	21.9	5.7
7	18.6	5.4	32	22.1	6.4
8	23.4	6.5	33	20.4	6.0
9	19.7	5.5	34	19.9	6.3
10	20.4	6.3	35	19.6	5.9
11	17.8	5.5	36	20.7	6.5
12	18.0	5.4	37	22.0	5.6
13	20.0	6.3	38	24.6	6.4
14	17.4	5.3	39	21.4	5.7
15	19.7	5.4	40	22.8	6.5
16	21.5	6.2	41	24.3	5.9
17	19.6	6.4	42	22.0	6.0
18	21.5	6.0	43	21.8	5.5
19	16.5	5.8	44	21.3	5.6
20	21.0	6.2	45	22.3	5.5
21	18.0	5.0	46	19.1	5.6
22	18.5	5.6	47	22.4	5.8
23	22.3	5.9	48	18.1	5.4
24	21.9	5.8	49	19.4	5.4
25	23.0	6.5	50	21.3	5.9

*Table 6.1: The lengths and labio-lingual dimensions of teeth used in this study in millimetres. (Blue – minimum dimensions; red – maximum dimensions)*

Maximum and minimum dimensions for the teeth used in the study were as follows:

- maximum length: tooth nr. 38: 24.6mm
- minimum length: tooth nr. 19: 16.5mm
- maximum labio-lingual width: tooth nr. 28: 6.6mm
- minimum labio-lingual width: tooth nr. 14: 5.3mm

The mean length of the lower incisors used in this study was 20.6mm (range 16.5 – 24.6) with a mean labio-lingual dimension of 5.9mm (range 5.3 – 6.6).

### **Discussion**

The ranges of other observers (Chapter III) for central and lateral lower incisor teeth lengths vary from 16.9 to 28.0 mm's and labio-lingually dimensions from 4.8 to 7.4mm's<sup>(5,27,29)</sup>. Mean lengths for centrals are 20.8<sup>(5)</sup>; 21.5<sup>(27)</sup> and 22.0<sup>(29)</sup>mm's; while the mean for lower lateral incisors were 22.1<sup>(5)</sup>; 23.5<sup>(27)</sup> and 24.0<sup>(29)</sup>mm's for the various researchers. Teeth used were thus generally shorter than the mean as found by other observers. It may be ascribed to the teeth having more attrition than would usually be found in orthodontic patients, as it can be assumed that most of the teeth were extracted in older patients because of advanced periodontal disease. Another possible explanation is that there were more lateral incisors (that are slightly longer) than central incisors in the study sample.

### **Conclusion**

Regarding sub aim 1 "to verify that the teeth used in the study conform to normal dimensions for lower incisors" it could be concluded that:


**for purposes of this study to investigate an alternative method for incisor inclination the dimensions of the teeth used in the investigation were acceptable.**

### 6.3 TEMPLATE VERIFICATION (Sub aim 2)

#### Results

A tracing of the template was analysed in the length and width and compared to the norms for the central lower incisor (Figure 6.1). The template tracing had dimensions of 23.8 mm and 6.0 mm.

*Figure 6.1: The template drawing provided a tooth with a length of 23.8 mm and a labio-lingual dimension of 6.0 mm at the crown-root junction.*



#### Discussion

If it is assumed that the general enlargement factor is 8% on lateral cephalometric radiographs, the true object size of the tooth represented by the template tracing would be 22.04 mm by 5.56 mm ( $23.8 \times 100/108 = 22.037$  and  $6 \times 100/108 = 5.555$ ). The ranges of other observers (Chapter III) for central and lateral lower incisor teeth lengths vary from 16.9 to 28.0 mm's with labio-lingual dimensions from 4.8 to 7.4 mm's<sup>(5, 27, 29)</sup>. The tooth presented by the tracing was therefore found to be within the normal range of lower incisors.

The use of the template has shortcomings as it translates all teeth to a standardised norm. This does not imply that template drawings should be discarded and every tooth drawn to a



separate specifically predetermined size. That would be impractical. It is, however, important to keep the shortcomings and the adverse effects it may have in consideration.

### **Conclusion**

In relation to sub aim 2 “to confirm that the template dimensions used to trace the teeth were correct” the conclusion can be made that **the template supplied a tracing of the lower incisor that conforms to mean dimensions of the relevant tooth.**

## **6.4 RADIO-OPAQUE DENTAL MARKERS TO DEFINE THE INCISOR CROWN ANATOMY (Sub aim 3)**

### **Results**

The radiographic markers gave a clear image of the crown in the sagittal dimension as is obvious on the relevant radiographs (Figure 5.6; 5.7). The clinical advantages of such a clear image are discussed in chapter VII in relation to *in vivo* application on selected patients.

### **Discussion**

Quite often rotated teeth have to be analysed. The effect on linear measurements like the incisor edge to the APO-line can be compromised when this measurement is not taken from the centre mesio-distally of the incisor edge. The radiographic markers as used on the rotated teeth numbers 41-50 clearly indicated the middle of the incisal edge (Figure 6.2). Advantages of using radiographic markers in this regard are that it should enable true, constant and exact measurements from a specific reproducible reference point. Tooth no. 47 in Figure 6.2 provided a fine example of the difference that a radiographic marker

indicating the exact incisal edge and labial surface at the mesio-distal midpoint implies. The difference in a measurement taken from the anterior edge or from the radiographic marker is  $\pm 1.5\text{mm}$ .

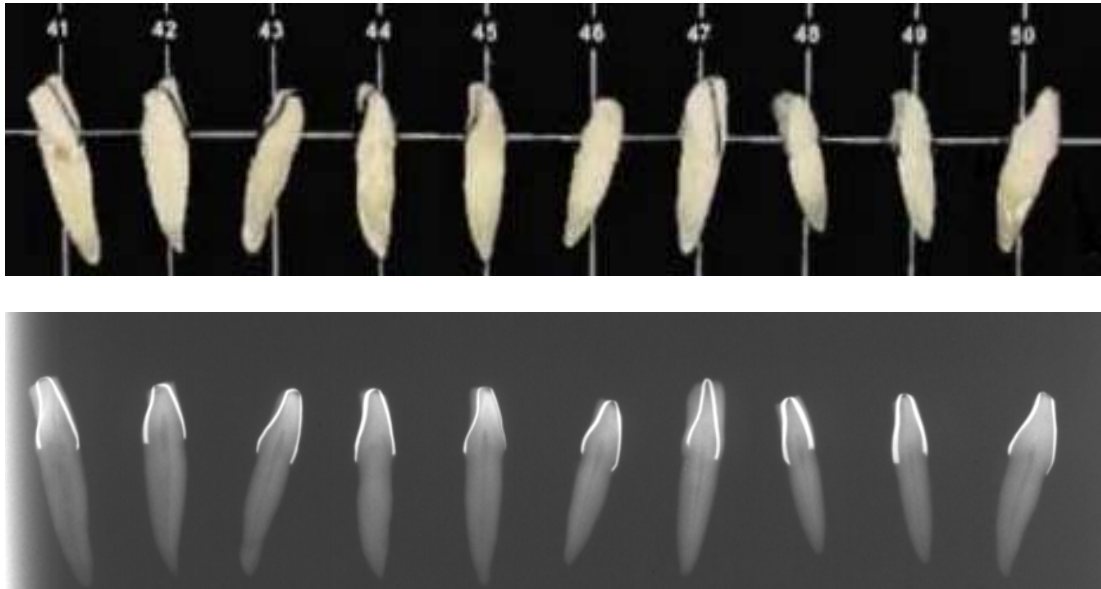


Figure 6.2: The radiographic images provided by the **radiographic markers on rotated teeth numbers 41-50**.

Although a radiographic marker placed as illustrated in Figure 6.3 may provide a tooth that is smaller in the labio-lingual dimension when the tooth is rotated as in B, the dimensions at the root-crown junction are still the same in relation to the middle of the incisal edge.

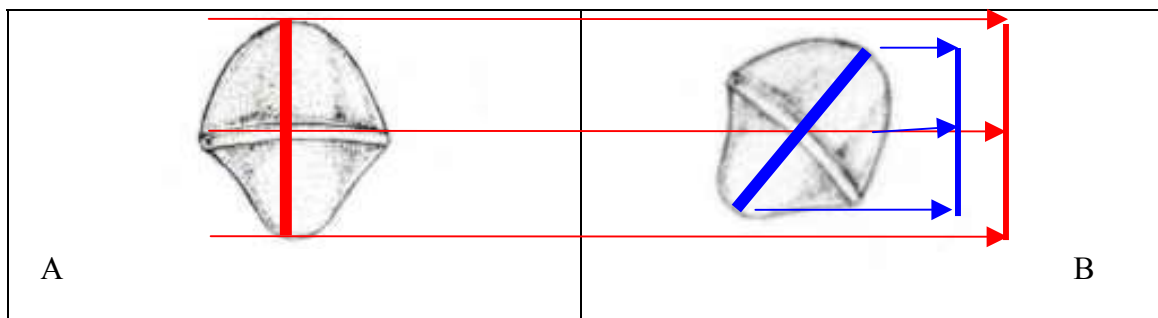


Figure 6.3: The effect of rotation on the radiographic image of an incisor with a radiographic marker. A – tooth perpendicular to x-ray beam; B - tooth rotated.

## **Conclusion**

Regarding sub aim 3 of this study "to evaluate the potential of radio-opaque dental markers to exactly define the incisor crown anatomy in the sagittal dimension" it can be confidently stated that it **provided a clear indication of the anatomical crown of the tooth in the sagittal dimension.**

## **6.5 DETERMINING LOWER INCISOR INCLINATION UTILISING RADIOGRAPHIC MARKERS (Main aim)**


The defined main aim of this *ex vivo* study was to determine whether a line through the tip of the tooth and bisecting the crown in the sagittal dimension at the crown-root junction is a valid method to establish the relevant tooth inclination.

### **6.5.1 Presentation of the data**


The inclination of the lower incisors as determined by the different observers tracing to specified reference points on the crown (defined by the radiographic markers) on the two different occasions are presented on the following pages.

#### **6.5.1.1 Graphical presentation of data**


Composite tracings of the observers' different tracings are presented in relation to the true inclination in Figures 6.4 – 6.6 that enable visual comparison of the results. All the tracings of the observers and the true inclination were included into the graphical composition in Figure 6.7 to visualise the final results.



*Figure 6.4: A composite tracing of observer I's first and second tracings compared to the true inclination. (Black – true inclination; dark blue- first tracing; light blue – second tracing.)*



*Figure 6.5: A composite tracing of observer 2's first and second tracings compared to the true inclination. (Black – true inclination; red – first tracing; light green – second tracing.)*



*Figure 6.6: A composite tracing of observer 3's first and second tracings compared to the true inclination. (Black – true inclination; dark green – first tracing; orange – second tracing.)*

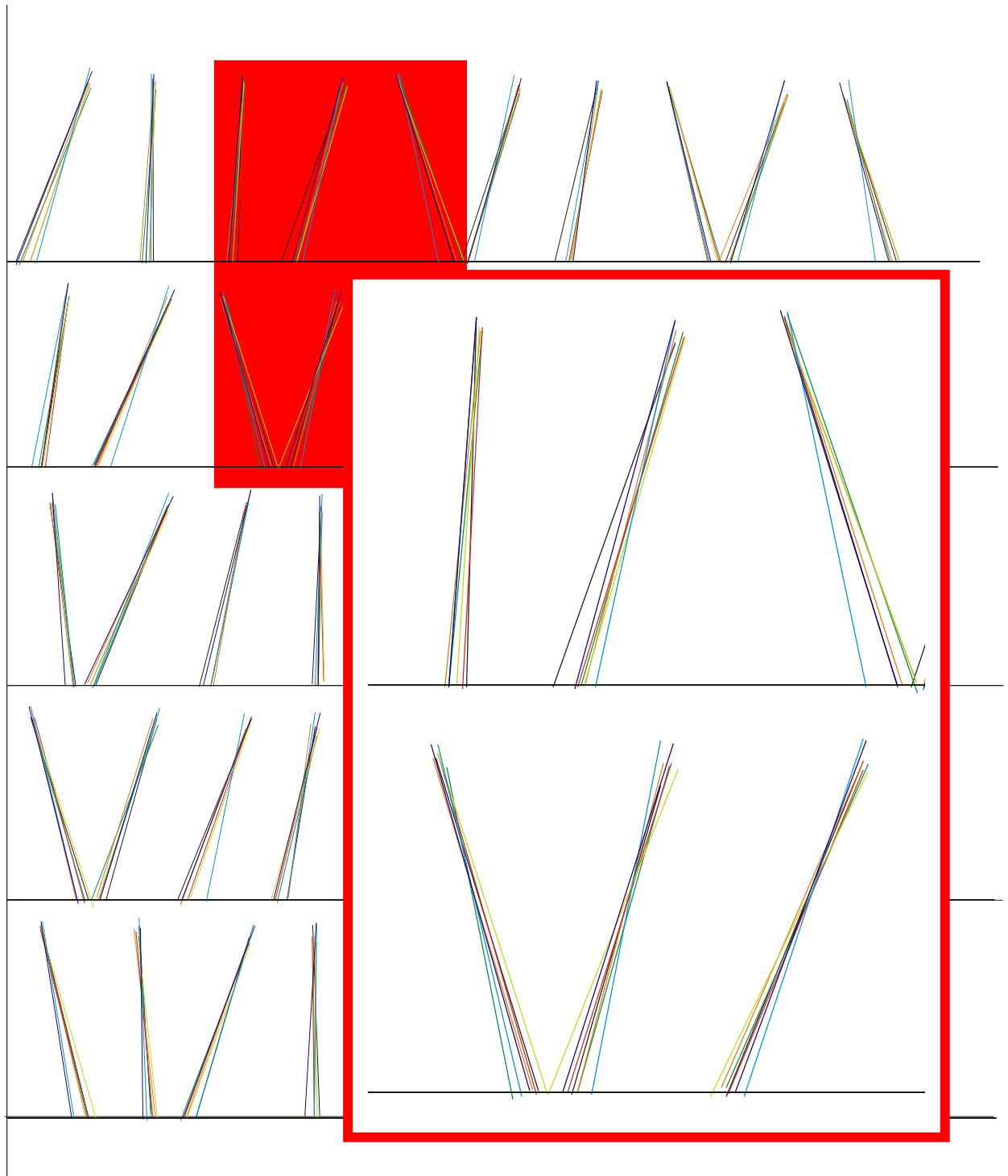


Figure 6.7: *Compilation of all tracings with the inclinations of teeth 3 – 5 and 13 – 15 enlarged. (Black- true inclination; Light and dark blue- observer 1; red and light green – observer 2; orange and dark green- observer 3.)*

### 6.5.1.2 Data in calculated format

The inclination of the lower incisors as determined by the different observers on the two different occasions were measured in comparison with a reference line to enable scientific interpretation as explained in Chapter V. Results are presented in the Tables 6.2 – 6.4.

Descriptive statistical analysis of the results was initially utilised to scientifically interpret the data followed by statistical analysis specifically applicable to medical method comparison studies.

The differences between each observer's first assessment to the true inclination (as determined on radiograph A by consensus), the second assessment to the true inclination, the mean of each different observer's two assessments and the difference between each observer's mean to the true inclination were calculated and are presented in Tables 6.2 – 6.4. The difference was calculated by subtracting the true inclination from the observer's assessment of inclination:

- $90^\circ$  (observer's inclination) –  $85^\circ$  (true inclination) =  $5^\circ$ .

The observer therefore could be said to over-estimate in the above instance. A negative score would be an indication of under-estimation of inclination.

#### Keys to tables 6.2-6.4:

- *Red – the maximum over-estimate for each observer.*
- *Green - the maximum under-estimate for each observer.*
- *Blue - All differences more than 4 degrees (plus or minus) are highlighted in blue.*



Tooth Number	Tracing 1B1	Difference to true	Tracing 1B2	Difference to true	Mean of 2 tracings	Difference Mean to true	TRUE inclination
1	74.7	6.4	68.5	0.2	71.6	3.3	68.3
2	89.4	-0.8	86.8	-3.4	88.1	-2.1	90.2
3	85.9	-2.3	85.8	-2.4	85.9	-2.4	88.2
4	77.8	7.3	74.3	3.8	76.1	5.6	70.5
5	102.0	-4.3	107.0	0.7	104.5	-1.8	106.3
6	78.0	6.2	73.6	1.8	75.8	4.0	71.8
7	79.8	3.6	82.4	6.2	81.1	4.9	76.2
8	103.4	0.7	103.4	0.7	103.4	0.7	102.7
9	75.8	6.6	73.2	4.0	74.5	5.3	69.2
10	97.9	-9.8	106.0	-1.7	102.0	-5.8	107.7
11	78.9	-2.0	81.7	0.8	80.3	-0.6	80.9
12	72.1	6.5	65.3	-0.3	68.7	3.1	65.6
13	103.3	-4.0	105.3	-2.0	104.3	-3.0	107.3
14	79.1	5.3	72.3	-1.5	75.7	1.9	73.8
15	71.6	3.8	69.3	1.5	70.5	2.6	67.8
16	86.4	4.3	85.2	3.1	85.8	3.7	82.1
17	97.4	-3.9	96.0	-5.3	96.7	-4.6	101.3
18	75.8	4.9	73.7	2.8	74.8	3.8	70.9
19	96.6	-3.3	96.6	-3.3	96.6	-3.3	99.9
20	71.5	2.9	66.0	-2.6	68.8	0.2	68.6
21	96.4	-1.6	93.8	-4.2	95.1	-2.9	98.0
22	68.5	1.8	64.9	-1.8	66.7	0.0	66.7
23	78.5	2.9	76.3	0.7	77.4	1.8	75.6
24	87.8	0.3	89.0	1.5	88.4	0.9	87.5
25	99.9	-0.3	101.2	1.0	100.6	0.4	100.2
26	83.5	-0.9	86.1	1.7	84.8	0.4	84.4
27	97.6	-4.5	99.8	-2.3	98.7	-3.4	102.1
28	108.1	-0.7	109.2	0.4	108.7	-0.1	108.8
29	84.9	-0.6	86.8	1.3	85.9	0.3	85.5
30	77.3	4.3	71.9	-1.1	74.6	1.6	73.0
31	103.3	-4.2	103.7	-3.8	103.5	-4.0	107.5
32	72.6	-1.5	72.8	-1.3	72.7	-1.4	74.1
33	78.2	10.1	69.5	1.4	73.9	5.8	68.1
34	80.5	0.0	75.9	-4.6	78.2	-2.3	80.5
35	79.8	6.2	73.7	0.1	76.8	3.2	73.6
36	86.9	-0.8	87.1	-0.6	87.0	-0.7	87.7
37	83.8	-1.8	84.4	-1.2	84.1	-1.5	85.6
38	109.2	-0.8	110.3	0.3	109.8	-0.3	110.0
39	87.7	1.4	82.4	-3.9	85.1	-1.2	86.3
40	74.6	-4.9	73.3	-6.2	74.0	-5.6	79.5
41	98.9	-4.5	98.5	-4.9	98.7	-4.7	103.4
42	92.2	-1.4	90.8	-2.8	91.5	-2.1	93.6
43	73.3	0.0	69.5	-3.8	71.4	-1.9	73.3
44	89.1	-2.8	86.6	-5.3	87.9	-4.1	91.9
45	90.9	0.8	86.7	-3.4	88.8	-1.3	90.1
46	76.5	3.7	70.1	-2.7	73.3	0.5	72.8
47	82.8	0.5	82.4	0.1	82.6	0.3	82.3
48	103.4	-0.1	97.6	-5.9	100.5	-3.0	103.5
49	95.0	-3.1	93.1	-5.0	94.1	-4.1	98.1
50	73.3	-0.8	73.6	-0.5	73.5	-0.7	74.1
Mean of 50	86.2	0.5	84.7	-1.1	85.5	-0.3	85.7

Table 6.2: The inclinations of the teeth as determined by observer number 1 on radiograph B compared to the true inclination as determined on radiograph A.

Tooth Number	Tracing 2B1	Difference to true	Tracing 2B2	Difference to true	Mean of 2 tracings	Difference Mean to true	TRUE inclination
1	71.3	3.0	71.5	3.2	71.4	3.1	68.3
2	88.0	-2.2	88.4	-1.8	88.2	-2.0	90.2
3	85.9	-2.3	86.4	-1.8	86.2	-2.1	88.2
4	72.9	2.4	73.0	2.5	73.0	2.5	70.5
5	110.0	3.7	110.0	3.7	110.0	3.7	106.3
6	72.7	0.9	73.0	1.2	72.9	1.1	71.8
7	78.4	2.2	79.9	3.7	79.2	3.0	76.2
8	106.2	3.5	105.4	2.7	105.8	3.1	102.7
9	70.2	1.0	71.1	1.9	70.7	1.5	69.2
10	108.4	0.7	108.8	1.1	108.6	0.9	107.7
11	82.4	1.5	81.5	0.6	82.0	1.1	80.9
12	65.9	0.3	66.3	0.7	66.1	0.5	65.6
13	106.0	-1.3	107.7	0.4	106.9	-0.5	107.3
14	72.7	-1.1	68.0	-5.8	70.4	-3.5	73.8
15	67.4	-0.4	64.1	-3.7	65.8	-2.1	67.8
16	82.0	-0.1	81.6	-0.5	81.8	-0.3	82.1
17	94.9	-6.4	94.0	-7.3	94.5	-6.8	101.3
18	74.2	3.3	74.1	3.2	74.2	3.3	70.9
19	99.6	-0.3	101.4	1.5	100.5	0.6	99.9
20	65.4	-3.2	67.6	-1.0	66.5	-2.1	68.6
21	95.7	-2.3	96.6	-1.4	96.2	-1.8	98.0
22	66.2	-0.5	65.7	-1.0	66.0	-0.8	66.7
23	78.7	3.1	78.1	2.5	78.4	2.8	75.6
24	91.9	4.4	91.2	3.7	91.6	4.1	87.5
25	98.5	-1.7	98.7	-1.5	98.6	-1.6	100.2
26	85.0	0.6	84.8	0.4	84.9	0.5	84.4
27	99.4	-2.7	99.5	-2.6	99.5	-2.6	102.1
28	111.9	3.1	110.4	1.6	111.2	2.4	108.8
29	88.3	2.8	84.3	-1.2	86.3	0.8	85.5
30	77.5	4.5	76.8	3.8	77.2	4.2	73.0
31	104.8	-2.7	107.7	0.2	106.3	-1.3	107.5
32	71.9	-2.2	71.8	-2.3	71.9	-2.3	74.1
33	70.9	2.8	71.0	2.9	71.0	2.9	68.1
34	76.0	-4.5	74.5	-6.0	75.3	-5.3	80.5
35	74.1	0.5	74.8	1.2	74.5	0.8	73.6
36	88.9	1.2	86.5	-1.2	87.7	0.0	87.7
37	85.3	-0.3	87.0	1.4	86.2	0.6	85.6
38	111.2	1.2	111.1	1.1	111.2	1.2	110.0
39	83.6	-2.7	85.1	-1.2	84.4	-2.0	86.3
40	77.0	-2.5	76.5	-3.0	76.8	-2.8	79.5
41	104.3	0.9	106.0	2.6	105.2	1.8	103.4
42	95.2	1.6	96.1	2.5	95.7	2.1	93.6
43	69.9	-3.4	70.0	-3.3	70.0	-3.3	73.3
44	90.5	-1.4	90.7	-1.2	90.6	-1.3	91.9
45	89.6	-0.5	90.5	0.4	90.1	0.0	90.1
46	72.0	-0.8	73.6	0.8	72.8	0.0	72.8
47	82.9	0.6	83.0	0.7	83.0	0.7	82.3
48	99.5	-4.0	103.2	-0.3	101.4	-2.2	103.5
49	96.3	-1.8	95.7	-2.4	96.0	-2.1	98.1
50	74.4	0.3	71.1	-3.0	72.8	-1.3	74.1
Mean of 50	85.7	0.0	85.7	0.0	85.7	0.0	85.7

Table 6.3: The inclinations of the teeth as determined by observer number 2 on radiograph B compared to the true inclination as determined on radiograph A.

Tooth Number	Tracing 3B1	Difference to true	Tracing3B2	Difference to true	Mean of 2 tracings	Difference Mean to true	TRUE inclination
1	67.9	-0.4	69.6	1.3	68.8	0.5	68.3
2	85.7	-4.5	85.5	-4.7	85.6	-4.6	90.2
3	84.7	-3.5	84.1	-4.1	84.4	-3.8	88.2
4	73.8	3.3	75.2	4.7	74.5	4.0	70.5
5	108.9	2.6	107.4	1.1	108.2	1.9	106.3
6	72.3	0.5	74.2	2.4	73.3	1.5	71.8
7	79.8	3.6	81.2	5.0	80.5	4.3	76.2
8	106.5	3.8	103.1	0.4	104.8	2.1	102.7
9	71.0	1.8	67.4	-1.8	69.2	0.0	69.2
10	105.3	-2.4	106.7	-1.0	106.0	-1.7	107.7
11	79.9	-1.0	82.5	1.6	81.2	0.3	80.9
12	64.5	-1.1	67.2	1.6	65.9	0.3	65.6
13	101.3	-6.0	107.0	-0.3	104.2	-3.1	107.3
14	74.4	0.6	75.6	1.8	75.0	1.2	73.8
15	66.4	-1.4	68.1	0.3	67.3	-0.5	67.8
16	84.0	1.9	84.1	2.0	84.1	2.0	82.1
17	95.5	-5.8	93.7	-7.6	94.6	-6.7	101.3
18	74.1	3.2	73.1	2.2	73.6	2.7	70.9
19	98.1	-1.8	95.8	-4.1	97.0	-3.0	99.9
20	65.5	-3.1	67.4	-1.2	66.5	-2.1	68.6
21	95.9	-2.1	97.1	-0.9	96.5	-1.5	98.0
22	67.8	1.1	65.7	-1.0	66.8	0.0	66.7
23	78.5	2.9	78.9	3.3	78.7	3.1	75.6
24	88.7	1.2	88.2	0.7	88.5	1.0	87.5
25	100.4	0.2	98.4	-1.8	99.4	-0.8	100.2
26	86.2	1.8	84.9	0.5	85.6	1.2	84.4
27	97.9	-4.2	97.3	-4.8	97.6	-4.5	102.1
28	107.7	-1.1	110.7	1.9	109.2	0.4	108.8
29	86.3	0.8	86.0	0.5	86.2	0.7	85.5
30	77.5	4.5	77.4	4.4	77.5	4.5	73.0
31	104.8	-2.7	102.9	-4.6	103.9	-3.7	107.5
32	71.9	-2.2	72.7	-1.4	72.3	-1.8	74.1
33	70.9	2.8	69.4	1.3	70.2	2.1	68.1
34	76.0	-4.5	83.6	3.1	79.8	-0.7	80.5
35	74.1	0.5	78.6	5.0	76.4	2.8	73.6
36	88.9	1.2	86.2	-1.5	87.6	-0.1	87.7
37	85.3	-0.3	84.2	-1.4	84.8	-0.8	85.6
38	111.2	1.2	110.7	0.7	111.0	1.0	110.0
39	83.6	-2.7	84.5	-1.8	84.1	-2.3	86.3
40	77.0	-2.5	75.2	-4.3	76.1	-3.4	79.5
41	104.2	0.8	103.4	0.0	103.8	0.4	103.4
42	94.0	0.4	96.0	2.4	95.0	1.4	93.6
43	68.9	-4.4	71.1	-2.2	70.0	-3.3	73.3
44	89.5	-2.4	89.6	-2.3	89.6	-2.4	91.9
45	88.1	-2.0	88.5	-1.6	88.3	-1.8	90.1
46	69.6	-3.2	78.6	5.8	74.1	1.3	72.8
47	82.9	0.6	85.7	3.4	84.3	2.0	82.3
48	103.4	-0.1	104.7	1.2	104.1	0.6	103.5
49	96.0	-2.1	95.6	-2.5	95.8	-2.3	98.1
50	72.2	-1.9	73.2	-0.9	72.7	-1.4	74.1
Mean of 50	85.1	-0.6	85.7	0.0	85.4	-0.3	85.7

Table 6.4: The inclinations of the teeth as determined by observer number 3 on radiograph B compared to the true inclination as determined on radiograph A.

## 6.5.2 Comparison of observers' tracings to the true inclination

### Statistical analysis

The means, standard deviations and ranges were calculated for the different variables and presented in Table 6.5. The number of teeth estimated more than 4° off the true inclination (already indicated in Tables 6.2 – 6.4) for the different observers are presented in Table 6.6. The mean errors of the observers' estimates were also plotted against the true inclination to verify possible trends in Figure 6.8.

### Results and discussion

The results and discussion of the relevant topics are presented consecutively and the findings collectively summarised in the conclusion.

#### 6.5.2.1 Standard deviation and mean

Observer	Tracing	Mean	Std Dev	Min	Max
1	1	0.5	4.0	-9.8	10.1
1	2	-1.1	2.8	-0.6	6.2
1	Mean of 1 & 2	-0.3	3.0	-5.7	5.8
2	1	-0.0	2.5	-6.4	4.5
2	2	-0.0	2.6	-7.3	3.8
2	Mean of 1 & 2	0.0	2.4	-6.8	4.2
3	1	-0.6	2.6	-6.0	4.5
3	2	0.0	2.9	-7.6	5.8
3	Mean of 1 & 2	-0.3	2.5	-6.7	4.5

Table 6.5: The mean inclination error on all 50 teeth on the first, second and the mean of the two tracings as well as the standard deviations and the error range of the different observers.

Interpretation of the mean scores can be summarised as follows:

- Observer 1: Is very inconsistent and initially under and then over scored in the different tracings.
- Observer 2: Is very consistent.
- Observer 3: Is fairly inconsistent, but improved with the second tracing.

The differences between observers are clear with observers 2 and 3 standard deviations smaller (2.43; 2.47) than the standard deviation of observer 1 (3.02).

#### 6.5.2.2 Teeth estimated more than 4° off the true inclination

The number of teeth estimated more than 4° off the true inclination (already indicated in Tables 6.2 – 6.4) for the different observers are presented in Table 6.6.

Observer number	Number of teeth in tracing 1 with inclinations more than 4° incorrect.	Number of teeth in tracing 2 with inclinations more than 4° incorrect.	Mean of the two tracings
1. n = 50	17	10	10
2. n = 50	5	4	4
3. n = 50	7	12	6
Total n = 150	29	26	20

*Table 6.6: The number of teeth assessed by the different observers with inclinations of more than 4° off the true inclination. (n=150)*

Observers 2 and 3 were generally in consensus on determining the teeth inclinations with observer 2 determining only 5 teeth and observer 3 only 7 teeth more than 4°

(approximately 2 std dev.) from the true inclination with the first tracings. Of interest is that both observers shared 3 of these teeth: numbers 17, 30 and 34. In the second set of tracings observer 2 indicated only 4 teeth more than  $4^\circ$  off the true inclination and once again it was teeth numbers 17, 30 and 34. Observer 3 indicated 12 teeth more than  $4^\circ$  off the true inclination, including teeth numbers 17 and 30 with the second tracing. This possibly indicates that either abnormal crown anatomy or the true inclination as determined by the observers and the researcher on radiograph A was inaccurate. True inclination was confirmed as previously indicated, but the consistency of observer number two in all tracings and these of the other observers in the general incorrect assessing of inclination of specific teeth (17, 30 and 34) is indicative that certain teeth may tend to angulations between crown and root axis in the sagittal dimension. (The inclinations of rotated teeth (teeth no. 41 – 50) were assessed as well as the other teeth. Rotated teeth are clinically more difficult to assess and the use of radiographic markers may be advantageous on such teeth.)

The number of teeth assessed more than  $4^\circ$  declined from 29 in the first tracing to 26 in the second tracing and to 20 when the mean of the observers' 2 tracings to the true inclination was compared. This may be interpreted to verify the use of taking the mean of two tracings as a more accurate indicator of true inclination. The results can be interpreted either way: all observers had a tracing either first or second with the total number of teeth very close to mean. If this is interpreted in conjunction with the difference of the mean of the tracings to the true inclination it follows that if the observer is accurate there is not much to gain from a second or the mean of two tracings. In practice it may be difficult to determine accuracy and be better to use the mean of tracings.

### 6.5.2.3 Verifying trends at different true inclinations

The mean errors of the observers' estimates were also plotted against the true inclination to verify possible trends in Figure 6.8. The observers' estimates were plotted against the true inclinations at the different possibilities from 60 degrees to 110 degrees to verify if certain patterns of over- or under estimation were realised at certain true inclinations.

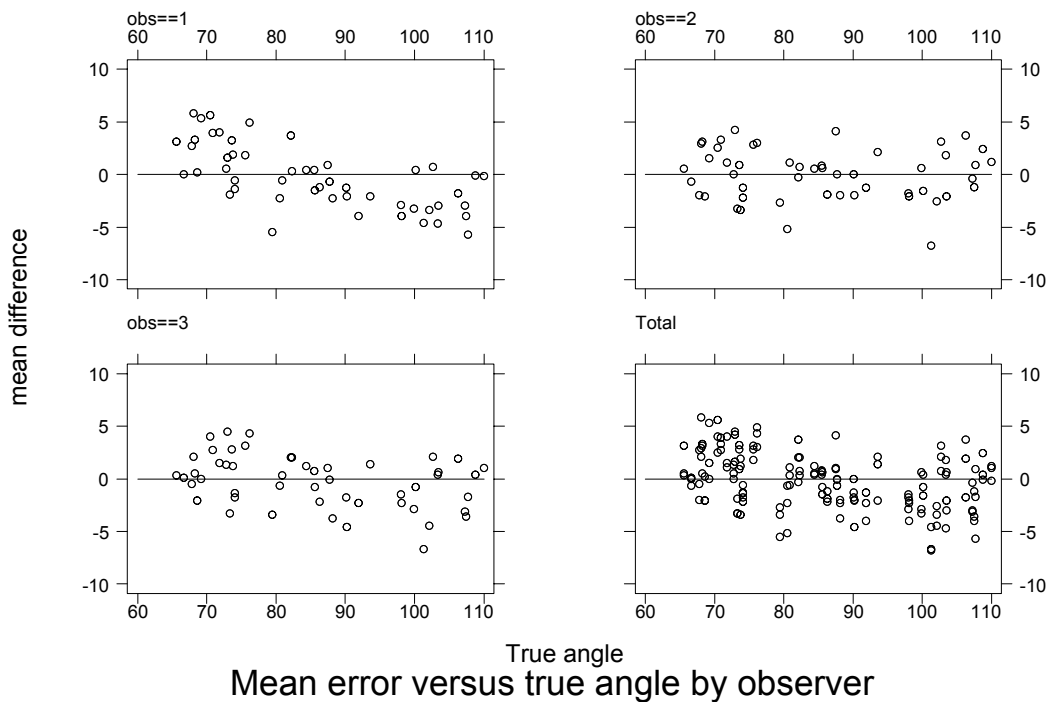


Figure 6.8: Mean error versus true angle by different observers.

Observer 2 and 3 were generally constant (under and over scoring throughout with no specific tendency), but observer 1 tends to underscore at low angle teeth and over scores from 85 degrees onwards. Observer 1 therefore had the tendency to err in the direction of the existing inclination of the teeth – a pattern that is clearly indicated with the graphical presentation in figure 6.8.

## Conclusion

The differences between observers are clear with observers 2 and 3 standard deviations of the mean of the two tracings smaller (2.43; 2.47) than the standard deviation of observer 1 (3.02).

- Observer 1: (Standard deviation tracing 1: 4.00; Standard deviation tracing 2: 2.83)  
Is very inconsistent and initially under and then over scored in the different tracings (tendency to err in the direction of the existing inclination of the teeth).
- Observer 2: (Standard deviation tracing 1: 2.49; Standard deviation tracing 2: 2.62)  
Is very consistent (no specific tendency).
- Observer 3: (Standard deviation tracing 1: 2.62; Standard deviation tracing 2: 2.90)  
Is fairly inconsistent, but improved with the second tracing (no specific tendency).

## 6.5.3 Method comparison to other studies

### 6.5.3.1 Statistical analysis

The method suggested by Altman specifically applicable to medical method comparison studies was applied to the results <sup>(45)</sup>. This approach regarding the “limits of agreement” implies that given a measurement, what are the limits on the error compared to the true agreement rather than hypothesis testing. If it is assumed that a single “random” operator makes the observation two sources of error/variations are possible:

- Between operator variation
- Within operator variation

This implies that  $y_{ij} = \mu(\text{mean value}) + o_i(\text{operator effect}) + e_{ij}(\text{within operator variability})$  where  $y_{ij}$  denotes the  $j^{\text{th}}$  measurement by operator  $i$ .



This will imply according to the “random effects of variance model” that:

$$\text{var}(y_{ij}) = \sigma_u^2 + \sigma_e^2$$

= between operator variance + within operator variance.

### 6.5.3.2 Results

The variance components  $\sigma_u^2$  and  $\sigma_e^2$  were estimated by fitting a one way random effects analysis of variance model in the statistical package Stata version 6 (Stata Corporation, Release 6.0; 1999). Unfortunately the between observer mean square was less than the within observer mean square and the between observer component of variance therefore estimated as zero.

The within observer component of variance was  $\sigma_e^2 = 10.856$  and  $SD = 3.29$ . The mean error from 50 teeth read by 3 operators on the 6 tracings was  $-0.17$  and the 95% limits of agreement therefore  $-0.17 \pm 2 SD$  or  $(-6.75; 6.41)$  for individual assessments.

For the mean difference (to the true inclination) of the two tracings the between observer component of variance was again estimated as zero. The within observer component of variance was  $\sigma_e^2 = 9.118$  and the  $SD = 3.02$ . The 95% limits of agreement therefore became  $-0.17 \pm 2 SD$  or  $(-6.21; 5.87)$ .

### 6.5.3.3 Discussion

#### *Method comparison analysis*

Altman states that for reasonably symmetric distributions we expect the range mean  $\pm 2$  standard deviations to include about 95% of observations <sup>(45)</sup>. The error if an individual reads an angle with the discussed method could range from  $-6.75^\circ$  to  $6.41^\circ$  i.e. under estimate the angle by as much as  $-6.75^\circ$  or over estimate by up to  $6.41^\circ$ . The 95% limits became  $-6.21^\circ$  to  $5.87^\circ$  when the mean of assessments was taken into consideration, slightly better than for a single reading.

**Comparison of results to the findings of other relevant other studies**

It was important to compare the findings of this investigation with the findings of other relevant studies to clarify validity of the method as suggested (Table 6.7).

Study	Type of Study	Materials & Methods	Reference plane	Errors between -3° to +3°	Standard deviation	
					Inter-observer	Intra-observer
Broadway <i>et al.</i> (1962) <sup>44</sup>	Accuracy of cephalometric radiographs tracing technique.	40 Patient radiographs. 2 observers. 1 observer traced twice.	Mandibular plane	*	4.33°	3.14°
Baumrind and Frantz (1971) <sup>33</sup>	Reliability of head film measurements.	20 Patient radiographs. 5 observers. Traced once.	Mandibular plane	68%	3.15°	*
Tng <i>et al.</i> (1994) <sup>23</sup>	Validity of cephalometric landmarks.	Control: 30 Skull radiographs with markers. Experiment: 30 Skull radiographs without markers repeated. 1 observer traced each once.	Mandibular plane	*	*	4.00°
Present study (2002)	Validity and reliability determining lower incisor inclination from the incisor crown only.	Control: 1 Radiograph with 50 mounted incisor teeth with roots visible. Experiment: 1 Radiograph with 50 mounted incisor teeth with roots invisible. 3 observers traced each twice.	Constructed axes	63.7%	3.29°	3.29°
		Same as above. Mean of each observers' two tracings analysed.	Constructed axes	67.9%	3.02°	3.02°

Table 6.7: Comparison of relevant studies. \* Data not available.

It can be concluded from Table 6.7 that the inclination of the lower incisor tooth can be determined from the crown only with as much confidence as with other existing methods.

Altman, however, emphasises that most clinical measurements are not precise, either because measurements of the “quantity of interest cannot be made directly or the measurement in itself being difficult to make”<sup>(45)</sup>. These uncertainties make comparison of different methods of clinical measurement difficult, as the degree of agreement to estimation is in question rather than hypothesis being tested. Furthermore, direct comparison of the results of this investigation with other studies should be interpreted with

care due to the fact that this study was done on extracted teeth simulating certain angles on a Perspex sheet:

- without other structures interfering on the radiographic image of the crowns of the teeth.
- with only the one axis forming the angle when determining incisor inclination as a variable.

However, the radiographic markers should give the same clear image *in vitro* and the roots were totally obstructed (even more than *in vivo* lateral cephalometric radiographs). Chan et al. furthermore explain in their investigation on the influence of different variables on inclination as determined in cephalometrics that the incisor axis ( $\pm 4^\circ$ ) are much more prone to inaccuracy than the mandibular plane ( $\pm 1.1^\circ$ )<sup>(34)</sup>. This investigation and the study of Tng et al.<sup>(23)</sup> however, were the only ones where the true inclinations were known.

Interpretation of the results of this experimental study to other studies should take all these variables in consideration.

#### **6.5.3.4 Conclusion**

Regarding the main aim of this *ex vivo* study that was to “determine whether a line through the tip of the tooth and bisecting the crown in the sagittal dimension at the crown-root junction is a valid method to establish the relevant tooth inclination”. It can be concluded that the inclination of the tooth can be determined with the discussed method with as much confidence as other existing methods.

## 6.6 SUMMARY

The main aim of this *ex vivo* study was to:

determine whether a line through the tip of the tooth and bisecting the properly defined crown in the sagittal dimension at the crown-root junction is a valid method to establish the relevant tooth inclination. **The method as described (utilising radiographic markers on incisor teeth to define the labio-lingual dimension on a lateral cephalometric radiograph and tracing from incisor edge to the middle of the labio-lingual dimension at the crown-root junction) indicated incisor inclination as accurately as other methods. This, however, was an ex vivo study only determining the reliability of one of the axes that influence the incisor inclination and direct comparison to other methods should be interpreted accordingly.**

Utilising a radiographic marker on an incisor seemed to provide a solution to the existing problem to reliably determine the outline and the inclination of the lower incisor. Examples of the clinical use of dental radiographic markers are provided in the next chapter in relation to sub aim 4.

\* Courtney, in a letter regarding evidence based orthodontics, quotes Vig: "Training programs which produce clinicians unable to access evidence according to current scientific standards perpetuate the problems by **validating yesterday's superstitions and today's follies as the 'art' of practice**; paving the way for tomorrow's fads; and **creating a generation of trained 'believers', instead of competent critics** immune to the claims of pseudo-progress."<sup>(47)</sup>

## CHAPTER VII

### CLINICAL EXAMPLES OF DENTAL RADIOGRAPHIC MARKERS

#### 7.1 GENERAL DISCUSSION

The *ex vivo* study proofed the possible advantages of dental radiographic markers. Clinical applications of the use of dental radiographic markers were tested on a few selected patients to investigate sub aim 4.

If the inclination of an incisor has to be determined, the radiographic marker can be placed with no adverse effect to other indicators of apex inferior as currently used. The assessment of incisor inclination should be more accurate as the advantages of the lead marker are used in conjunction with other indicators of inclination that can still be applied as usual.

In the first two examples radiographic markers were placed on the lower and upper incisors as well as on the right upper molar (Figure 7.1 - 7.6).

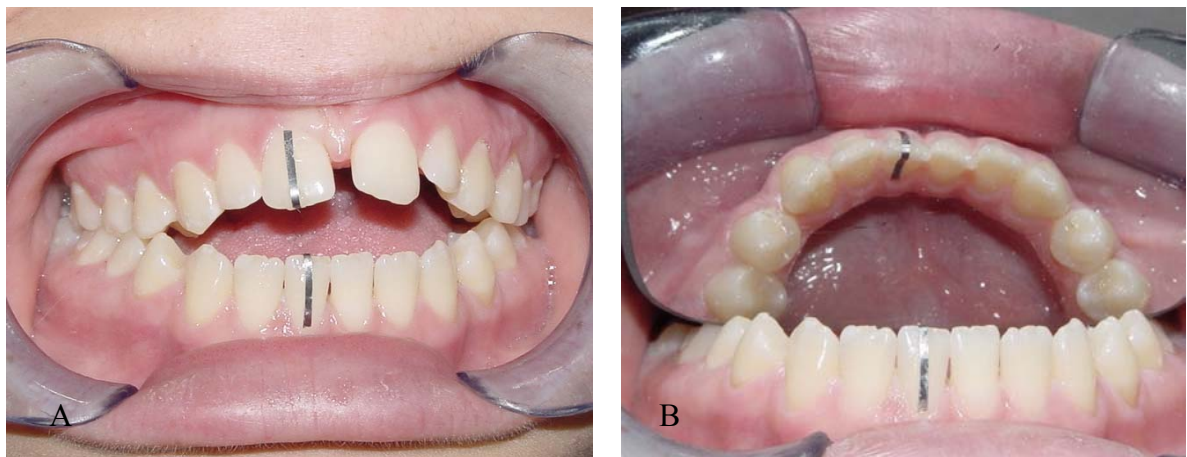
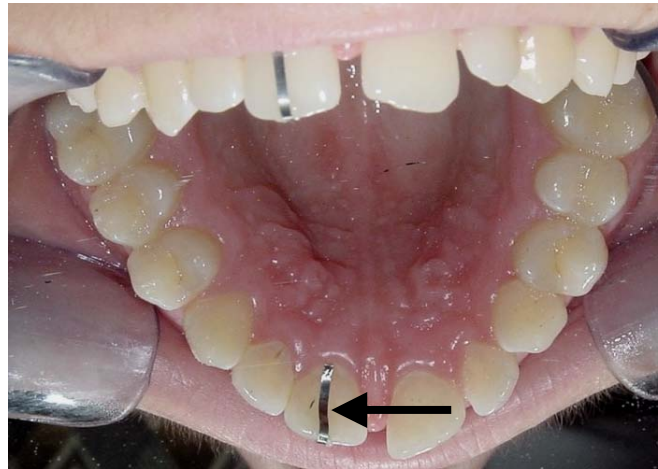


Figure 7.1: A. Labial view of teeth with the lead markers in place. B. Occlusal photo demonstrates the marker on the lower incisor.

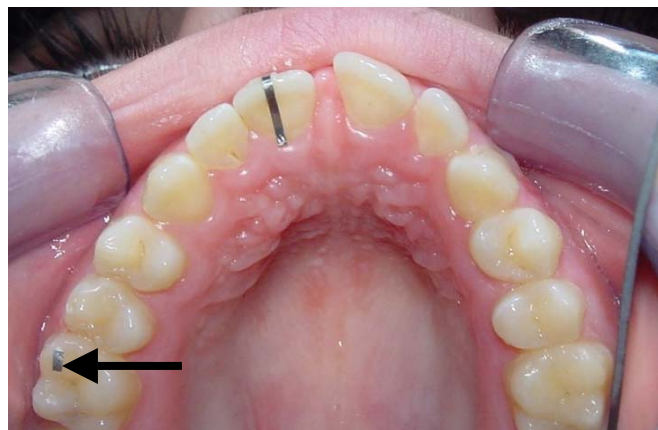The upper incisor marker was placed in exactly the same manner as on the lower incisor.

*Figure 7.2: Occlusal photo of the upper incisor demonstrating the lingual aspect of the lead marker as well.*



Molar markers can be placed to determine the exact vertical and sagittal location of a specific tooth. For this investigation a small piece of lead film was attached to the upper right molar mesio-buccal cusp (Figure 7.3).

*Figure 7.3: The lead marker attached to the upper first molar mesio-buccal cusp.*



The lateral cephalometric radiographs of the patient illustrated with the above photos are presented in Figures 7.4 and 7.5. The molar marker served as a basic indicator to distinguish the right from the left molars on the x-ray and provided a reproducible reference point (in the same way as a filling on a molar can be used as a reference point). Usually markers will be placed on the molars closest to the film. In this study the film was on the right of the face so the right side with the least enlargement and distortion was traced.

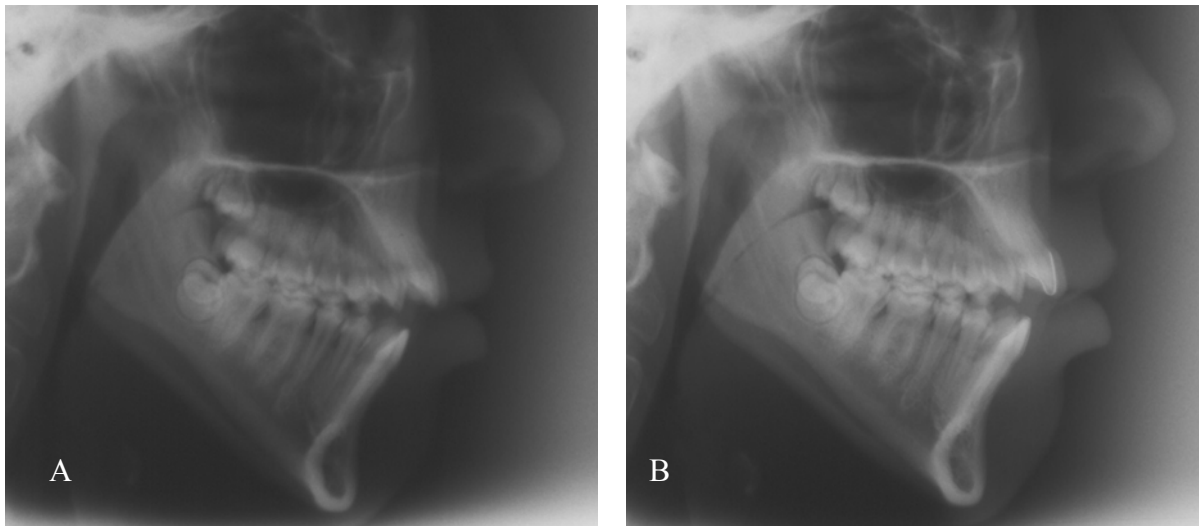


Figure 7.4: A. Lateral cephalometric radiograph without any lead markers. The double image in the ramus/corpus and posterior teeth was ascribed to improper positioning in the cephalostat and another radiograph requested. B. Lead markers were placed on the teeth before taking the second radiograph.

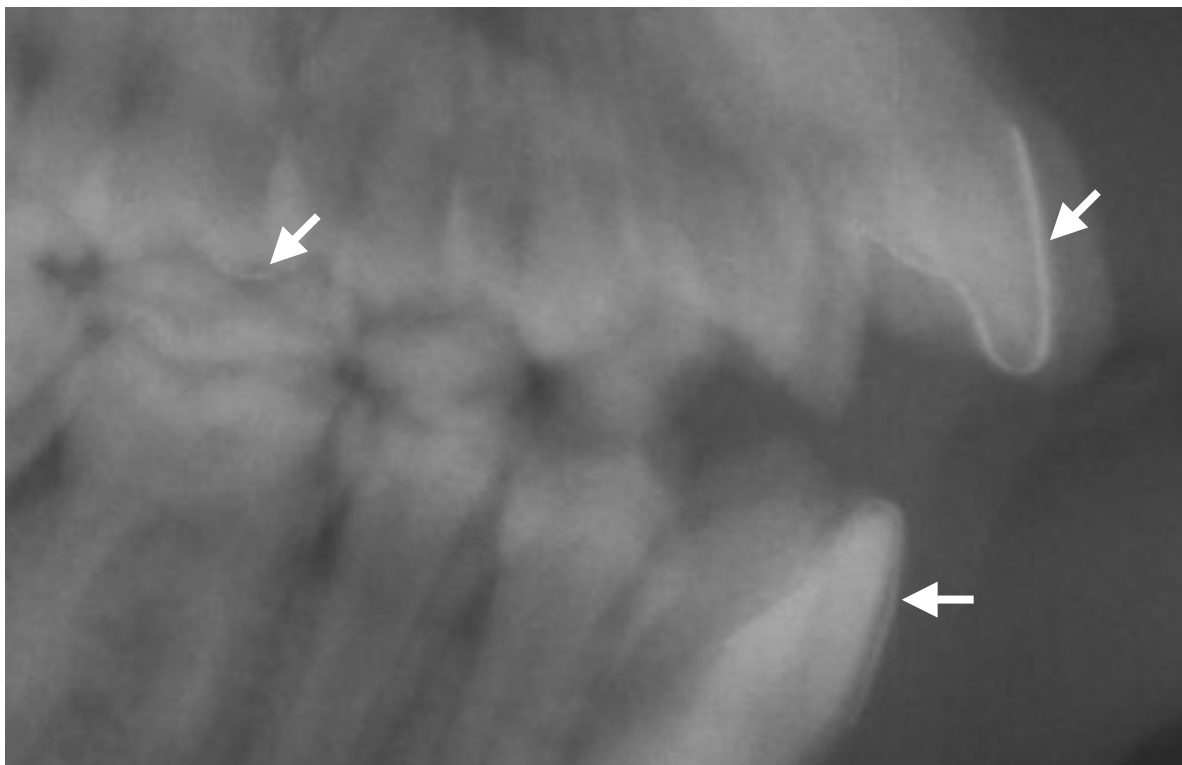
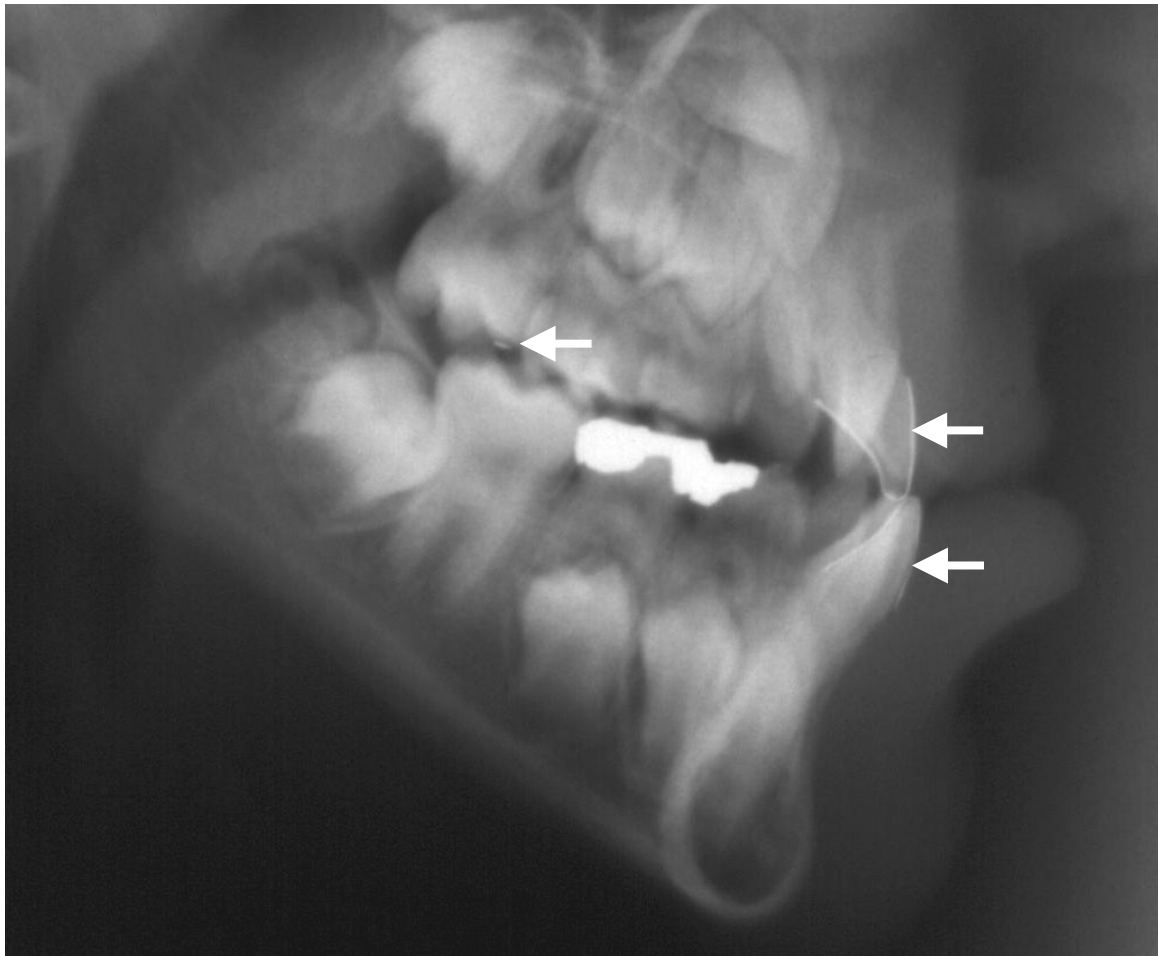


Figure 7.5: The relevant area of the lateral cephalometric radiograph in figure 8.4B enlarged to provide clear visualisation of the markers.

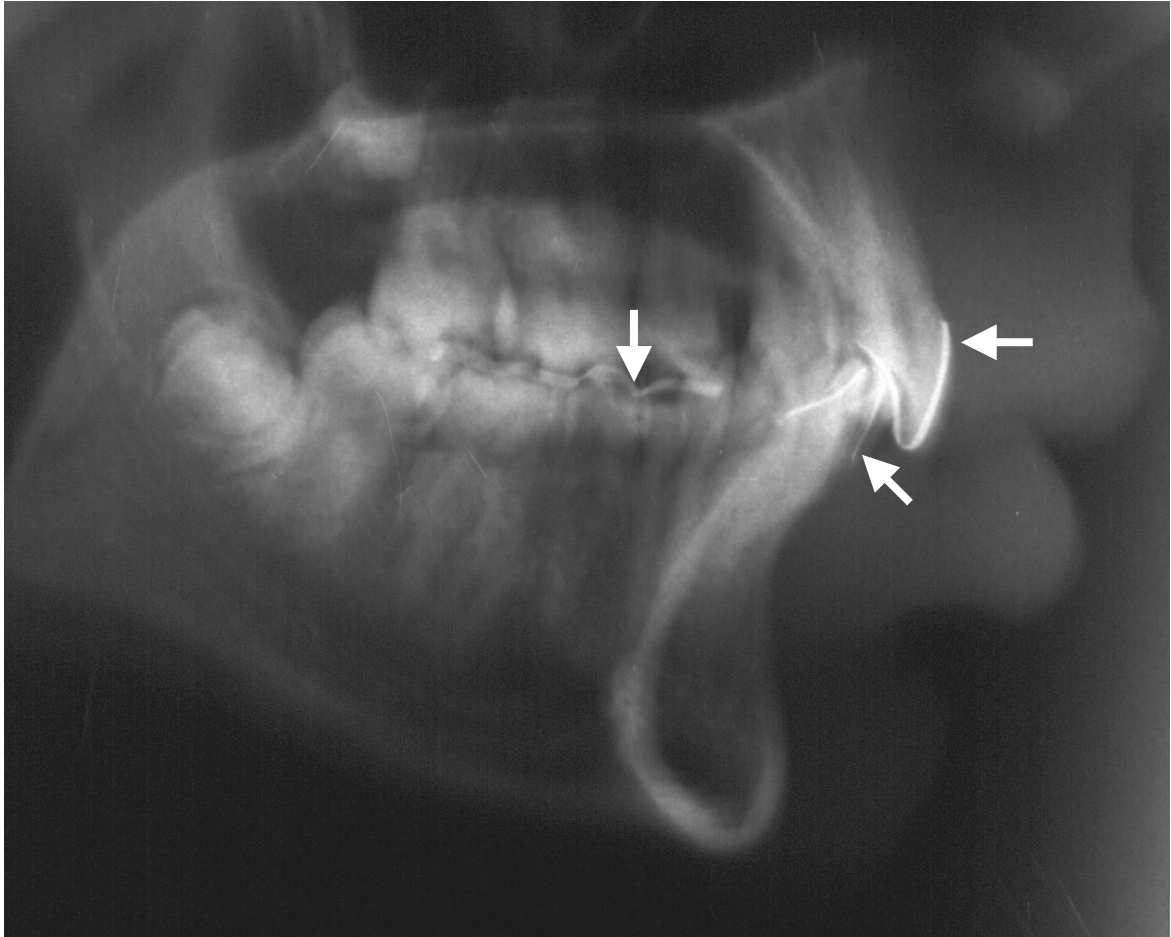
Radiographic markers were placed on the upper and lower incisors as well as the right upper molar in the next patient (Figure 7.6). The clear distinction and definition of the right upper and lower incisors would have been difficult without the markers. The patient is being treated among other things with distraction osteogenesis and the molar marker will be utilised to discriminate between dental and skeletal treatment effects.



*Figure 7.6: Lead markers utilised to define the upper and lower incisors as well as the upper molar mesio-buccal cusp.*



The functional occlusal plane is also difficult to assess on a lateral cephalometric radiograph. A radiographic marker was placed as illustrated in Figure 7.7 to indicate the occlusal plane from the right molar to the first premolar.



*Figure 7.7: A lead-film strip was placed on the incisors as well as on the occlusal surface from the first right lower molar to the first premolar to indicate the true functional occlusal plane.*

## **7.2 CONCLUSION**

The use of lead markers as illustrated enabled exact location of relevant teeth and outlined crown dimensions of the anterior teeth. Furthermore, the radiographic markers enabled constant and reproducible dental reference points to ensure that all measurements

clinically, on study models and on the lateral cephalometric radiograph were taken from exactly the same point.

The radiographs presented were taken some time apart as routine procedures to monitor treatment progress and cannot be interpreted to compare the accuracy of dental landmark reliability. These examples may, however, be of valuable assistance and factual evidence to obtain ethical permission to do an extended in vivo study on the use of dental radiographic markers.

## CHAPTER VIII

### CONCLUSIONS AND RECOMMENDATIONS

#### 8.1 INTRODUCTION

As this research project developed the magnitude of the problem of "evidence based orthodontics" became clear. Orthodontists experience not only the problem of clinical measurements being imprecise, but also radiographic measurements being unreliable. Furthermore, what changes can be attributed to treatment and what to growth? Baumrind and Frantz state "that our current measurement instrument, the angular head film measurement, is in most cases too inaccurate to differentiate all but the grossest changes" and conclude that "the severity of the problem has caused some critical observers to abandon all hope of discerning growth differences or small anatomic changes in individual subjects" <sup>(33)</sup>. The authors explain: "Clinical procedures always involve comparisons between values for one head film and some set of standards or *norms*. In either event, it is the difference between the two values for any given measurement, which is important. It seems obvious that in order for the observed difference to be considered real (that is, biologic) it must exceed by a consequential margin the measurement error for that measure (at least twice the standard deviation of the estimating error). Only then can one say with reasonable certainty that the observed difference is real and not simply the product of estimating errors" <sup>(33)</sup>.

In a recent article Kamoen et al. highlight the adverse effects of tracing accuracy in cephalometry and consider landmark accuracy as the most important source of error and stress that is important in research projects to "reduce the error of the method as much as

possible in relation to the rather small measured changes in an attempt to draw valid conclusions from these results”<sup>(48)</sup>. Change can only be attributed to treatment effects after natural growth and the error of method have been deducted from the difference between two comparative lateral cephalometric radiographs.

Baumrind and Frantz therefore recommend several steps that can be taken to reduce errors in measurement of head films:

- recognize that a problem exists.
- take care and concentration in order to obtain reliable tracings.
- obtain radiographs and interpret tracings under optimal standardized conditions<sup>(33)</sup>.

The current investigation pointed out the advantages of using radiographic markers to enhance cephalometric landmark identification. This should contribute to a smaller error of method and therefore more valid growth and treatment comparisons on lateral cephalometric radiographs.

## **8.2 VALUE OF THIS INVESTIGATION**

From this study and the examples provided in chapter VII the results of this experimental study using radio-opaque markers on the incisor teeth can be summarised as follows:

1. it will clearly indicate which tooth is being assessed.
2. it will provide a clear indication of the anatomical crown in the sagittal dimension even when the tooth is rotated.
3. it will improve accurate measurements from the crown providing a constant reference point for clinical, study model and cephalometric measurements all taken from exactly the same point.

4. the position of the lower incisor will be indicated more validly and reproducibly and thus contribute to improved diagnosis, treatment planning and exact research.
5. the inclination of the tooth can be determined with as much confidence as with other existing methods, even when the tooth is rotated.
6. it may contribute to improved computer assisted cephalometric analysis by clearly defining the specific object as progress towards digital imaging and film free hospitals are made<sup>(49)</sup>.

### **8.3 CRITICAL EVALUATION OF THE STUDY**

This was an *ex vivo* study to determine whether the crown of the lower incisor could be defined with the use of lead-film markers on lateral cephalometric radiographs and whether the tooth inclination could be reliably extrapolated from the tooth incisor edge and the labio-lingual dimensions at the crown-root junction. As this was an experimental study, it was decided to first investigate the theory on extracted teeth where the tooth apex would be clearly distinguishable on a radiograph. The results indicated that the crown of the lower incisor is clearly outlined and that the inclination as determined by using the above mentioned reference points is a valid method to determine incisor inclination.

The direct comparison of the results of this investigation with other studies should be interpreted with care due to the fact that this study was done on extracted teeth simulating certain angles on a Perspex sheet:

- without other structures interfering on the radiographic image of the crowns of the teeth.

- with only the one axis forming the angle when determining incisor inclination as a variable.

Furthermore pre-manufactured radiographic markers are not available and the lead film used as radiographic markers in this study weren't cut to the exact same width. A point to consider is that the method is time consuming that implies that it might be impractical for routine use on all patients in general practice.

#### **8.4 COMMERCIALY AVAILABLE RADIOGRAPHIC MARKERS**

Radiographic markers are not commercially available or standardised and were cut from lead- film of used radiographs for this study. Although satisfactory results were obtained, the ideal width, radio-opacity and the ultimate method of placing the radiographic markers are still to be investigated. The current method of placing the marker by means of routinely used band cement is time consuming and not the ideal. It is therefore not recommended for routine use, but will be of great value in scientific studies where measurements will be more exact and reference points consistent and reproducible. The method may also be of use in patients with rotated lower incisors as well as for patients where the incisors are obscured by other structures.

It may be possible to manufacture sheets with radiographic markers or use configurations of orthodontic wire or radio-opaque separating elastics (or metal de-impacting springs) on molars as dental radiographic markers. If dental radiographic markers could be manufactured which facilitate simple placement on the teeth, routine use on all patients could be encouraged. Suggestions in this regard will be forwarded with the results of the study to relevant manufacturers.

## 8.5 FURTHER INVESTIGATION RECOMMENDED

The *ex vivo* study proofed the possible advantages of dental radiographic markers. The clinical applications of the use of dental radiographic markers were tested on a few selected patients. Radiographic markers clearly indicated the relevant landmarks, but as the true inclination could not be confirmed without CAT-scans, no valid method comparison was possible.

Further *ex vivo* investigation is recommended. An excellent study could be to use the same skulls that have been used in previous studies and repeat lateral cephalometric radiographs with radiographic markers on central incisors and re-establish the inclinations of the upper and lower incisors accordingly (Tng et al.<sup>(23)</sup> and Phelps and Masri<sup>(20)</sup>).

*In vivo* studies to confirm the results should be done if the studies on skulls confirm the accuracy and reproducibility of this method. (The only means to determine the true incisor apex *in vivo* would be with computer assisted tomography scans. A prerequisite before ethical approval to conduct an *in vivo* method comparison study would be that the method to be investigated should be experimentally proofed to be superior.)

## REFERENCES

1. Slavkin H. Toward understanding the molecular basis of craniofacial growth and development. *Am J Orthod Dentofacial Orthop* 2000; 117(5): 538-539.
2. Sinclair PM. Tomorrow's challenges for the science of orthodontics. *Am J Orthod Dentofacial Orthop* 2000; 117(5): 551-552.
3. Hans MG. Introduction: evidence-based orthodontic practice. *Seminars in Orthodontics* 1999; 5(2): 75.
4. Proffit WR. *Contemporary orthodontics*. 3d ed. St Louis: Mosby; 2000. p 170-186.
5. Woelfel JB. *Dental anatomy: its relevance to dentistry*. 4th ed. Philadelphia: Lea & Febiger; 1990. p 51-63.
6. Moyers RE. *Handbook of orthodontics*, 4th ed. Chicago: Yearbook Medical Publishers; 1988. p. 118-119.
7. Alexander RG. *The Alexander discipline: contemporary concepts and philosophies*. 1st ed. Glendora (CA): Ormco Corporation; 1986. p. 105-106.
8. Rossouw PE, Preston CB, Lombard CJ, Truter JW. A longitudinal evaluation of the anterior border of the dentition. *Am J Orthod Dentofacial Orthop* 1993; 104(2): 146-151.
9. Richardson ME. Late lower arch crowding in relation to soft tissue maturation. *Am J Orthod Dentofacial Orthop* 1997; 112(2): 159-164.
10. Kahl-Nieke B, Fischbach H, Schwarze CW. Treatment and postretention changes in dental arch width dimensions: A long-term evaluation of influencing cofactors. *Am J Orthod Dentofacial Orthop* 1996; 109(4): 368-378.
11. Andrews L. The six keys to normal occlusion. *Am J Orthod* 1972; 62(3): 296-309.
12. De La Cruz AR, Sampson P, Little RM, Årtun J, Shapiro PA. Long-term changes in arch form after orthodontic treatment and retention. *Am J Orthod Dentofacial Orthop* 1995; 107(5): 518-530.
13. Cross JJ. The Tweed philosophy: the Tweed years. *Seminars in Orthodontics* 1996; 2(4): 231-236.
14. Steiner CC. Cephalometrics in clinical practice. *Am J Orthod* 1959; 29(1): 8-29.
15. Athanasiou AE. *Orthodontic cephalometry*. 1<sup>st</sup> ed. London: Mosby-Wolfe; 1995. p. 125-133.



16. Jacobson A. Radiographic cephalometry. 1<sup>st</sup> ed. Chicago: Quintessence; 1995. p. 1-5; 297-299.
17. Lenz GJ, Woods MG. Incisal changes and orthodontic stability. *The Angle Orthodontist* 1999; 69(5): 424-432.
18. McNamara JA. A method of cephalometric evaluation. *Am J Orthod* 1984; 86(6): 449-469.
19. Friedland B. Clinical radiological issues in orthodontic practice. *Seminars in Orthodontics* 1998; 4(2):64-78.
20. Phelps AE, Masri N. Location of the apex of the lower central incisor. *Am J Orthod Dentofacial Orthop* 2000; 118(4): 429-431.
21. Nelson S. Epidemiology for the practicing orthodontist. *Seminars in Orthodontics* 1999; 5(2):77-84.
22. Houston WJB. The analysis of errors in orthodontic measurements. *Am J Orthod* 1983; 83(5): 382-390.
23. Tng TTH, Chan TCK, Hägg U, Cooke MS. Validity of cephalometric landmarks - an experimental study on human skulls. *Eur J Orthod* 1994; 16(2): 110-120.
24. Cohen AM. Uncertainty in cephalometrics. *Br J Orthod* 1984; 11(1): 44-48.
25. Hägg U, Cooke MS, Chan TCK, Tng TTH, Lau PYW. The reproducibility of cephalometric landmarks: an experimental study on skulls. *Aust J Orthod* 1998; 15(3): 177-185.
26. Gianelly AA. Evidence-based treatment strategies: an ambition of the future. *Am J Orthod Dentofacial Orthop* 2000; 117(5): 543-544.
27. Jordan RE, Abrams L, Kraus BS. *Kraus' dental Anatomy and occlusion*. 2nd ed. St Louis: Mosby Year Book; 1992. p 21-27.
28. Taylor RMS. *Variation in morphology of teeth*. Springfield (Ill): Charles C Thomas Publishers; 1978. p 120-135.
29. Carlsen O. *Dental morphology*. 1<sup>st</sup> Ed. Copenhagen: Munksgaard; 1987. p 67-72.
30. Harris EF, Hassankiadeh S, Harris JT. Maxillary incisor crown-root relationships in different Angle malocclusions. *Am J Orthod Dentofacial Orthop* 1993; 103(1):48 – 53.
31. Proffit WR. The evolution of orthodontics to a data-based speciality. *Am J Orthod Dentofacial Orthop* 2000; 117(5): 545-547.

32. Richmond S, Klufas ML, Sywanyk M. Assessing incisor inclination: a non-invasive technique. *Eur J Orthod* 1998; 20(6): 721-726.
33. Baumrind S, Frantz RC. The reliability of head film measurements. 2. Conventional angular and linear measures. *Am J Orthod* 1971; 60(5): 505-517.
34. Chan CK, Tng TH, Hägg U, Cooke MS. Effects of cephalometric landmark validity on incisor angulation. *Am J Orthod Dentofacial Orthop* 1994; 106(5): 487-495.
35. Stabrun AE, Danielsen K. Precision in cephalometric landmark identification. *Eur J Orthod* 1982; 4(3): 185-196.
36. Nauert K, Berg R. Evaluation of labio-lingual bony support of lower incisors in orthodontically untreated adults with the help of computed tomography. *Journal of Orofacial Orthopedics* 1999; 60(5): 321-334.
37. Fuhrmann R. Three-dimensional interpretation of labiolingual bone width of the lower incisors. *Journal of Orofacial Orthopedics* 1996; 57(3): 168-185.
38. Fuhrmann R. Three-dimensional interpretation of periodontal lesions and remodeling during orthodontic treatment. *Journal of Orofacial Orthopedics* 1996; 57(4): 224-237.
39. Fuhrmann R. Three-dimensional interpretation of alveolar bone dehiscences. *Journal of Orofacial Orthopedics* 1996; 57(2): 63-74.
40. Mulie RM, Ten Hoeve A. The limitations of tooth movement within the symphysis - studied with laminagraphy and standardized occlusal films. *J Clin Orthod* 1976; 10(12): 882-899.
41. Wehrbein H, Bauer W, Diedrich P. Mandibular incisors, alveolar bone and symphysis after orthodontic treatment. A retrospective study. *Am J Orthod Dentofacial Orthop* 1996; 110(3): 239-246.
42. Baumrind S. Clinical research about clinical treatment: A new agenda for a new century. *Am J Orthod Dentofacial Orthop* 2000; 117(5): 548-550.
43. Björk A. Facial growth in man, studied with the aid of metallic implants. *Acta Odont. Scand* 1955; 13: 9-34.
44. Broadway ES, Healy MJR, Poyton HG. The accuracy of tracings from cephalometric lateral skull radiographs. *Transactions of the B.S.S.O. The Dental Practitioner* 1962;12(12): 455 – 460.
45. Altman DG. *Practical statistics for medical reasearch*. London: Chapman and Hall; 1991. p. 396 – 403.

46. Gravely JF, Benzie PM. The clinical significance of tracing error in cephalometry. *Br J Orthod* 1974;1(3): 95 – 101.
47. Courtney MD. Evidence-based orthodontics (Readers' forum). *Am J Orthod Dentofacial Orthop* 2001; 120(3):18A.
48. Kamoen A, Dermaut L, Verbeeck R. The clinical significance of error measurement in the interpretation of treatment results. *Eur J Orthod* 2001; 23(5): 569-578.
49. Hutton TJ, Cunningham S, Hammond P. An evaluation of active shape models for the automatic identification of cephalometric landmarks. *Eur J Orthod* 2000;22(5): 499 – 507.