

Chronic ulcerative stomatitis and lichen planus: just a coincidence or a direct link between the two diseases?

Przewlekłe wrzodziejące zapalenie jamy ustnej i liszaj płaski: przypadkowa zbieżność czy bezpośredni związek tych dwóch schorzeń?

Witold Kamil Jacyk¹, Jeanine Fourie², Willie F. van Heerden³

¹ Department of Dermatology, University of Pretoria, Pretoria, Republic of South Africa

² Department of Periodontics and Oral Medicine, University of Pretoria, Pretoria, Republic of South Africa

³ Department of Oral Pathology and Oral Biology, University of Pretoria, Pretoria, Republic of South Africa

ABSTRACT

Chronic ulcerative dermatitis (CUS) is characterized by painful exacerbating and remitting oral erosions and ulcerations. A very characteristic direct immunofluorescence (DIF) pattern differentiates CUS from other immune-mediated oral vesiculo-erosive conditions. The clinical and histopathological features of CUS are very similar to erosive oral lichen planus. A middle-aged woman had CUS confirmed by DIF and chronic plantar ulceration. Histology of the lesion on the sole showed features of lichen planus (LP). DIF of the plantar lesion showed the same pattern as the oral lesion of CUS. The relationship between CUS and erosive (ulcerative) LP of the foot is discussed. Chloroquine improved the oral lesions while oral cyclosporine A ameliorated both oral and plantar lesions.

Key words: chronic ulcerative stomatitis, lichen planus, squamous epithelium – specific nuclear antibodies (SES-ANA), cyclosporine A

STRESZCZENIE

Przewlekłe wrzodziejące zapalenie jamy ustnej (CUS) charakteryzuje się bolesnymi nawracającymi nadżerkami i owrzodzeniami jamy ustnej. Bezpośrednie badanie immunofluorescencyjne, bardzo charakterystyczne, odróżnia CUS od innych autoimmunizacyjnych pęcherzykowo-nadżerkowych procesów jamy ustnej. Kliniczne i histologiczne cechy CUS są bardzo podobne do liszaja płaskiego jamy ustnej. Przedstawiono przypadek 43-letniej kobiety z CUS potwierdzonym przez bezpośrednie badanie immunofluorescencyjne, u której dodatkowo występowały przewlekłe zmiany nadżerkowo-wrzodziejące na stopie. Badanie histopatologiczne owrzodzenia na stopie ujawniło cechy liszaja płaskiego. Immunofluorescencja bezpośrednia zmiany na stopie i zmiany w jamie ustnej wykazała podobny obraz. Związek między CUS i liszajem płaskim poddano dyskusji. Chlorochina miała korzystny wpływ na przebieg zmian w jamie ustnej, podczas gdy podanie cyklosporyny A doprowadziło do wygojenia nadżerkowego owrzodzenia stopy. Cyklosporyna A łagodziła też zmiany w jamie ustnej.

Słowa kluczowe: przewlekłe wrzodziejące zapalenie jamy ustnej, liszaj płaski, *squamous epithelium – specific nuclear antibodies* (SES-ANA), cyklosporyna A

Introduction

Chronic ulcerative stomatitis (CUS) is characterized by the presence of painful chronic and recurrent erosive and ulcerative lesions of the oral mucosa. The diagnosis requires direct immunofluorescence (DIF) of the mucosal biopsy which shows a very characteristic pattern – presence of antinuclear antibodies reactive only

with squamous epithelia of the lower part of the stratum spinosum (squamous epithelium-specific nuclear antibodies – SES-ANA).

Some authors classify CUS as a variant of erosive oral lichen planus (EOLP) [1]. Clinically and histologically CUS may be indistinguishable from EOLP[2].

We describe a patient with CUS and a rare form of lichen planus (LP)-ulcerative (erosive) LP of the foot. DIF of the biopsy from the

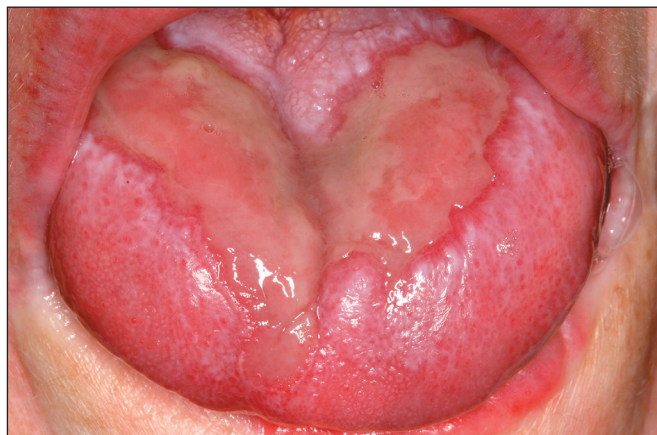

Fig. 1. Ulceration of tongue
Ryc. 1. Owrzodzenie na języku

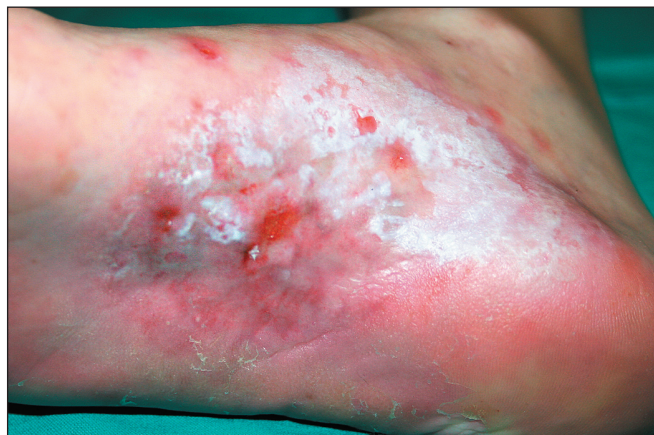

Fig. 2. Plantar ulceration
Ryc. 2. Owrzodzenie na podeszwie

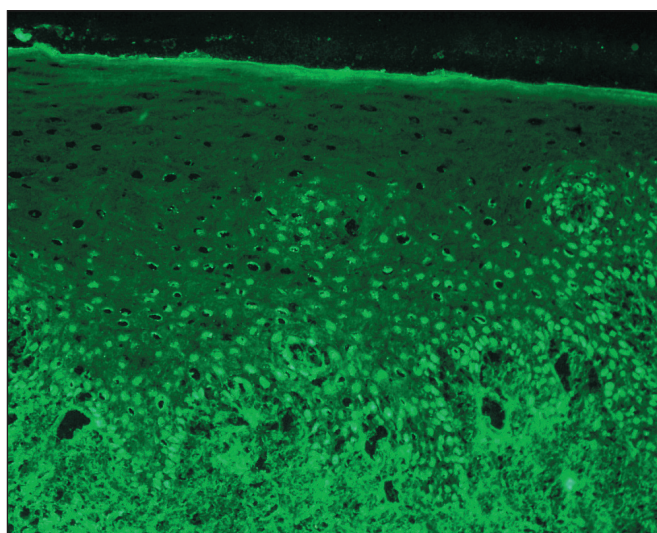


Fig. 3. DIF from a biopsy of the oral mucosa shows perinuclear IgG deposition affecting the lower third of the spinous layer
Ryc. 3. Biopsja owrzodzenia jamy ustnej. DIF – złogi IgG w komórkach dolnych rzędów stratum spinosum

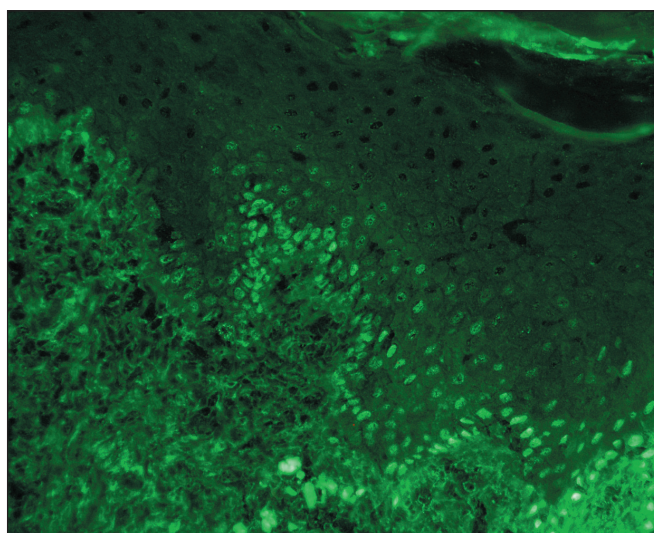


Fig. 4. DIF of the biopsy from the plantar ulcer, deposition of IgG
Ryc. 4. DIF owrzodzenia na stopie. Złogi IgG

periphery of the plantar ulcer demonstrated a similar pattern to that of oral ulceration.

Case report

A 43-year-old woman was referred from the Department of Periodontics and Oral Medicine with an ulceration of the plantar aspect of the right foot. She had several superficial painful ulcers in the oral cavity diagnosed as CUS [3] (fig. 1). The ulcer on the sole preceded the oral lesions by several months. The superficial ulcer was very painful and measured 3×1.5 cm (fig. 2). The patient complained of generalized pruritus and had several areas on the trunk and limbs with scratch marks. The nails were not affected. Her medical history revealed anxiety and depression. Routine laboratory tests were within normal limits.

Microscopic examination of the H&E stained specimen of the mucosal lesion showed an ulcer surrounded by stratified squamous epithelium. A diffuse subepithelial inflammatory cell infiltrate consisting of lymphocytes, plasma cells, histiocytes and mast cells extended into an underlying connective tissue was present.

The H&E stained biopsy specimen from the periphery of the plantar ulcer showed acanthotic epidermis with a slightly saw-toothed appearance, focal hypergranulosis, mild vacuolar alteration

of the basal layer and a chronic subepidermal lymphocytic infiltrate with focal lymphocytic exocytosis.

DIF of the biopsy from the plantar ulcer demonstrated perinuclear IgG and IgA deposition in the cells of the basal layer and in the cells of the lower third of the spinous layer (fig. 3). The DIF staining pattern of this lesion was identical to that of the oral ulceration. DIF of the oral lesion showed also IgG and IgA deposits (fig. 4). Indirect immunofluorescence was not performed.

When in the Department of Periodontics and Oral Medicine, the patient was prescribed 200 mg of chloroquine daily and after two months a significant improvement of the oral lesions was found. Chloroquine did not affect the foot ulceration. An eight week course of oral cyclosporine A (4 mg/kg/day) introduced in the Department of Dermatology led to healing of the plantar ulcer and maintained the mucosal lesions under control. However, in spite of the continued administration of cyclosporine A, erosions tended to appear on the surface of the healed ulcer. Topical 1% pimecrolimus ointment applied two times daily diminished this erosive tendency.

Discussion

CUS is one of several immunologically-mediated conditions affecting the oral cavity with chronic erosions and ulcerations, e.g.

mucous membrane pemphigoid, pemphigus vulgaris, linear IgA disease and erosive lichen planus. These conditions are often effectively treated with systemic corticosteroids. In CUS, corticosteroids are much less effective and hydroxychloroquine or chloroquine are the agents of choice. Hydroxychloroquine is furthermore not available in South Africa.

CUS was first described by Jaremko et al. [4] In four elderly women with chronic oral erosive and ulcerative lesions, high titres of circulating SES-ANA were found and DIF of the oral lesion biopsies showed a very characteristic pattern of their deposition in the nuclei of keratinocytes. Only nuclei of basal cells and cells of the lower third of the spinous layer were involved. DIF of the biopsies in our patient (oral mucosa and skin) showed deposition of IgG and IgA. Only some cases of CUS examined by DIF showed IgA. Although there have been no studies investigating the clinical significance of IgA antibodies in patients with CUS, a study of mucous membrane pemphigoid showed that patients with dual IgG and IgA have more severe disease [5].

Lee et al. characterized the CUS protein autoantigen and showed it to be a variant of the p53-like KET gene [6]. The CUS protein seems to be very important for epithelial development and regeneration. Anti-CUS protein antibodies may interfere with normal CUS protein function leading to chronic ulcerations and impaired wound healing.

Circulating SES-ANA directed against CUS protein have been detected in sera from patients with other conditions with autoantibodies (dermatomyositis, lupus erythematosus) and in sera of patients with LP. In the study reported by Parodi et al. [7] nine patients with LP had circulating anti-CUS antibodies. Four of them had only skin lesions, three only mucosal and two mucosal and skin lesions. DIF was not performed in this study.

Skin lesions of LP in patients with CUS are very rare. Chorzelski et al. [8] found lesions of LP in three patients with CUS. DIF on the skin lesions was not performed in this study. Solomon [9] suggested that there is a subset of LP patients who produce SES-ANA in high enough titre to be detected by DIF while in others the titre is low and the diagnosis of CUS cannot be made.

Finding of in vivo bound SES-ANA in the skin lesion of plantar erosive LP in a patient in whom CUS has already been confirmed raises the question concerning the relationship between CUS and LP. Ulcerative LP of the foot is a rare chronic form of lichen planus [10]. As in CUS, ulcerative LP affects mainly middle-aged women and often leads to marked disability. Our patient may represent an incomplete variation of this LP variant with only a single plantar ulcer and absence of nail abnormalities. Gradual permanent loss of toenails often with secondary webbing of the toes is seen in more severe cases. According to Rebora et al. [1] ulcerative LP of the feet is in fact erosive rather than ulcerative, as the process starts as blisters

resulting from a disruption of the basal cells [11]. Thus, the site of primary damage is the same as in CUS. The term erosive LP of the foot appears to be more appropriate than ulcerative. Efficacy of Cyclosporine A in erosive LP of the foot has been reported [12]. Patrone et al. [13] suggested that a course of cyclosporine A preceding excision and grafting offers the best treatment for this disorder.

References

1. Rebora A. *Erosive lichen planus: What is this?* Dermatol. 2002;205:226-228.
2. Parodi A, Cardo PP. *Patients with erosive lichen planus may have antibodies directed to a nuclear antigen of epithelial cells: A study on the antigen nature.* J Invest Dermatol. 1990;94:689-693.
3. Fourie J, van Heerden WF, McEachen SM, van Zyl A. *Chronic ulcerative stomatitis: a distinct clinical entity?* South African Dent J. 2011;66:119-121.
4. Jaremko WM, Beutner EH, Kumar V, et al. *Chronic ulcerative stomatitis associated with a specific immunologic marker.* J Am Acad Dermatol. 1990;22:15-20.
5. Setterfield J, Shirlaw PJ, Kerr-Muir M, et al. *Mucous membrane pemphigoid: a dual circulating antibody response with IgG and IgA signifies a more severe and persistent disease.* Br J Dermatol. 1998;138:602-610.
6. Lee LA, Walsh P, Prater CA, et al. *Characterization of an autoantigen associated with chronic ulcerative stomatitis: The CUSP autoantigen is a member of p53 family.* J Inv Dermatol. 1999;113:146-151.
7. Parodi A, Cozzani E, Massone C, et al. *Prevalence of stratified epithelium-specific antinuclear antibodies in 138 patients with lichen planus.* J Am Acad Dermatol. 2007;56:974-978.
8. Chorzelski TP, Olszewska M, Jarzabek-Chorzelska M, Jablonska S. *Is chronic ulcerative stomatitis an entity? Clinical and immunological findings in 18 cases.* Eur J Dermatol. 1998;8:261-265.
9. Solomon LW. *Chronic ulcerative dermatitis.* Oral Diseases. 2008;14:383-389.
10. Cram DL, Kierland RR, Winkelmann RK. *Ulcerative lichen planus of the feet.* Arch Dermatol. 1966;93:692-701.
11. Mahrle G, Gartmann H, Orfanos CE. *Ulzeriender Lichen ruber der Fusse: Zugleich eine elektronenmikroskopische Studie der subepidermalen Blasenbildung beim Lichen ruber bullosus.* Arch dermatol Forsch. 1972;243:292-304.
12. Cecchi R, Giomi A, Bartoli L., Tuci F. *Cyclosporine A in chronic ulcerative lichen planus of the feet.* Eur J Dermatol. 1994;4:68.
13. Patrone P, Stinco G, La Pia E, et al. *Surgery and cyclosporine A in the treatment of erosive lichen planus of the feet.* Eur J Dermatol. 1998;8:243-244.

Received: 2012.08.30. Approved: 2012.09.02.

Conflict of interests: none declared

Address for correspondence:

Professor W.K. Jacyk
Department of Dermatology, University of Pretoria,
P.O. Box 667,0001 Pretoria, Republic of South Africa
tel.: +27 12 3613600, fax: +27 12 3541856
e-mail: witold.jacyk@up.ac.za