



Suspected cardiac glycoside intoxication in sheep and goats in Namibia due to *Ornithogalum nanodes* (Leighton)

C. BAMHARE¹

ABSTRACT

BAMHARE, C. 1998. Suspected cardiac glycoside intoxication in sheep and goats in Namibia due to *Ornithogalum nanodes* (Leighton). *Onderstepoort Journal of Veterinary Research*, 65:25–30

The main clinical and necropsy features of field and experimental cases of suspected cardiac glycoside intoxication following ingestion and dosing of the plant *Ornithogalum nanodes*, are described. The distribution of intoxication in the area as well as a description of the plant are given. Plant samples tested for cardiac glycosides by fluorescence polarization immuno-assay (FPIA) gave a strong positive reaction. This is a new finding, as other toxic *Ornithogalum* species in southern Africa are devoid of cardiac glycoside activity and poisoning with them result only in a severe, often fatal diarrhoea, without obvious cardiac involvement. It is also the first record of toxicity of this particular plant.

Keywords: Cardiac glycosides, chinkerinchee, goats, Liliaceae, Namibia, plant poisoning, *Ornithogalum* spp., sheep

INTRODUCTION

The southern part of Namibia is hot, dry and grazing is scarce even in the best of seasons. The 1995/96 season was one of the worst in recent history. Most of the region had a very cold winter but received unusually heavy rains at the end of July. Whereas these rains had a positive effect on availability of green grass and browse in the Karas area, a poisonous plant took a heavy toll from August to October 1996 in animals which had not seen any green material for a long time. A total of 2 077 sheep and 759 goats on 42 farms are believed to have died from a plant intoxication in the period August to October 1996. Losses on individual farms were up to 200 animals.

A plant well-known to farmers in the Karas mountain region appeared to be the cause. They refer to it as the “krimpsiekte” plant from the main clinical signs it

causes in sheep and goats. It was identified by the National Botanical Research Institute (Windhoek) as *Ornithogalum nanodes* (Leighton) (R. Kubirske, National Botanical Research Institute, Windhoek, personal communication 1996).

At the time of writing, the National Botanical Institute, Pretoria is treating the plant (which also occurs in South Africa) as an *Ornithogalum* sp. nov (C. Archer, Botanical Research Institute, Pretoria, personal communication 1996).

In this report the clinical signs, necropsy and some histopathological features observed in field cases of *O. nanodes* poisoning during routine investigations as well as the results of a limited dosing trial with ground, fresh plant material, are given.

The main aims of the investigation were to prove that the signs and deaths were attributable to ingestion of the plant, and to determine the toxic principle. Attempts were also made to establish the geographical distribution of the intoxication and to estimate the extent of livestock losses induced by this plant.

The brief study was successful in attaining most of the desired objectives.

¹ Senior State Veterinarian, P.O. Box 30, Keetmanshoop, Namibia
Accepted for publication 11 December 1997—Editor

BRIEF DESCRIPTION OF THE PLANT

Ornithogalum nanodes (Leighton) belongs to a rather toxic genus of the Liliaceae commonly known as the chinkerinchees. Southern African species of the plants were described by Obermeyer (1978). The plant appears to be fast growing, green, semi-succulent with a soft, onion-like underground bulb. The leaves are slender, curve downwards, vary in number (4–10) and sprout from the bulb to appear at ground level. The underground bulb tapers upwards towards the surface. Bulbs occur singly but some plants have up to four with each bulb 1–3 cm in diameter. The plant rarely grows more than 10 cm high. Like *O. ornithogaloides* (vlei chinkerinchee), therefore, it is much smaller than the other well-known members of this genus, *O. thyrsoides* (star of Bethlehem), *O. saundersiae* (Transvaal chinkerinchee) and the “bosveld chinkerinchee” (*O. prasinum*), which are commonly associated with stock poisoning (Kellerman, Coetzer & Naudé 1988).

The plant appears 1–2 weeks after about 20 mm of rainfall and is one of the first plants to appear, even faster than *Enneapogon desvauxii*, the eight-day grass. New growth follows any subsequent significant rains (about 15 mm). Plant density varies greatly but as many as 10/m² were found in infested paddocks.

The above-ground part of the inflorescence is short (c. 3 cm but sometimes longer) and the stalk starts at ground level. Flower buds are at first arranged close together but separate out as they mature. The flower has six petals, which are cream (dark white) with a brown line. It matures to give a green three-chambered fruit which develops black, flat, winged seeds with a white kernel.



FIG. 1 *Ornithogalum nanodes* growing in its typical surroundings. Note the sparsity of other vegetation

The plant grows in rocky to stony areas, often in crevices, in well-drained red soils and along dry river banks.

MATERIALS AND METHODS

Field cases

Investigations were made into reports of many deaths of sheep and goats attributed to a plant unknown to veterinary staff at Keetmanshoop. Some of the affected farms were visited and clinical and *post mortem* examinations performed. Farmers and shepherds were interviewed to establish the apparent cause, course and outcome of intoxication. To determine the extent of the problem, the suspected plant was shown to farmers at a meeting and the signs described. Farmers whose properties had the suspect plant and whose animals had died following the clinical picture as described, were requested to indicate their losses on a list. The location of affected farms were plotted on a map using Supercalc version 5TM (Computer Associates) software.

Dosing trial

A dosing trial was conducted to confirm the plant as the cause of intoxication and to record and document clinical signs and necropsy findings. Plant material was collected on 27 August 1996 from the farm Arus 72B, district of Keetmanshoop, where 64 animals had reportedly died from this plant poisoning. The plant material was stored in a cold room until it was used over the following 2 d.

Three apparently healthy Karakul ewe-lambs aged about 5 months were obtained from Gellap Ost (a Government Research Station) where the suspected plant does not occur. On arrival they were housed in separate pens and food and water were withheld from them overnight. They were then weighed and offered fresh plant which they refused. After withholding of food and water for a further 24 h, the plant was once more offered to them but was again rejected. They were then dosed with an aqueous suspension of 500 g of plant material (consisting of leaves and flowering parts) chopped with a knife and then ground with a mincer and suspended in water to give a final volume of 3. This was then divided into 0,5 l, 1 l and 1,5 l portions and the three selected sheep were dosed by stomach tube or bottle to an equivalent of c. 4, 8 and 12 g of plant material/kg body mass.

Animals were observed at intervals of 30–60 min during the course of the day but only significant changes were recorded. To keep handling to a minimum, behavioural signs were recorded with the aid of a video camera.

Post mortem examinations were performed on all three animals and tissue samples submitted in 10 %

formalin to the Central Veterinary Laboratory at Windhoek for histopathological examination, following routine staining procedures.

RESULTS

Field cases

The reports of plant poisoning were widespread but occurred mostly on the eastern and northern aspects of the Karas mountains at grid reference *c.* 27°S 19°E (Fig. 2). *O. nanodes* was believed to be responsible for the death of livestock on 42 farms in the region. Most of the farms at which intoxication occurred had received 20 mm or more rain that season.

The following observations were made at three representative farms investigated between 19th August and 10th September, 1996.

Farm 1

The farm had received 40 mm of winter rain on 24–25 July, the first time so much had been received in 40 years. Forty sheep were reported to have died up to that date.

CLINICAL SIGNS

Five of the 15 affected sheep were examined. The main clinical signs were gazing or staring into space without being blind; torticollis with the head bent back onto the shoulder (when disturbed the position returned to normal); and a tucked in abdomen. This was accompanied by abdominal breathing, a mucoid nasal discharge, slow accentuated "deliberate" heart-

beats, and ruminal stasis. The rectal temperature was normal (*c.* 38,6 °C).

NECROPSY FINDINGS

The changes in two animals examined included sub-epicardial petechial haemorrhages; haemorrhages in the atria and ventricles, which were filled with clotted blood (*viz.* the heart was not in *rigor*); congestion and oedema of lungs, with froth in trachea; congestion of the liver and slight oedema of kidneys; congestion of meningeal vessels and haemorrhages into sinuses. The rumen contents were apparently normal. It was not clear whether the rumen lining was sloughing as a result of the poisoning or whether the loosening of the epithelium was due to autolysis. There was no evidence of diarrhoea.

Farm 2

The history was similar to that of farm 1.

CLINICAL SIGNS

Affected animals stared, stood with the abdomens tucked in, and exhibited torticollis. Some lambs trembled and older ewes tired easily.

NECROPSY FINDINGS

The heart was not in *rigor* (blood clots in all chambers) and petechial haemorrhages were present in the sub-endocardium and sub-epicardium. Amongst the other changes recorded were generalised lung congestion with areas of consolidation; mild liver congestion; sub-capsular and cortical oedema of the kidney; suspected sloughing of rumen lining (could have been autolysis); hyperaemia, oedema and swelling of abomasal mucosa; congestion of mesenteric vessels and congestion and oedema of the caecum and colon, which had very fluid contents. No evidence of diarrhoea was found.

Farm 3

The farmer reported a history of plant poisoning since moving to the farm in 1992. Sixty-three of 300 goats and 12 of 800 sheep had died. Symptoms appeared 3–4 d after exposure and death followed in 3–4 d. Animals remained sick for up to 14 d and some took up to a month to recover.

CLINICAL SIGNS

These were the same as observed at the two farms described above, but some affected animals had diarrhoea. Goats which had been moved, appeared to be in worse condition than sheep in the same group. Head tremors were marked in goats. The fate of the sick animals is unknown and none were presented for necropsy.

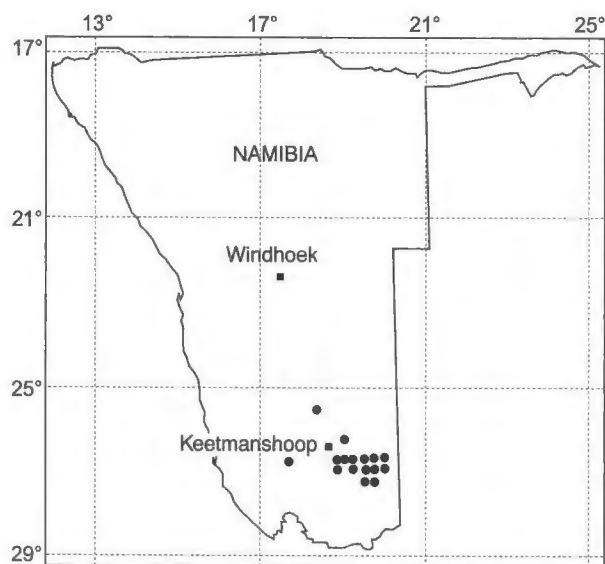


FIG. 2 Location of farms reporting suspected *Ornithogalum nanodes* poisoning in the Keetmanshoop area of southern Namibia (August to October 1996)

Dosing trial

All three animals refused to eat the fresh plant material after being deprived of food and water for respectively 12 and again 36 h.

The sheep were then clinically examined and appeared normal in all respects, their temperatures ranging from 37–38,5°C and heart rates from 96–112/min. Ruminal movements were noted as normal and respiratory and cardiac rates were taken just prior to the dosing experiment. They were then dosed either by stomach tube or bottle as indicated, and the resultant signs are summarized in Table 1. All three animals died overnight.

Pathological findings

GROSS LESIONS

Since all three animals were found dead the next morning, the *interim* could not be determined. Advanced autolysis may have contributed to some of the gross lesions not being histopathologically confirmed.

Congestion and oedema of the lungs were observed in all three animals. Sheep 1, in addition, had emphysema and haemorrhages in the apical lobes, while sheep 2 displayed froth in trachea and some foam at the nose and mouth. Sub-epicardial and -endocardial petechial haemorrhages were seen in all three animals, with clotted blood in all cardiac chambers. Congestion of the liver was marked in sheep 1 and 2, and the liver of sheep 1 was pale and soft. The

rumen lining appeared normal in sheep 1, but the ruminal papillae tended to slough off in the other two. Sheep 1 showed swelling of the abomasum, congestion and haemorrhages of the duodenum and upper third of the small intestine, and congestion of the rest of the intestinal tract.

A pathological anatomical diagnosis of heart and circulatory failure was entered for all three animals.

HISTOPATHOLOGICAL CHANGES

Specimens of all three sheep were examined at the Central Veterinary Laboratory, Windhoek, Namibia. No lesions were detected in the liver, kidney or heart. The bronchi and alveoli were filled with numerous granulocytes and areas of lymphatic aggregation and congestion and alveolar and interstitial oedema occurred. There was evidence of autolysis in the small intestine but no inflammatory changes were encountered in the rumen. No further changes of any significance were found.

The pathologist was of the opinion that these lesions were not attributable to plant poisoning and a diagnosis of severe acute alveolar pneumonia was made in one of the experimental animals (F.P. Mettler, Central Veterinary Laboratory Windhoek, personal communication 1996).

SUMMARY OF OBSERVATIONS

The most consistent clinical signs observed in animals following natural exposure and from the limited

TABLE 1 Signs of intoxication in three sheep dosed with fresh *Ornithogalum nanodes* plant material

Interval post administration	Sheep 1	Sheep 2	Sheep 3
0 h	Dosed 4 g/kg	Dosed 8 g/kg	Dosed 12 g/kg
c. 2 h	Nothing unusual	Grunting, abdominal breathing	Grunting, abdominal breathing. No discernible ruminal movements
c. 3 h and 4 h	Increased respiratory rate, grinding of teeth	Grunting more pronounced; head hanging, ruminal stasis	Increased respiratory rate, abdominal breathing
5 h	Do. Shifting mass between hind legs, standing with tucked in abdomen	Do.	Groaning, watery diarrhoea, urinating, shifting mass between hind legs
6 h	Do.	Do. Recumbent, slight frothing from nose and mouth	Do. Standing immobile
6,5 h	Do. Nibbled at offered lucerne hay	Do. Nibbled at offered lucerne hay	Recumbent, almost moribund
22 h	Found dead	Found dead	Found dead

feeding trial were abdominal breathing, torticollis, head tremors, tucked in abdomen ("krimpsiekte"), ruminal stasis, shifting mass and staring into space. Less consistent were a mucoid nasal discharge, frothing at the mouth, diarrhoea, tooth grinding and grunting. Impulsive chewing and foaming at the mouth were observed in goats, and farmers reported the signs in goats to be much worse than in sheep. Death followed within 3–4 d of the clinical signs appearing but occurred sooner in animals that were subject to physical stress, e.g. after walking long distances or following handling. Animals died in lateral recumbency with evidence of struggling in some.

The plant appears to be very toxic. Signs of distress appeared within 2 h of dosing 4–12 g/kg body mass and death followed in less than 24 h. At the highest dose one experimental animal developed profuse diarrhoea within 4 h. Diarrhoea was occasionally reported in natural cases.

The clinical signs and necropsy features of *O. nanodes* intoxication were highly suggestive of cardiac glycoside poisoning as described by Kellerman *et al.* 1988. These authors list diarrhoea as the outstanding feature of chinkerinchee poisoning, but make no mention of cardiac involvement in this condition. Sun dried plant samples were, accordingly, submitted to the Onderstepoort Veterinary Institute to be tested for cardiac glycosides by fluorescence polarization immuno-assay (FPIA). A strong positive reaction was obtained, a most unusual finding for a member of the genus *Ornithogalum* (R. Anitra Schultz & T.W. Naudé, OVI, personal communication 1996).

DISCUSSION

In southern Africa the genus *Ornithogalum* comprises 62 species (Arnold & De Wet 1993) all of which should be regarded as toxic unless proven otherwise (T.S. Kellerman & T.W. Naudé, OVI, personal communication 1996). All parts of the plants are toxic.

Moll (1989) describes the stage of maximum toxicity among chinkerinchees as varying with species. In many species the fruits, seeds or bulbs contain the largest amount of poison, whilst in others the young tender shoots before flowering are most toxic.

Although the very irritant glycosidal toxic principle isolated from *O. thyrsoides* by L.A.P. Anderson (OVI, unpublished data 1987) has a steroid aglycone, it is definitely not a cardiac glycoside (R. Vlegaar, Department of Chemistry, University of Pretoria, personal communication 1997). The clinical signs elicited by the other three species most commonly involved in stock intoxication in southern Africa, *O. saundersiae*, *O. prasinum* and *O. ornithogaloides*, are identical to that of the former (Kellerman *et al.* 1988) and it is, therefore, assumed that they have similar, or structurally closely-related, toxic principles.

In the case of *O. nanodes* animals are most at risk when they eat the young shoots. The plant is one of the very first to come up after rains and in many cases will be the only green material available (Fig. 1). By the time of flowering, other green plants will most probably be available for the animals to eat and some of the toxic plant's leaves will have dried out. Although some farmers observed that animals tend to avoid the plant when other grazing is available, deaths were reported on three farms following further rainfalls of 15–20 mm. The relative reluctance of animals to graze this plant is borne out by the observation that the experimental animals refused voluntary intake of this plant even after being deprived of food and water for as much as 36 h.

The clinical signs observed in the case of *O. nanodes* poisoning are highly suggestive of acute cardiac glycoside intoxication as described in tulp and slangkop poisoning by Kellerman *et al.* (1988), viz. ruminal stasis accompanied by either diarrhoea or constipation; posterior paresis; dyspnoea, or even apnoea; and severe arrhythmia, often resulting in cardiac failure and death. In contrast, the most important and most constant feature of typical chinkerinchee (*Ornithogalum* spp) poisoning in small stock is a watery, foetid diarrhoea (starting within 24 h of intoxication and lasting up to 3 weeks), without obvious cardiac involvement. In the current outbreak, although at necropsy intestinal contents were sometimes very fluid, diarrhoea was rarely observed in the field and experimentally only at the highest dose.

The conclusion was reached that the clinical signs induced by *O. nanodes* were more consistent with those of cardiac glycoside than chinkerinchee poisoning. *O. nanodes* must, therefore, be included with tulp, slangkop and the succulent plakkies as a cause of cardiac glycoside intoxication of stock in southern Africa.

Dosing intoxicated animals with activated charcoal in water at 2 g/kg body mass as recommended by Kellerman *et al.* 1988 is the treatment of choice.

Current information suggests that the only effective method of control is to avoid affected paddocks until other edible plants start growing. This may not always be practicable but must be seriously considered if heavy losses are to be avoided.

ACKNOWLEDGEMENTS

The author acknowledges with gratitude the enthusiastic assistance of local farmers and the staff of the Gellap Ost Research Station, and the technical and professional contributions regarding the histopathology by Dr F.P. Mettler, Central Veterinary Laboratory, Windhoek; the botanical assistance by Ms R. Kubirske and Mr W. Geiss of the National Botanical

Research Institute (Windhoek) and Mrs Anitra Schultz of the Section of Toxicology of the Onderstepoort Veterinary Institute for the FPIA determination and Profs T.W. Naudé and T.S. Kellerman of the same Division for critical revision of and assistance in the final preparation of the manuscript.

The Director of Veterinary Services (Namibia) is thanked for granting permission to publish this paper.

REFERENCES

- ARNOLD, T.H. & DE WET, B.C. 1993. *Plants of Southern Africa*. Pretoria: National Botanical Institute (*Memoirs of the Botanical Survey of South Africa*; no. 62).
- KELLERMAN, T.S., COETZER, J.A.W. & NAUDÉ, T.W. 1988. *Plant poisonings and mycotoxicoses of livestock in Southern Africa*. Cape Town: Oxford University Press.
- MOLL, E. & MOLL, G. 1989. *Struik pocket guides for southern Africa. Poisonous plants*. Cape Town: Struik.
- OBERMEYER, A.A. 1978. *Ornithogalum*: a revision of southern African species. *Bothalia*, 12(3):323–376.