

# Pneumoesophagography and the appearance of masses in the caudal portion of the esophagus in dogs with spirocercosis

Robert M. Kirberger, BVSc, MMedVet; Liesel L. van der Merwe, BVSc, MMedVet; Eran Dvir, DVM, MMedVet

**Objective**—To determine the usefulness of pneumoesophagography, compared with that of survey radiography, for characterization of esophageal pathological changes in dogs with endoscopically confirmed intraluminal *Spirocerca lupi* nodules in the caudal portion of the esophagus.

**Design**—Diagnostic test evaluation.

**Animals**—30 dogs with endoscopically confirmed spirocercosis.

**Procedures**—Dorsoventral (DV) and right lateral recumbent (RLR) thoracic survey radiographs were obtained for each dog. Endoscopy was subsequently performed, the esophagus was inflated with air, and left lateral recumbent, RLR, DV, and ventrodorsal thoracic radiographs were obtained. The amount of esophageal and gastric distention was recorded. Visibility, location, and surface characteristics of lesions and total length of esophageal involvement were recorded independently for each radiograph and modality and compared with each other.

**Results**—Survey DV radiographs were more reliable than survey RLR radiographs for detecting caudal esophageal pathological changes. Lateral pneumoesophagograms showed more esophageal air and had more visible nodules than did their orthogonal counterparts. Right lateral recumbent pneumoesophagograms allowed for evaluation of the air-filled stomach, particularly the cardiac portion, for additional pathological changes. Pneumoesophagography allowed the mural position (47% located dorsally) and surface characteristics of *Spirocerca* nodules to be determined. Six of 9 dogs with confirmed malignant disease had an irregular nodule surface suggestive of neoplastic transformation.

**Conclusions and Clinical Relevance**—Pneumoesophagography was easily performed in dogs with spirocercosis and showed promise as a cost-effective and safe initial diagnostic procedure for further evaluation and characterization of suspected caudal esophageal lesions. (*J Am Vet Med Assoc* 2012;240:420–426)

Routine radiographic examination of the thorax in dogs consists of an LLR or RLR view and its orthogonal DV or VD counterpart. The effect of various radiographic views on the visibility or position of thoracic structures in healthy dogs has been described.<sup>1,2</sup> Various views have also been used to better define thoracic pathological changes,<sup>3–5</sup> and the effect of positioning on the appearance of caudodorsal mediastinal masses has been reported.<sup>6</sup> Mediastinal lesions are generally better delineated on a DV or VD radiograph than on LLR or RLR views.<sup>3,7,8</sup>

Anatomic structures in the caudodorsal mediastinum include the dorsal intercostal arteries and veins, esophagus, thoracic duct, right and left paravertebral ganglia and associated nerves, vagal nerves, descending aorta, bronchoesophageal arteries and veins, and the azygos vein.<sup>7</sup> In clinically normal dogs, the esophagus is not visible, except occasionally in large-breed dogs, in which the esophagus may be detected just cranial to the

## ABBREVIATIONS

DV	Dorsoventral
LLR	Left lateral recumbent
RLR	Right lateral recumbent
VD	Ventrodorsal

diaphragm on an LLR radiograph.<sup>2</sup> The descending mid mediastinal aorta is seen reasonably well at the level of the heart and is seen better on DV and LLR projections<sup>2</sup>; however, the caudal mediastinal aorta becomes less well-defined on the lateral view as well as on DV and VD views because its left edge joins the vertebral column border. The remaining caudodorsal mediastinal structures are not visible in clinically normal dogs.

Caudodorsal mediastinal disease, in particular disease that causes a mass effect (ie, pathological process that displaces adjacent organs or structures), primarily involves pathological changes in the esophagus. Causes in dogs include foreign bodies, *Spirocerca lupi* nodules (in geographic regions in which the parasite is endemic) and neoplastic transformation thereof, food- or fluid-filled megaesophagus, hiatal hernia, gastroesophageal intussusception, primary and metastatic neoplasia, and esophageal diverticula.<sup>7,9–12</sup> A

From the Department of Companion Animal Clinical Studies, Faculty of Veterinary Science, University of Pretoria, Onderstepoort 0110, Republic of South Africa.

Presented in abstract form at the European Association of Veterinary Diagnostic Imaging Congress, Giessen, Germany, July 2010.

Address correspondence to Prof. Kirberger (robert.kirberger@up.ac.za).

caudodorsal mediastinal mass effect may also be attributable to paraesophageal hernia; diaphragmatic rupture, hernia, abscess, or hematoma; neoplasia of neural or vertebral body origin; migrating foreign bodies; and mediastinitis secondary to esophageal perforation.<sup>7,9,11,12</sup> Vascular causes of caudodorsal mediastinal lesions include aortic aneurysms, usually secondary to *S lupi* larval migration, and a markedly distended azygos vein secondary to absent prehepatic caudal vena cava or a portoazygous shunt.<sup>11,13</sup>

Positive contrast esophagography is routinely performed in dogs to elucidate pathological esophageal changes<sup>9</sup> but may lead to pulmonary aspiration of barium or obscure the visibility of small nodules. Pneumo-esophagography as a contrast radiographic procedure was alluded to in a literature review<sup>14</sup> on *S lupi* infection in dogs but is not mentioned in a recent standard radiology textbook<sup>9</sup> as a possible diagnostic tool. Safety and cost-effectiveness are major advantages of the technique.

The purpose of the study reported here was to determine the usefulness of pneumoesophagography, compared with that of survey radiographs, for determining the visibility and size of esophageal masses in dogs with endoscopically confirmed intraluminal *S lupi* nodules in the terminal portion of the esophagus. Although computed tomography and endoscopy are sensitive techniques for detecting esophageal disease, they involve the use of expensive equipment that is not always readily available in routine small animal practice. Pneumo-esophagography may be a less expensive yet effective option by which to diagnose various causes of esophageal lesions ranging from foreign bodies to mural neoplasia.

## Materials and Methods

**Animals**—Thirty dogs from a larger prospective spirocercosis study<sup>15–17</sup> in which terminal esophageal nodules were diagnosed by means of endoscopy were selected. All dogs were evaluated over a 1-year period (2007 to 2008). This study was approved by the University of Pretoria Animal Use and Care Committee as well as the Research Committee.

**Survey radiography**—Four standard radiographic thoracic views (DV, VD, RLR, and LLR) were obtained from each dog. However, because DV and RLR thoracic views are better than VD and LLR views for identifying caudodorsal mediastinal masses,<sup>6</sup> only DV and RLR radiographs were used for study purposes.

**Endoscopic measurements**—Twenty-four to 48 hours after radiography, dogs underwent esophageal and gastric endoscopy.<sup>a</sup> For this procedure, dogs were premedicated with various drugs on the basis of clinician preference. Anesthesia was then induced with propofol<sup>b</sup> and maintained with isoflurane.<sup>c</sup> Each dog was positioned in LLR, and a complete esophageal and gastric endoscopic examination, including the cardia, was performed. The *S lupi*-associated nodules and masses were counted and assessed for appearance (smooth or cauliflower-like), individual length, and confluent length of esophageal involvement. Nodule length was determined by measuring its distance from the canine tooth and subtracting the most caudal measurement

from the more cranial one. When several nodules were present, the total length of esophagus involved was measured as the distance from the cranial edge of the first nodule to the caudal edge of the last nodule or, when the nodule involved the cardia, to the cardia. These findings were then compared with the survey radiographs when only 1 mass was visible and with pneumoesophagograms when multiple nodules were suspected. The width of the nodules could not be ascertained endoscopically, and the circumferential location of the nodules was not recorded. Dogs were classified as positive for *S lupi* infection on the basis of typical endoscopic and radiographic signs or identification of characteristic eggs during fecal testing.<sup>14</sup>

**Pneumo-esophagographic technique**—Immediately after endoscopy, each anesthetized dog was transferred to the radiography room. An additional endotracheal tube was placed in the esophagus with the tip located in the distal cervical region of the esophagus, and a resuscitator was attached. Adult and infant silicone resuscitators<sup>d</sup> were used in dogs > 10 kg (22 lb) and < 10 kg, respectively. The esophagus was initially inflated with room air by use of 3 to 4 resuscitator compressions. Routine RLR and LLR thoracic radiography was subsequently performed. The esophagus was then reinflated, and DV and VD radiographs were obtained.

**Image evaluation**—All radiographs obtained were stored in digital format and subsequently retrieved from the Onderstepoort Veterinary Academic Hospital picture archiving system for interpretation. All were evaluated by 1 board-certified radiologist (RMK), who subjectively adjusted the image contrast, brightness, and magnification to optimize visibility of pathological changes. All radiographs were examined independently from each other to avoid interpretation attributable to a mass having been identified on another view.

Each of the 2 survey radiographs and 4 pneumoesophagograms was assessed for the visibility of a nodule or mass (seen or not seen), and the total length of affected esophagus was recorded. The potential effect of radiographic magnification was ignored. On the 4 pneumoesophagograms, the degree of esophageal and gastric distention with air was graded by use of a 5-point scale (0 = no air evident; 4 = marked distention evident). Mass margins were classified as smooth or irregular. The point of esophageal attachment was recorded by use of a clock face analogy, with dorsal, left side, ventral, and right side defined as 12, 3, 6, and 9 o'clock, respectively.

Nodules were characterized as sessile or pedunculated. When > 1 mass was identified, the total number was counted and the 2 largest masses were evaluated. The total length of affected esophagus was measured. Whether a nodule or mass was identified in the air-filled stomach was also noted. In addition, factors that might have influenced image interpretation such as poor dog positioning or the presence of lung lesions were also recorded.

**Statistical analysis**—Data were recorded and statistically analyzed by use of a spreadsheet program<sup>e</sup> and statistical software.<sup>f</sup> Results were expressed as median and range. Visibility of the *S lupi* masses (seen or not

seen) on the various views was compared by use of the  $\chi^2$  test. Affected esophageal length was compared among the pneumoesophagographic, survey radiographic, and endoscopic measurements by use of a paired *t* test. Descriptive statistics were used to summarize the total number of nodules identified, nodule surface outline, mural attachment location, cardia visibility, and degree of gastric distention (distention score). The esophageal distention score was compared among views by use of the Mann-Whitney test. For all tests, values of  $P \leq 0.05$  were considered significant.

## Results

**Animals**—Dogs had a median age of 49 months (range, 9 to 125 months) and median body weight of 21 kg (46.2 lb; range, 3.6 to 41.4 kg [7.9 to 91.1 lb]). Purebreds included 5 Jack Russell Terriers, 3 German Shepherd Dogs, 3 Boerboels, 2 Bull Terriers, 2 Rottweilers, and 2 Labrador Retrievers; the remaining 13 were mixed breeds or single representatives of various other breeds.

**Esophageal distention scores**—The degree of esophageal distention with air evident on pneumoesophagograms ranged from 2 to 4 for lateral views (Figure 1) and 0 to 4 for the DV and VD views, with a median of 3 for

all views. When distention scores were compared among the 4 views, the lateral views (LLR and RLR) showed significantly ( $P = 0.020$ ) more distention than did orthogonal views (DV and VD). There was no significant difference in distention scores between the 2 lateral ( $P = 1.00$ ) and 2 orthogonal ( $P = 0.87$ ) views. Most dogs had concomitant gastric distention, which improved visibility of the cardiac region. Cardiac region gas distention was most commonly seen in RLR views (29/30 [97%] dogs); it was only evident in 12 (40%) dogs when DV and VD views were used and in 8 (27%) dogs when LLR views were used.

**Nodule detection**—The ability of the different imaging techniques to show caudal esophageal nodules varied (Table 1). Survey radiography allowed most nodules to be seen on DV views (Figure 2), whereas with pneumoesophagography, most nodules were visible on lateral views (Figure 3).

The combined 2 survey radiographic views (RLR and DV) had a sensitivity of 93% for detecting esophageal masses (Table 1). The combined 4 pneumoesophagographic views (DV, VD, RLR, and LRL) had a sensitivity of 90%, and a combination of all views had a sensitivity of 97%. Right lateral recumbent pneumoesophagograms were significantly ( $P = 0.030$ ) more sensitive than DV pneumoesophagograms for caudal esophageal mass de-

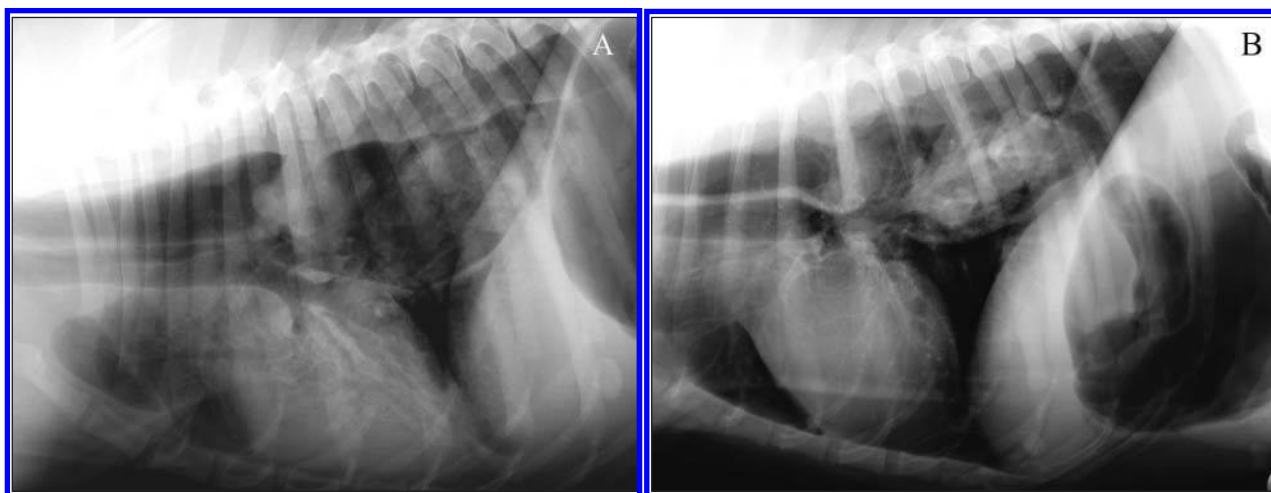


Figure 1—Lateral recumbent pneumoesophagographic views of a 7-year-old Labrador Retriever with several caudal esophageal nodules caused by *Spirocerca lupi* infection. A—The RLR view shows gas in the corpus and cardiac regions of the stomach. The degree of esophageal distention was graded as 4 (marked distention). B—The LLR view reveals gas in the pylorus and duodenum. Esophageal distention was graded as 3 (moderate distention).

Table 1—Findings of survey radiography and pneumoesophagography in 30 dogs with endoscopically confirmed spirocercosis.

Variable	Survey radiography*			Pneumoesophagography					Both methods
	RLR	DV	Either view	RLR	LLR	DV	VD	Any view	Any view
No. of dogs with nodules	14	25	27	24	25	16	16	27	29
Sensitivity for nodule detection (%)	48	86	93	80	83	53	53	90	97

\*One dog had megaesophagus and the esophagus was not filled with air; therefore, the dog could not be evaluated.  
For sensitivity calculations, endoscopy was considered the reference standard.

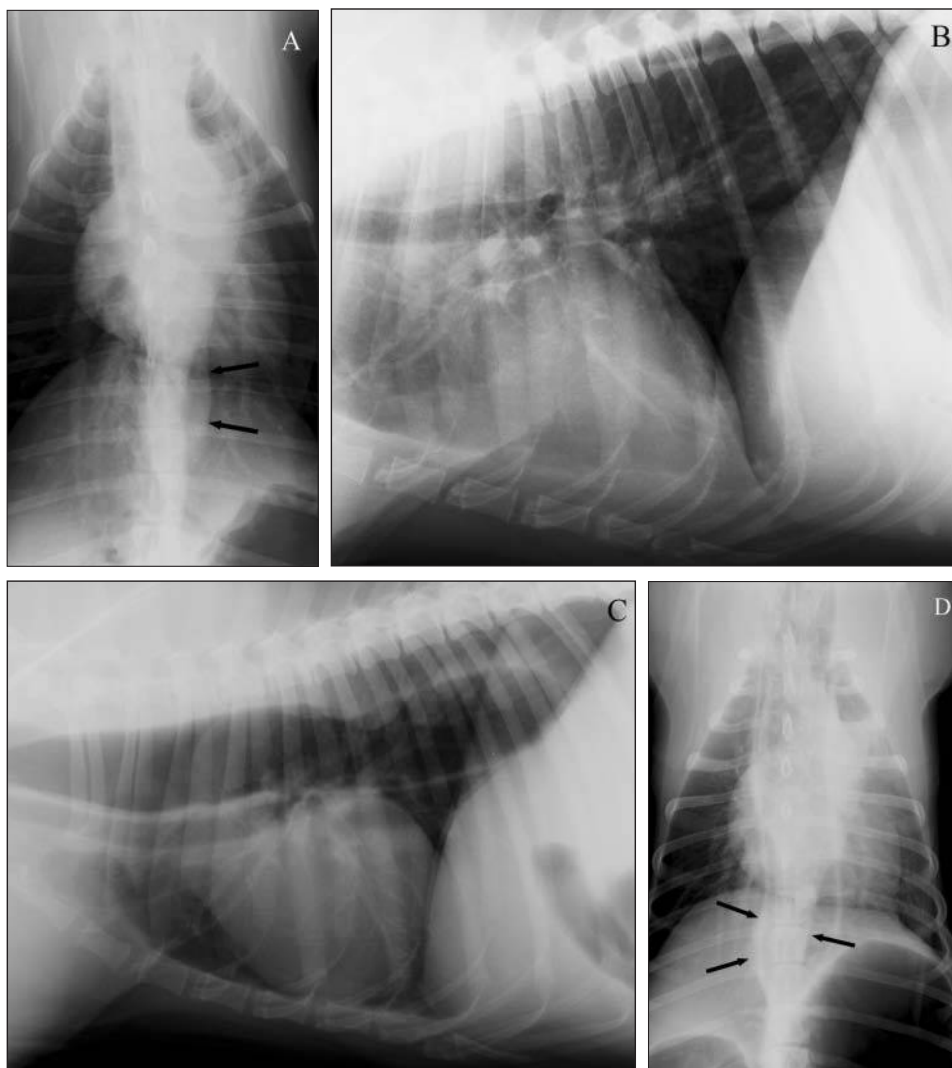


Figure 2—Thoracic radiographic views of a 2-year-old Rottweiler with *S lupi* infection. A—The DV survey radiograph shows a small caudal esophageal mass (arrows). B—The RLR survey radiograph shows no obvious esophageal mass. C—The RLR pneumoesophagogram shows a dorsal esophageal mass. D—The DV pneumoesophagogram shows a midline mass (arrows).

tection, whereas DV survey radiographs were significantly ( $P = 0.003$ ) more sensitive than lateral survey radiographs. The sensitivity of LLR pneumoesophagograms was similar to that of RLR pneumoesophagograms, and the sensitivity of VD pneumoesophagograms was similar to that of DV pneumoesophagograms. Findings from 1 dog were not included in the statistical analysis of survey radiographic findings because it had megaesophagus.

**Nodules**—Although the survey DV views allowed detection of more nodules than the DV and VD pneumoesophagograms, pneumoesophagography aided in detecting the origin of the nodules on the lateral esophageal wall (11 on DV views and 9 on VD views). In 2 dogs that did not have a nodule visible on the survey radiographs, 1 had nodules detected on the pneumoesophagograms. In 1 dog, no nodules or masses could be detected in any of the 6 radiographic views. In 2 dogs in which survey radiographs revealed a mass, the mass could not be seen on pneumoesophagograms. Two dogs had no radiographic lesions evident, and endoscopy revealed nodules 10 mm

long in one and 20 mm long in the other. However, there were 8 dogs in which 10- to 20-mm nodules were visible via endoscopy as well as via pneumoesophagography.

**Location of nodules**—No gastric nodules or masses were seen by means of radiography or endoscopy. When a nodule was dorsally or ventrally attached to the esophagus, it usually only had a luminal appearance on the DV and VD views with no attachment seen, particularly for smaller nodules. Similarly, lateral nodules often appeared luminal on RLR and LLR views (Figure 4). Mural location was readily seen with pneumoesophagography but could not be compared with the endoscopic images because the location was not recorded. Fourteen (47%) dogs had dorsal, 10 (33%) had ventral (Figure 3), and 4 (13%) had lateral wall attachment of nodules. Twelve of the dorsally and 4 of the ventrally attached nodules also had lateral wall involvement.

**Number of nodules**—Esophageal endoscopy identified between 1 and 9 nodules/dog (median, 2 nodules/dog), which ranged in size from 5 to 100 mm. Pneumoesophagography allowed detection of multiple nodules on a single view in 4 dogs, whereas 15 dogs had multiple nodules on endoscopic images. The total length of esophageal involvement in endoscopically seen nodules, survey radiographs, and pneumoesophagograms did not differ significantly among the views and modalities (Table 2).

**Mass characteristics**—Nine dogs had esophageal nodules or masses that were confirmed to be malignant on the basis of results of histologic examination or no response to treatment. Endoscopy revealed surface roughening, tissue proliferation, and necrotic craters on the esophageal mucosal surface. Pneumoesophagography allowed correct identification of an irregular nodule surface in 6 of the 9 dogs on at least 1 view and an irregular surface in 1 dog in which lesions appeared benign and smooth with endoscopy. Only 3 dogs were assessed as having a pedunculated mass on pneumoesophagograms, of which 2 had confirmed malignant lesions.

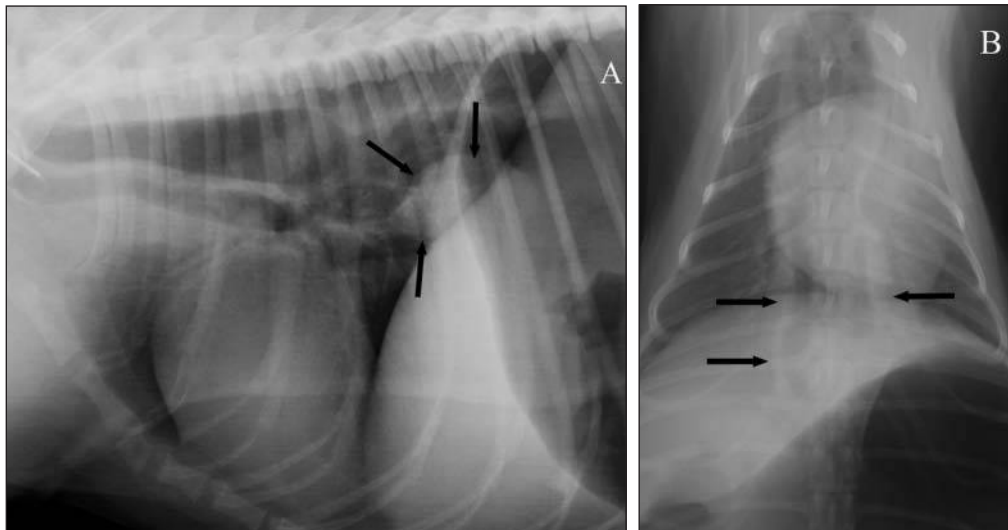


Figure 3—Pneumoesophagographic views of a 5-year-old Miniature Pinscher with a large caudoventral esophageal mass caused by *S lupi* infection. A—The RLR view shows a luminal and mural sessile smooth-surfaced mass adjacent to the diaphragm (arrows). This mass appeared 31 mm long on radiographs and 30 mm long on endoscopy. B—The DV view shows the esophageal wall with a difficult-to-discern mass (arrows).

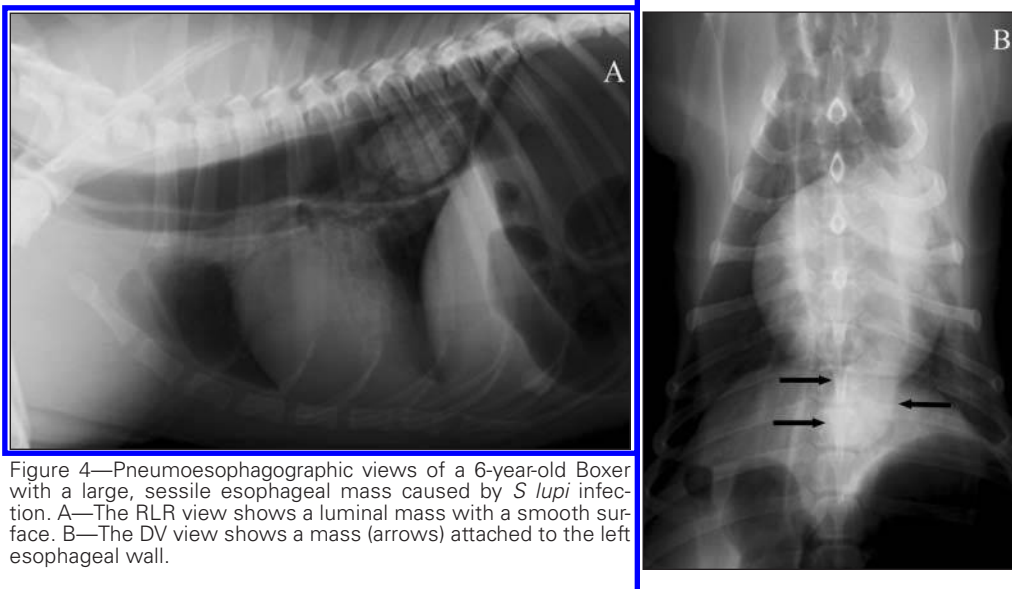


Figure 4—Pneumoesophagographic views of a 6-year-old Boxer with a large, sessile esophageal mass caused by *S lupi* infection. A—The RLR view shows a luminal mass with a smooth surface. B—The DV view shows a mass (arrows) attached to the left esophageal wall.

Table 2—Mean  $\pm$  SD length of apparent esophageal involvement of lesions identified via survey radiography, pneumoesophagography, and endoscopy in 30 dogs with *Spirocerca lupi* infection.

View	Length (mm)	P value*
RLR pneumoesophagography	68.0 $\pm$ 41.1	0.53
LLR pneumoesophagography	67.6 $\pm$ 37.8	0.73
DV pneumoesophagography	68.0 $\pm$ 37.8	0.22
VD pneumoesophagography	79.3 $\pm$ 31.1	0.19
RLR radiography†	59.7 $\pm$ 29.1	0.08
DV radiography†	69.4 $\pm$ 39.2	0.85
Endoscopy	64.5 $\pm$ 41.7	—

— = Not applicable.  
\*Represents comparison of indicated view measurements with endoscopic findings. †One dog had megaesophagus and the esophagus was not filled with air; therefore, the dog could not be evaluated.

Several dogs had various degrees of left lung lobe consolidation secondary to having been positioned in LLR for an extended period for endoscopy. This consolidation did not appear to affect evaluation of lateral pneumoesophagograms but did hamper interpretation of the DV and VD views by effacing the esophageal wall to some extent.

## Discussion

When dogs are screened for pulmonary disease, 2 orthogonal radiographs or 2 opposing lateral views are routinely obtained.<sup>5,7</sup> Veterinary clinicians need to be aware of the effect a chosen view can have on the radiographic visibility and location of healthy thoracic structures as well as thoracic lesions. We previously showed that DV and RLR survey thoracic views are best to define caudodorsal mediastinal masses and, in particular, those caused by spirocercosis.<sup>6</sup> However, small nodules or nodules located in the hilar region may be difficult to see on survey radiographs, and in these situations, pneumoesophagography is useful to detect pathological changes or to better define obvious caudal esophageal lesions.

Use of the silicone resuscitator inflation technique resulted in good distention of the esophagus, particularly on lateral views, which provided the contrast required to detect nodules, length of esophageal involvement, location, and surface characteristics. The technique also allowed an estimation of nodule size and number. In addition, gastric distention took place, allowing for evaluation of potential gastric pathological changes, including aberrant *S lupi* nodules. Such evaluation was important because up to 5% of *S lupi* nodules involve the cardia.<sup>18</sup> Right lateral recumbent pneumoesophagographic views allowed air to accumulate in the corpus and fundus of the stomach and away from the

pylorus, through which air would escape in LLR views, in which the pylorus would be uppermost. The RLR pneumoesophagograms therefore optimized visibility of the cardiac sphincter region, allowing greater accuracy in determining nodule location. The degree of gastric distention may still have been a result of the endoscopic procedure used in our study. However, after the study, when we performed pneumoesophagography in dogs without concurrent endoscopy, gastric filling with air usually still took place. In the absence of a resuscitator, the esophagus can be inflated by other means and the opening closed with a stopper.

Survey radiographs allowed most nodules to be seen on DV views as previously described,<sup>6</sup> whereas lateral views were better for nodule detection when pneumoesophagography was used. On lateral survey radiographs, minor esophageal pathological changes are masked by the overlying lung tissue, whereas on DV views, the bulge in the caudodorsal mediastinum is clearly outlined by the adjacent lungs, even in the presence of the vertebral column and sternum.<sup>6</sup> On lateral pneumoesophagograms, the walls of the air-filled esophagus were contrasted by the air within the esophagus and the surrounding pulmonary tissue, clearly outlining intraluminal, mural, and even extramural nodules. On DV and VD pneumoesophagograms, mass visibility was reduced because dorsal (47%) or ventral (33%) mass location was superimposed on the vertebral column and sternum, making masses poorly visible unless markedly enlarged. On survey radiographs, the esophageal wall was added to this soft tissue opacity, thus widening the apparent size of the mass, whereas in the pneumoesophagograms, the esophageal wall was displaced away from the mass by the introduced air. The decreased luminal filling seen on DV and VD pneumoesophagograms also contributed to less intraluminal contrast, and the superimposition of less aerated, atelectic lungs contributed to this as well. On the lateral views, any possible atelectic lung changes caused minimal interference.

The DV and VD pneumoesophagograms in the present study were useful for seeing the origins of nodules on the lateral esophageal wall, which in turn often had a luminal appearance on the RLR and LLR views (Figure 1). The high prevalence of dorsally located nodules was expected because *S lupi* larvae migrate from the aorta to the adjacent ventrally located esophagus. Most nodules appeared sessile. Dorsally or ventrally attached nodules, particularly smaller nodules, typically had only a luminal appearance on the DV and VD pneumoesophagograms. This information can aid surgeons in planning their surgical approach to the caudal portion of the esophagus, even though a left-sided thoracotomy is usually performed. In disease processes other than *S lupi* infection in which lesions may be more laterally located, DV and VD pneumoesophagographic views may be more useful than lateral views.

Pneumoesophagography allowed detection of multiple nodules on a single view in 4 dogs, but endoscopy revealed multiple nodules in 15 dogs. We did not attempt to determine whether nodule location was similar among the various pneumoesophagographic views, and multiple nodules were only counted when seen on a single view. Thus, a single nodule seen on each of

several pneumoesophagograms could have represented multiple individual nodules. Such an explanation could account for the poor sensitivity of pneumoesophagography for multiple nodule detection.

Performance of pneumoesophagography in dogs with spirocercosis would be highly useful for practitioners in endemic areas. Early nodule diagnosis can allow intervention before neoplastic transformation.<sup>14,17,19</sup> This imaging technique improves the ability to characterize nodules. In spirocercosis, all of the smaller, early, benign nodules are sessile and appear as a mound on the esophageal luminal wall. As neoplastic transformation occurs, the nodules proliferate into a more vegetative structure, which may have a broad-based attachment to the esophageal wall.<sup>14,17,19</sup> Lesions in 9 dogs in our study were confirmed to be malignant on the basis of results of histologic examination or absence of response to treatment. At least 1 pneumoesophagographic view revealed an irregular proliferative surface in 6 and a pedunculated mass in 2 of these 9 dogs. Many of the larger masses may have been pedunculated, but because they were lying closely adjacent to the wall because of the restricted esophageal space, they may have been mischaracterized. Sessile tumors necessitate greater resection of the esophageal wall, which has a negative effect on healing.<sup>19</sup> Knowledge that a mass is pedunculated is therefore useful in determining a surgical prognosis.

Several dogs in the present study had various degrees of consolidation in the left lung lobe that was secondary to the fact that dogs were in LLR for an extended period for the endoscopy. This consolidation did not appear to affect lateral pneumoesophagographic interpretation but did hinder interpretation of the DV and VD views to some extent. The order of procedures in the study was dictated in part by their order in the larger spirocercosis study<sup>15-17</sup> and could not be adapted. However, in a clinical situation, pneumoesophagography will be performed when endoscopy is not available. Dogs in that situation should consequently be positioned in sternal recumbency for anesthesia and only be placed in lateral recumbency immediately prior to imaging to avoid the impact of atelectasis on results. Theoretically, postendoscopic reflux could have affected the pneumoesophagographic findings in the study dogs, but because food had been withheld from them prior to imaging, the effect of this reflux would have been minimal and was not believed to affect interpretation.

The present study had several limitations. Performance of endoscopy immediately prior to pneumoesophagography resulted in pulmonary atelectasis in some dogs and prefilling of the stomach with gas. In addition, all dogs were known to have spirocercosis and no clinically normal dogs were included; as such, the specificity and predictive values of various imaging views could not be determined. However, the objective was to determine which views were most appropriate to detect masses in dogs with known disease, particularly during pneumoesophagography. Endoscopy is excellent for nodule detection and characterization<sup>14</sup> but only identifies the intraluminal esophageal portion of the nodule; therefore, the nodule size measurement might not be highly accurate. Computed tomography is a supe-

rior cross-sectional imaging technique for assessment of nodule characteristics, and future studies of the diagnostic accuracy of various radiographic techniques should involve computed tomography as the reference standard. However, pneumoesophagography allowed nodule characteristics, location, and mural and extramural nodule formation to be readily determined. Additionally, pneumoesophagography appears to be an easy, cost-effective, and safe additional initial diagnostic procedure for elucidating esophageal pathological changes, including pathological changes other than spirocercosis nodules. Given that there was no significant difference in pneumoesophagographic findings between LLR and RLR or DV and VD views, 1 lateral and 1 orthogonal view should be sufficient for diagnosing and characterizing pathological changes in the esophagus. However, additional views can be obtained to further define any identified lesions.

- a. Olympus GIF video endoscope, type XQ200, Tokyo, Japan.
- b. Fresenius Kabi Pty Ltd, Halfway House, Midrand, Gauteng, South Africa.
- c. Safeline Pharmaceuticals Pty Ltd, Roodepoort, Johannesburg, South Africa.
- d. AmbuSilicone Resuscitator, SSEM, Johannesburg, South Africa.
- e. Excel, Microsoft Corp, Redmond, Wash.
- f. SPSS, version 17, SPSS Inc, Chicago, Ill.

## References

1. Kirberger RM, Avner A. The effect of positioning on the appearance of selected cranial thoracic structures in the dog. *Vet Radiol Ultrasound* 2006;47:61–68.
2. Avner A, Kirberger RM. Effect of various thoracic radiographic projections on the appearance of selected thoracic viscera. *J Small Anim Pract* 2005;46:491–498.
3. Brinkman EL, Biller D, Armbrust L. The clinical usefulness of the ventrodorsal versus dorsoventral thoracic radiograph in dogs. *J Am Anim Hosp Assoc* 2006;42:440–449.
4. Thrall DE. The pleural space. In: Thrall DE, ed. *Textbook of veterinary diagnostic radiology*. 5th ed. Philadelphia: WB Saunders Co, 2007;555–567.
5. Lang JW, Wortman JA, Glickman LT, et al. Sensitivity of radiographic detection of lung metastases in the dog. *Vet Radiol* 1986;27:74–78.
6. Kirberger RM, Dvir E, van der Merwe LL. The effect of positioning on the radiographic appearance of caudodorsal mediastinal masses in the dog. *Vet Radiol Ultrasound* 2009;50:630–634.
7. Thrall DE. The mediastinum. In: Thrall DE, ed. *Textbook of veterinary diagnostic radiology*. 5th ed. Philadelphia: WB Saunders Co, 2007;541–554.
8. Baines E. The mediastinum. In: Schwarz T, Johnson V, eds. *BSAVA manual of canine and feline thoracic imaging*. Quedgeley, Gloucester, England: British Small Animal Veterinary Association, 2008;177–199.
9. Watrous BJ. Esophagus. In: Thrall DE, ed. *Textbook of veterinary diagnostic radiology*. 5th ed. Philadelphia: WB Saunders Co, 2007;495–509.
10. Ridgway RL, Suter PF. Clinical and radiographic signs in primary and metastatic esophageal neoplasms of the dog. *J Am Vet Med Assoc* 1979;174:700–704.
11. Dvir E, Kirberger RM, Malleczek D. Radiographic and computed tomographic changes and clinical presentation of spirocercosis in the dog. *Vet Radiol Ultrasound* 2001;42:119–129.
12. Dennis R, Kirberger RM, Barr FJ, et al. *Handbook of small animal radiology and ultrasound: techniques and differential diagnoses*. 2nd ed. London: Elsevier, 2010;210–219.
13. Fischetti AJ, Kovak J. Imaging diagnosis: azygous continuation of the caudal vena cava with and without portocaval shunting. *Vet Radiol Ultrasound* 2008;49:573–576.
14. van der Merwe LL, Kirberger RM, Clift S, et al. *Spirocerca lupi* infection in the dog: a review. *Vet J* 2008;176:294–309.
15. Dvir E, Clift SJ. Evaluation of selected growth factor expression in canine spirocercosis (*Spirocerca lupi*)-associated non-neoplastic nodules and sarcomas. *Vet Parasitol* 2010;174:257–266.
16. Dvir E, Clift SJ, Williams MC. Proposed histological progression of the *Spirocerca lupi*-induced oesophageal lesion in dogs. *Vet Parasitol* 2010;168:71–77.
17. Dvir E, Kirberger RM, Mukorera V, et al. Clinical differentiation between dogs with benign and malignant spirocercosis. *Vet Parasitol*. 2008;155:80–88.
18. Brodey RS, Thompson RG, Sayer PD, et al. *Spirocerca lupi* infection in dogs in Kenya. *Vet Parasitol* 1997;3:49–59.
19. Ranen E, Lavy E, Aizenberg I, et al. Spirocercosis-associated esophageal sarcomas in dogs. A retrospective study of 17 cases (1997–2003). *Vet Parasitol* 2004;119:209–221.