



Helminths in dogs belonging to people in a resource-limited urban community in Gauteng, South Africa

W.N. MINNAAR and R.C. KRECEK*

Department of Veterinary Tropical Diseases, Faculty of Veterinary Science, University of Pretoria Private Bag X04, Onderstepoort, 0110 South Africa

ABSTRACT

MINNAAR, W.N. & KRECEK, R.C. 2001. Helminths in dogs belonging to people in a resource-limited urban community in Gauteng, South Africa. *Onderstepoort Journal of Veterinary Research*, 68: 111–117

One hundred and sixty-four faecal samples, 148 adhesive tape swabs and 132 blood samples were collected from dogs in Boksburg, Gauteng, to assess the prevalence of helminth parasites in the area. Sixty-nine of these dogs were also necropsied and helminths recovered from the gastro-intestinal tracts.

Ancylostoma caninum was the most common helminth and was present in 88% of the dogs, followed by *Dipylidium caninum* in 39% of dogs, *Toxocara canis* in 36%, *Ancylostoma braziliense* in 20%, *Spirocerca lupi* in 14%, *Toxascaris leonina* in 9%, *Trichuris vulpis* in 6%, *Joyeuxiella pascualei* in 6% and *Taenia* spp. in 4%. Microfilariae of *Dipetalonema reconditum* were found in 2% of the blood samples. The results of this study extend the geographic distribution of *T. vulpis*

With the exception of *Spirocerca* and *Dipetalonema*, all these helminths are potentially zoonotic, and may pose a threat to community health.

Keywords: Community health, dogs, Gauteng, helminth prevalence, zoonotic

INTRODUCTION

Helminth parasites are important in dogs because of the disease they cause and their zoonotic potential for humans. Studies in southern Africa include necropsies performed in South Africa (Ortlepp 1934; Verster 1979) and faecal examination of samples collected in a public park in Zimbabwe (Mukaratirwa & Busayi 1995). However, we have no knowledge of the prevalence of helminths in dogs in resource-poor areas of South Africa.

The aim of this study was to determine the prevalence of helminth parasites in dogs from necropsies and from faecal samples from live and dead animals in a resource-poor area in Gauteng, South Africa.

Low-income informal settlements around business and older residential areas were selected mainly because dogs in these settlements are generally not treated for worms. Samples were collected from untreated animals and their owners interviewed. To assess the intensity of helminth infection in dogs and their zoonotic potential fresh biological samples were collected from both living and dead animals.

MATERIALS AND METHODS

The city of Boksburg (28°18'E, 26°12'S) is situated in Gauteng highveld, and has an annual rainfall of 700–750 mm and frosty winters (Fig. 1). This urban community with nearby low-income informal settlements was selected as the study area. The surrounding veld type is the central version of Bankenveld (Acocks 1975) with sour grass and sandy soil.

* Author to whom correspondence is to be directed

Accepted for publication 30 January 2001—Editor

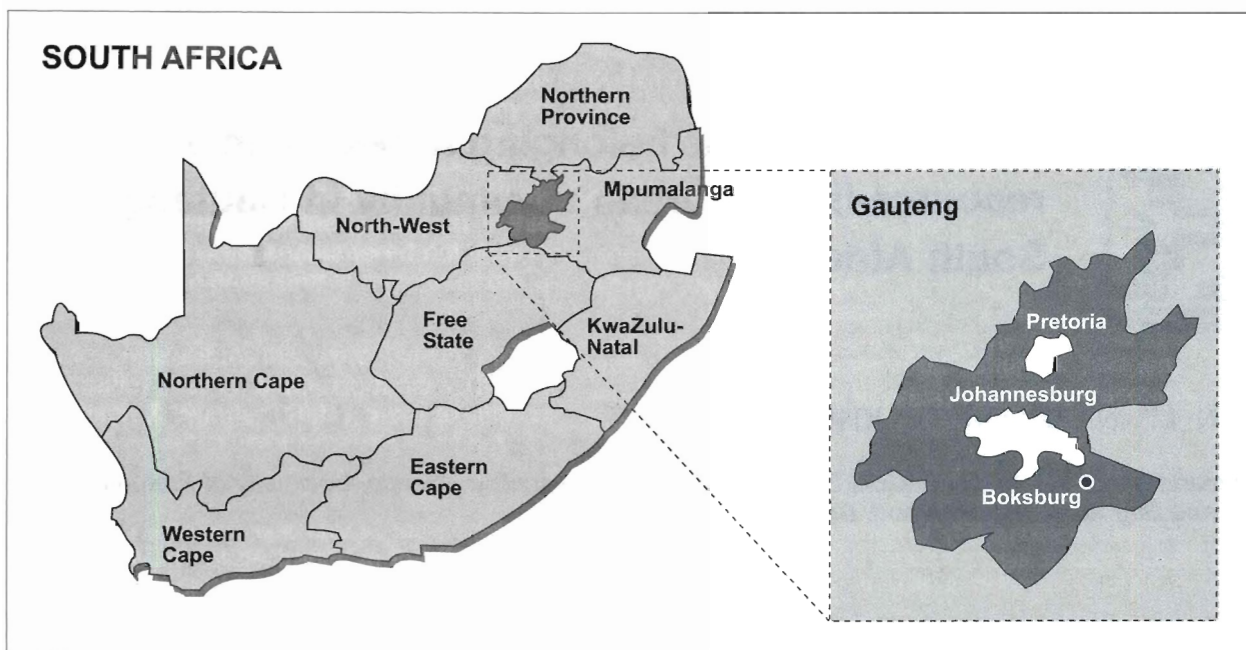


FIG. 1 Map showing the geographic locality of Boksburg in Gauteng, South Africa

The residents who were interviewed were mostly Zulu or Sotho speaking, but some also spoke Xitsonga, Xhosa and Setswana. These five languages are native official languages spoken in South Africa. Some were illegal immigrants from Zimbabwe and Mozambique. Many were unemployed, and their dogs were mainly kept for security reasons.

This investigation was a long-term cross-sectional study. A variety of sample types was collected periodically from live or dead dogs of various ages and breeds from 30 April 1997 to 27 May 1998. The following were collected from the dead and live animal: blood samples (Pratt 1985), adhesive tape swabs applied to perianal skin and hair (Deplazes & Eckert 1988) and faecal samples (Reinecke 1983; Sloss, Kemp & Zajac 1994). In addition, organ samples (Jacobs, Arakawa, Courtney, Gemmell, McCall, Myers & Vanparijs 1994) were collected from dogs that had been impounded and that were subsequently euthanased (Table 1). A total of 164 faecal samples, 132 blood samples, 148 adhesive tape swabs and 69 organ samples were collected.

Blood samples

Immediately after euthanasia cardiac blood was collected in bleeding tubes that contained ethylenediamine tetraacetic acid (EDTA) anticoagulant. Blood samples were collected from the superficial antebrachial vein of live animals while the animal was restrained. Each tube was marked and placed in a cooler box containing ice for transportation to the laboratory. The purpose of collecting blood samples

TABLE 1 Total number of samples collected from 130 live dogs and 69 dead dogs from Boksburg, Gauteng

Samples	Live dogs	Dead dogs
Blood samples	74	58
Adhesive tape swabs	113	35
Faecal samples	102	62
Organs	—	69

was twofold: to make and examine blood smears for haemoprotzoan parasites, and to detect and identify microfilariae in the blood.

In the laboratory two blood smears were made from each blood specimen on glass microscope slides—one thin, which was stained with Cam’s Quick Stain (Diff Quick) (Pratt 1985) and the other thick, which was stained by the Giemsa method. Both smear types were examined microscopically for haemoprotzoan parasites and filarial nematodes. In addition, all the samples were also screened for the detection of microfilariae, using the modified filter technique (Sloss *et al.* 1994), which employed transparent 3 µm-aperture polycarbonate filters. The blood was not haemolyzed with 2% formalin as is often routinely done prior to the filter step because this could interfere with the subsequent staining of the filters.

After filtration of a 0.5 ml volume of blood from each sample the filters were mounted on microscope slides, left to dry, and then stained with Giemsa stain.

If microfilariae were detected on a filter, another was prepared and mounted in the same manner and stained using the acid phosphatase staining technique (Balbo & Abate 1972) for identification of the microfilariae to species level.

Adhesive tape swabs

Adhesive tape swabs (Deplazes & Eckert 1988) were prepared to detect cestode eggs and/or segments, if present, on the peri-anal skin and hair of 35 of the euthanased dogs. In dead dogs, the anal sac sphincter muscles relax and, when the tail is lifted fluid is released from these sacs. This soils the adhesive tape, and prevents the cestode eggs from sticking to the surface of the slide. Consequently, many of these swabs were discarded. Collection of the swab samples from the perianal region of live dogs did not pose problems. This was performed by dabbing the perianal area of the restrained dog with the adhesive surface of ordinary clear stationery "sticky tape" (Sellotape®). It was then smoothed with the adhesive side down on a clean glass microscope slide, and examined in the laboratory under a light microscope using a 10X objective lens.

Faecal examination

Collection of faecal samples from the rectum of dead dogs generally took place during the evisceration procedure. A sample of about 1–2 g was collected from each dog and placed in a Faecalizer® well, which was marked with the dog's identification number, and preserved in an insulated box containing ice for transport to the laboratory.

For the collection of a faecal sample (Pratt 1985; Reinecke 1983) from the live restrained animal, an index finger of a latex-gloved hand lubricated with liquid paraffin was inserted into its anus. About 2 g of faeces was then scooped from the rectum, and marked and stored in the same manner as the samples obtained from the dead dogs.

Some discomfort was manifested by most of the live animals during the sampling process, which was aggravated if the dog was constipated (about a fourth of all cases); it proved impossible to collect faeces from these animals. In some there were no faeces present in the rectum because the dog had defecated shortly prior to the arrival of the team. However, if fresh faeces were found and there was only one dog on the premises, or if the sampling team or a member of the household had actually seen the dog defecating, a sample was collected from it.

The faecal flotation technique (Sloss *et al.* 1994) was used for the examination of the faeces for the presence of nematode and, possibly, cestode eggs. Identification of helminth eggs was done according to Thienpont, Rochette & Vanparijs (1979).

Organ samples

The heart and lungs of each dog necropsied were removed after the aorta and cranial and caudal vena cava had been ligated and bisected some distance from the heart. The cranial ends of the oesophagus and of the rectum were also tied off and the entire gastro-intestinal tract was removed from the carcass (Jacobs *et al.* 1994). These organs were transported in a cooler box containing ice packs to the laboratory where they were examined.

The heart and major blood vessels were opened to determine if mature *Dirofilaria immitis* were present. The lumens of the trachea and bronchi were exposed to investigate for the presence of *Filaroides osleri* infection. The gastro-intestinal tract of each animal was opened and its contents flushed out. The latter and mucosal scrapings were sieved through a 150 µm aperture sieve in two stages: the first being the stomach contents and mucosal scrapings, and the second, those of the intestine, colon and caecum. The material retained in the sieve was visually examined with the aid of a magnifying diamond sorting lamp. Any helminths present were collected and preserved in an aqueous solution of 70% alcohol, a solution containing equal volumes of 70% alcohol and 5% glycerine, or 10% formalin for subsequent identification, sexing and counting under a stereo- or light microscope under low magnification. The identification of helminths was done with the assistance of Reinecke (1983).

Representative samples of helminths samples were deposited in three museum collections. These are the United States National Parasite Collection of the United States Department of Agriculture (USDA), Maryland, USA (accession numbers 90494–90501); the Natural History Museum in London, UK (accession numbers 2000.7.26.1–53); and the National Collection of Animal Helminths at the Plant Protection Research Institute, Agricultural Research Council, Rietondale, South Africa (accession numbers 2351–2364).

RESULTS

The results of the blood sample analyses of 132 and the adhesive tape swabs of 148 of the live and dead dogs are summarized in Table 2, and total numbers and species of helminths recovered from the 69 necropsied dogs are recorded in Table 3. Fig. 2 reflects the results of the 164 faecal samples examined from the live or dead dogs, and the helminths recovered from 69 necropsied dogs are given in Fig. 3–6.

Two of the adhesive tape swabs from the three euthanased dogs from which *Taenia* spp. were recovered at necropsy contained taeniid eggs.

The only parasite identified in the blood smears was one positive identification of a *Babesia* sp. The smear

TABLE 2 Results of blood samples and adhesive tape swabs examined from live and dead dogs

Test	Number (n)	Number positive	%
Blood smears thin (Diff Quick)	132	1 (<i>Babesia canis</i>)	0.8
Blood smears thick (Giemsa)	132	0	0.0
Blood filters	132	3 <i>Dipetalonema reconditum</i>	2.3
Adhesive tape swabs	150	3 <i>Dipylidium caninum</i>	2.0
		3 <i>Taenia</i> spp.	2.0
		2 <i>Toxocara canis</i>	1.4

TABLE 3 Helminth species recovered from 69 necropsy examinations of dogs in Boksburg, Gauteng

	Prevalence (%)	Range	Mean
Nematodes			
<i>Ancylostoma caninum</i>	88.4	1–1 600	76.1
<i>Ancylostoma braziliense</i>	20.3	1–43	10.3
<i>Toxocara canis</i>	36.2	1–90	18.0
<i>Toxascaris leonina</i>	8.7	1–19	8.0
<i>Spirocerca lupi</i>	14.5	1–143	25.3
<i>Trichuris vulpis</i>	5.8	1–8	3.8
Cestodes			
<i>Dipylidium caninum</i>	39.1	1–288	35.5
<i>Joyeuxiella</i> sp.	5.8	1–96	43.5
<i>Taenia</i> spp.	4.3	1	1.0

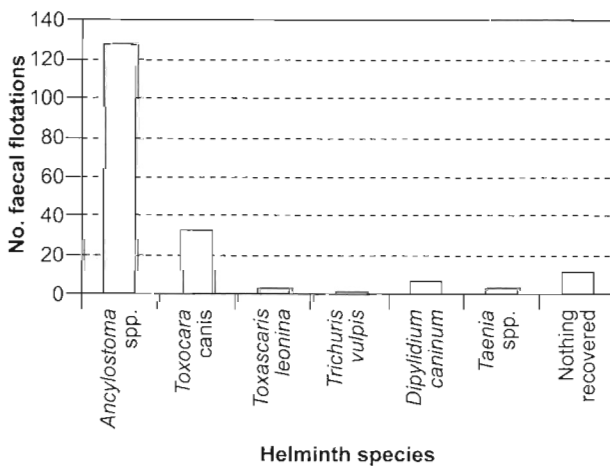


FIG. 2 Helminth parasite species identified in faecal flotations of dogs (n = 164) from Boksburg

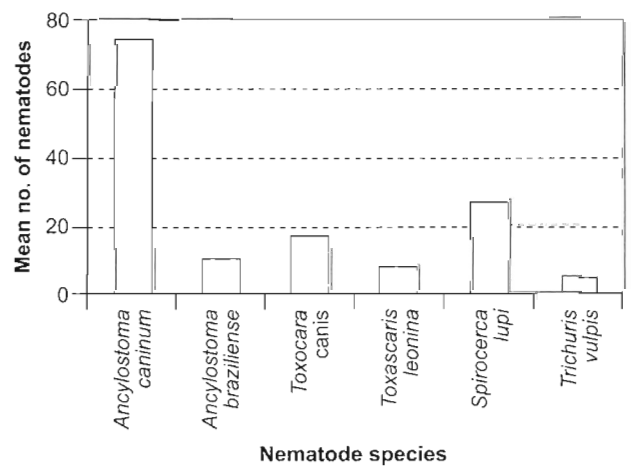


FIG. 3 Mean number of nematodes recovered per infected dog necropsied in Boksburg

was made from the blood of a severely icteric dog that was necropsied. Babesiosis had not been diagnosed before it was euthanased. Using the filter technique, and subsequently staining with the acid phosphatase method, three blood samples also containing microfilariae of *Dipetalonema reconditum* were detected.

Of the total of 164 faecal flotation tests performed, 77.3% contained *Ancylostoma* spp. eggs. The results of the faecal flotation tests done on 61 of the

euthanased dogs were compared with the species of helminths actually recovered from the intestines. *Ancylostoma* spp. eggs were detected in 42 of the dogs while the parasite itself was found in 55 of them.

In this study area, 97% of all *Ancylostoma* spp. recovered from the 61 necropsied dogs, i.e. a total of 4 642 hookworms, were *Ancylostoma caninum*. There was a higher tendency of infection with *A. caninum* in mastiff-type breeds compared to all other dog breeds ($P = 0.0001$), and in terrier breeds com-

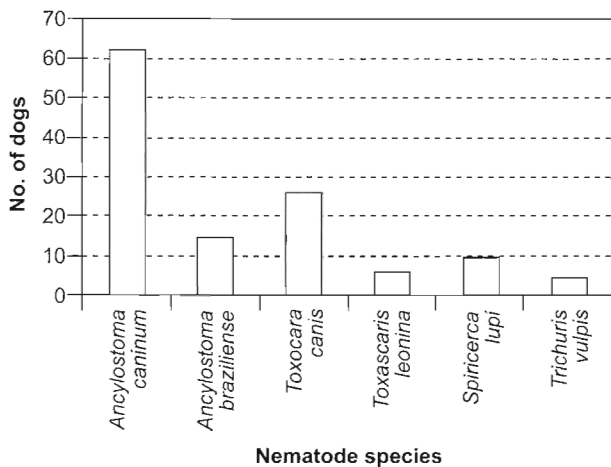


FIG. 4 Nematode species identified and number of dogs infected ($n = 69$) in Boksburg

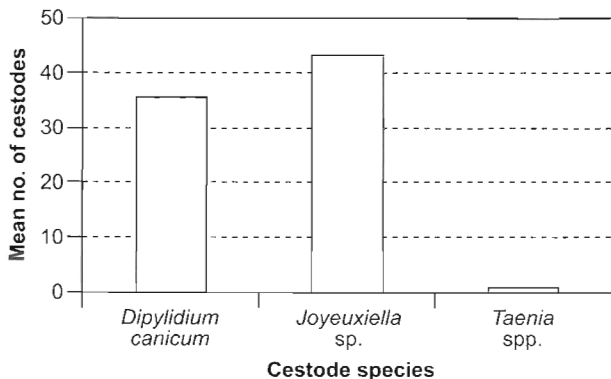


FIG. 5 Mean number of cestodes recovered per infected dog necropsied in Boksburg

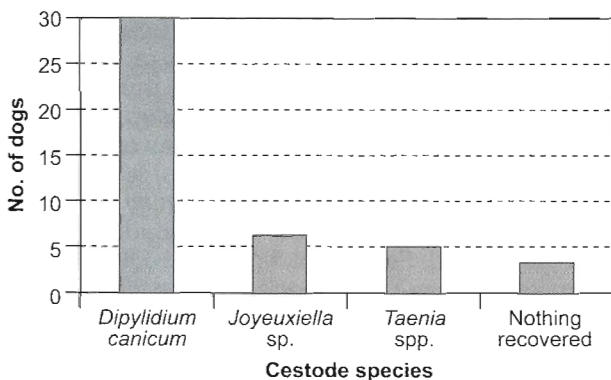


FIG. 6 Number of dogs from which cestodes were recovered ($n = 69$) in Boksburg

pared to breed types of sheepdogs, retrievers, toy dogs and crossbreeds ($P = 0.0001$ throughout) in this study.

As recorded by Jacobs (1994) and Woodruff (1975), there was a significant increase in infection with *T.*

canis in the pup age group ($P = 0.0001$) compared to adult dogs.

In this survey area, ten of the 69 necropsied dogs were found to be infected with *Spirocerca lupi*. One of them harboured 143 adult worms embedded in numerous granulomas in the wall of the oesophagus.

Dipylidium caninum was by far the most common cestode and its occurrence was only second to *A. caninum*. Twenty-seven dogs were hosts to this tapeworm and 288 scoleces were recovered from one dog. Infection with *D. caninum* tended to be more common in the summer months ($P = 0.0233$) than during winter. The level of infection with *Joyeuxiella* sp. was only one-seventh that of *D. caninum*, with four dogs being infected.

DISCUSSION

Ancylostoma caninum was the most common helminth encountered. Differentiation between the eggs of *A. caninum* and *Ancylostoma braziliense* microscopically is not possible with the faecal flotation technique. Therefore diagnosis of hookworm was done to genus level only in the live animal.

The number of eggs found on flotation only reflects the population of patent *Ancylostoma* spp. females present. The number of eggs produced by each female per day also varies as the duration of the nematode infection progresses, or as immunity develops (Miller 1967). The presence of immature stages and the male:female ratio of *A. caninum* also influences the egg yield per gram of faeces. *A. braziliense* females also produce fewer eggs per day than do *A. caninum*. It is still uncertain as to what extent concurrent infection with other species of nematodes and environmental factors, such as limited (dog) freedom, re-infection rate, nutrition and clinical disease will have on the faecal egg count. The fact that *Ancylostoma* spp. could only be diagnosed in 76% of the infected dogs suggests the flotation technique may be inefficient for its diagnosis.

One animal had an *Ancylostoma* spp. positive faecal sample, but no hookworms were recovered from it during necropsy. The same phenomenon was experienced with three faecal samples positive for *T. canis* eggs.

The high prevalence of *A. caninum* infection at the levels encountered in the Boksburg area is a cause for concern. Only a few owners were aware of the possibility of their dogs harbouring internal parasites and, although some do treat their dogs against worms, the treatment does not seem to make a difference to the levels of parasitism encountered.

Although *A. braziliense* was less common in the dogs (14 of the 61 infected with *Ancylostoma* spp.), its

mere presence in the community is significant. It does not cause anaemia to the same extent and severity as *A. caninum* (Miller 1966), but it is well known as a zoonosis that may cause cutaneous larva migrans in humans. The occurrence of larval migration in humans could unfortunately not be determined in the area under review, as there was no access to medical records.

Results from two previous studies (Ortlepp 1934; Verster 1979) indicated a prevalence of *Ancylostoma* spp. of 20% and 69%, respectively, in the Pretoria vicinity. The prevalence of 90%, 83% and 93% in three other study areas (the former two elsewhere in Gauteng and the latter in NorthWest Province) (Minnaar, Krecek & Rajput 1999) and 88% indicated during this study, suggests that canine hookworm as a cause of verminosis in dogs, and as a potential cause of cutaneous larva migrans in humans may be more important than previously thought.

Fifteen (i.e. more than three-fifths) dogs were infected with gravid females of *T. canis*. Such worms are a source of infection in the home environment. This zoonotic parasite also poses a threat to public health.

The data obtained in this study also supports the hypothesis that *T. canis* favours pups or immature dogs, bitches in late pregnancy and lactating bitches (Woodruff 1975; Reinecke 1983). Of the 25 dogs infected with *T. canis*, 17 were pups, two were sub-adults, two were lactating bitches, and only four were adults. The reason why these four adult dogs had toxocarosis is uncertain, but may be related to sub-clinical or recent recovery from disease, nutritional deficiencies, stress-related reduction of immunity or high levels of infective stages of *T. canis* in the environment. Many dogs in such communities are fed only maize porridge, and a lack of protein may undermine the efficiency of the immune system (Roitt 1997). The number of worms recovered from the adult dogs was low, two to four on average, except for one dog that had ten adult *T. canis* males in its small intestine.

Ortlepp (1934) and Verster (1979) reported a *T. canis* incidence of 32% and 44% in the Pretoria area, respectively. This is in agreement with the findings of a prevalence of 36% in the present study. Woodruff (1975) reported an incidence of *T. canis* in 20.7% of dogs in southern England, and found eggs of the parasite in 24.4% of soil samples in the same areas. He reported that, although most human cases were asymptomatic, 2.1% of the human population were found to be serologically positive, and were at risk of developing symptoms. The findings of higher prevalence in the local studies reported here suggest the presence of a greater number of more infective stage *T. canis* eggs in the environment and a potentially higher infection rate in the human hosts. As

many cases of visceral larva migrans remain undiagnosed (Woodruff 1975), this implies that the impact of this parasite on the local workforce may be considerable.

Interestingly, *T. canis* eggs were found on two of the adhesive tape swabs. It is felt that this should, none-the-less, be regarded as an incidental finding; faecal flotation is a much more sensitive test compared to the adhesive tape swab test to demonstrate the presence of nematode eggs.

Three flotation tests showed the presence of *T. canis* eggs, but no *T. canis* worms were recovered from the intestines of the animals from which the faecal samples originated. The reason for these results is possibly that nematode eggs, and not infective larvae had been ingested, the eggs, not being infective, passing harmlessly through the intestinal tract without further development.

The prevalence of *Toxascaris leonina* in the survey area was considerably lower than that of *T. canis*, only six dogs being infected. The most recovered were 19 from an apparently healthy dog. Another animal had 16 adult *T. leonina* in the small intestine, and its immunity was clearly compromised as it was also suffering from parvoviral enteritis. The other infected dogs carried an average of just more than three worms each. Although older dogs tend to be more often infected (Reinecke 1983), no age trend was found regarding infection with *T. leonina* in this study.

Spirocerca lupi is a nematode of which the importance is greatly underestimated for both its prevalence and pathogenicity. It is usually diagnosed in live dogs only when oesophageal granulomas cause physical obstruction to the passage of food, or when secondary osteosarcomas develop (Evans 1983). On diagnosis, the condition is invariably far advanced (Deplazes & Eckert 1988), and the prognosis is guarded. Some cases are misdiagnosed, as opacity of oesophageal or aortic granulomas only shows up in radiographs after calcification of lesions has taken place. Oesophageal endoscopy may reveal the presence of granulomas, but this procedure is seldom performed. Faecal flotation and sedimentation techniques are not very effective for the diagnosis of *S. lupi* infection as eggs are not passed unless an oesophageal granuloma has acquired an opening into the lumen and patent females are present to produce eggs. In this survey several faecal sedimentation tests (Markovics & Medinski 1996) were performed without a single *Spirocerca* egg being demonstrated. Many dogs probably die from old age or other causes while being asymptomatic hosts to this parasite, without the owner ever knowing.

Trichuris vulpis is not regarded as important in South Africa. Reinecke (1983) mentions that, to his knowledge, *T. vulpis* is only known to occur in Durban. This

study shows that *T. vulpis* also occurs in the Boksburg area.

The presence of *D. caninum* in the dogs suggests that the owners were not implementing effective flea control. Humans, especially small children, can be infected if an infected flea is swallowed. Although the intermediate host, the common dog flea, *Ctenocephalides canis*, was not present on all the dogs infected, one can assume that only a few fleas are necessary to maintain the life cycle of this cestode. In a low-income community such as this, unawareness and inability to control these parasites because of a lack of resources may support the build-up of parasites and the continuation of the life cycle of *D. caninum*. Only one swab of the 27 dogs positive for *D. caninum* at necropsy revealed the presence of its eggs, which suggests that diagnosis of this species by this method is ineffective.

Future studies are needed to improve the methods currently used for the diagnosis of helminth parasites in live dogs and cats. For a lack of a reliable method, the diagnosis of *D. caninum* in dogs and cats is mainly dependent on reports from pet owners, rather than observations in the clinic, or faecal flotations. There is also a need for a simple, sensitive and affordable technique to diagnose *S. lupi* in the live animal. Workers should also address the actual zoonotic impact that helminths of dogs have on man.

ACKNOWLEDGEMENTS

The authors thank the Department of Veterinary Tropical Diseases of the University of Pretoria, the National Research Foundation and Bayer Animal Health for financial support. Thanks are also due to Messrs H.M. Boshoff, S.A. Milne, S. Mangera and R. Morobane for their technical support; M. van der Linde and H.T. Groeneveld for statistical analysis; R. Serfontein for typing and Prof. R.C. Tustin for constructive comments on this manuscript as well as helpful comments from the referees.

REFERENCES

- ACOCKS, J.P.H., 1975. *Veld types of South Africa*, 2nd ed. [Pretoria:] Botanical Research Institute, Department of Agricultural Technical Services, RSA (Memoirs of the botanical survey of South Africa, no. 40).
- BALBO, T. & ABATE, O. 1972. Histochemical differentiation of microfilariae of *Dirofilaria immitis*, *Dirofilaria repens* and *Dipetalonema* sp. *Parassitologia*, 14:239–247.
- DEPLAZES, P. & ECKERT, J. 1988. Untersuchungen zur Infektion des Hundes mit *Taenia hydatigena*. *Schweizer Archiv für Tierheilkunde*, 130:289–306.
- EVANS, L.B. 1983. Clinical diagnosis of *Spirocerca lupi* infestation in dogs. *Journal of the South African Veterinary Association*, 54:189–191.
- JACOBS, D.E., ARAKAWA, A., COURTNEY, C.H., GEMMELL, M.A., MCCALL, J.W., MYERS, G.H. & VANPARIJS, O. 1994. World Association for the Advancement of Veterinary Parasitology (W.A.A.V.P.) guidelines for evaluating the efficacy of anthelmintics for dogs and cats. *Veterinary Parasitology*, 52:179–202.
- MARKOVICS, A. & MEDINSKI, B., 1996. Improved diagnosis of low intensity *Spirocerca lupi* infection by the sugar flotation method. *Journal of Veterinary Diagnostic Investigation*, 8:400–401.
- MILLER, T.A. 1966. Blood loss during hookworm infection, determined by erythrocyte labeling with radioactive chromium. II. Pathogenesis of *Ancylostoma braziliense* infection in dogs and cats. *Journal of Parasitology*, 52:856–865.
- MILLER, T.A. 1967. Immunity of dogs to *Ancylostoma braziliense* infection following vaccination with X-irradiated *Ancylostoma caninum* larvae. *Journal of the American Veterinary Medical Association*, 150:508–515.
- MINNAAR, W.N., KRECEK, R.C. & RAJPUT, J.I. 1999. Helminth parasites of dogs from two resource-limited communities in South Africa. *Journal of the South African Veterinary Association*, 70:90–91.
- MUKARATIRWA, S. & BUSAYI R. M. 1995. A survey of patent gastrointestinal parasites of stray dogs in Bulawayo urban area. *Zimbabwe Veterinary Journal*, 26:19–27.
- ORTLEPP, R.J. 1934. *Echinococcus* in dogs from Pretoria and vicinity. *Onderstepoort Journal of Veterinary Science and Animal Industry*, 3:97–108.
- PRATT, P.W. 1985. Laboratory procedures for animal health technicians, 1st ed. Goleta, USA: America Veterinary Publications Inc.
- REINECKE, R.K. 1983. Veterinary helminthology. Durban, South Africa: Butterworth Publishers (Pty) Ltd.
- ROITT, I.M. 1997. *Roitt's essential immunology*. Oxford, London, UK: Blackwell Science Ltd.
- SLOSS, M.W., KEMP, R.L. & ZAJAC, A.M. 1994. *Veterinary clinical parasitology*, 6th ed. Ames, Iowa, USA: Iowa State University Press.
- THIENPONT, D., ROCHETTE, F. & VANPARIJS, O.F.J. 1979. *Diagnosing helminthiasis through coprological examination*. Beerse, Belgium: Janssen Research Foundation.
- VERSTER, A. 1979. Gastro-intestinal helminths of domestic dogs in the Republic of South Africa. *Onderstepoort Journal of Veterinary Research*, 46:79–82.
- WOODRUFF, A.W. 1975. *Toxocara canis* and other nematodes transmitted from dogs to man. *British Veterinary Journal*, 131:627–632.