

Common paediatric renal conditions

Few children in South Africa have access to dialysis or renal transplantation, so it is important to recognise kidney disease early enough to prevent progression to end-stage disease.

Gertruida van Biljon, MB ChB, MMed(Paed), FCP (Paed) SA, Cert Paediatric Nephrology

Professor and Senior Consultant, Department of Paediatrics, Faculty of Health Sciences, University of Pretoria

Gertruida van Biljon is a full-time senior consultant in the Department of Paediatrics and Head of the Paediatric Nephrology Unit at Steve Biko Academic Hospital. The Paediatric Renal unit is an accredited paediatric nephrology training unit. Professor Van Biljon has a special interest in the treatment interventions in children with chronic kidney disease, hypertension and nephrotic syndrome.

Correspondence to: Gertruida van Biljon (ida.vanbiljon@up.ac.za)

Chronic kidney disease (CKD) is not a priority on the health agenda in South Africa, and this is particularly true with regard to children. Infectious diseases like HIV and tuberculosis, respiratory diseases, malnutrition and trauma enjoy a far more prominent status as an attention-worthy cause of morbidity and mortality. The reality is that very few children with end-stage renal failure will have access to dialysis or renal transplantation. It is imperative, therefore, that all health care professionals should be vigilant in identifying children with underlying kidney disease and institute preventive treatment to slow progression of disease towards end-stage renal failure.

Paediatric kidney diseases that clinicians are likely to come across in clinical practice include several of the common congenital abnormalities of the kidney and urinary tract (CAKUT) and acute acquired disorders presenting with oedema and or hypertension, and positive urine findings.

Common congenital abnormalities of the kidney and urinary tract (CAKUT)

The routine use of antenatal sonar has allowed *in utero* diagnosis of underlying CAKUT before clinical presentation. Early diagnosis and appropriate management can prevent development of complications in many of these patients. The most commonly diagnosed CAKUT include a multicystic dysplastic kidney (MCDK), vesico-ureteric reflux (VUR) and obstructive uropathy due to posterior urethral valves (PUV) or pelvo-ureteric junction obstruction (PUJO).

Multicystic dysplastic kidney (MCDK)

A MCDK is estimated to occur in approximately 1 in 4 000 live births.¹ In most cases it is discovered by routine antenatal sonar, which demonstrates a kidney with multiple cysts of varying sizes. The ureter is atretic and the kidney is non-functional. A MCDK is usually accompanied by both compensatory hypertrophy and function of the opposite kidney. Bilateral MCDKs are incompatible with extrauterine life.

The reality is that very few children with end-stage renal failure will have access to dialysis or renal transplantation.

Infants with a MCDK are usually asymptomatic. It is rarely associated with hypertension, while in other cases it is discovered when a work-up is done for an infant with an abdominal mass. A MCDK usually involutes with time. If the diagnosis is not made by antenatal sonar, the patient may at a later stage be thought to have 'unilateral renal agenesis'.

Special investigations to exclude associated abnormalities in the contralateral kidney, like hypodysplasia, PUJO or VUR are necessary because they occur in 30 - 51% of patients with a MCDK.² There is no evidence that a MCDK is associated with a risk of malignancy.³ All patients with a solitary functioning kidney should be followed up

indefinitely as they may have subclinical evidence of defects in the solitary kidney and have an increased risk of developing hypertension and proteinuria later in life.⁴

Posterior urethral valves (PUV) (also known as congenital obstructing posterior urethral membrane (COPUM))

PUV is the most common cause of severe obstructive uropathy in children, affecting 1 in 5 000 - 8 000 boys.⁵ It is rarely seen in girls.

PUV are of unclear origin. They are thought to be caused by abnormal insertion of the mesonephric ducts into the cloaca in the place of the normal plicae colliculi, which cause varying degrees of obstruction.⁶

Affected boys with PUV are usually discovered prenatally when maternal ultrasonography reveals bilateral hydronephrosis, a distended bladder which empties poorly and, if obstruction is severe, oligohydramnios. Features of renal dysplasia, including cystic changes in the kidneys, are often present.

The morbidity and mortality associated with PUV depends on the severity of the obstruction and the time of onset during foetal development. Detection of PUV before 24 weeks' gestation identifies a high-risk group with a 50% mortality risk. Pulmonary hypoplasia caused by oligohydramnios is the most common cause of death in the first few hours after birth, while renal dysplasia, which is a consequence of the high urinary

Paediatric renal conditions

tract pressures, results in irreversible chronic renal failure.

Prenatal bladder decompression by vesico-amniotic shunt placement has been attempted, but evidence of clinical benefit is lacking.⁷

Infants with a MCDK are usually asymptomatic.

Spontaneous decompression of the urinary tract following the development of unilateral VUR may act as a pressure vent – which leads to ipsilateral renal dysplasia but allows development of better renal function in the contralateral kidney (VURD syndrome).⁸

Clinical features of PUV

Neonates may present with:

- Potter facies (see Fig. 1)
- acute respiratory distress and spontaneous pneumothorax
- clubbed feet and contractures of the hips
- urinary ascites
- acute renal failure – often associated with gram-negative septicaemia
- prolonged jaundice due to urinary tract infection (UTI), usually *E. coli*.

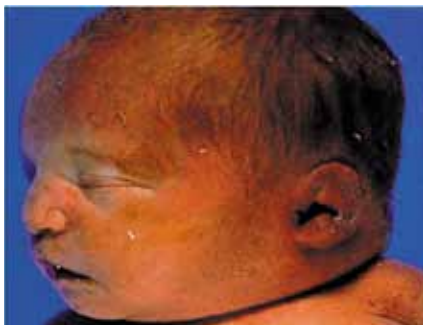

Fig. 1. Infant with Potter facies. Note the flat facial profile, beaked nose, small chin and low-set ears.

Those with less severe bladder obstruction present later in infancy with:

- failure to thrive or stunting
- polyuria
- spontaneous unexplained dehydration
- recurring UTIs
- poor urine stream (dribbling of urine)
- chronic renal failure.

Obstructive uropathy may also form part of a syndrome, the Eagle-Barrett syndrome,

sometimes called 'prune belly syndrome' (Fig. 2). It is characterised by a triad of

- deficient abdominal musculature
- megacystis and megaureter
- cryptorchidism (undescended testes).

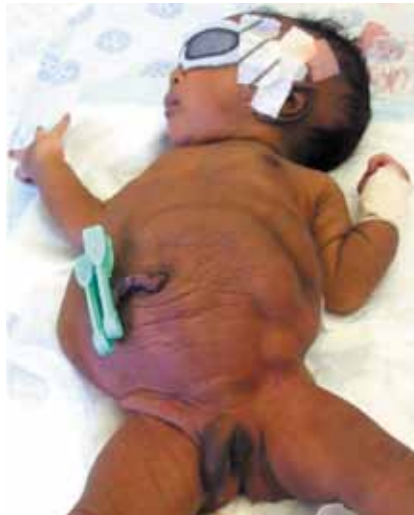

Fig 2(a). Infant with prune belly syndrome showing wrinkled skin of the abdominal wall.

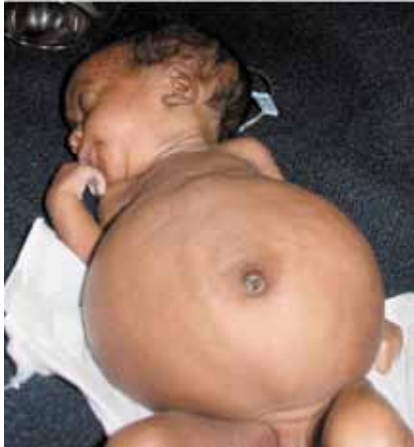

Fig. 2(b) Infant with prune belly syndrome showing severely distended abdomen due to urinary ascites.

Special investigations to exclude associated abnormalities in the contralateral kidney, like hypodysplasia, PUJO or VUR are necessary because they occur in 30 - 51% of patients with a MCDK.

The skin of the anterior abdominal wall is wrinkled, thin and lax, which accounts for the prune-like appearance and the name of the syndrome. The ureters are dilated and tortuous. Variable degrees of renal dysplasia occur, ranging from severe dysplasia to mild cystic dysplasia. The bladder is enlarged and the prostatic urethra is dilated. Urethral obstruction is an associated finding reported in 0 - 100% of patients.

The diagnosis of PUV is confirmed by a voiding cysto-urethrogram (VCU) (Figs 3a and 3b).

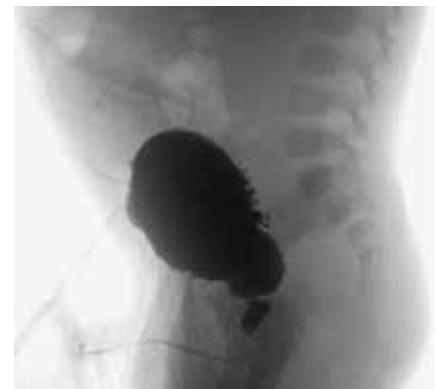

Fig. 3(a). VCU lateral view demonstrating posterior urethral valves, a trabeculated bladder with diverticulae and a dilated posterior urethra.

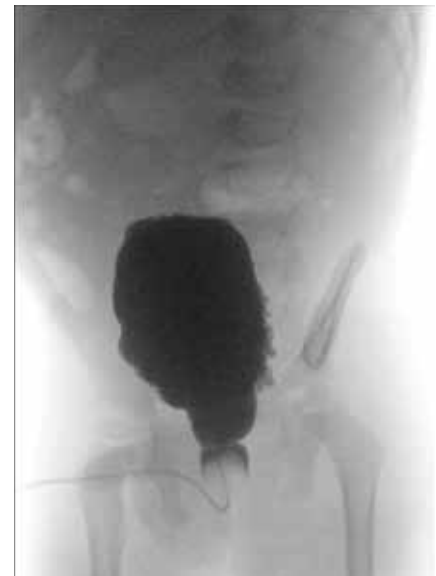

Fig. 3(b). VCU anterior-posterior view demonstrating posterior urethral valves, a trabeculated bladder with diverticulae and a dilated posterior urethra.

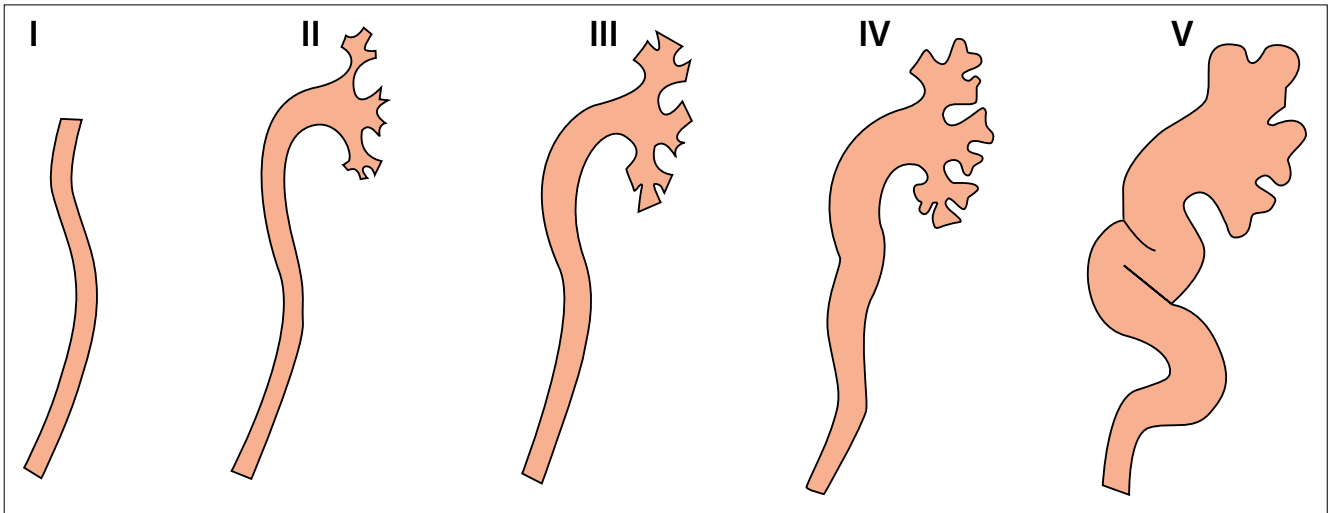


Fig. 4. International classification system of vesico-ureteric reflux.

Management of patients with PUV

- Neonates with PUV who have acute respiratory distress may benefit from ventilatory support, but the majority die due to pulmonary hypoplasia.
- Temporary drainage of the bladder can be achieved with a suprapubic bladder catheter until valve ablation can be done at a later stage when the infant is stable.
- Follow-up ultrasonography should be done to monitor improvement of hydronephrosis. Improving hydronephrosis without corresponding decline of serum creatinine suggests that severe renal dysplasia is present.
- Cutaneous vesicostomy is sometimes performed for those infants with advanced renal failure, but it does not offer any advantage over primary valve ablation when comparing preservation of renal function.
- After drainage of the bladder urine output should be monitored closely. Post-obstructive diuresis is common. Parenteral fluid and electrolyte replacement is usually necessary until the polyuria resolves.

Vesico-ureteric reflux (VUR)

VUR is a condition where urine refluxes in a retrograde direction from the bladder into the ureters and kidneys. It is graded according to an international classification system (Fig. 4). Grade III or more VUR is associated with dilatation of the urinary tract which may be discovered with antenatal ultrasonography. In most other

cases VUR is only discovered when special investigations are done following a UTI in a child.

In most instances, VUR is an inherited abnormality that resolves over time. The rate of resolution depends on several variables, including the age of the patient at presentation and the grade of reflux. Lower degrees of VUR are associated with high spontaneous resolution rate as the child grows older.

PUV is the most common cause of severe obstructive uropathy in children, affecting 1 in 5 000 - 8 000 boys. It is rarely seen in girls.

The main clinical problem associated with VUR is recurring febrile UTIs. General facts on VUR and UTIs:

- Regardless of VUR status, patients who have recurrent UTIs are susceptible to infection because they have alterations in the urothelium of the bladder that enhance bacterial attachment.⁹
- Ureteric reimplantation does not eliminate the risk of febrile UTIs.
- Prophylactic antibiotic treatment also does not solve this problem. In addition the chronic administration of antibiotics increases the risk of a UTI with a resistant bacterium.

- The potential benefit of prophylactic antibiotics in children with grades IV and V VUR associated with renal impairment is currently being investigated.¹⁰
- In children with VUR who develop fever, empiric antibiotic treatment should be started promptly after sterile urine culture has been done and before the results of culture and sensitivity are available.
- Early and effective antibiotic treatment has been shown to be the main preventive strategy to limit the risk for development of a new renal scar.
- There is no conclusive evidence that ureteric reimplantation improves the long-term outcome of children with VUR compared with conservative treatment.
- Surgical intervention is a treatment option for children with grade III or more VUR who experience recurrent febrile UTIs.¹¹
- Patients who were successfully operated on for grades IV and V VUR may redevelop VUR 3 - 5 years later.¹²
- The most likely cause for the development of chronic kidney disease and end-stage renal failure in children with reflux nephropathy is abnormal *in utero* kidney development.¹³

Pelvo-ureteric junction obstruction (PUJO)

PUJO is usually discovered with antenatal sonar investigation which shows a unilateral dilated renal pelvis, varying degrees of calycectasis and no demonstrable ureter on that side. In rare and extreme cases where there is bilateral PUJO, complete obstruction

Paediatric renal conditions

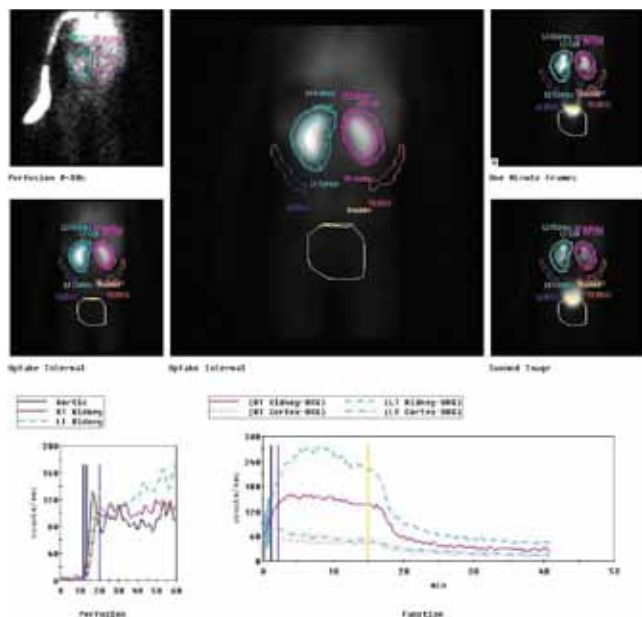


Fig. 5(a). MAG3 scan demonstrating dilated non-obstructed collecting systems bilaterally with differential renal function right 47% and left 53%.

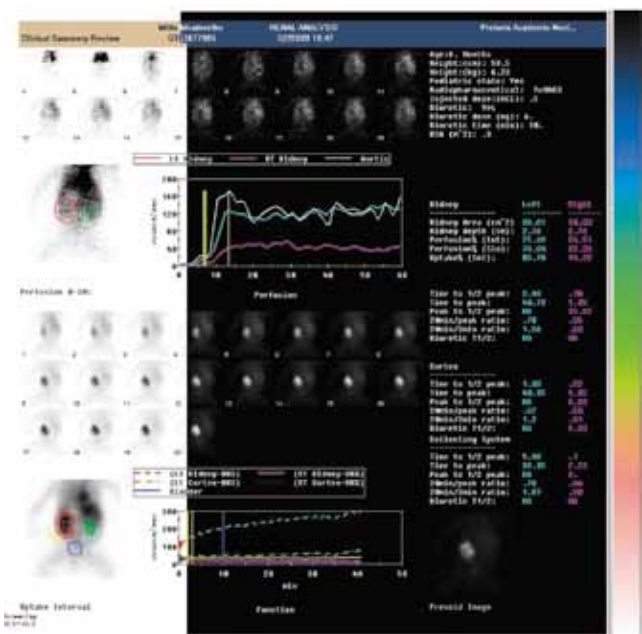


Fig. 5(b) MAG3 scan demonstrating a non-functional right kidney and a dilated obstructed collecting system on the left side (left PUJO). Differential renal function right kidney 0% and left kidney 100%.

leads to an empty bladder with consequent oligohydramnios and development of Potter sequence.

Unilateral PUJO may remain undiagnosed if it is not discovered by antenatal sonar investigation. In such cases the diagnosis is only made when a complication develops, like UTI, or when complete obstruction develops in a patient with a solitary functioning

kidney. Manifestations of unilateral PUJO include abdominal pain, vomiting, fullness in the flank, poor growth and hypertension.

In most instances, VUR is an inherited abnormality that resolves over time.

Management of infants with unilateral PUJO is based on the presence of clinical signs, supported by ultrasound and radio-isotope investigations. Infants with PUJO who remain asymptomatic, who are growing well, who have a normal blood pressure and stable renal function on imaging studies are managed conservatively.

Indications for referral to a paediatric urologist for possible pyeloplasty are:

- symptomatic patients
- bilateral PUJO
- anterior-posterior diameter of the renal pelvis >1.5 cm
- split renal function <40% on renography
- decreasing split renal function.

Split renal function is determined by radio-isotope DTPA renogram or MAG3 scan, which demonstrates uptake and clearance of the isotope of the individual kidneys (Figs 5(a) and (b)). Overall total function for a patient is 100% and the contribution of each kidney's function relative to the total renal function is calculated with an isotope camera. Normally the relative function of the two kidneys does not differ with more than 10%.

Example of PUJO: If the relative function of the obstructed kidney is 45% (and that of the other kidney 55%) on initial evaluation, but with follow-up it changes to 35%, the child should be referred for possible pyeloplasty.

References available at www.cmej.org.za

IN A NUTSHELL

- The routine use of antenatal sonar has allowed *in utero* diagnosis of underlying CAKUT.
- Early diagnosis and appropriate management can prevent development of complications in many infants with CAKUT.
- Oligohydramnios is most commonly the consequence of CAKUT.
- Associated abnormalities in the contralateral kidney occur in 30 - 51% of patients with a MCDK.
- Posterior urethral valves (PUV) is the most common cause of obstructive uropathy in children.
- Detection of PUV before 24 weeks' gestation identifies a high-risk group with a 50% mortality risk.
- Children who have recurrent urinary tract infections (UTIs) have alterations of their bladder urothelium that enhance bacterial attachment.
- Neither ureteric reimplantation nor prophylactic antibiotic treatment eliminates the risk of recurring febrile UTIs.
- Ureteric reimplantation does not improve the long-term outcome of children with VUR compared with conservative treatment.