

The Changing Coagulation Profile of Females: can Ultrastructure of Fibrin Teach Us Something?

Etheresia Pretorius

Affiliation: Department of Anatomy, School of Medicine, Faculty of Health Sciences, University of Pretoria, Pretoria, South Africa

ABSTRACT

Estrogen plays an important role during the life of a healthy female and impacts on the coagulation profile. Products that impact on the hemostatic health of women include contraception, as well as using hormone replacement later in life. Also, lifestyle habits like smoking are known to have an impact on coagulation and hemostasis. Because hemostasis and estrogen are so closely linked to these lifestyle choices of women, it is suggested that an ultrastructure of fibrin networks may provide relevant insight into the changing coagulation profile of females. In the current research, the fibrin network in females, under different conditions, is studied using a scanning electron microscope. Control female profiles are compared with pregnancy, contraceptive use, hormone replacement, females who smoke, as well as females during old age. Here, we argue that the changes in the different stages of womanhood have a direct impact on the health and possibly thrombotic status in women. It is concluded that information provided by ultrastructural analysis during routine clinical history taking, might provide useful information regarding the most appropriate management or regime, particularly for women.

Keywords: SEM, ultrastructure, fibrin networks

Correspondence: Etheresia Pretorius, Department of Anatomy, School of Medicine, Faculty of Health Sciences, University of Pretoria, BMW Building, PO Box 2034, Pretoria 0001, South Africa. Tel: +27 12 319 2533; Fax: +27 12 319 2240; e-mail: resia.pretorius@up.ac.za

INTRODUCTION

Estrogen plays an important role during the life of a healthy female and impacts on the coagulation profile. Products that impact on the hemostatic health of women include contraception, as well as using hormone replacement later in life. Also, lifestyle habits like smoking are known to impact coagulation and hemostasis. Because hemostasis and estrogen are so closely linked to these lifestyle choices of women, it is suggested that an ultrastructure of fibrin networks may provide relevant insight into the changing coagulation profile of females.

Although researchers know the impact of estrogen and lifestyle choices at the biochemical and physiological level, because of the many laboratory test information available, little is known about the ultrastructural imagery of the fibrin networks in particular. These networks could provide very important information, as it visually provides a snapshot view of the health status of the coagulation profile of the patient. Many conditions are reliant on the clinical profile that the health practitioner draws of the patient. Ultrastructural analysis may assist to add information to this existing profile.

Here, the use of scanning electron microscopy (SEM) is demonstrated and the aim is to show that it is an invaluable, reliable, and quick tool to gain information regarding the coagulation profile of a patient. In the current study we show how the fibrin network in females change by comparing the fibrin network ultrastructure of young female controls to users of contraception, individuals who smoke, older females

using hormone replacement, and, finally, women older than 80.

MATERIALS AND METHODS

Samples

Fresh platelet-rich plasma from each donor was prepared by drawing 40 ml of blood from females (ethical clearance was obtained from The Research Ethics Committee, Faculty Health Sciences, University of Pretoria, who complies with ICH-GCP guidelines and has US Federalwide Assurance; ethics clearance number: 151/2006, reapproved 2009). The following groups were studied: controls (6); contraception (6); hormone replacement (6); pregnancy (2); smoking (6); and old age (6). For each of our previous studies, six healthy control subjects are used to confirm the correctness of the analysis methods. The current controls showed an ultrastructure similar to previous published results.

Blood was centrifuged at 1000 rpm (maximum RCF = 17.523g; 1250 g) for 2 min. Human thrombin (provided by the South African National Blood Service) was used to prepare fibrin clots. When thrombin is added to platelet-rich plasma, fibrinogen is converted to fibrin and intracellular platelet components (eg, transforming growth factor, platelet-derived growth factor, and fibroblastic growth factor) are released into the coagulum. Twenty μ l of the PRP was mixed with 20 μ l of human thrombin on a 0.2 μ m millipore membrane to form the coagulum (fibrin clot). This millipore membrane was then placed in a Petri dish on filter paper dampened with

phosphate buffered saline (PBS) to create a humid environment and placed at 37°C for 10 min. This was followed by a washing process where the millipore membranes with the coagula were placed in PBS and magnetically stirred for 45 min. This was done to remove any blood proteins trapped within the fibrin network.^{1,2}

Washed fibrin clots were fixed in 2.5% glutaraldehyde in Dulbecco's phosphate buffered saline (DPBS) with a pH of 7.4 for 1 h. Each fibrin clot was rinsed three times in a phosphate buffer for 5 min before being fixed for 1 h with 1% osmium tetroxide (OsO₄). The samples were rinsed three times with distilled water for 5 min and were dehydrated serially in 30%, 50%, 70%, 90%, and three times with 100% ethanol. The SEM procedures were completed by critically point drying the material, mounting, and coating with ruthenium tetroxide (SPI Supplies, West Chester, Pennsylvania). This is a standard preparation method for electron microscopy and takes 3 h of laboratory work.

A Zeiss ULTRA plus FEG-SEM with InLens capabilities, using nitrogen gas and ultra high resolution BSE imaging studied surface morphology of the samples. Micrographs were taken at 1 kV. This instrument is located in the Microscopy and Microanalysis Unit of the University of Pretoria, South Africa.

RESULTS AND DISCUSSION

A typical clot formed by activating the fibrin networks using thrombin, consisting of fibrin networks formed by major thick fibers and minor thin fibers sparingly dispersed between the thick fibers. This morphology is present throughout a typical clot and at least 20 different areas, with a 5000 × machine magnification on a single clot, are studied to confirm morphology. Two clots per sample are separately prepared. At least 10 micrographs at 30 000 × and 40 000 × machine magnification are taken to confirm constant morphological characteristics. In the current study, a double-blind analysis of the micrographs, by an independent researcher, confirmed that the micrographs chosen for the current publication (for each group) were indeed representative of the different donors within each group. Reproducibility of the techniques is very high; however, a trained electron microscopy researcher is advisable.

Figure 1 shows a clot from a typical young female under the age of 25; a thick, white arrow shows thick fibers; a thin white arrow shows thin fibers. Due to the changes in estrogen, as well as the impact of smoking on hemostasis, this morphology changes.

Smoking impacts on coagulation and recently Pretorius and coworkers coined the term “sticky fibrin phenomenon”.³ The authors showed that smoking causes the fibrin networks to stick together and form matted layers. **Figure 2** shows a micrograph of a 23-year-old female who smokes occasionally during the past 3 years. A thick matted sticky fibrin is noted (white arrow). This change in morphology is alarming, as it apparently takes place quite soon and not, as in the case of lung damage, due to smoking developed over a period of




Figure 1. Scanning electron microscopy of fibrin fibers from a control female. Thick white arrow = major thick fibers; thin white arrow = minor thin fibers (scale bar = 1 μm)

time. Smoking is known to impact on coagulation and research has shown that the coagulation profile changed.

Pregnancy, as well as the use of contraception in the younger individuals, also changes the coagulation profile. In pregnancy, the estrogen levels increase and it is known that there is a marked increase in the procoagulant activity in maternal blood, characterized by an elevation of coagulation factors and fibrinogen, which is maximal around term.⁴ Researchers suggested that the rise in coagulation factors could be due to an increased synthesis, to an increased activation by thrombin, or to both. A pronounced increase in fibrinogen levels, up to two to threefold, has been found during pregnancy.⁴⁻⁹ Also, researchers have found increases from 20% to 1000% in factors VII, VIII, IX, X, and XII; while the von Willebrand factor may increase up to 400%.⁹ However, it was also noted that levels of prothrombin and factor V remain unchanged, while levels of factors XIII and XI decline slightly.¹⁰ According to Lockwood,¹⁰ during pregnancy there is an increased efficiency of clotting and impaired fibrinolysis; this has also been suggested by other researchers.^{4,8} These changes may lead to an increase in the prevalence of venous thromboembolism, which is otherwise uncommon in reproductive age women.¹⁰ Pretorius and

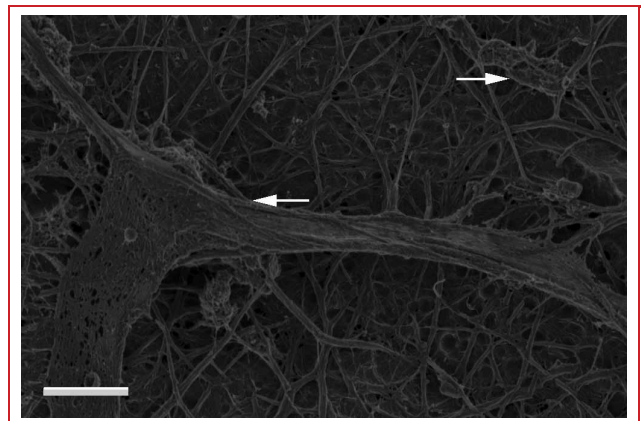


Figure 2. Scanning electron microscopy of fibrin fibers from a young 23-year-old female who smokes occasionally. White arrows = matted fibers forming a sticky matted layer (scale bar = 1 μm)

coworkers¹¹ demonstrated that during pregnancy the morphology of the fibrin networks also changes, and that the minor fibers form a net over the thick major fibers (**Figure 3**). It was concluded that during pregnancy, the fibrin network morphology changes dramatically and that this might contribute to the fact that there is an increase in thrombotic risk, because clots formed during pregnancy might take longer to be broken down by normal fibrinolytic activity due to the denser clot morphology.

Oral contraceptives have also been linked to an increased incidence of thrombovascular disease and that this is due to their effects on the hemostatic system. Epidemiologic reports also suggest that all contraceptives carry an increased thrombotic risk and careful clinical screening should be done before taking it. Family history is also an important consideration. Already in the late 1960s and 1970s, publications of the Royal College of General Practitioners in England reported that in women using oral contraceptives, the incidence of venous thromboembolism is increased by two to fourfold.¹² The main reason for this change in hemostasis is the increase in the activity of coagulation factors VII, X, and fibrinogen due to contraceptive usage,¹³ as increased factor VII levels are dependent on both the estrogen and progestogen component of the oral contraceptive.

Interestingly, there may also be a reduction in antithrombin III levels but increased fibrinolysis also has been shown in oral contraceptive users,¹³ which theoretically should balance the changes in the coagulation pathway. However, thrombus formation may occur when a local vascular wall damage exists or when other risk factors for thromboembolism, such as older age and smoking, coexist and create a local activation resulting in a thrombus.¹³

Interestingly, young females taking contraceptives also showed a changed morphology (**Figure 4**) where thick black arrows show major fibers and thin black arrows show minor thin fibers forming a netlike covering. This changed




Figure 3. Scanning electron microscopy of fibrin fibers from a healthy pregnant individual. Minor thin fibers cover major thick fibers in a netlike layer (scale bar = 0.5 μm)

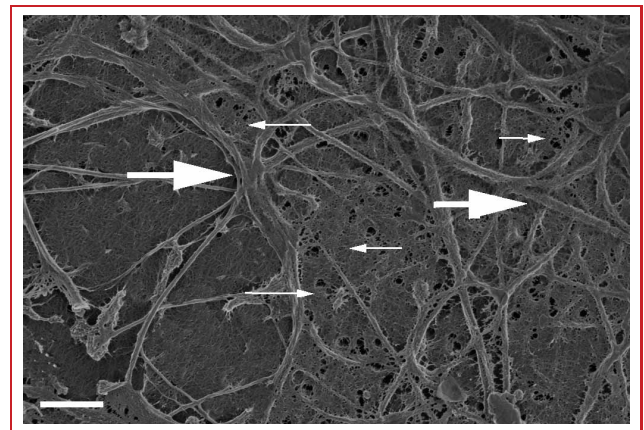


Figure 4. Scanning electron microscopy of fibrin fibers from a healthy female using contraception. Thick black arrows = major fibers; thin black arrows = minor thin fibers forming a netlike covering (scale bar = 1 μm)

morphology with a denser fibrin covering also provides evidence for the increase in thrombotic risk when taking contraceptives. The question now arises if this netted fibrin is also visible in older females using hormone replacement. As with pregnancy and contraceptive use, hormone replacement has also been associated with increased thrombotic risk. Furthermore, venous thromboembolism—either deep vein thrombosis or pulmonary embolism—is a serious side effect of postmenopausal hormone therapy.¹⁴ **Figure 5** shows an ultrastructure of a 50-year-old female using hormone replacement. Here, also, the minor fibrin fibers form a netted covering over the major thick fibers (thick white arrow shows minor thin fibers forming a netlike covering; thin white arrow shows major fiber network).

Therefore, these results suggest that estrogen levels seem to change the fibrin structure of the minor thin fibers in particular, and that this is prevalent in pregnancy, contraceptive use, as well as hormone replacement therapy.

The question now arises whether fibrin morphology of older females, not on hormone replacement, returns (after the use of hormone replacement) or perhaps retains a typical “young” morphology in individuals who has never used

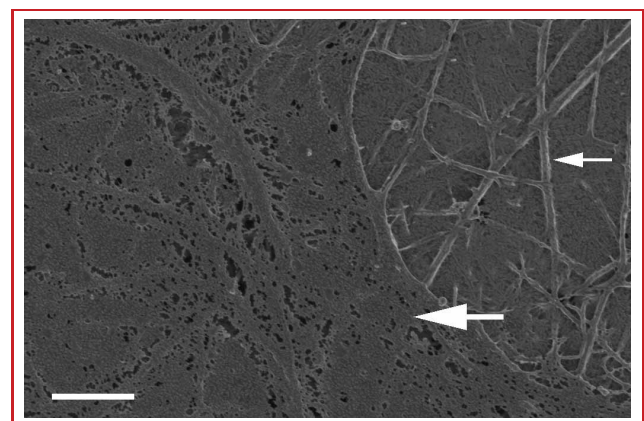


Figure 5. Scanning electron microscopy of fibrin fibers from a healthy female using hormone replacement. Thick white arrow = minor thin fibers forming a netlike covering; thin white arrow = major fiber network (scale bar = 1 μm)

hormone replacement. We know from previous research that in the process of aging inflammation increases, and, together with this, the coagulation profile. In 2009, Bucciarelli and Mannucci noted that the process of aging is accompanied by several modifications in the hemostatic system at different levels (blood coagulation, fibrinolysis, platelet activity, vascular endothelium).¹⁵ These changes may explain the higher incidence of arterial and venous thrombosis in the elderly compared to young people.

During aging, changes in vasculature, hemostasis, and endothelium, including alterations of platelets, coagulation, and fibrinolytic factors occur. Research has also reported that healthy, aged individuals have heightened coagulation enzyme activity, accompanied by signs of enhanced formation of fibrin and secondary hyperfibrinolysis. It is now believed that the impaired fibrinolytic potential in old age results in a condition that Gharacholou and Becker, in 2009, described as a systemic state of “thrombotic preparedness” that is far out of proportion to the physiological needs of the person.¹⁶ This state is far out of proportion to the physiological needs of the person.

Recently, Pretorius and coworkers,¹⁷ in 2010, showed that this apparent changed thrombotic profile in healthy aged individuals (over the age of 75) is evident in their platelet and fibrin network ultrastructure when compared to healthy individuals under 25 years of age. The main differences among young and older individuals were found in the fibrin network ultrastructure. It is concluded that with age, major fibers seem to become thinner and more sparsely arranged and that minor thin fibers dominate it the coagulum, forming a fine netlike structure. At irregular intervals in the coagulum, thicker fibrin fiber lattices are present; this is not found in healthy individuals. This might be due to the previously suggested enhanced fibrin formation and heightened coagulation enzyme activity. Pretorius and coworkers therefore provided ultrastructural evidence for the thrombotic preparedness previously suggested after studying the biochemistry of fibrinolysis and coagulation factors in the elderly. **Figure 6** shows an 86-year-old female coagulum, where flimsy fibers are present (thick white arrows) as well as regions where

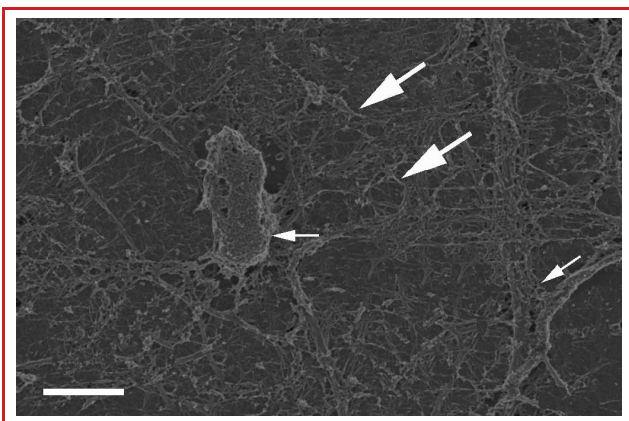


Figure 6. Scanning electron microscopy of fibrin fibers from an 86-year-old female. Thick white arrows = flimsy fibrin fibers; thin white arrows = fibers forming a lattice of bulky, irregularly arranged areas (scale bar = 1 μ m)

fibers form a lattice of bulky, irregularly arranged areas (thin white arrows).

CONCLUSION

It seems that females have an ever-changing coagulation profile. Estrogen appears to have a major impact on fibrin structure, whether it is natural, during pregnancy, or induced, which include contraceptive and hormone replacement therapy. Here, we argue that the changes in the different stages of womanhood have a direct impact on the health and possibly thrombotic status in women. Lifestyle choices have a major impact on fibrin networks, and unfortunately, combining estrogen modulating products together with smoking or smoking during pregnancy may possibly have catastrophic effect on hemostasis. Both have effects on fibrin networks and might cause a thrombotic event. It is concluded that information provided by an ultrastructural analysis during routine clinical history taking might provide useful information regarding the most appropriate management or regime, particularly for women. However, this research needs to be expanded and in each of the groups (eg, the contraceptive users and the women using hormone replacement) should include a larger sample size, where the effect of different types of estrogen should also be taken into account. This snapshot into the ultrastructural changes, due to the changing estrogen levels in women provides interesting evidence of the role of estrogen.

Disclosure: Dr. Ethersia Pretorius received funding from the Medical Research Council: South Africa–thrombosis research.

Funding: Research was funded by the Medical Research Council (MRC) of South Africa.

Acknowledgements: I would like to express my sincere thanks to my laboratory team, Dr. Nanette Oberholzer and Miss Wendy van der Spuy. Also, to my grandmother, Ouma Rien, who is 86 and who participated as one of the donors in this study.

REFERENCES

1. Pretorius E, Briedenhann S, Marx J, et al. Ultra-structural comparison of the morphology of three different platelet and fibrin fibre preparations. *Anat Rec.* 2007;290:188–198.
2. Pretorius E, Oberholzer HM, Smit E, Steyn E, Briedenhann S, Franz RC. Ultrastructural changes in platelet aggregates of HIV patients: A scanning electron microscopy study. *Ultrastruct Pathol.* 2008;32:75–79.
3. Pretorius E, Oberholzer HM, van der Spuy WJ, Meiring JH. Smoking and coagulation: The sticky fibrin phenomenon. *Ultrastruct Pathol.* 2010;34(4):236–239.
4. Stirling Y, Woolf L, North WR, Seghatchian MJ, Meade TW. Haemostasis in normal pregnancy. *Thromb Haemost.* 1984;52:176–182.
5. Bonnar J. Haemostasis and coagulation disorders in pregnancy. In: Bloom AL, Thomas DP, eds. *Haemostasis and Thrombosis.* Edinburgh: Churchill Livingstone; 1987:570–584.
6. Letsky EA. *Coagulation Problems During Pregnancy.* Edinburgh: Churchill Livingstone; 1985.
7. Beller FK, Ebert C. The coagulation and fibrinolytic enzyme system in normal pregnancy and the puerperium. *Eur J Obstet Gynecol Reprod Biol.* 1982;13:177–179.
8. Brenner B. Haemostatic changes in pregnancy. *Thromb Res.* 2004;114(5–6):409–414.
9. Bremme KA. Haemostatic changes in pregnancy. *Best Pract Res Clin Haematol.* 2003;16:153–168.

10. Lockwood CJ. Pregnancy-associated changes in the hemostatic system. *Clin Obstet Gynecol.* 2006;49(4):836–843.
11. Pretorius E, Bronkhorst P, Briedenhann S, et al. Comparisons of the fibrin networks during pregnancy, non-pregnancy and pregnancy during dysfibrinogenaemia using the scanning electron microscope. *Blood Coagul Fibrinolysis.* 2009;20:12–16.
12. Maurer-Major E, Keller PJ. Contraceptive agents and risk of thrombosis. *Praxis (Bern 1994).* 1997;86(40):1543–1548.
13. Norris LA, Bonnar J. Haemostatic changes and the oral contraceptive pill. *Baillieres Clin Obstet Gynaecol.* 1997;1(3):545–564.
14. Canonico M, Scarabin PY. Hormone therapy and risk of venous thromboembolism among postmenopausal women. *Climacteric.* 2009;12 (suppl 1):76–80.
15. Bucciarelli P, Mannucci PM. The hemostatic system through aging and menopause. *Climacteric.* 2009;12(suppl 1):47–51.
16. Gharacholou SM, Becker RC. Hemostasis and thrombosis in older adults. *J Thromb Thrombolysis.* 2009;27(2):249–251.
17. Pretorius E, Oberholzer HM, van der Spuy WJ, Meiring JH. Age-related changes in fibrin networks and platelets of individuals over 75: a scanning electron microscopy study showing “thrombotic preparedness.” *J Thromb Thrombolysis.* 2010;29(3):271–275.