

A Short Note on the Occurrence of a Leucocytozoon Infection. Host The Ostrich.

By J. WALKER, M.R.C.V.S., of the Division of Veterinary Research,
Grahamstown.

In November, 1911, the writer was requested to investigate the cause of the mortality occurring amongst ostrich chicks on a farm in the Middelburg District, Cape Province. The percentage of deaths, on a number of farms, of ostrich chicks of about 6-8 weeks is large, and from the following particulars furnished by the owner the losses have also been considerable on this farm.

In 1910 out of a total of 745 hatched 351 were reared.

In 1911 out of a total of 784 hatched 295 were reared.

In 1909 the losses were small; 360 were reared of a total of 365 hatched.

The cause of death was attributed by the owner to, in some instances, parasitic infection (intestinal) and liver disease (so-called yellow liver), and in many cases it was unknown.

A number of sick chicks of about 6-8 weeks old were examined, the *symptoms* noted were disinclination to feed, loss of condition, stunted growth, paleness of the buccal mucous membrane, skin of body and around eyes bluish, inability to keep up with the rest of the brood when driven, chicks were noticed sick some days before death.

A number of post-mortems were held, with the result that death, in some instances, was found to be due to parasitic infection (*strongylus Douglasii* and *Taenia*). The absence of intestinal parasites was, however, noted in some cases, and the cause of death had thus to be disassociated with wire worm and tape worm infection. It was found that the usual method of rearing and feeding chicks had not been departed from, and the particulars furnished and observations made pointed to the existence of a disease of a specific nature.

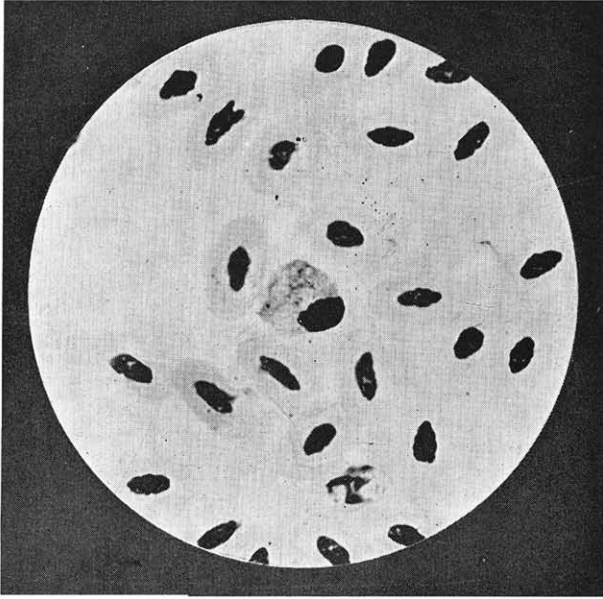
A microscopical examination of the organs showed no constant changes, but on examination of the blood the presence of a *Leucocytozoon* was frequently noted.

So far, in South Africa, a similar parasite had only been observed in some species of wild birds, *e.g.*, the Hawk, and consequently, from an economic point of view, its presence was not considered of much importance. It will now, however, be necessary to ascertain whether it enters into the etiology of some of the at present unknown diseases of ostrich chicks.

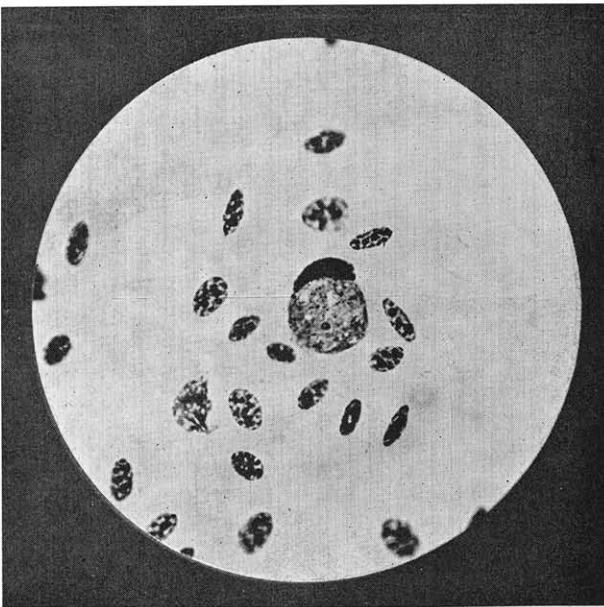
Microscopical Appearance of the Parasite in stained BLOOD SMEARS.

In dried blood smears fixed with methyl alcohol and stained with Giemsa, two main types of parasites which apparently correspond with male and female Gametocytes have been noted.

The Female Gametocyte occurs most frequently.



A.—Male Leucocytozoon.



B.—Female Leucocytozoon.

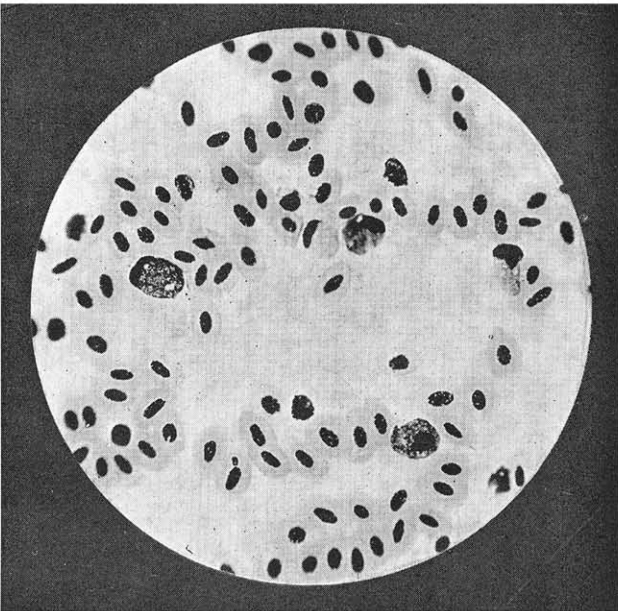


Plate No. 40.]
(contd.)

C.—Male and Female Leucocytozoon

The shape varies. Sometimes it is more or less rounded, but it may be irregular, probably due to distortion caused in making the smears.

The size varies from 11-15 microns in length and 9-13 microns in width.

The protoplasm of the parasite stains deeper than in the case of the male gametocyte, and scattered throughout it are a number of meta-chromatic granules which appear more distinctly in some of the parasites than in others. A number of small, clear spaces occur throughout the protoplasm. Situated in various positions, generally at the centre or near the edge, is an aggregation of small chromatin granules which represents the *nucleus*. In most instances a large chromatin granule situated in the mass of the chromatin granules, or at the side of, or some distance from these, stands out distinctly.

The nucleus of the host cell is always altered in shape. In most cases it is elongated and situated at the margin of the parasite.

The Male Gametocyte, as stated above, occurs less frequently than the female.

The shape varies. It is usually more or less rounded.

Size varies and is usually smaller than the female gametocyte.

The Protoplasm stains less densely than in the case of the female.

The chromatin granules of the *nucleus* are generally scattered throughout the cell, and sometimes they are large and widely separated, in which case they are very distinctly seen.

The nucleus of the host cell is irregular in shape, but less elongated and smaller than in the case of the cell invaded by the female. It is found at the edge of the parasite.

Contrary to what has been observed in Leucocytozoon infection in birds of some species, no *spindle-shaped formation* of the host cell has so far been observed in stained blood smears of infected ostriches.

Occurrence Amongst Ostriches and Age of Birds Affected.

For the purpose of ascertaining to what extent the infection occurs amongst ostriches, a number of blood smears from chicks and adult birds were collected from various farms, with the result as shown in the following table, viz., Table I. :—

No.	Farm.	Date.	Number of Smears examined and ages of Birds.	Result.	Remarks.
1	B.H.	31/1/12	12 x 7 year old Ostriches	Negative	Mortality amongst chicks on this farm heavy this year and previous years.
"	"	"	6 x 3 " " Chicks	"	
"	"	"	12 x 18 months " " Chicks	"	
"	"	"	12 x 2½ " " "	9 Leucocytozoon infection.	
"	"	"	12 x 6 weeks " "	11 Leucocytozoon infection.	
2	P.	12/2/12	11 x 7 year old Ostriches	Negative	Little or no mortality this year amongst chicks on this farm.
"	"	"	17 x 2 " " "	"	
"	"	"	5 x 2 months " Chicks	"	
3	C.	31/1/12	4 x 6 year old Ostriches	Negative	Losses have occurred this year and also in previous years.
"	"	"	6 x 15 months " Chicks	"	
"	"	"	6 x 7 " " "	1 Leucocytozoon infection.	
"	"	"	15 x 2 " " "	4 Leucocytozoon infection.	
"	"	"	2 x 6 weeks " "	2 Leucocytozoon infection.	
"	"	"	4 x 2 " " "	Negative	
4	G.	21/1/12	8 x 1 month old Chicks	Negative	Mortality heavy on this farm this year.
"	"	"	1 x 5 " " Chick	"	
"	"	"	4 aged Ostriches	"	
5	T.	18/1/12	4 x 11 months old Chicks	Negative	Mortality heavy on this farm during this year and previous years.
"	"	"	1 x 5 " " Chick	"	
"	"	"	5 x 4 " " Chicks	4 Leucocytozoon	
"	"	"	1 x 2½ " " Chick	Negative	
"	"	"	2 x 3 " " Chicks	"	
"	"	"	6 x 2 " " "	3 Leucocytozoon infection.	
"	"	"	7 x 2 days " "	Negative.	
6	B.H.	27/11/11	1 x 3 months old Chicks	Negative	Mortality heavy on this farm during the year and some previous years.
"	"	"	2 x 7 weeks old "	Leucocytozoon infection.	
"	"	"	4 x 6 " " "	Leucocytozoon infection.	
"	"	"	1 x 5 " " Chick	Leucocytozoon infection.	
"	"	"	1 x 4 " " "	Leucocytozoon infection.	

CONCLUSION.

A leucocytozoon infection has so far been observed in ostrich chicks aged from 4 weeks to 7 months. The examination of a number of smears collected from adult ostriches on farms on which the infection is common amongst chicks, gave negative results.

Since this parasite has so far not been recorded, I propose that it be named *Leucocytozoon Struthionis*.