

---

# CASE REPORT AND REVIEW OF THE LITERATURE

---

## Simultaneous ipsilateral femur and tibia lengthening after an iatrogenic nerve injury: Shortening external fixator time

FF Birkholtz MBChB(Pret), MMed(Orth)(Pret), FCOOrth(SA)  
Netcare Unitas, Zuid Afrikaans and Steve Biko Academic Hospitals, Pretoria, South Africa

### Reprint requests:

Dr FF Birkholtz  
PO Box 11328  
Centurion  
0046  
South Africa  
Tel: +27(0)12 644-2641  
Fax: +27(0)12 644-2642  
Email: fbirkholtz@gmail.com

### Abstract

Limb lengthening using distraction osteogenesis is an established technique; however it is often limited by prolonged external fixation times, with their associated difficulties and complications. A case is presented where a leg lengthening was performed with a relatively short external fixation time. This was made possible by the equal distribution of the patient's leg length discrepancy between the femur and tibia, secondary to an iatrogenic nerve injury while the patient was still growing. The technique of simultaneous ipsilateral femoral and tibial lengthening was shown to be an effective method of shortening external fixator time in this case and opens the door for further application of this technique in other clinical scenarios.

### Background

Leg lengthening through distraction osteogenesis is a well-established treatment method for congenital, post-infective or post-traumatic shortening of legs.<sup>1-6</sup> This is normally achieved with the use of external fixators<sup>1,3,6-8</sup> or implantable lengthening intramedullary nails.<sup>4,5,9-11</sup> This procedure, although effective, can be time consuming and fraught with complications related to the device or the lengthening itself.<sup>1,3-4,7,9,12-13</sup>

The time that the external fixator frame is required on the patient to achieve a specified amount of lengthening is quantified using the healing, and more recently, the external fixation index. This is defined as the amount of time in the fixator per amount of lengthening achieved and is normally expressed as either days or months per centimetre of lengthening.<sup>1,2,14-15</sup> This time period includes the lag period (a waiting time of approximately ten days after surgery before

distraction is commenced), the distraction time (where the bone is gradually lengthened to its new length) and the consolidation period (where the fixator is locked down to allow bony union). The external fixation index for lengthening in adults is accepted as upward of 1.5 months per centimetre<sup>1,14-15</sup> (Figure 1). The implication of this is an extended time of 6-8 months in an external fixation frame to achieve a 4 cm lengthening. This prolonged external fixation time is uncomfortable for the patient and additionally increases the risks of specific complications associated with limb lengthening,<sup>1,3,4,7,9,12-13</sup> some of which are related to the type of device used to lengthen the limb segment. This includes, for example, pin tract infections with the use of an external fixator<sup>1,2,5,9,16</sup> and uncontrolled lengthening with the use of an intramedullary device.<sup>4,11</sup> Furthermore, complications can arise as a result of the lengthening itself and can manifest as adjacent joint stiffness and subluxation.<sup>1,3,7,9,12,17</sup>

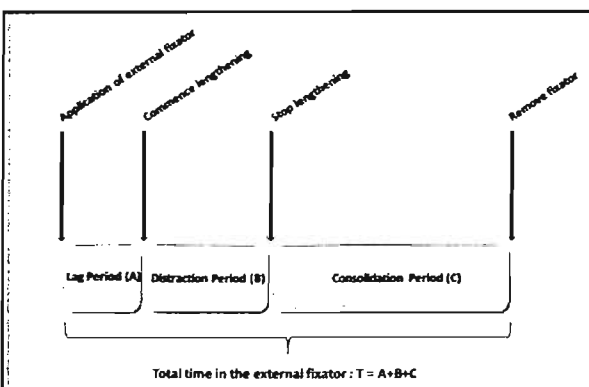
As most of these complications are related to the extent of the lengthening as well as the time the patient spends in an external fixator, it is desirable to keep external fixation times as short as possible.

Iatrogenic sciatic nerve injuries after intramuscular injections in the gluteal region have been reported in the literature, but the true prevalence is still unknown.<sup>18</sup> Injuries like these can give rise to varying degrees of sciatic nerve deficit and, although not clearly defined in the literature, can conceivably lead to limb shortening if it occurs in a growing child. These types of injuries seem to be more prevalent in the developing world.<sup>18</sup>

### Case presentation

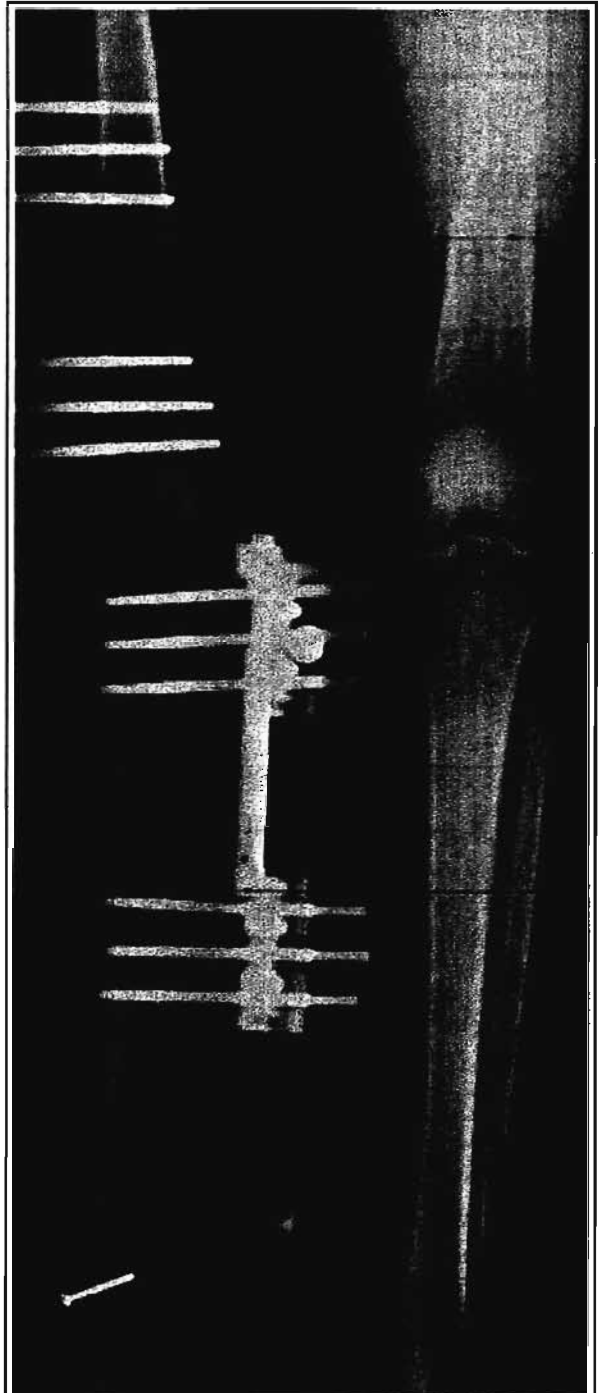
Mr VN is a 22-year-old male who was referred from a spinal surgeon with a painful, mobile scoliosis in the lumbar spine as a compensation for a significant leg length discrepancy. The patient's history includes an iatrogenic sciatic nerve injury after receiving an intramuscular injection in the gluteal region approximately 10 years before, resulting in a right sided drop-foot, as well as growth retardation of the right femur and tibia. The patient subsequently developed a painful compensatory scoliosis due to the significant leg length discrepancy which was aggravated by his poor compliance in wearing a bulky shoe-raise. The patient presented with a normal knee range-of-motion and his clinical examination revealed a pure leg length discrepancy of 4 cm. The Galeazzi test revealed that the femur and tibia both contributed equally to the discrepancy. Further clinical examination revealed no rotational or angular deformities.

**As most complications are related to the extent of the lengthening as well as the time the patient spends in an external fixator, keep external fixation times as short as possible**



**Figure 1:**

The total external fixation time (T) comprised the lag period (A), distraction period (B) and the consolidation period (C). The healing or external fixation index is the external fixation time per centimetre of length gained, i.e. T/cm.



**Figure 2:**

An X-ray showing the diastasis screw used distally to maintain the tibio-fibular relationship during distraction. This is often placed obliquely to improve the mechanics of this screw. Note the fixators in place on the lateral aspect of the femur and anteromedial aspect of the tibia. Distraction is underway at the corticotomy sites, with early regenerate (callus) formation at the distraction sites.

The long-leg standing radiological examination revealed no deformities and confirmed a leg-length discrepancy of 4 cm. The X-rays furthermore revealed that the discrepancy was due to a 2 cm femoral and tibial shortening each. Leg lengthening surgery was offered to the patient and written informed consent was obtained.

The subsequent management plan entailed the use of a simultaneous ipsilateral femoral and tibial lengthening motivated by two reasons. First, lengthening both the tibia and femur would result in a correction of the length discrepancy as well as ensuring equal knee levels bilaterally after lengthening; secondly, a simultaneous ipsilateral lengthening should result in a shortened external fixation index, because the total limb lengthening would be broken up into two half segments that would proceed simultaneously.

---

**Consolidation of both the regenerate sites proceeded rapidly and uneventfully until frame removal at just over four months**

---

A monolateral rail fixator was applied on the lateral side of the femur and anteromedial side of the tibia. A predrilled corticotomy<sup>1,2</sup> (a low energy osteotomy where maximal preservation of the endosteum and periosteum is attempted) was performed at each lengthening site using a percutaneous approach. The fibula was osteotomised through a limited lateral approach and a distal diastasis screw inserted percutaneously to prevent dissociation of the distal tibiofibular joint during distraction (*Figure 2*). A waiting period of 10 days was completed before commencing gradual lengthening at both sites. The rate of lengthening was 1 mm per day, divided into four increments of 0.25 mm each at each of the lengthening sites. Standard pin care in the form of occlusive dressings was applied. The patient was followed up during the distraction period at two-weekly intervals and the maintenance of knee movement was emphasised throughout the treatment period. Target length was obtained at about four weeks and distraction stopped. Mobilisation within pain limits was encouraged throughout the treatment period. No additional bone stimulants such as ultrasound or pulsed electromagnetic fields were utilised. Consolidation of both the regenerate sites proceeded rapidly and uneventfully until frame removal at just over four months. No splints or casts were needed after frame removal.

The chosen management plan resulted in an external fixation index of just less than 1.1 months per centimetre. As expected,<sup>8</sup> this is shorter than the established norm of 1.5 months per centimetre. The patient had no complications apart from a minor pin tract infection that responded well to oral antibiotic treatment. At follow-up 7 months after surgery, the patient was mobilising comfortably without aid and had recovered his pre-operative knee range of motion. His neurological condition was unchanged, but his painful scoliosis had disappeared.

## Conclusion

The nature of the aetiology of this patient's leg length discrepancy led to equal shortening of the femur and tibia. This afforded the surgeon the opportunity to address this patient's leg length discrepancy by simultaneously lengthening the femur and tibia. As expected, the application of this technique resulted in a significantly shorter external fixator index with its potential advantages of lower complication rates and patient discomfort. This specific technique may have clinical relevance in other scenarios where a limb length discrepancy exists in both segments of the lower limb, in an effort to shorten external fixator indices.

*No benefits of any form have been received from a commercial party related directly or indirectly to the subject of this article. Written informed consent was obtained from the patient to use his information and X-rays for the purposes of this article.*

## References

1. Aronson J. Limb-lengthening, skeletal reconstruction, and bone transport with the Ilizarov method. *J Bone Joint Surg Am* Aug 1997;**79**(8):1243-58.
2. Friend L, Widmann RF. Advances in management of limb length discrepancy and lower limb deformity. *Curr Opin Pediatr* Feb 2008;**20**(1):46-51.
3. Noonan KJ, Leyes M, Forriol F, Canadell J. Distraction osteogenesis of the lower extremity with use of monolateral external fixation. A study of two hundred and sixty-one femora and tibiae. *J Bone Joint Surg Am* Jun 1998;**80**(6):793-806.
4. Simpson AH, Shalaby H, Keenan G. Femoral lengthening with the Intramedullary Skeletal Kinetic Distractor. *J Bone Joint Surg Br* Jul 2009;**91**(7):955-61.
5. Hankemeier S, Gosling T, Pape HC, Wiebking U, Krettek C. Limb lengthening with the Intramedullary Skeletal Kinetic Distractor (ISKD). *Oper Orthop Traumatol* Feb 2005;**17**(1):79-101.
6. Aston WJ, Calder PR, Baker D, Hartley J, Hill RA. Lengthening of the congenital short femur using the Ilizarov technique: a single-surgeon series. *J Bone Joint Surg Br* Jul 2009;**91**(7):962-7.
7. Stanitski DF, Shahcheraghi H, Nicker DA, Armstrong PF. Results of tibial lengthening with the Ilizarov technique. *J Pediatr Orthop* Mar-Apr 1996;**16**(2):168-72.
8. Curran AR, Kuo KN, Lubicky JP. Simultaneous ipsilateral femoral and tibial lengthening with the Ilizarov method. *J Pediatr Orthop* May-Jun 1999;**19**(3):386-90.
9. Krieg AH, Speth BM, Foster BK. Leg lengthening with a motorized nail in adolescents: an alternative to external fixators? *Clin Orthop Relat Res* Jan 2008;**466**(1):189-97.
10. Singh S, Lahiri A, Iqbal M. The results of limb lengthening by callus distraction using an extending intramedullary nail (Fitbone) in non-traumatic disorders. *J Bone Joint Surg Br* Jul 2006;**88**(7):938-42.

11. Guichet JM, Deromedis B, Donnan LT, Peretti G, Lascombes P, Bado F. Gradual femoral lengthening with the Albizzia intramedullary nail. *J Bone Joint Surg Am* May 2003;**85-A(5)**:838-48.
12. Glorion C, Pouliquen JC, Langlais J, Ceolin JL, Kassis B. Femoral lengthening using the callotasis method: study of the complications in a series of 70 cases in children and adolescents. *J Pediatr Orthop* Mar-Apr 1996;**16(2)**:161-7.
13. Vargas Barreto B, Caton J, Merabet Z, Panisset JC, Pracros JP. Complications of Ilizarov leg lengthening: a comparative study between patients with leg length discrepancy and short stature. *Int Orthop* Oct 2007;**31(5)**:587-91.
14. Sakurakichi K, Tsuchiya H, Uehara K, Kabata T, Tomita K. The relationship between distraction length and treatment indices during distraction osteogenesis. *J Orthop Sci* 2002;**7(3)**:298-303.
15. Kristiansen LP, Steen H, Reikeras O. No difference in tibial lengthening index by use of Taylor spatial frame or Ilizarov external fixator. *Acta Orthop* Oct 2006;**77(5)**:772-7.
16. Antoci V, Ono CM, Antoci V, Jr., Raney EM. Pin-tract infection during limb lengthening using external fixation. *Am J Orthop* Sep 2008;**37(9)**:E150-4.
17. Maffulli N, Nele U, Matarazzo L. Changes in knee motion following femoral and tibial lengthening using the Ilizarov apparatus: a cohort study. *J Orthop Sci* 2001;**6(4)**:333-8.
18. Pandian JD, Bose S, Daniel V, Singh Y, Abraham AP. Nerve injuries following intramuscular injections: a clinical and neurophysiological study from Northwest India. *J Peripher Nerv Syst* Jun 2006;**11(2)**:165-71.

• SAOJ

## PROFESSIONAL, EFFICIENT, SAFE and RELIABLE

Stuart Black the owner of A2B Shuttle Services has been in the transport business for the past 15 years having worked for Avis Chauffeur Drive, Airport Link and Luxury Limos. He began the Company with the aim of offering clients that 'additional extra' that makes their journey more relaxing when you travel with A2B.

A2B Shuttle Services began in 2008 and is an exciting emerging business with service offerings that include: door-to-door shuttle services, transporting clients to and from the airport, return Sun City trips as well as transportation around Gauteng and when required, travel anywhere within and around South Africa.

We also offer VIP chauffeur drive services for the business executive and accommodate those who enjoy an evening out without having to worry about drinking and then driving. We too are affiliated with established tour operators and can arrange any tour clients may wish to go on.

We Look Forward to Being of Shuttle Service to You

For a free quotation and/or booking you are welcome to call us directly on 076 552 6362; or send an email to [info@a2bshuttle.com](mailto:info@a2bshuttle.com).

