

EXPERIMENTAL STUDIES ON A SPECIFIC PURULENT NEPHRITIS OF EQUIDAE.

By Dr. K. F. MEYER.

ALL standard works (*Pflug, Kitt*, etc.) on nephritis in domesticated animals only contain a few notes on the distribution and etiology of purulent nephritis in the horse. The lucid description given in *Kitt's* book on Pathology will be found without amendments in all the new publications. Generally the *Streptococcus equi* will be noted as the cause of purulent nephritis, but *Siedamgrotzky* described a case of nephritis as a sequel of castration, and *Seidemann*, in several cases, as a sequel of pneumonia and pleurisy, but in none of these reports has the haematogenous origin of this nephritis been experimentally proved. The theory of the haematogenous origin was supported by the experiments of *Fraenkel* and *Josef Koch*. The observations of *Koch* were published at a much later date than those of *Fraenkel*, but both investigators proved that by intravenous injection of *Staphylococcus pyogenes aureus* a disseminated purulent nephritis can be easily produced in rabbits.

The most exhaustive notes on purulent nephritis in cattle and pigs are found in the publications on *Bacillus pyelo nephritidis bovis*, and the paper of *Degen* on Purulent nephritis in pigs. The latter is of a certain importance for my experiments, but *Degen* also failed to prove that the isolated bacillus described in this paper is really the cause of the haematogenous nephritis.

Generally we can say that all purulent affections of domesticated animals have a poly-bacterial origin. The following bacteria may be the cause of purulent affections in the horse:—*Staphylococci*, *Streptococci*, *Bacillus mallei*, *Bacillus pseudo-mallei*, *Bacterium coli*, and *Bacillus necrosis*. With the exception of the above and the one case described by *Dieckerhoff* and *Grawitz*—where a small bacillus was found in a pustular dermatitis of horses—no other specific bacteria has been found in purulent lesions in horses.

In the last few years, cases of a specific purulent nephritis have occasionally been found in *post-mortem* examinations made in this institute. As early as 1902 *Theiler* conducted some experiments on the study of this disease, but failed to reproduce it by inoculation, since the isolated bacillus died out or lost its virulence to such a degree that no further proof of its importance as a specific bacterium in horses could be demonstrated. I had the opportunity in January, 1909, of examining a typical case of this disease, and I succeeded in isolating the micro-organism and in studying its morphology and biology. It was then possible for the first time to give the exact proof that one particular bacillus causes a specific haematogenous nephritis which generally ends fatally.

The following reports were handed over to me by Dr. *Theiler* for the purposes of my research:—

Case No. 1.—Mule (Cattle Preservation Department).—Showed a temperature of 103° F., pulse 70, hurried respiration, depression, and general weakness. In the few days preceding death the pulse amounted to about 104° F. The animal stood in the stall, leaning by its shoulders against the wall, and swayed from one side to the other whilst passing urine. A slight oedema was noted on the hind legs.

Post-mortem examination.—Made on the 5th March, 1902, shortly after death. The blood was dark black. Both lobes of the lungs were slightly oedematous; both ventricles of the heart were empty; in the left endocardium were a few ecchymoses. The liver was enlarged and showed stasis of the blood; the parenchyma was friable and the presence of white-yellowish patches (commencement of degeneration) gave it a mottled appearance. The spleen was enlarged, the capsule being slightly distended; the pulp was dark red and slightly soft. Both kidneys were considerably enlarged and embedded in an oedematous peri-capsular tissue; the kidneys weighed 1·412 kilo. The capsule of both kidneys was rather thickened and oedematous, and when it was torn off two pieces of the tissue remained attached. The whole parenchyma was dark red, in patches nearly black, and in the cortex and the intermediate zone were numerous small abscesses which contained a strongly mucous pus; the largest abscesses were found in the cortex and were nearly of the size of a pea. In the urinary bladder a small quantity of dark brown urine mixed with blood and coagula was noted. The stomach was almost empty; the fundus was slightly hyperaemic and rather thickened. The caecum and colon showed a slight catarrhal inflammation; microscopically in the pus, leucocytes and bacteria were found, and in the urine leucocytes and triple phosphate crystals. Bacteriologically (by means of cultures, the details of which appear later) on agar and glycerine-agar, the growth of a gram-negative bacillus was noted, biologically corresponding with the bacillus isolated by me. This bacillus was only pathogenic for guinea-pigs by intraperitoneal injections of large doses. No results were obtained with later sub-cultures.

Case No. 2.—Horse 120 had been infested on the 12th May, 1902, with ticks for a piroplasmosis experiment.

Post-mortem examination.—Made on the 21st May, 1902. Both kidneys were very much enlarged, weighing 1·8 kilo., and were embedded in a yellowish serous gelatinous mass. The capsule was rather thickened, and between the capsule and the kidney was a distinct oedema with fibrous deposits. Large pieces of the kidney parenchyma were torn off by removal of the capsule, and the surface of the kidneys was studded with haemorrhages and small yellowish foci. The whole parenchyma was dark red, strongly infiltrated and oedematous; on section the cortex and the medulla were rather friable, and studded with large and small abscesses which contained a mucous slightly yellowish odourless pus. The purulent foci in the medulla were longitudinal in form and those of the cortex distinctly rounded; the papilla was slightly oedematous. All the other organs were normal. There was a necrosis of the ligaments of the neck. Microscopically, leucocytes and bacilli were found in the pus, and the same gram-negative bacillus was isolated on media. This bacillus was also pathogenic in large doses for guinea-pigs, but died out before further experiments could be conducted.

In the museum of our institute I found two specimens which on histological examination proved to be cases of the same type of purulent nephritis, and by special staining the typical bacillus could be easily detected.

Specimen No. 1 (Mark HP. 443).—This is a right kidney considerably enlarged and weighing 1·480 kilo. The capsule is in several places attached

to the parenchyma and the whole surface of the kidney is studded with red and often yellowish nodules, distinctly protruding above the level of the normal tissue. The intermediate tissue is fibrous with haemorrhagic infiltrations, and only normal in small areas in the tissue. The size of the nodules in this case varies from that of a pin-head to a small pea. On section these nodules are yellowish abscesses which are embedded in the cortex and in the intermediate zone. The contents of the foci in the fixed specimen are rather viscid; all the foci are surrounded by haemorrhagic zones. In several places there are longitudinal yellowish streaks, and the adjoining tissue is red and friable; this represents nothing else than metastasis in the medulla. This specimen shows the distribution of small abscesses to a larger extent throughout the whole parenchyma than is usually observed in the artificially produced cases, a fact which seems to be of certain importance for the explanations given later.

Microscopical examination.—In sections of this specimen the blocking of the capillaries with leucocytes and bacteria could be clearly demonstrated. The small dark foci were distinct from the normal tissue, and the whole kidney therefore showed typical lesions to the naked eye. All the abscesses lay in the cortex, and therefore we cannot definitely decide the point of origin of these lesions; it may be in the capillaries of the interstitium, or the glomeruli, or in a certain number of cases in the convoluted tubules.

Generally the intensity of the lesions is proportional to the numbers of the bacteria. A division of the abscesses into three parts is more or less distinct. The first zone is haemorrhagic, surrounding the purulent one, and in the middle it is more or less necrotic. The structure here differs therefore a little from the cases referred to later. Probably a rather slow development of the lesions took place, because in an old embolus the lesions in the surrounding tissue are generally more pronounced than in a fresh one. The tubules contain a few small leucocyte casts and the epithelium is slightly swollen and granular. The parts near the papillae are free from lesions.

Specimen No. 2 (Horse HP. 442).—Some sections of a left kidney. The capsule is rather thickened and shows fibrous infiltrations, the parenchyma is attached to the capsule on such places where foci of a yellowish colour are noted. These foci are haemorrhagic and form typical ulcers; the centre of these ulcers corresponds with an abscess in the cortex, which shows all the characters described above.

One of the renal arteries is stopped by a thrombus at two places. In the centre of the thrombus a purulent softening is noted. Several papillae show purulent infarcts, and in several places they are necrotic. The few small pieces of the pelvis which are found in this specimen are swollen, hyperaemic, and covered with a purulent deposit.

Microscopical examination.—In sections prepared from this organ the alterations are those usually seen in embolic nephritis. It was interesting in this case to find only small abscesses which did not show any tendency to become confluent. The dark bluish foci, leucocyte-infiltrations, lay in the interstitia, and the commencement of a sinus in the tubules is well illustrated. The convoluted tubules are doubtless in several cases the starting point of the bacterial emboli, having as a sequel abscess formation, which after full development make it rather difficult to decide from where they originated. A few other places show rudiments of the glomeruli, and therefore probably these were the starting point of the inflammation. An enormous number of bacteria brought to the kidney produce symptoms like this; nearly in every

capillary a small embolus will be formed. This may take place in the glomeruli or in the interstitial tissue of the tubules. If they pass the glomeruli without causing any lesions they are generally retained in the convoluted tubules and there set up a purulent focus. The surrounding tissue of the foci is but little altered and only shows the commencement of a nephritis. When stained by *Weigert's* method for demonstrating fibrine, fresh network of fibrine is found in the abscesses and in the tubules. Bacteria could be easily demonstrated with methylene blue and Giemsa solution, and it seemed that the glycerine (the specimen was preserved in Kaiserling) had a mordant action on the bacilli. Leucocyte casts were fairly frequent in the tubuli recti.

Material collected from the following case was used for all the experiments described in this paper:—

Horse 3944.—Was used in a horse-sickness experiment, and from the 11th day showed a typical reaction. The two days preceding death were characterized by the presence of small abscesses and petechiae on the conjunctival membranes. The pulse was very weak and varied between 74 and 79. No abnormal position was assumed by the animal in passing urine.

Post-mortem.—Made on the 12th January, 1909; gelding, two and a half years old, condition fair, rigor mortis present; the subcutaneous and intermuscular tissue was slightly yellowish and the body fat was rather gelatinous. In the peritoneal cavity a small quantity of liquid was present. On opening the peritoneal cavity the kidneys were seen to be of a remarkable size. The peri-renal tissue was yellow and gelatinous, and a large quantity of liquid escaped on section. The adjacent muscular tissue and the serous membrane were thickened and oedematous (collateral oedema). The left kidney weighed 2·015 kilo. and had a diameter of 18·5 cm.; the right one weighed 2·340 kilo., had a diameter of 18 cm., and a thickness of 7·5 cm. The capsule was greyish white, rather thickened in parts and rough, covered with fibrous filaments. The blood vessels were very distinct, and the external layer of the capsule was distended, so that a space filled with liquid was formed between the tunica and the capsule. The capsule could only be detached in patches, the other parts remaining attached to the parenchyma, and it was only with difficulty that small pieces could be torn off. The capsule was adherent to the parenchyma of the kidney by means of small abscesses. In the right kidney an abscess containing a viscid yellowish pus was found under the capsule. The shape and size of the kidneys had naturally been considerably altered, and both were more or less roundish. The surface was only shiny in a few places, otherwise irregularly shaped, studded with small ulcerations and erosions. All these ulcers with their yellowish centres and the star-like irregular edges were surrounded by haemorrhagic areas. The whole colour of the kidney was dark red, at several places with a slight bluish tinge. This colour was irregularly intermixed with that of the small yellowish abscesses. The stellulae verheinii were nothing else than large haemorrhages, and showed fibrous edges; the consistence was very friable. On section the dark red haemorrhagic cortex showed longitudinal and punctiform abscesses, all containing slightly yellowish mucous, stringy, and odourless pus. The interstitial tissue which contained groups of embolic haemorrhages had nearly disappeared under the influence of the abscesses. In the intermediate zone these longitudinal abscesses were all situated at the same level and were of almost the same size. Very rarely a small well-defined abscess could be detected in the medulla. The papilla contained a considerable amount of blood, but no necrotic masses. The pelvis contained a viscid yellowish urine, and the mucous membrane was slightly congested. No ulcers could be found

on the mucosa; the mucous membranes of the ureters were slightly swollen, and near the urinary bladder a few small areas of effusion were noted. In the urinary bladder about 450 c.c. of a cloudy urine mixed with blood coagula was found, the mucosa was slightly oedematous; there were no epithelial defects or thickening. The peritoneum was shiny near the kidneys, slightly oedematous, and in the stomach was a small quantity of bile-stained contents. The mucosa was covered with thick dark yellowish deposit, the margin between the fundus and the pylorus being especially discoloured. The whole fundus portion was swollen and showed haemorrhagic infiltrations. In the middle of the fundus a tumour the size of a nut with a fine fistula contained a yellowish pus, but no worms. The mucous membrane of the duodenum was slightly swollen, bile stained, and showed greyish red discolourations. Several *Gastrus* larvae and a few *ascaris megalcephala* were present. The mucosa of the jejunum and ileum was swollen, folded and slightly congested, and covered with a bile-stained mucous deposit. Peyer's patches were normal. In the caecum the mucosa was slate coloured; the apex was spotted with haemorrhagic patches and ecchymoses. *Sclerostoma armata* and *tetracantha* were fairly frequent. The mucosa of the colon showed in the yellowish-grey mucous membrane a few small petechiae and nodules with caseous contents; several of these formed real ulcers. The serosa and the mesentery showed patchy areas of effusion, and the lymphatic glands were rather soft but not enlarged. The spleen measured $48 \times 50 \times 22$ cm., it was slightly enlarged, of a bluish grey colour, and the capsule showed a few sub-capsular ecchymoses. The pulp was dark brown, soft, and moist. Between the trabeculae the follicles could be easily detected. The lymphatic glands in the gastro-splenic ligament were slightly swollen, and this was the seat of the haemorrhagic infiltrations. Fibrous filaments could be found on the capsula glissoni. On section the liver was dark brown, the lobuli were not very distinct, but stasis could be noted in the vena centralis. In the left lobe were patches of greenish-yellow discolouration. In the pericardium was about 35 c.c. of a slightly blood-stained liquid. The heart was of normal size, and the epicardium along the sulcus coronarius were several small ecchymoses; the heart muscle was slightly yellowish in colour and flabby and soft in consistency; both endocardia were normal; there were well-formed coagula present. The surface of the pleura was rough, and showed irregularly defined patches, the colour varying between white and yellowish. Directly under the pleura and situated in the reddish lung tissue were several small nodules. On section these nodules showed a yellowish mucous centre which could be pressed out; they had a tendency to become confluent, and were generally surrounded by a fine capsule, but very rarely only a red demarcation line separated them from the healthy tissue. In the anterior lobe several egg-shaped haemorrhagic pneumonic infiltrations pointing to the centre of the lung were surrounded by gelatinous infiltrations of the interalveolar tissues. Both lobes of the lungs were oedematous and congested. Several mediastinal lymphatic glands were enlarged but did not contain nodules. In the trachea a small quantity of foam was noted, and the mucous membrane showed a few ramifications. The nasal cavity, larynx, and lymphatic glands of the head were normal.

Diagnosis.—Purulent nephritis, metastatic nodules in the lungs; horse-sickness. Parasitic nodules in the intestines.

Cause of death.—The animal was in a horse-sickness experiment and showed typical lesions of this disease; at the time therefore it was difficult to decide whether horse-sickness or purulent nephritis caused death. Observations on experimental cases showed a similar *post-mortem* appearance, and

I am inclined to think that the purulent nephritis (and not horse-sickness) with specific toxines produced the heart lesions and all the secondary alterations in the liver and intestinal tracts.

Urine.—Was dark yellowish in colour, but fairly clear with a white deposit; its consistence was slightly viscid and mucous, and its specific gravity was 1·018. The reaction was slightly alkaline (Esbach's albuminometer), 0·5 per cent. albumine, and albumoses were present; there was no sugar, methaemoglobine (Spectroscope), no reducing substances (Brezkatechin Hydroquinone). Phosphate (Uranacet) was found in small quantities. Microscopical examination showed carbonates, hippuric acid, triple phosphates, and a considerable number of epithelial cells of the urinary tract, the pelvis and Henle's tubules, leucocyte casts, red blood corpuscles, and bacteria. These bacteria were isolated by means of cultures, and the same organism as that in the kidney abscess was found. Bacteriological investigation revealed a gram-negative bacillus, which only grew on glycerine agar in pure culture. Not only in the pus of the kidney abscesses, but also from the lung-nodules this bacillus could be easily isolated. The injection of different nodules into male guinea-pigs gave an absolutely negative result, which also proves in a certain way that the glanderous nature of these lesions has to be excluded.

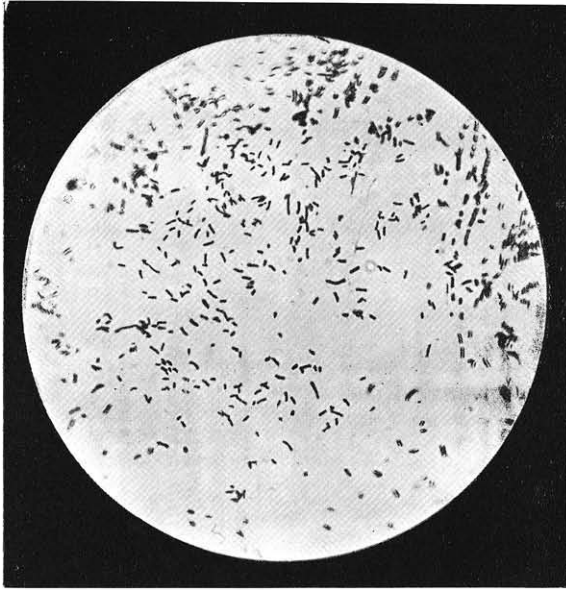
The histological alterations of the different organs were studied on paraffine sections stained with Van Gieson, Delafield haematoxyline, orange, Weigert's fibrine stain, etc. The organs were fixed in 8 per cent. formalin, concentrated sublimate with alcohol, and in absolute alcohol.

In frozen sections, stained with Sudan 3 a distinct fatty infiltration of the epithelial cells was found between the debris, and the cubical cells were often free in the tubules and studded with fine globules of fat. The leucocyte casts which were found in the tubuli recti also showed in several places well marked fatty degeneration. In an unstained preparation the destruction of the normal structure of the renal parenchym in general is at once noticeable; there was hyperaemia, diffuse haemorrhagic exudations, conglomerations of leucocytes in abscesses, etc., corresponding with the macroscopically detected lesions, and with the exception of the medulla it was rather difficult to find any normal tissue in the kidney.

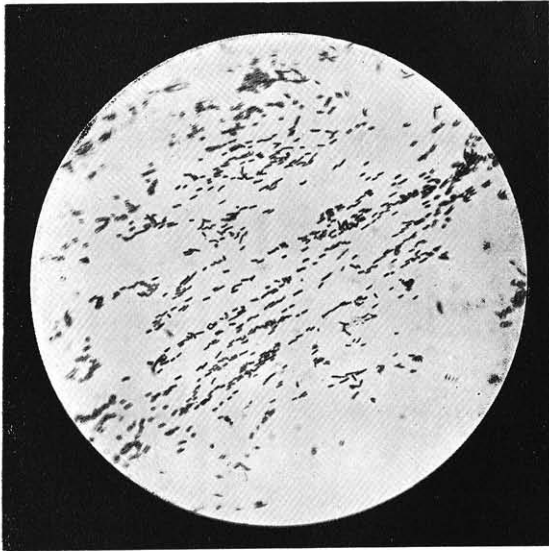
The tunica propria of the cortex is rather thickened, folded, and on the outer surface it was studded with leucocytes. Between the two parts of the tunica propria several considerably enlarged capillaries were surrounded by small haemorrhages. In other places abscesses in the cortex communicated with the longitudinal band of tissue by means of large leucocytic infiltrations. In the external parts of the cortex only a few leucocytes were found, but distinct haemorrhagic infiltrations of the interstitiae were noticeable. The convoluted tubules were compressed by blood corpuscles, and in the tubules themselves hyaline, fibrine casts, and desquamated epithelium were found. Along the basement membrane haemosiderine crystals were very frequent. Between the layers of Bowman's capsule hyaline albumous masses, leucocytes, and epithelial cells were found. The capillaries of the glomeruli were distended by erythrocytes. In the inner parts of the cortex more or less all tubules and glomeruli had disappeared, and the whole tissue was studded with leucocytes, forming large and small abscesses or only groups of a few leucocytes surrounding a small capillary which contained a newly formed thrombus. The abscesses generally start their initial stage from emboli in one of the arteriae rectae, and very rarely a glomerulus may be the starting point of the inflammatory process. Often in one section all the stages from the

embolus to the abscess may be observed. The external parts of these abscesses were rather dark, and infiltrated with leucocytes; the star-like filaments which were nothing else than the interstitial tissue protrude into the abscess. In a few cases small tubules filled with leucocytes and degenerated epithelial cells were found in the middle of these abscesses. The masses of leucocytes always showed a fine, easily stainable fibrinous stroma, and the surrounding capsule of the abscess was formed by a slightly thickened interstitial fibrous tissue showing an irregular haemorrhagic exudation. Not only the interstitiae in these haemorrhages but also the tubules were blocked with erythrocytes mixed with epithelial cells and a few leucocytes. In the medulla, longitudinal haemorrhages were found along with long areas of leucocytic infiltrations, varying in length from 150-300 μ , and are probably caused by blocking of the tubules and later themselves forming abscesses. Near the papillae the tubular casts had a hyaline character; the longitudinal foci of the intermediate tissue were formed by leucocytes which often caused atypical bulging. The tubular casts were always spotted on the surface by desquamated epithelial cells. It was interesting to demonstrate in a few sections the bacilli in these casts, and we can therefore state that these casts retained the eliminated bacteria and gave rise to a new inflammatory process. Necrosis and abscess formation may occur as a sequel. The different parts of the arteriae rectae and the capillaries are throughout the whole tissue distended by blood cells. Near the papillae the parallel channels are filled with blood cells and are very distinct. In the excretory ducts near the papillae a well pronounced epithelial degeneration with the beginning of necrosis is often observed. The mucous membrane of the papillae and the pelvis shows distinct blocking of the capillaries, and has the appearance of a desquamating catarrh. No signs of resolution could be observed in the whole kidney tissue. All the symptoms and lesions were in the acute stage of the development, and would of necessity cause death. Greyish nodules were embedded in the sub-pleural tissue, and often also in the lung tissue along the trachea and even throughout the parenchyma in general; they were usually of the type of a pneumonic infiltration with central conglomeration of leucocytes in the alveoli. Near a bronchus or one of the blood vessels the alveoli were infiltrated with leucocytes entering through the walls of the blood vessels which were rather thickened. The lumen of the blood vessel, which is usually found in the middle of the nodule, showed red blood corpuscles, blood platelets, fibrine, and a few leucocytes. The endothelium of the blood vessels was slightly swollen, and the structure of the walls was generally indistinct. Around each, to the extent of about 0.4 to 0.6 mm., the whole tissue contained leucocytes, epithelial cells, and bacteria. The bronchi usually showed no lesions; a few of the surrounding alveoli showed a slight infiltration. In several cases between the mucous glands, a rupture of the lumen had occurred, and consequently the lumen contained a purulent deposit of cast-off epithelium. The surrounding zones of the nodules showed always a distinct filling of the blood vessels of the alveolar septa; a slight fibrinous serous exudate was found in the alveoli, and rarely a catarrhal desquamation of the alveolar epithelium. The infiltration therefore protrudes into the normal tissue. The haemorrhagic infiltration varies in the different nodules according to the age of the infection. Several pneumonic infiltrations showed a capsule-like thickening of the interstitial tissue of the septa, but caryorhexis or necrobiosis could never be observed in the centre of the nodules. It is therefore distinct from the glanders nodule.

The blood vessels in the middle of these foci always contained a small thrombus which seemed to be comparatively newly formed. In several places intact red blood corpuscles and leucocytes in normal proportions were found.



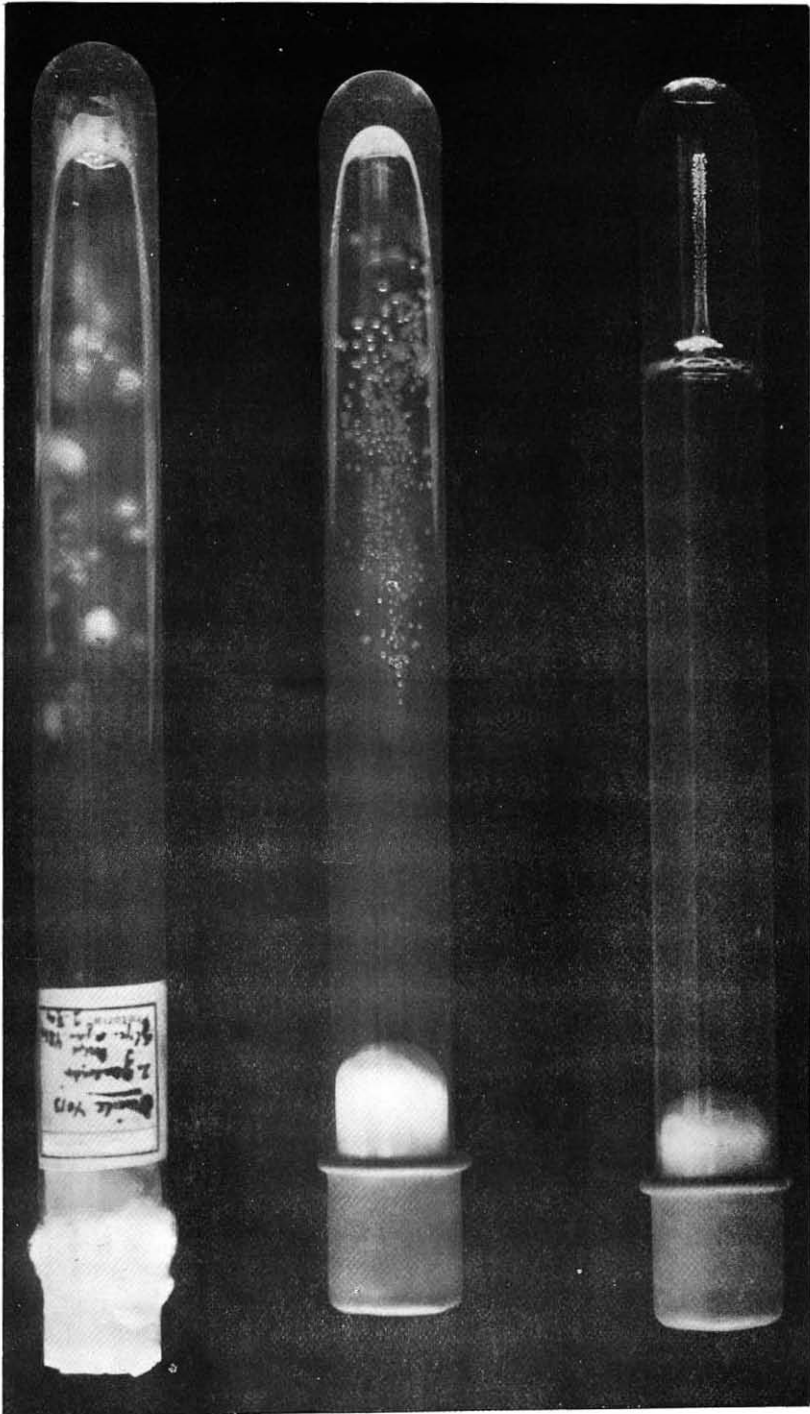
(a).



(b).

Bacillus nephritidis equi :—

- (a) Glycerine agar-culture ; 24 hours old, diluted carbol-fuchsin (1:950)
- (b) Serum culture ; 48 hours old, diluted carbol-fuchsin (1:950).



Growth of the *Bacillus nephritidis equi* :

- (a) Stab culture in alkalic gelatine, 8 days old at 23°.
- (b) Stroke culture on glycerine agar; strain A, generation 6; 24 hours old at 37°.
- (c) Stroke culture; glycerine agar, isolated from mule 4013; generation 1, 24 hours old at 37°.

The presence of nodules in the peripheral layer of the lung tissue under the pleura indicates the embolic origin of the whole nodule. This embolus may be formed in two different ways: (1) the bacteria may be carried in the blood stream into the smaller pulmonary arteries, where they produce thrombosis, arteritis, peri-arteritis, and all the sequelae; or (2) the bacilli alone are the exciting cause; the subsequent emigration of leucocytes and red blood corpuscles producing an infiltration in the peri-bronchial, inter-lobular, and alveolar tissues, before a real thrombus has been formed. The sequel of this is then naturally similar to that described under (1). In both cases small pneumonic infiltrations are formed, and by filling of the alveoli the typical white nodules are formed. The lesions in the lungs are therefore also of a haematogenous origin and have the same source as those of the kidney.

BACTERIOLOGICAL INVESTIGATION.

(1) *Morphology of the micro-organism.*

In the smears made from the viscid pus of the kidney abscesses and the lung nodules, a micro-organism was found. This was a rather long, thick, bacillus with rounded edges, and only staining with difficulty. The length varied between 0.5 to 0.8 microns. As a rule no characteristic grouping was found; in a few cases an arrangement resembling that sometimes seen in cholera was noted. This arrangement, however, is merely due to the mucosity of the purulent material, and may be seen in any preparation of cultures of most bacteria if mixed with the mucus of frogs' eggs. In rare cases micro-organisms and bi-polar bacilli forming streptothrix filaments were seen. The typical pleomorphism seen in the cultures was never noted in the material isolated from the organs. In sections, compact easily staining masses are generally noted, and under the influence of acids these masses become slightly enlarged and permit of the demonstration of short bacilli. The numbers of bacteria do not stand in any relation to the lesions observed macroscopically; for example, the largest abscesses often contain only a small number, and it may be difficult to find the specific organism. Phagocytosis is rarely observed. No proofs could be given that the chemical constituents of the bacillus influenced phagocytosis. Similar cluster-formation was also observed in the urine of animals suffering from purulent nephritis. The identification of the bacillus is rather difficult, and probably only possible for the experienced observer, since other bacteria are also seen in the urine, which have the same staining reaction as the nephritis bacillus. Morphological variations of the bacillus are more pronounced in cultures than in the tissues, but during the experiments the characters of the bacillus were found to be fairly constant in cultures. In a twenty-four hours old glycerine agar culture the bacilli were found to vary in length, but showed a parallel arrangement and had sharp cut ends. In size the bacillus most resembled the tuberculosis or glanders bacillus; bi-polar staining was never observed. On microscopical examination the bacilli were grouped in irregular clusters. In cultures about six days old, short and cocciform forms were frequent, and this appearance might lead one to think that the culture was impure, but tests always revealed its purity. After repeated cultivation the form of the bacillus changes to that of a long filament, this being in my opinion an involution form. In milk and bouillon cultures, fine and rather long bacilli were more frequent. From the fifth day the pleomorphism was pronounced, and the affinity for ordinary staining was found to vary greatly. Cocci-like forms were generally found in peptone solution and serum. Dividing forms were very rare. Generally it could be noted that the morphology of the bacillus grown under the same conditions and on

the same medium showed considerable variations. Passage through animals often had an influence on the morphology of the bacillus, but at the same time the cultural characters were altered, as will be seen later. All these observations, together with the facts published by other authors (*Degen, Grixoni*), regarding the pleomorphism of the bacterium shows that probably the growth in the kidney, under the influence of the urine and other chemicals, may cause these alterations.

In hanging drop preparations the bacillus never showed any signs of motility, and in preparations stained by Pepper's method, no flagella were seen. Spores or resistance forms could never be observed.

(2) *Staining.*

As the surrounding membrane of the bacillus consists of a thick mucid substance, staining with the simple aniline dye was very difficult. The best results were obtained with diluted fuchsin, gentian violet, or giemsa solution. The smears treated with diluted acetic acid showed a swollen irregular mucous capsule. The bacillus could never be stained by Gram's method. In pus smears the bacillus stained best with Loeffler's methylene blue, and slightly better results were obtained by a slight differentiation with acid alcohol. Metachromatic bodies could never be shown by any method. The new prescription from burri with Indian ink gave very good results. As a rule only a few bacteria could be detected in the lung nodules.

(3) *Biology of the organism. Growth on different media.*

Gelatine plates.—The bacillus grew very slowly; after two to three days, small punctiform colonies strongly adherent to the surface of the medium appeared. They reached the maximum size of a pin's head and were greyish, shiny, and soft. Ten days afterwards these colonies had slightly sunk in the medium and were surrounded by a small quantity of diluted and liquefied gelatine. The colony itself was more convex and dull; the growth seemed to stop at the end of the sixth day.

When magnified by fifty diameters the cultures showed finely granular round colonies with a sharp or slightly irregular margin. The size of the granules in the different colonies varied according to the age of the culture. In colonies which were ten and twelve days old the edges showed fine filaments, protruding into the surrounding liquified zone.

Stab cultures.—Stab-cultures in gelatine showed an appearance resembling that of a nail. At first the growth was filiform, and after five to six days showed fine punctiform white discrete colonies along the needle track. The growth showed regular lateral branches throughout its course with a typical line of dots. The colonies did not tend to become confluent. When ten to twelve days old the "head" had a diameter of two to five millimetres. It was irregular, lobulated with folded margins, and slightly yellowish in colour. From the 7th day a slight liquefaction in the upper part of the needle track commenced and a small bell-shaped depression formed with its maximum size at the 14th day. The deposit of the liquid mass was whitish and flocculent and accordingly the whole "nail" seemed to sink into the gelatine.

Agar-plate.—The strain never showed any growth on this medium.

Glycerine agar—slightly alkaline.—In twenty-four hour old plate cultures were seen, small, whitish, shiny, and slightly conical colonies about the size of a pin head, and very adherent to the medium. The bacterium isolated directly from the body showed only a few large and very shining colonies; after forty-eight hours the colonies had only slightly increased in size; they had a white centre and slightly yellowish edges. The large and small colonies

were very viscid and of mucous consistence, and filaments of mucus of 30 centimetres in length could be easily withdrawn by touching with the needle. No colonies were seen in the depth of the medium.

When magnified by fifty diameters, the colonies were seen to be round with a regular margin, convex, dark, and opaque; the margin adhered to the medium. The large colonies had a transparent periphery which was slightly granular and the centre was homogenous and grey.

Stroke culture.—Colonies resembling those on agar-plates were noted and showed no confluence. On a freshly prepared and still moist medium the colonies showed a pronounced tendency to extend. The mucous consistence and adherence to the medium was very remarkable. The water of condensation was mucous and very stringy, forming a whitish mass which after twenty-four hours had separated into a clear upper part and a whitish deposit. The upper part was viscid and did not moisten the glass. The growth had reached its maximum at the end of forty-eight hours. When making sub-cultures, a certain amount of the medium was always removed, because the culture was very adhesive to the medium.

Stab-cultures.—After twenty-four hours, filamentous, whitish slightly granular streaks of growth were found along the needle track; the surface was irregular and very shiny.

Serum-Glycerine Agar.—On this medium the growth was quicker and more abundant when the serum used was obtained from a horse. The colonies were very soft and attained a larger size than on other media.

Urine agar.—The growth was very slow and a distinct brown discolouration of the colonies was noticeable.

Brain-agar.—The growth was very slow, similar to that on glycerine agar.

Agar-shake cultures.—After twenty-four hours only a few round white colonies were seen on the surface, or only 1 centimetre below. These colonies did not continue to grow and no breaking-up of the medium occurred.

Ascites agar, or agar mixed with pleural exudate (horse-sickness).—The growth was very good; similar to that on serum agar.

Serum (horse, cattle, sheep, and dog).—(a) Liquid.—After eighteen hours a thick, more or less, compact deposit occurred. The whole medium became very viscid and mucus, and filaments of mucus were easily drawn off. The bacterium seemed to live longer in this medium than in others. A small quantity of nutrose did not seem to have any influence on the growth or the morphology of the bacteria.

(b) Coagulated.—After twenty hours fine clear and round colonies, which were rather adherent to the medium and showed no confluence, appeared. The water of condensation became very viscid and showed a whitish flocculent deposit. The formation of mucus was more distinct when grape sugar or glycerine was added to the serum, and strings up to the length of 1 metre could be withdrawn. Analogous appearances have only been obtained with the micro-coccus *Freudenreichii*.

Bouillon culture.—After twelve hours the medium was slightly turbid, and a distinct deposit was formed. After twenty-four hours the upper part was quite clear and the deposit was rather tenacious and of mucous consistence. By shaking, a tuft-like formation of the lower part was obtained which remained for some time because the whole medium was very viscid and mucus. The growth continued for the next few days when carbo-hydrates or polyvalent alcohols were added to the medium. The growth was very poor in ordinary pettone bouillon. A small quantity of serum gave a better growth and a

more viscid deposit. In grape sugar-bouillon no gas was produced, and a similar growth to that in the glycerine bouillon was observed. After twenty-four hours the reaction was distinctly acid. The viscosity of the sub-stratum became greatly increased under the influence of carbo-hydrates. Several of the organic compounds were tested, as the following table shows:—

In the preparation of the medium used for the following tests 1 per cent. of substance was added to an ordinary bouillon broth.

	Substratum.	Formation of Mucus.
Monosaccharides	Glucose	Distinct.
	Mannose	Distinct.
	Galactose	Distinct.
	Fructose	Distinct.
Pentose	—	Slight.
Disaccharides	Maltose	Slight.
	Lactose	Slight.
	Saccharose	Slight.
Polyvalent-alcohols ..	Erithrite	Slight.
	Dulcite	Slight, but distinct with a five day old culture.
	Mannite	Slight.

It can be easily demonstrated that the monosaccharides assist in the formation of mucus. The polyvalent alcohols, with the exception of dulcite, did not give positive results. The dulcite became split up into dextrose under the influence of the acid produced in the medium, and this dextrose, as a mono-saccharide assisted in producing the mucus. The vitality of the bacillus in these media is but low, and generally three days after inoculation they died out.

Loeffler's blood serum, lime-bouillon, bouillon-martin, serum-bouillon, urine bouillon (1 : 2).—All gave more or less typical growth, but without any definite characteristics which could be used for diagnostic purposes.

Blood-agar (horse or rabbit blood).—After twenty-four hours small slightly reddish shiny colonies were seen, but the surrounding zone never showed any haemolytic discolouration. Cultures four days old showed a dirty brownish discolouration.

Potato-culture.—Repeated attempts to obtain potato cultures all failed. Glycerine or sugar added to this medium did not favour growth.

Glycerine-potato bouillon and glycerine-potato agar (Nicolle).—Similar growth to that on ordinary bouillon or ordinary agar was noted.

Milk-culture.—During the first day no changes were observed. After thirty-six hours the liquid was viscid, adherent, and mucus. The test tube did not become moistened, and with the platinum needle long mucous strings could be stripped off. Typical coagulations were formed 64 to 70 hours afterwards, probably under the influence of the acid formation by the bacillus.

About the third day the bacteria began to die out, and the character of the medium became gelatinous and syrupy. On the fifth day, a flocculent adherent deposit of casein coagula was seen on the bottom of the tube. The upper part of the medium was very viscid. This fact was so characteristic that it can be used for diagnosis, because no other bacteria, with perhaps the exception of the micro-coccus *Freudenreichii* showed such a formation of mucus in milk.

Petruschky's litmus whey.—On this medium the bacteria produced a typical acid formation of lactose. After two days the slight violet colour changed to a typical red and on the bottom of the medium a viscid mass similar to that described above was formed. The third day the whole medium was slightly turbid, and in several cases resembled that observed in milk. No growth was observed in medium covered with a layer of paraffin.

Peptone solution.—The growth was very weak. A fine deposit was noticed twenty-four hours later.

Media without albuminoids.—No growth was seen. Occasionally the formation of a small deposit was observed, but in these instances a small quantity of the former medium was transmitted along with the bacteria. When carefully conducted no growth was observed.

Litmus milk-sugar agar plates (Conradi-Drigalski).—This very useful medium for the identification of the bacillus in the intestinal tract demonstrated the considerable amount of acid formation produced by this bacillus. About twenty-four hours after inoculation, well-formed viscid and adherent colonies surrounded by a red zone were seen. After forty-eight to sixty-four hours the whole plates had nearly changed into a red colour. The mucous consistence of the colonies was considerably reduced.

Endo-fuchsin agar.—After twenty-four hours the colonies were a deep red colour, and in older cultures slightly fluorescent. The fuchsin stain seemed to accumulate on the colonies; controls with bacteria coli never showed the same red tinge as the nephritis bacillus. This medium can, therefore, be used for diagnostic purposes.

Malachite-green agar (Loeffler).—On this medium no growth could be observed. The growths on the different media containing stains, such as "neutral red", "orzein", etc., showed that no reduction of stains had occurred.

Temperature.—The bacillus was strictly mesophile, under 20° C. no growth was observed; at 22° C. the growth was very poor and slow; the optimum was 37° C. It may be stated here that the temperature had a certain influence on the vitality, because cultures grown at 25° C. were still alive after twelve days. Others grown at 37° C. died out after four days.

Chemical actions.—Indol was never formed in peptone bouillon, neither was there any formation of H_2S ; no smell and no colouration was noted, but the formation of acid and mucus was typical and always found in culture of the nephritis bacillus.

The results on the different media showed that the formation of mucus is connected with the quantity of suitable carbo-hydrates available. I am unable to decide at present whether we have a typical formation of galactan (Scharidinger), or only a swelling of the capsule of the bacillus.

Fermentation was found to occur in connection with the formation of mucus from different kinds of sugar, and several polyvalent alcohols. None of these showed any gas production. Acid fermentation due to a reduction of glucose, manose, galactose, fructose, maltose, dulcite, or mannite was observed.

Several experiments proved also that a toxine was produced in the cultures. This peculiarity of the strain will be noted later. The bacillus is an obligatory aerobe; different methods (pyrogalic acid, hydrogen, etc.) were used but all efforts to obtain growth under anaerobic conditions failed.

Vitality and resistance.—A temperature of over 50° C. kills the bacillus immediately. Diffused daylight acts almost in the same way, and cultures die after 20 to 35 minutes' exposure. Several chemical disinfectants were roughly tested, and showed that the bacillus is not very resistant. Sublimate and lysol solutions had an immediate action. The vitality on the different media is very low. As soon as the medium had become rather dry, as was observed in the incubator three days after the inoculation, the culture could not be transmitted with success. The conditions were a little better in bouillon cultures grown and kept at a temperature of 22° C. where the bacteria remained alive for about 10 to 14 days. It was therefore necessary to transmit the bacillus into a fresh medium every 48 to 72 hours, otherwise there was always the risk of the strain dying out. By this means the bacillus adapted itself slowly to the medium and although the growth was more or less abundant, its virulence rapidly decreased. This decrease in virulence was very clearly shown in several experiments, and it is probably a peculiarity of all the nephritis bacilli in domesticated animals, as *Degen* observed it, also with his bacillus polymorphus suis, and all his negative experimental results with the bacillus were probably only due to an attenuation in virulence.

Distribution in the animal.—(a) Normal.—Microscopically or by means of cultures the bacillus could never be detected in purulent lesions such as abscesses, suppurating wounds, canker of the foot, pneumonia or other alterations. During the last year quite a collection of purulent material was inoculated on the medium used for the identification of this bacillus, but the bacillus could never be traced. Outside the body it is probably very difficult or impossible to find it because its resistance against climatic influences is very slight. I shall return to this question when referring to the pathogenesis in general.

(b) *Pathological.*—The bacillus was found in the purulent lesions in the kidneys, lungs, and in the urine. In experimental cases it could be detected in the spleen, liver, and other glandular organs. As far as could be proved by the experiments, the bacilli were eliminated with the urine and this is probably the manner in which infection is carried to animals standing in the same stable. On the other hand, it is not impossible that the bacillus lives as a saprophyte in the healthy body and under certain conditions is able to multiply and cause all the lesions characteristic for the disease.

The pathogenic action of the bacillus was shown by the following experiments carried out on animals of the same species, and also on small laboratory animals. At the same time, I will refer to the reactions in sick animals.

ANIMAL EXPERIMENTS.

The question had to be settled whether it would be possible by inoculation to produce similar lesions as those seen in the original cases. Inoculation was first of all carried out on equidae and later also on guinea-pigs, rabbits, sheep, goats, dogs, cattle, and fowls. Toxine experiments were only carried out on horses and guinea-pigs.

(a) *Equidae (horse, mule, donkey).*

Experimental infection was attempted by subcutaneous, intravenous, intravesicular, and intraocular injections. The material was suspended in

normal saline solution, and in order to overcome the mucous consistence and to prepare homogenous suspensions, the liquid was shaken for a while and filtered through blotting paper. This was necessary in order to avoid embolism. At the beginning the experiments were successful, but later when the virulence had diminished, the bacillus was harmless.

(1) *Subcutaneous injections*.—Horse 3746 was injected on the 25th January, 1909, subcutaneously on the left shoulder with 15 c.c. glycerine agar culture, strain "A", generation 5. On the 26th January, 1909, the temperature was 98.7° F.; in the evening, 102° F.; at the place of injection a hot, painful swelling was formed; the animal looked dull and did not feed well. Slight injection of the conjunctival membrane was noted. On the 27th January, 1909, the temperature was the same, a distinct swelling from the scapular crests to the elbow joint was noticeable, with a slight fluctuation in the middle and collateral oedema in the muscles and subcutaneous tissue. The animal was not feeding well on this date. Ecchymoses on the conjunctival membranes were present. On the 30th January, 1909, the swelling extended from the seat of injection down to the fetlock joint. In the middle an abscess the size of an apple was formed. The appetite was a little better, and the temperature had slightly decreased. On the 31st January, 1909, a puncture of the abscess revealed a clear viscid pus. Bacilli resembling those injected were found on microscopical examination and these were isolated in pure culture. The urine contained small quantities of albumine, but no bacteria. On the 16th February, 1909, the swellings at the shoulder were absorbed, and a hard fibrous growth was found at the seat of injection. The general health was normal. The animal was killed on the 8th March, 1909, that is forty-two days after inoculation.

Post-mortem examination.—Gelding; condition good. On the left shoulder the subcutaneous tissue was slightly thickened, otherwise normal. In the pericardium was a small quantity of liquid. A few small vessels were slightly injected. Both ventricles were normal. A few nodules were present, otherwise the lungs were normal. The liver was slightly discoloured, dark brown on section, and contained a few calcareous nodules, about the size of a pin's head. The spleen measured 46 × 49 × 22; the pulp was normal. Both kidneys were embedded in normal fat tissue, the capsule could be easily stripped off. The parenchyma was slightly greyish-brown; in the middle of the cortex were two small slightly prominent nodules of a yellowish colour and of the size of a pea. On section they appeared wedge-shaped, entering through the cortex into the intermediate zone, and in the middle of the zone were a few petechiae. The injection of the glomeruli was very distinct. In the cortex of the right kidney were two small nodules, apparently infarcts. The tissue showed a slight hypostasis. The pelvis, ureters, and the bladder were normal. The stomach and intestines were normal. In the anterior mesenteric artery was a parasitic aneurism. All the other organs were normal.

Diagnosis.—Chronic interstitial nephritis, a few infarcts in both kidneys. Old glanders lesions in the lungs. Cultures were negative. Complement deviation with extract of glanders bacillus was positive, and that with nephritis bacillus negative. At the beginning of the disease the serum had not been tested. Microscopically the macroscopic diagnosis could not be confirmed. Histologically the two small infarcts showed small structures resembling adenoma of the papillar type. Portions of various sizes were divided by septa on which small cubical and epithelial cells (showing fatty degeneration) forming real villi. In the lumina a small quantity of coagulated albumine was found. The surrounding interstitial tissue was slightly thickened. The tubules themselves were slightly compressed, and the epithelium partly degenerated. We

can therefore come to the conclusion suggested by *Ribbert*, namely, that the adenoma is a direct sequel of an interstitial nephritis. It cannot be definitely decided whether the specific bacillus is the real cause.

(2) *Intramuscular injections*.—Another strain of a higher generation was used for the intramuscular injections.

Horse 3049 was injected on the 19th March, 1909, with 20 c.c. glycerine bouillon culture, strain "B", generation 8, into the left anterior deep pectoral muscle, and with 20 c.c. of the same culture in the serratus magnus of the right side. On the 20th March, 1909, a slight swelling at the seat of injection was noted. The urine was normal. On the 22nd March, 1909, behind the shoulder of the right side a hot and painful tumour the size of a child's head was noticed. On the left shoulder there was a flat swelling the size of a hand. General health of the animal was normal. In the urine a small quantity of albumine was present; specific gravity was 1.045. On the 23rd March, 1909, all local reactions had partly disappeared. About 100 days after injection the general health and the urogenous organs were normal. Several urine tests gave negative results. Control tests with the same strain proved a diminution of the virulence.

(3) *Intravenous injections*.—*Horse 3885* injected intravenously on the 30th January, 1909, at 11.30 a.m. with 25 c.c. nephritis bacillus culture, strain "A", generation 6. In the evening of the same day the temperature was 104° F., and the following morning 102° F., reaching 103° F. in the evening. Distinct depression and slight dyspnoea was noticeable. The appetite was bad; 3.3 litres of urine were passed in the first twenty-four hours; it was of a slightly yellowish colour, of a mucous and stringy consistence and slightly turbid with a large deposit. Specific gravity was 1.025; the reaction was strongly alkaline; albumine amounted to 0.6 per cent., and a few phosphates were present. Microscopically, epithelial cells, leucocytes, casts, carbonates, and crystals of triple phosphates could be detected. The typical bacterium mixed with other bacteria, especially staphylococci were seen in culture. A few colonies of the nephritis bacillus were then isolated. On the 1st February, 1909, the temperature in the morning was 103.8° F., and in the evening, 104.6° F. The same symptoms were present, the albumine amounting to 0.9 per cent.; the urine was flocculent with a mucous sediment. On the 2nd February, 1909, the temperature was 104.2° F. The pulse could not be detected; there were ecchymoses on the conjunctiva which showed a slight yellowish discolouration. Trembling of the muscles was noted; 1.5 litres of urine were passed; it had a flocculent deposit and the upper part was almost clear; the phosphates had increased. Microscopically renal epithelial cells, epithelial casts, red blood corpuscles, leucocytes, carbonates and triple phosphates were seen. The animal died at 3.30 p.m.; namely seventy-six hours after inoculation.

Post-mortem examination.—Condition good. In the peritoneal cavity was a small quantity of yellowish serous liquid. The peritoneum was in all parts shiny. The stomach was contracted and slightly folded, with a small quantity of contents. The fundus was hyperaemic, and near the pylorus was a slight yellowish discolouration. The mucous membrane of the duodenum was slightly congested and covered with an adherent mucus. The jejunum showed a yellowish slate colour and was contracted, with a small quantity of contents. The mucous membrane of the ileum was folded and showed haemorrhagic

patches and longitudinal streaks. The caecum was distended with a quantity of liquid. The mucous membrane of the apex was diffusely hyperaemic. There was a slight swelling of the Peyer's patches. In the colon was a small quantity of dry food, and the mucosa showed a few capillary ramifications. The lymphatic glands were normal. In the mesentery were a few hyperaemic patches. The spleen was slightly enlarged and the sub-capsular vessels were injected; the capsule had a dark greyish colour, the pulp was reddish-brown, and the follicles were slightly swollen and protruding. The lymphatic glands in the gastro-splenic ligament were slightly succulent. The liver was somewhat swollen and showed a few fibrous filaments on the capsule. The parenchyma was slightly congested, and a few lobuli showed greyish discolouration and slight enlargement. The bile ducts were rather thickened and contained a dark yellowish bile. Both kidneys were embedded in an oedematous infiltrated mass, the right one weighed 1.260 kilo. and the left one 1.430 kilo. In stripping off the capsule small pieces of parenchyma were torn off. Between the propria and the parenchyma a few small abscesses were noted in the right kidney; and an abscess flattened in shape was found. On section the haemorrhagic infiltrated cortex showed round and longitudinal abscesses containing viscid pus. In some cases the tissue surrounding these abscesses appeared normal and in other cases they showed a haemorrhagic infiltration. Abscesses in the medulla were not observed. The blood vessels of the papillae were also slightly congested. In the pelvis there was a small quantity of urine. In the urine bladder was 50 c.c. of a turbid urine. In the pleural cavities about 100 c.c. of a clear liquid was present. Both lobes of the lungs were in inspirium. The pleura showed a few whitish yellow patches, and was distinctly oedematous. Throughout the whole lung tissue, but especially under the pleura, small slightly prominent nodules were found the size of a pea. The nodules were surrounded by a capsule-like thickening of the septa and contained purulent debris. In the right anterior lobe were a few old pneumonic infiltrations (stages 2 and 3), the parenchyma contained at these places a few abscesses with greenish pus. In the middle part of the left middle lobe was a pneumonic egg-shaped focus the size of an apple. In the middle of this a small thrombus of an artery was found (infarct). The mediastinum was slightly gelatinous. On the capsule of the bronchial glands a few ecchymoses were found. There was foam in the trachea, and the mucosa showed a few ecchymoses. In the pericardial cavity were a few drops of liquid. The heart was distended in diastole. On the epicardium along the auricles and the sulcus coronarius were petechiae, and near the apex a few livid areas. The whole myocardium was of a grey colour and soft. In the left ventricle were a few white patches. Both endocardia were normal. The sub-maxillary lymphatic glands were embedded in a thick fibrous tissue, and showed cicatrization. *Streptococcus equi* was present in smears from the pneumonic infiltration. In the nodules found in the kidney, spleen, and liver the nephritis bacillus was rather frequent.

Diagnosis.—Pyaemia and toxæmia as a sequel of nephritis.

Old strangles-pneumonia.

Cause of death.—Paralysis of the heart due to the toxine.

Histological investigation showed distinct fatty degeneration in the muscle fibres of the myocardium. In the liver the fatty degeneration was also very pronounced, the stasis in the central veins gave the whole tissue an irregular shape. The lung nodules showed the same structure as described in the

original case. There were also leucocyte infiltrations of the alveoli, generally near the bronchus, and surrounded by hyperaemia and haemorrhages, thus showing the great activity of the toxine. The large pneumonic infiltrations also showed the character of a haemorrhagic infarct with distinct filling of the alveoli with red blood corpuscles. The septa were in several places indistinct. Pigmentation was noted at the edges of the infarcts. A hyperaemic zone divided it from the normal tissue. In the kidney the pus foci were smaller than in the original case, and all showed a retrogressive tendency. The external parts of the cortex were especially affected. These foci were of a round or oval form; where they were connected with the convoluted tubules they formed an irregular sinus. The surrounding tissue was rich in red blood corpuscles and gave the whole kidney the character of an interstitial haemorrhage; the epithelial cells were granular, the contours of the cells were irregular, and the nuclei could not be easily stained. The different stages of the alterations in the channel system, casts with leucocytes, etc., were frequent, but signs of resolution could never be observed.

Horse 4300.—Injected intrajugularly on the 8th February, 1909, with 10 c.c. of nephritis bacillus cultures, strain "A", generation 9. The clinical symptoms noted during the first three days were slight depression, diminished appetite, and weak pulse. The temperature on the morning of the 4th day was 103° F., and in the evening 105·8° F. In the morning of the 6th day the animal was found lying in the stable; there was a jerky respiration and the pulse could not be detected. The complement deviation with glanders bacillus extract was positive; agglutination was obtained with a dilution of 1:800. The result with nephritis bacillus extract was positive with 0·5 c.c.

Serum.—The examination of the urine showed the following results:—On the first day at 6 p.m., specific gravity, 1·045; a small quantity of albumine and nephritis bacillus. Second day, dark yellowish turbid and flocculent deposit, reaction alkaline, specific gravity 1·022, and albumine amounted to 0·3 per cent. Microscopically triple phosphates, hippuric acid crystals, pieces of hyaline casts, epithelial cells, and leucocytes were seen. During the next few days the examinations were as follows:—

	Specific Gravity.	Albumine.	Albumose.	Haemoglobine.
3rd day..	.. 1·024	0·25 %	Positive	Positive
4th day..	.. 1·015	0·5 %	Positive	Positive
5th day..	.. 1·005	0·5 %	Positive	Positive
6th day..	.. 0·01	1·6 %	Positive	Positive

On the first day, in the flocculent deposit and mixed with leucocytes, the injected bacteria could be demonstrated. From day to day they increased in number. On the fourth day the blood showed a distinct polynuclear leucocytosis, with about 82·4 per cent polynuclear leucocytes. The animal died on the 14th February, 1909.

Post-mortem examination.—Gelding, ten years old; fair condition; rigor mortis not present. Several muscles were rather oedematous. In the peritoneal cavity were a few drops of liquid. The position of the intestines was:

normal. In the caecum was a small quantity of contents; the slate coloured mucous membrane showed red haemorrhages. *Sclerostoma armatum* and *tetracanthum* were fairly frequent. The colon contained a small quantity of contents, and the mucosa was slightly swollen and diffusely hyperaemic. Nodules with a greyish dry cement-like contents with a distinct capsule were frequent in the mucosa. The ileum was contracted and the mucosa showed longitudinal ramifications of the blood vessels. The jejunum was hyperaemic in patches. The duodenum had a small quantity of bile-stained contents adherent to the slightly hyperaemic mucous membrane. The lymphatic glands of the mesentery were slightly enlarged, and on section were grey, soft and partly congested in the sinus. The stomach contained a small quantity of undigested food, the fundus showed hyperaemic patches and superficial erosions. The kidneys had a gelatinous oedematous capsule, and were not much enlarged. The left kidney weighed 775 grams, and the right one 797 grams. The capsule was easily detachable, with the exception of a few small places where the parenchyma remained attached. The colour was slightly bluish, with a slight red and distinct injection of the *Stellulae verheimii*. The tissue was very friable and soft. A small number of yellowish abscesses protruded through the cortex. On section they contained a small quantity of a viscid yellowish pus. The whole cortex showed dark haemorrhagic infiltrations with a few slightly yellowish streaks. The intermediate zone, medulla, and pyramids were oedematous and hyperaemic in patches. No abscesses were seen in the medulla. The papillae were rather whitish, the pelvis and the calices contained a small quantity of urine. The mucous membranes were slightly swollen and showed a few ecchymoses. Both ureters and the urinary bladder were normal. The spleen was enlarged, measuring $28 \times 52 \times 60$ cm.; the capsule was greyish blue, the trabeculae were distinct and the pulp was dark and rather dry. The malpighian bodies were slightly protruding. The liver was of normal size, on section it had a mottled appearance, with injection of the central veins and discolouration of a few lobuli. In the pleural cavities a small quantity of liquid was present. The pleura was shiny, and both lobes were in inspirium. Under the pleura were a few small, rather hard, nodules the size of a pea. In the middle of the parenchyma they were rather rare. On section these nodules showed a whitish centre and a membranous thickening of the tissue. None of them showed a red zone. A few nodules were calcareous. There was a slight oedema and hyperaemia in both lobes. In the bronchi and trachea was a small quantity of foam. The mediastinal, bronchial glands were slightly enlarged and soft. There was hyperaemia in the sinus. In the pericardium was about 50 c.c. of liquid. The heart was slightly enlarged, and was in diastole; in the left ventricle was a dark greyish discolouration of the myocardium. The blood vessels along the sulcus coronarius showed distinct injection. In the surrounding tissue were a few petechiae. The myocardium was soft, and on section had a rather mottled appearance. The left ventricle contained badly coagulated blood. The whole endocardium showed whitish patches. The right ventricle, endocardium, and valves were normal. In smears from the lung nodules, bacilli similar to the glanders bacilli were detected. Two guinea-pigs injected with material from these nodules died of typical glanders thirty-four days later. In the kidney abscesses the typical nephritis bacillus was demonstrated.

Diagnosis.—Toxaemia as a sequel of purulent nephritis, old glanders lesions in the lungs, parasitic nodules in the intestines.

In cultures from the heart, blood, kidney, liver, and spleen, the nephritis bacillus could be isolated.

Microscopically, the same lesions as described above were demonstrated.

Mule 4013.—Injected intravenously on the 16th February, 1909, with a twenty-four hour old glycerine agar culture, strain "B", generation 2. On the first and second day no clinical symptoms were noted. On the morning of the third day the temperature reached 104° F. and in the evening 105° F. The pulse was irregular and weak. Depression and symptoms of irritation in the urogenous organs were noticeable. By palpation per rectum the left kidney was detected as a tumour, surrounded by a hanging oedematous tissue. The urinary bladder was distended by a large quantity of urine. Specific gravity was 1.01, the reaction was alkaline, albumine amounted to about 0.2 per cent. The test for albumose was positive, also that for haemoglobine. Microscopically, carbonates and crystals of triple phosphates were detected. The ammonia test of *Hess* was positive. Leucocytes, red blood corpuscles, and bacteria were present. Cultures showed a mixture of staphylococci, bacterium coli, and the specific bacillus. In the morning of the fourth day, the animal was found dead in the stable. The vessel used for collecting urine contained a rather clear, viscid urine with a cloudy deposit. The specific gravity was 1.035, the reaction was alkaline, and the test for albumose was positive. The albumine amounted to 0.25 per cent. Microscopically, as before.

Post-mortem examination.—Mule, twelve years old, condition fair, rigor mortis present. There was slight tympanitis, and the subcutaneous tissue was slightly infiltrated, the psoas muscle was discoloured and anaemic, almost white and friable. In the peritoneal cavity was a considerable amount of liquid. The intestines were normal in position, but were distended by gas. In the caecum was a small quantity of contents, its mucosa showed black discolourations; in the apex were a few punctiform haemorrhages. The colon showed longitudinal black streaks, and the posterior portions were slightly haemorrhagic. The rectum had rather dry contents covered with mucus, the folds were slightly thickened and patchy. All the small intestines were slate-coloured and patchy. The serosa of all intestines was slightly injected and the mesentery showed a few livid areas. The stomach had a small quantity of contents and was covered with an adherent mucus. The kidneys (*vide* illustration) were embedded in a gelatinous fat tissue; the right one weighing 1.15 kilo, the left 1.58 kilo; the capsule was thickened in parts. When the capsule was stripped off, a viscid pus escaped from a number of small abscesses. At several places between the parenchyma a fine fibrine network could be found. The dark brown cortex showed small abscesses, as described in the other cases. The papillae and the pelvis were haemorrhagic, the mucous membrane of the ureter and the bladder was normal. In the urinary bladder was about 50 c.c. of a clear urine with slightly blood-stained flocculent deposit. The super-renal glands showed a distinct haemorrhagic infiltration of the zona fasciculata. The lymphatic glands in the sacral parts of the pelvis were slightly swollen and soft. In the anterior mesenteric artery an aneurism was found. The spleen was slightly enlarged, measuring 50 × 52 × 25 cm. The capsule was slightly oedematous; dark greyish in colour, the margins were rounded and the pulpa was dark red and protruding. The liver was slightly enlarged and on section slightly oedematous. Several lobuli were enlarged and the portal lymphatic glands were all enlarged. In the pleural cavity was about 150 c.c. of liquid; both lobes of the lungs were in inspirium, and showed typical interstitial

oedema. Throughout the whole parenchyma the same nodules as observed in other cases were found. In the trachea was a small quantity of foam. There was slight imbibition of all mucous membranes of the respiratory tract. The pericardium contained about 300 c.c. liquid. The heart was slightly enlarged; there were ecchymoses along the sulcus coronarius; the myocardium was soft and discoloured in patches. In the left ventricle were a few blood coagula, and sub-endocardial haemorrhages were very distinct. Also in the right kidney were blood coagula, the valves of the pulmonary artery along the margin were slightly thickened and showed a fine deposit of fibrine. All lymphatic glands of the head and neck were slightly enlarged. Microscopically, in smears from the kidney, valves, lung nodules, liver and spleen, the bacillus could be demonstrated.

Diagnosis.—Pyæmia, toxæmia as a sequel of *Nephritis purulenta specifica*. Peri-nephritis, embolic lung-nodules, endocarditis, degeneration of the liver, and myocardium, spleen tumour and slight lymphadenitis. The bacillus could also be isolated from the spleen, lungs, kidney, and liver.

Microscopically.—The same lesions as described in the original cases were observed, with the exception that they were not developed to such a degree. On the valves was a fine, fresh, fibrine network with leucocytes and bacteria. There was a general degeneration, especially of a fatty character, in all glandular organs.

Horse 4236.—Injected on the 8th February, 1909, with 1 c.c. nephritis bacillus culture, strain "A", generation 10. In the evening the temperature was 102·2° F., and the third day it reached the maximum of 103° F., and fell during the next eight days rapidly to normal. During the fifty-four days, the animal was kept under observation, no remissions could be observed. The urine on the 7th February, 1909, was dark brown, yellow, turbid, reaction alkaline, specific gravity 1·035, and no albumine. On the 8th February, 1909, the same specific gravity of 1·035. Microscopically, carbonates, a few granular epithelial cells and leucocytes were seen. On the 9th February, 1909, the urine was light brown in colour, slightly turbid, with a specific gravity of 1·005; the reaction was alkaline and the albumine amounted to 0·01 per cent. Microscopically, crystals of triple phosphates, a few hyaline casts, leucocytes undergoing fatty degeneration and a few bacteria were found. On the 12th February, 1909, the urine was rather viscid, the specific gravity was 1·046, there was a small quantity of albumine, no bacteria, but leucocytes and casts were fairly frequent. On the 14th February, 1909, the urine was normal. On the 19th March, 1909, the specific gravity of the urine was 1·035, reaction alkaline, and it was free from pathological changes. The animal was used later in another experiment, and showed a remarkable sensibility (similar to anaphylaxia).

Donkey 2551.—Injected intraveneously on the 3rd March, 1909, with 10 c.c. of nephritis bacillus culture, strain "B", generation 11. Clinically the animal showed no alterations from normal. During the forty-eight days the animal was kept under observation, a few temperature rises in the evening with a slight albuminuria the next morning and sometimes a slight polynuclear leucocytosis (about 86·4 per cent) were observed. The daily examination of the urine was as follows:—

Date.	Colour.	Sediment.	Consistence.	Reaction.	Specific Gravity.	Albumine.	Microscopical Examination.
4 March	Light yellowish ..	Heavy	Viscid ..	Alkali	1·022	Nil	Carbonates and crystals of hippuric acid, with a few bacteria similar to the nephritis bacillus.
5 March	Dark yellowish ..	Flocculent deposit	Viscid ..	Alkali	1·035	0·05%	A few crystals of triple phosphate, leucocytes, epithelial cells, and nephritis bacillus.
6 March	Brownish ..	Slight	Mucus ..	Alkali	1·020	Very small quantity	A few leucocytes; no bacteria.
7 March	Dark yellowish ..	Nil	Viscid ..	Alkali	1·012	0·01%	Bacteria rather frequent, no nephritis bacilli.
8 March	Dark brown ..	Distinct	Rather stringy	Alkali	1·025	0·02%	Epithelial cells, triple phosphates, and a few granular casts. Leucocytes and bacteria.
9 March	Rather light ..	Slight	Viscid ..	Alkali	1·040	Nil	Corpuscular elements very rare.
10 March	Light yellowish ..	Nil	Viscid ..	Alkali	1·043	Very small quantity	A few triple phosphates crystal; a few leucocytes and bacteria.
11 March	Brownish ..	Slight	Viscid ..	Alkali	1·053	Nil	Very few leucocytes.
12 March	Light yellowish..	Slight	Viscid ..	Alkali	1·032	Nil	A few triple phosphates, and a few epithelial cells from the urinary bladder; no bacteria.
The test of the following days always revealed a normal urine, but on the—							
28 March	Rather clear ..	Fine	Viscid ..	Slightly alkalic	1·02	0·01%	A few casts with some gram-negative bacilli, which microscopically resembled nephritis bacteria.