

## Research Article

THE KOUGA MUMMIFIED<sup>S</sup> HUMAN REMAINSMARYNA STEYN<sup>1\*</sup>, JOHAN BINNEMAN<sup>2</sup> & MARIUS LOOTS<sup>1</sup><sup>1</sup>Department of Anatomy, University of Pretoria, P.O. Box 2034, Pretoria, 0001, South Africa<sup>2</sup>Department of Archaeology, Albany Museum, Somerset Street, Grahamstown, 6139, South Africa

(Received June 2006. Revised October 2006)

## ABSTRACT

This paper reports and discusses the morphological analysis of the mummified human remains found during 1999 in a rock shelter in the Kouga Mountains near Joubertina, Eastern Cape Province, South Africa. The upper part of the body was covered with *Boophane disticha* leaves, a medicinal plant still widely used by indigenous peoples in southern Africa. The plant is known for its antiseptic qualities and probably contributed to the excellent preservation of the body. The remains are those of a male, about 30–40 years of age. He was about 135–145 cm tall. No clear abnormalities could be seen from gross morphological investigation, but X-rays revealed a healed amputation of the distal part of the fifth finger of the left hand, as well as a fracture of the pelvis. This fracture most probably occurred as a result of the excavation and/or transport of the remains. Some unusual dental characteristics were observed. Radiocarbon dating indicated an age of about 2000 BP.

Keywords: mummy, amputation, Late Stone Age, Khoe-San, skeletal biology.

## INTRODUCTION

It is remarkable that mummified or desiccated human remains are not often found in South Africa, taking into account the many dry caves and shelters throughout the region. However, a few cases have been reported. One example came from a *circa* 2000 year old site at Eland Cave (Sealy *et al.* 2000). In this case (Eland Cave 2) a child of about 6–7 years was discovered in a cave, with considerable soft tissue still present. Other similar remains were found in the caves at Makapans Valley, Steenbokfontein (Jerardino *et al.* 2000) and also at Faroskop (Manhire 1993). It seems that the common element in these cases is that they were interred in a cave or rock shelter, which is dry, relatively cool and protected from the elements.

During April 1999 the mummified remains of a San hunter-gatherer were found in a rock shelter in the foothills of the Kouga Mountains near Joubertina in the Langkloof region, Eastern Cape Province, South Africa (Binneman 1999) (Fig. 1). Not only was the body remarkably well-preserved, but the find also generated much interest from local community groups and the media. After lengthy negotiations between Khoe-San community leaders and the Eastern Cape Provincial Government, the remains were removed and transported *in toto* to the Albany Museum to be studied. Owing to the sensitive nature of human remains, these remains will not be displayed and local communities will determine their final destiny.

Mummified and desiccated human remains are valuable sources of information on past lifestyles, diet and health (Aufderheide 2003). Much research has been conducted on remains that were either mummified as a result of human intervention (e.g. Egyptian mummies), or naturally/spontaneously mummified remains (e.g. Otze, the Ice Man of the Alps-Seidler

*et al.* 1992; Roberts 1993; Nedden *et al.* 1994; Recheis *et al.* 1999). Research possibilities involving mummies are numerous, and include specialized investigations such as histological analysis of various body tissues (e.g. Tapp 1986; Williams *et al.* 1995; Hess *et al.* 1998; Pabst & Hofer 1998) including immunohistochemistry (Fulcheri 1995), computer tomography (e.g. Recheis *et al.* 1999), isotopic analysis for dietary reconstruction (e.g. Macko *et al.* 1999) and analysis of the content of the gastrointestinal tract (e.g. Dickson 1997). The aim of this paper is to report on the results of the first gross morphological analysis and X-rays of the Kouga individual. Although results from other studies and information regarding the cultural events associated with the burial will be discussed and published elsewhere, some insights into burial practice and Late Stone Age behaviour will be obtained, as well as information on the physical characteristics of the people from this region. The term Khoe-San will be used throughout, in accordance with Crawhall (2006).

## BURIAL POSITION AND DATING

The remains were found against the back wall of a large rock shelter in a grave hollow some 0.80 metres deep. A large flat stone with San paintings marked the position of the body (see Pearce 2003). Underlying the painted stone were two layers of sticks, leaves and branches. The body was buried in the traditional flexed position, lying on its left side, orientated with the head in an easterly direction and facing the back wall. Most of the body, between the pelvis and the skull was covered with a thick layer of leaves from the medicinal plant *Boophane disticha* (*gijbol*, poisonous bulb or *izchwé*). This is a well-known medicinal plant that has many uses among indigenous peoples in southern Africa (Watt & Breyer-Brandwijk 1962) and the medicinal qualities of the plant and the very dry condition of the deposits may have been instrumental in the remarkable preservation of the skin tissue. Others view the presence of the plant leaves as “making a symbolic statement” (see Lewis-Williams & Pearce 2004).

Fragments of a thin rope made of the fibres of the plant



FIG. 1. Rockshelter where the individual was found.

<sup>S</sup>This paper discusses the morphological investigation of the Kouga human remains, therefore the term mummified describes the biological condition of the body and does not refer to any cultural activities or conditions.

\*Author for correspondence. E-mail: msteyn@medic.up.ac.za

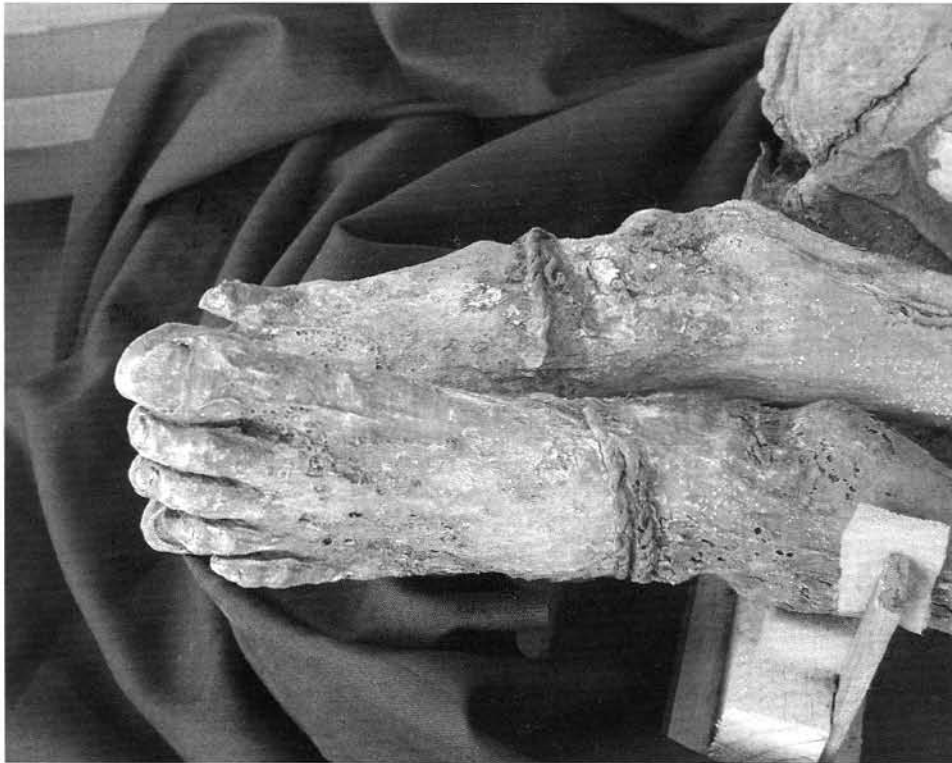

FIG. 2. Close-up of the rope attached to the feet.

*Cyperus textilis* were found around the feet, stretching backwards to the pelvis area (Fig. 2) Presumably the body was tied up in a flexed position before burial. After the plant coverage was removed, a string of seed beads was found around the neck of the mummy (Fig. 3). The only other grave goods were a few marine shell beads found near the skull. Branches from the grave were radiocarbon dated to  $1930 \pm 20$  years BP (Pta-7908) and finger bones from the right hand to  $2000 \pm 35$  BP (Pta-8361).

#### METHODS

The aim of this analysis is to provide a basic description of the remains, including age and sex. Gross morphological characteristics were therefore observed, and where possible standard anthropometric measurements were taken (Buikstra & Ubelaker 1994). The measurements were mostly done on the skeletonized sections of the body, using sliding and spreading callipers. As the long bones were measured *in situ*, a measuring tape was used instead of the traditional osteometric board. An

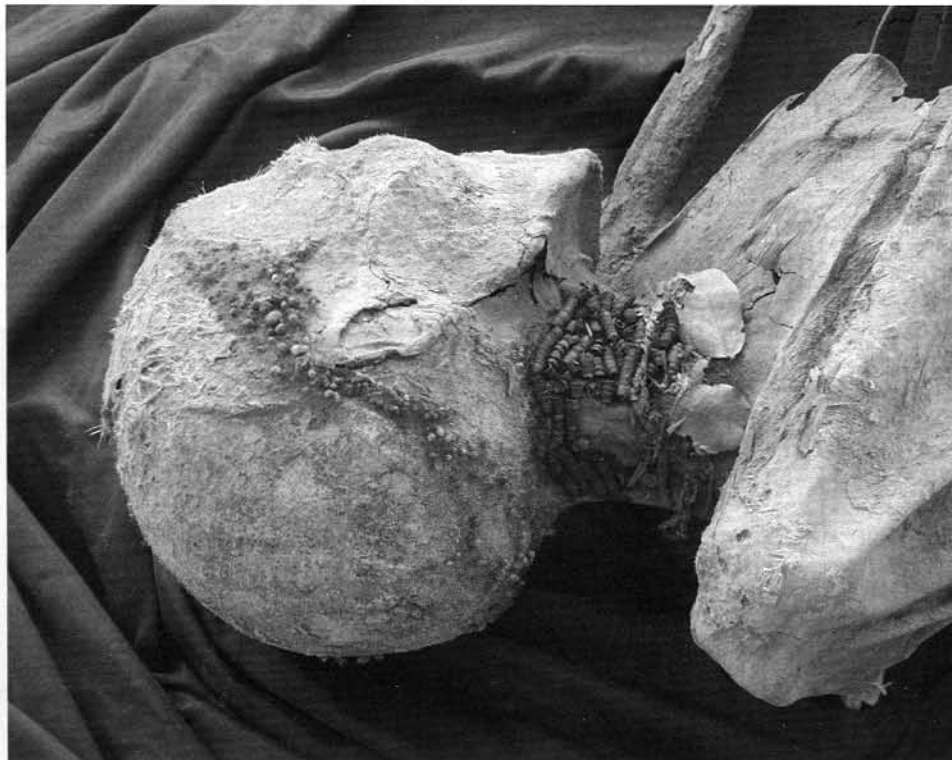

FIG. 3. The seed beads around the neck.

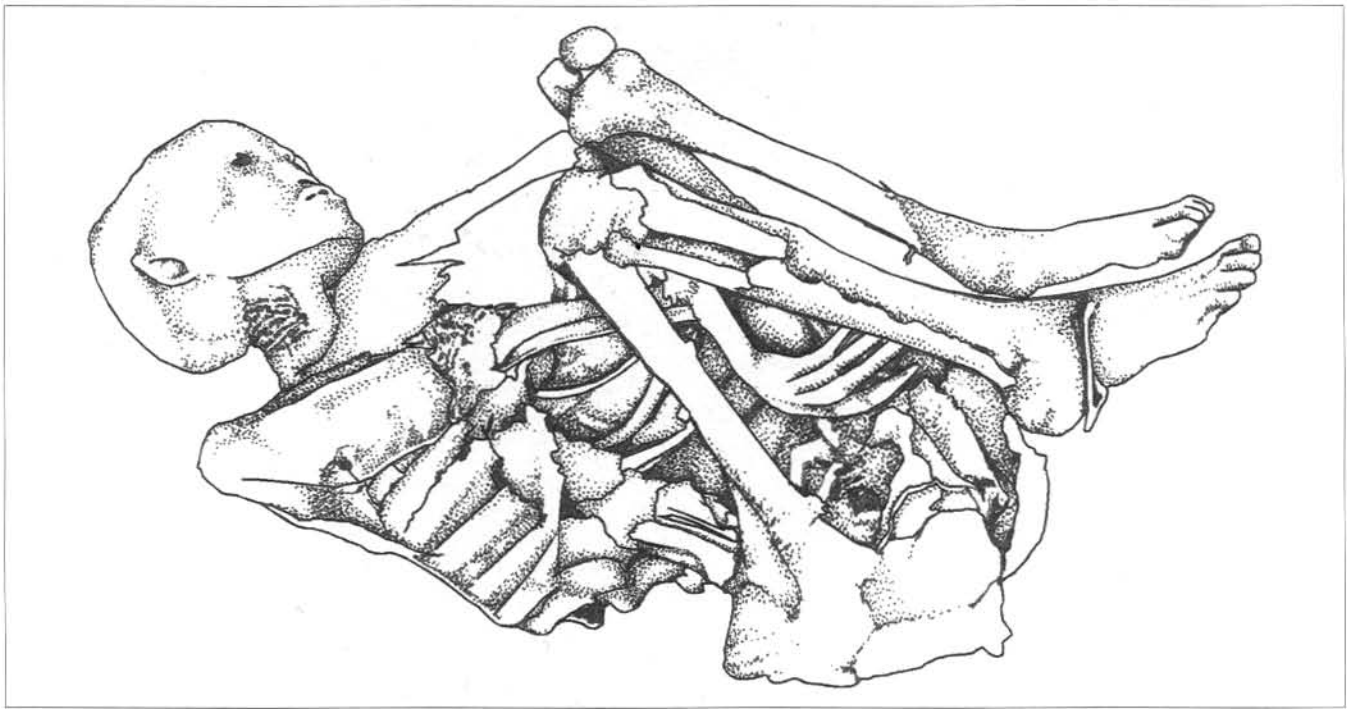


FIG. 4. Drawing of the Kouga mummy after removal of the covering plant material, indicating the burial position. Drawing by M. Pretorius.

effort was made not to disturb the body, and therefore the set of measurements is not complete. Standard techniques for age and sex determination were used (e.g. Ferembach *et al.* 1980; Krogman & İşcan 1986; Buikstra & Ubelaker 1994; Oettlé & Steyn 2000).

Various samples of soft tissues were taken, but these are still awaiting analysis. Soft tissue samples include the skin, lungs and abdominal content. Soft tissue samples of desiccated tissue taken at the posterior wall of the thorax and of the skin were small, comprising a few grams only. The abdominal content comprised mostly soil, but it may be possible that dietary fibre and/or remains of parasites can be found. Two right-sided ribs were removed by Profs T. Jenkins and H. Soodyall in 2000 for the purpose of DNA extraction. X-rays were taken of the whole body at a radiological practice in Grahamstown, but it was not possible to obtain MRI or other scans. Samples of the plant material were also kept.

## RESULTS

The remains consist of a near complete and intact desiccated human body. It was covered with a variety of leaves and branches, some of which adhered tightly to the skin. These were especially thick over the torso and skull. All leaves and associated material were carefully removed with the aid of tweezers, completely exposing the remains.

The body is complete, although the bones of the right hand are not attached to the rest of the remains. The bones from the right hand were completely skeletonized and became separated from the body during the transportation and cleaning process in the laboratory. Some of the phalanges were used for radio-carbon dating, and are no longer available for study. The individual is lying on its left side in a tightly flexed position, with the knees drawn up in front of the chest area. The heels are located next to the pelvic area, and the feet are pointing away from the body with remains of a rope still present over the arches. Both arms are between the legs and torso, with the right arm flexed at the elbow so that the forearm projects downwards between the trunk and upper legs. The left elbow

is situated just above the left knee with the left hand between the upper legs, on top of the left femur and close to the pelvis (Fig. 4).

Soft tissue covers most of the face and skull, legs and arms (Fig. 5). The skin is partially intact over the back, more so on the upper side (right) than the lower (left) side. It is nearly complete over the buttock area. The right leg is mostly covered with skin, while the foot is virtually intact. Bones of the left leg are more exposed, but the foot is intact and covered by skin. Similarly, the right arm is mostly covered by skin, while the left arm bones are skeletonized. Very little soft tissue remained in the torso area. The anterior aspects of the ribs are exposed, and some dried tissue (possibly the remains of lung tissue) can be visualized inside the chest area. No identifiable remains of abdominal organs could be found.

The skull and facial area are well preserved, with most of the skin intact. Soft tissue and eyelids are visible at the right eye, but the left orbit is completely skeletonized. The teeth are just visible behind desiccated lips. The right ear is present, but the left could not be visualized. Short, tightly curled black hair is visible on the skull, especially over the back. The skin is fairly light in colour, with a distinct yellowish appearance. This does not necessarily imply that the skin colour was similar in life, as it is uncertain how the process of desiccation influences skin colour.

The supra-orbital ridges are well developed and the superior orbital rims rounded, indicating a male (De Villiers 1968). The chin area is square, also suggesting a male. Sparse facial hair is visible on the upper lip, chin and mandible, also supporting evidence for a male individual. The pelvis was revealed in the X-rays, and showed typical male features such as a narrow sciatic notch and long and narrow sacrum (Krogman & İşcan 1986).

All visible epiphyses (knee and elbow areas) were closed, indicating an adult individual (Ferembach *et al.* 1980). The sternal end of the left fifth rib is in phase 4, indicating an age of 30–37 years (Oettlé & Steyn 2000). The fourth rib could not be used, as it had previously been removed for DNA analysis. No arthritic



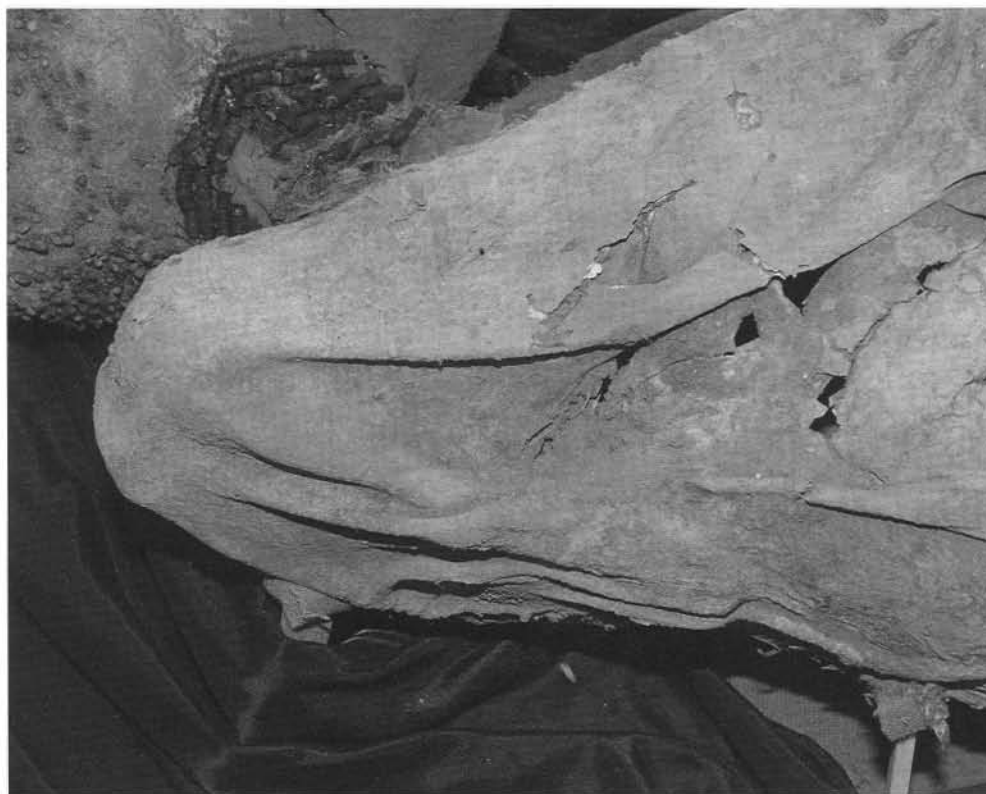

FIG. 5. Posterior view of the mummy, showing the relatively intact skin.

changes could be observed on any of the long bones or vertebrae, also indicating a young adult. This individual was thus most probably an adult between 30 and 40 years of age.

The skull showed the typical Khoe-San features such as prominent zygomae, pentagonal skull shape, wide interparietal groove and absence of prognathism (De Villiers 1968). The sparse body and facial hair are also characteristic to Khoe-San groups. The cranial and mandibular measurements that were possible are shown in Table 1.

In an attempt to determine stature, the remains were measured with a measuring tape, from heel to vertex, over the back. A length of about 145 cm was obtained. Stature was also calculated according to the method suggested by Wilson and Lundy (1994) whereby the femoral length is estimated to make up about 26.7% of the actual stature. This yielded a result of about 135 cm, which is substantially shorter than what was obtained from the estimate of the total body. Since the femur

TABLE 1. Cranial and mandibular measurements of the Kouga mummy (Buikstra & Ubelaker 1994).

Dimension	mm
Maximum cranial length*	177
Maximum cranial breadth*	141
Bizygomatic diameter*	127
Upper facial height*	±53
Min. frontal breadth*	95
Upper facial breadth*	109
Nasal height	±37
Nasal breadth	±32
Orbital breadth	36
Orbital height	28
Total facial height	±95
Skull circumference	513
Bigonial width	±79

\*Measurement includes skin thickness which was estimated not to exceed 1 mm.

could obviously not be measured with an osteometric board, it is quite possible that its length was underestimated. The postcranial measurements are shown in Table 2.

The teeth were very difficult to analyse macroscopically, as few of them were visible. Some of the teeth could be seen through the partially open mouth. X-rays indicated severe attrition, especially on the posterior teeth. An unusual feature is that both maxillary canines are impacted. The left mandibular third molar is absent, while the maxillary third molar opposing this absent tooth shows over-eruption. Residual roots at the position of the first lower right mandibular molar are indicative of severe caries (Herman Bernitz, pers. comm. 2004).

The skin was examined with the naked eye under normal and fluorescent light, and no signs of disease, wounds or decorations (tattoos) could be seen. The left tibia was nearly

TABLE 2. Postcranial measurements of the Kouga mummy (Buikstra & Ubelaker 1994).

Dimension	mm
Humerus, epicondylar breadth	50
Humerus, min. diameter, midshaft	17
Femur, bicondylar length	±360
Femur, epicondylar breadth	73
Femur, ant-post midshaft diameter	±23
Femur, med-lat midshaft diameter	±26
Femur, midshaft circumference	84
Tibia, length	±312
Tibia, max. prox. epiphyseal breadth	69
Tibia, max. diameter at nutrient foramen	31
Tibia, med-lat diameter at nutrient foramen	22
Tibia, circumference at nutrient foramen	82
Fibula, max. length	95
Fibula, max. diameter at midshaft	5

All measured on right side. med-lat = mediolateral; ant-post = anteroposterior; max. = maximum; min. = minimum; sup = superior.

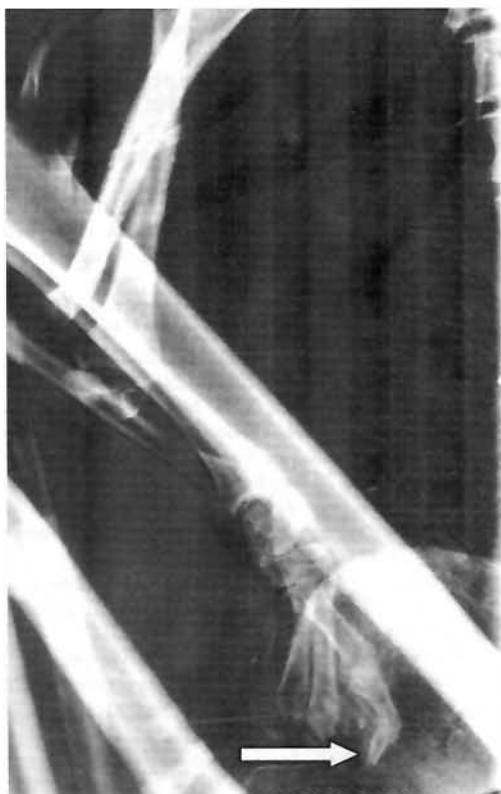

FIG. 6. X-ray image of the amputated last digit of the left fifth finger.

completely exposed, and looked healthy with no signs of subperiosteal bone growth. No cribra orbitalia was present. With gross morphological analysis, it was found that the distal part of the left fifth finger was missing, and initially it was assumed that it was lost as part of the excavation process. However, on X-ray analysis it could be seen that the distal phalanx of this finger was amputated, so that complete healing had taken place at the distal end of the middle phalanx (Fig. 6).

X-rays of the pelvis also showed the presence of a pelvic fracture through the superior and inferior rami of the right os coxa (Fig. 7). This most probably happened during the process of excavation/transport of the remains. Another interesting find was that the individual had only 11 ribs on each side. This is a congenital anomaly. From the X-rays it is not clear whether there are fewer thoracic vertebrae and/or more lumbar vertebrae, but a CT scan may shed more light on this.

## DISCUSSION

The remains are those of a male, Khoekhoen individual. He was between 30 and 40 years old when he died, and was only about 145 cm tall. Some unusual dental characteristics are present, such as inverted upper canines. Further analysis is needed.

According to Wilson and Lundy (1994), recorded statures of recently living San are similar to those of prehistoric individuals. San stature decreased after 3000 BP, and may have increased again after 2000 BP. In their sample of 26 males the mean stature was found to be 151 cm, with four individuals being shorter than 145 cm. Although towards the shorter end of the spectrum the stature of the Kouga male, 145 cm or slightly less, is not unusual for a San male from this time period. In the Wilson and Lundy study all the shorter-than-150 cm males were found to be from the 2000–3000 BP sample. This fits well with the evidence from the Kouga individual. All Khoekhoen males in this study had statures between 150.5 and 176.1 cm, thus making it very unlikely that the Kouga individual was

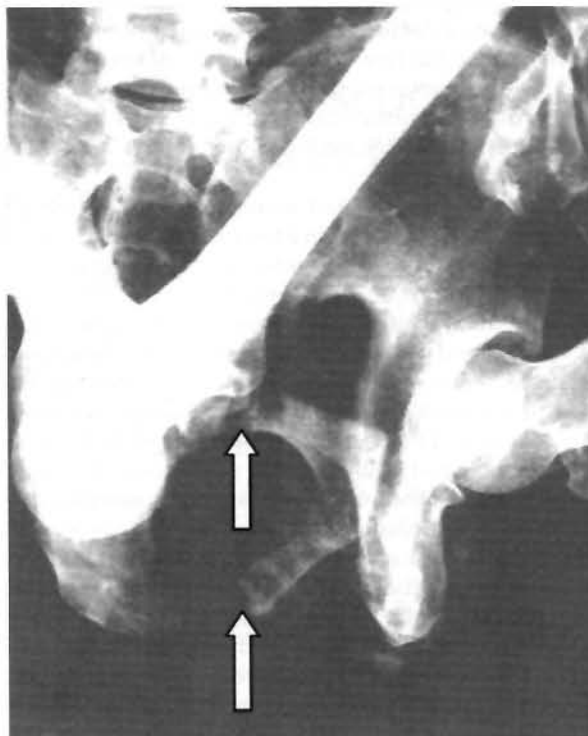

FIG. 7. X-ray image of the pelvic fracture. Note the spaces between the medial and lateral parts of the rami.

Khoekhoen. The short stature therefore suggests that he was more likely to have been from San rather than Khoekhoen origin.

Pfeiffer and Sealy (2006) also investigated body size and stature among Holocene foragers of the western and southern Cape. They found that there is an increased variability in femoral length between 4000 and 2000 BP, with much smaller and shorter femora in this period. Femoral length started to increase again before 2000 BP, which is well before the advent of pastoralism in this region. Decreased femoral lengths may have been related to the amount of food rather than the type of food that was consumed. The femur length of the Kouga individual, being about 360 mm, is much shorter than any of the lengths quoted by Pfeiffer and Sealy, although it should be kept in mind that this length is only an estimate, and is the bicondylar length whereas that of Pfeiffer and Sealy is the maximum length. Nevertheless, the Kouga individual was definitely on the shorter end of the spectrum, at a time where some increases in stature were observed in other groups.

The amputated distal phalanx of the left fifth finger is interesting. According to Mitchell and Plug (1997) the ritual amputation of finger joints by San groups occurred frequently in the past. Drennan (1937) also described finger mutilation in "Bushmen". It seems that these amputations were performed in very early childhood, either by a reed or by placing a sharp instrument on the finger and hitting it with a heavy blow. Various reasons for this practice were offered, including that this will ensure that a child grows up, to cure young children of disease, or ensuring a safe journey to a place after death. According to Drennan (1937) and Mitchell and Plug (1997), however, these amputations were done on the right hand if it was a boy, and on the left hand if it was a girl. This is in contrast with what is observed in the Kouga individual, since this is a male but with an amputated phalanx on the left hand. Unfortunately the right hand is no longer available for analysis. It thus seems that this practice is a very old one, but the meaning of it may have changed over the years.

The cause of death in this individual is not clear. If the observed pelvic fracture occurred before death, that clearly would have been of a serious enough nature to cause death. It also may have occurred during the process of excavation and/or transportation. Scanning of the remains may provide some insight into this.

Mummified or desiccated human remains are not often found in South Africa, although a few cases have been reported. Other examples came from another *circa* 2000 year old site at Eland Cave (Sealy *et al.* 2000), and Makapans Valley. These cases were interred in a cave or rock shelter, which is dry, relatively cool and protected from the elements. The unusually good preservation of the Kouga individual is most probably related to favourable environmental conditions such as the relative dryness of the shelter and the types of plant material that covered the body. However, the processes contributing to the preservation of the soft tissue are not fully understood, and more research is needed.

As these are the only remains of this precise kind ever found in southern Africa, it seems unlikely that mummification was a standard practice among Khoe-San people, but does not rule out individual cases. Whether the Kouga individual was intentionally mummified, however, remains an open question. Until the discovery of other such remains it would seem as if the preservation of these remains was accidental, but future research may prove otherwise. The remains will not be displayed but will remain in the Albany Museum, Grahamstown, until local communities determine its final destiny.

#### ACKNOWLEDGEMENTS

The authors thank Dr Herman Bernitz from the University of Pretoria for his opinion on the dental X-rays, and Dr Höll of the Pretoria Academic Hospital for an opinion on the other X-rays. The X-rays were taken at the practice of Drs Visser, Erasmus and Partners. The research of M. Steyn is supported by the National Research Foundation. J. Binneman acknowledges the support and assistance of the Albany Museum.

#### REFERENCES

- Aufderheide, A.C. 2003. *The Scientific Study of Mummies*. Cambridge: Cambridge University Press.
- Binneman, J.N.F. 1999. Mummified human remains from the Kouga Mountains, Eastern Cape. *The Digging Stick* 16: 1–2.
- Buikstra, J.E. & Ubelaker, D.H. (eds) 1994. Standards for data collection from human skeletal remains. *Arkansas Archaeological Survey Research Series* No. 44.
- Crawhall, N. 2006. Languages, genetics and archaeology: problems and the possibilities in Africa. In: Soodyall, M (ed.) *The Prehistory of Africa: Tracing the Lineage of Modern Man*: 109–124. Jeppesstown: Jonathan Ball Publishers.
- De Villiers, H. 1968. *The Skull of the South African Negro*. Johannesburg: Witwatersrand University Press.
- Dickson, J.H. 1997. The moss from the Tyrolean Iceman's colon. *Journal of Bryology* 19: 449–451.
- Drennan, M.R. 1937. Finger mutilation in the Bushmen. *Bantu Studies* 11: 247–249.
- Ferembach, D., Schwidetzky, I. & Stloukal, M. 1980. Recommendations for age and sex diagnoses of skeletons. *Journal of Human Evolution* 9: 517–549.
- Fulcheri, E. 1995. Immunohistochemistry: a new outlook in histopathology. *Journal of Biological Research* 71(4): 105–110.
- Hess, M.W., Klima, G., Pfaller, K., Kunzel, K.H. & Gaber, O. 1998. Histological investigations on the Tyrolean Ice man. *American Journal of Physical Anthropology* 106: 521–532.
- Jerardino, A., Sealy, J. & Pfeiffer, S. 2000. An infant burial from Steenbokfontein Cave, West Coast, South Africa: its archaeological, nutritional and anatomical context. *South African Archaeological Bulletin* 55: 44–48.
- Krogman, W.M. & İşcan, M.Y. 1986. *The Human Skeleton in Forensic Medicine*. Springfield: Charles C. Thomas.
- Lewis-Williams, D. & Pearce, D. 2004. *San Spirituality: Roots, Expressions and Social Consequences*. Cape Town: Double Storey Books.
- Macko, S.A., Lubec, G., Teschler-Nicola, M., Andrushevich, V. & Engel, M.H. 1999. The Ice Man's diet as reflected by the stable nitrogen and carbon isotopic composition of his hair. *The Federation of American Societies for Experimental Biology Journal* 13: 559–562.
- Manhire, A. 1993. A report on the excavations at the Faraoskop rock shelter in the Graafwater district of the South-western Cape. *Southern African Field Archaeology* 2: 3–23.
- Mitchell, P.J. & Plug, I. 1997. Ritual mutilation in Southern Africa. In: Wadley, L. (ed.). *Our Gendered Past*: 135–166. Johannesburg: Witwatersrand University Press.
- Nedden, D., Knapp, R., Wicke K., Judmaier, W., Murph., W.A., Seidler, H. & Platzer, W. 1994. Skull of a 5300-year-old mummy: reproduction and investigation with CT-guided stereolithography. *Radiology* 193: 269–272.
- Oettlé, A.C. & Steyn, M. 2000. Age estimation from sternal ends of ribs by phase analysis in South African Blacks. *Journal of Forensic Sciences* 45(5): 1071–1079.
- Pabst, M.A. & Hofer, F. 1998. Deposits of different origin in the lungs of the 5300-year-old Tyrolean Ice man. *American Journal of Physical Anthropology* 107: 1–12.
- Pearce, D.G. 2003. The Tierkloof burial stones. *South African Journal of Science* 99: 125–127.
- Pfeiffer, S. & Sealy, J. 2006. Body size among Holocene foragers of the Cape Ecozone, southern Africa. *American Journal of Physical Anthropology* 129: 1–11.
- Roberts, D. 1993. The Ice man. *National Geographic* June: 37–67.
- Recheis, W., Weber, G.W., Schafer, K., Knapp, R., Seidler, H. & Nedden D. 1999. Virtual reality and anthropology. *European Journal of Radiology* 31: 88–96.
- Sealy, J., Pfeiffer, S., Yates, R., Willmore, K., Manhire, A., Maggs, T. & Lanham, J. 2000. Hunter-gatherer child burials from the Pakhuis mountains, Western Cape: growth, diet and burial practices in the Late Holocene. *South African Archaeological Bulletin* 55: 32–43.
- Seidler, H., Bernhard, W., Tescher-Nicola, M., Platzer, W., Nedden, Z., Henn, R., Oberhauser, A. & Sjøvold, T. 1992. Some anthropological aspects of the prehistoric Tyrolean Ice Man. *Science* 258: 455–457.
- Tapp, E. 1986. Histology and histopathology of the Manchester mummy. In: David, A.R. & Tapp, E. (eds) *Proceedings of the Science in Egyptology symposia*: 39–45. Manchester: Manchester University Press.
- Watt, J. & Breyer-Brandwijk, M.G. 1962. *The Medicinal and Poisonous Plants of Southern and Eastern Africa*. Edinburgh: Livingstone.
- Williams, A.C., Edwards, H.G.M. & Barry, B.W. 1995. The Iceman: molecular structure of 5200-year-old skin characterized by Raman spectroscopy and electron microscopy. *Biochimica et Biophysica Acta* 1246: 98–105.
- Wilson, M.E. & Lundy, J.K. 1994. Estimated living statures of dated Khoisan skeletons from the south-western coastal region of South Africa. *South African Archaeological Bulletin* 49: 2–8.