

# Previously undiagnosed MVA trauma to TMJ

SADJ April 2016, Vol 71 no 3 p125

Z Yakoob<sup>1</sup>, A Uys<sup>2</sup>

Temporomandibular disorders (TMD) have a multifactorial aetiology, one suggestion being that facial trauma caused by motor vehicle accidents (MVA) may result in TMD. However, the relationship is somewhat controversial as there is no conclusive evidence.<sup>1</sup> Trauma to the temporomandibular joint (TMJ) can be classified as micro- or macro-trauma. The degree of severity varies from malocclusion, whiplash during MVA and facial fractures including mandibular and condylar fractures. Trauma to the TMJ whether direct or indirect may affect the balance of the TMJ, resulting in degeneration of the articular cartilage by altering the mechanical properties of the disc. A number of problems may be experienced including dislocation, effusion, fibrous adhesions, ankylosis, fracture of the condylar head or neck and limited jaw opening.<sup>2</sup> A long-term effect of MVA to the TMJ is a secondary malocclusion developing long after the primary treatment. The most common reason for this malocclusion is that the anteroposterior or transverse dimensions have been altered. In cases where condylar fractures were undiagnosed an open bite will develop, leading to a retrognathic mandible.<sup>3</sup>

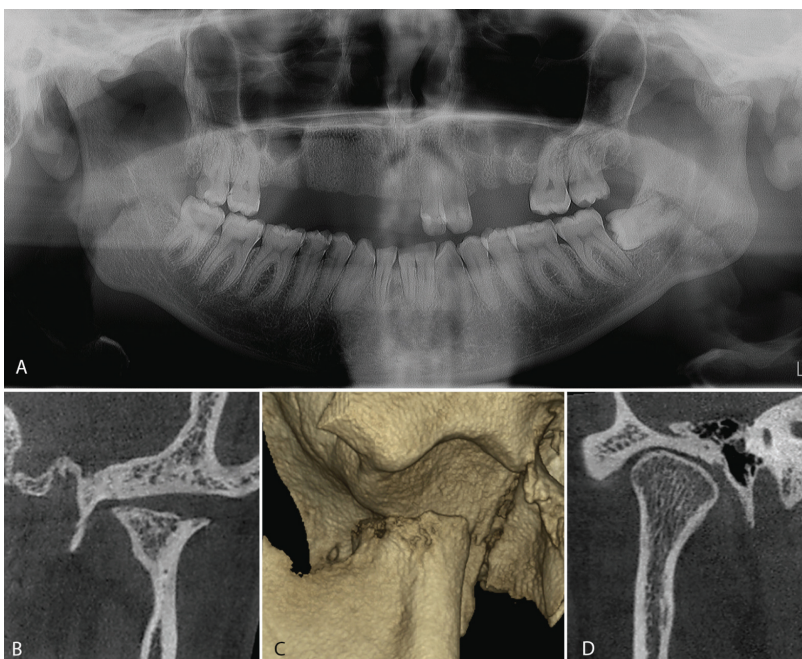
## CASE HISTORY

A 24 year old female with a history of a previous MVA presented at our Oral Health hospital. The patient had sustained the injuries three years ago and had not received treatment. The main complaint was pain in the TMJ during function as well as a limited range of movement. A panoramic radiograph was taken at the initial examination.

During trauma the fractured segment is often displaced antero-medially due to the pull of the lateral pterygoid muscle. Degenerative changes may occur with time and these changes are more severe if the condyle is displaced.

## ACRONYMS

<b>CBCT:</b>	Cone beam computed tomography
<b>MVA:</b>	motor vehicle accidents
<b>TMD:</b>	temporomandibular disorders
<b>TMJ:</b>	temporomandibular joint



**Figure A:** The panoramic radiograph shows the loss of maxillary teeth as a result of the trauma. The left condyle head is anteriorly displaced with an abnormal shape probably due to remodelling.

**Figure B:** Coronal cone beam computed tomography (CBCT) of the left TMJ shows a flattened articular fossa. The condyle head is severely deformed and the superior surface is flattened and irregular. The joint space varies from medial to lateral.

**Figure C:** Reconstructed 3D of the left TMJ shows the condyle displaced from the normal position to more anteriorly. Note the irregular surface of the condyle head.

**Figure D:** Coronal CBCT of the right TMJ shows a normal articular fossa, condyle head shape and joint space.

In cases with trauma to the anterior mandible the possibility of a condylar fracture must always be considered.

## References

1. Kolbinson D, Epstein J, Burgess J, Senthilvelan A. Temporomandibular disorders, headaches, and neck pain after motor vehicle accidents: a pilot investigation of persistence and litigation effects. *J Prosthet Dent* 1997; 77: 47-51.
2. Yun P, Kim Y. The role of facial trauma as a possible etiologic factor in temporomandibular joint disorder. *J Oral Maxillofac Surg* 2005; 63:1576-83.
3. Laine P, Kontio R, Salo A, Mesimäki K, Lindqvist C, Suuronen R. Secondary correction of malocclusion after treatment of maxillofacial trauma. *J Oral Maxillofac Surg* 2004; 62:1312-20.

1. **Zarah Yakoob:** BChD, PDD, MSc (Maxillofacial Radiology), School of Dentistry, University of Pretoria. E-mail: zarah.yakoob@up.ac.za
2. **André Uys:** BSc, BChD, Dip. Odont.(Materials), Dip. Odont.(Endo), MSc(Odont.), School of Dentistry, University of Pretoria. E-mail: andre.uys@up.ac.za