

Anatomical Studies, No. 39: A Congenital Meningeal Lipoma in a Sheep.

By H. H. CURSON, F.R.C.V.S., Dr.Med.Vet., Veterinary Research Officer, Onderstepoort.

DR. E. M. ROBINSON kindly brought me, at the end of May, 1932, the head of a cross-bred (Persian-Merino) wether, 18 months' of age, on the parietal region of which was a firm tumour (see Fig. 1). The history was that the tumour was present at birth, but that as the sheep became older, so did the " lump " become larger.

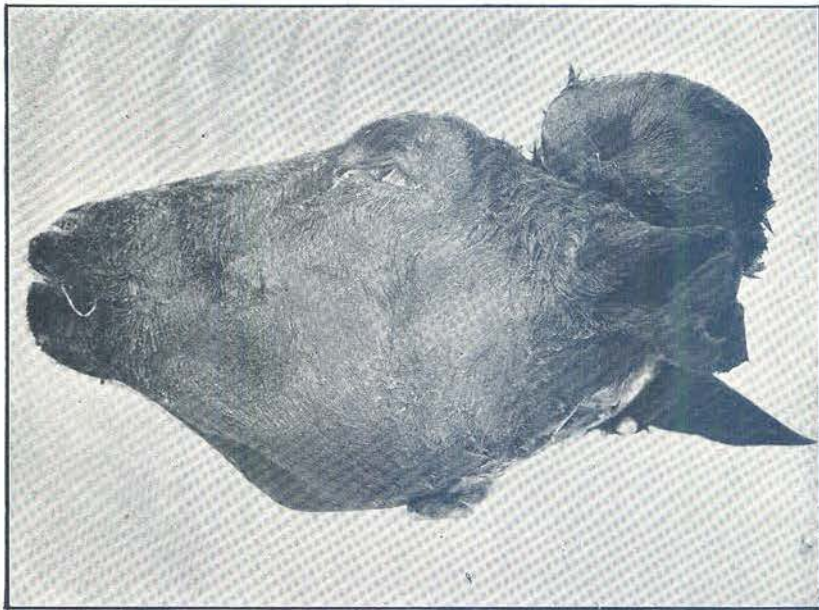

Fig. 1. A parietal tumour in a hamel.

On removal it was found to weigh 227 gm. and to have a diameter of 9 cm. and a height of 5 cm. The cranial wall, at the region of the base of the tumour, was found to be perforated by a circular opening, diameter 3·5 cm., involving the parietal and interparietal bones (see Fig. 2). Within the tumour was a cavity 2·25 cm. in width and 2·5 cm. in depth, lined presumably by the inner layer of the dura mater. Visible through the circular opening referred to above was the anterior part of the vermis of the cerebellum

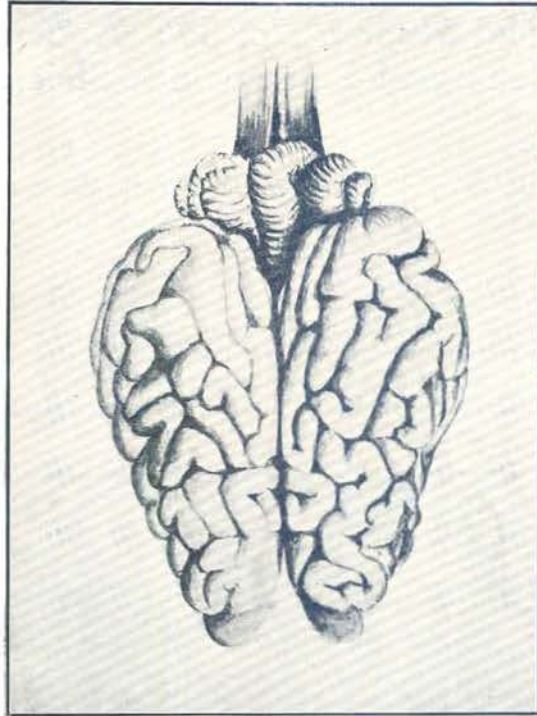


Fig. 2. (a) Normal.

and the posterior or occipital poles of the cerebral hemispheres. Macroscopic examination of the dorsal surface of the encephalon showed not only almost complete fusion of the cerebral hemispheres, but also an irregular arrangement of the gyri and sulci [see Fig. 2 (b)].

Histologically, my colleague, Mr. C. Jackson, B.V.Sc., identifies the tumour as a congenital meningeal lipoma.

Embryologically, it is believed that the growth commenced intracranially within the dura mater. Development occurred outwards before ossification of the parietal bones, and the undue pressure thus exerted no doubt contributed to the irregularity of the encephalon.

In conclusion, thanks are due particularly to J. Todd, Esq., P.O. Immerpan, Northern Transvaal for handing the material to Dr. Robinson.

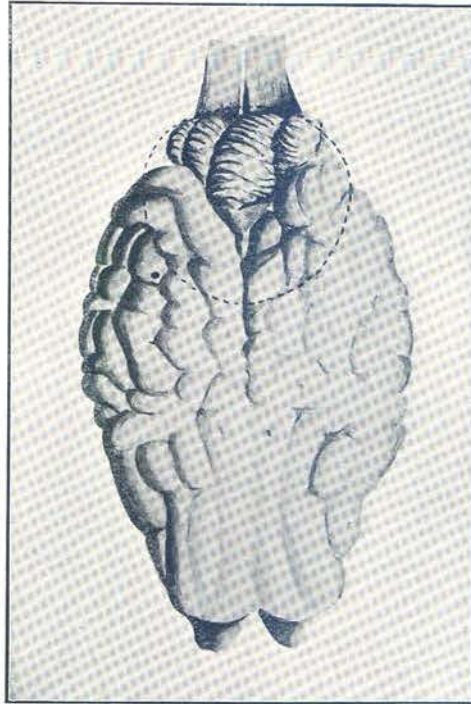


Fig. 2. (b) Abnormal; dotted line indicates rim of bony opening.