

Thoracic Outlet Syndrome in a Patient With Absent Scalenus Anterior Muscle

Robert M. Collins, MBBCh, MSc,* Jasvanti Bhana, BSc, MBBCh,*† Jonathan S. Patricios, MBBCh, MMedSci,*
 Andre Du Plessis, MBChB, MMed,‡ Martin Veller, MBBCh, MMed,§ Donovan Schultz, BTech, MScMed, MMedSci,
 PhD,‡ and Dina C. Janse van Rensburg, MD, MMed, MSc, MBChB*

Abstract: This case report describes the rare anomaly of an absent right anterior scalene muscle presenting with the symptoms and signs of the thoracic outlet syndrome. The thoracic outlet syndrome in our patient can be attributed to the absence of the right anterior scalene muscle, which resulted in the brachial plexus being in proximity to the subclavian vein and artery in a narrowed and abnormal interscalene space. In addition, the absence of the anterior scalene muscle resulted in the neurovascular structures being compressed onto the first rib in the costoclavicular space. The most likely cause of the presentation is, however, the possibility of the presence of aberrant muscle slips, which would cause compression of the structures in the anterior (venous) and posterior (neurological) sections of the thoracic outlet.

Key Words: thoracic outlet syndrome, absent anterior scalene muscle, thoracic outlet

INTRODUCTION

Thoracic outlet syndrome (TOS) is a group of conditions resulting from the compression of the neurovascular structures that course from the neck to the axilla through the thoracic outlet. Thoracic outlet syndrome may present with a spectrum of clinical scenarios based on variations in the structures compressed in individual patients. The most common site of neurovascular compression is the costoclavicular space between the clavicle and the first rib (costoclavicular syndrome). Other sites of compression are the triangle formed by the anterior scalene muscle, the middle scalene muscle and the upper border of the first rib (anterior scalene syndrome), and the angle between the coracoid process and the pectoralis minor insertion (hyperabduction syndrome or pectoralis minor syndrome).

There are many examples cited of anatomical variations of the anterior scalene muscle presenting with signs and symptoms of TOS (anterior scalene or scalenus anticus syndrome).¹⁻³ This case report describes a patient presenting with neurovascular symptoms typical of TOS, where the causative factor was the rare anomaly of an absent right anterior scalene muscle. This variant has, to the best of our knowledge, only been described in 1 cadaver case to date. Murakami et al³ described it in an 89-year-old Japanese female patient who died of heart failure. As a substitute for this muscle, some aberrant muscle slips arose from the lower vertebrae and descended in front of the ventral rami of the lower cervical nerves.

CASE REPORT

A 40-year-old female patient presented with pain in the right acromioclavicular joint caused by a blow from a horse's head. Unrelated to the recent trauma, she had experienced pain and paresthesia of the right shoulder and lateral aspect of the right upper arm for 4 years. Magnetic resonance imaging of the cervical spine performed 4 years before to investigate the paresthesia revealed no abnormality to explain the symptoms. The patient was right-hand dominant and was involved in horse-riding activities. She had never previously been involved in over-head sporting activities such as swimming or tennis.

Examination revealed a distinctly abnormal posture. In what the patient believed to be her neutral posture, she elevated her right shoulder relative to the left when seated, as this relieved symptoms in the right arm (Figure 1). Within 30 seconds of placing the shoulder in the anatomically symmetric position, the patient experienced paresthesia in a C8-T1 distribution, accompanied by a blue discoloration of the hand and fingers. The maximal forearm diameter of the right arm was 26 cm compared with 30 cm on the left arm. Radial pulses were normal on both sides. No other signs were evident in the "neutral" position.

Cervical spine x-rays revealed no abnormalities. A Doppler ultrasound examination of the subclavian veins was also normal. A venogram of the subclavian veins was then performed to exclude the presence of a subclavian vein thrombosis.

Because the symptoms were only present with the arm in an anatomically symmetric position, the venogram was performed in both anatomic and "neutral" positions (Figure 2). Both venograms showed a filling defect in the subclavian vein at the level of the anterior scalene muscle, which was thought to be caused by a hypertrophied anterior scalene muscle.


Electrodiagnostic studies were performed, which consisted of median and ulnar sensory, orthodromic palmar stimulation with recordings from the median nerve, and ulnar nerve at a distance of

From the *Section Sports Medicine, University of Pretoria, Pretoria, South Africa; †AstraZeneca Pharmaceuticals, Johannesburg, South Africa; ‡Netcare Union Hospital, Johannesburg, South Africa; and §Department of Surgery, University of Witwatersrand, Johannesburg, South Africa.

The authors report no conflicts of interest.

Corresponding Author: Robert M. Collins, MBBCh, MSc, Section Sports Medicine, University of Pretoria, PO Box 3264, Houghton, Johannesburg 2014, South Africa (robcollins@wol.co.za).

FIGURE 1. A, Anatomically symmetric position. B, "Neutral" position: right shoulder elevated relative to the left shoulder.



8.5 cm. Sensory nerve action potential amplitudes and compound muscle action potential amplitude (CMAP) interside differences of 20% were considered significant. The symptomatic right side showed reduced ulnar sensory orthodromic amplitude of more than 35% compared with the left, with a 25% reduction in median motor nerve CMAP amplitude on the right. F-wave studies showed a delayed F-wave latency best demonstrated in ulnar nerve [C8-T1] distribution, when the arm was placed in an anatomically symmetric position; whereas, near-normal F-wave latency was demonstrated in the "neutral" position. We noted a blue discoloration of the hand accompanying the electrophysiological changes demonstrated in the anatomic position. The electrodiagnostic findings were therefore consistent with a chronic lower trunk lesion.

No abnormality of the thoracic outlet could be seen on ultrasound; it was assumed that the filling defect was caused by a hypertrophied anterior scalene muscle, and conservative management was initiated. This consisted of regular physiotherapy to release the tight muscles in the neck and shoulder girdle, and to strengthen the scapular stabilizers. The patient's symptoms improved markedly within approximately a month.

However, she underwent a period of extreme emotional stress resulting in a recurrence of symptoms, with aggravation of the paresthesia and pain in the arm until it was virtually permanently present. Unfortunately, physiotherapy was no longer effective as a treatment.

We considered giving her a course of Botox injections into the anterior scalene muscle to release the spasm, but further investigation was required to prove the presumptive diagnosis of anterior scalene hypertrophy. Magnetic resonance imaging scan of the thoracic outlet was noncontributory. Computed tomographic (CT) venography (Figure 3) of the thoracic outlet showed an absent anterior scalene muscle on the right. The subclavian vein was therefore posteriorly displaced, seeming to cause pressure on the artery and brachial plexus.

Despite rigorous physiotherapy, the symptoms persisted, and we decided to decompress the thoracic outlet surgically. A first rib resection through supraclavicular approach was performed. Intraoperatively, the anterior scalene muscle was noted to be absent from its usual position. No other anatomical variations were noted at surgery. The patient

experienced no postsurgical complications. The pain, paresthesia, and discoloration of the arm resolved completely from the moment she was conscious postoperatively.

DISCUSSION

Financial constraints delayed the full investigation of our patient from the outset, and a presumptive diagnosis of hypertrophied anterior scalene muscle was made. The later CT venogram disproved this, and the absence of an anterior scalene muscle was confirmed at the surgical decompression of the thoracic outlet. It is unusual for symptoms of TOS to resolve with physical therapy, if a structural anomaly is the cause. Our patient subjectively described a near complete recovery, only to relapse at a later stage. We can only presume that she overstated her early recovery, or we would have expected the same level of recovery later in her treatment.

Our case report is, to the best of our knowledge, the first reported case of TOS resulting from the congenital absence of an anterior scalene muscle. As mentioned earlier, Murakami et al³ reported an absent anterior scalene muscle in an 89-year-old female cadaver case.

In their case, as a substitute for this muscle, some aberrant muscle slips arose from the lower vertebrae and descended in front of the ventral rami of the lower cervical nerves. These aberrant slips ran between the ventral rami of the eighth cervical and first thoracic nerves, and were fused with the right middle scalene muscle. Thus, the subclavian artery and vein ran in front of the aberrant slips, together with the ventral ramus of the first thoracic nerve.

In our patient, the possible causes of the TOS can be attributed to the absence of the right anterior scalene muscle, resulting in proximity of the brachial plexus to the subclavian vein and artery in a narrowed and abnormal interscalene space, and the absence of the anterior scalene muscle that

FIGURE 2. A, Right subclavian vein shows narrowing, where it crosses the anterior portion of the first rib in the neutral position. B, The external compression on the vein from superior is again seen in the anatomically symmetric position.

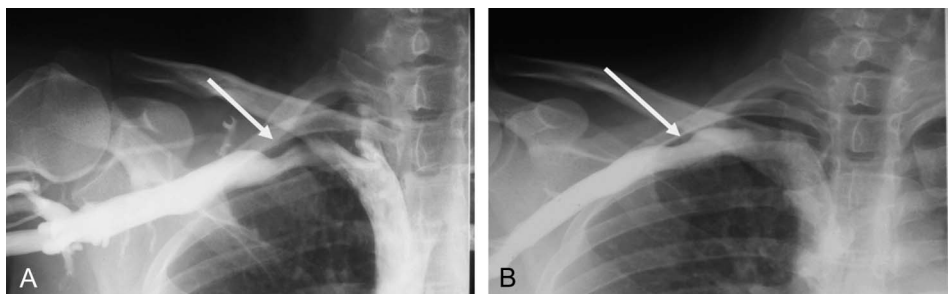
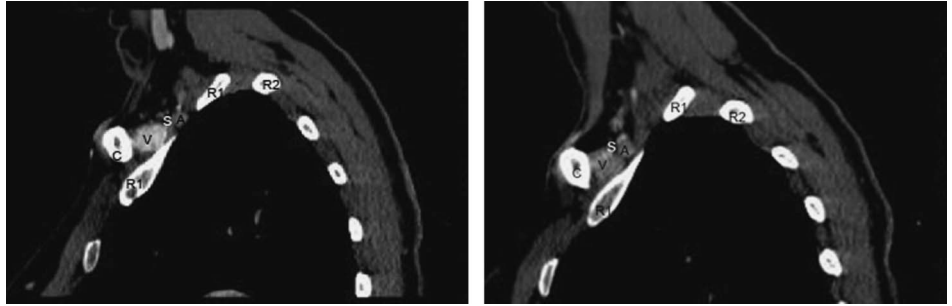


FIGURE 3. Left: C, clavicle; R1, first rib; R2, posterior second rib; V, subclavian vein; A, subclavian artery; S in white, extending inferior, vertical distal portion of M scalenus anterior just proximal to its insertion into the first rib. Nerves from the brachial plexus are seen posterior to the artery. Right side: C, clavicle; R1, first rib; R2, posterior second rib; V, subclavian vein; A, subclavian artery; S in white, absent M scalenus anterior



comment on comparing right and left in the same patient, it is apparent that no anterior scalene muscle is present inferior to the position marked "S" on the right. Also, noted is that the posterior aspect of the left subclavian vein is flat and kept in position by the scalene muscle posterior. Viewing the right side, a convex unsupported posterior aspect of the vein is noted, extending inferior to the artery.

resulted in compression of the neurovascular structures onto the first rib in the costoclavicular space. The most likely cause of the presentation is, however, the possibility of the presence of aberrant muscle slips, which would cause compression of the structures in the anterior (venous) and posterior (neurological) sections of the thoracic outlet.

All clinicians should therefore be aware, when patients present with symptoms suggestive of TOS, of the anatomical variations that can exist, and the varied and often nonclassical presentations, which can pose diagnostic dilemmas. These anatomic variations are critically important in the treatment

and management decisions undertaken in patients presenting with TOS.

REFERENCES

1. Baltopoulos P, Tsintzos C, Prionos G, et al. Exercise induced scalenus syndrome. *Am J Sports Med.* 2008;36:369–374.
2. Harry WG, Bennett JDC, Guha SC. Scalene muscles and the brachial plexus: anatomical variations and their clinical significance. *Clin Anat.* 1997;10:250–252.
3. Murakami S, Horiuchi K, Yamamoto C, et al. Absence of scalenus anterior muscle. *Acta Med Okayama.* 2003;57:159–161.